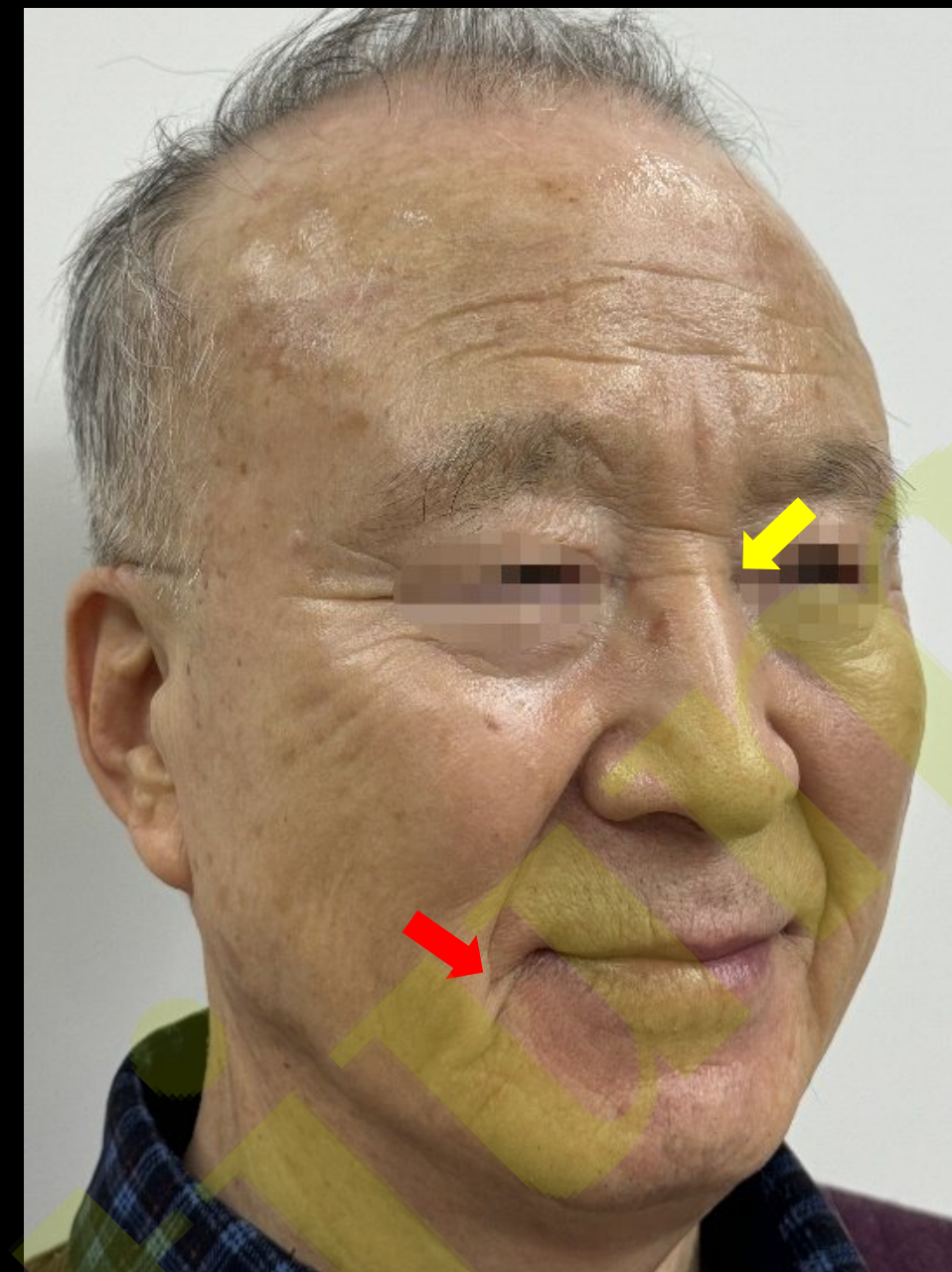
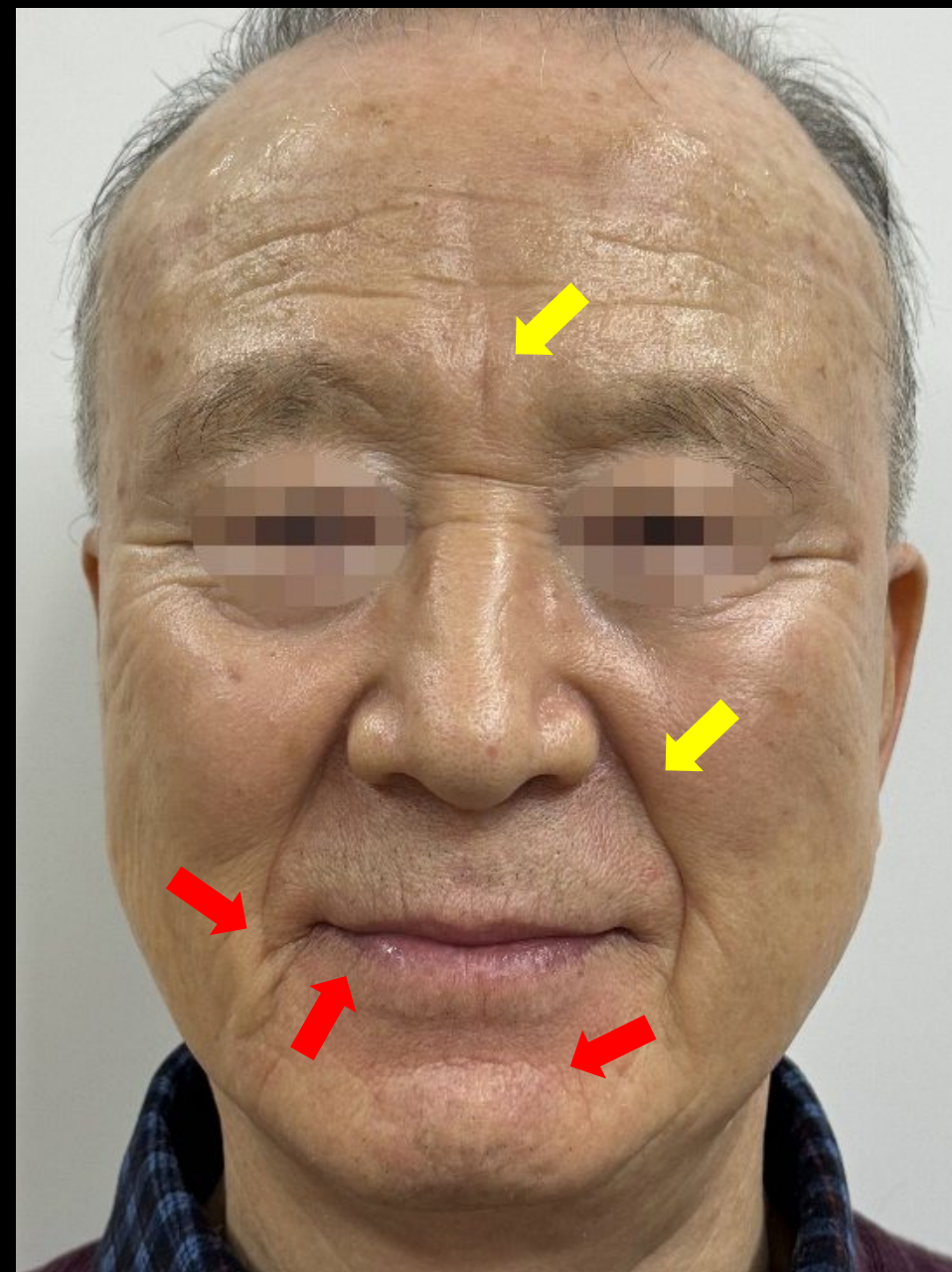
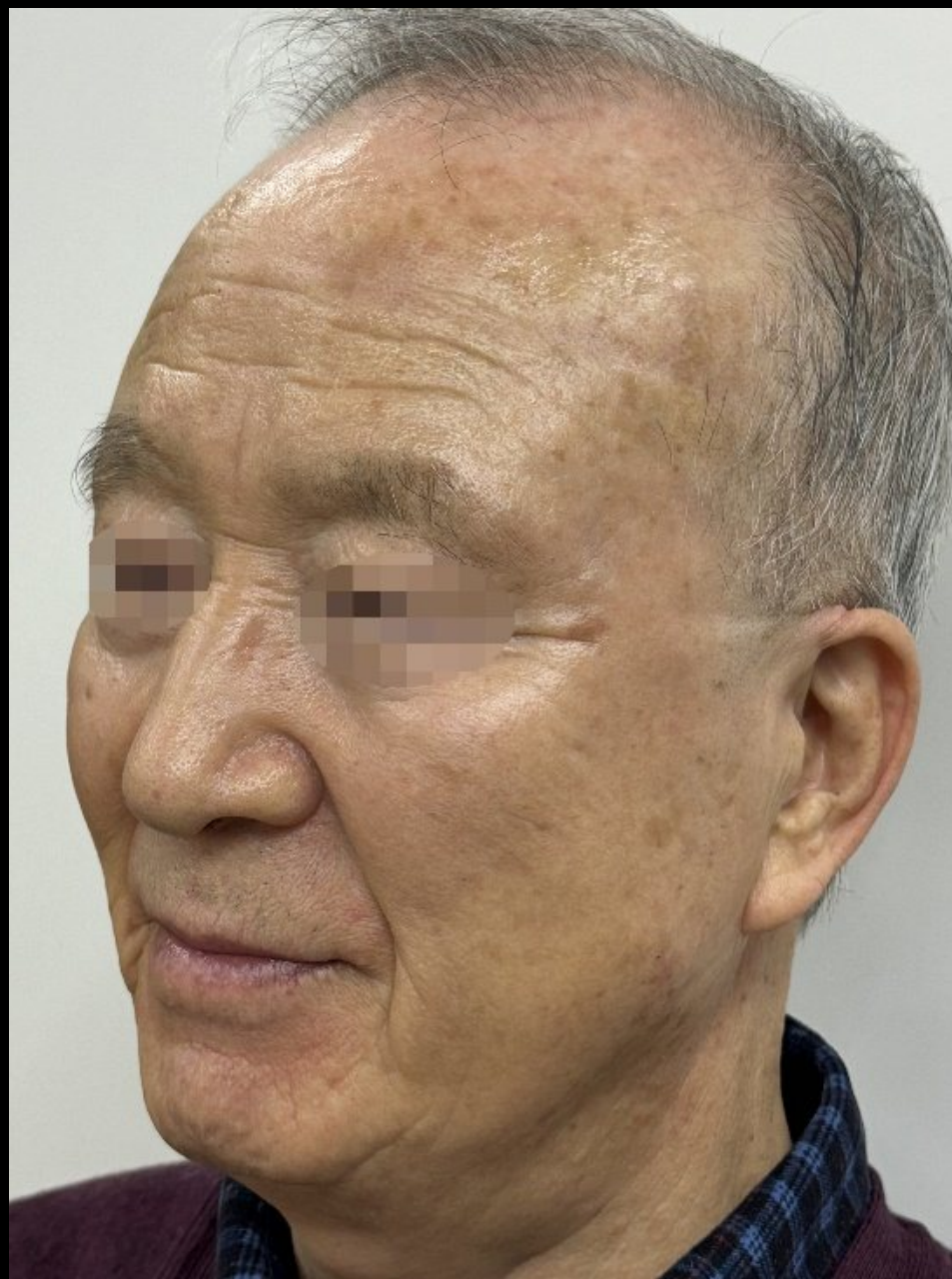




Perioral Natural volume up Through intra oral injection Aged patients

Dr SM Chung

before



application site

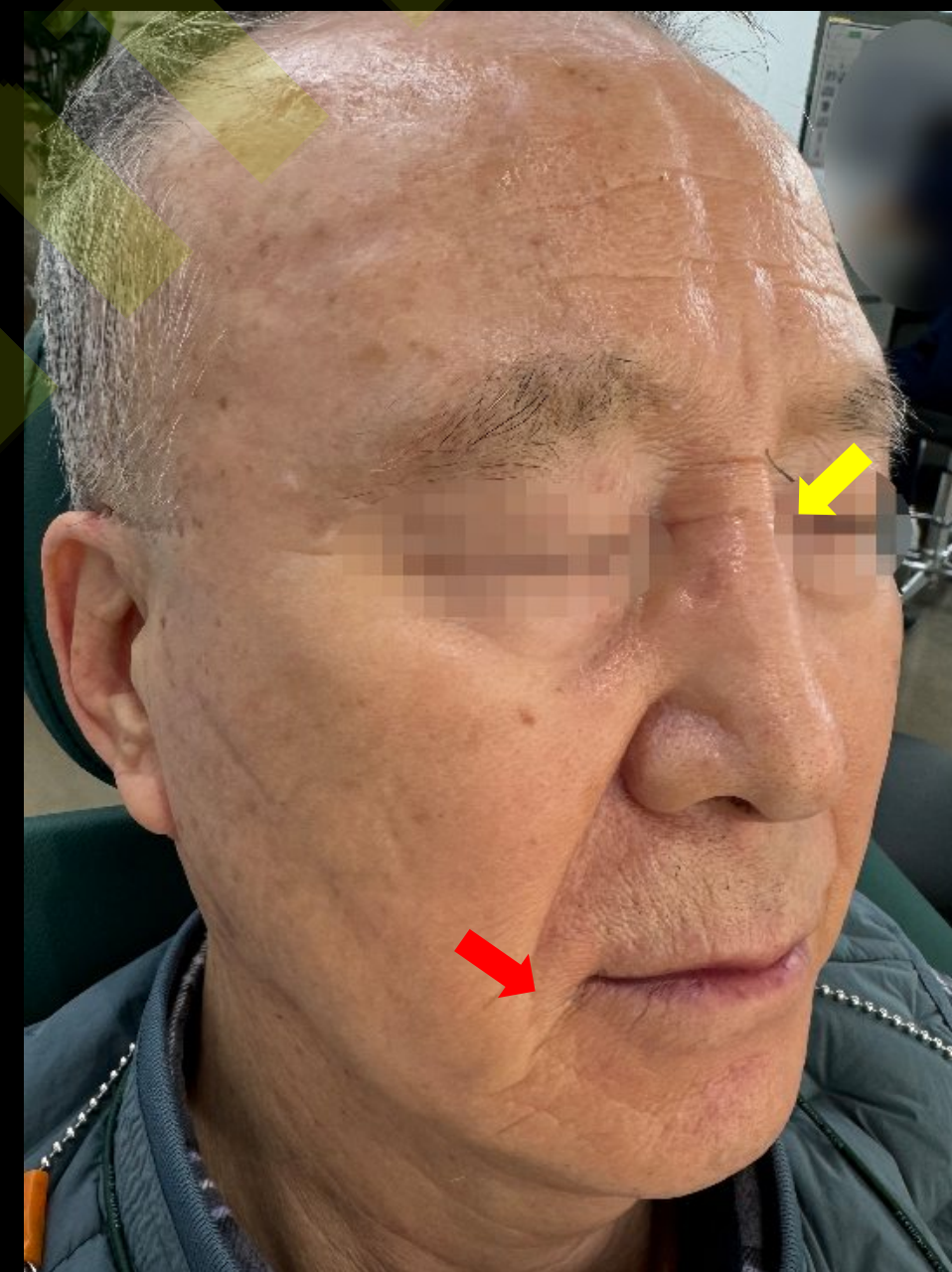
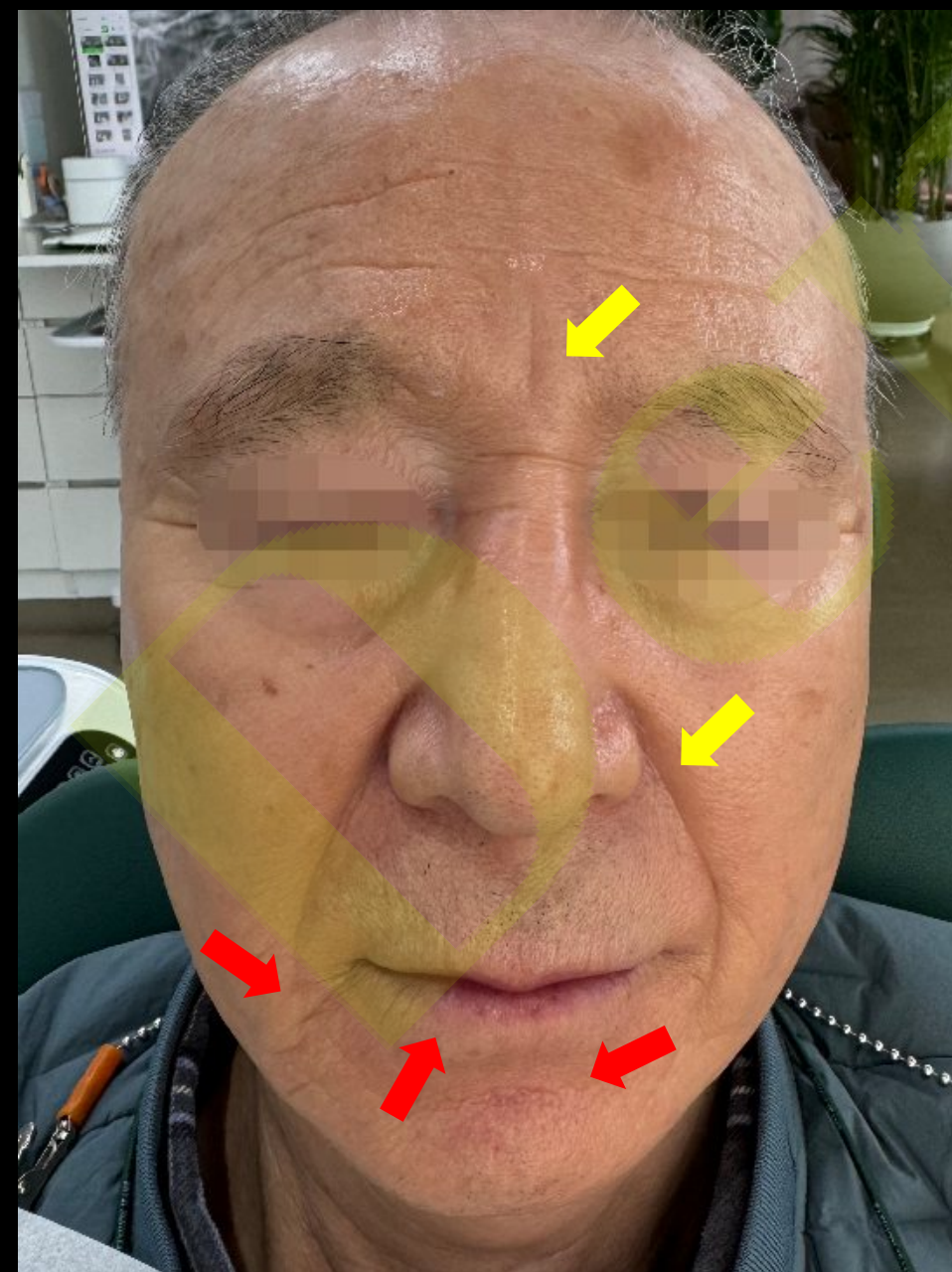
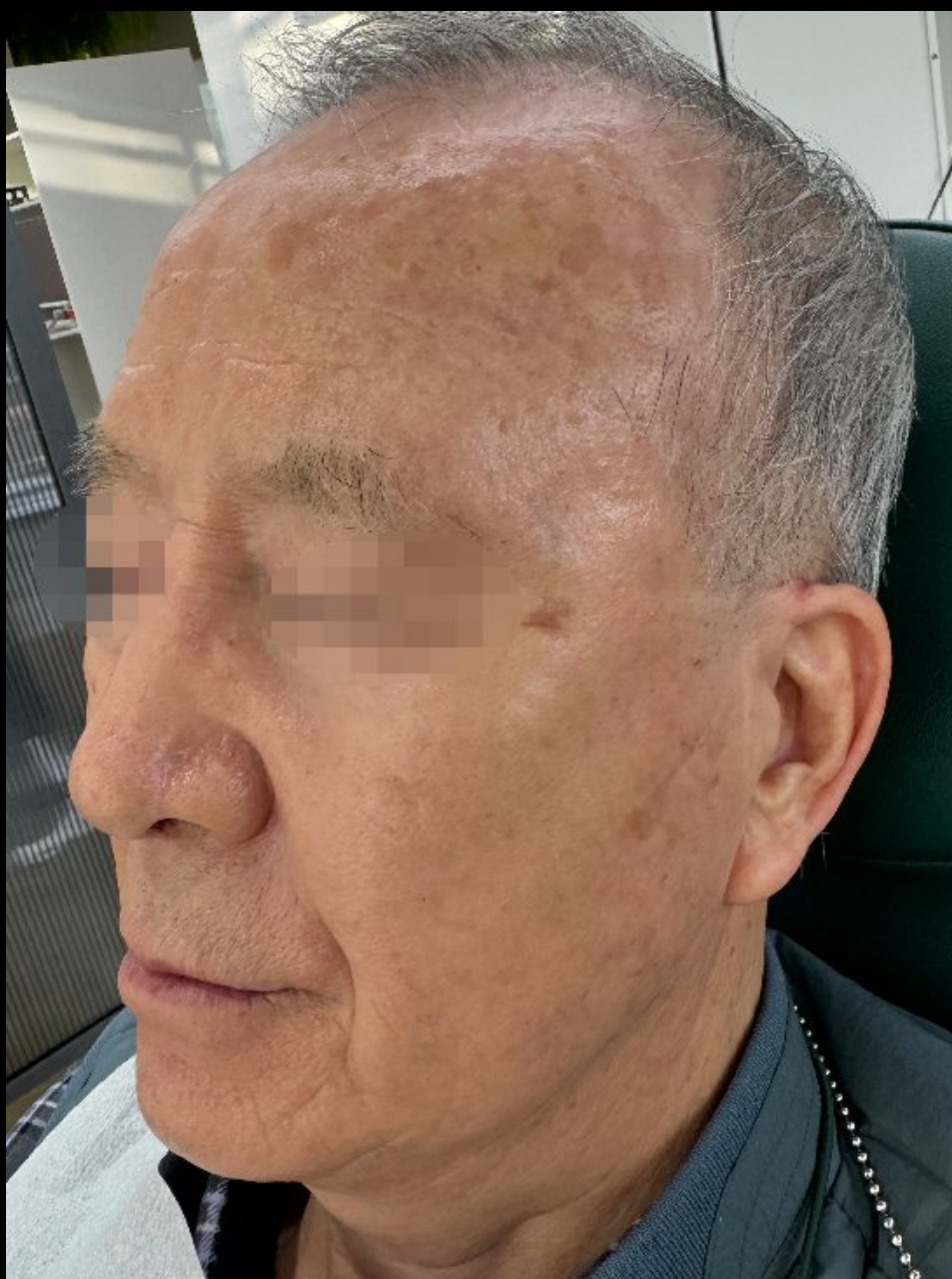High 

- Nose
- Nasolabial folds
- Frown lines

Smile 

- Temples
- Nasolabial folds
- Marionette lines
- Lip
- Mental Crease

2w
After



A Change in appearance with aged person

- 1 Reduced soft tissue volume - collagen
- 2 A slight decrease in bone tissue
- 3 Reduced elasticity of the skin

-> Appears in the form of **sagging, facial depression**, etc

The concept of fillers for elderly patients

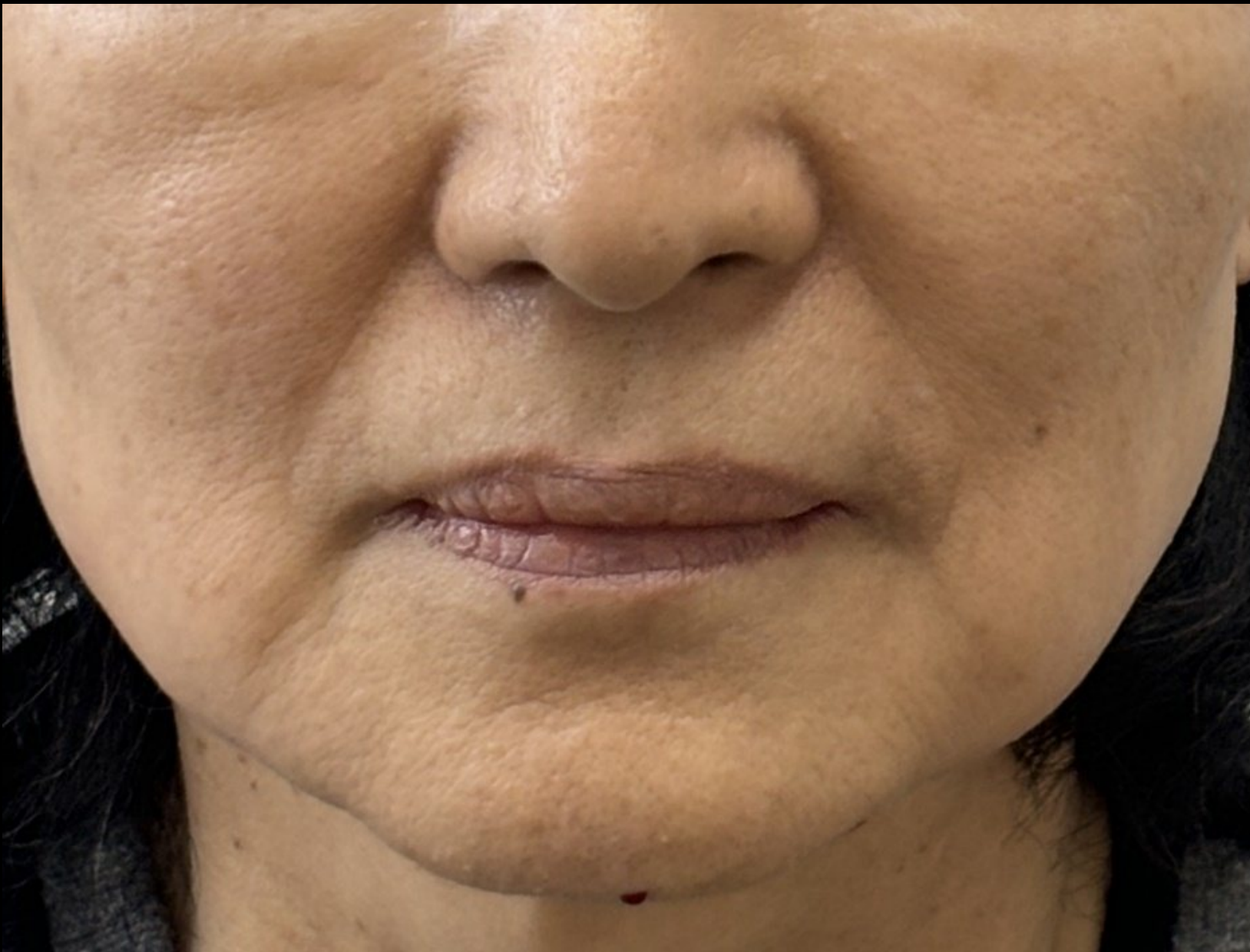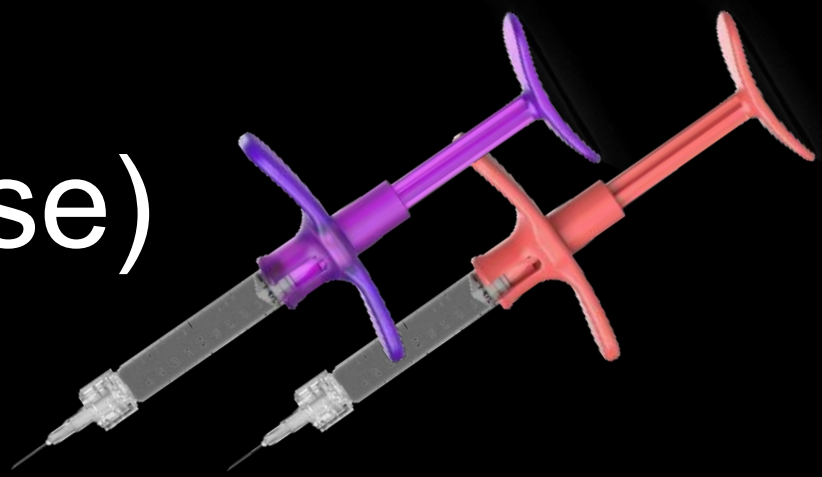1 Injection area

- 1) Nasolabial fold
- 2) Marionette line

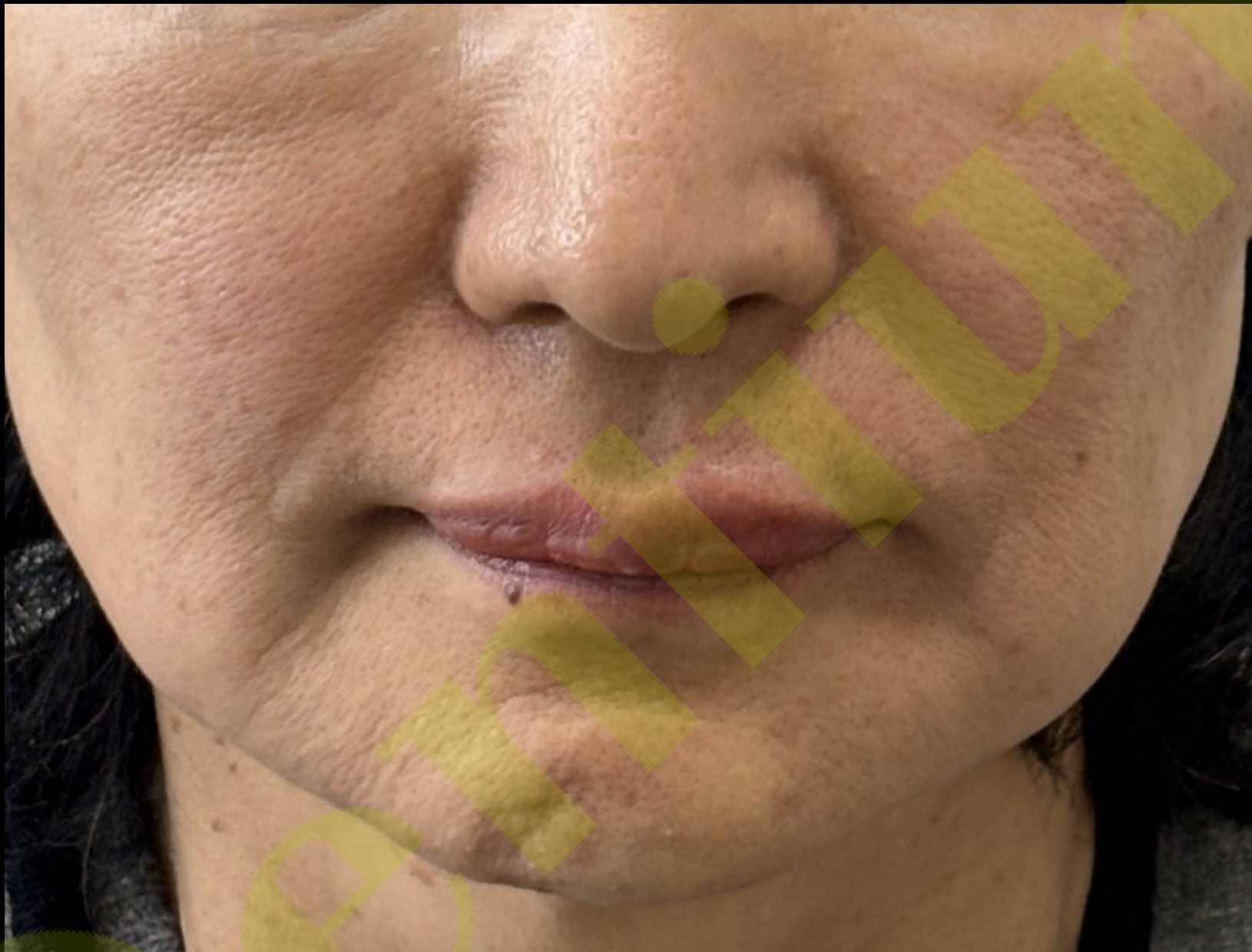2 Increase the volume

- 1) **Mainly injection** needle instead of cannula
- 2) **Mainly Bone contact**
- 3) Inject only fine wrinkles of the skin directly under the skin
- 4) Increased effectiveness when used with Botox

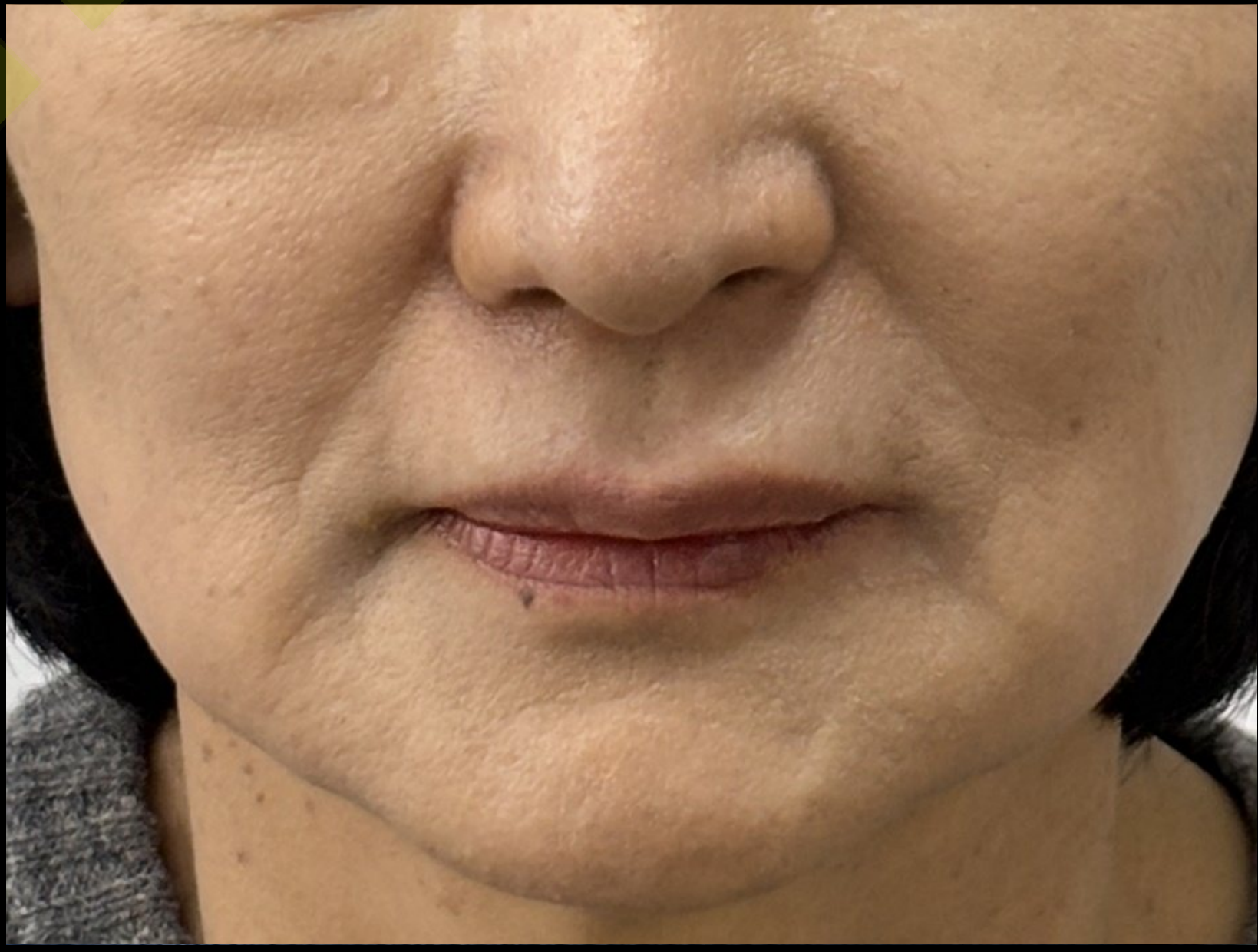Lower Face(Nasolabial folds / Lip / Marionette lines / Mental Crease)



Before

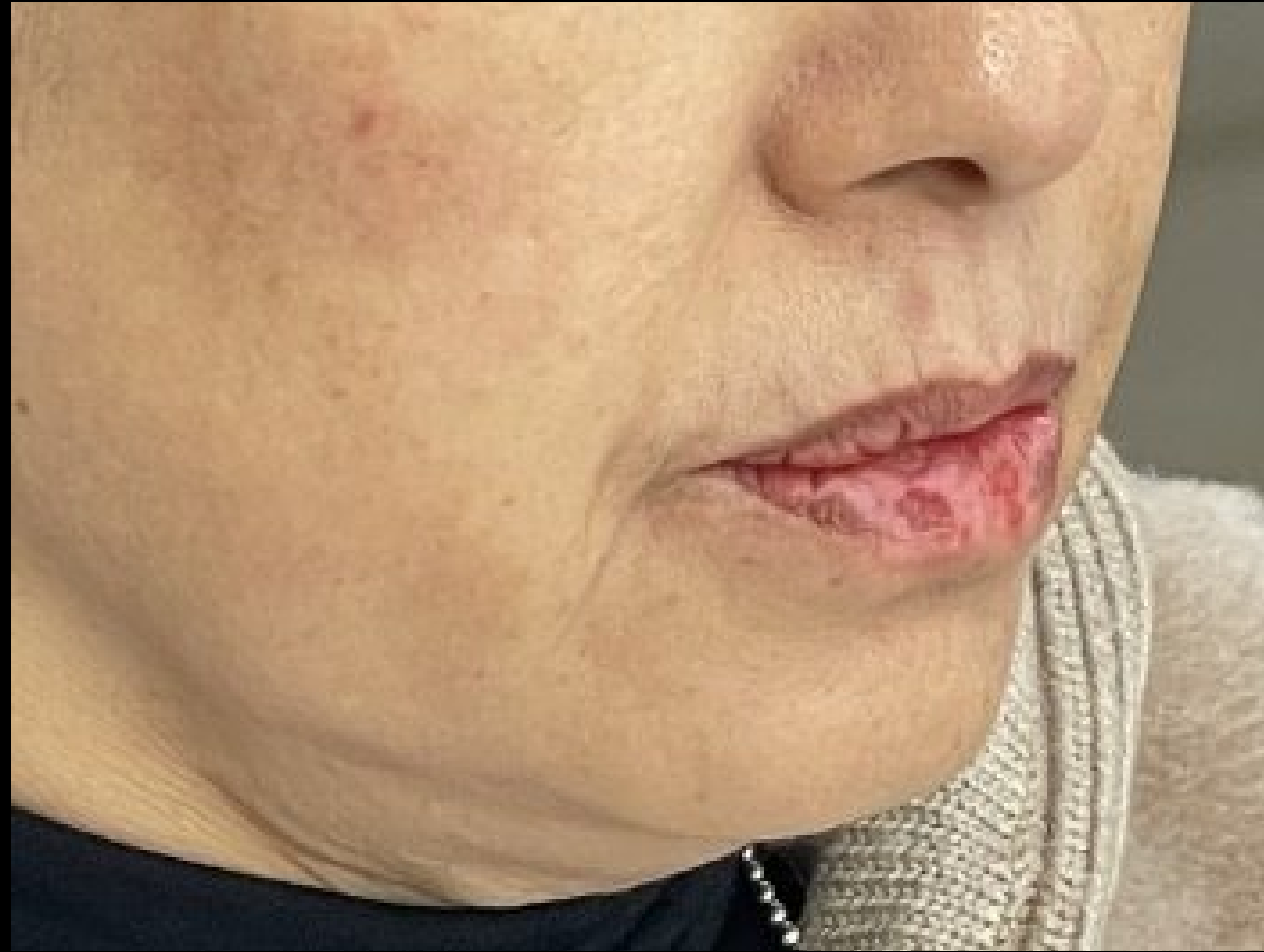
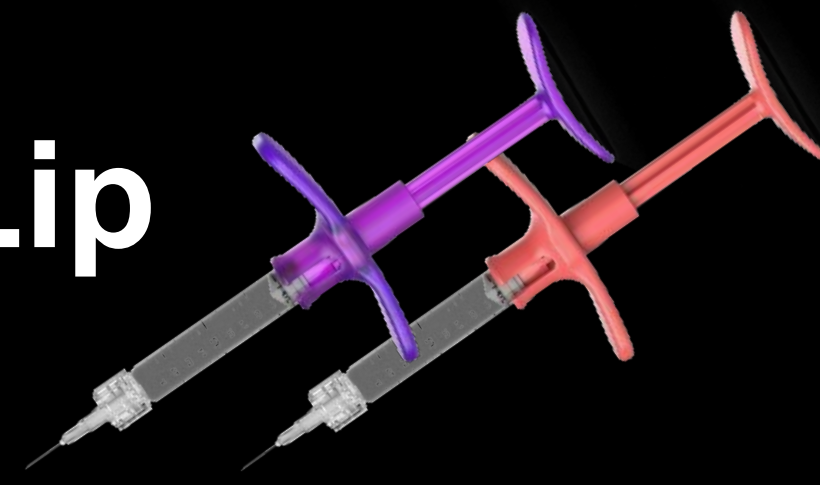
After

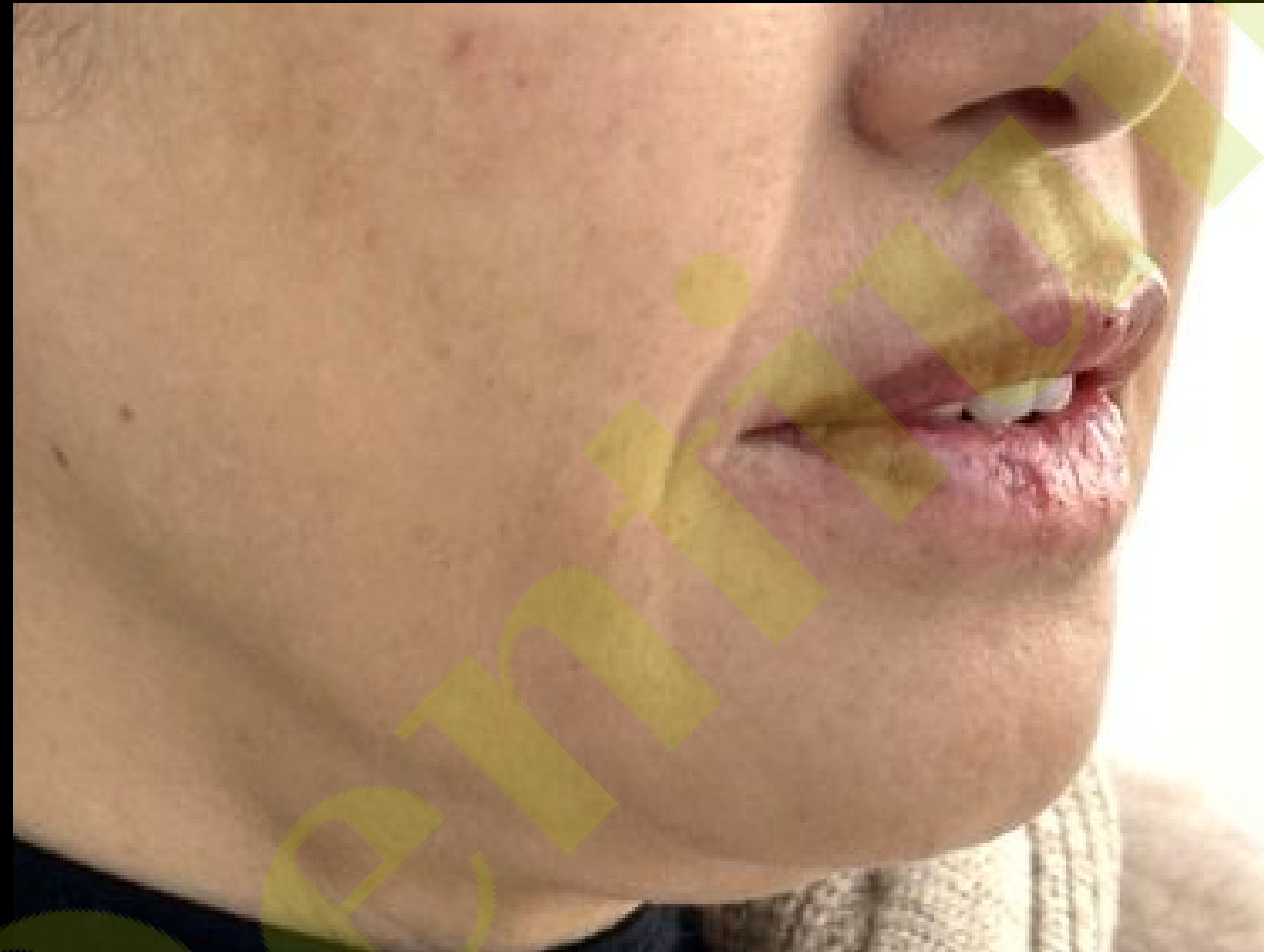

2 Weeks Later

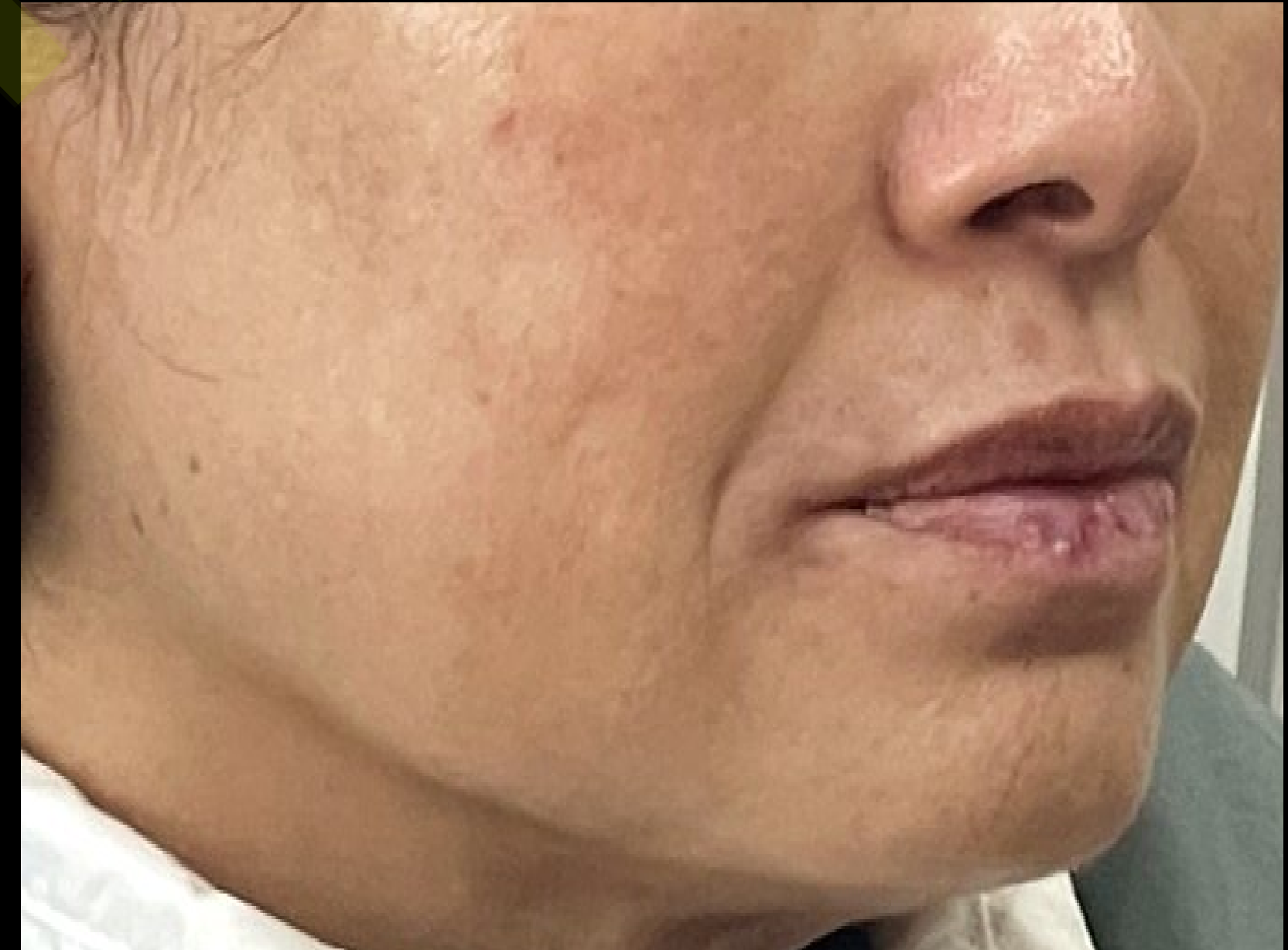Perioral wrinkles & Lip



Before



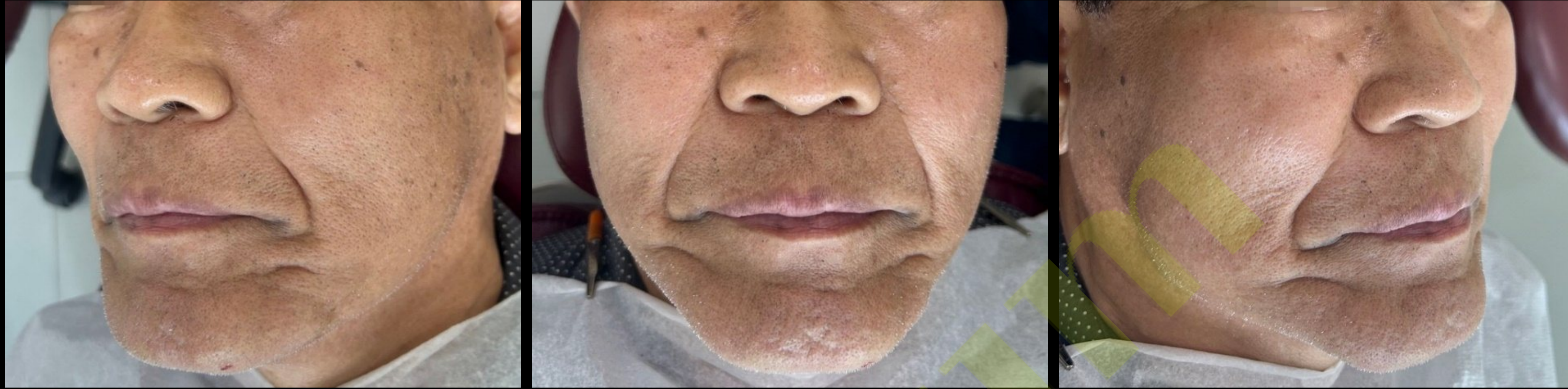After



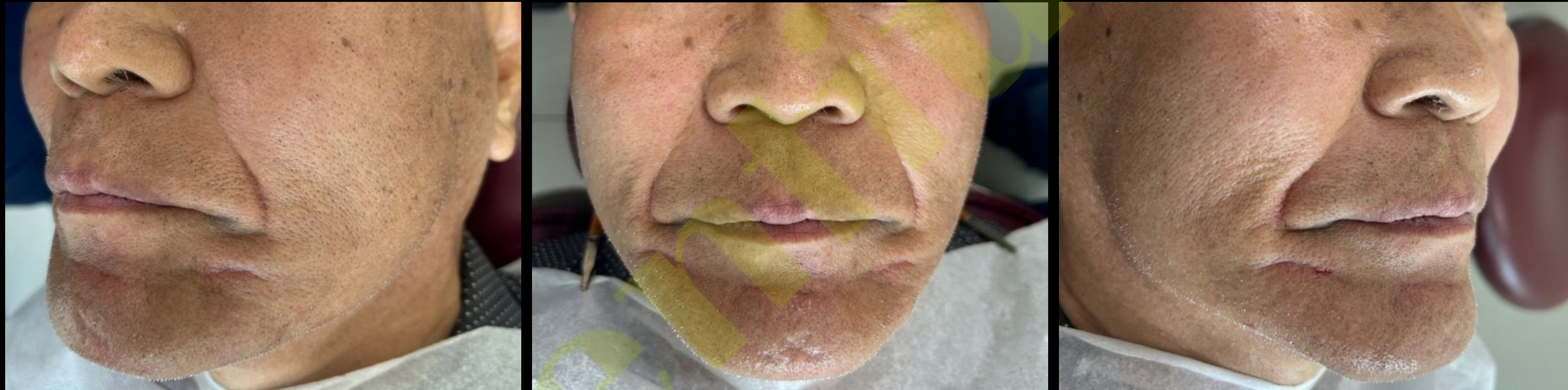5 Weeks Later

Clinical case : Nasolabial folds, Lip, Perioral wrinkles

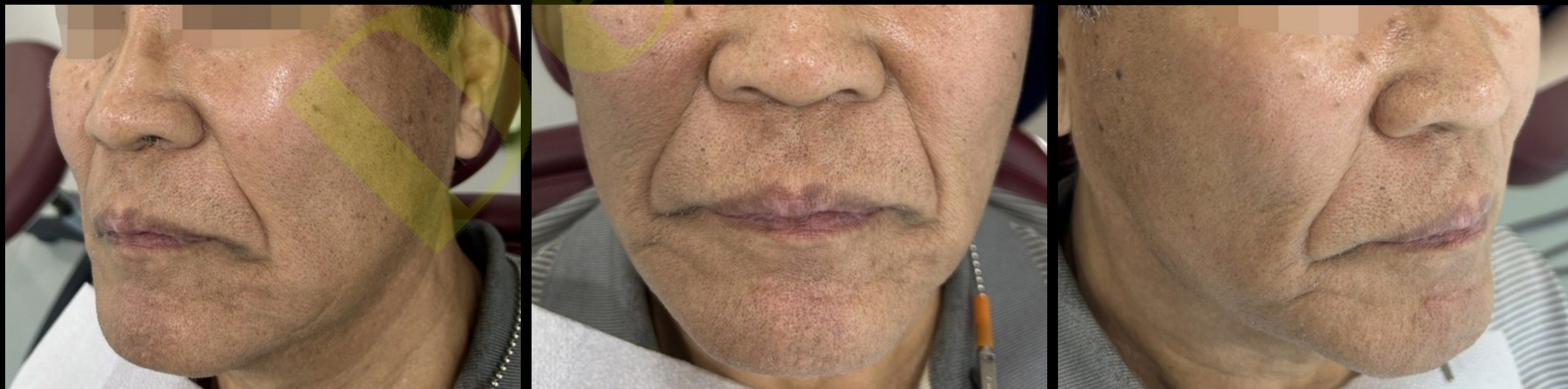before



after



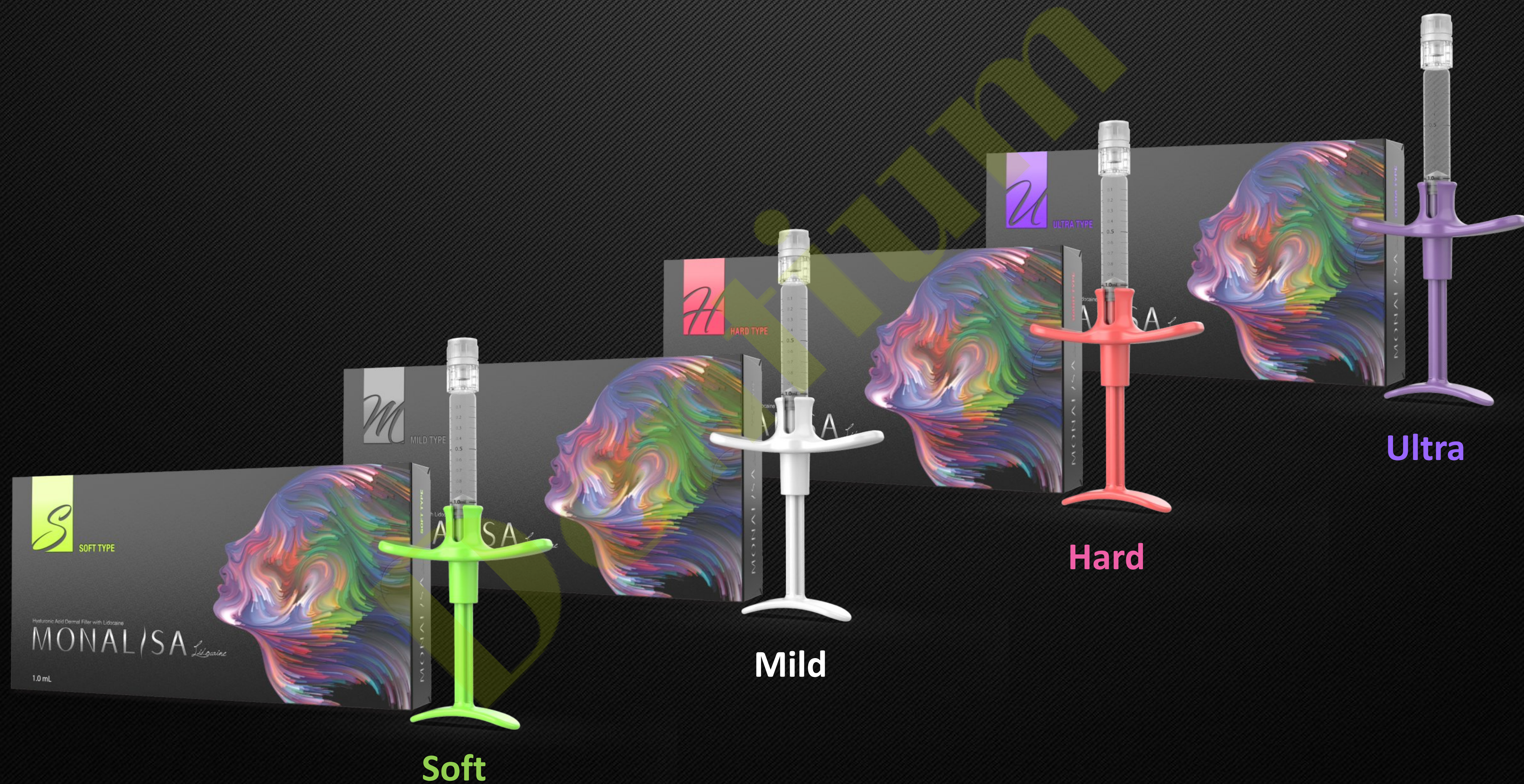2w
after



MONALISA Lidocaine

Hyaluronic Acid Dermal Filler with Lidocaine

MONALISA



Soft

Mild

Hard

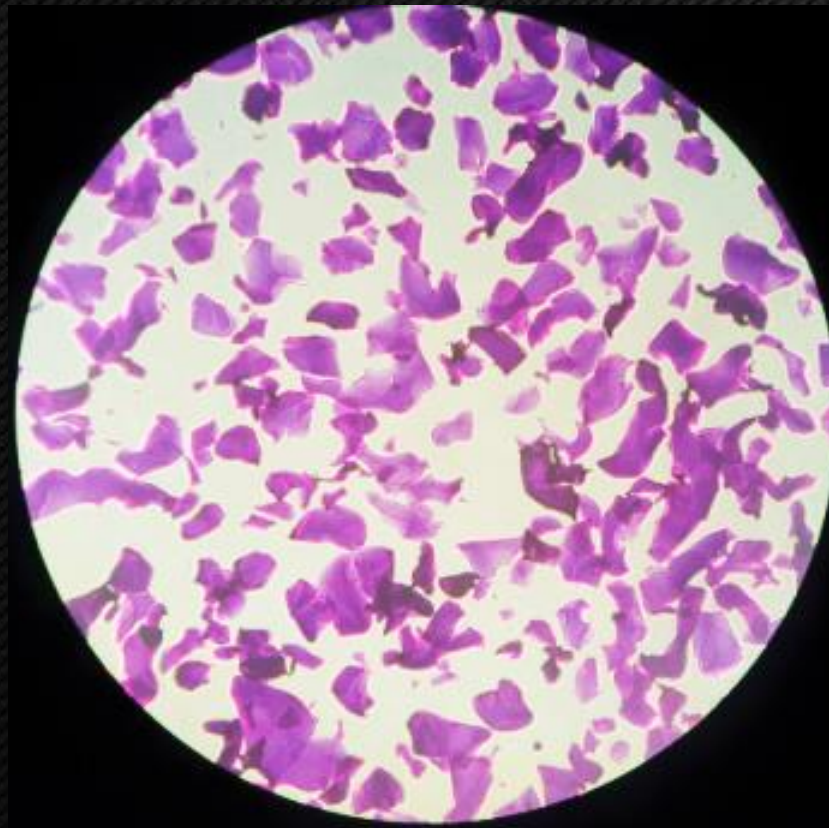
Ultra

Physical Properties

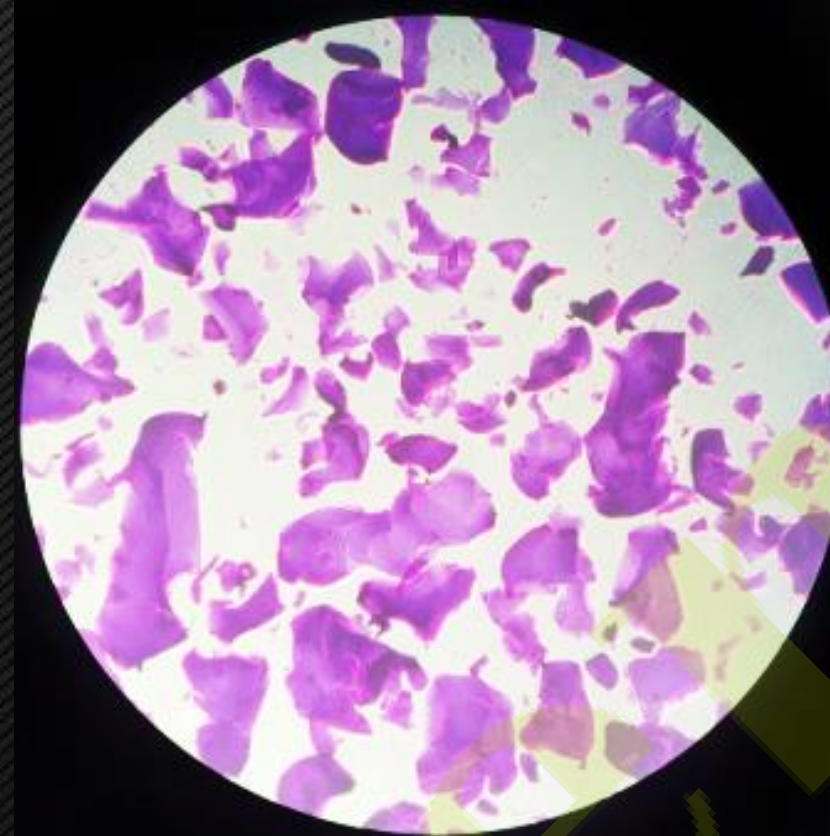
Hyaluronic Acid Dermal Filler with Lidocaine

MONALISA

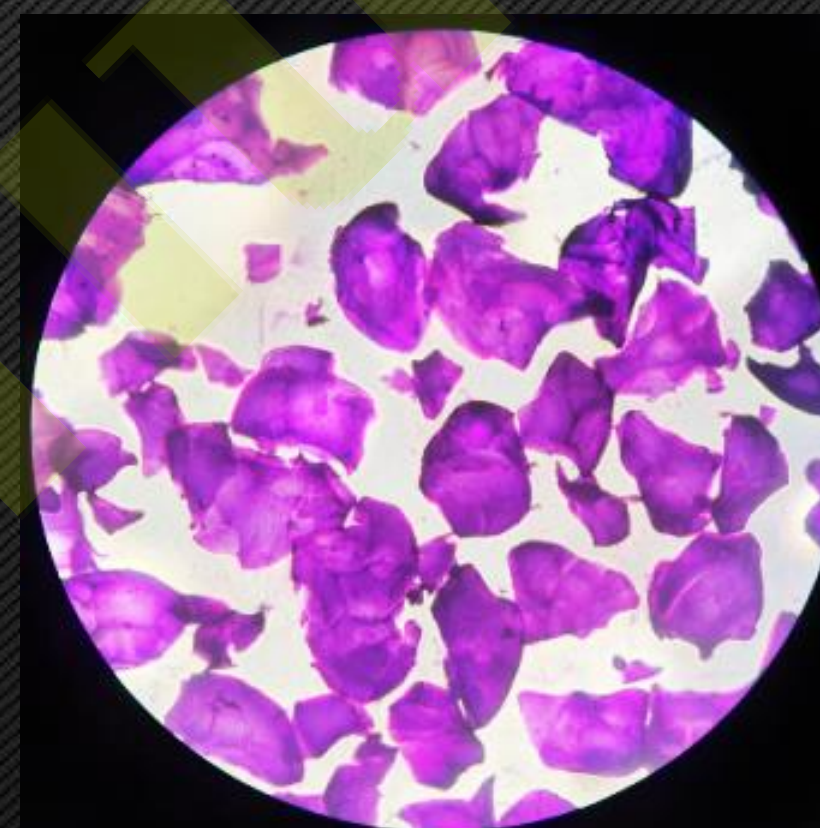
Particle size & shape



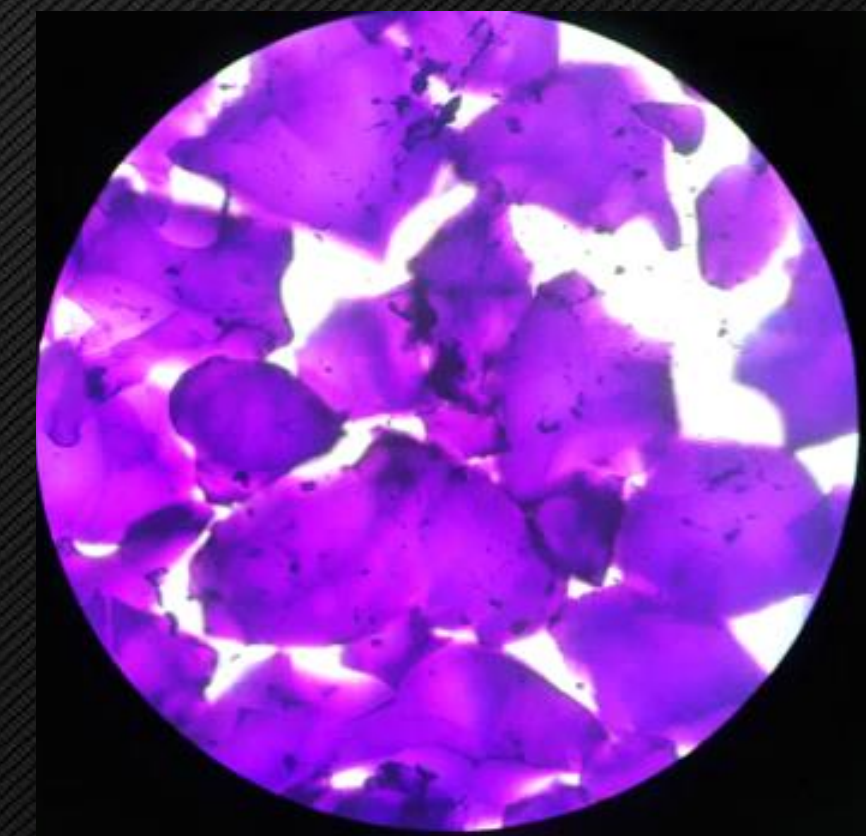
Soft



Mild / Smile



Hard



Ultra / High Elastic

x 40

MONALISA Lidocaine

Hyaluronic Acid Dermal Filler with Lidocaine

MONALISA

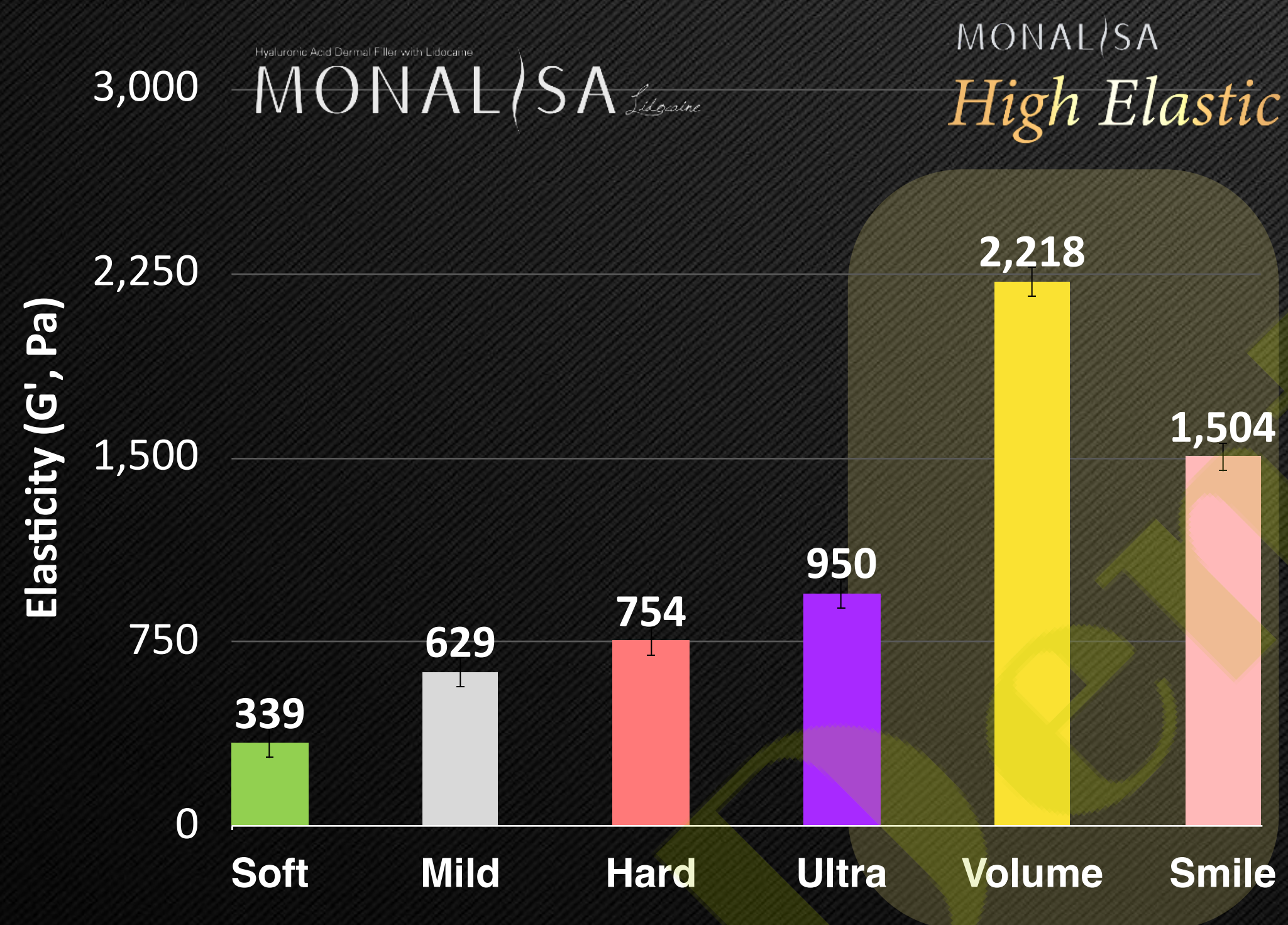


Product	SMILE		HIGH ELASTIC
Form	No impurities, transparent and colorless gel		
Components	Cross-linked hyaluronic acid, 0.3% Lidocaine		
HA Concentration	24 mg/mL		
Particle Size	400 μm		900 μm
Volume	1.0 mL		
Application	Superficial dermis / Middle layer of subcutis		Deep to very deep layer of subcutis
Needle size	27 GTW*		25 GTW*
Storage Temperature	2 ~ 25 °C		

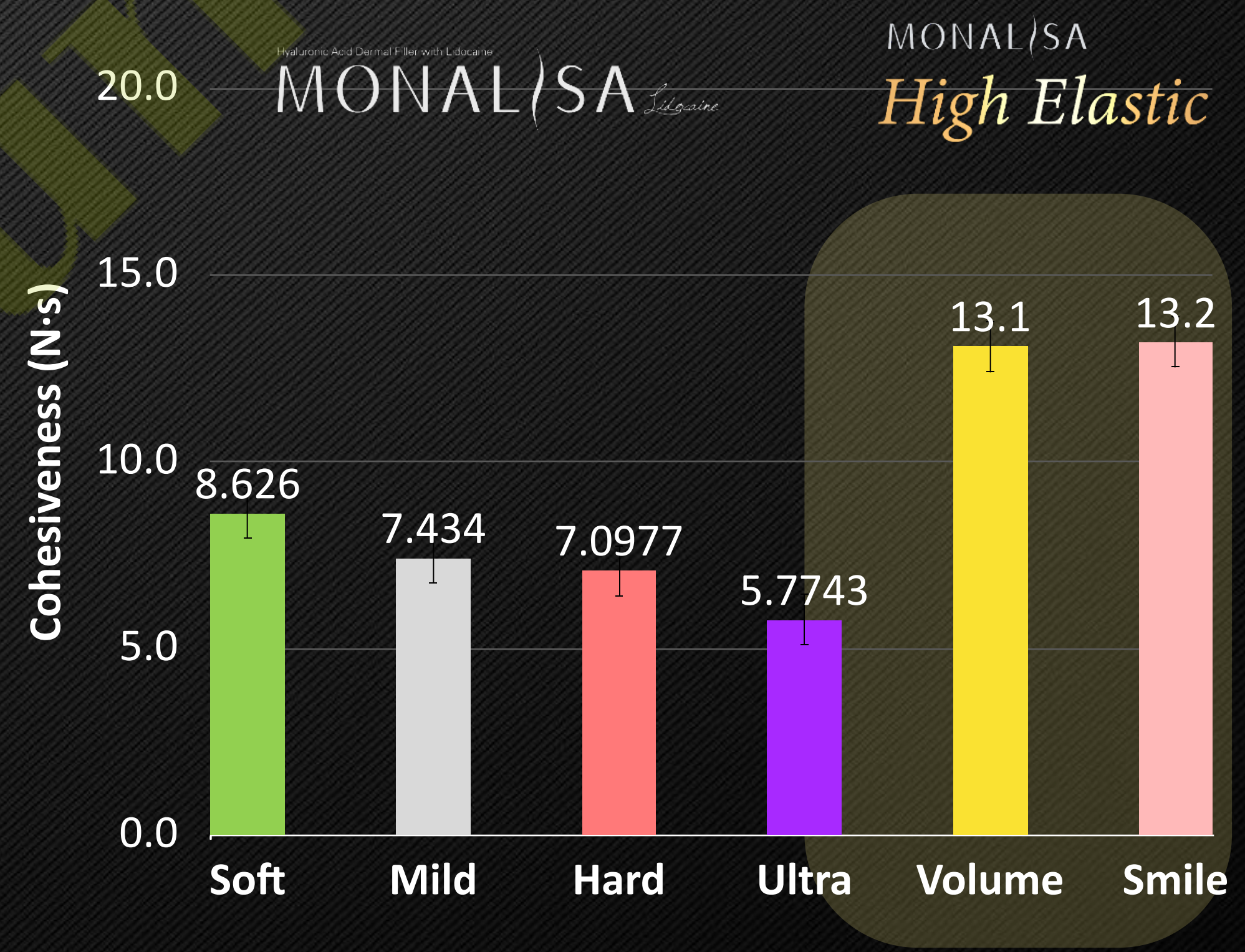
* TW : Thin wall

Physical Properties

Elasticity



Cohesiveness

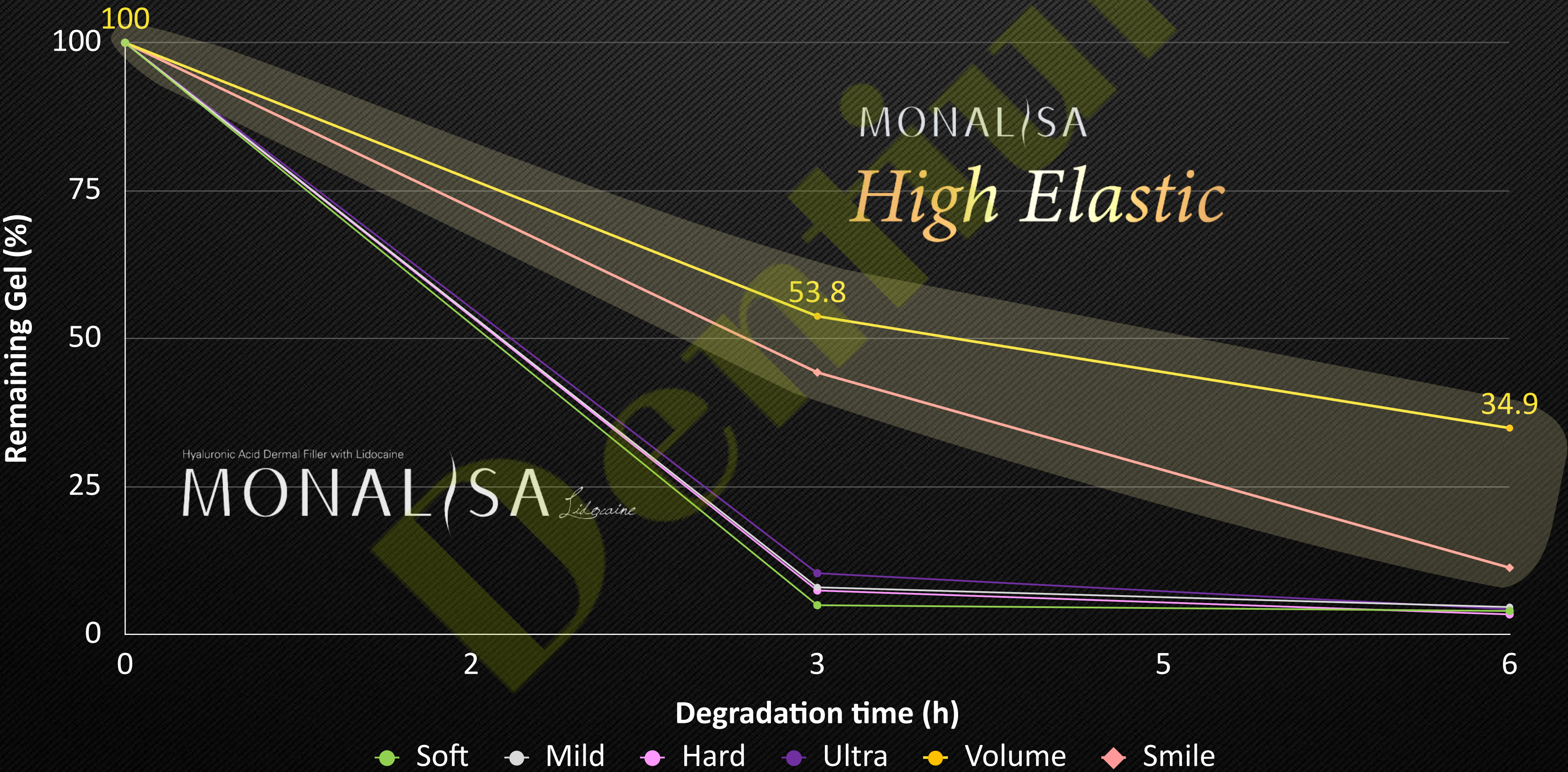


Physical Properties of MONALISA

Hyaluronic Acid Dermal Filler with Lidocaine

MONALISA

Behavior of degradation by Hyaluronidase



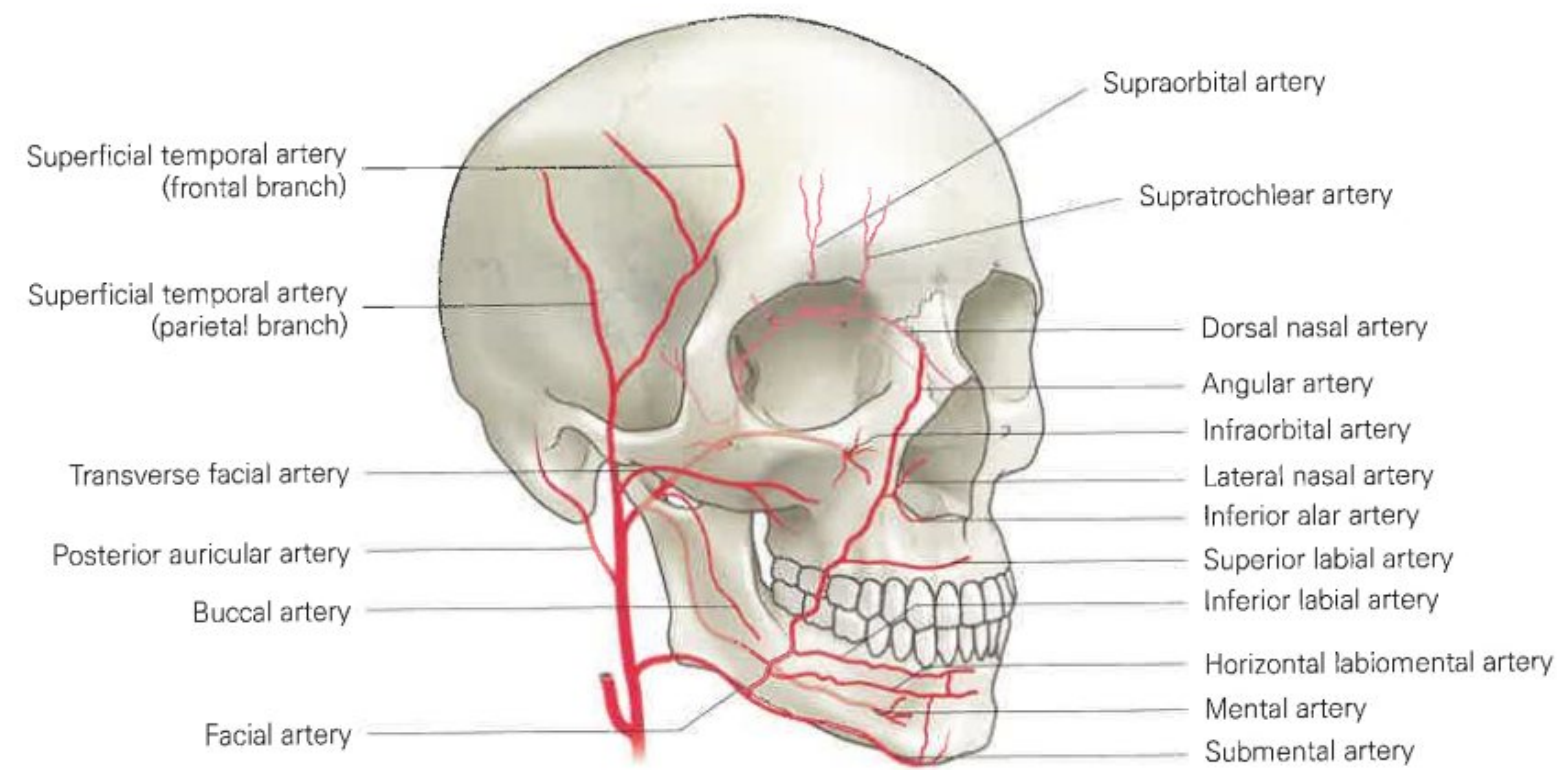
Preparing products

Body filler

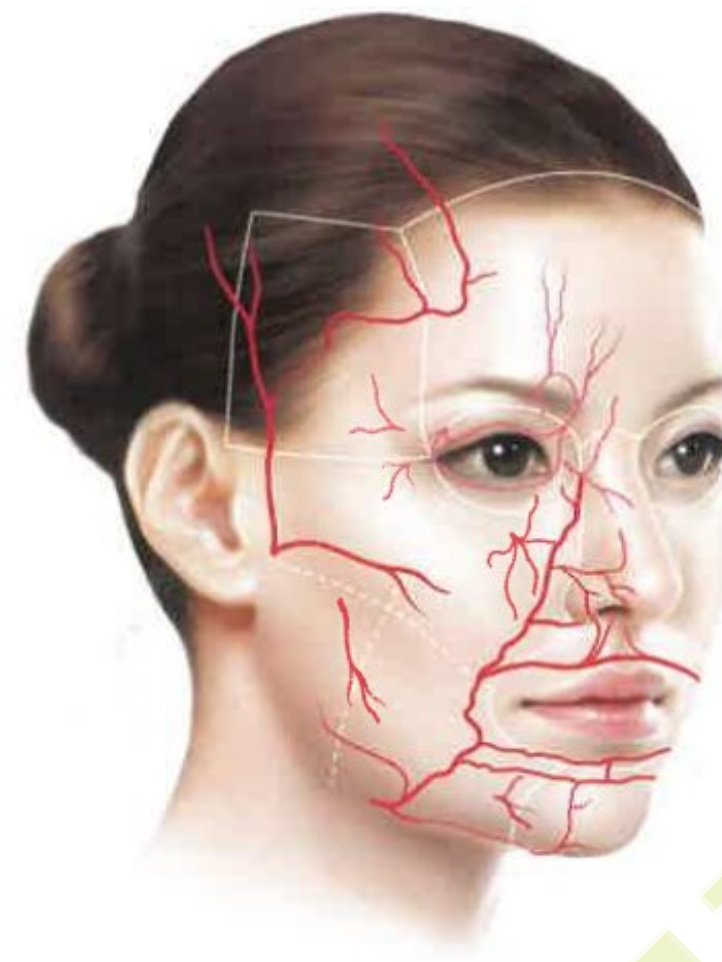
PDRN

PN + HA

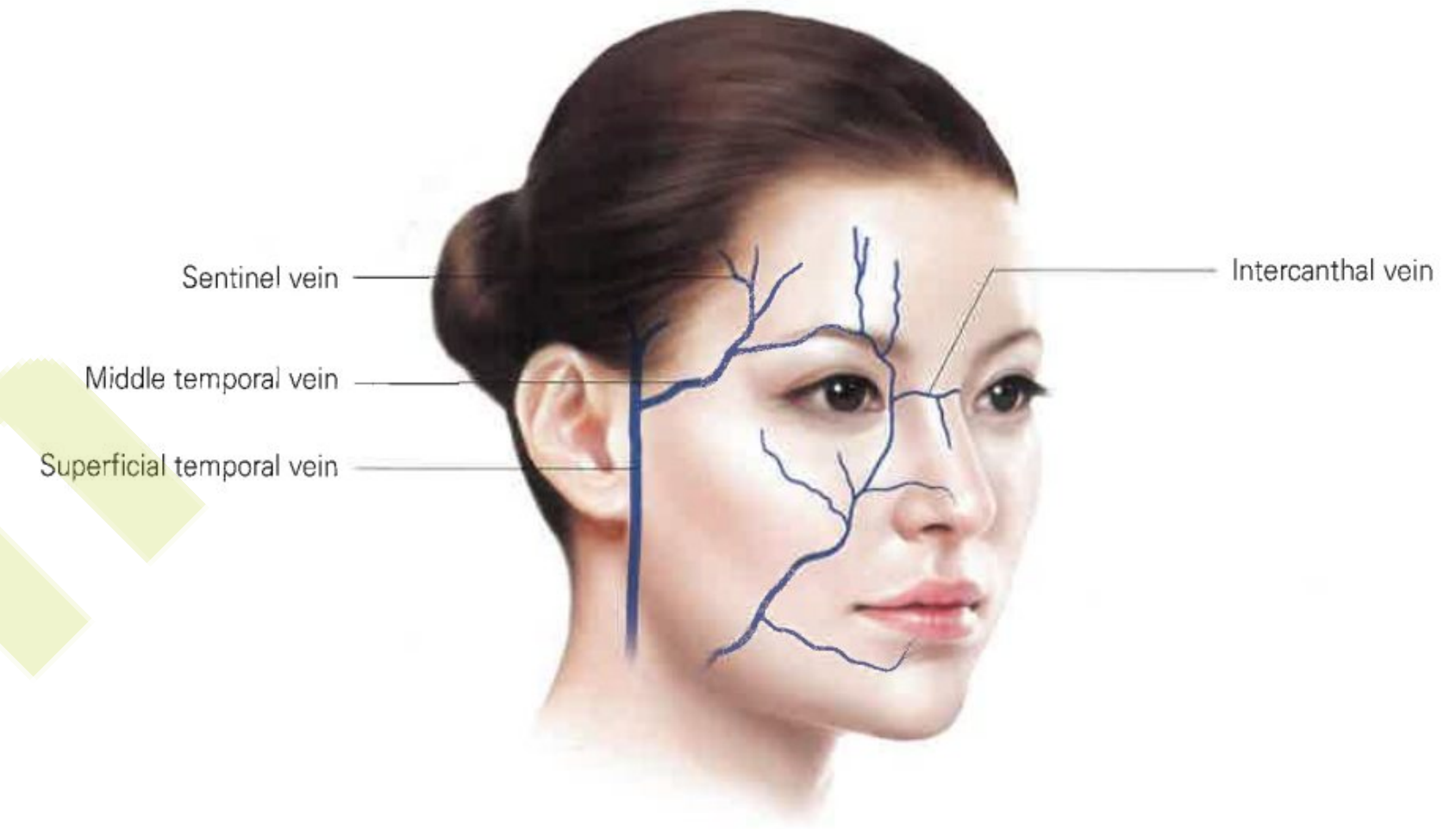
Essence with high contents
of PDRN and HA



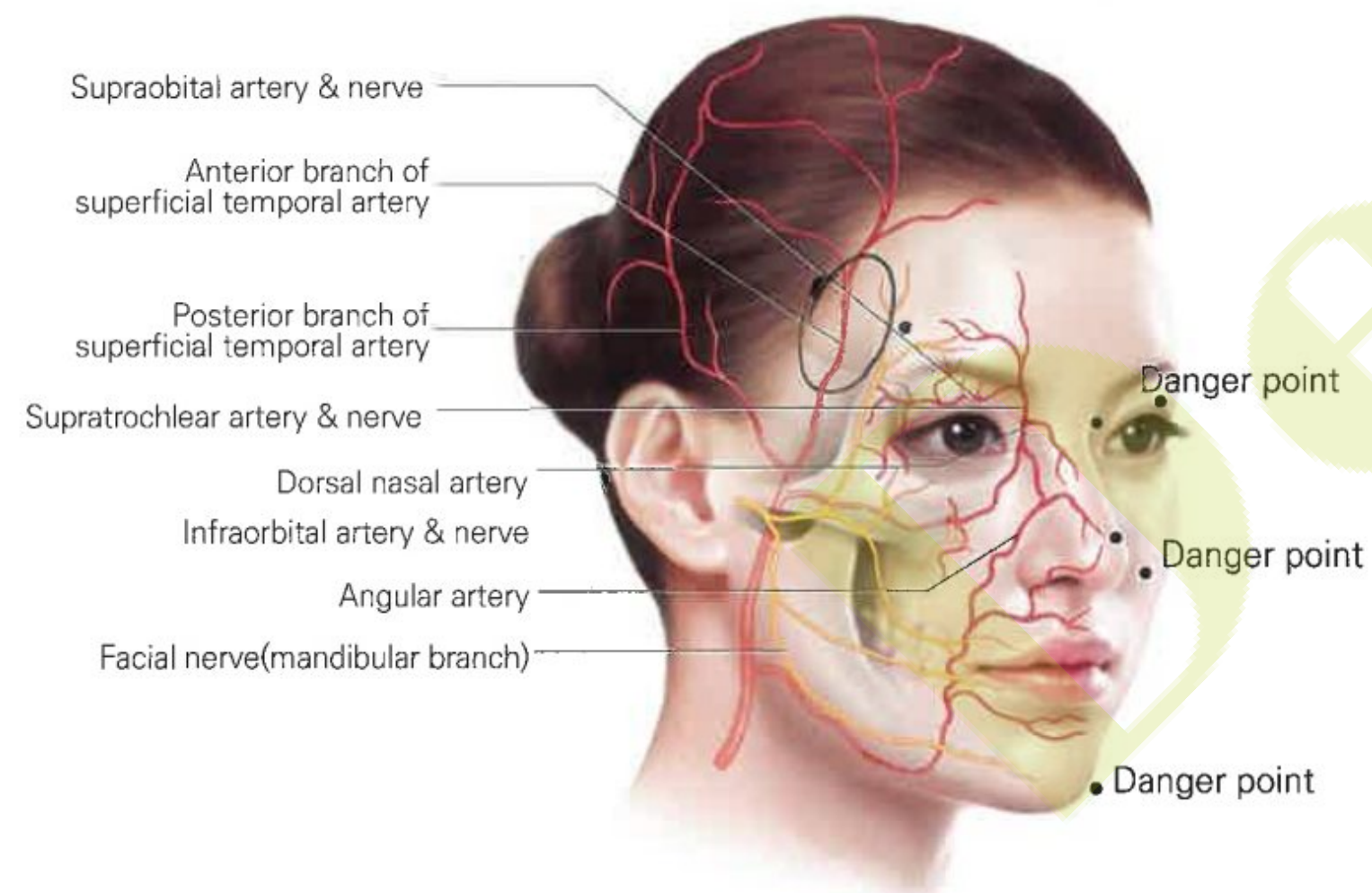
▲ Arterial branches of face



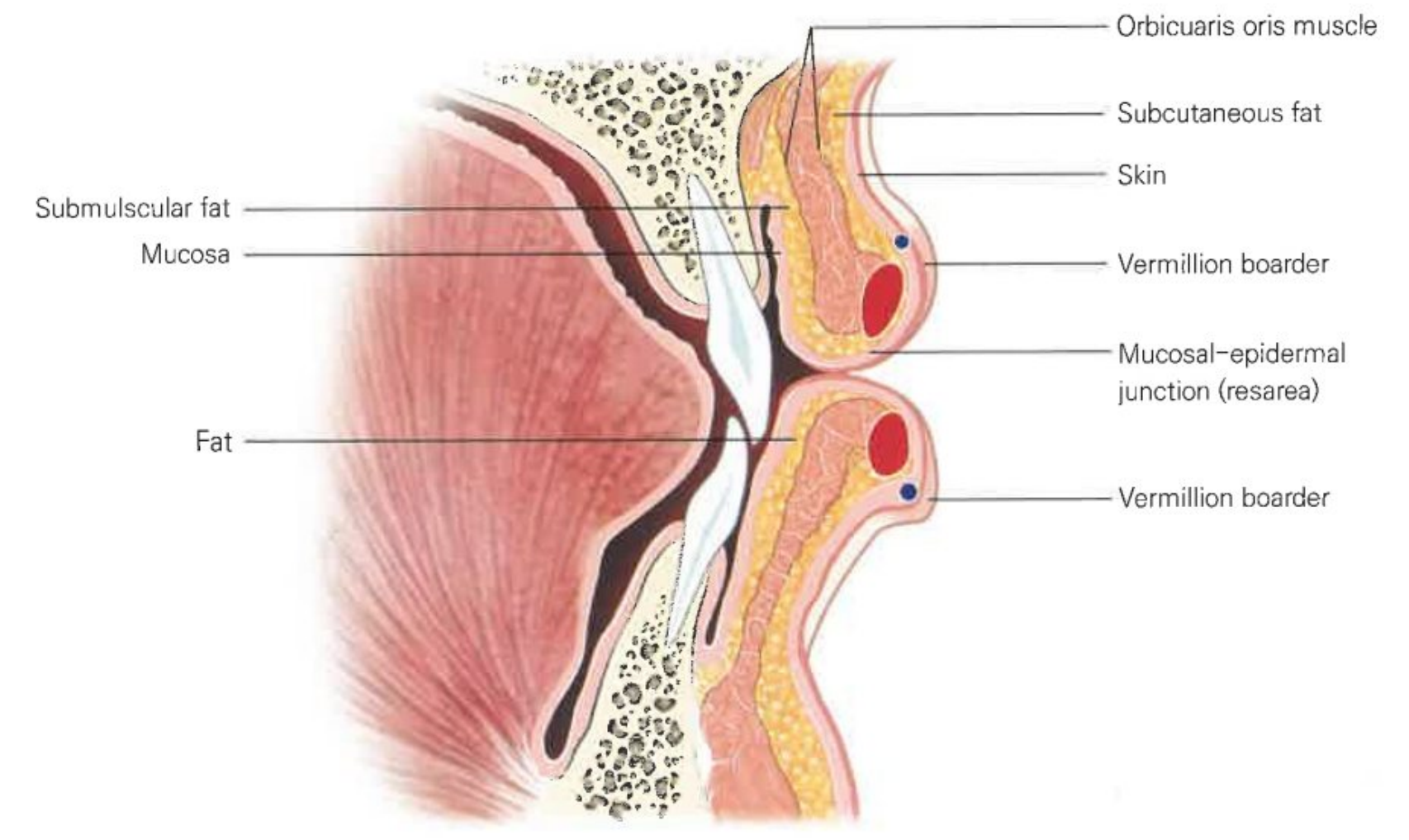
▲ Arteries supplying facial regions



▲ Veins of face



▲ The blood supply of lateral forehead area



▲ Sagittal section of the lip

Safe filler

Natural filler injection

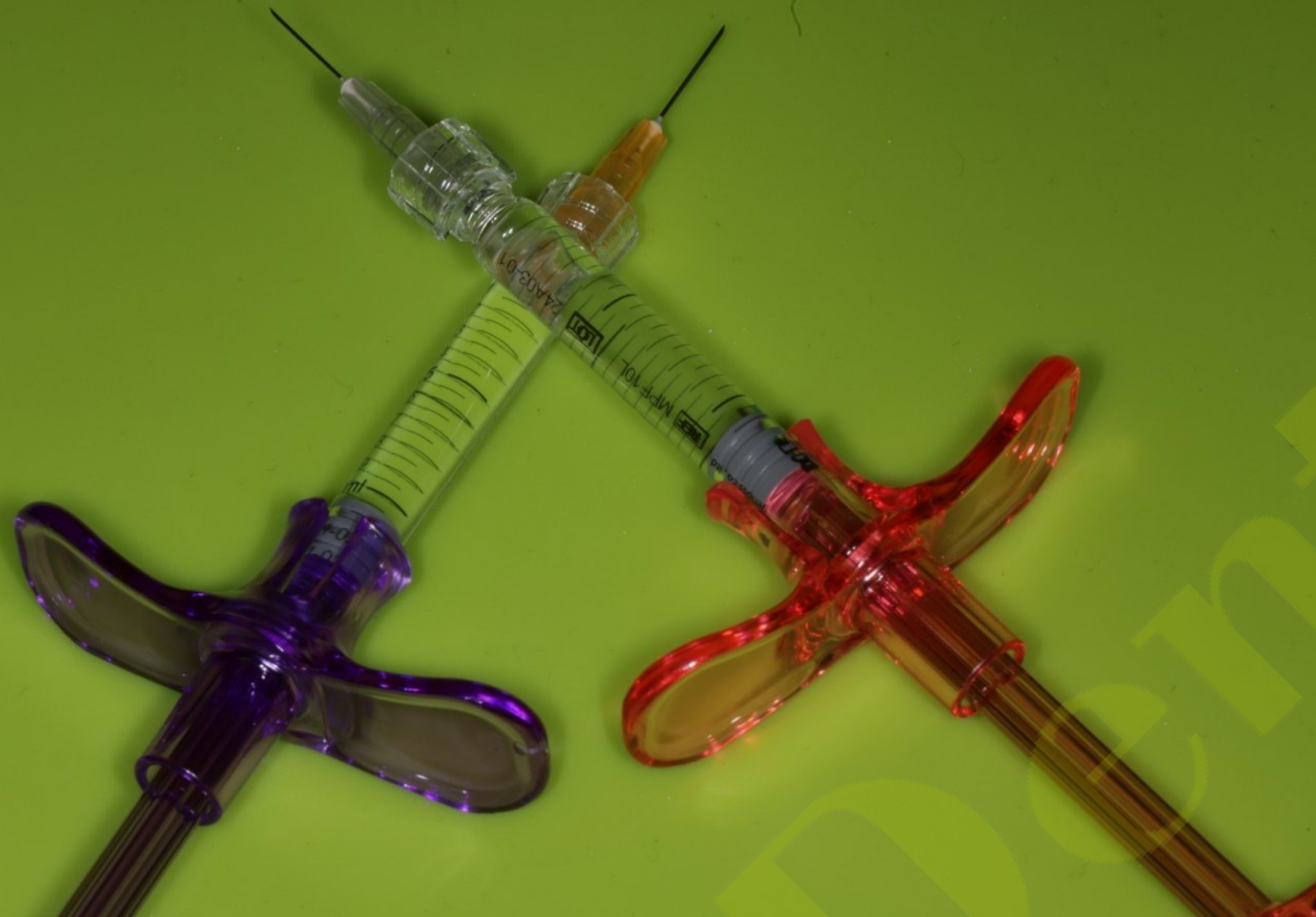- not enough volume

Mutilayer

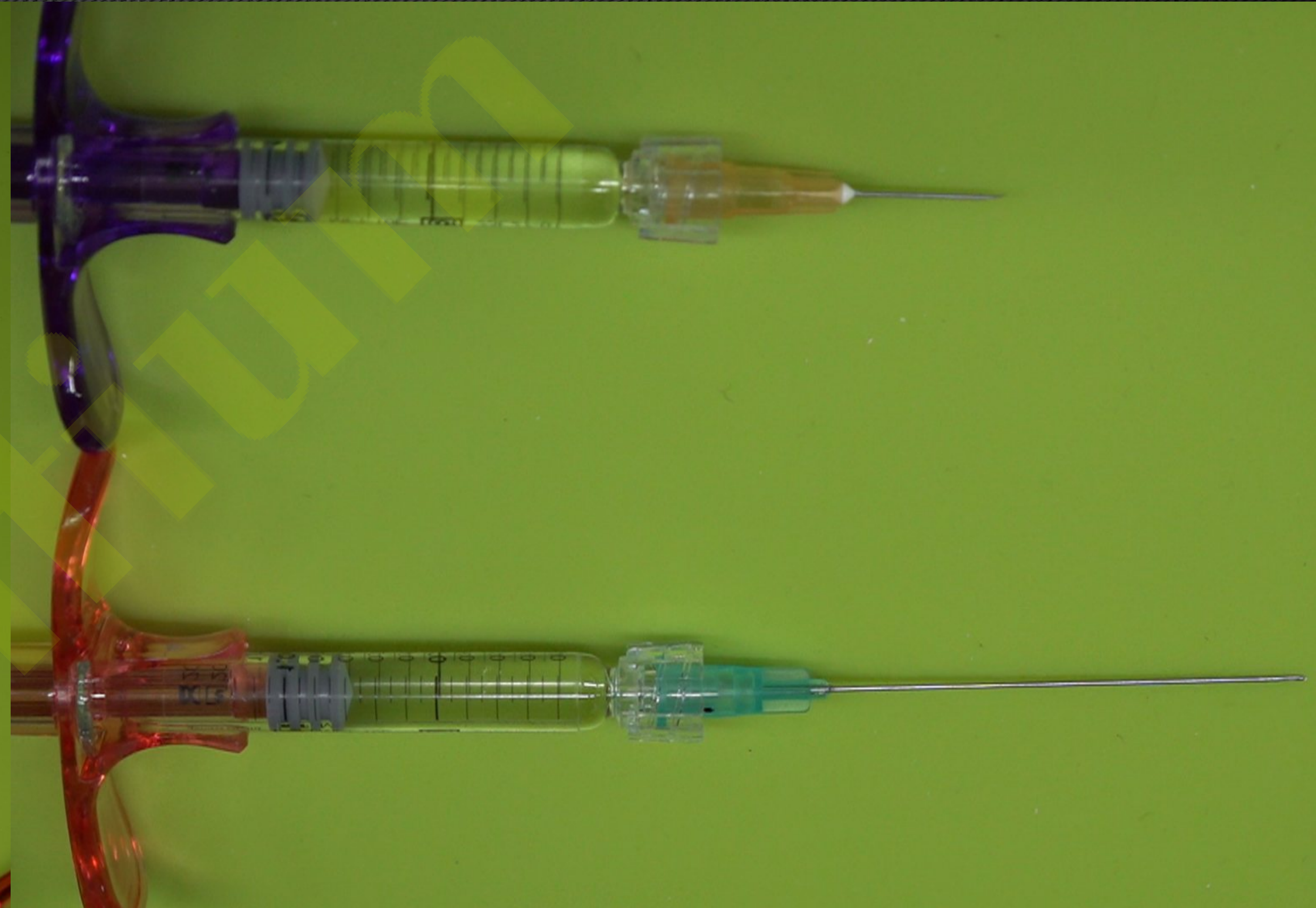- bone contact
- just below the dermis

Hyaluronic Acid Dermal Filler with Lidocaine

MONALISA

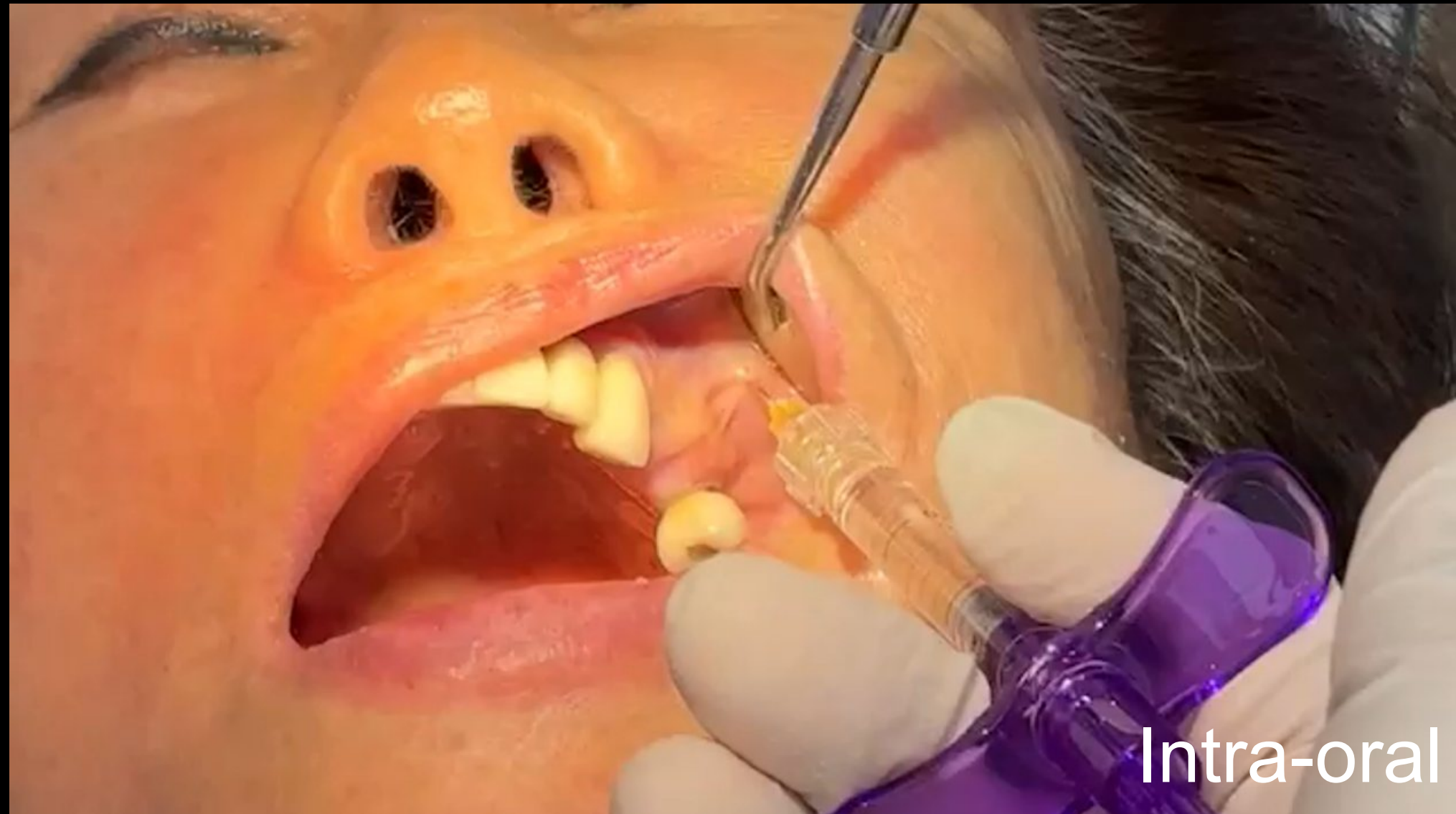

25G Needle



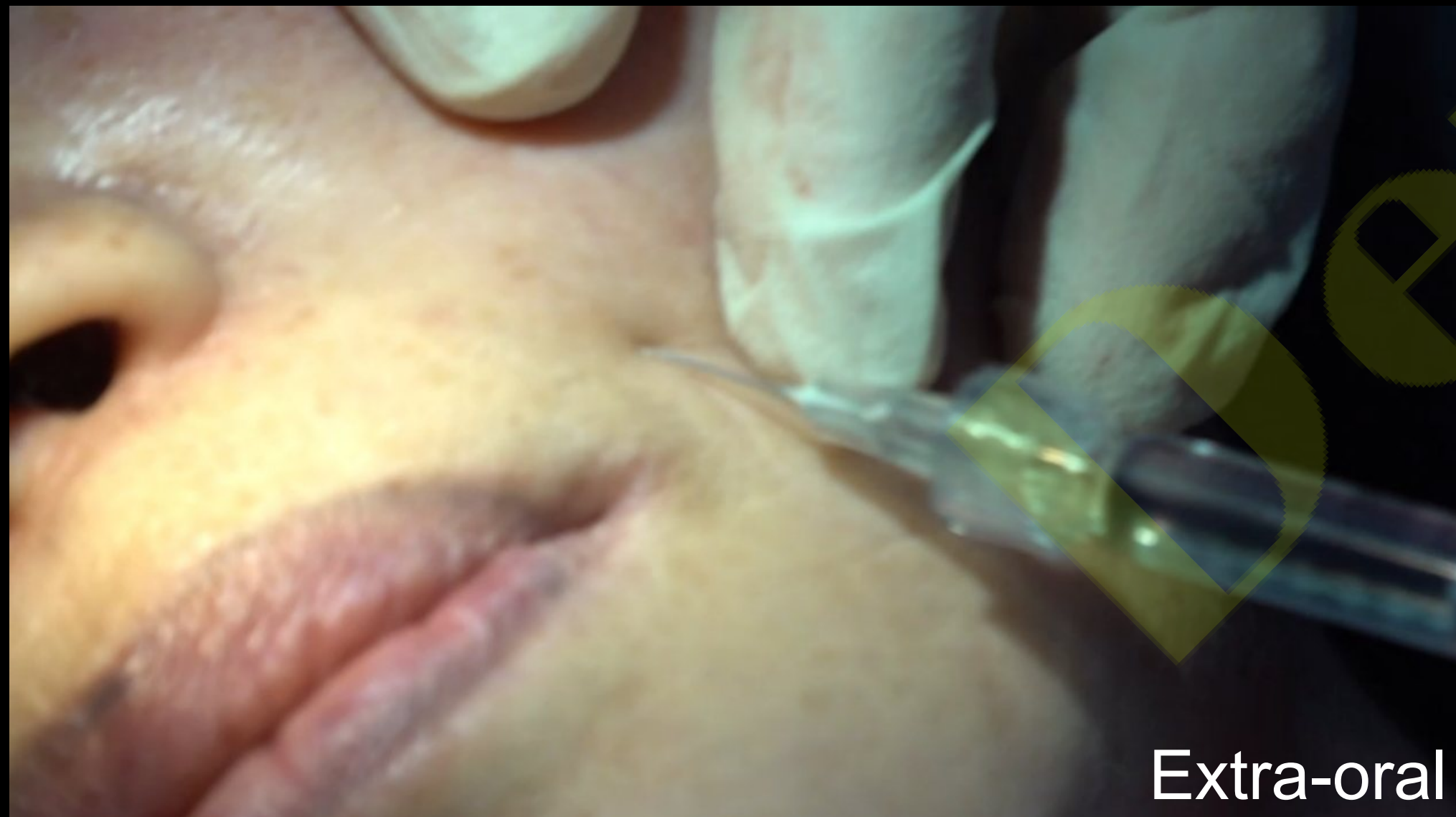
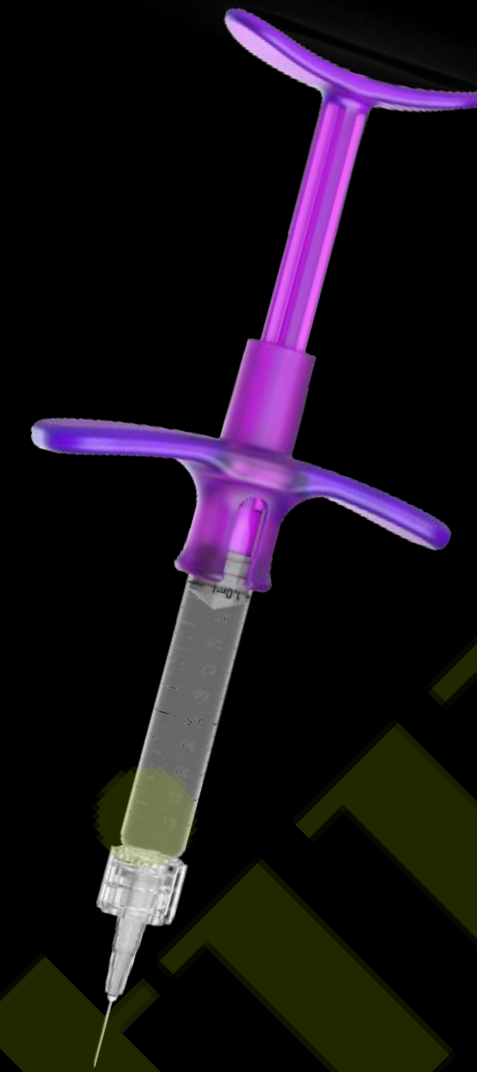25G Needle / 23G Cannula

Application site



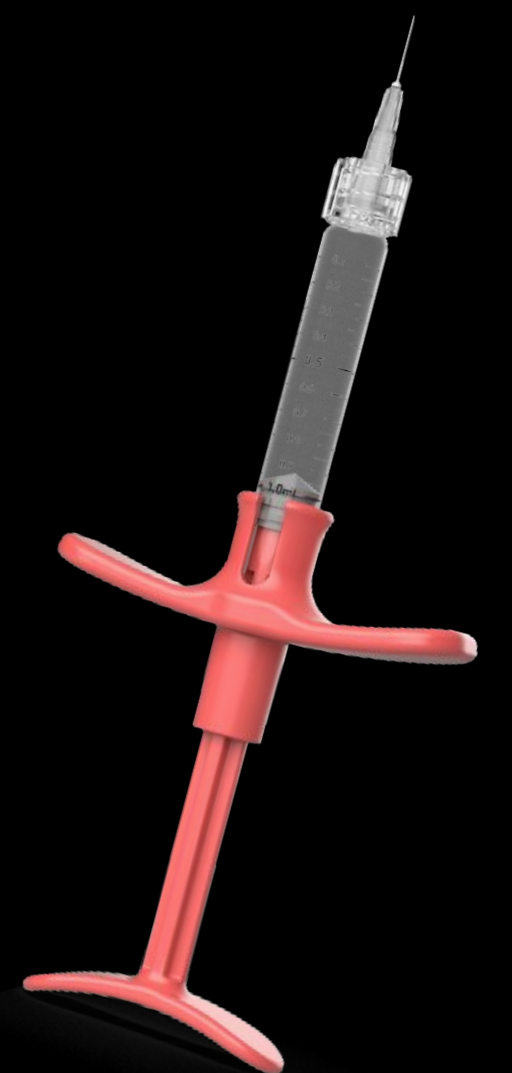Bone contact touch (Deep fatty layer)

- Long-lasting
- Deep wrinkle improvement

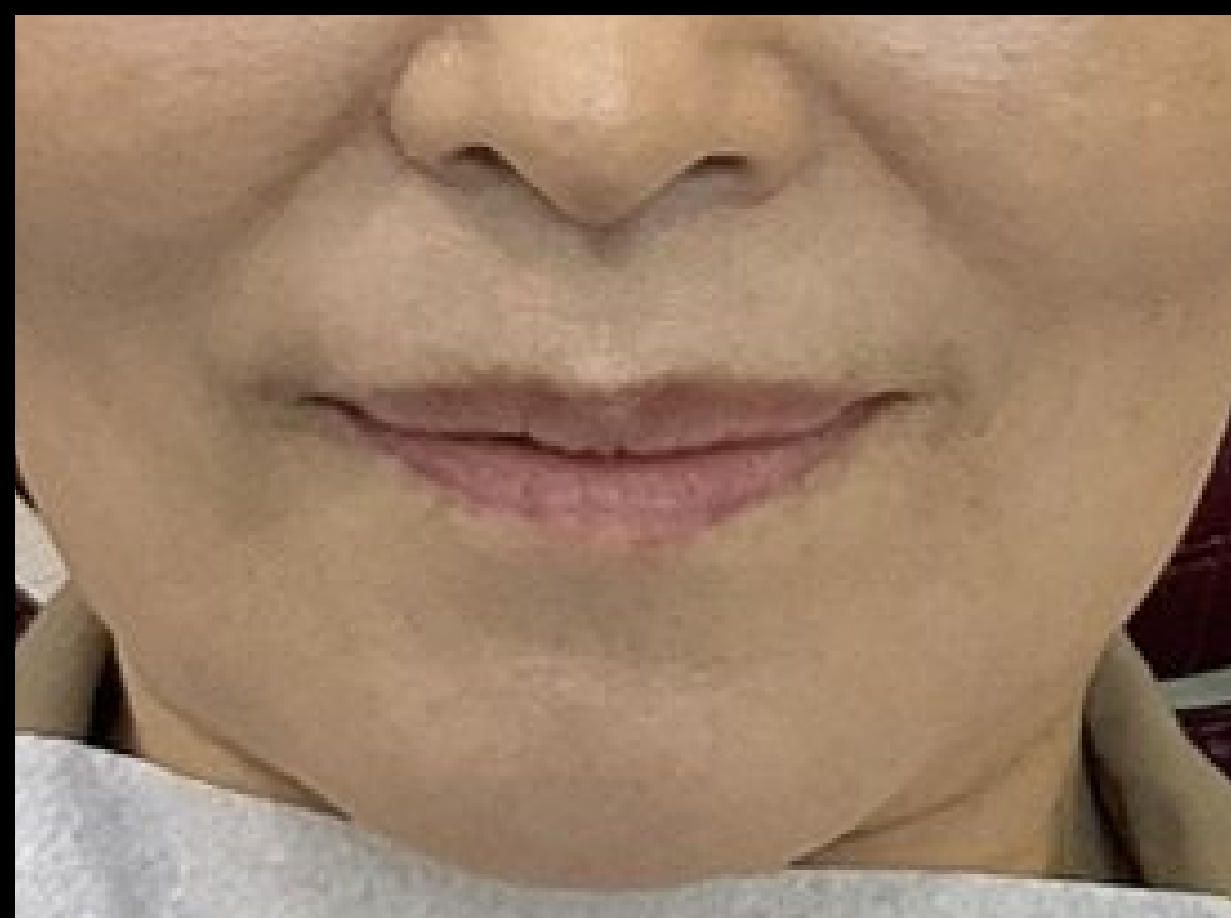
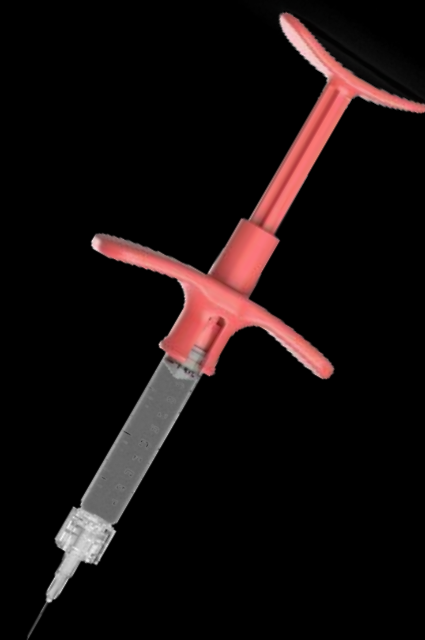
Superficial skin (Superficial fatty layer)

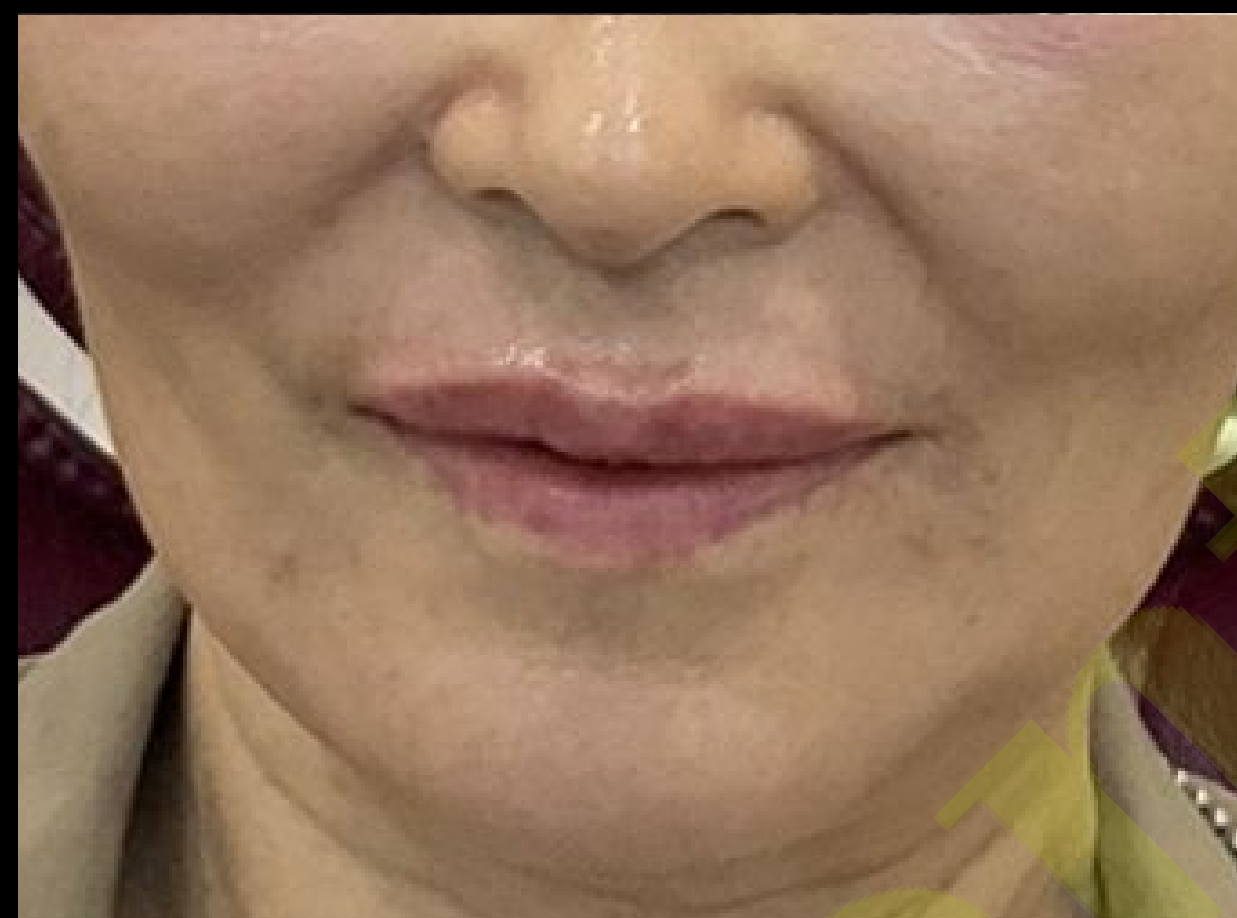- maintain a natural and smooth appearance
- low invasiveness



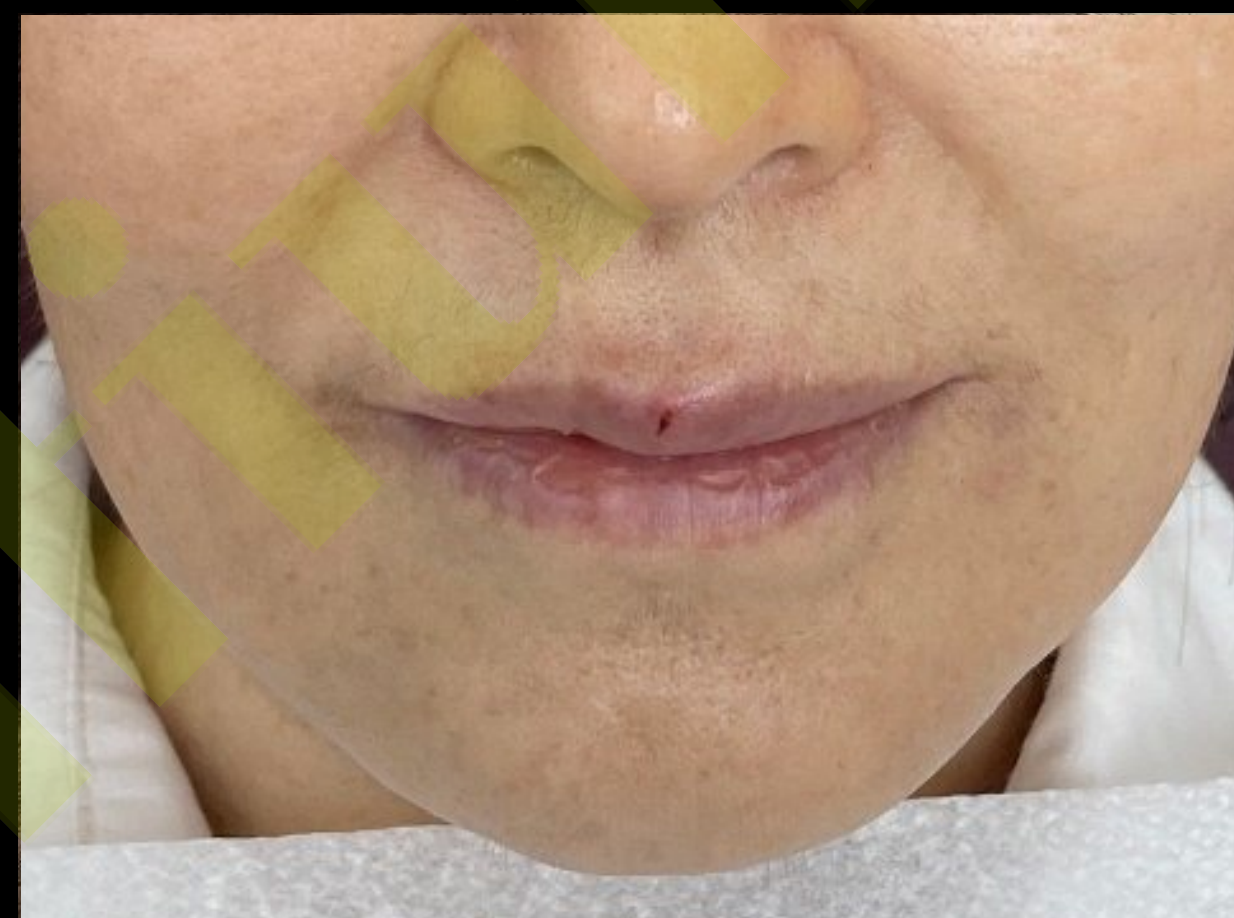Case : Lips



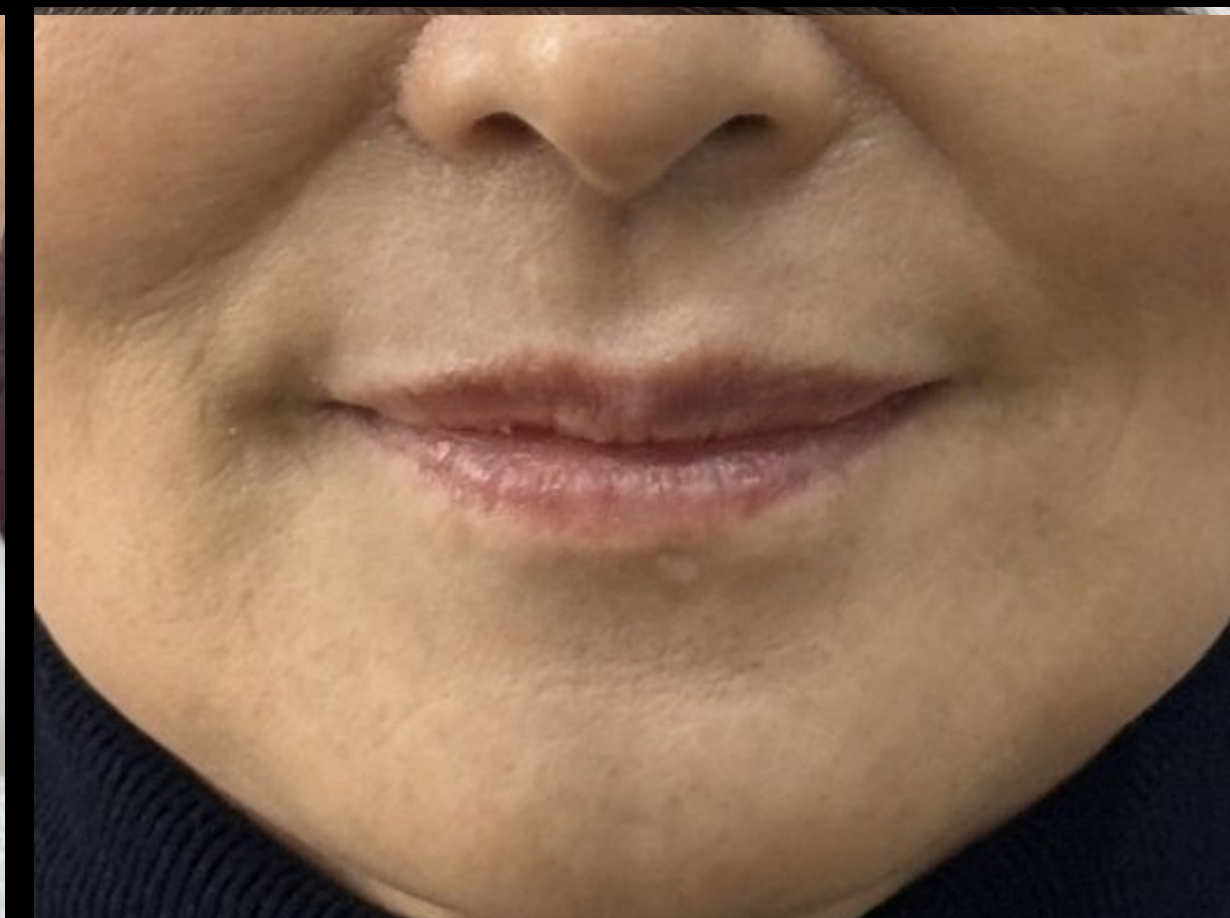Before



After

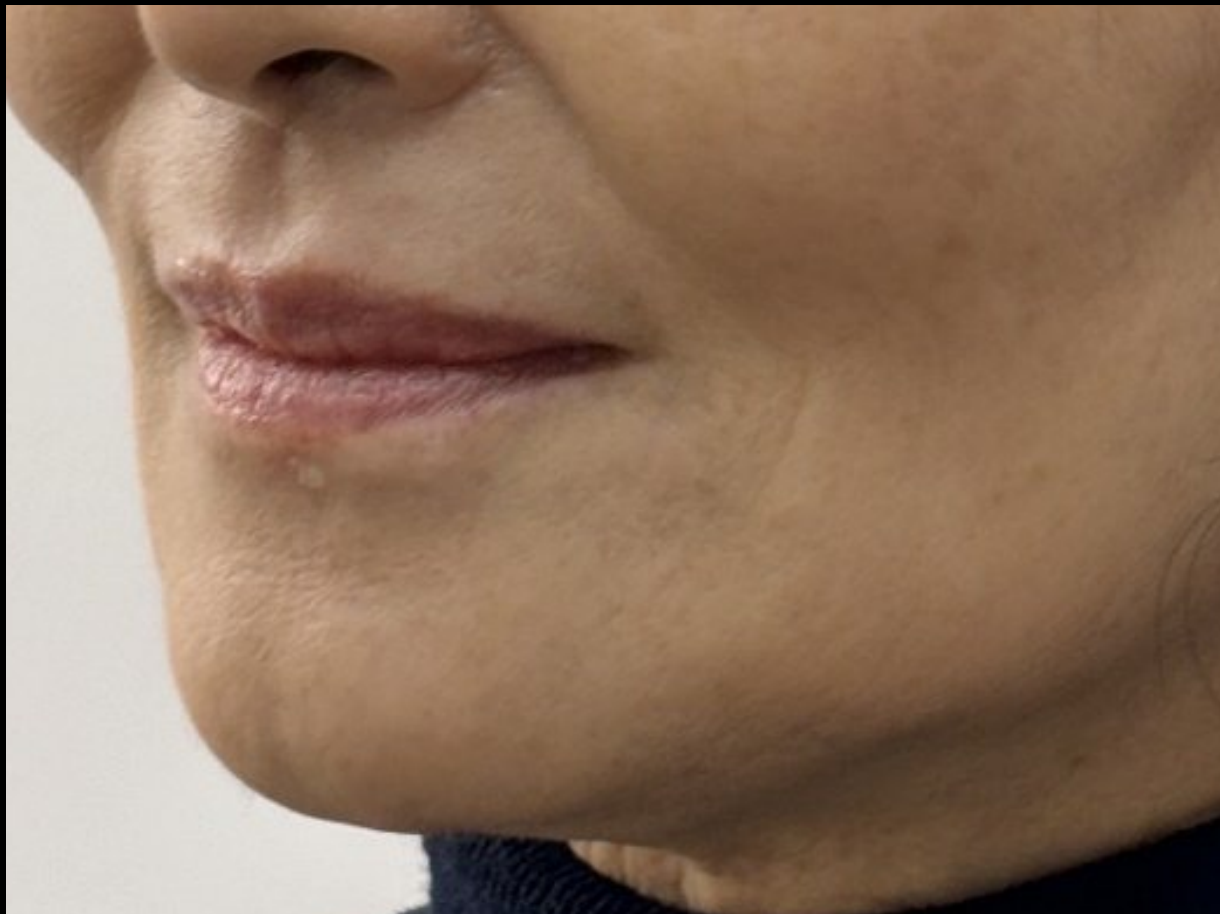
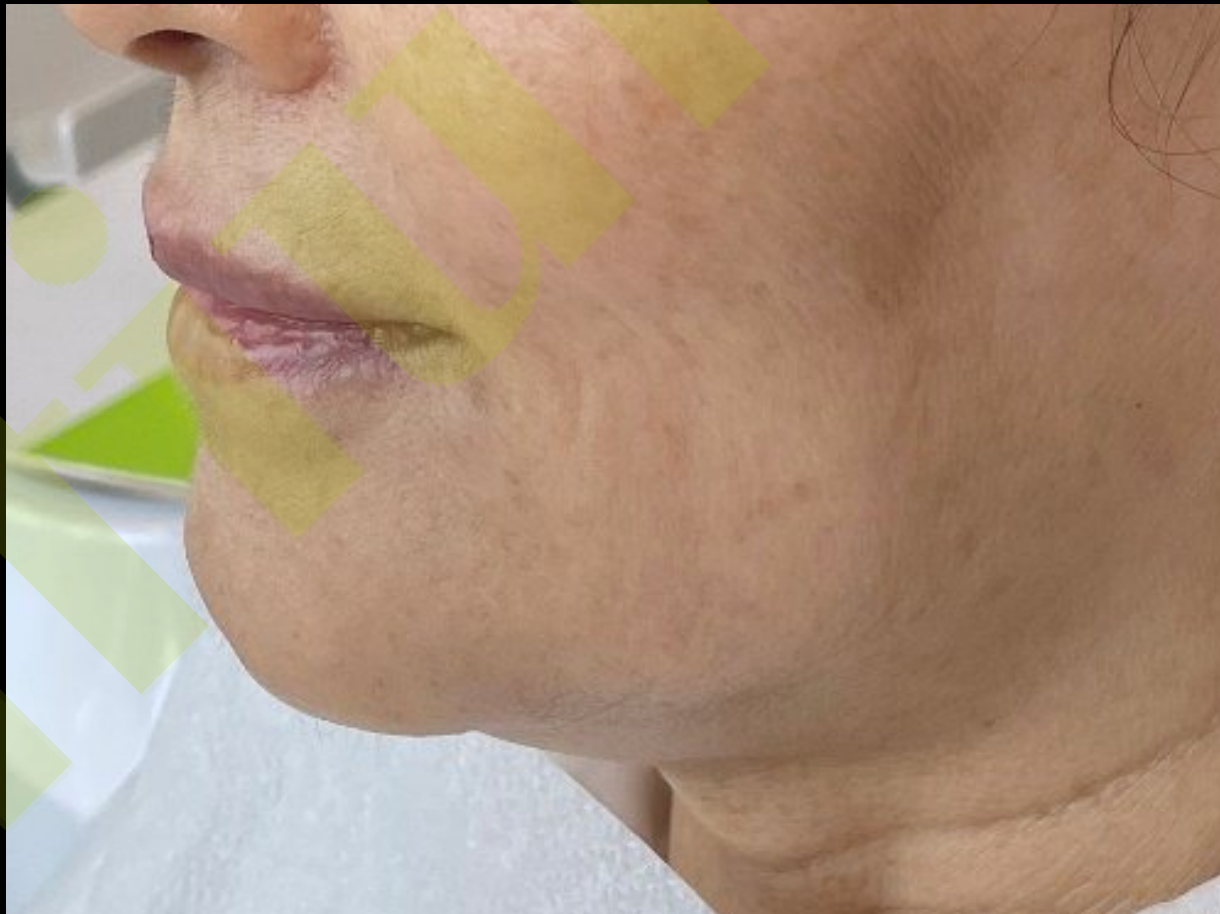
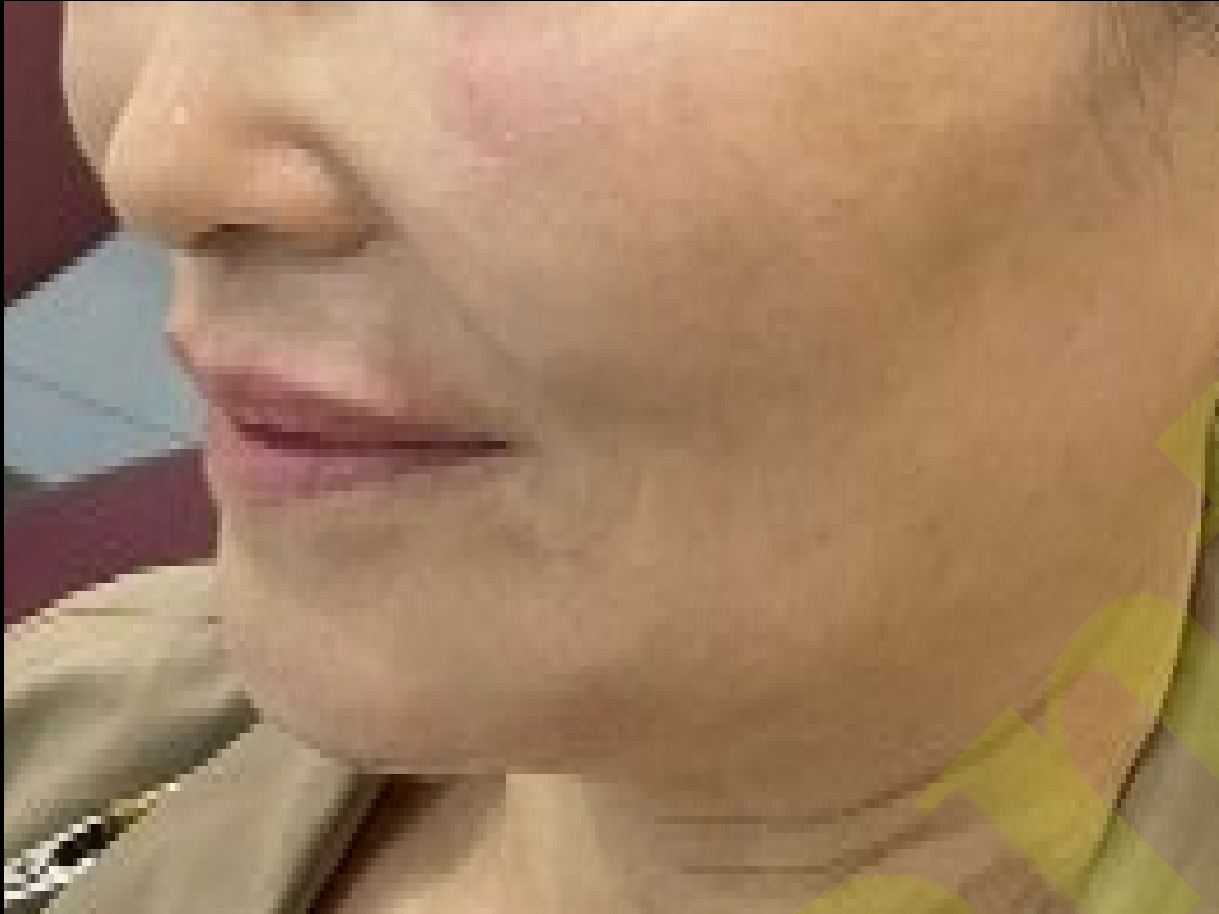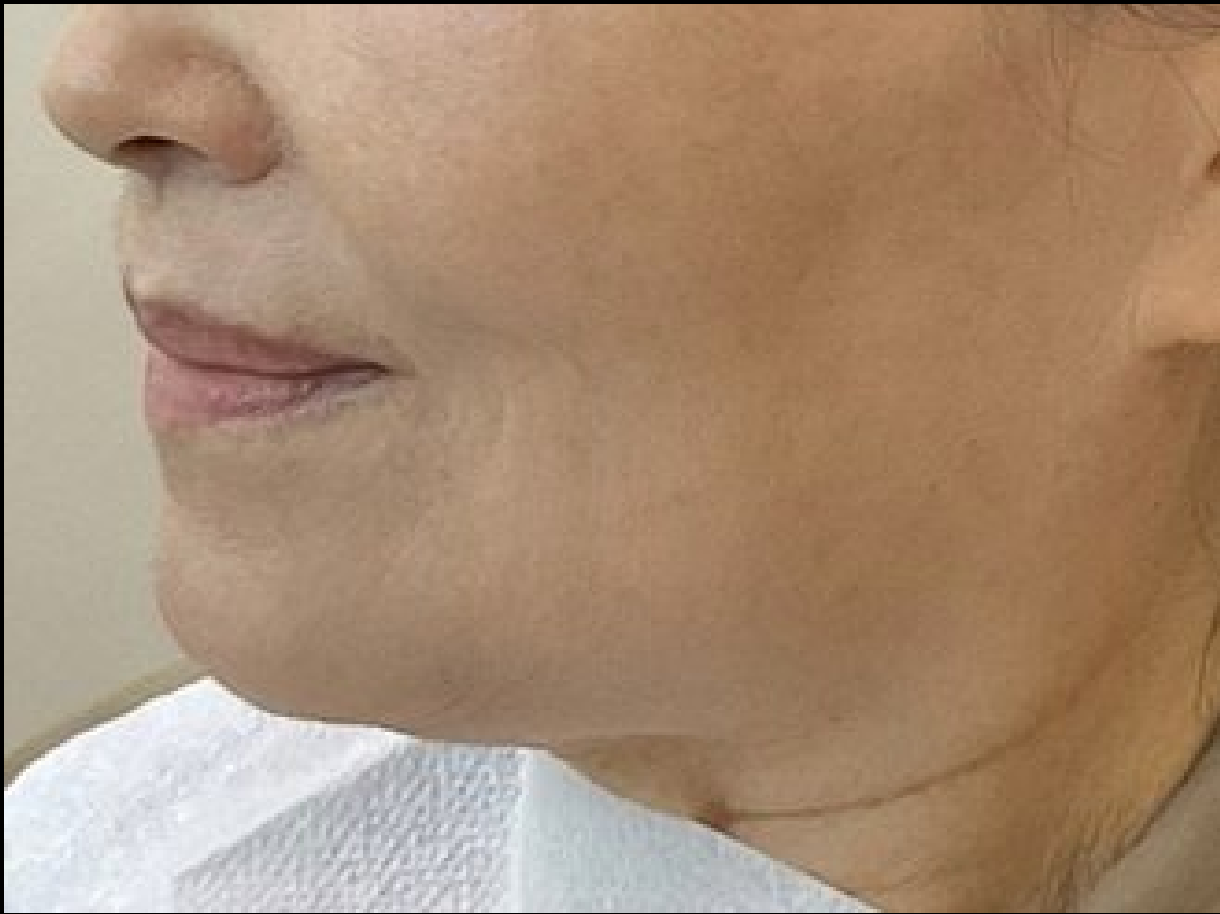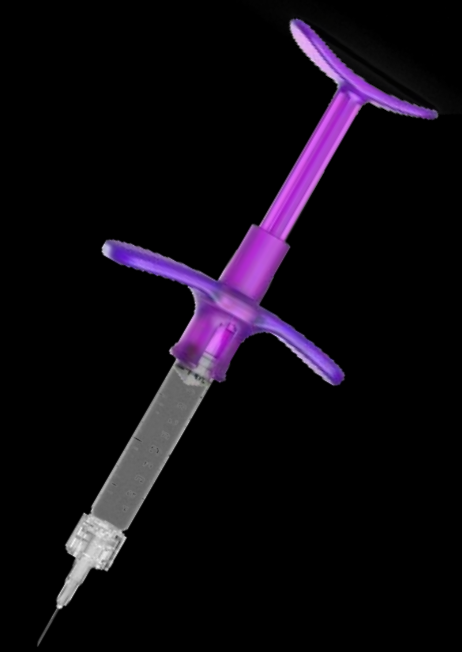2 Weeks Later



6 Months Later

Case : Jaw Contour



Before

After

2 Weeks Later

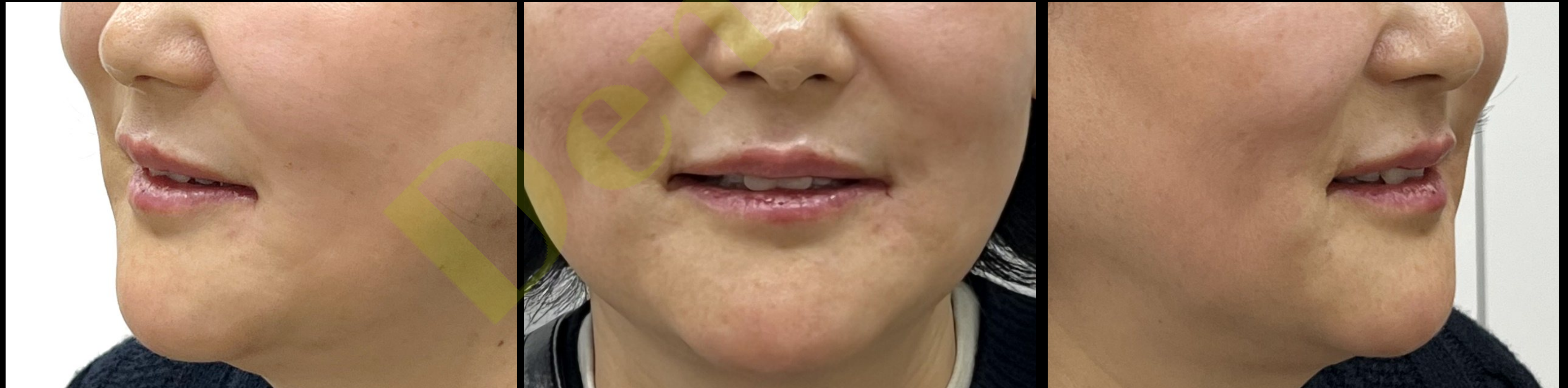6 Months Later

Clinical case : Nasolabial folds & Marionette Line & Lip

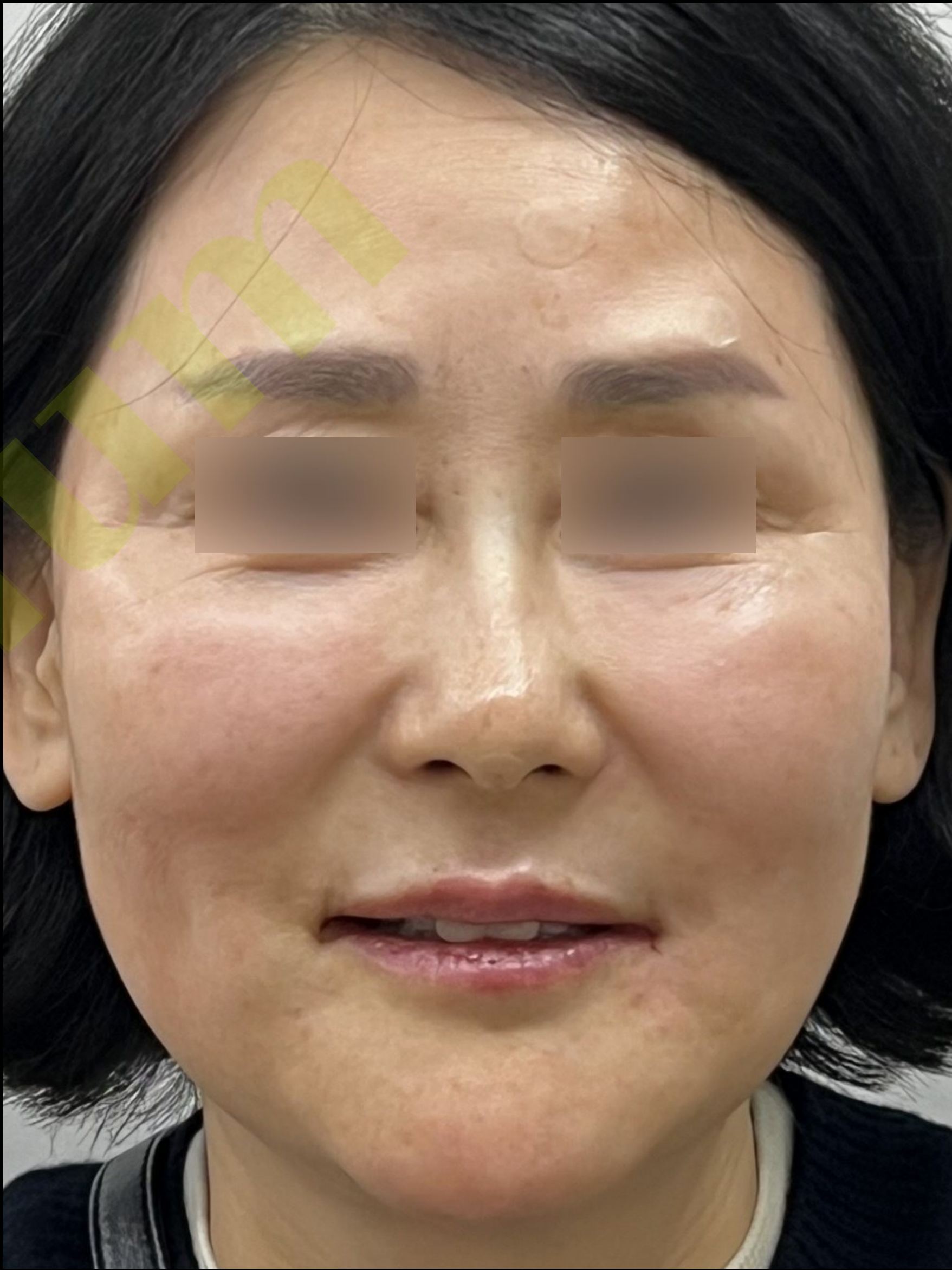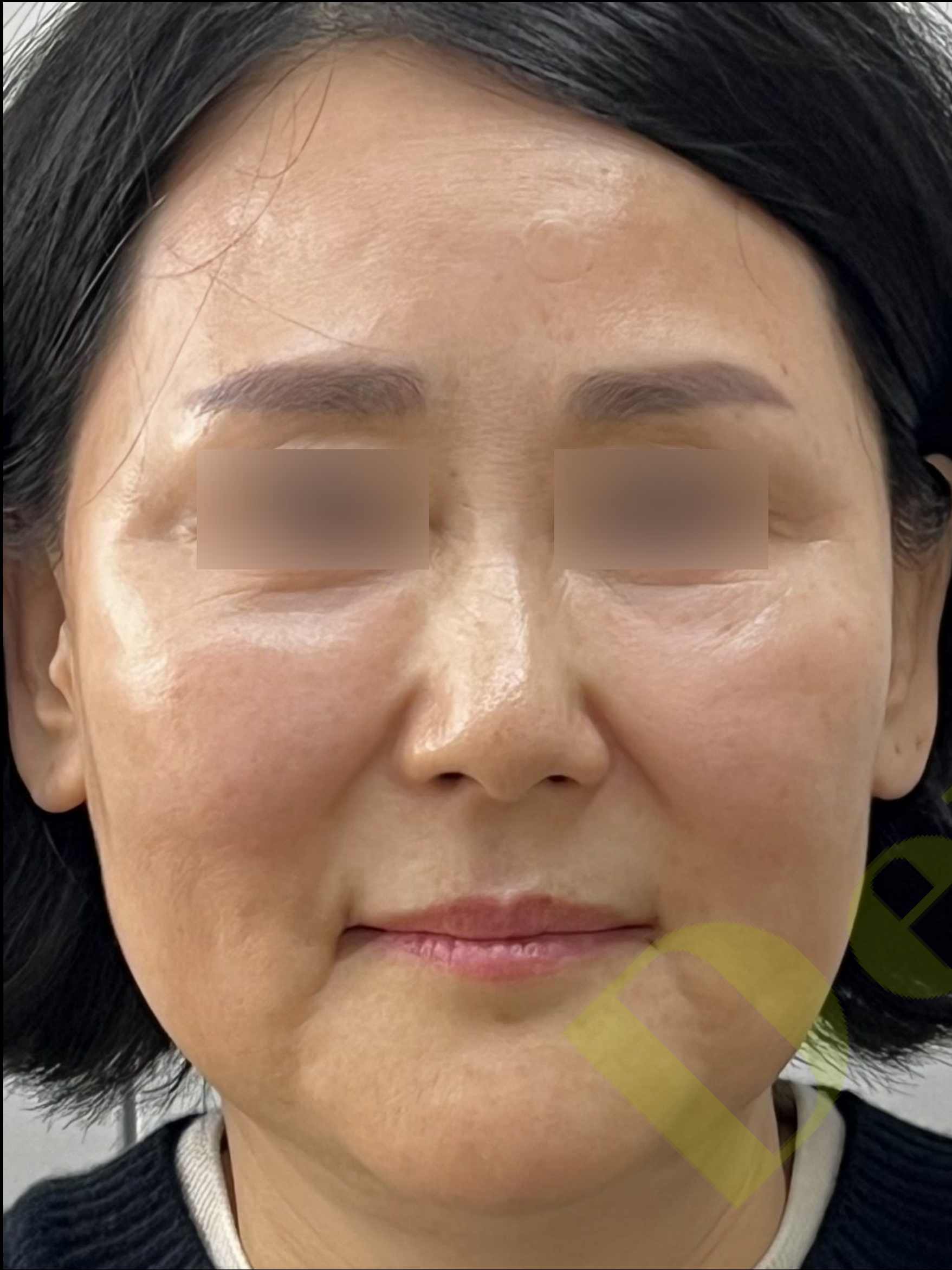Before



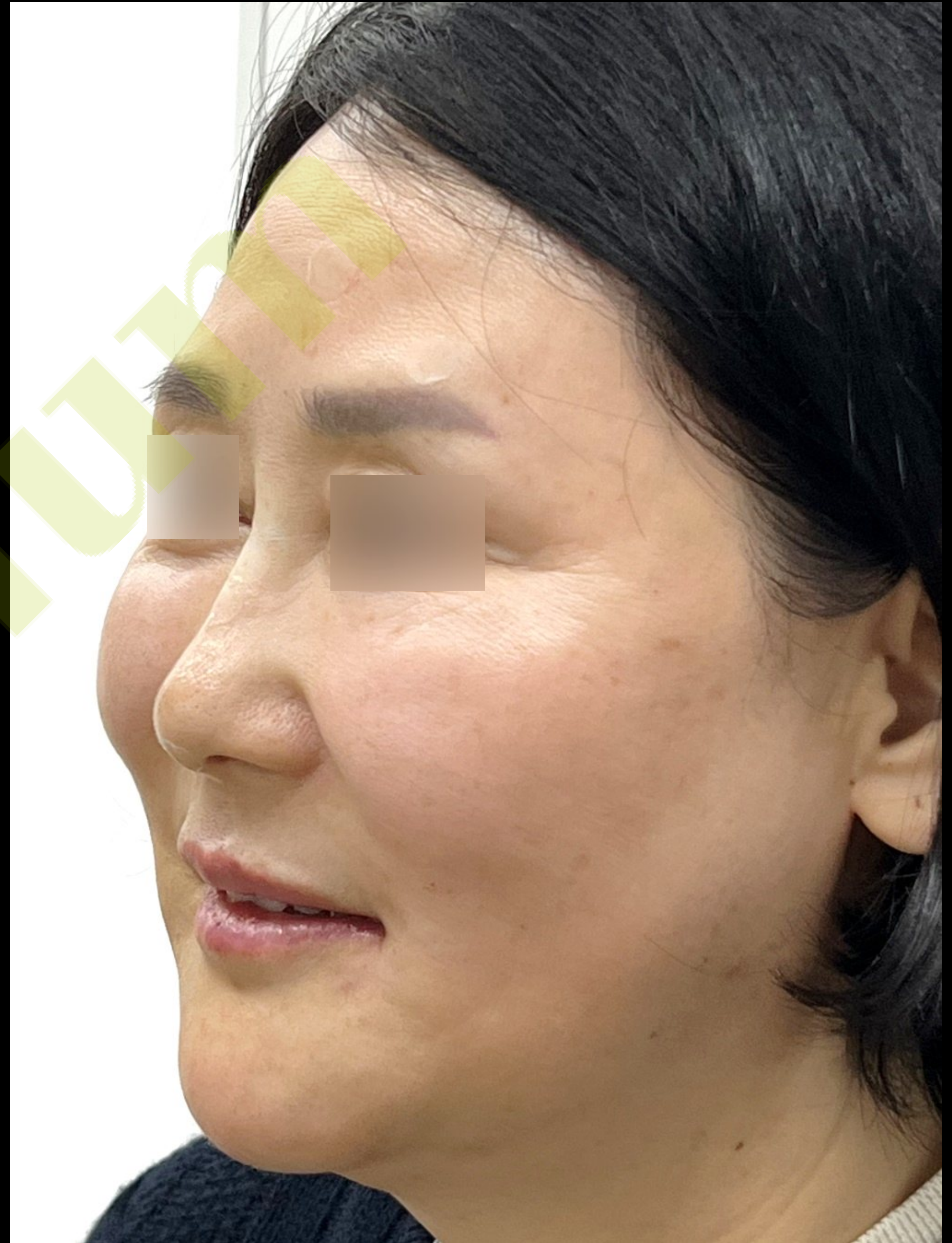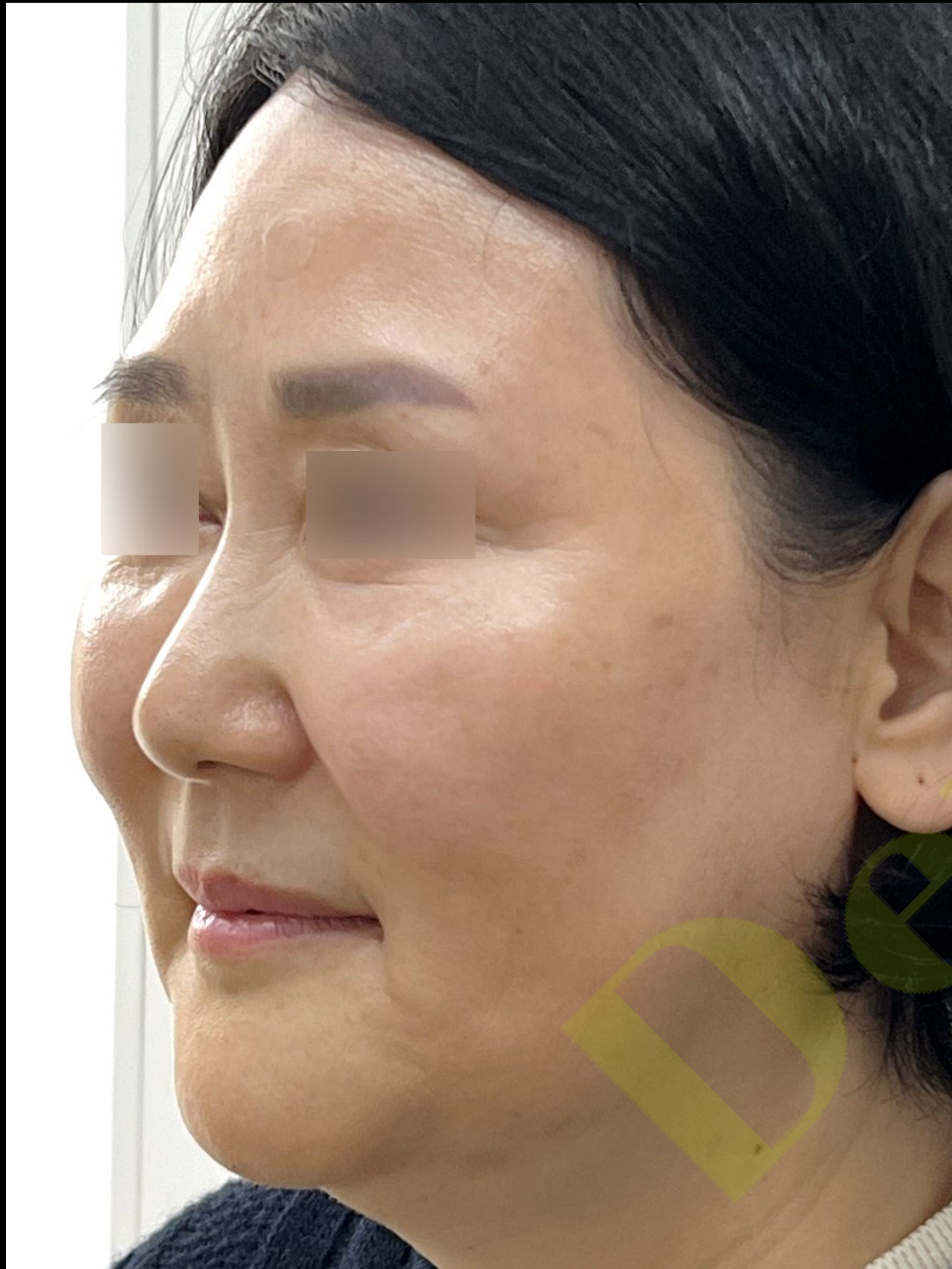After



Before & After



Before & After



Hyaluronic Acid Dermal Filler with Lidocaine

MONALISA

Contents

Introduction of Monalisa
Application to aged
Combined with dental tx

*Long term
Stability*



Prosthesis + Filler

(Bright mono, bright CT, facial Scan,
High elastic, smile)

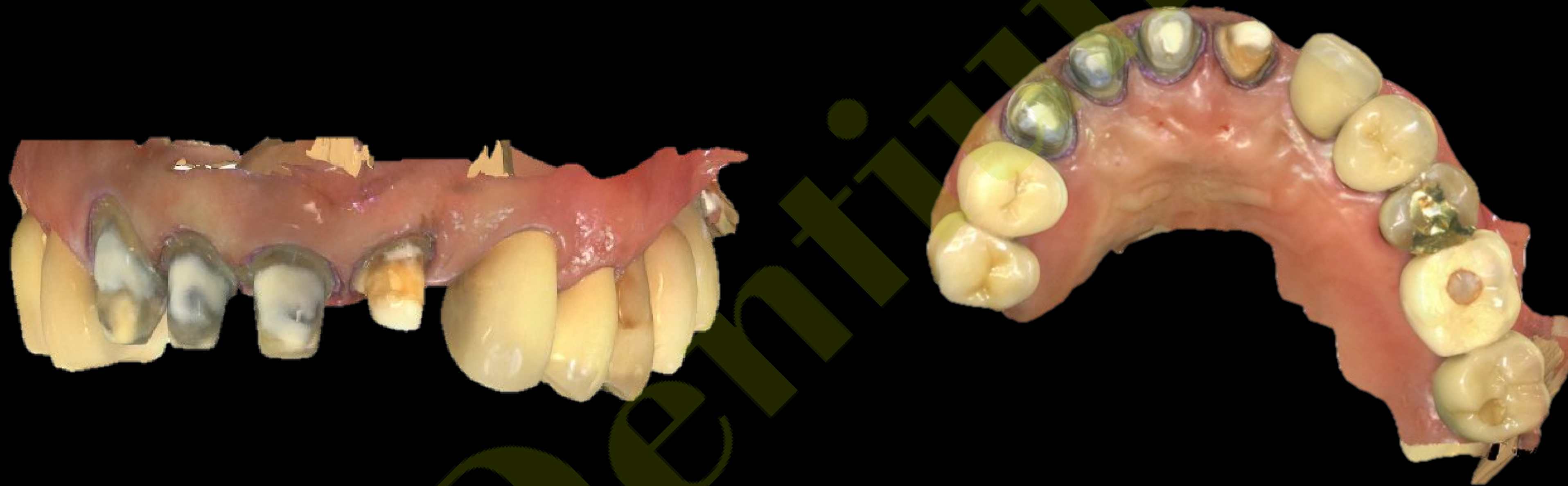Pt.1959 / M

Virtual Set-up combined with facial scanner

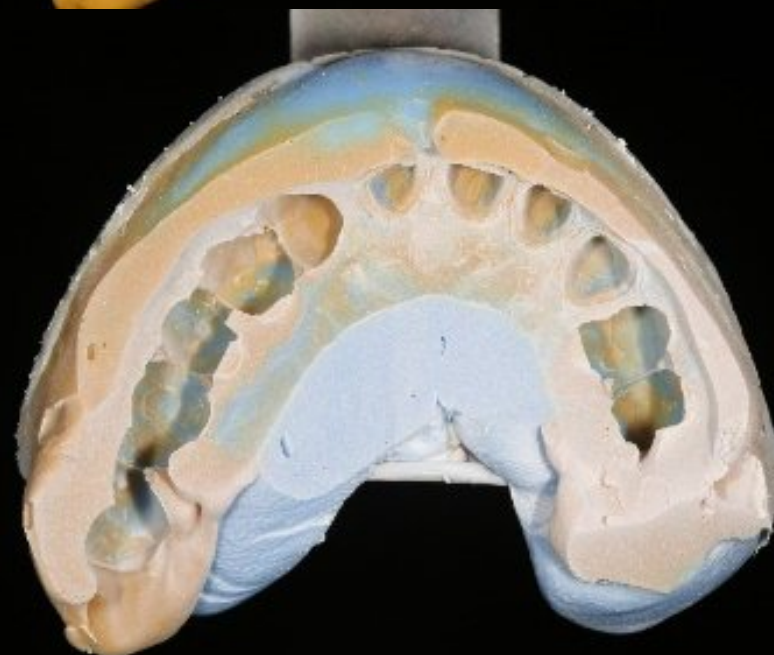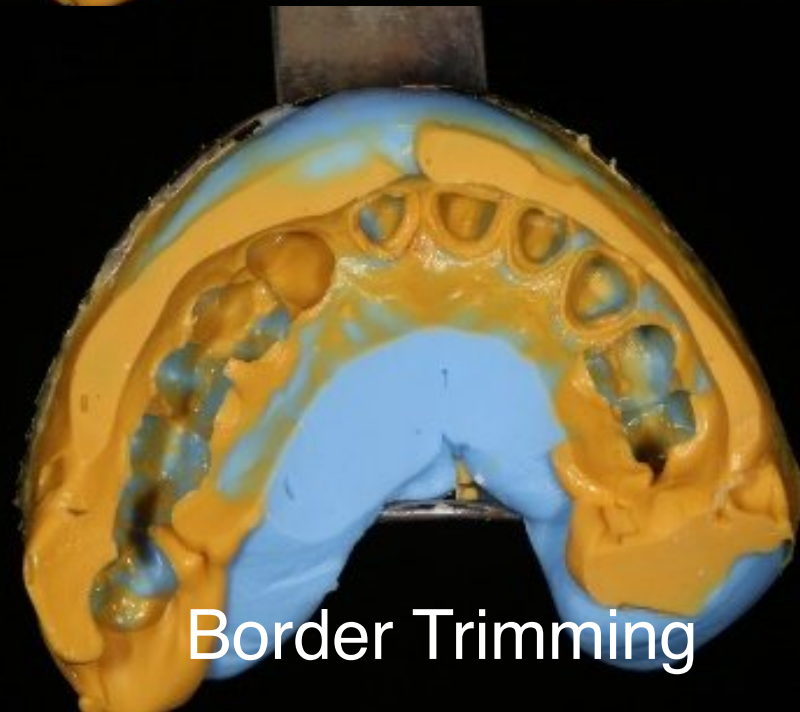

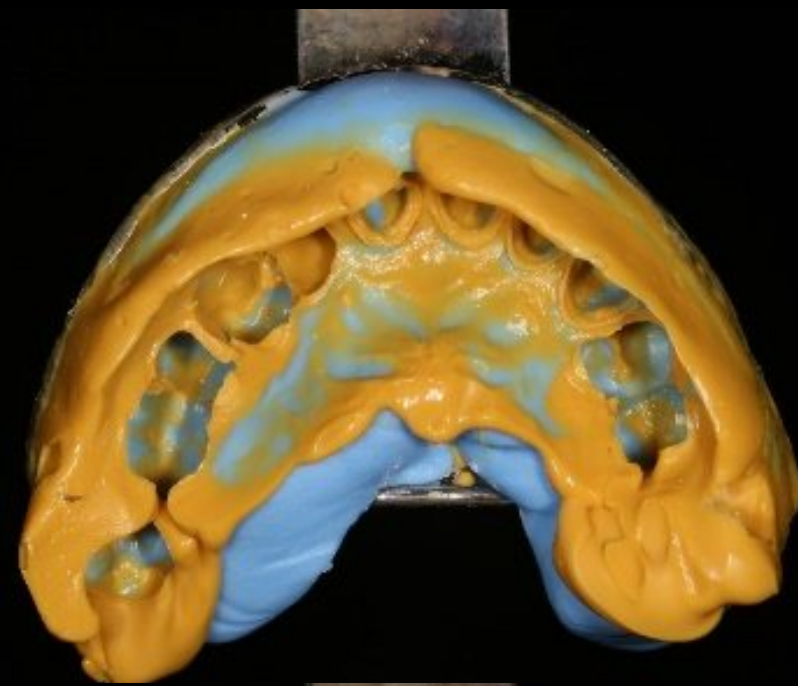
Very good with pts consulting and systemic tx

Dentium

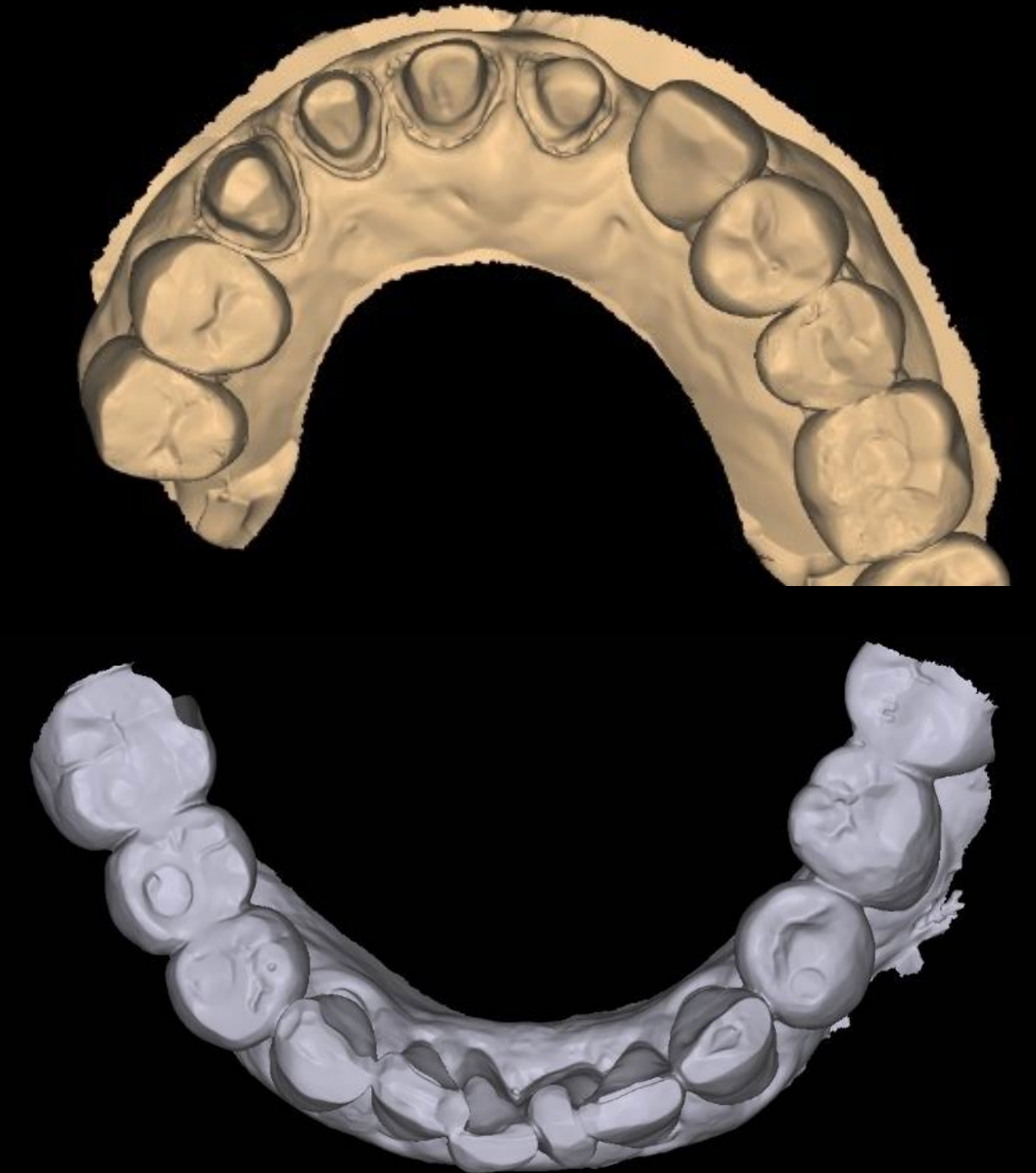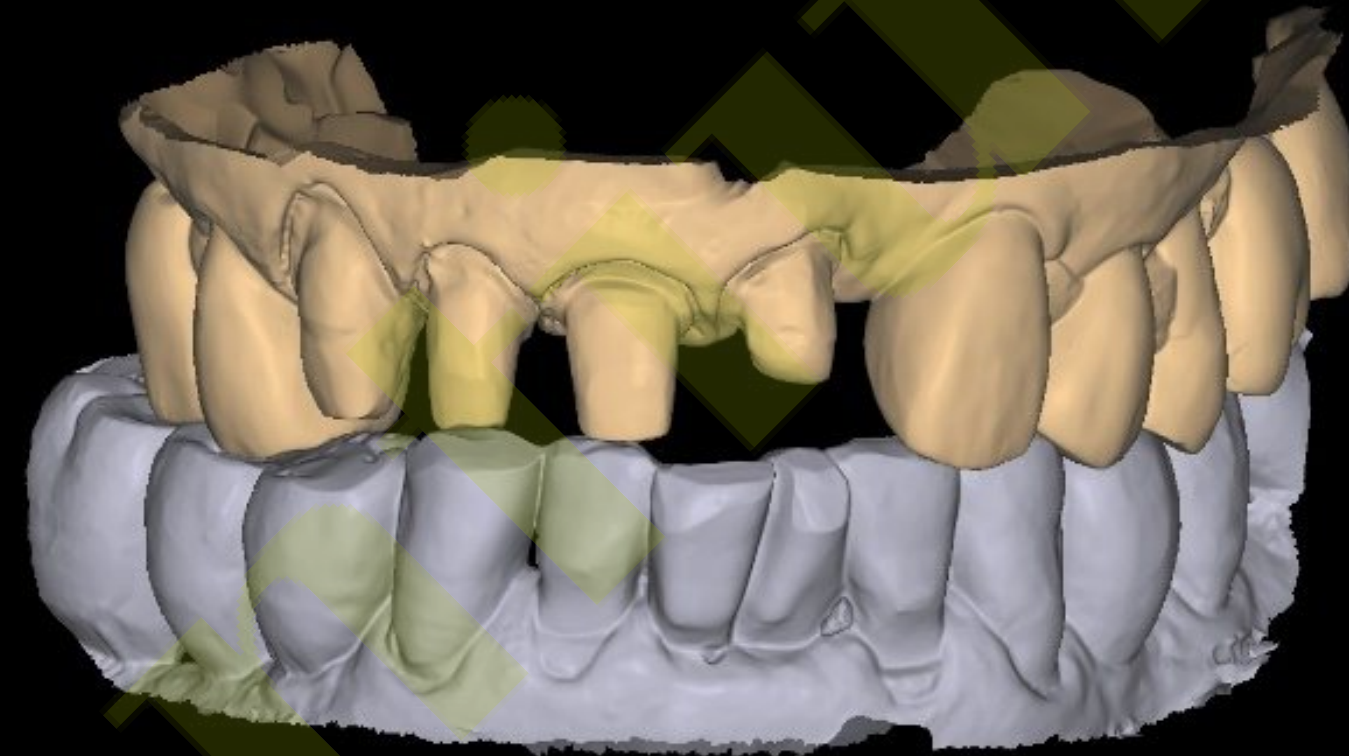



Impression scan for working model



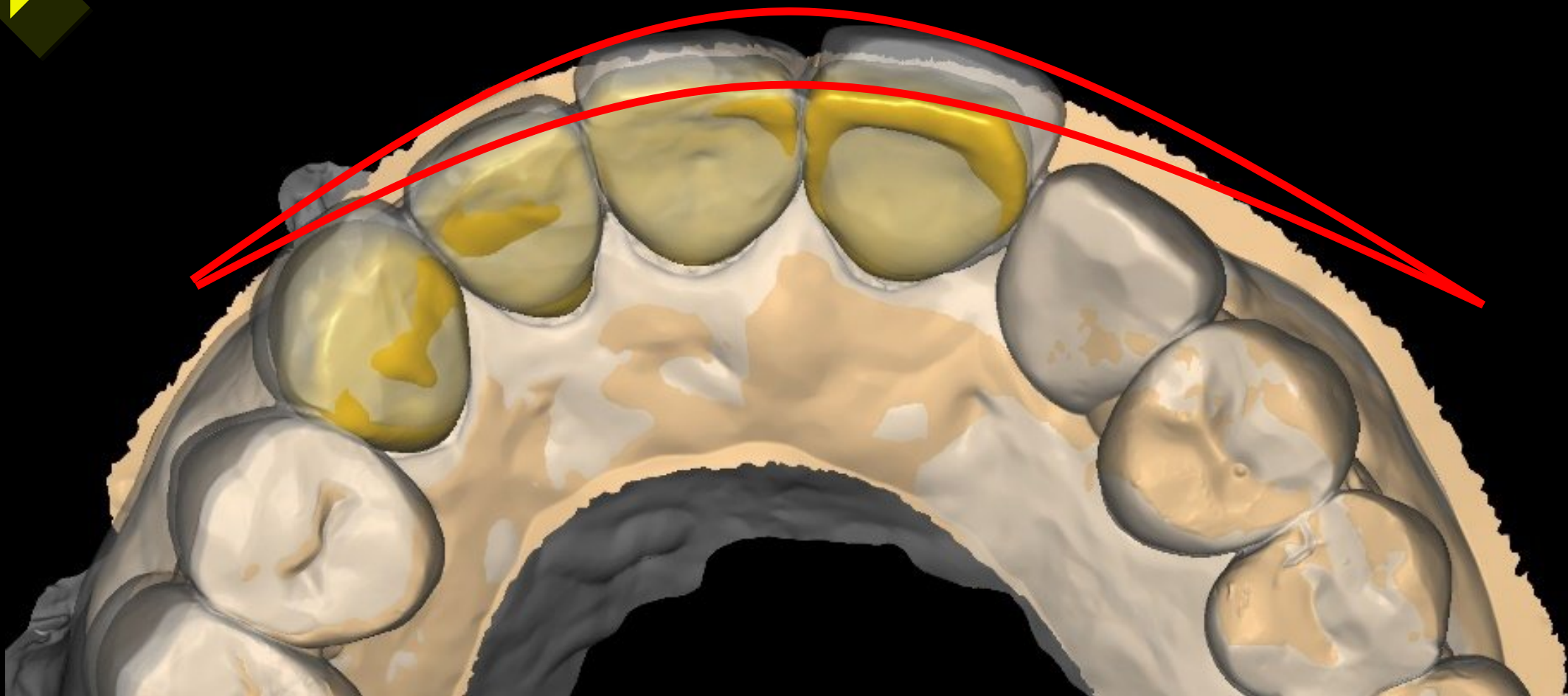
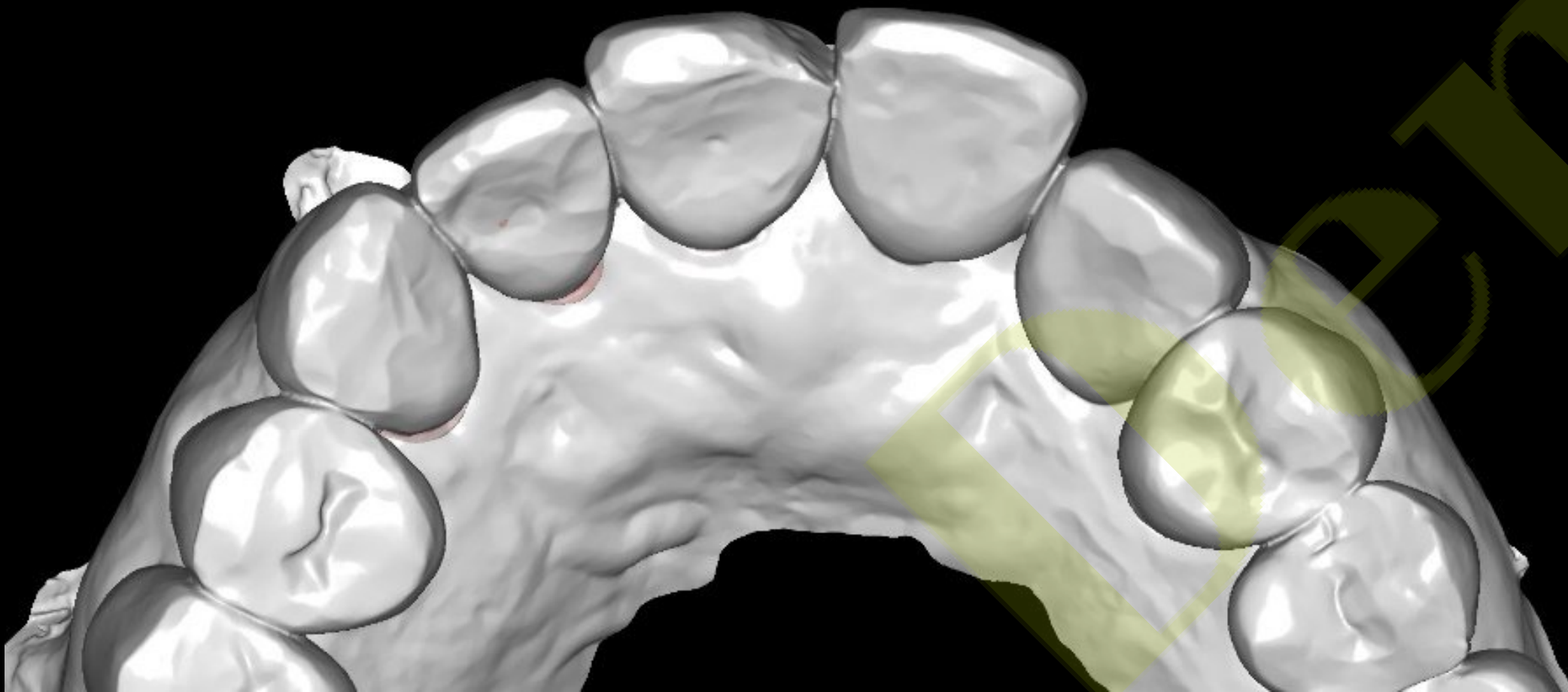

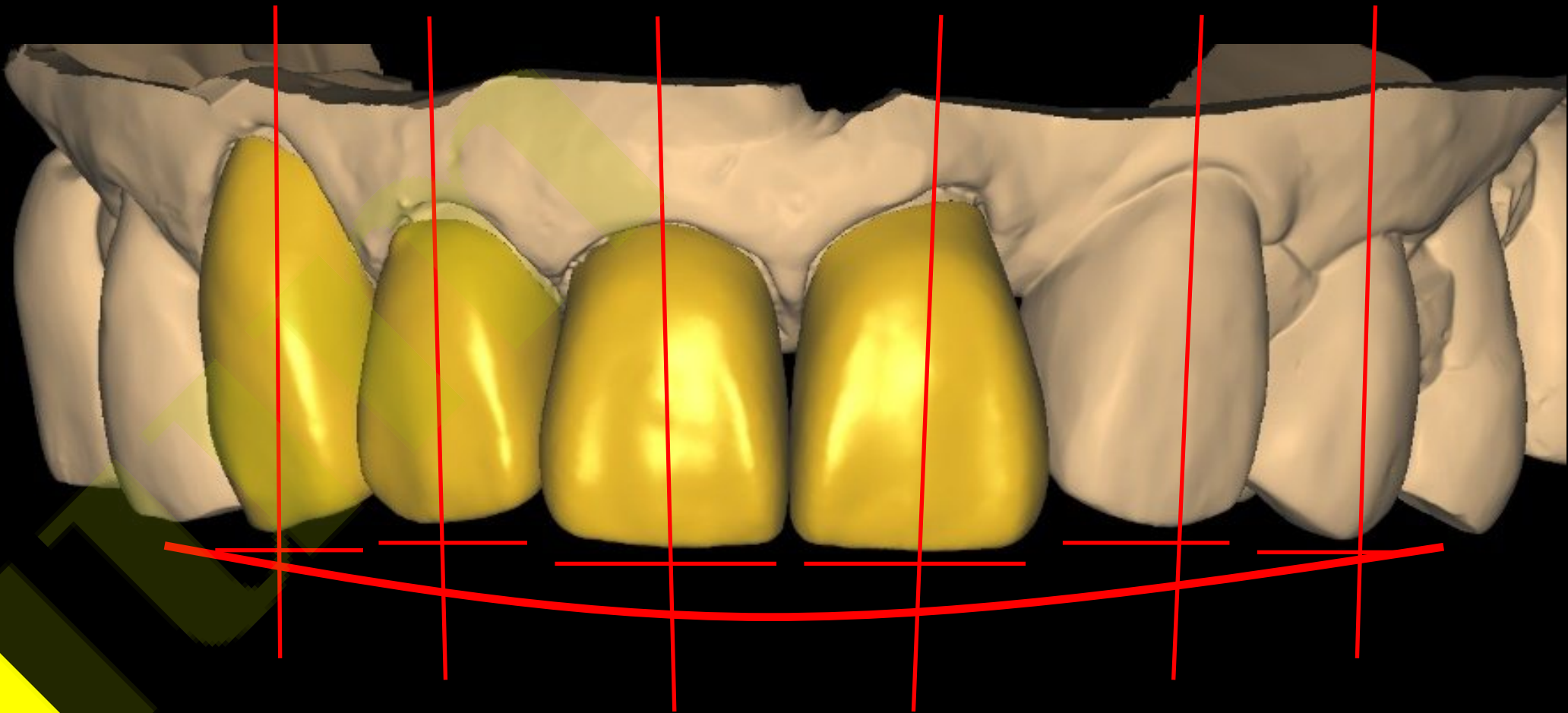
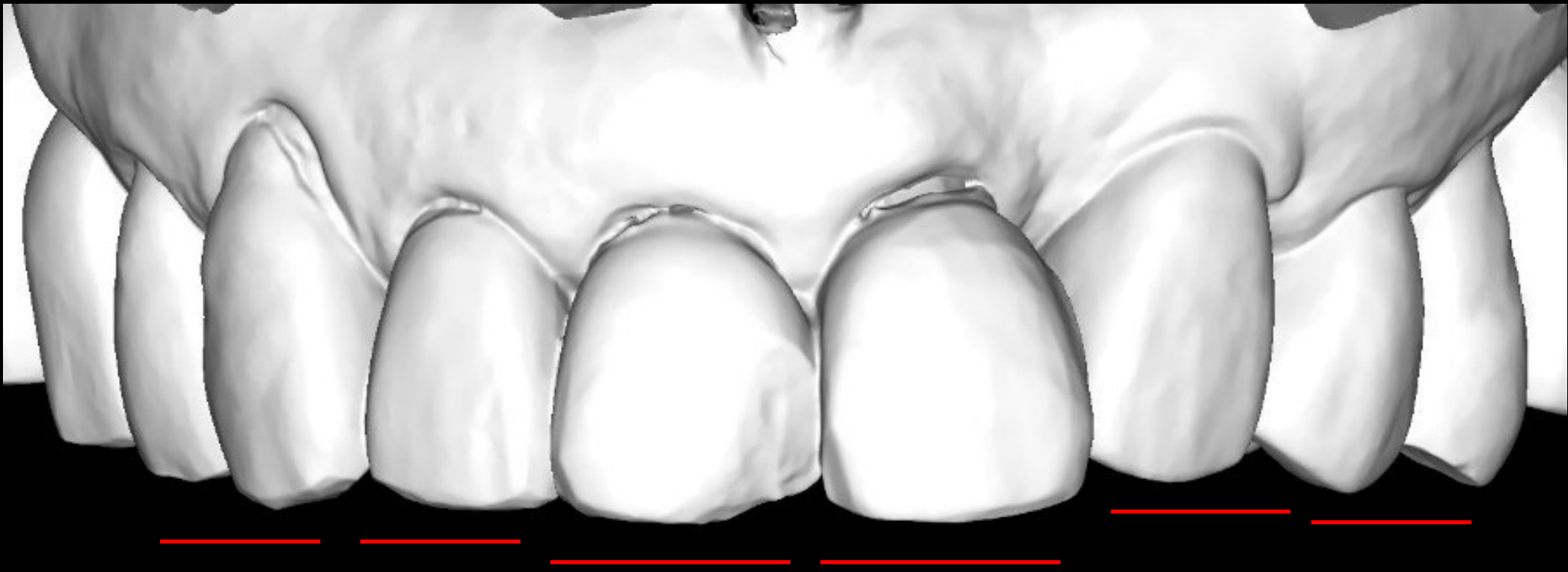
Border Trimming

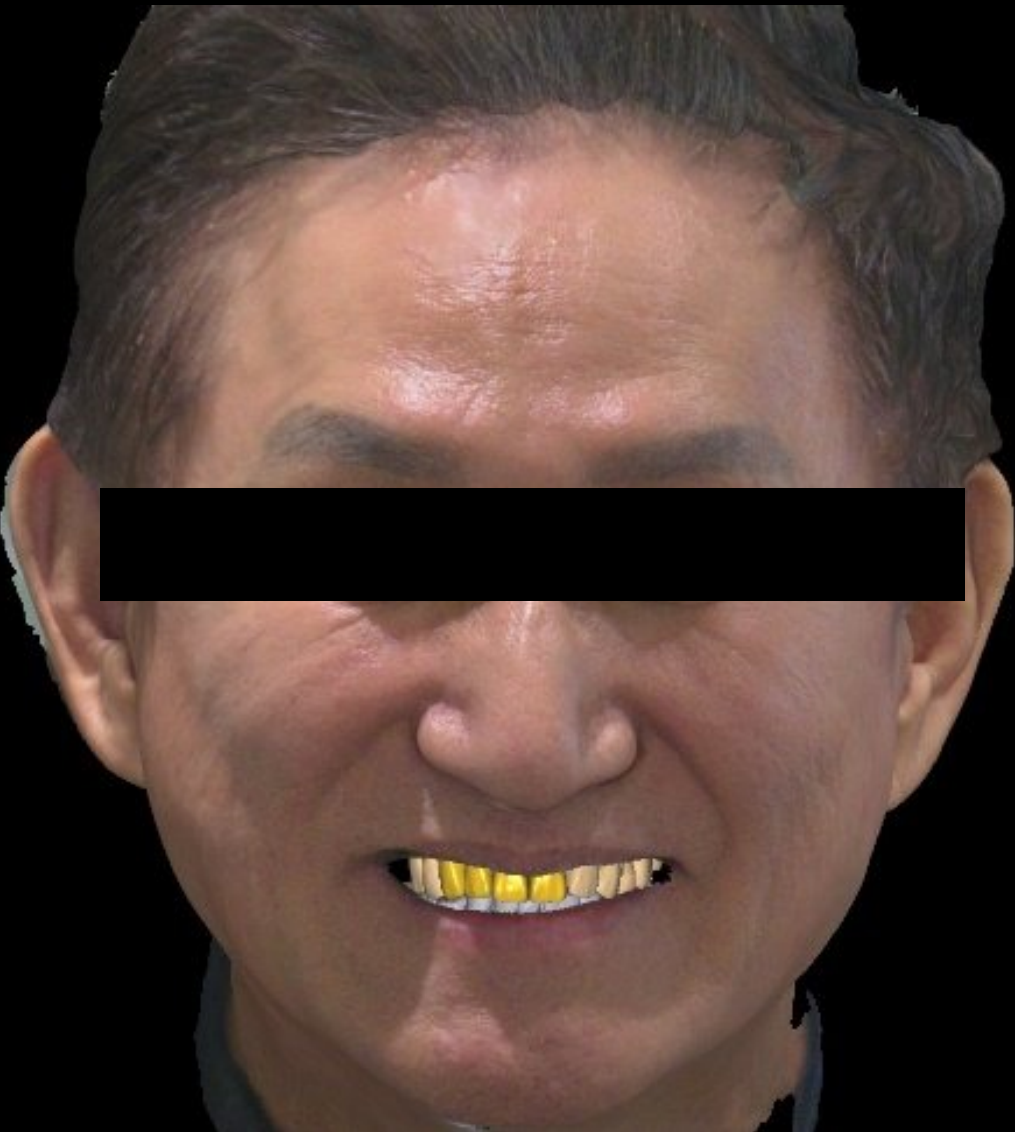Scan spray



Dentium

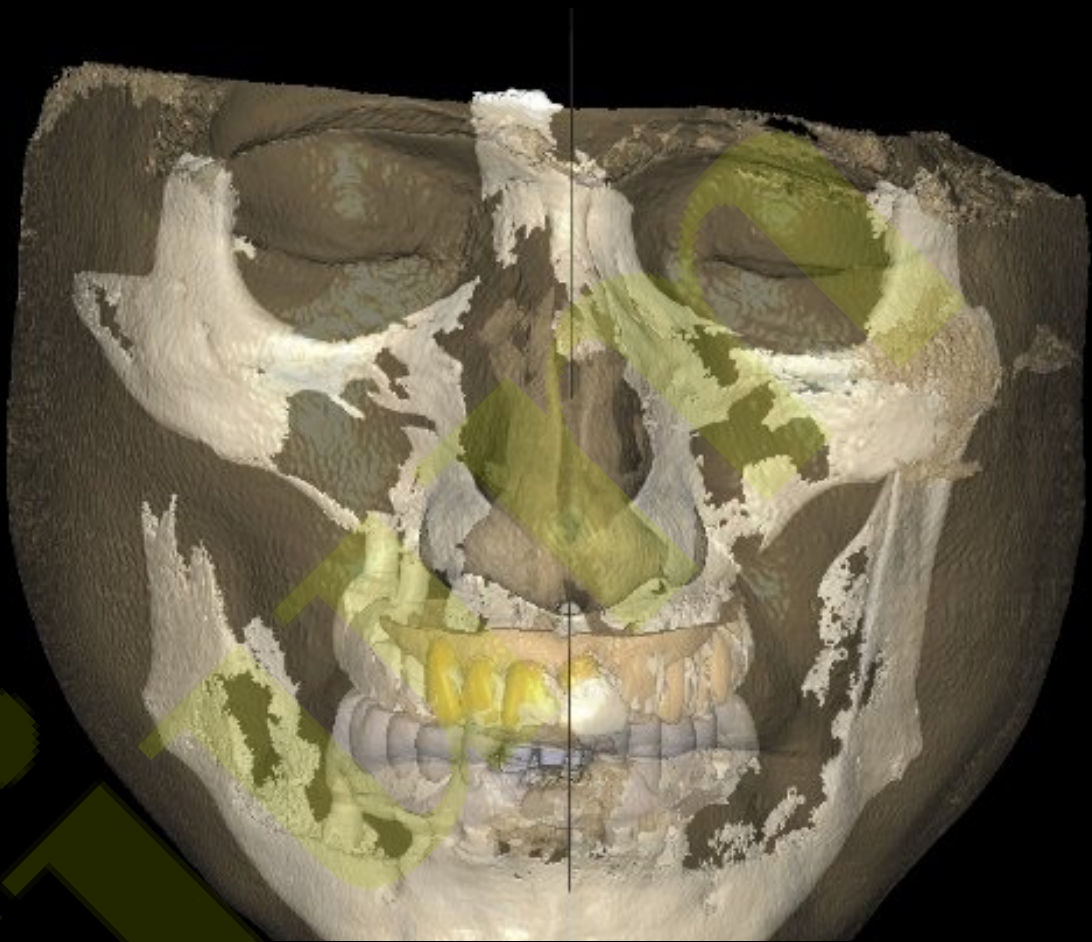Prosthesis design





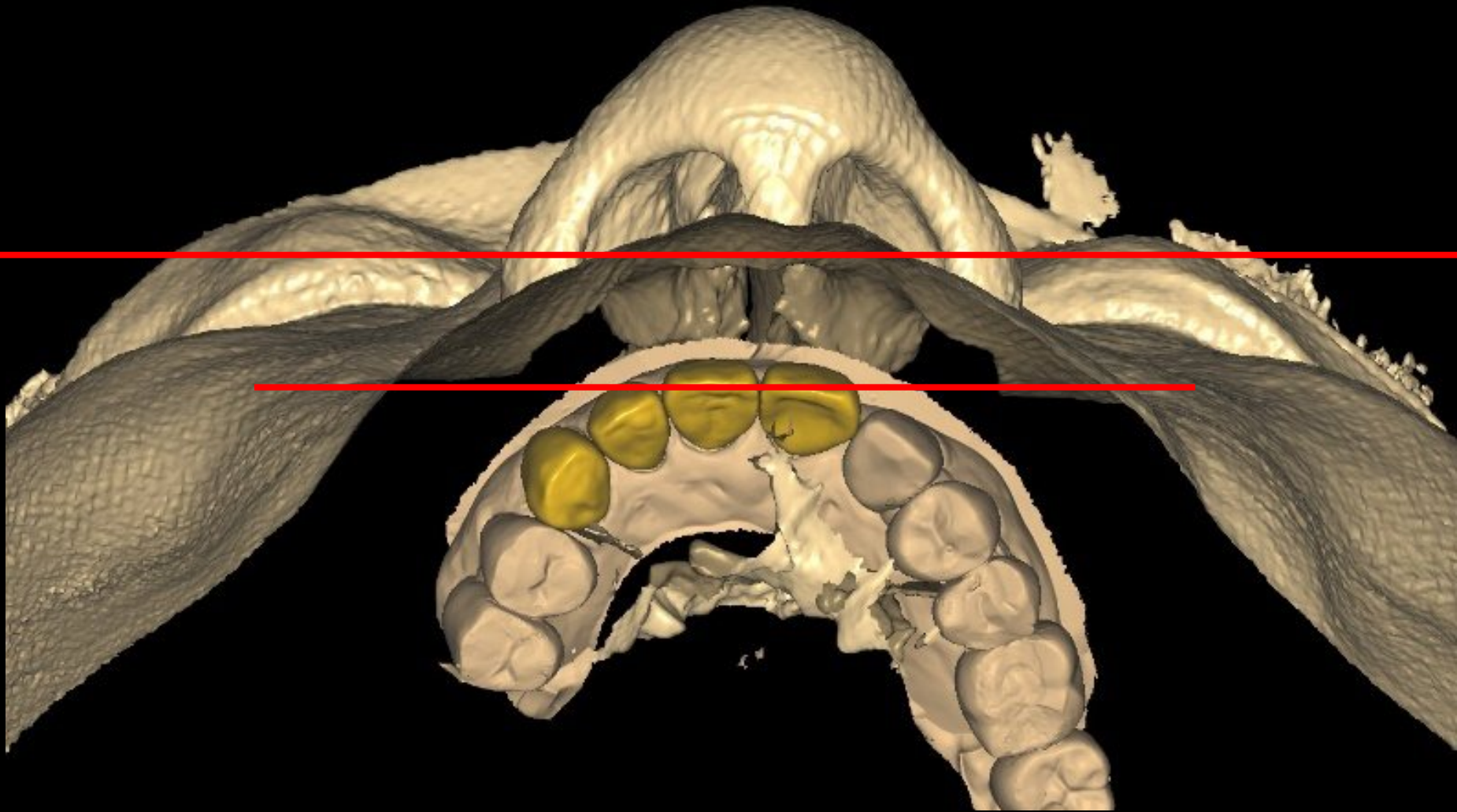
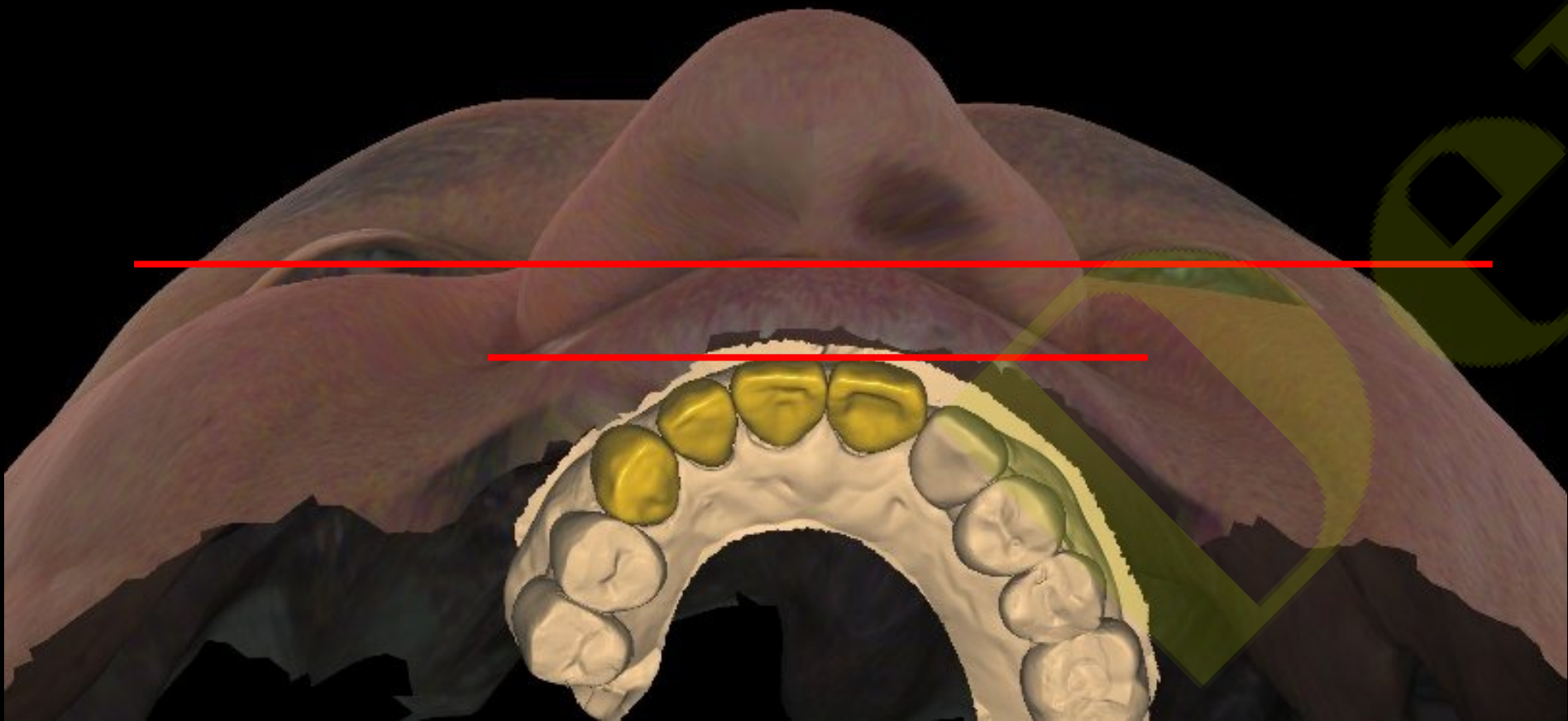
Facial scanner

Good for pts consulting

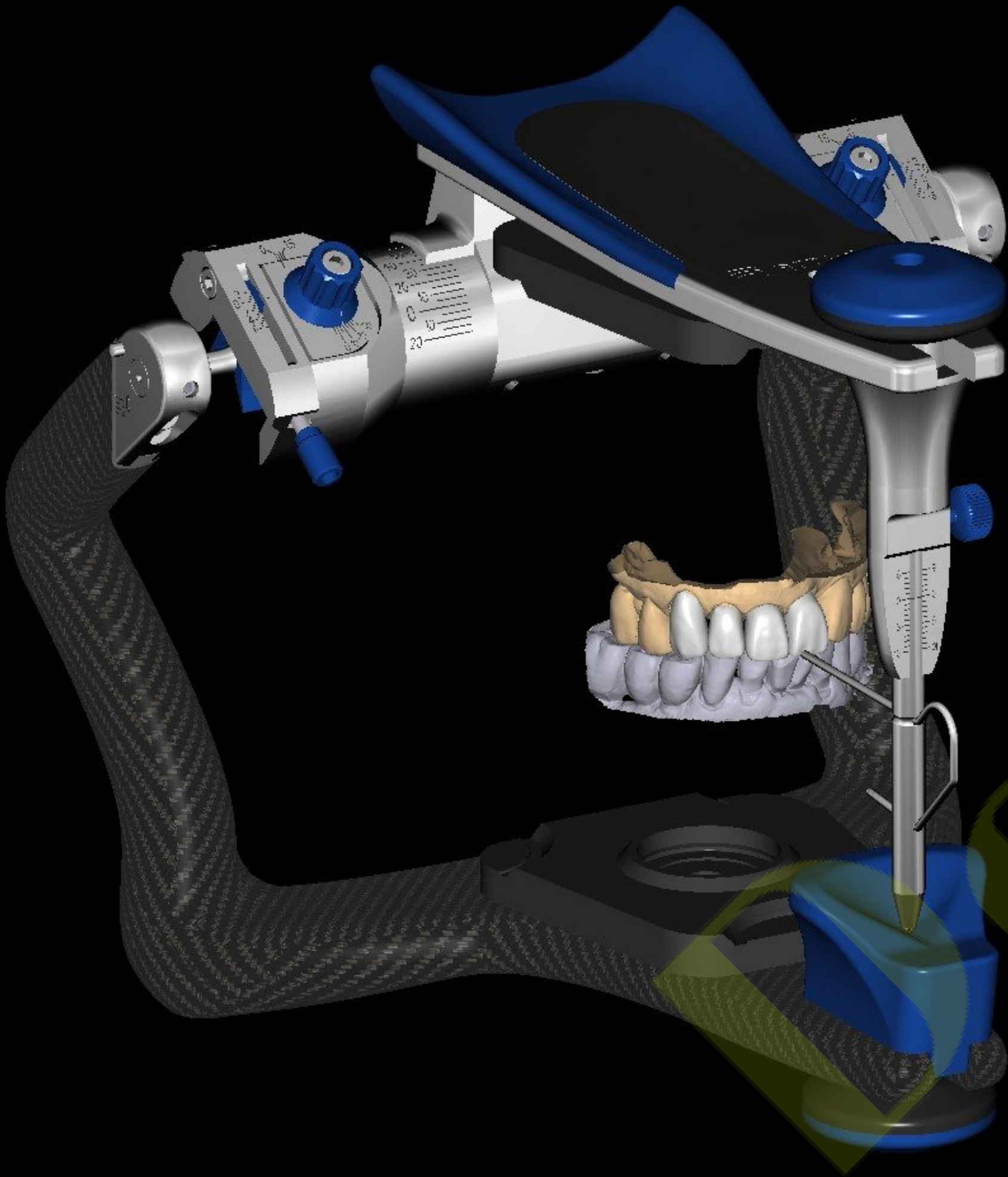


CT STL

More precise for lab



Prosthesis design



-1

-0.88

-0.75

-0.62

-0.5

-0.38

-0.25

-0.12

...

교합점 보기

?

대합치

인접치

Include healthy

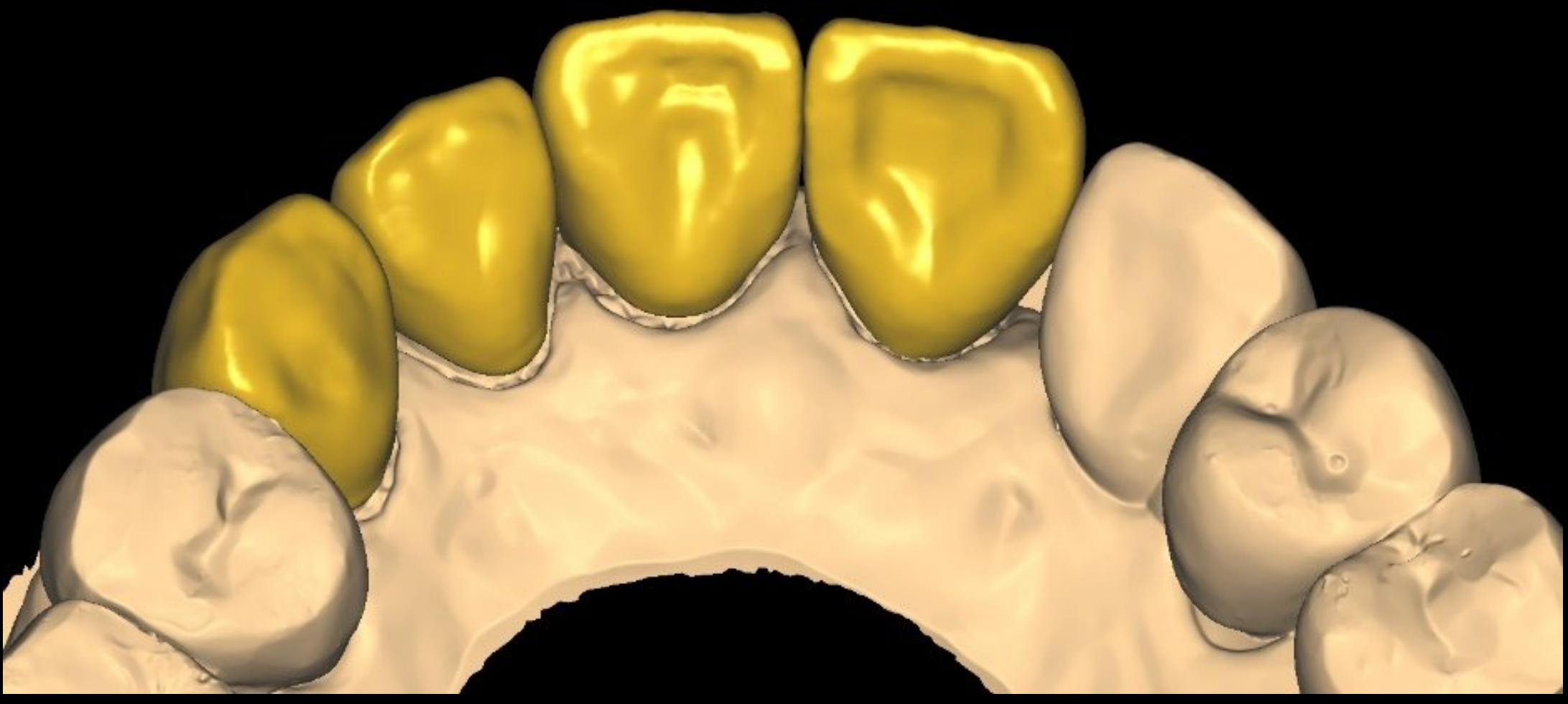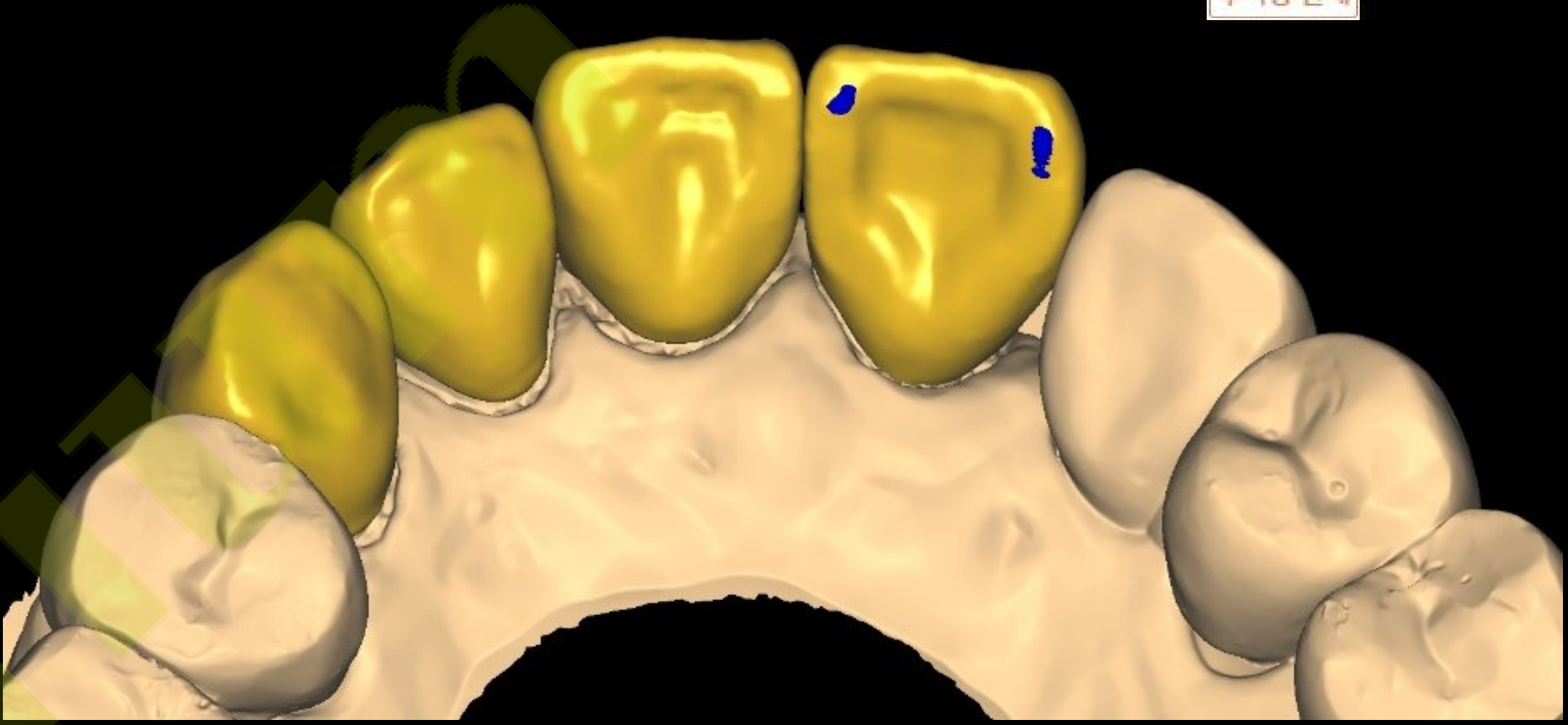
다이나믹

좌측방 한계

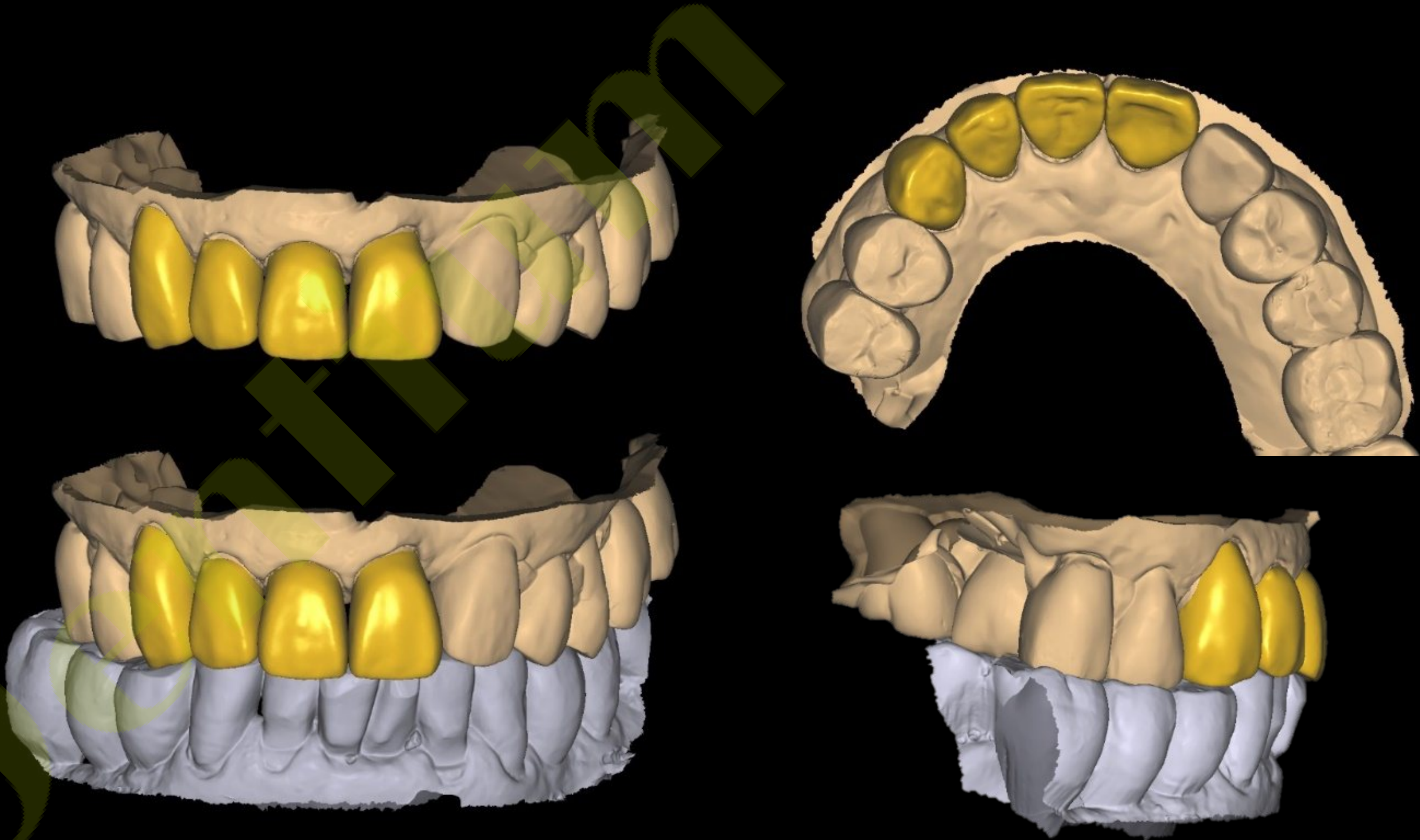
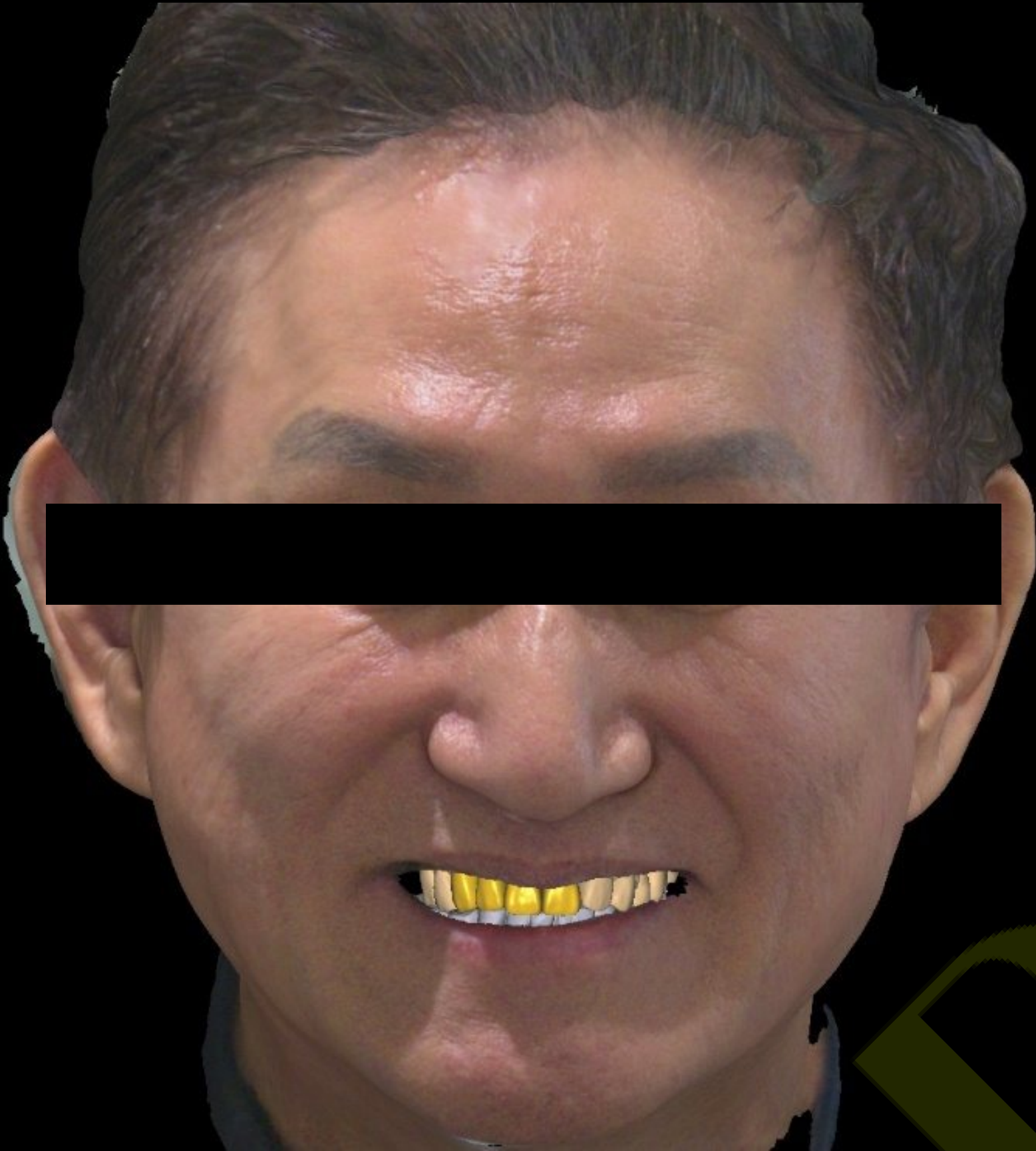전방한계

후방한계

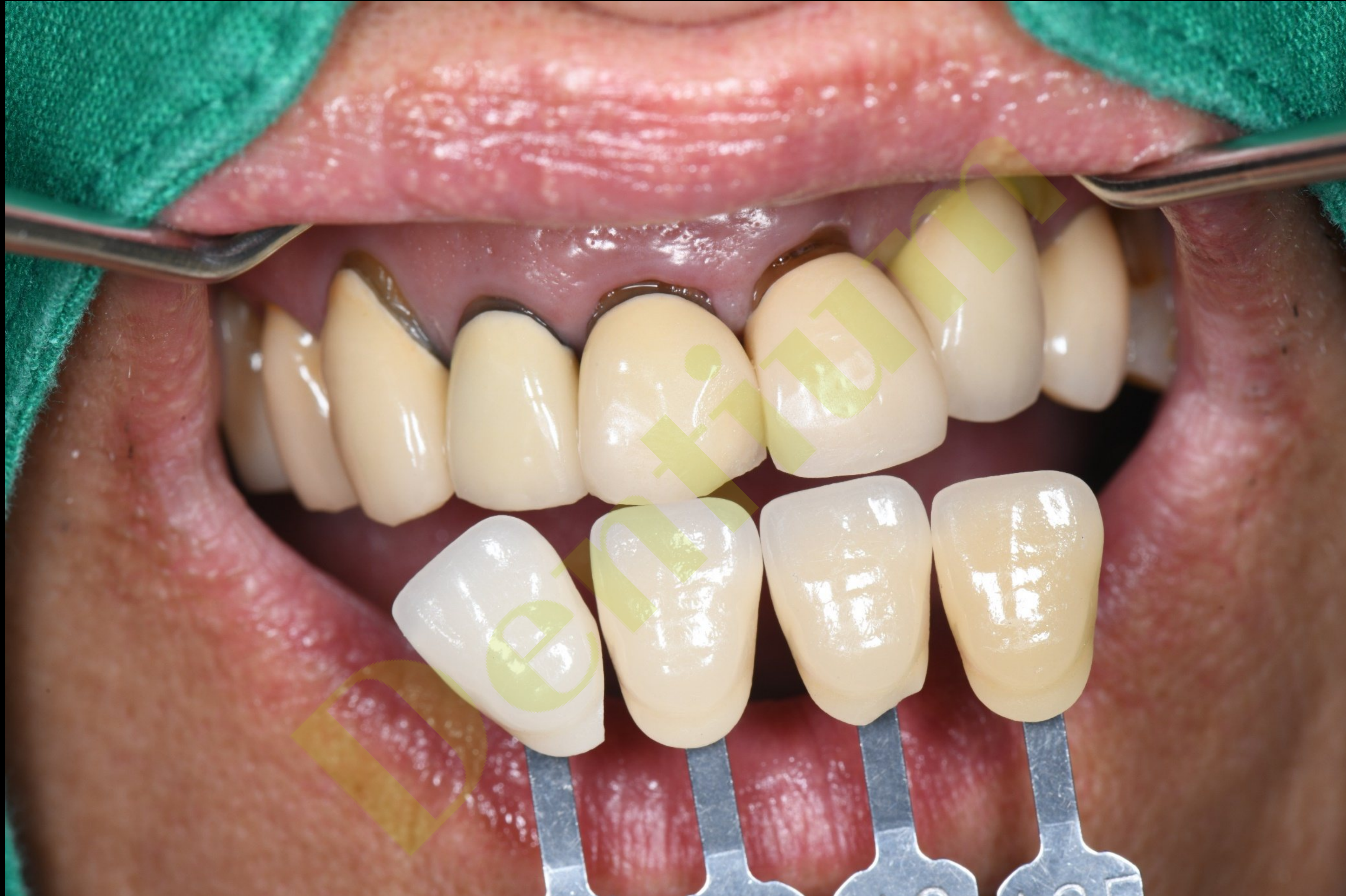우측방 한계



Prosthesis design

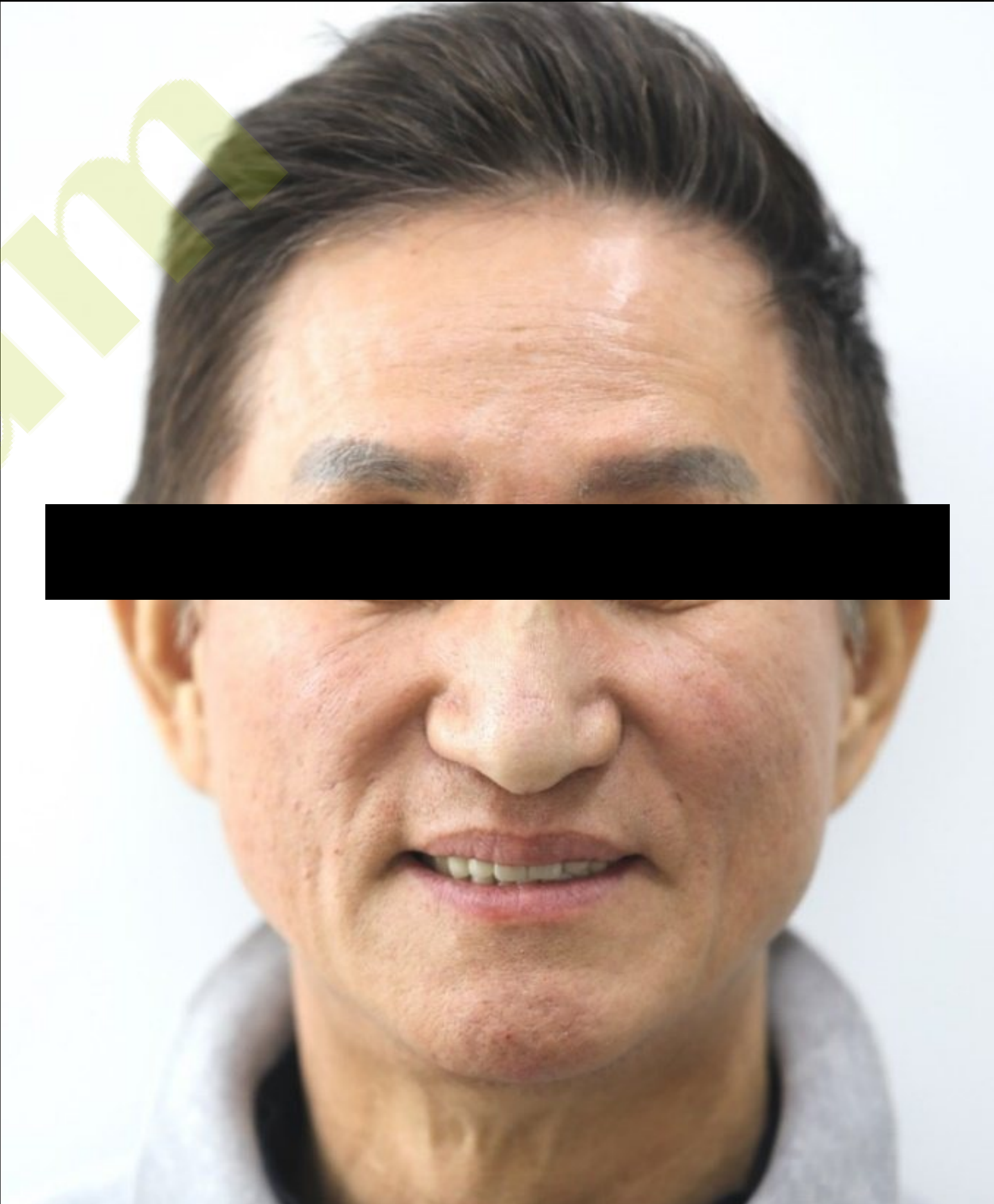
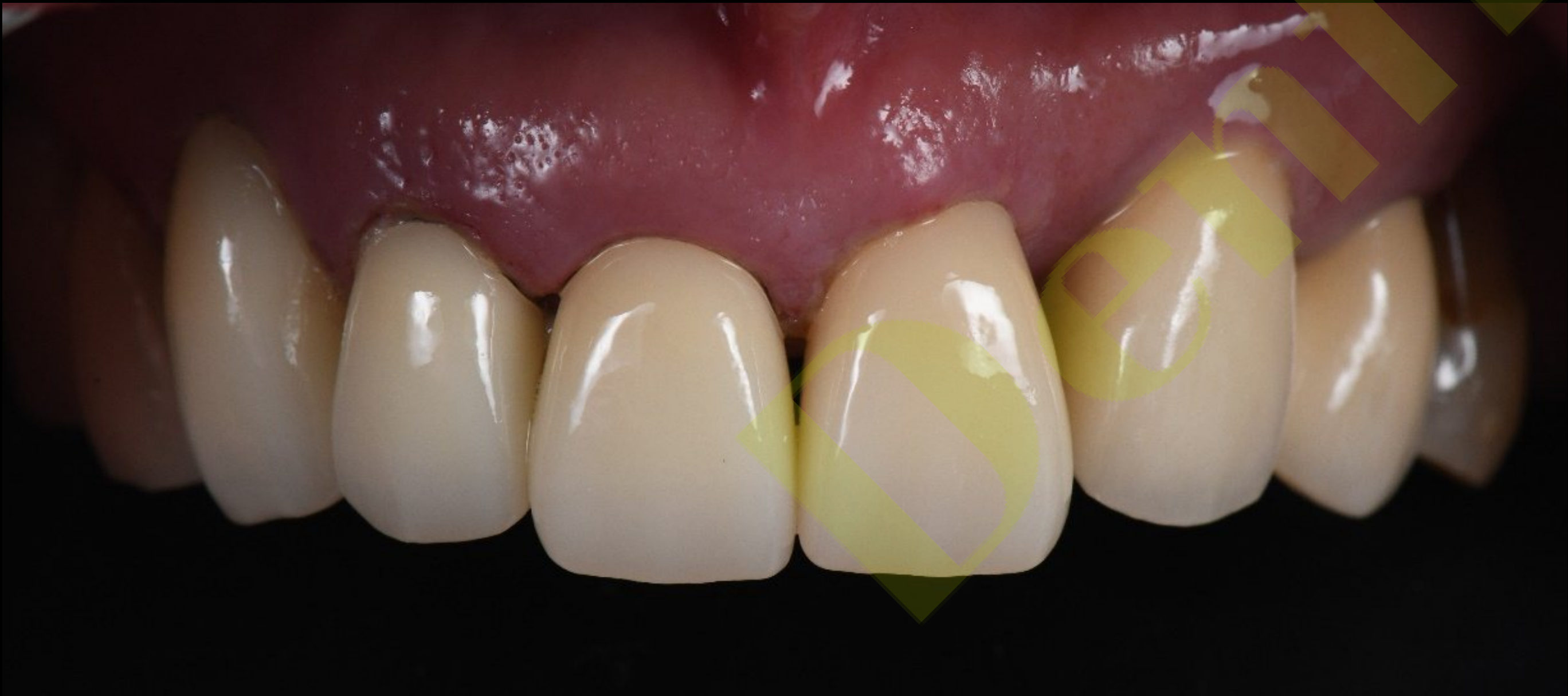
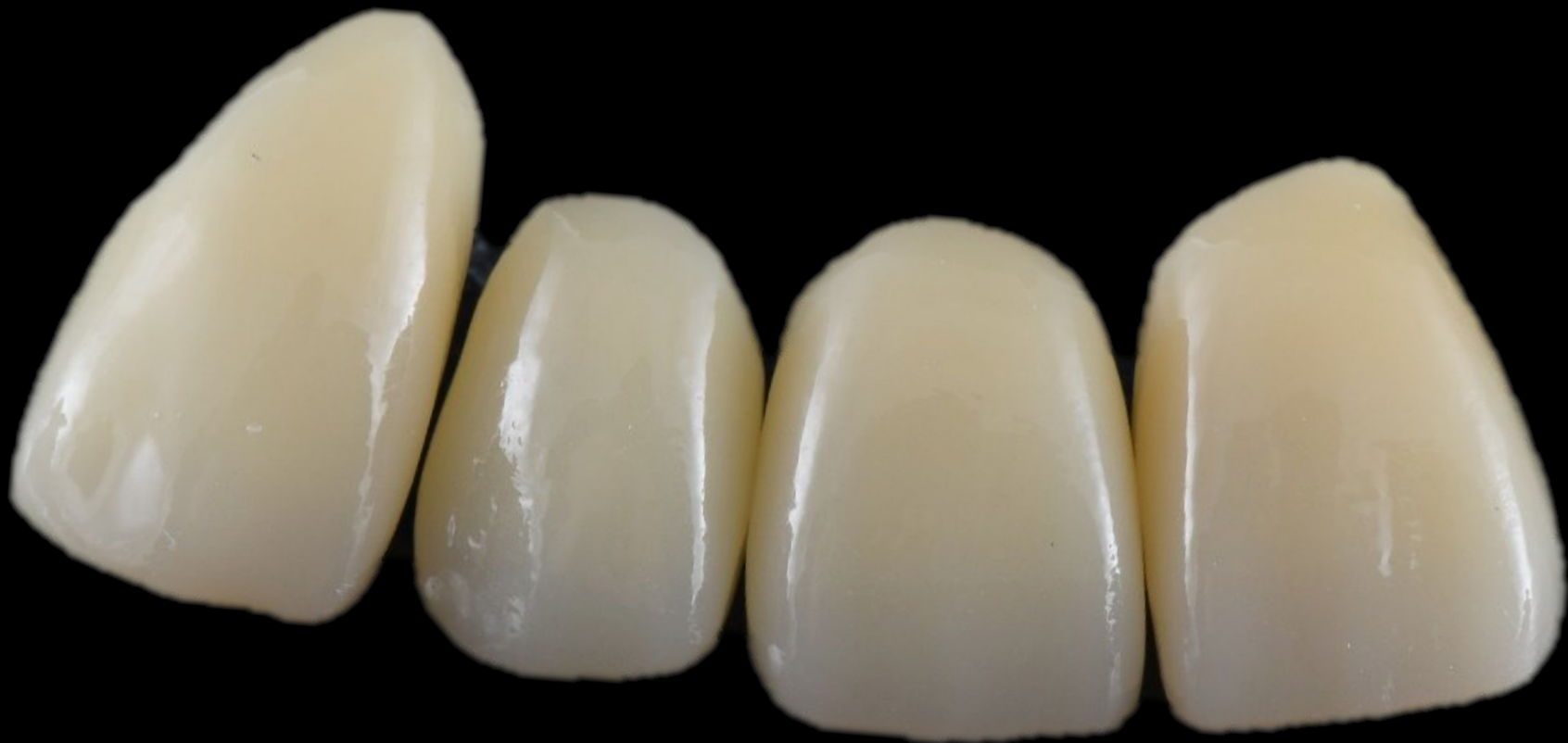Shade taking (A3)

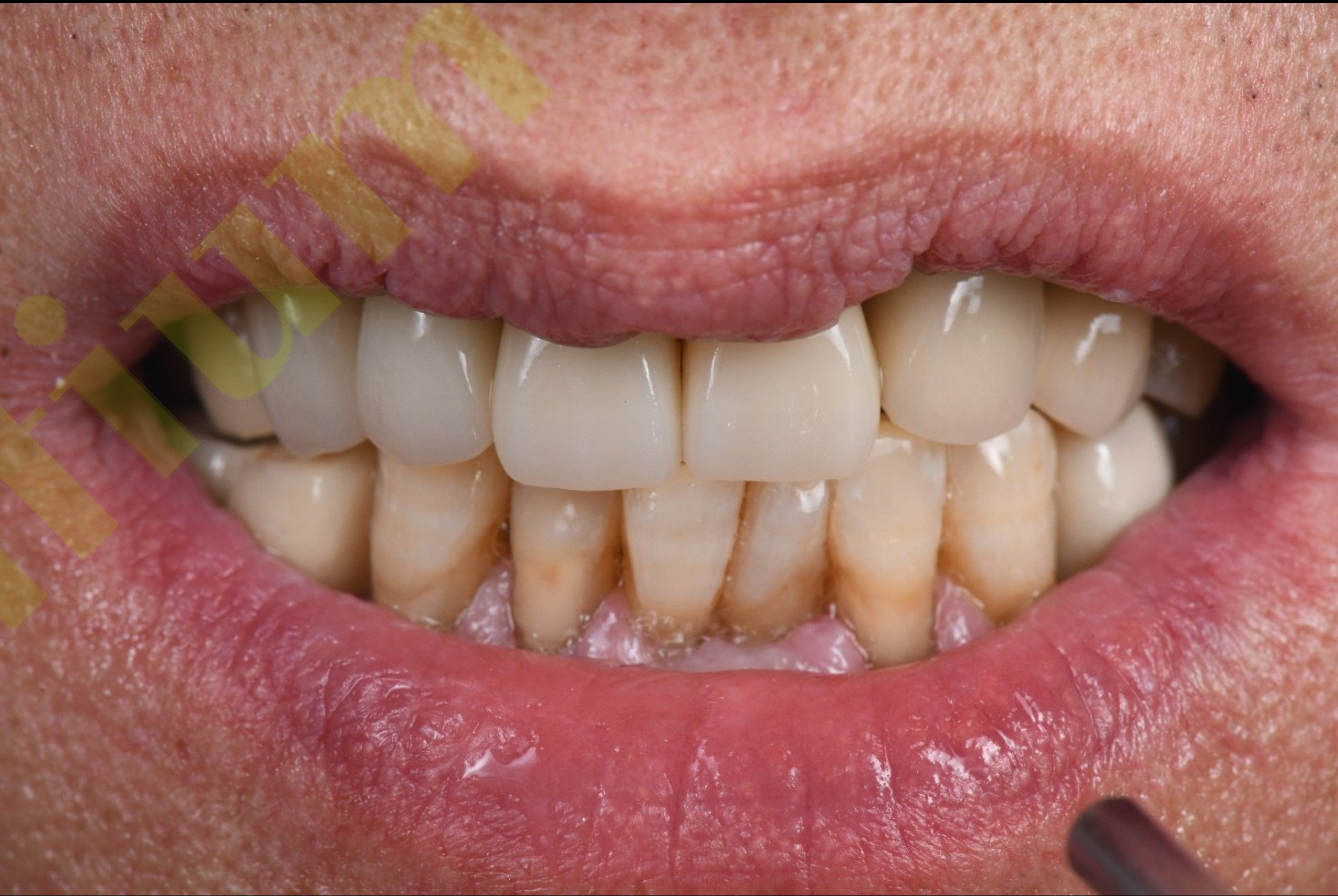
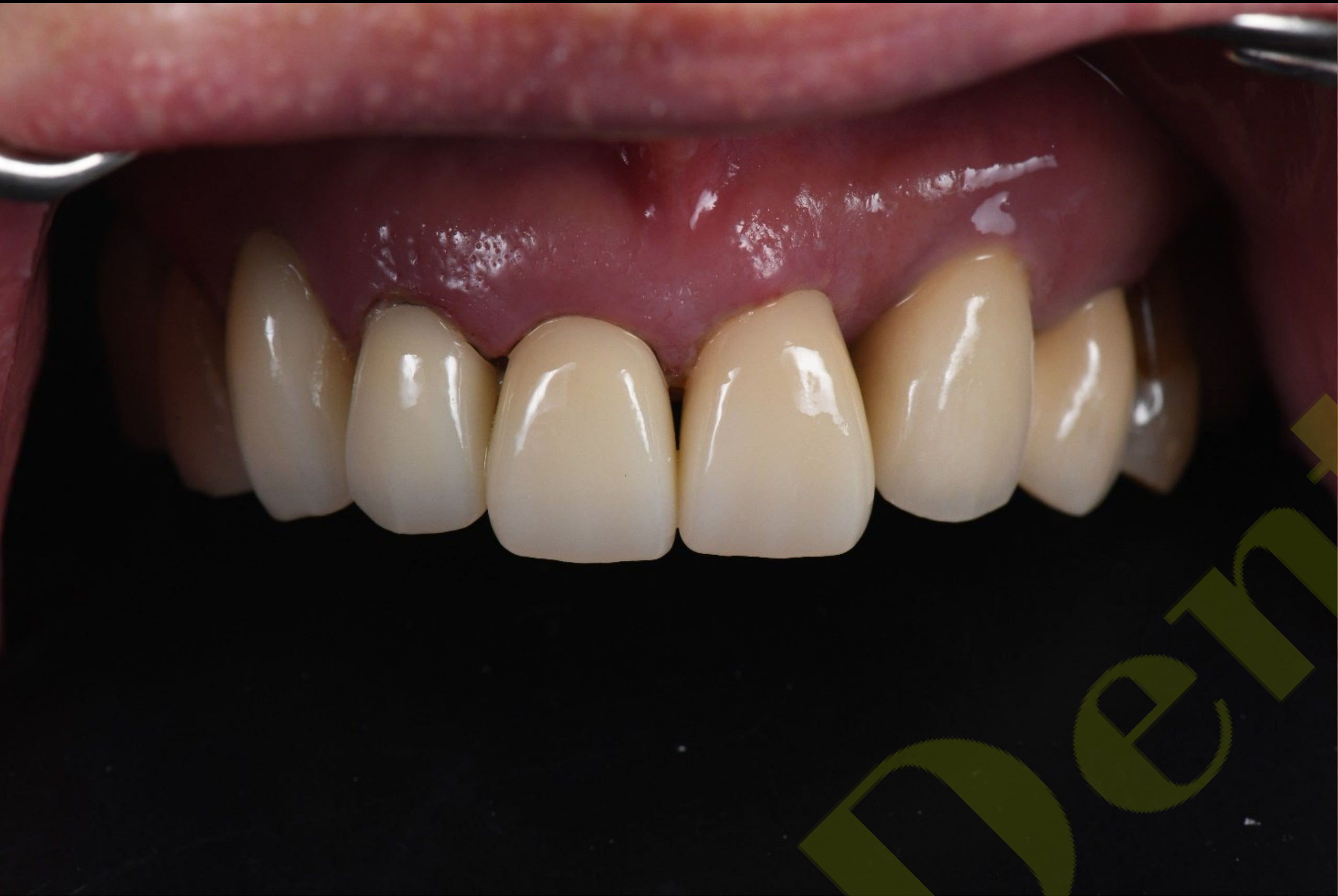
Dentium

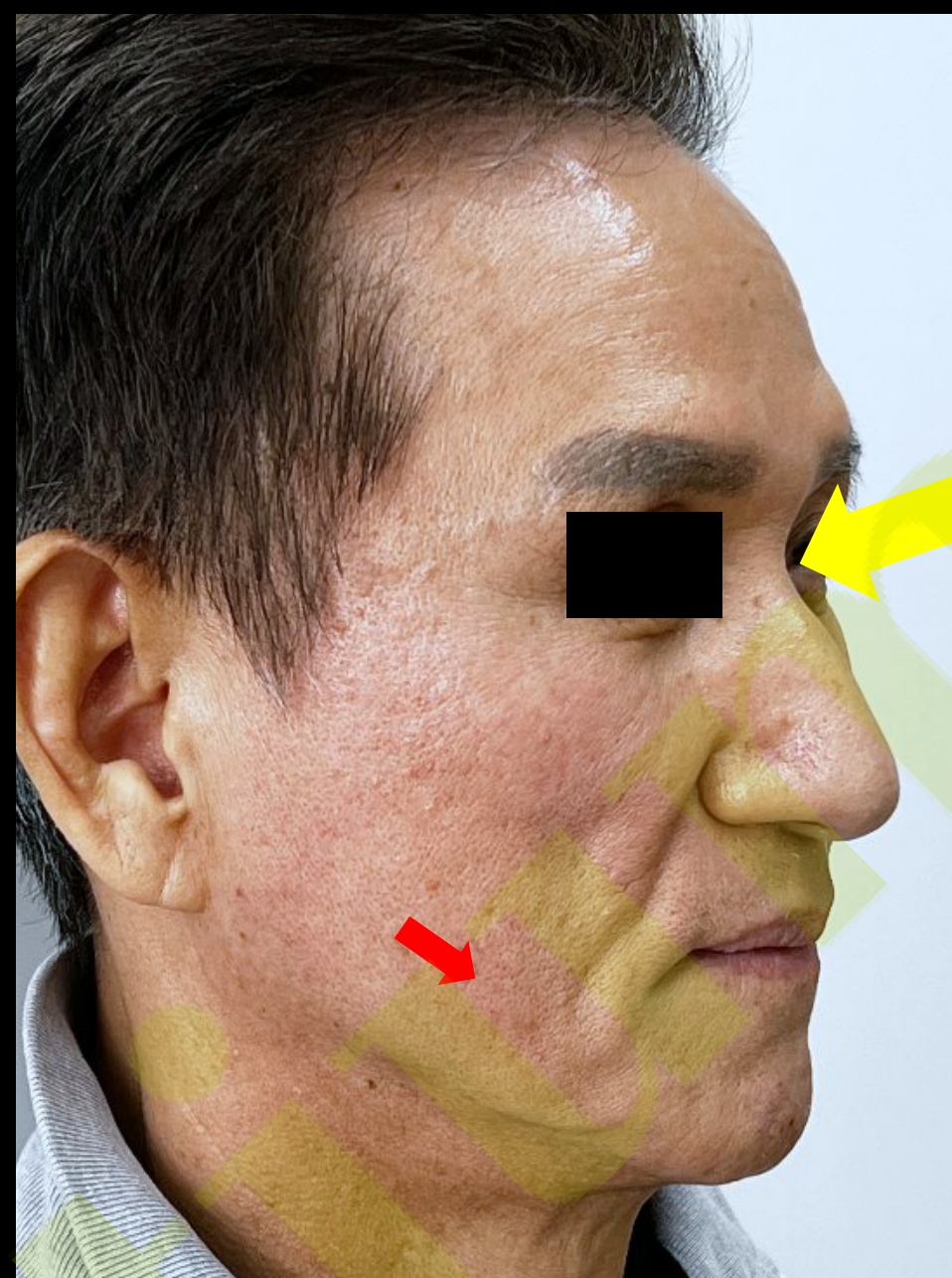
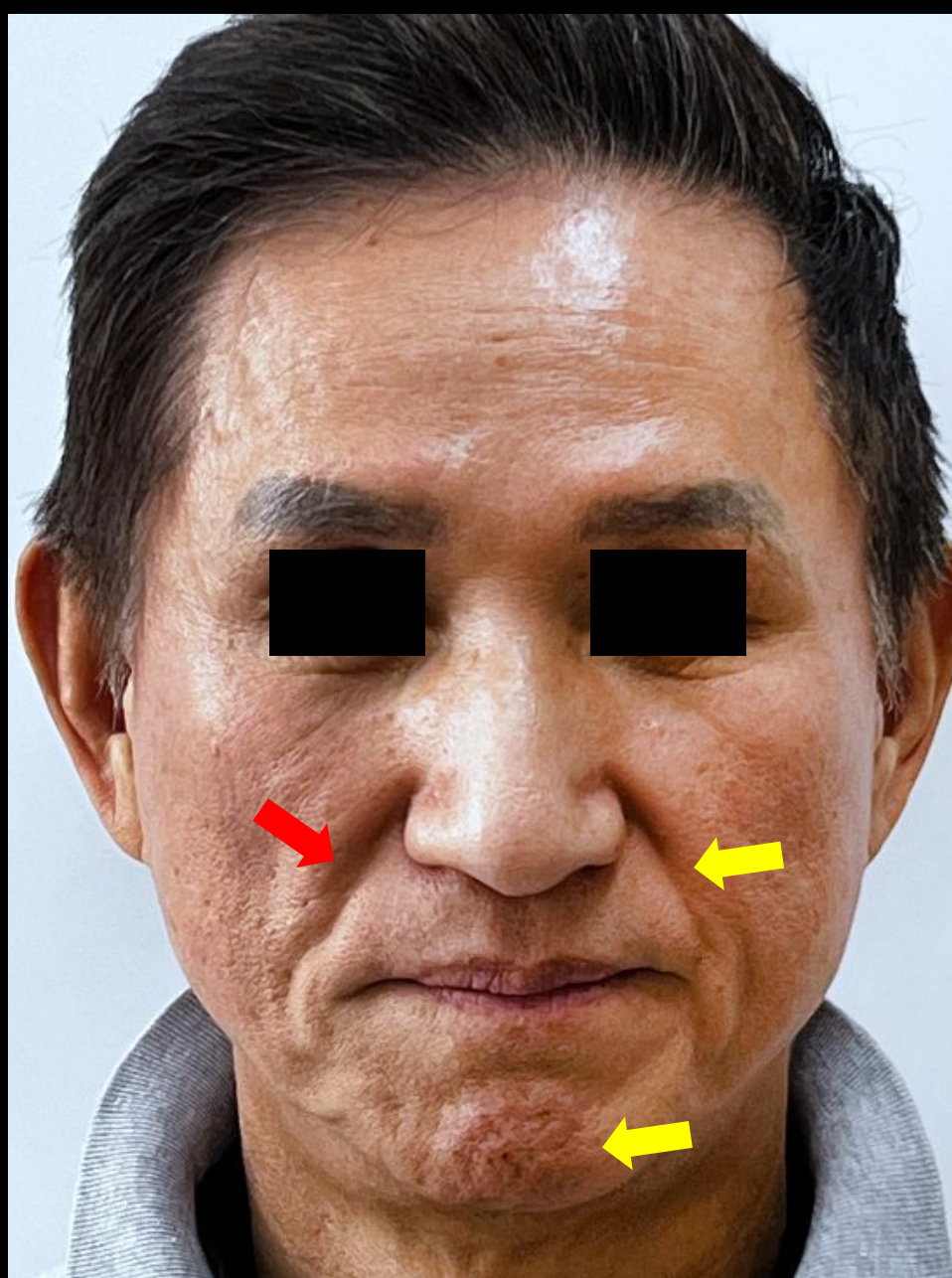
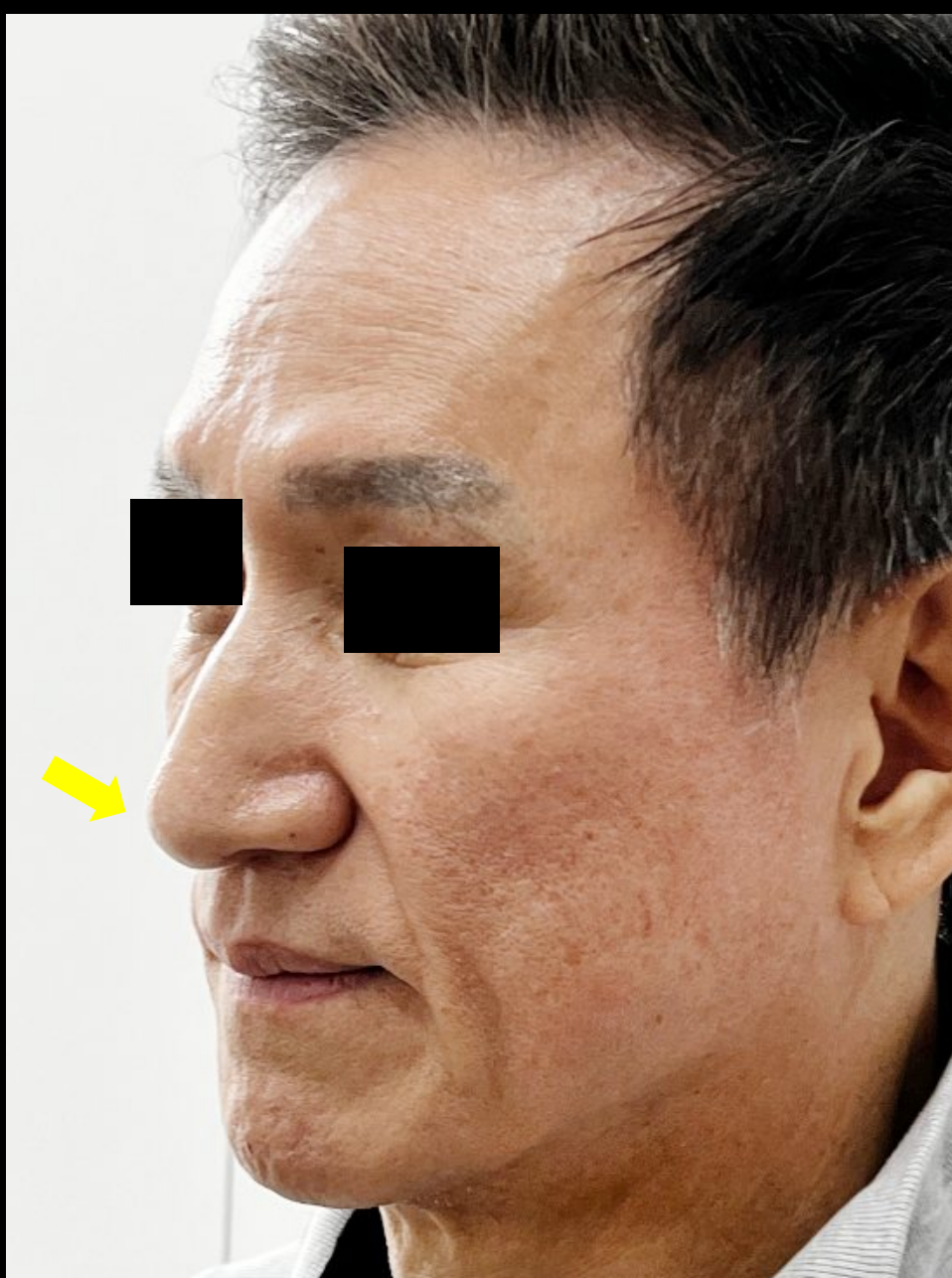
Final prosthesis (2024-02-24)



Final prosthesis (2024-02-24)



before

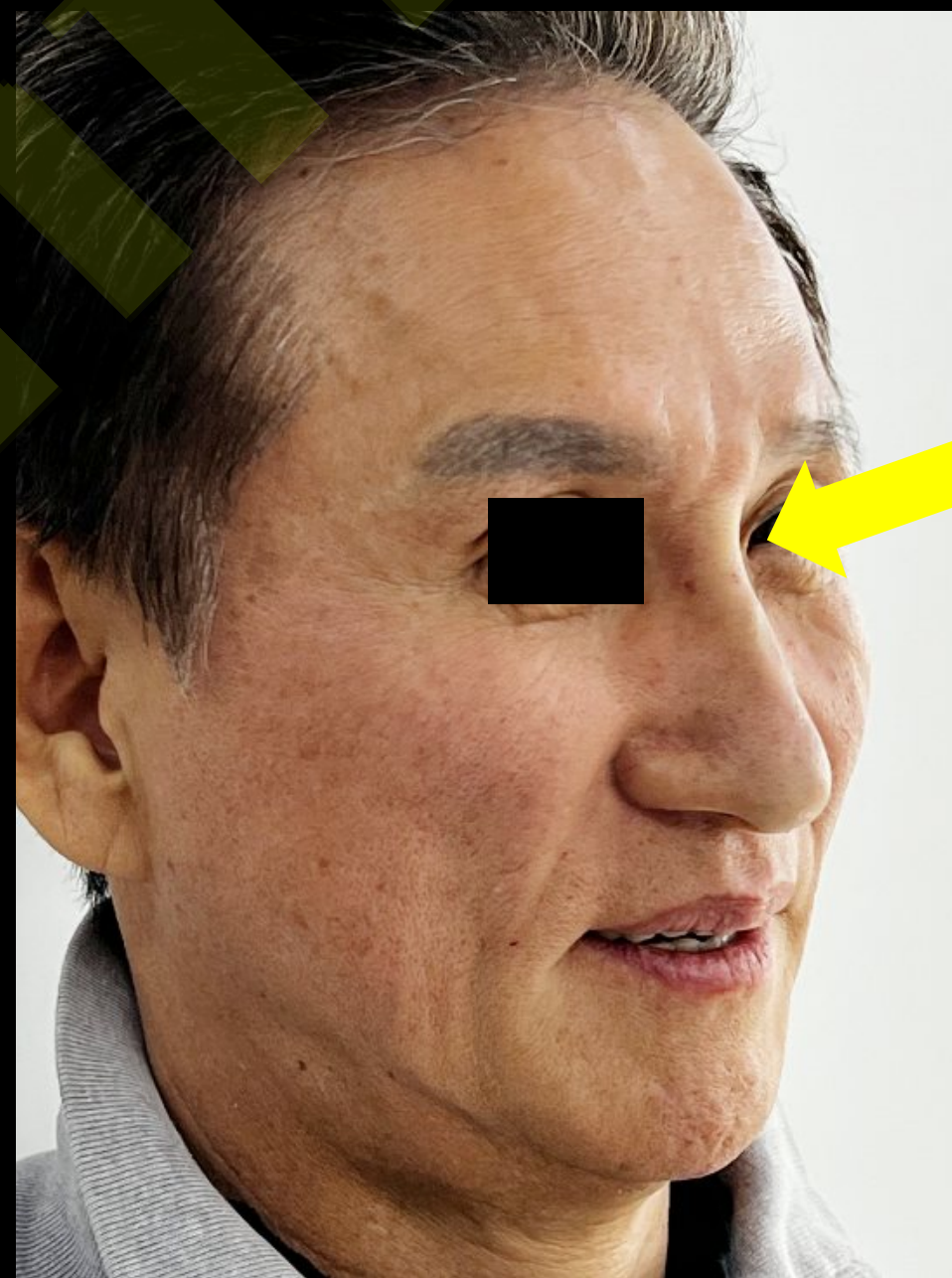
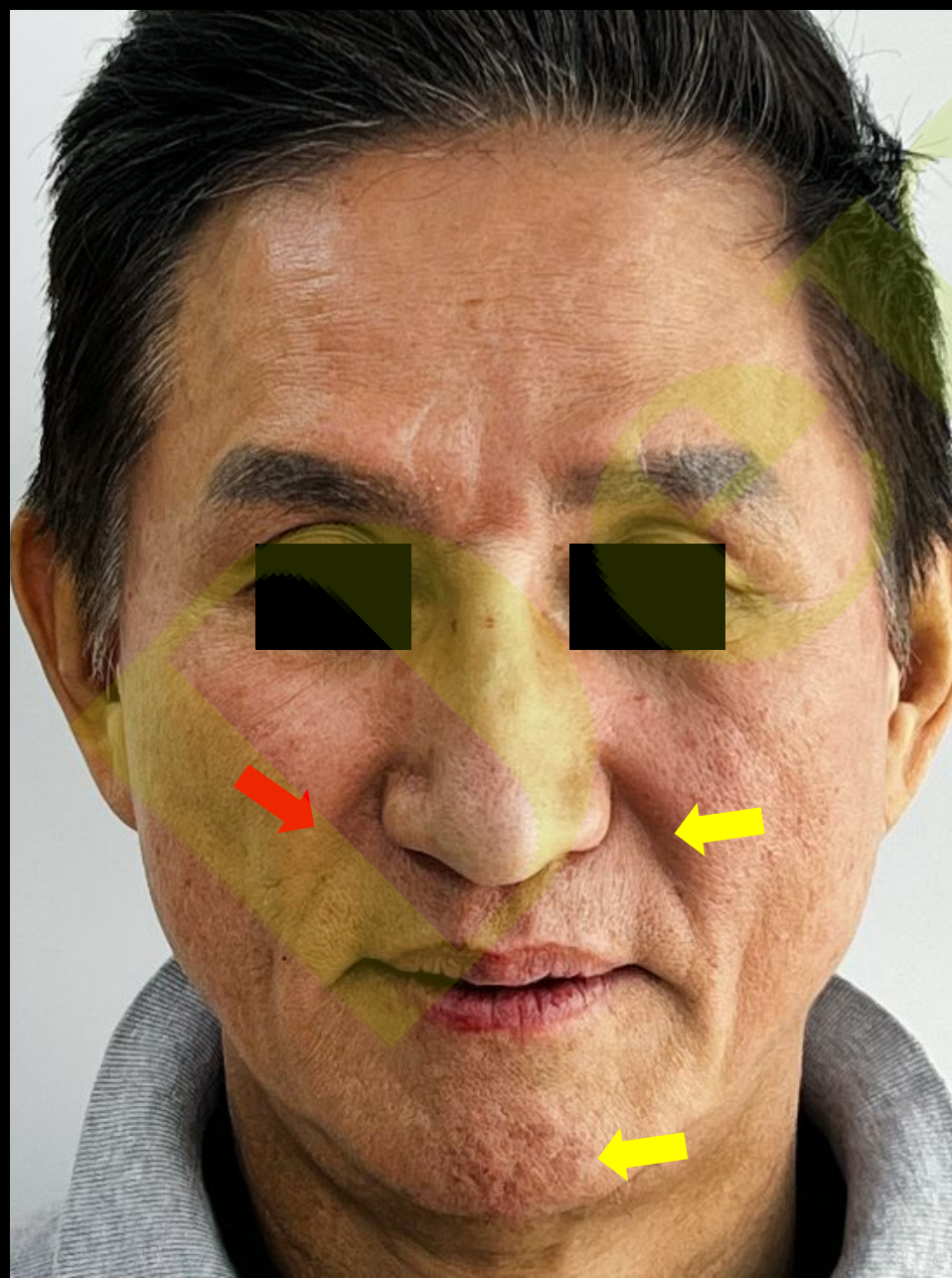
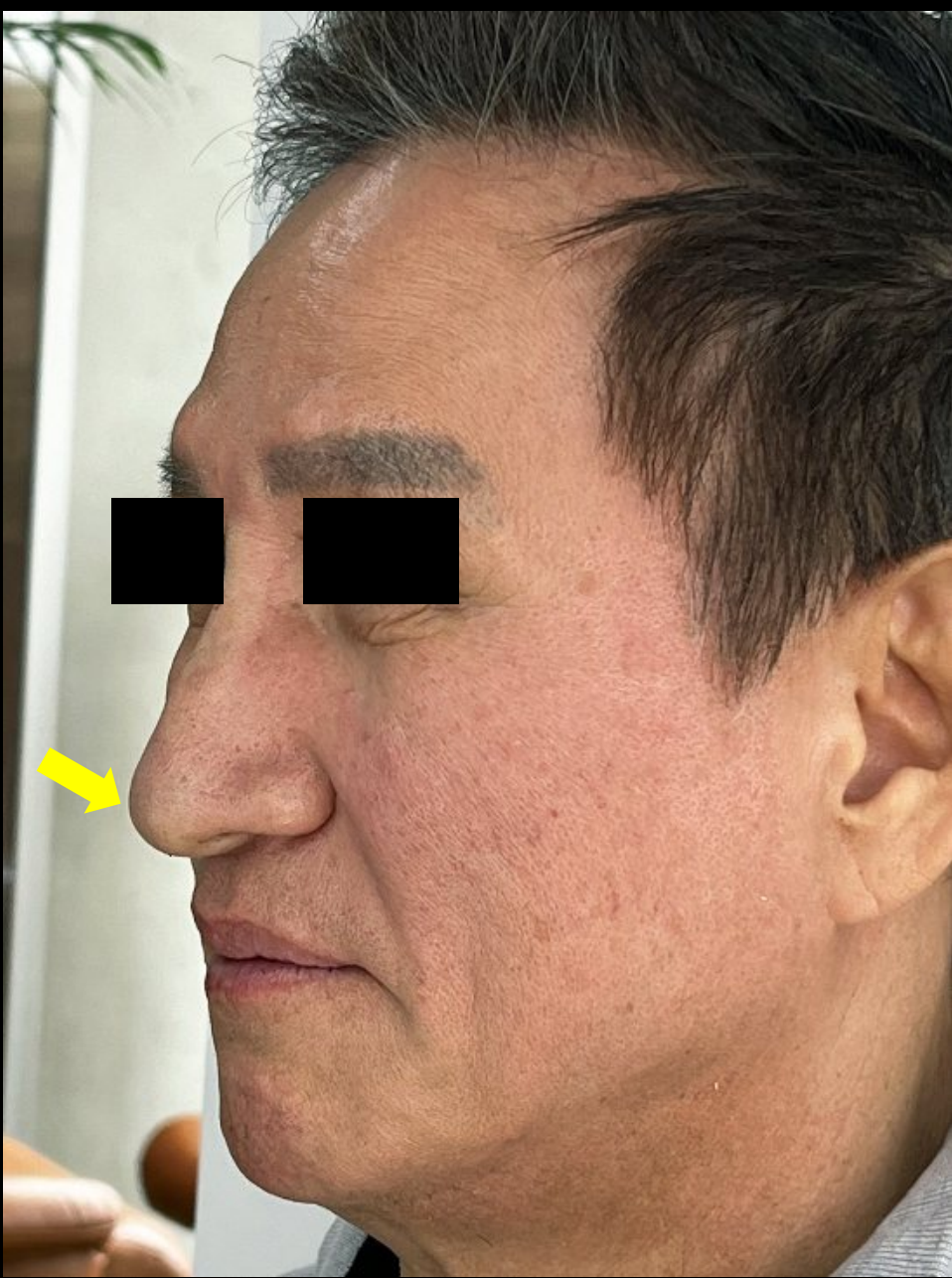
application site

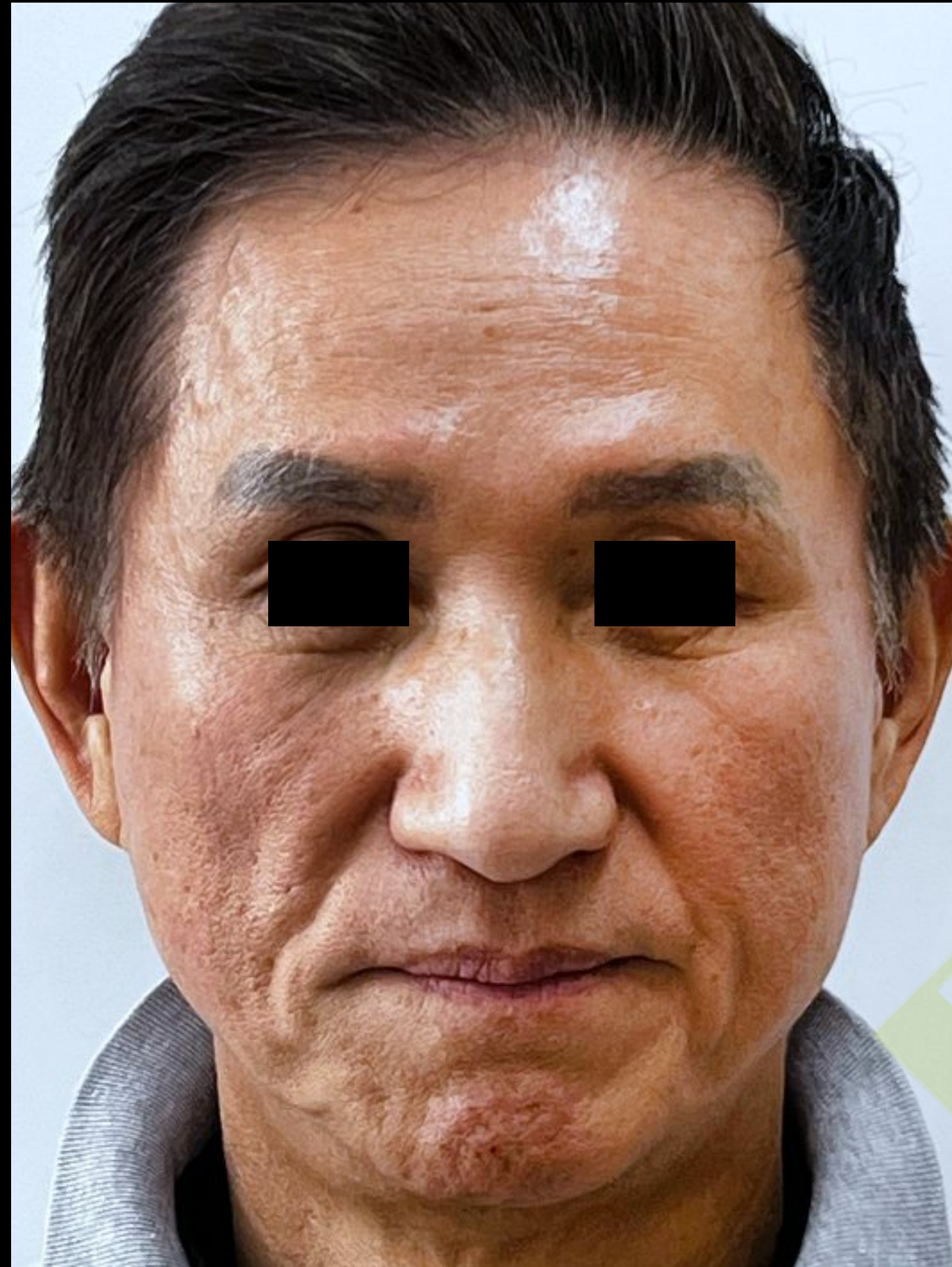High ✓
- Nose
- Nasolabial folds
- Chin

Smile ✓
- Nasolabial folds

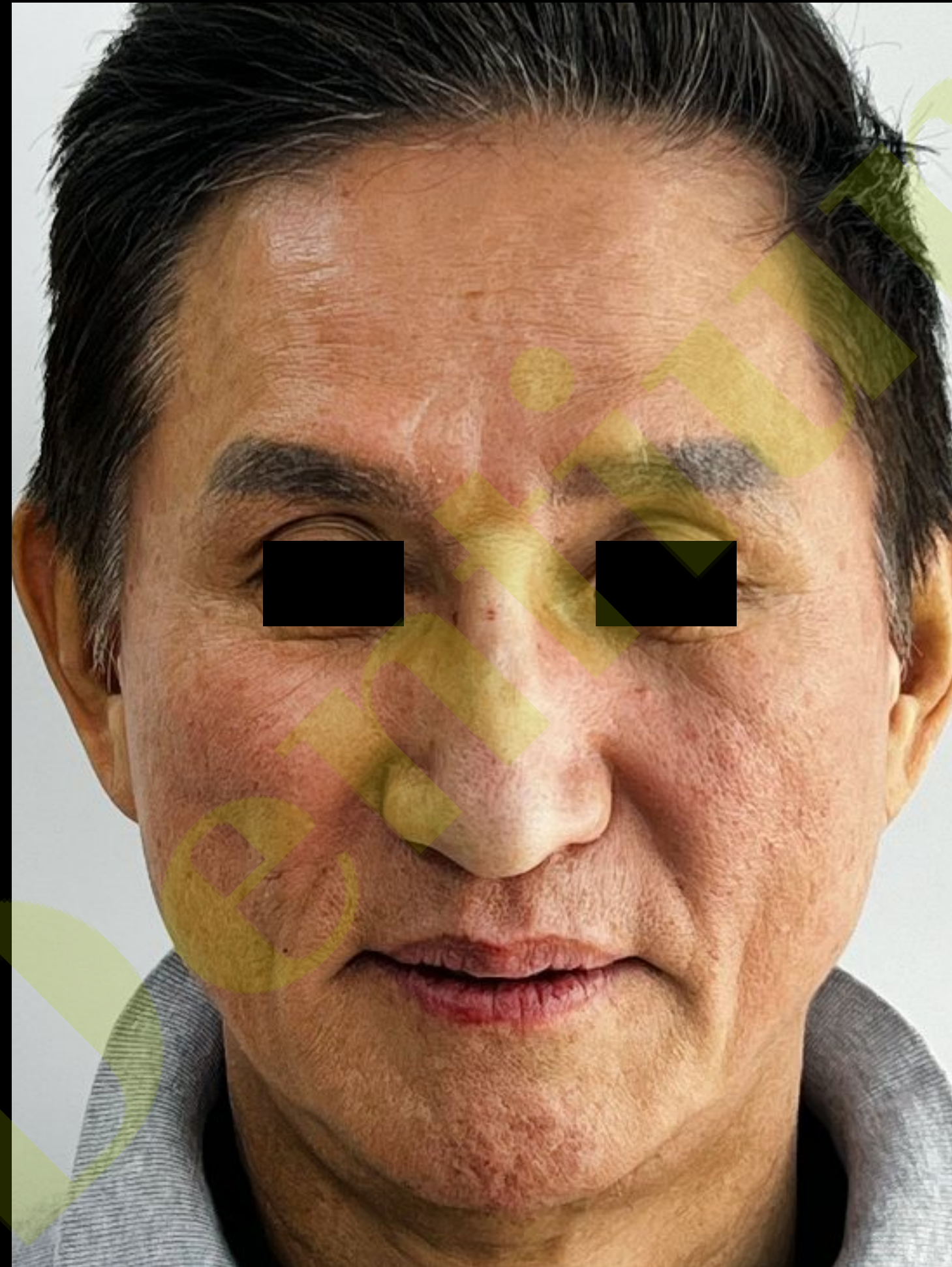after



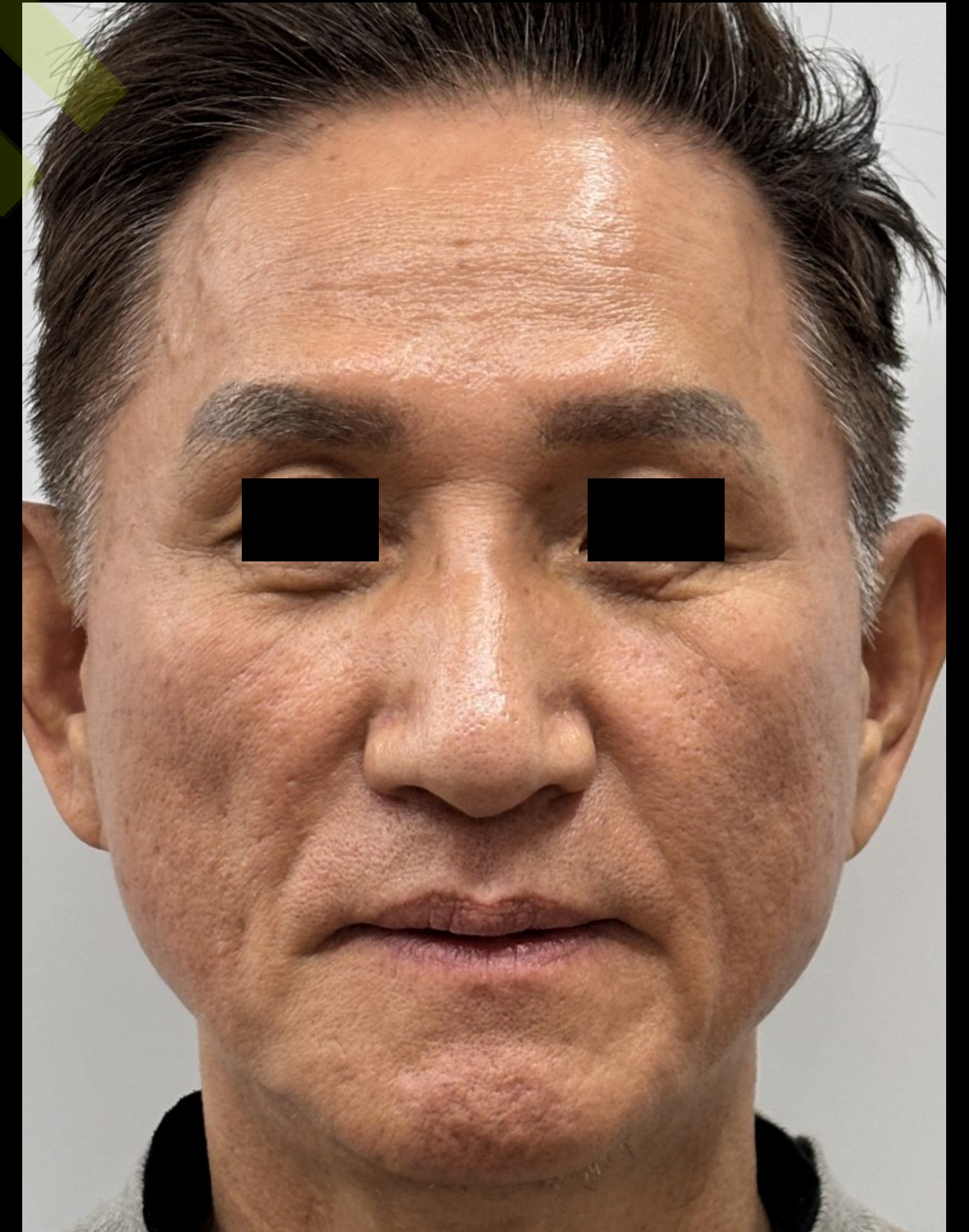
Before



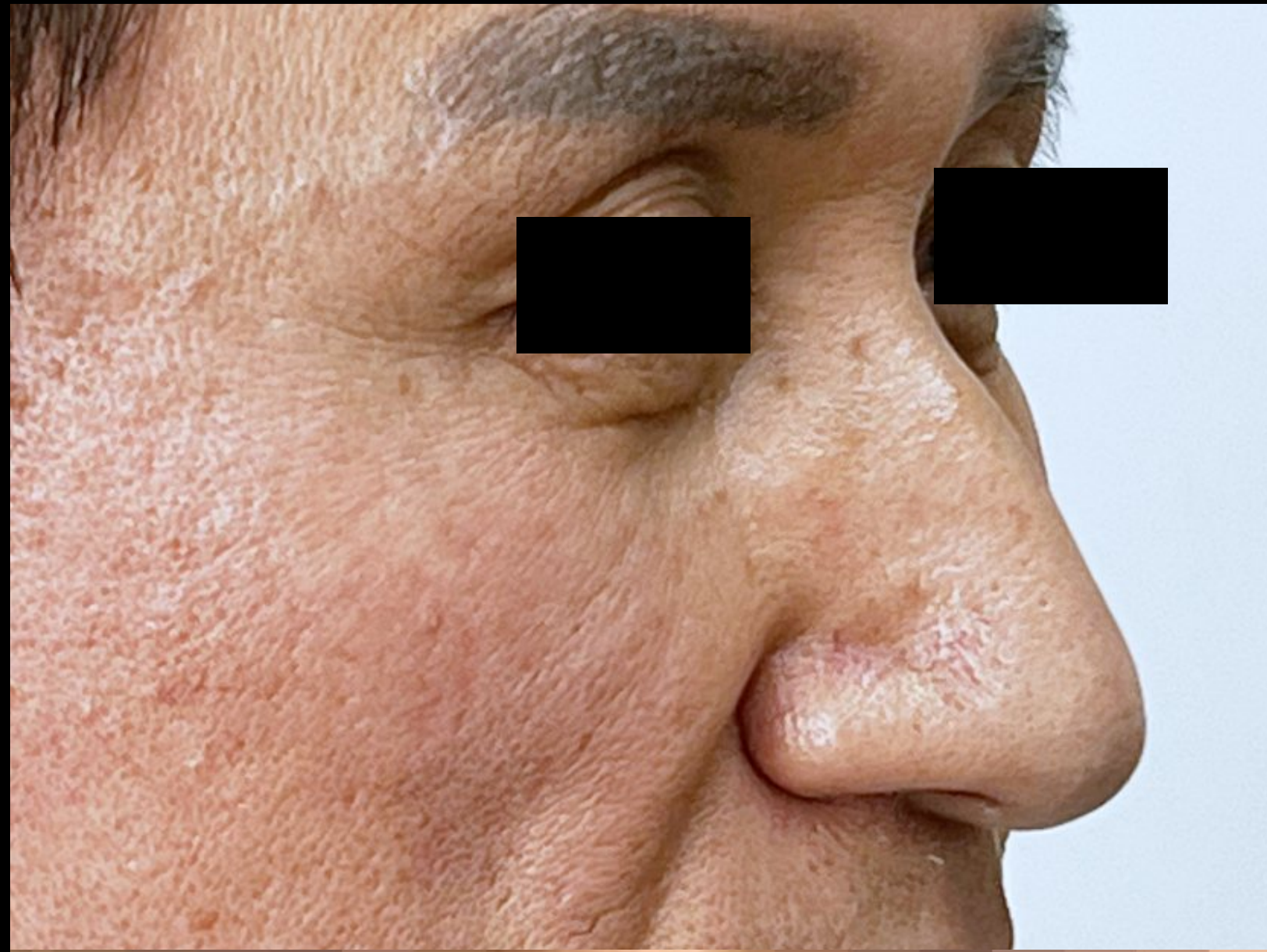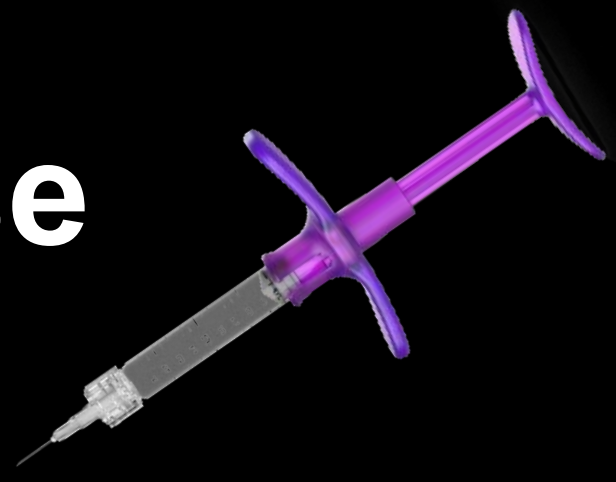After



1 Month Later



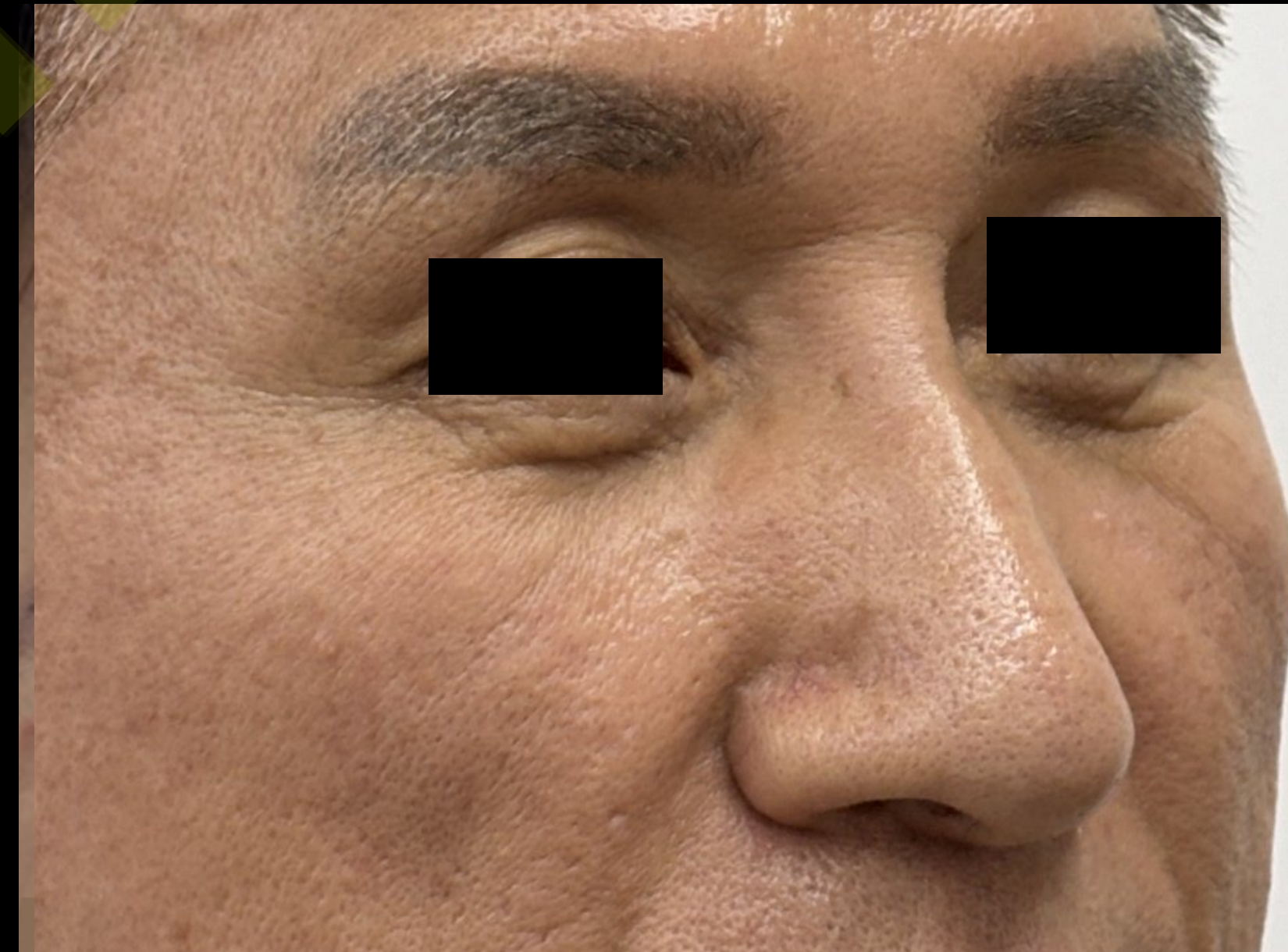
Nose



Before

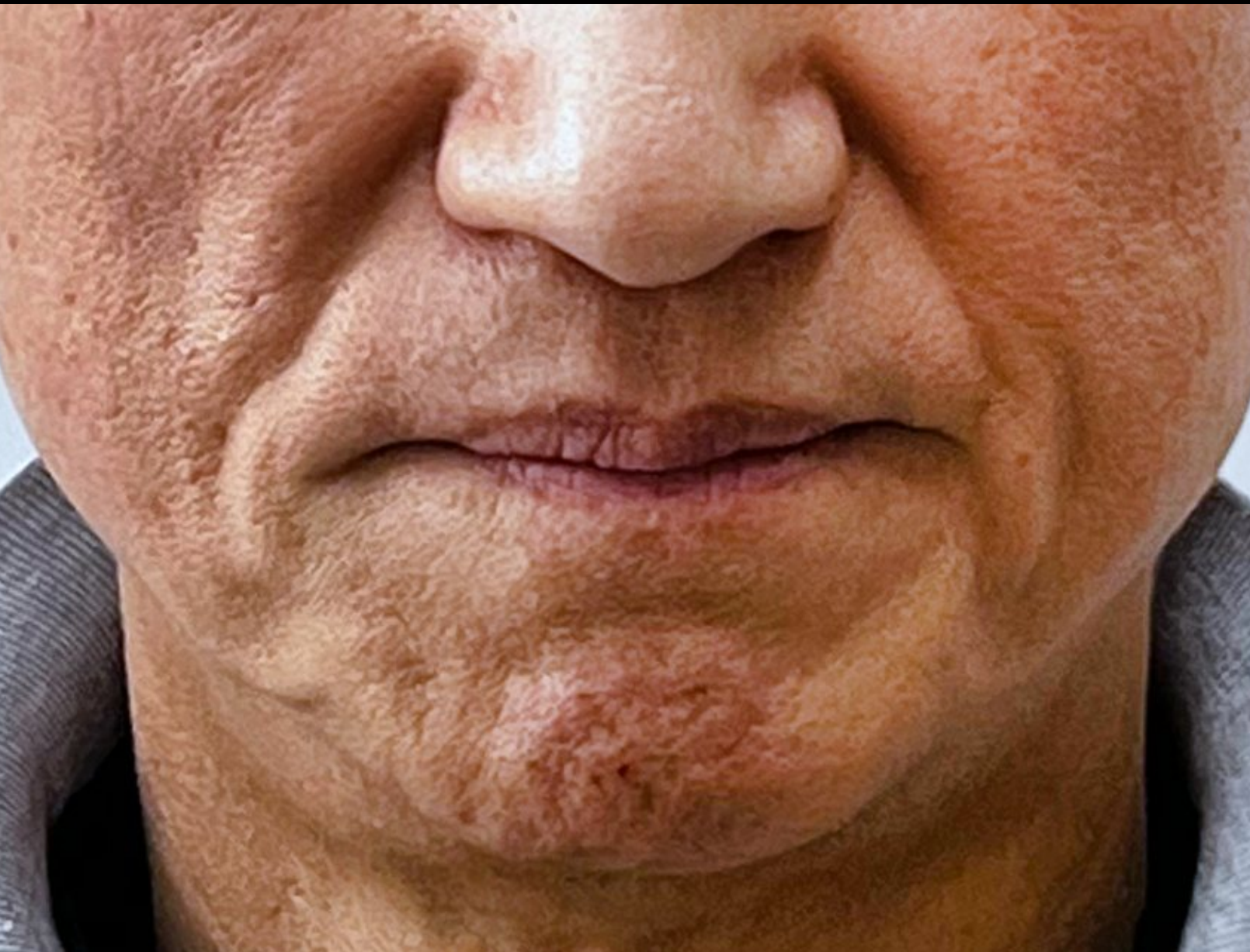
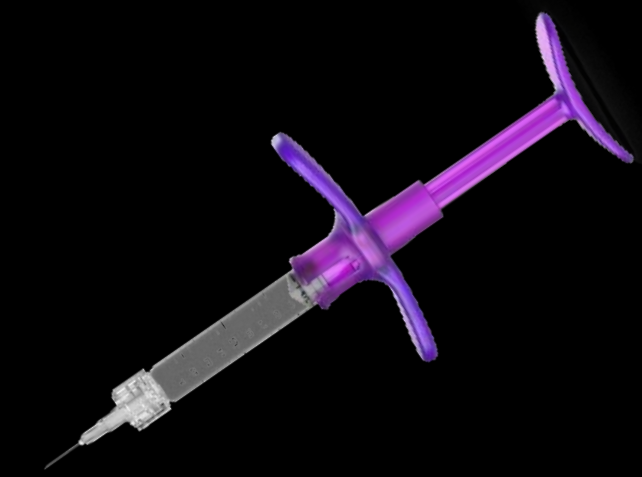
After

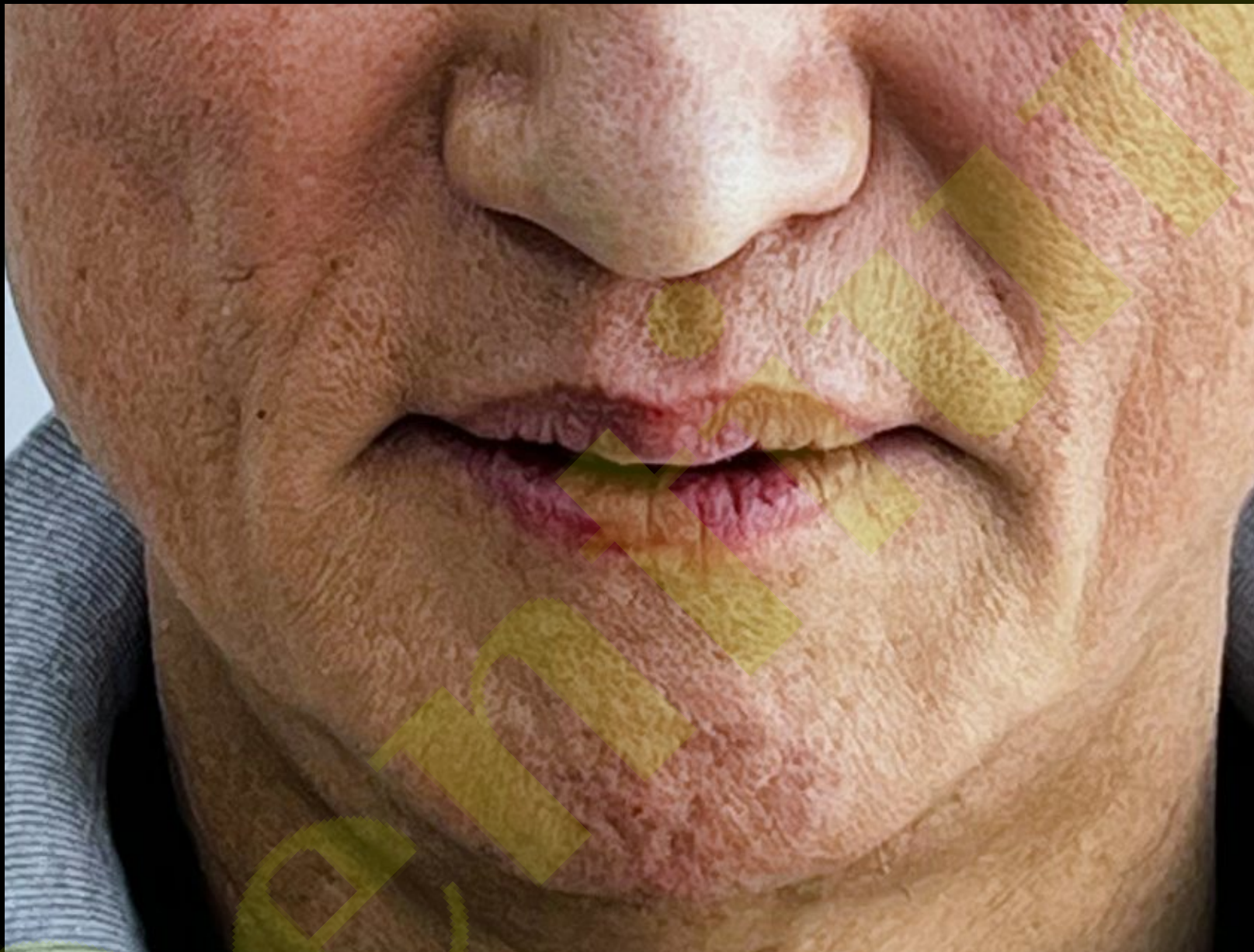

1 Month Later

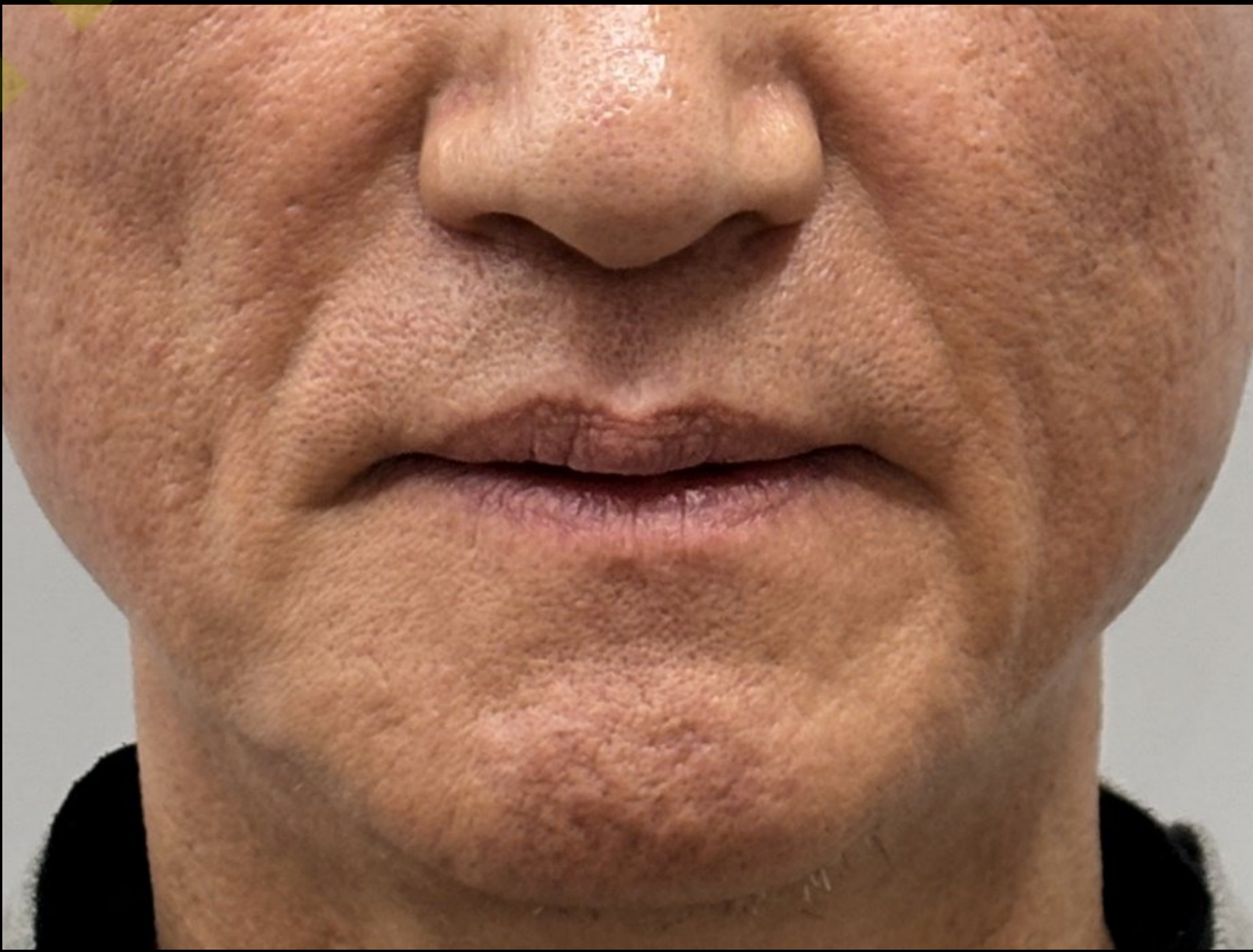
Nasolabial folds, Chin



Before



After



1 Month Later