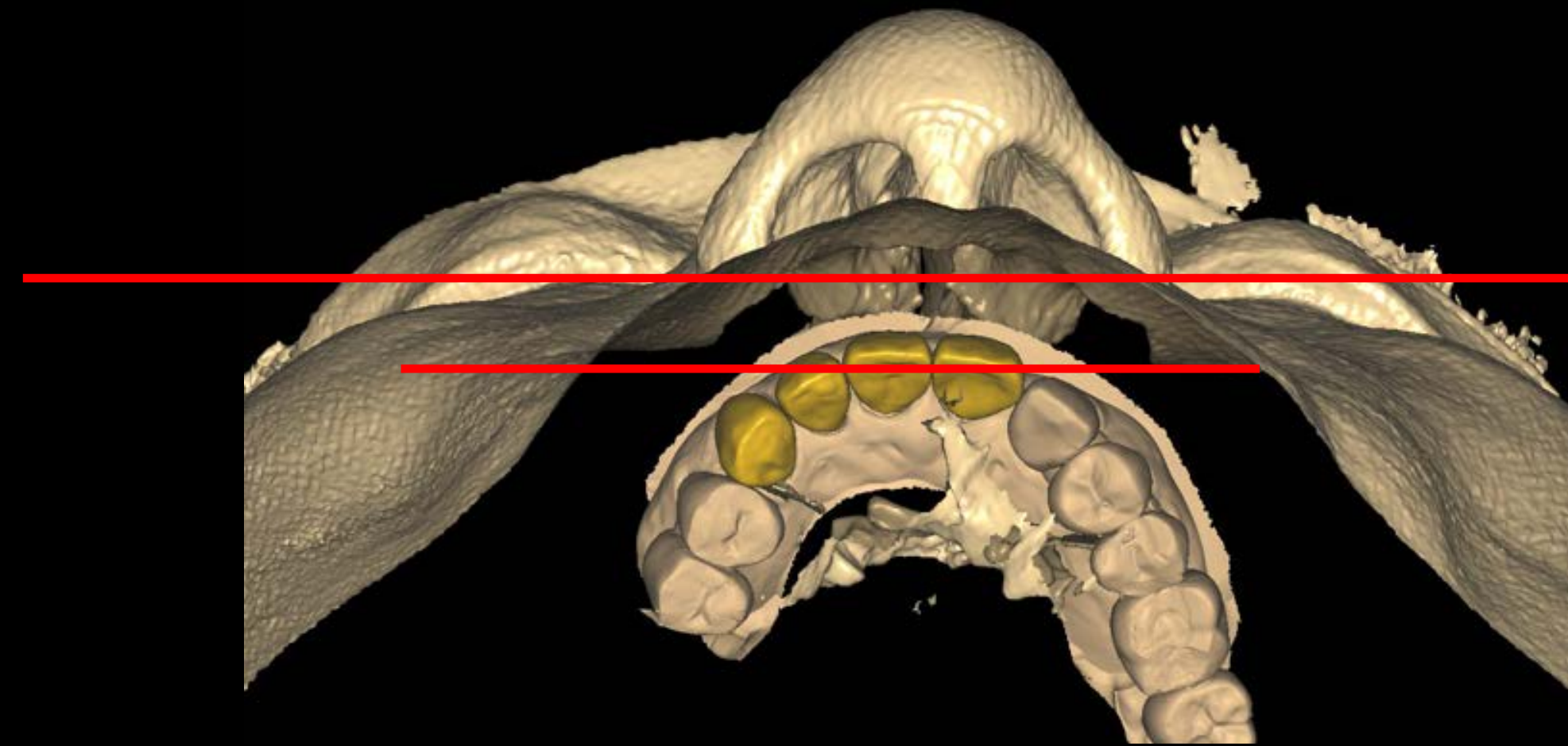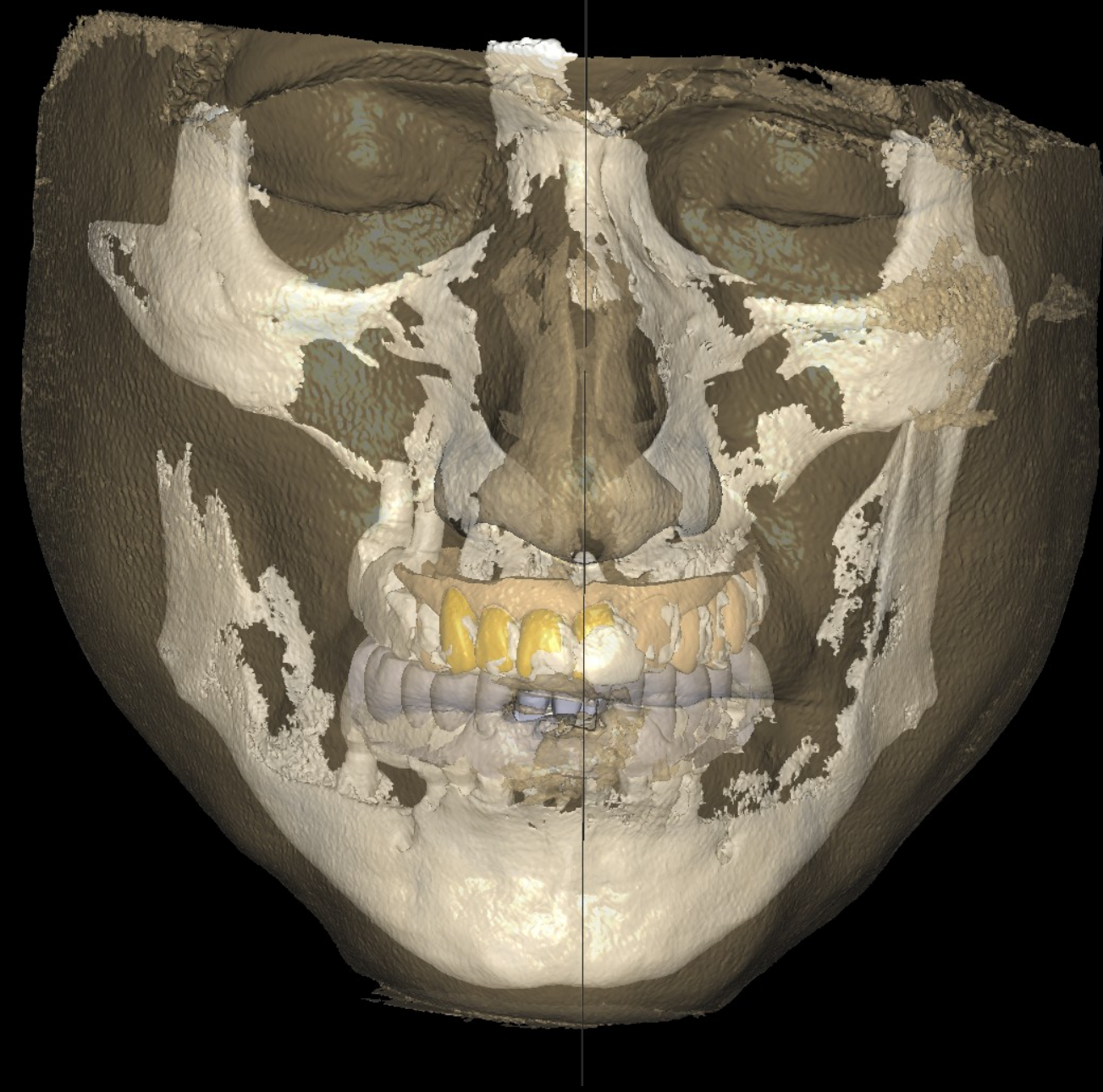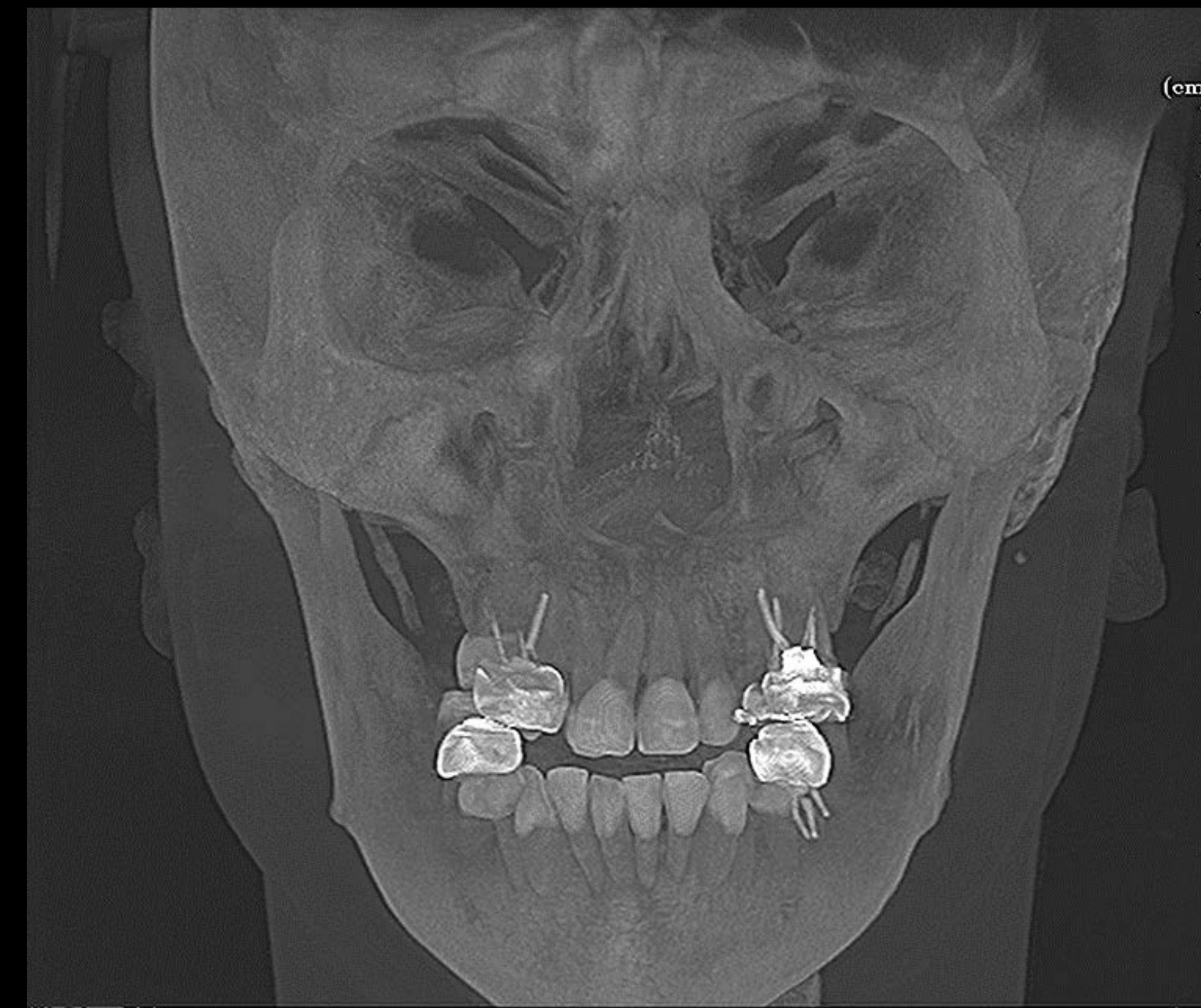
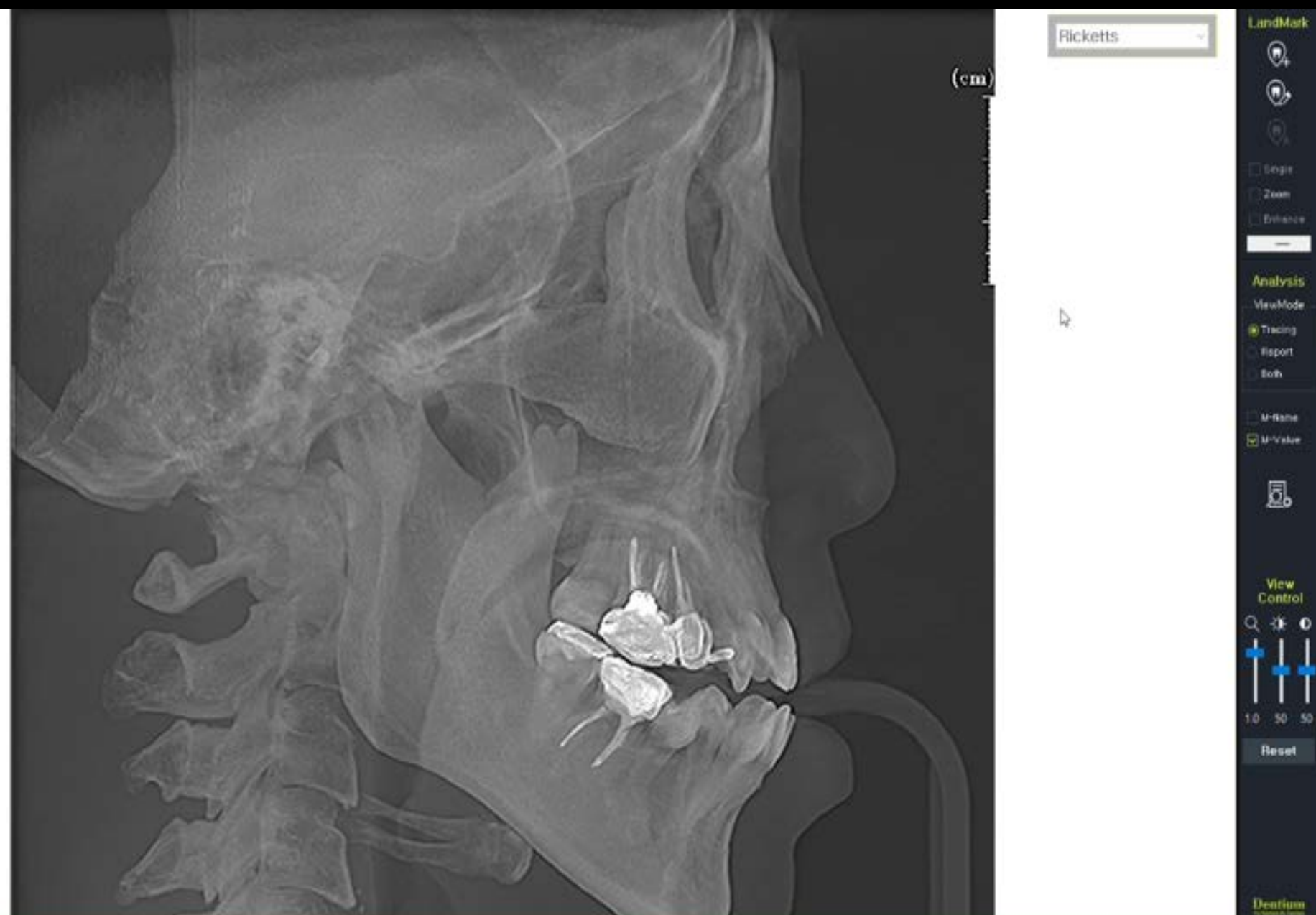


Digital Minimalism

Dr SM Chung

Dentium and Genoss



Digital minimalism

Practical- easy and simple

Daily routine approach with accuracy

Minimal investment of minimal equipment

Good cooperation with dental lab

Why digital in somatology?

Accurate

Convenient

How to apply digital concepts?

BTS (bite tray impression scanning)

CT based occlusal plane

CT check bite

Zr and material development for digital

Contents

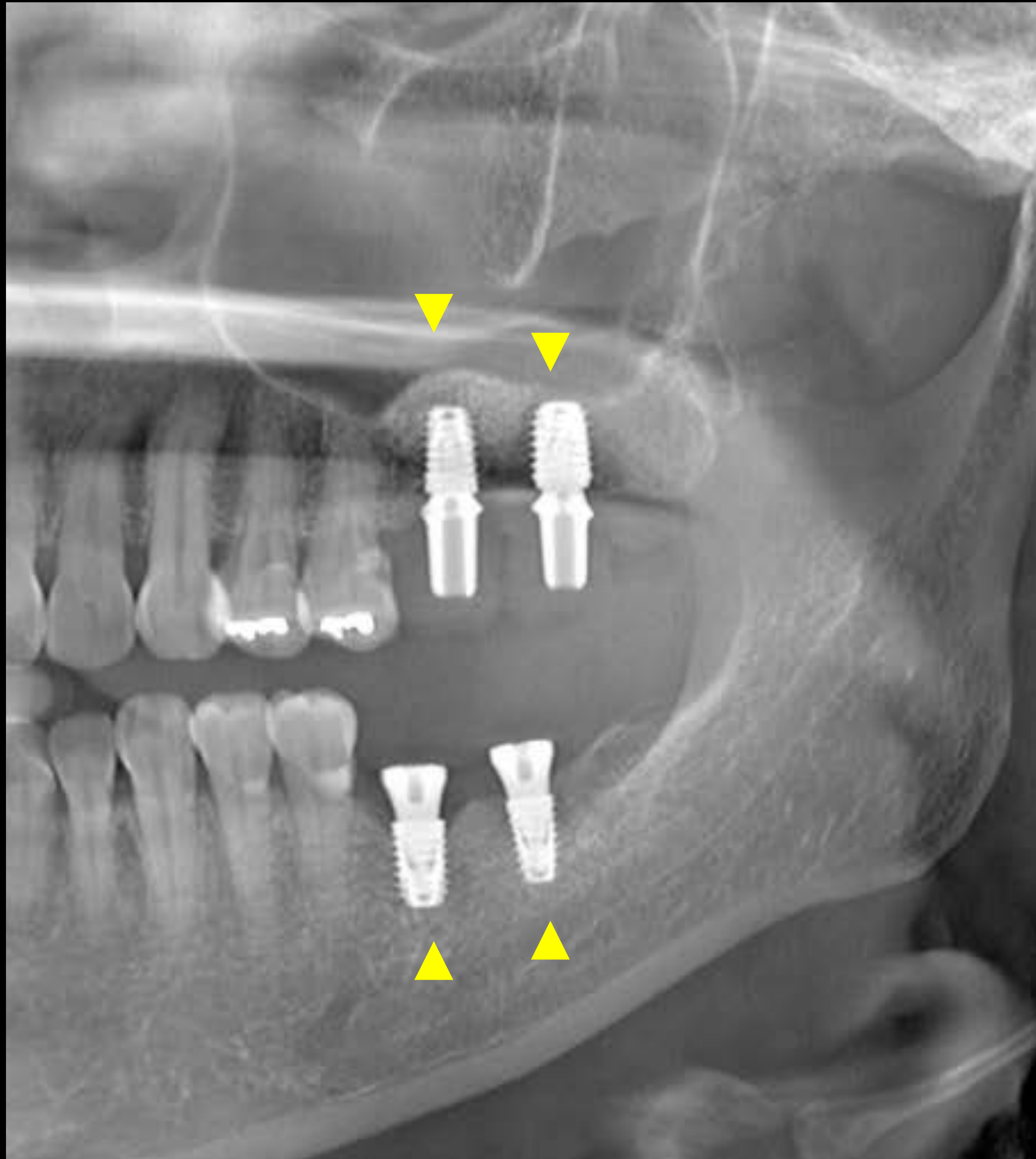
BTS

Diverse applications of CT viewers

Zirconia block

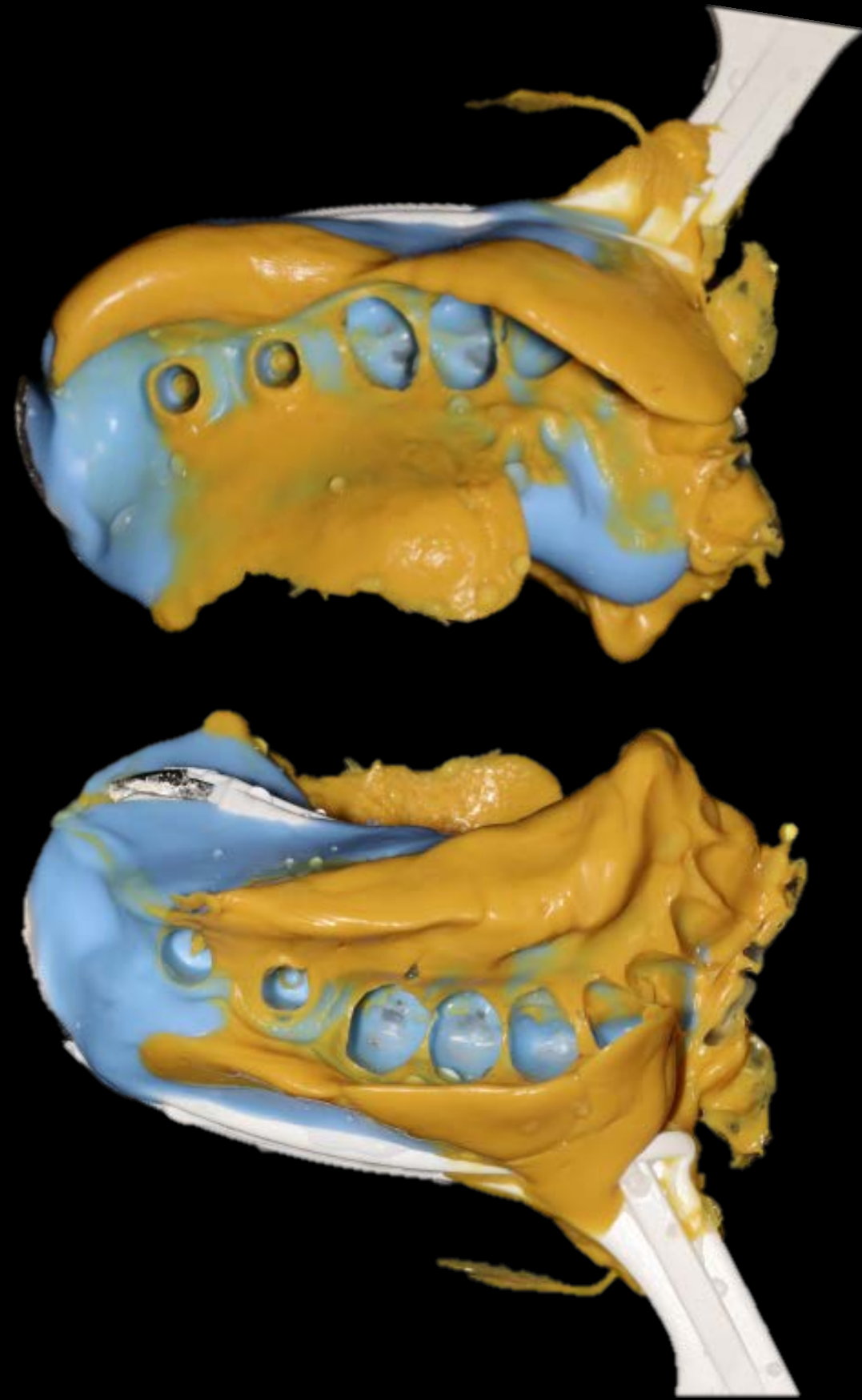
Auxiliary

Bite Tray impression Scan

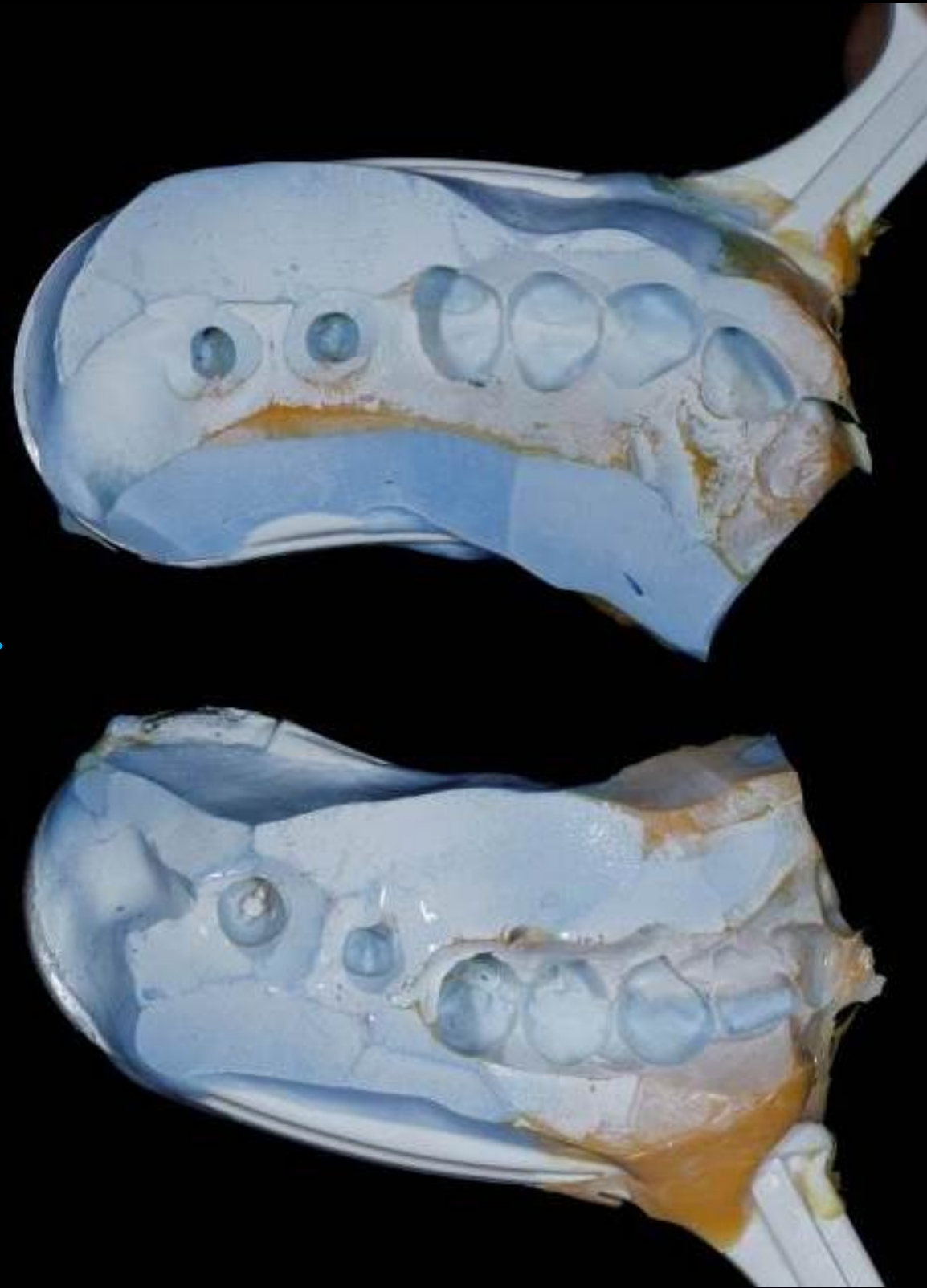


- # 26i, 27i, 36i, 37i
- bright Bone Level
- bright 3 layer A3.5
- Stain & Glazing

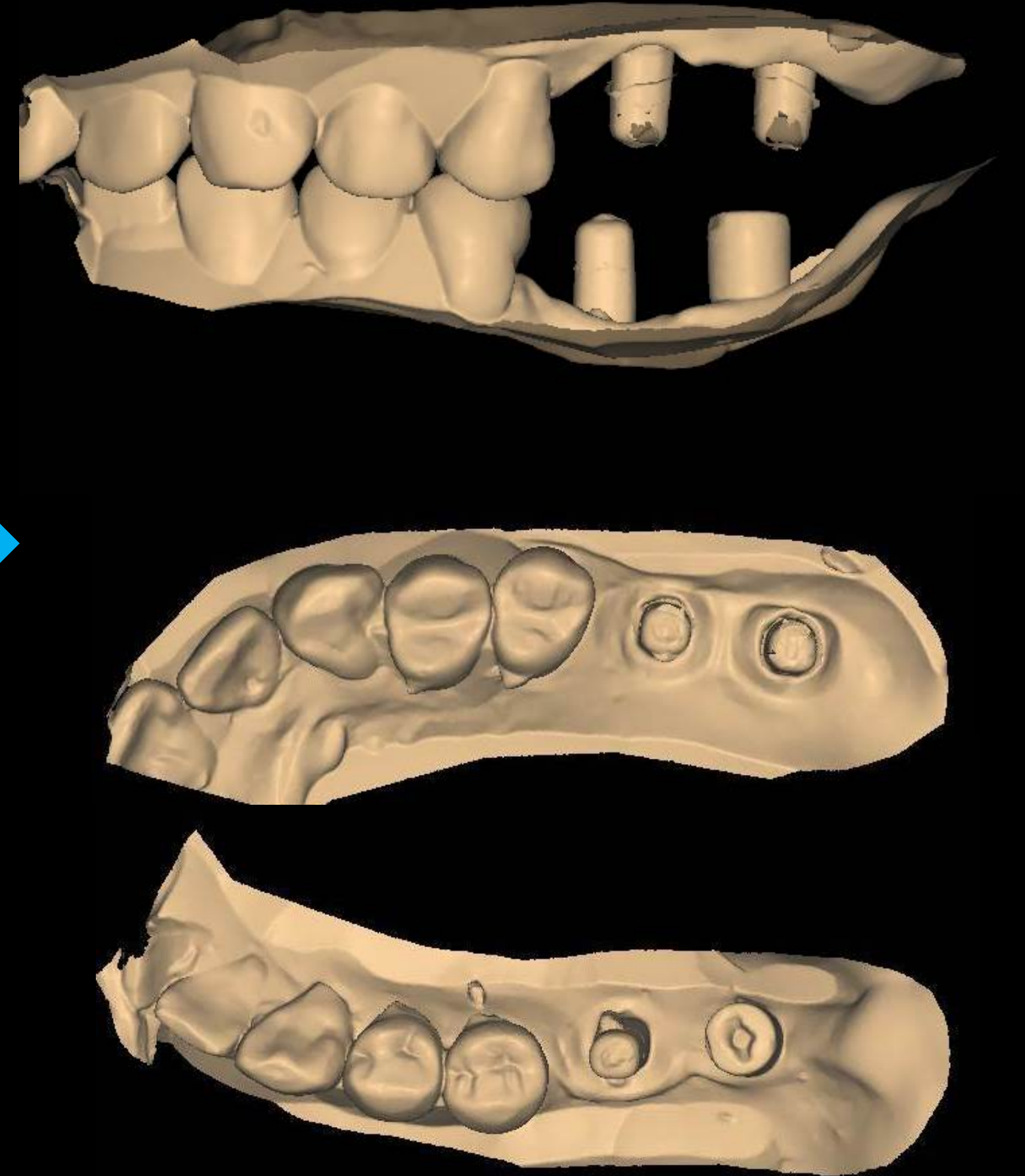
Bite Tray impression Scan



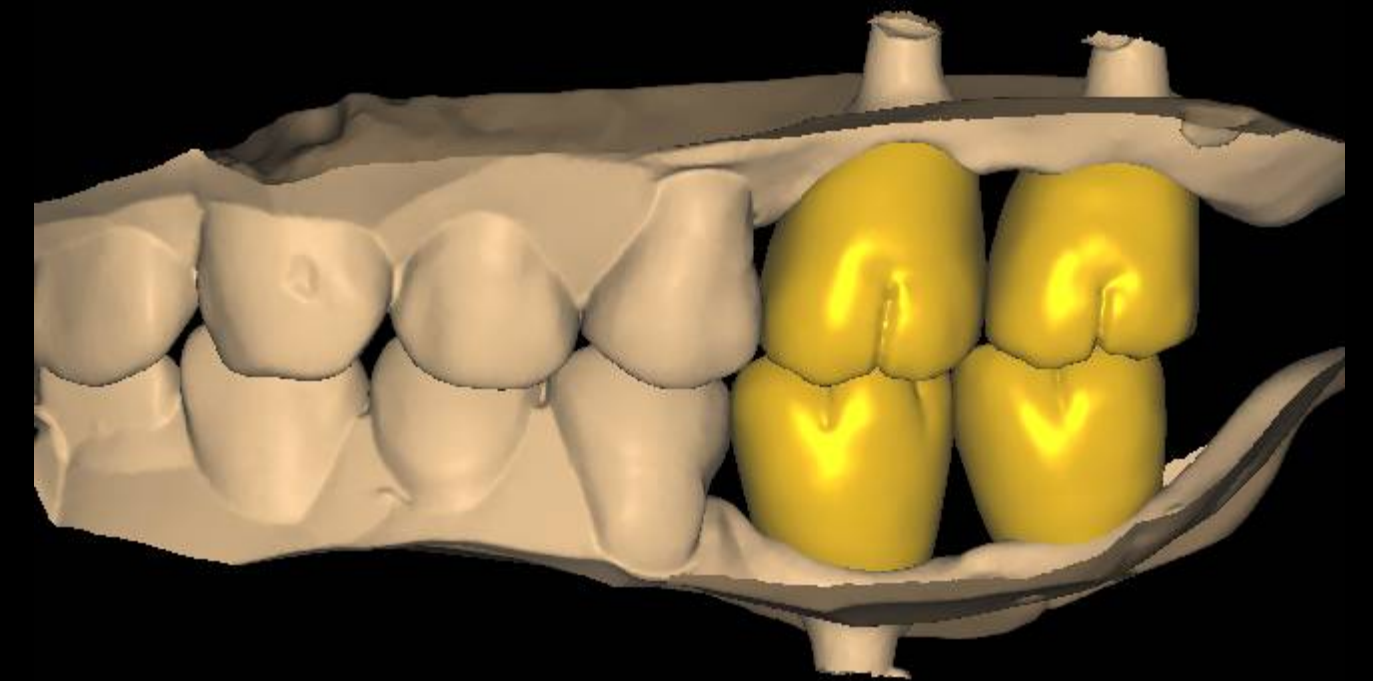

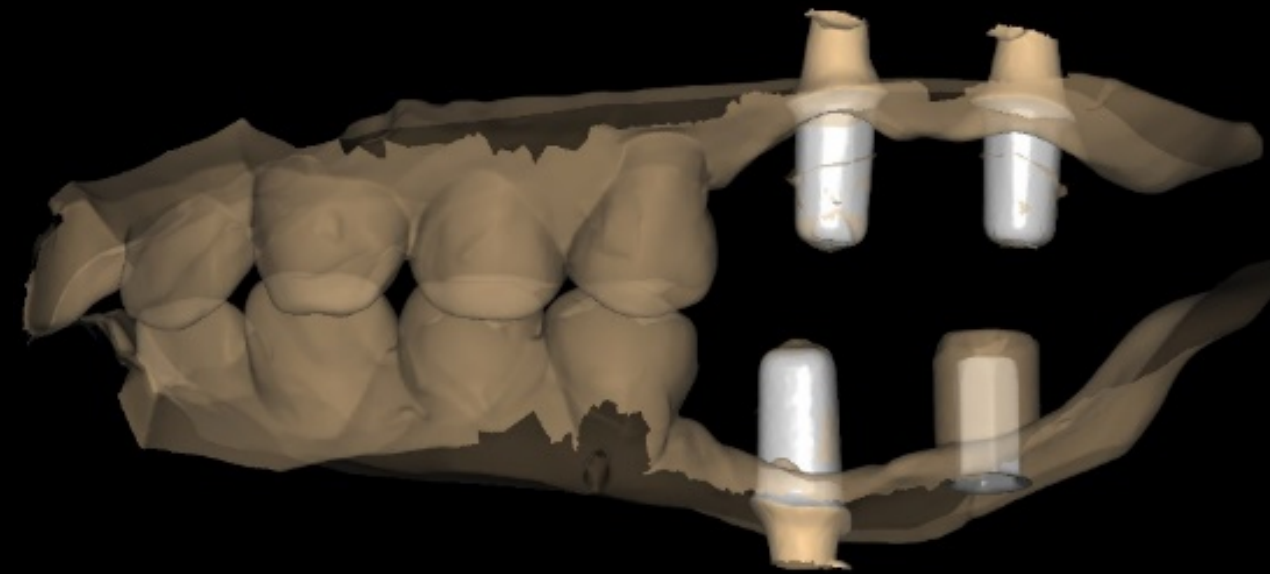

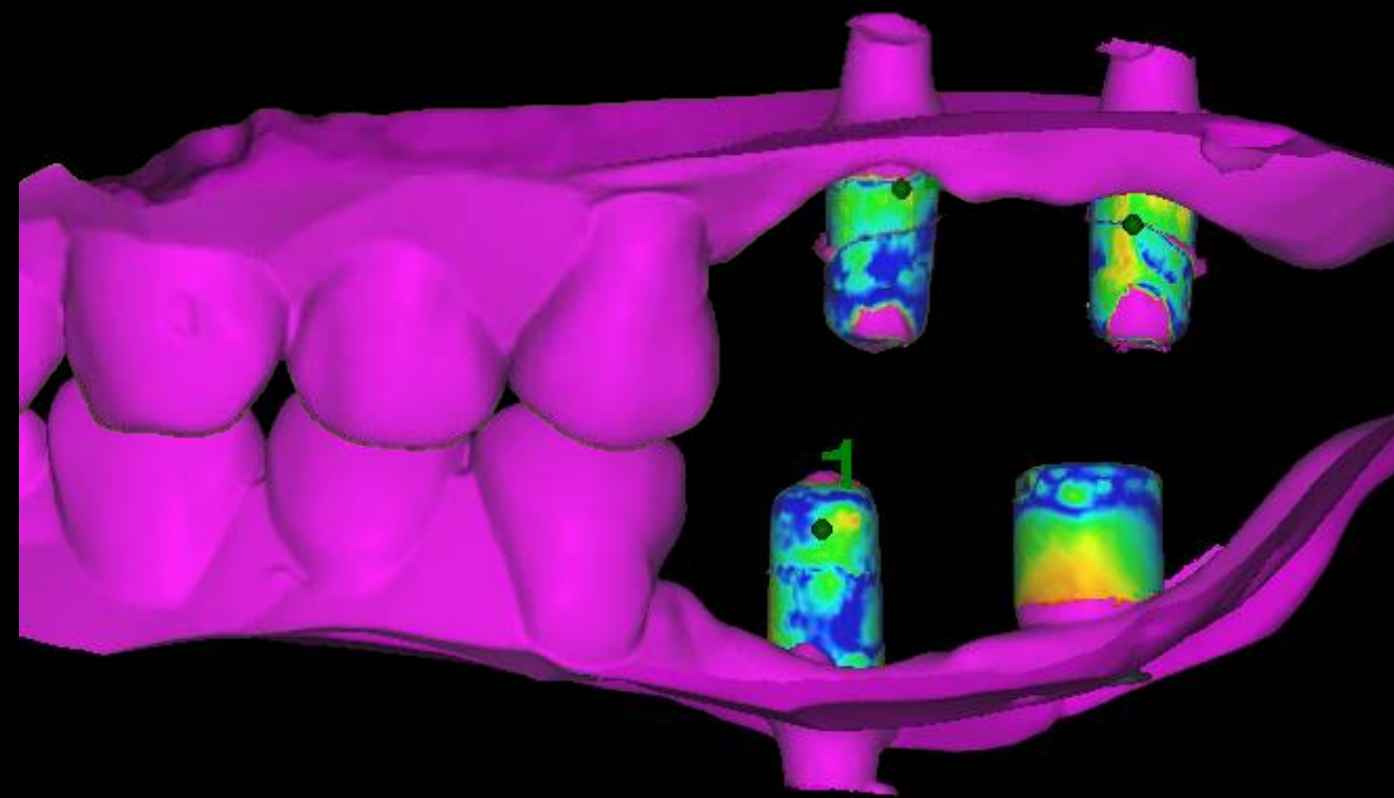
Border Trimming



Scan spray



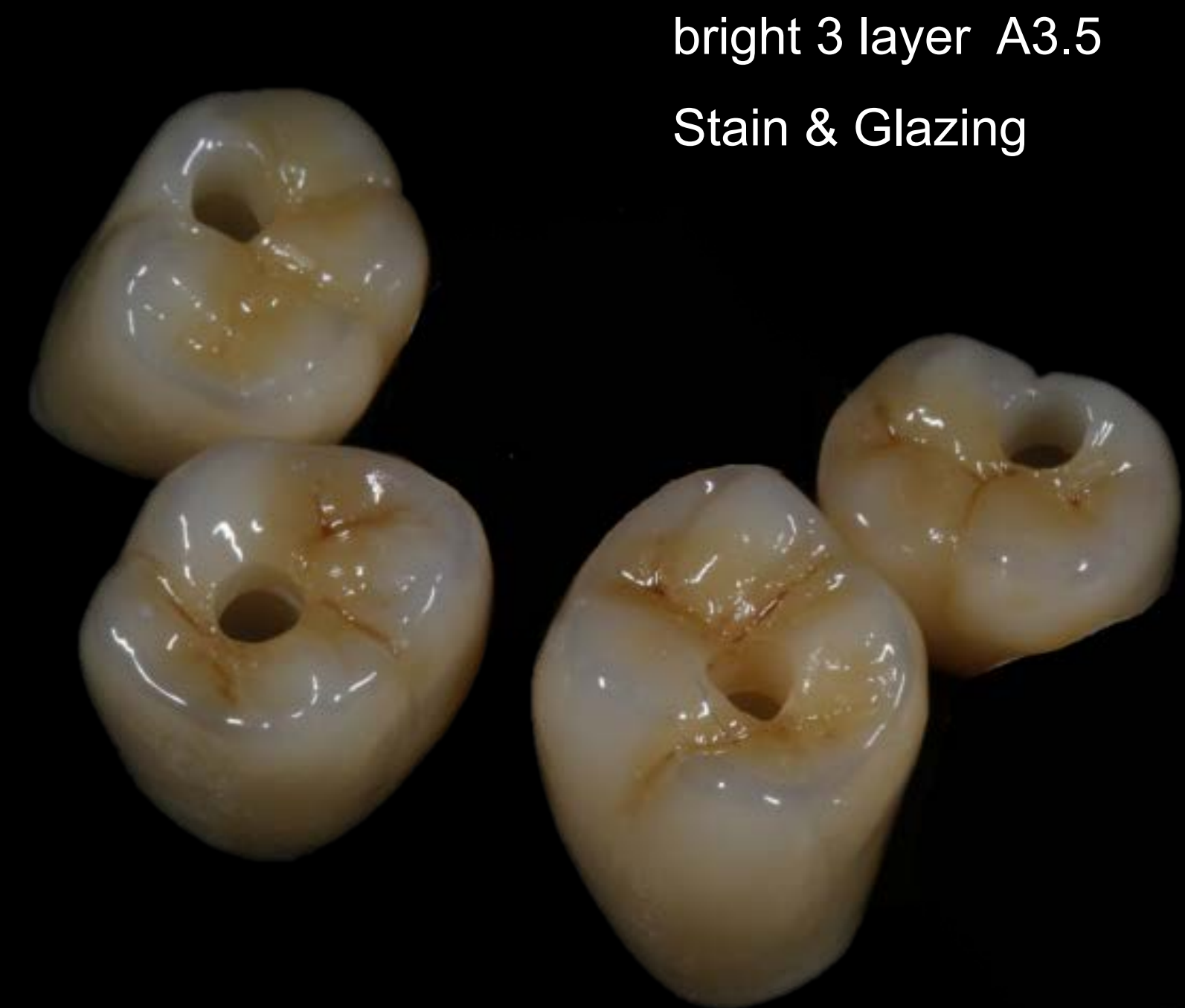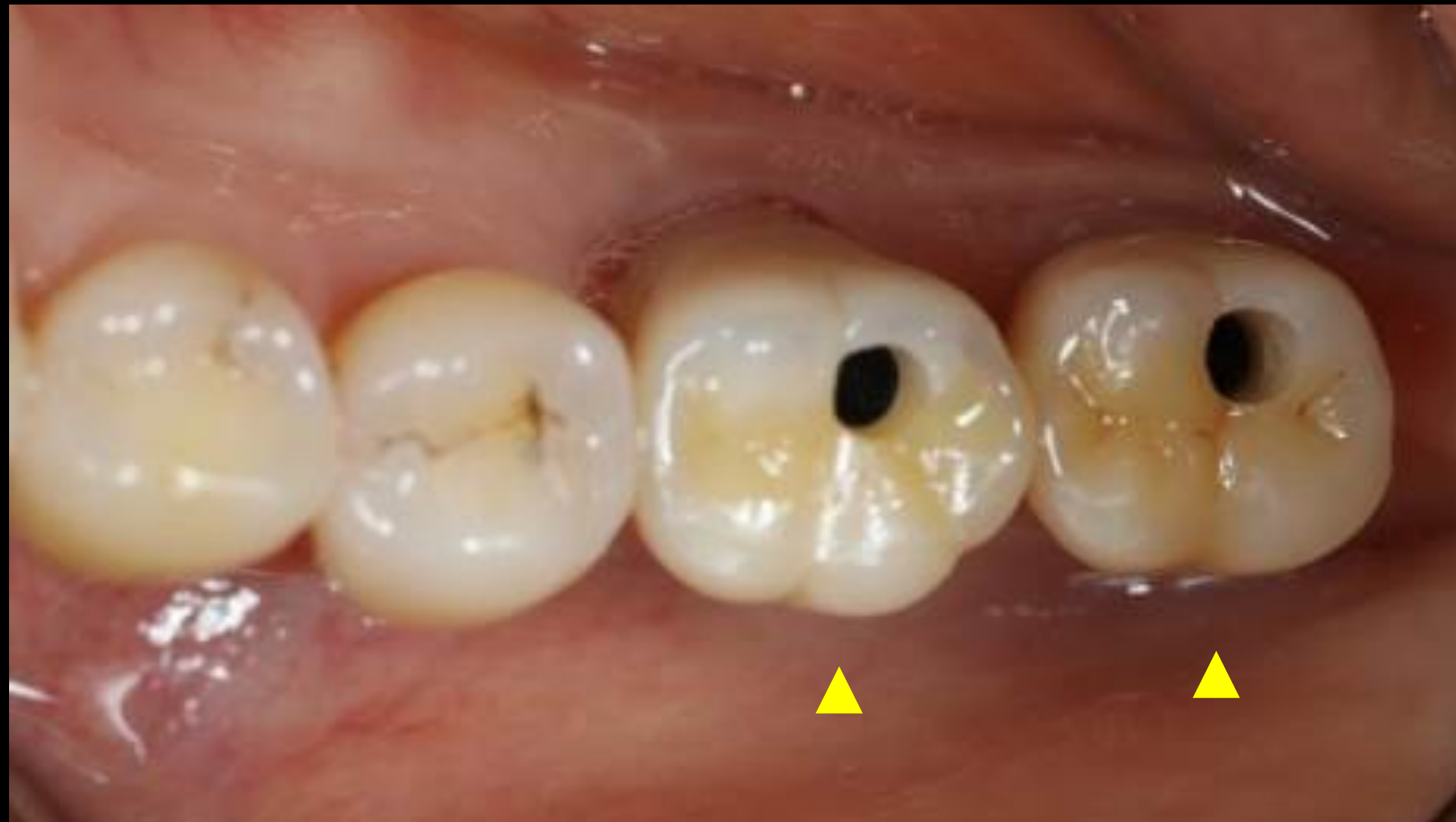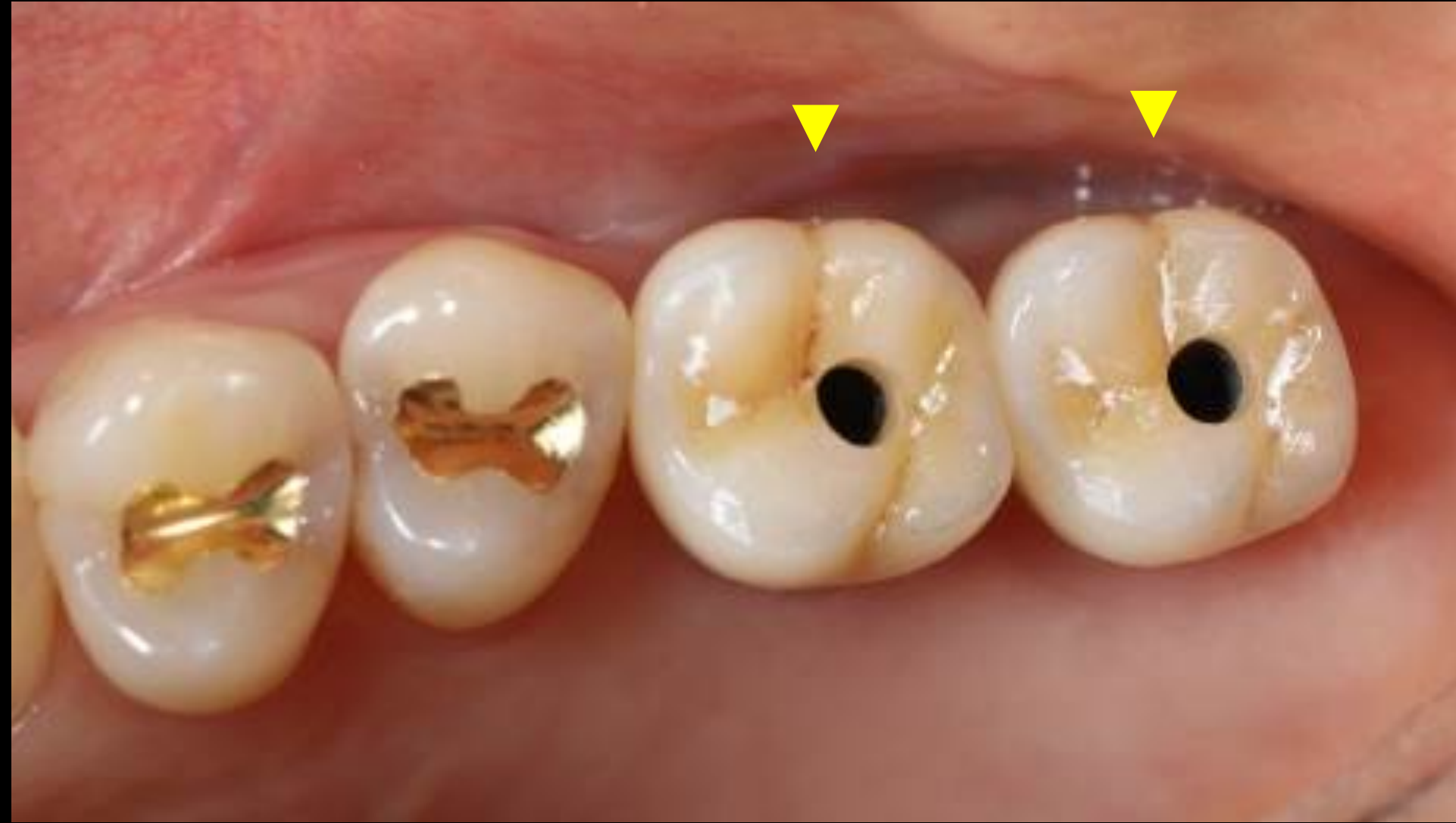Working Model



1) Abutment library stitching

2) Crown design

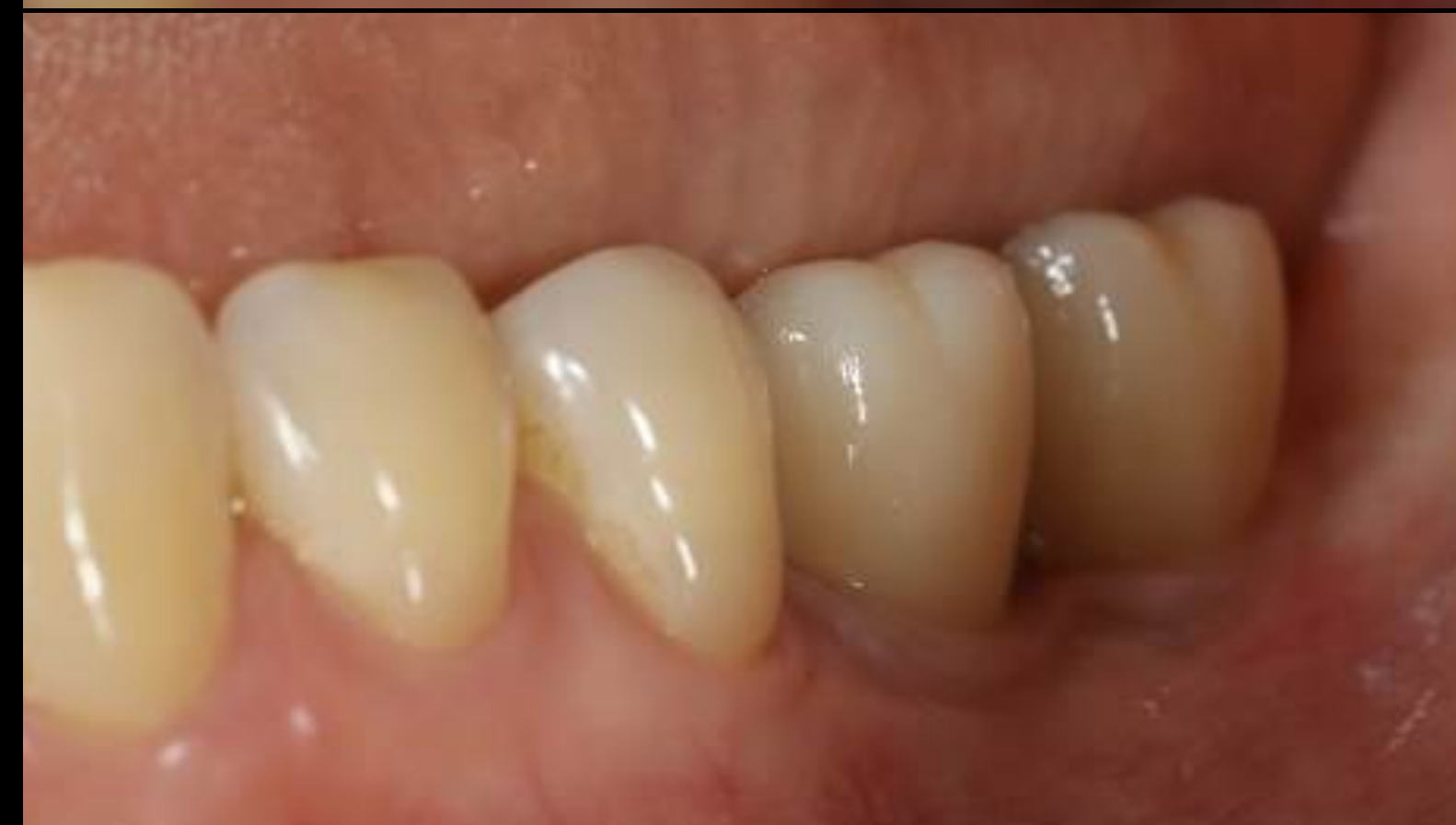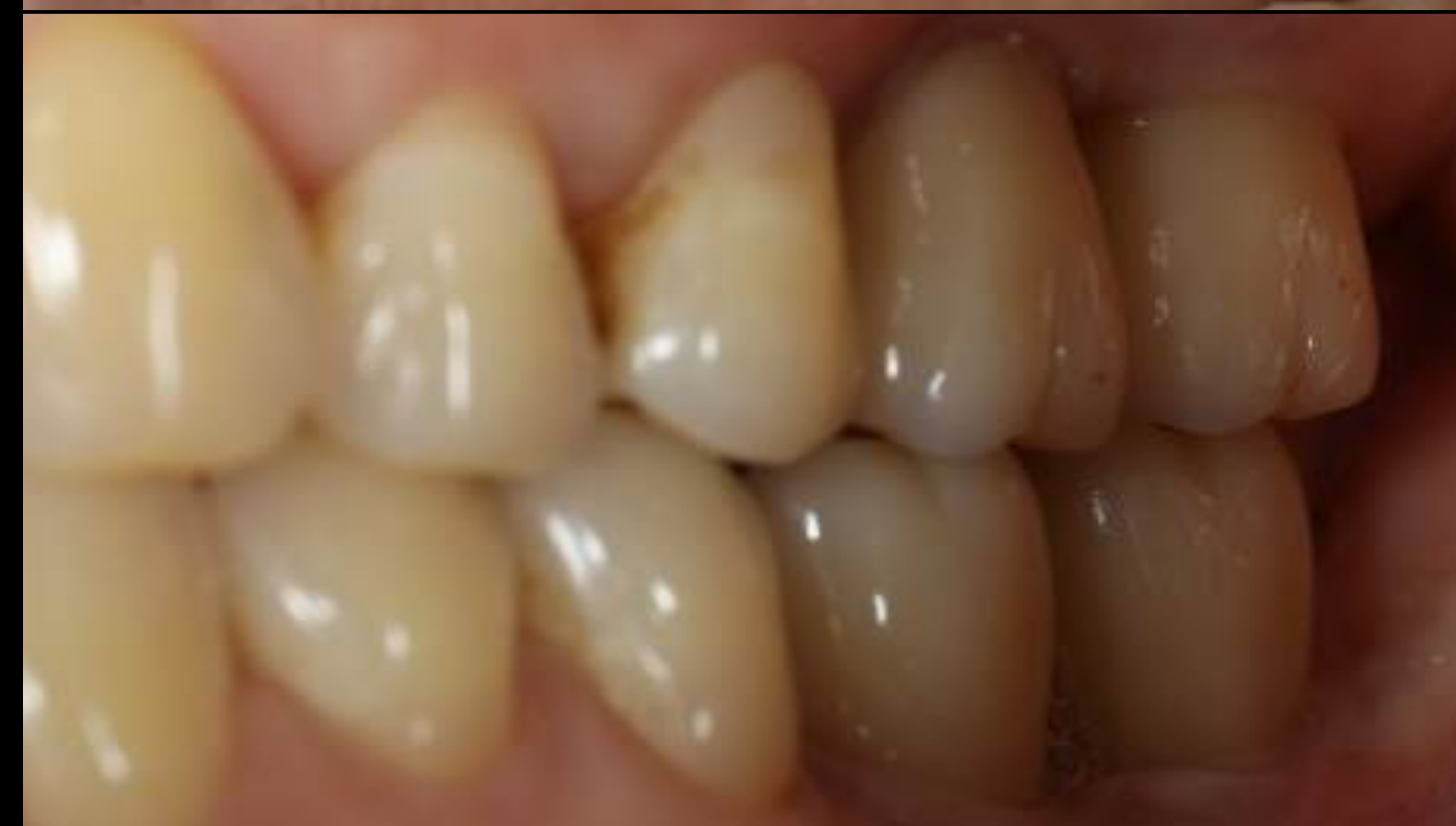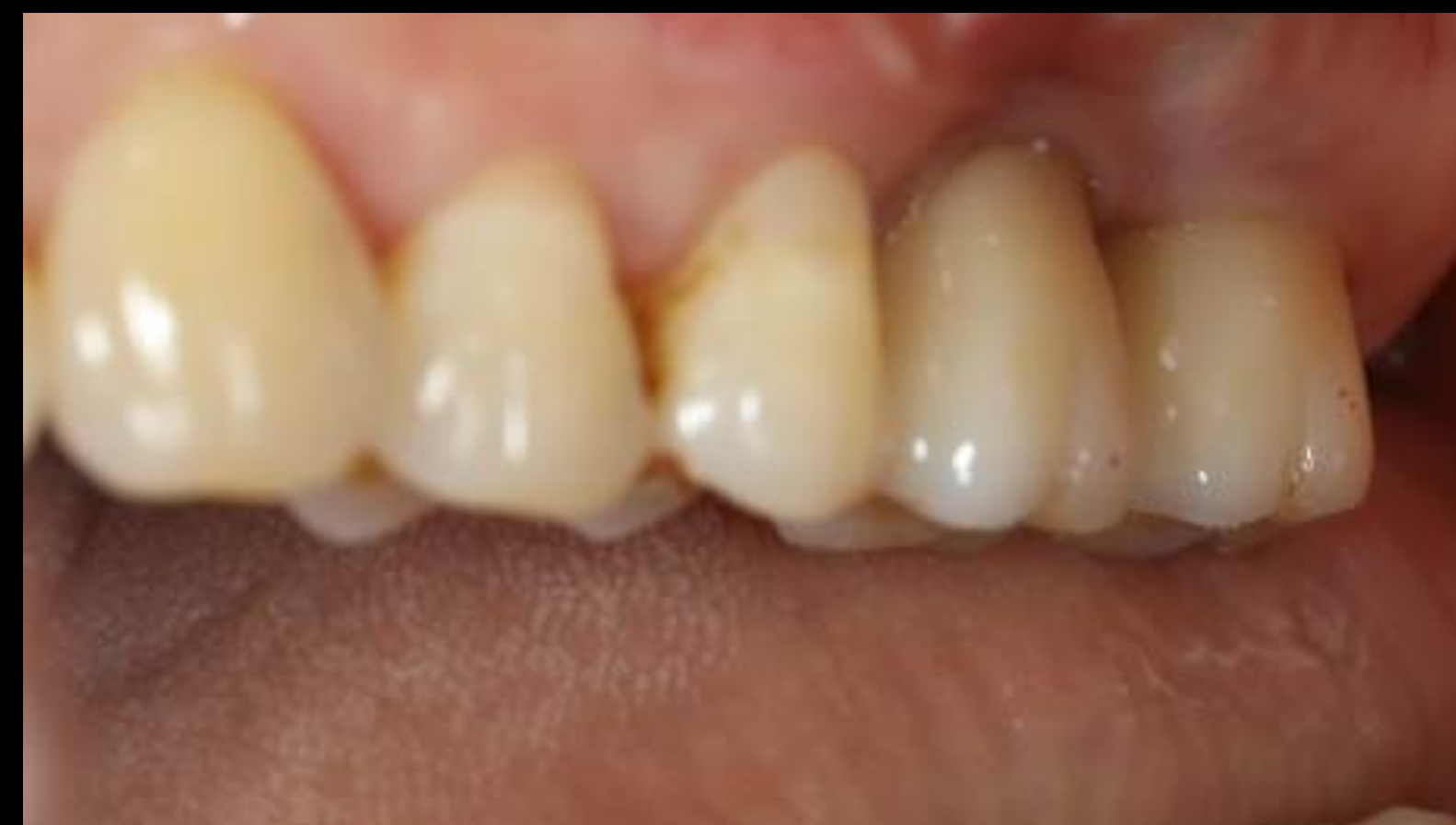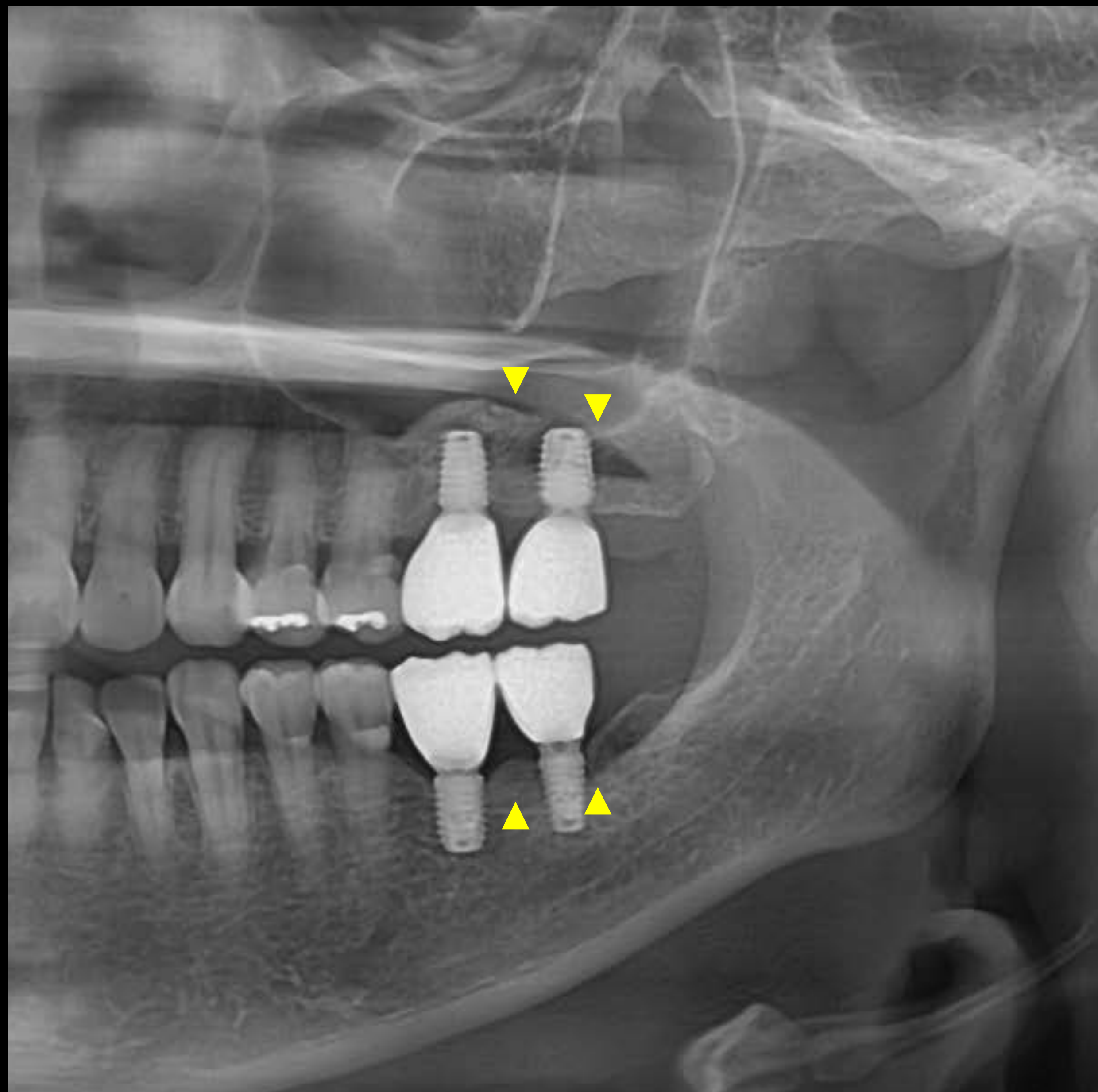
Final Prosthesis



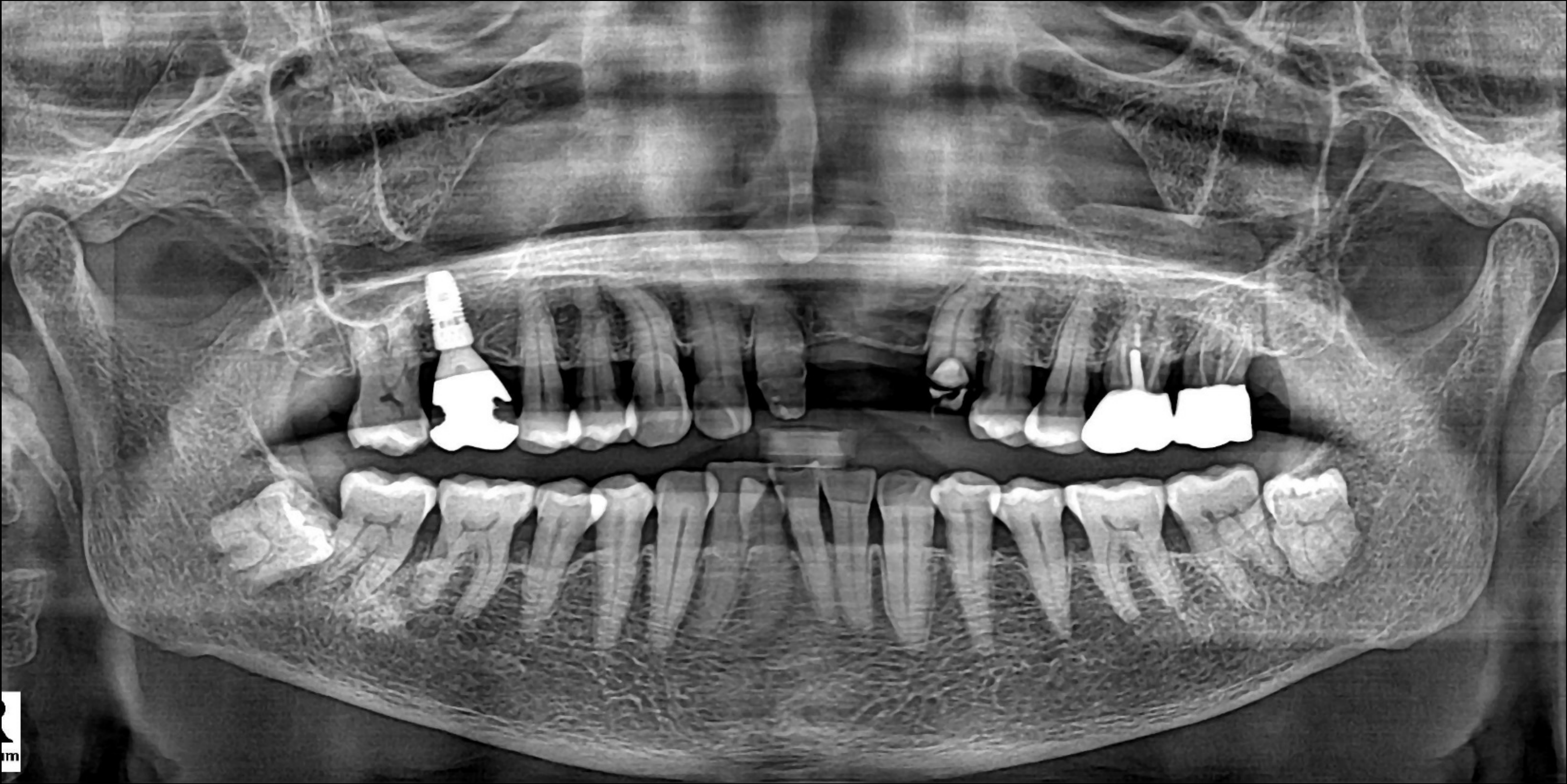
bright 3 layer A3.5
Stain & Glazing

Very precise without occlusal adjustment

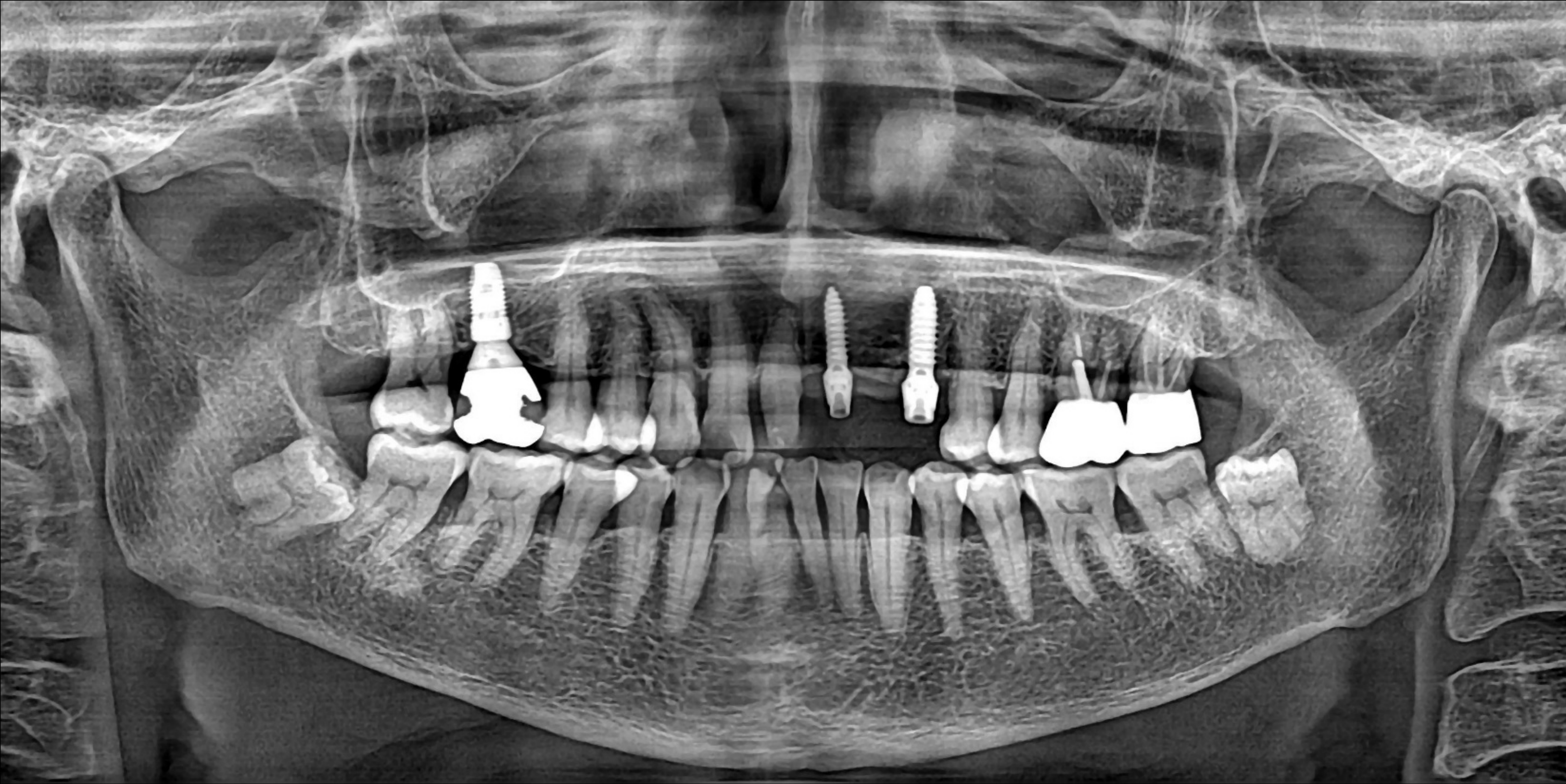
Final Prosthesis



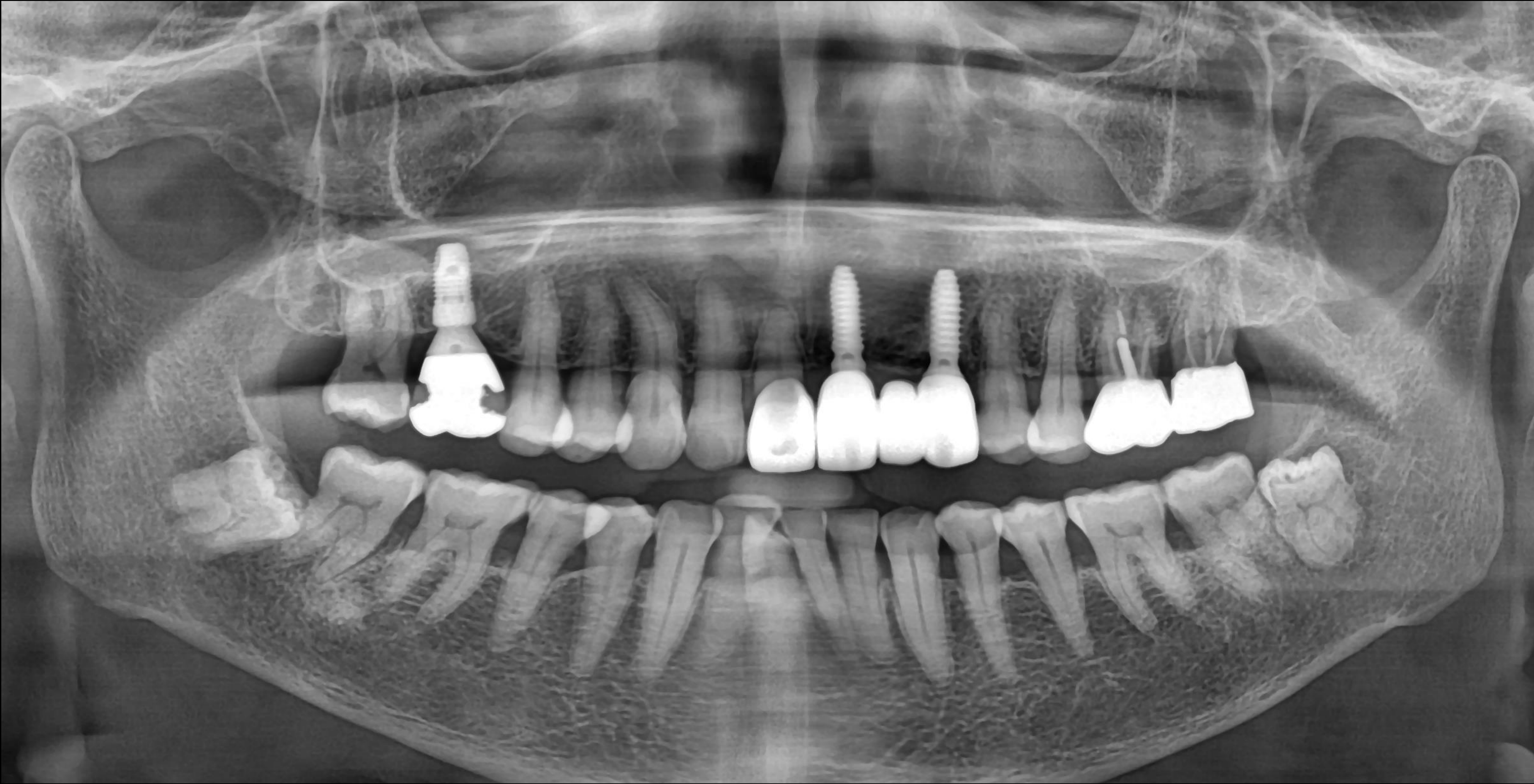
Pre-op (2023-09-06)

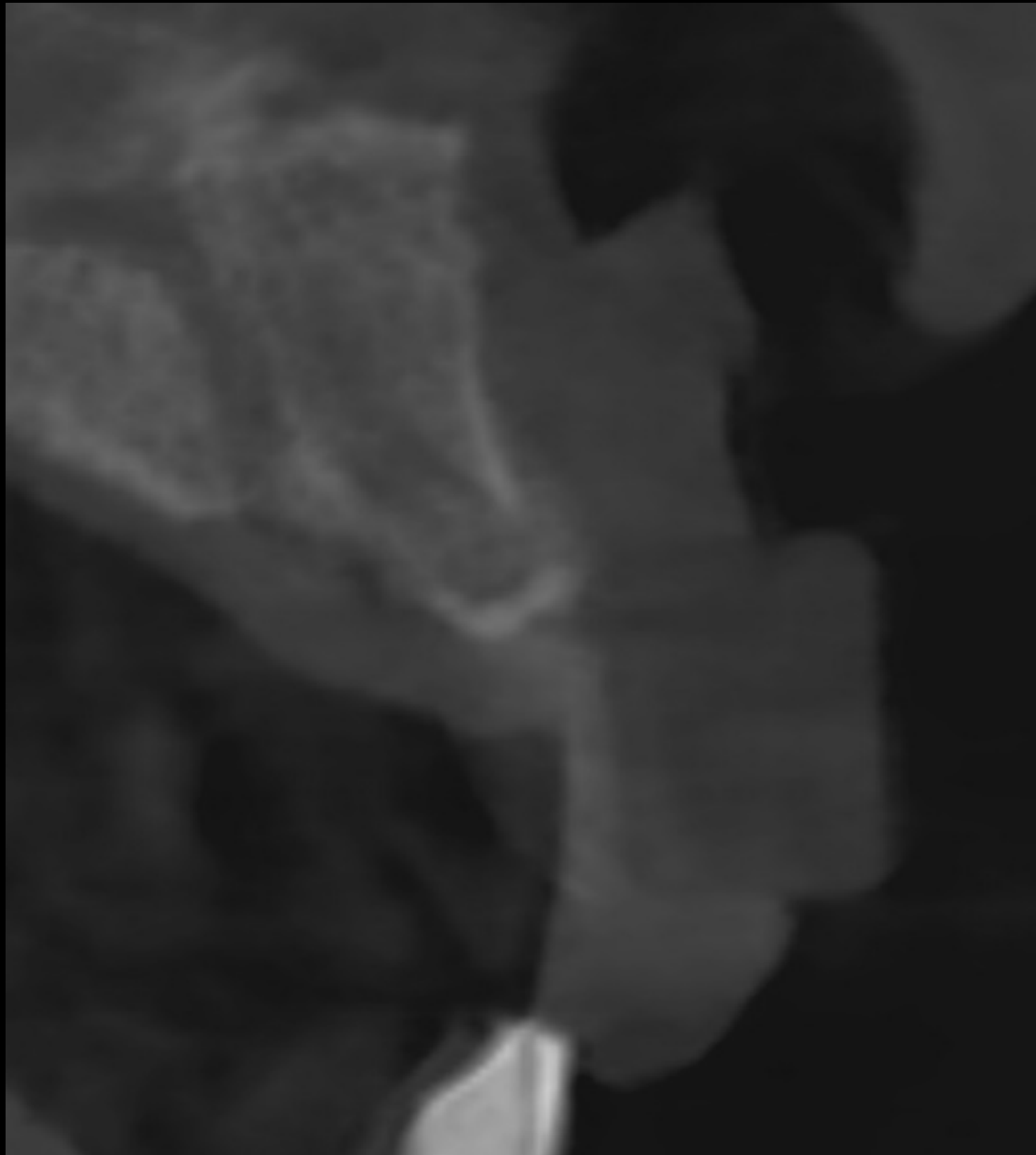

Post-op (2023-09-06)

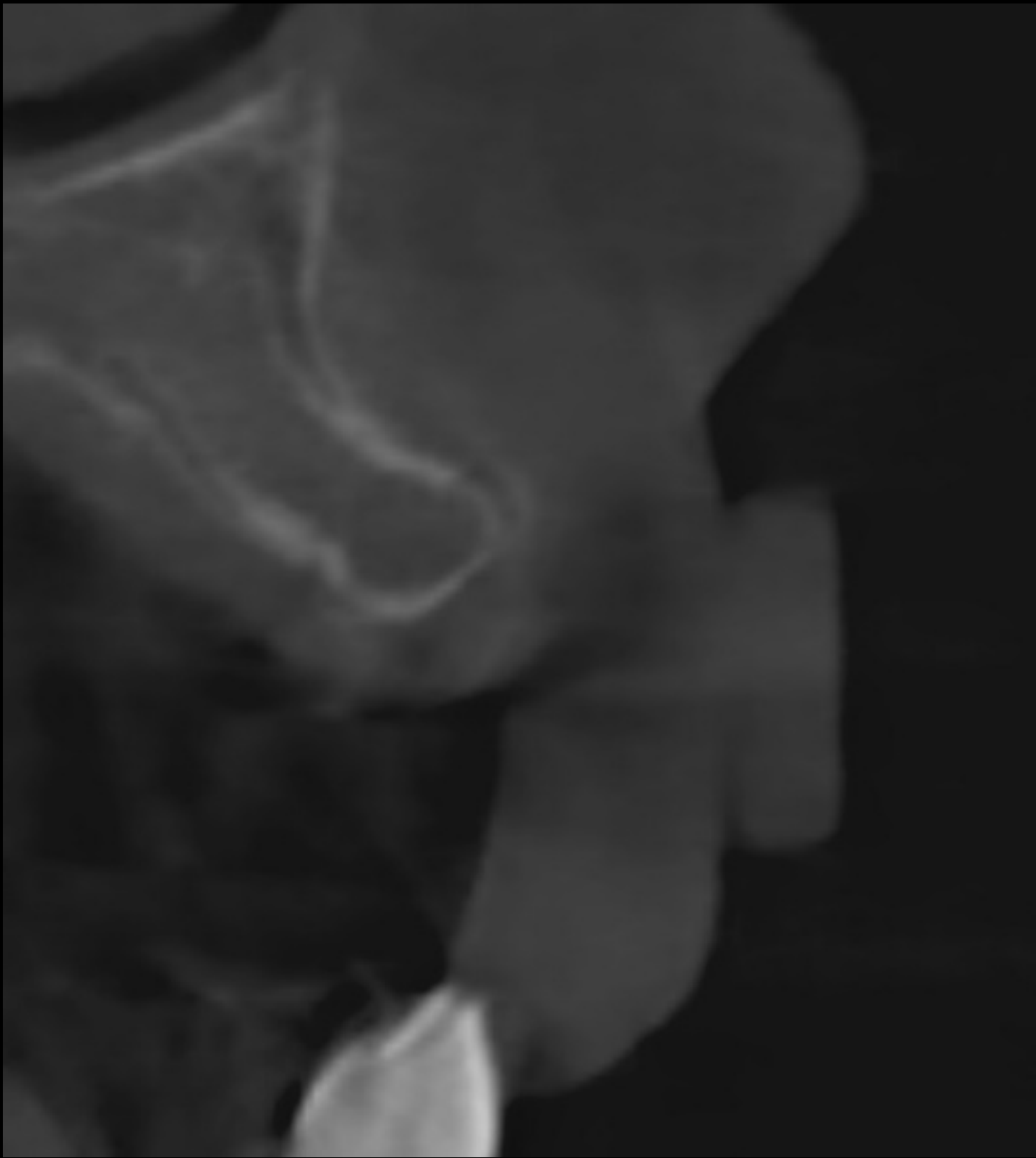


Final prosthesis (2023-11-02)

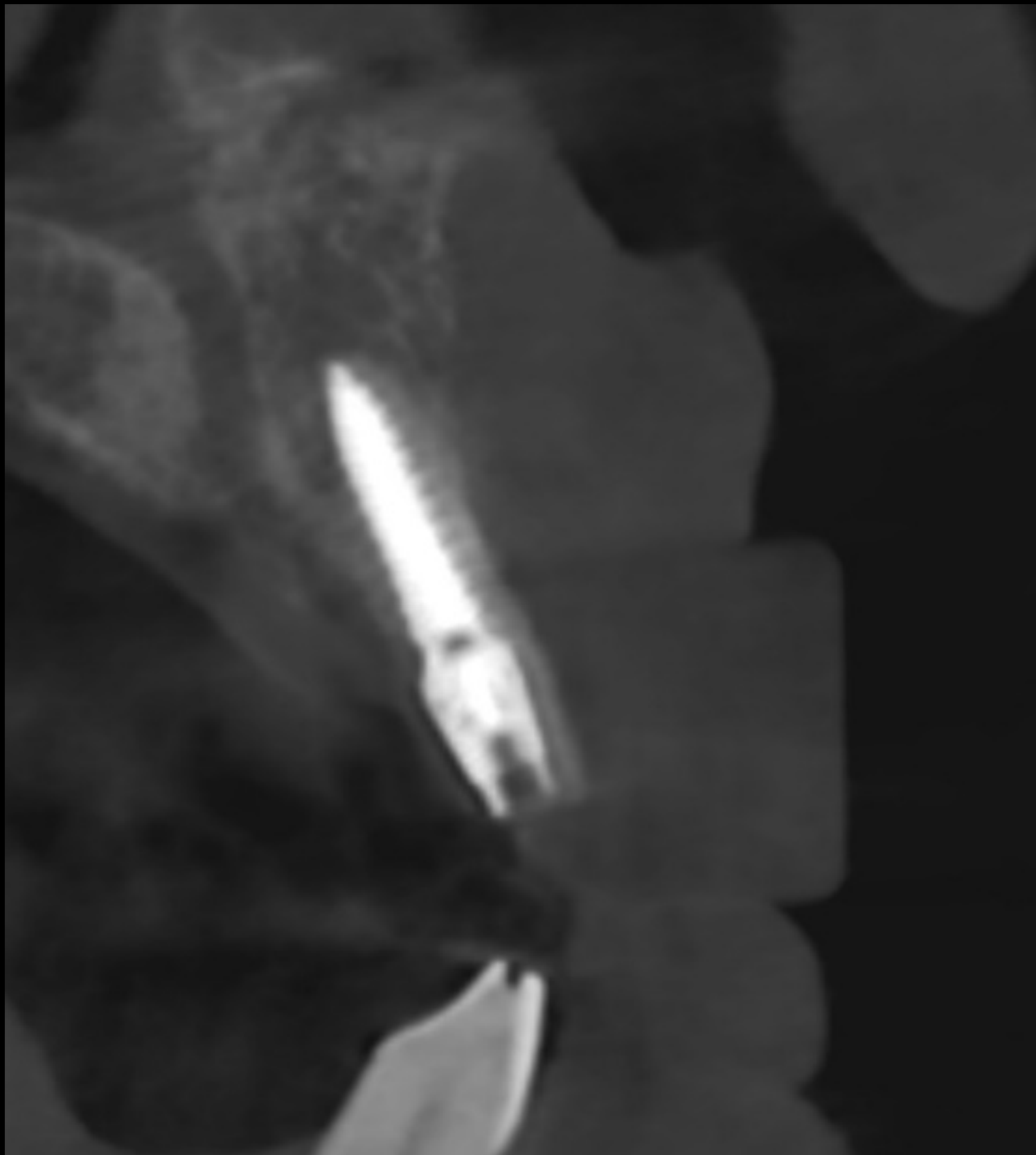




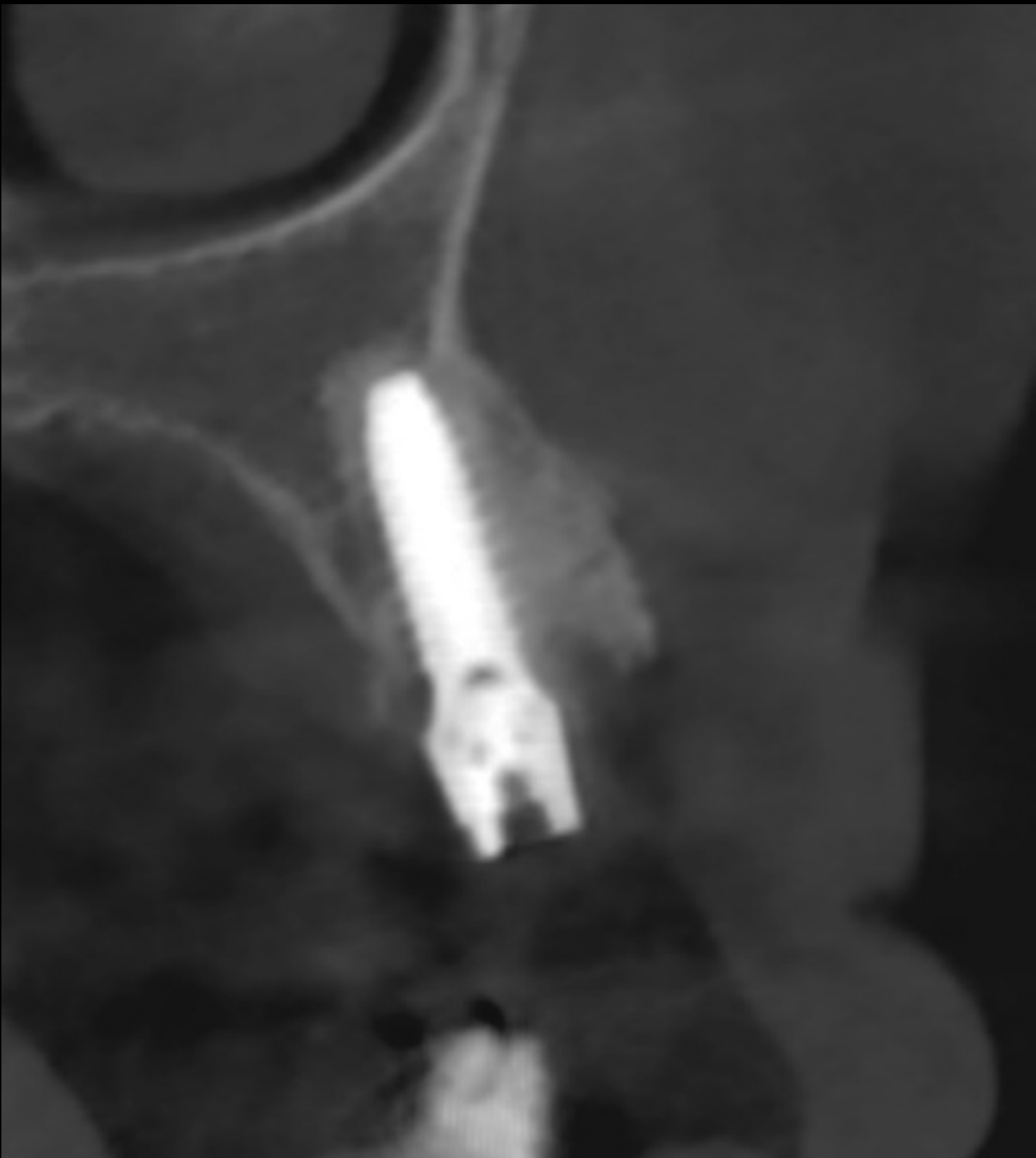#21



#22

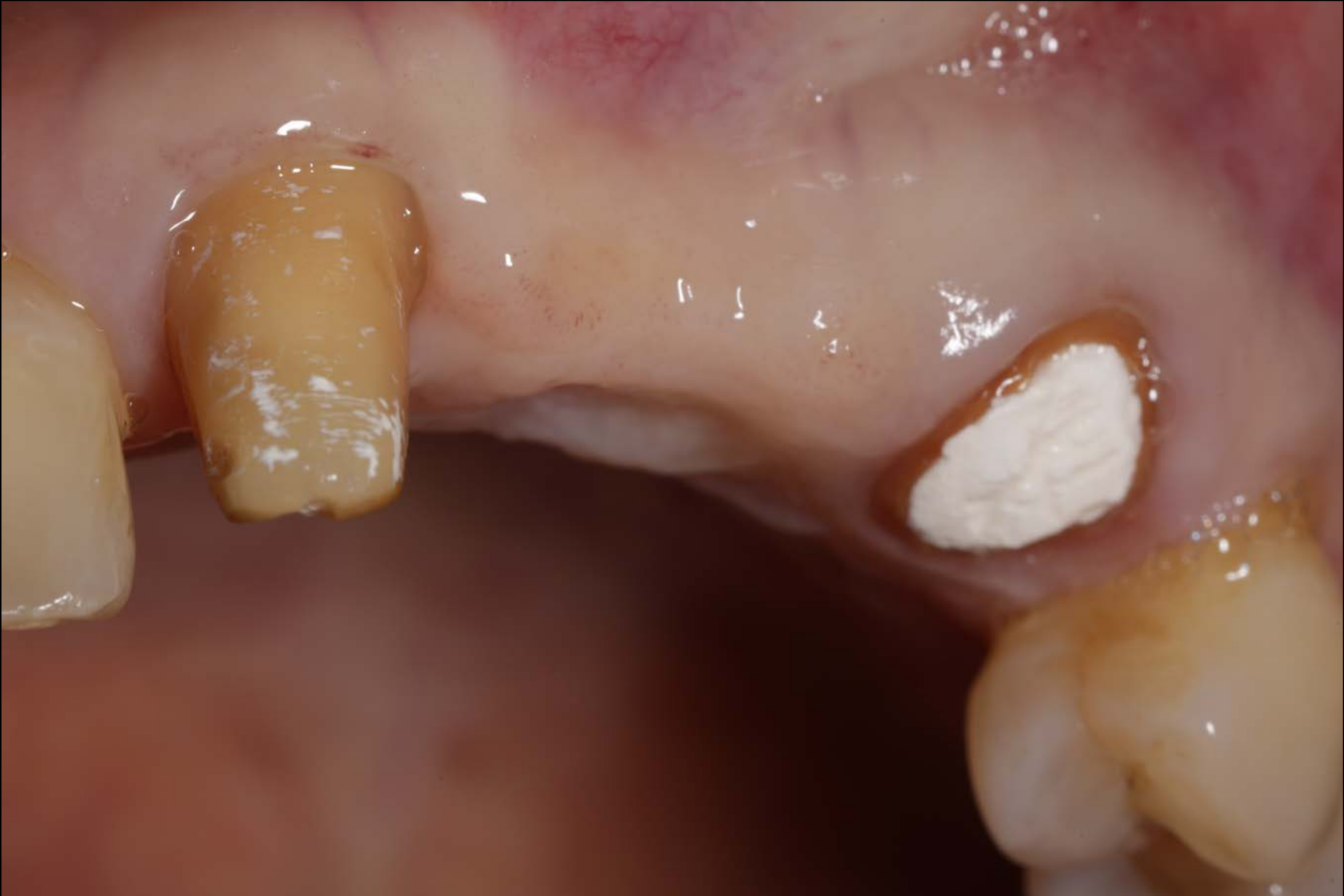

#21

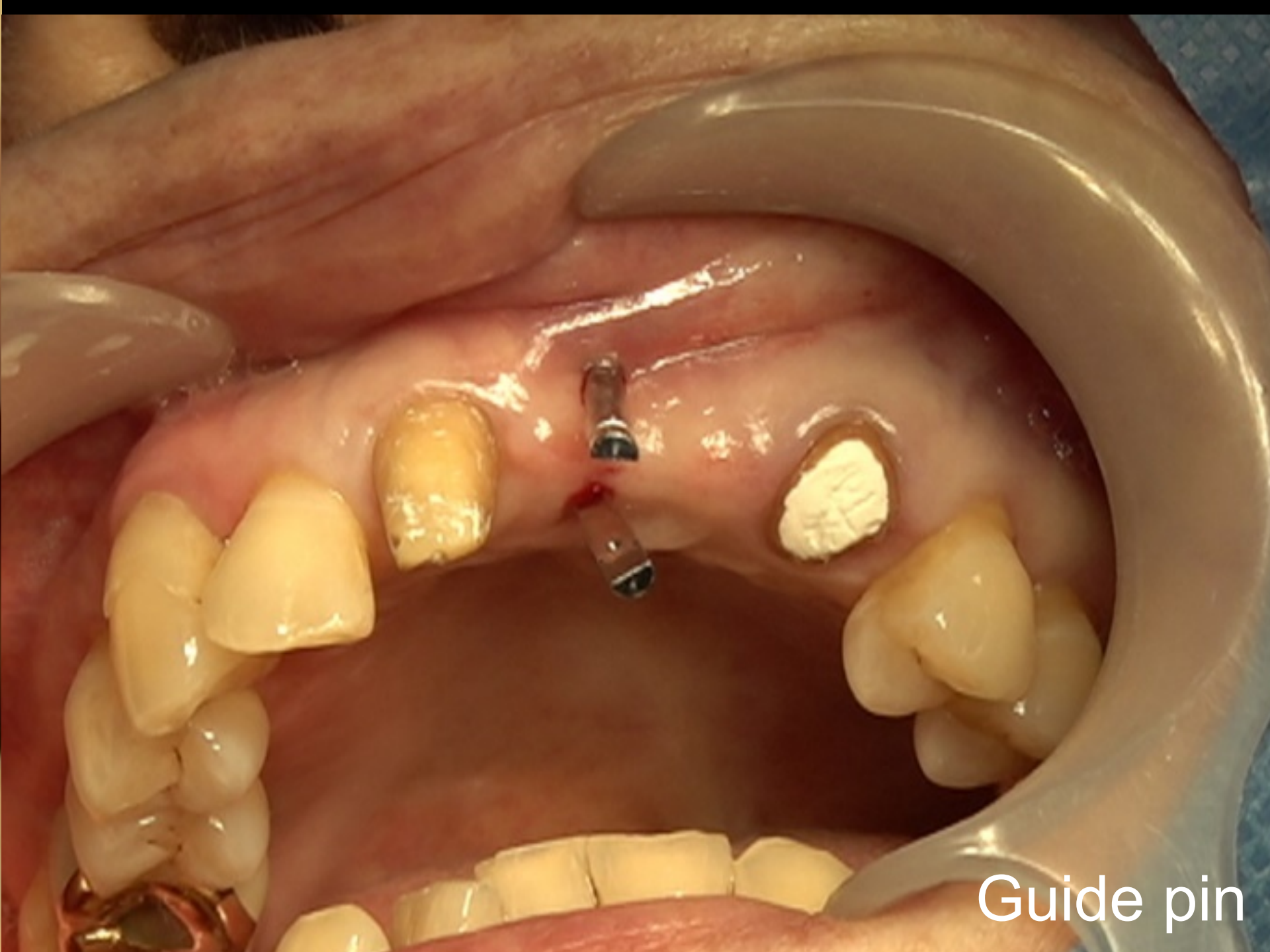
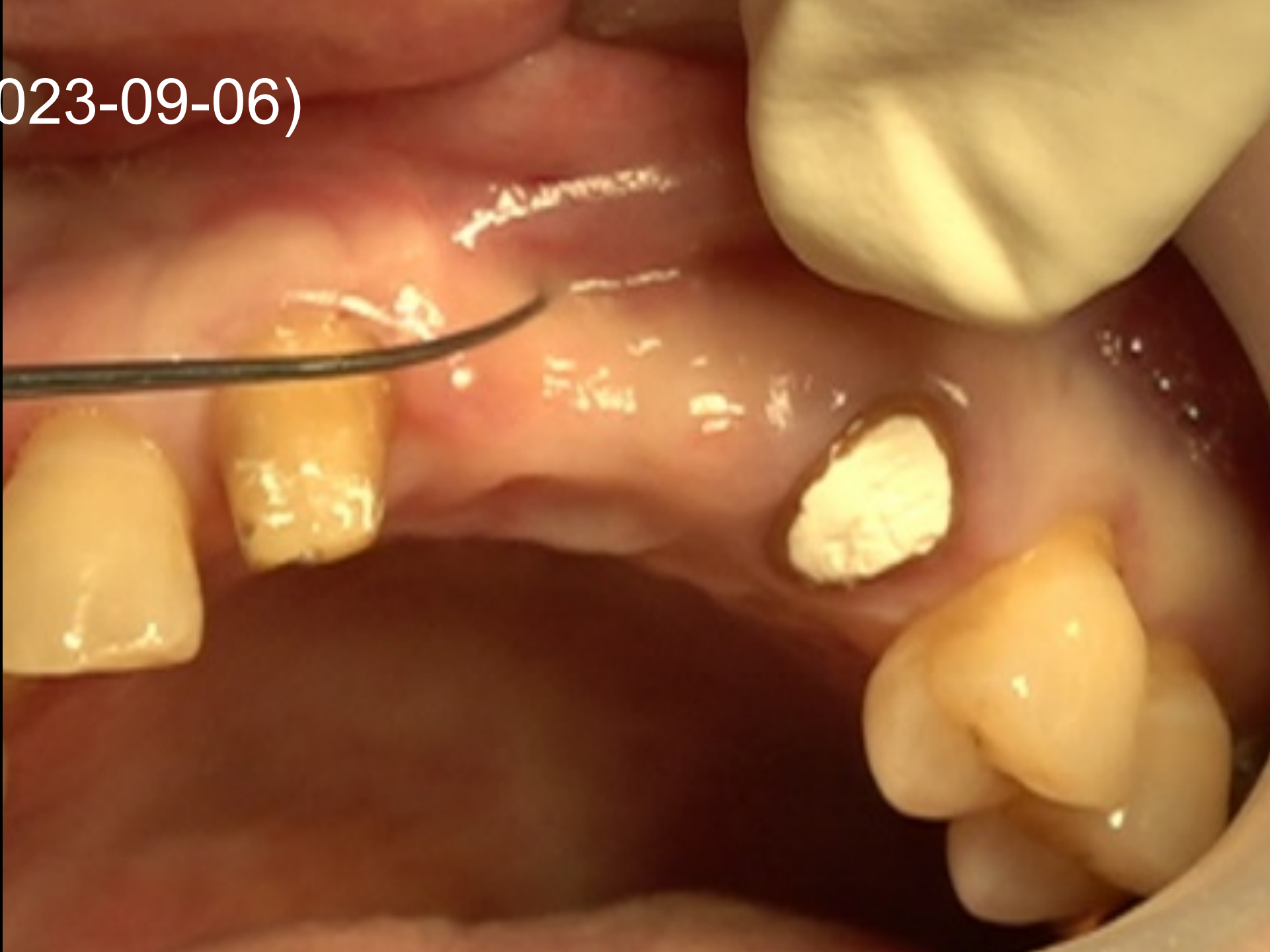


#22

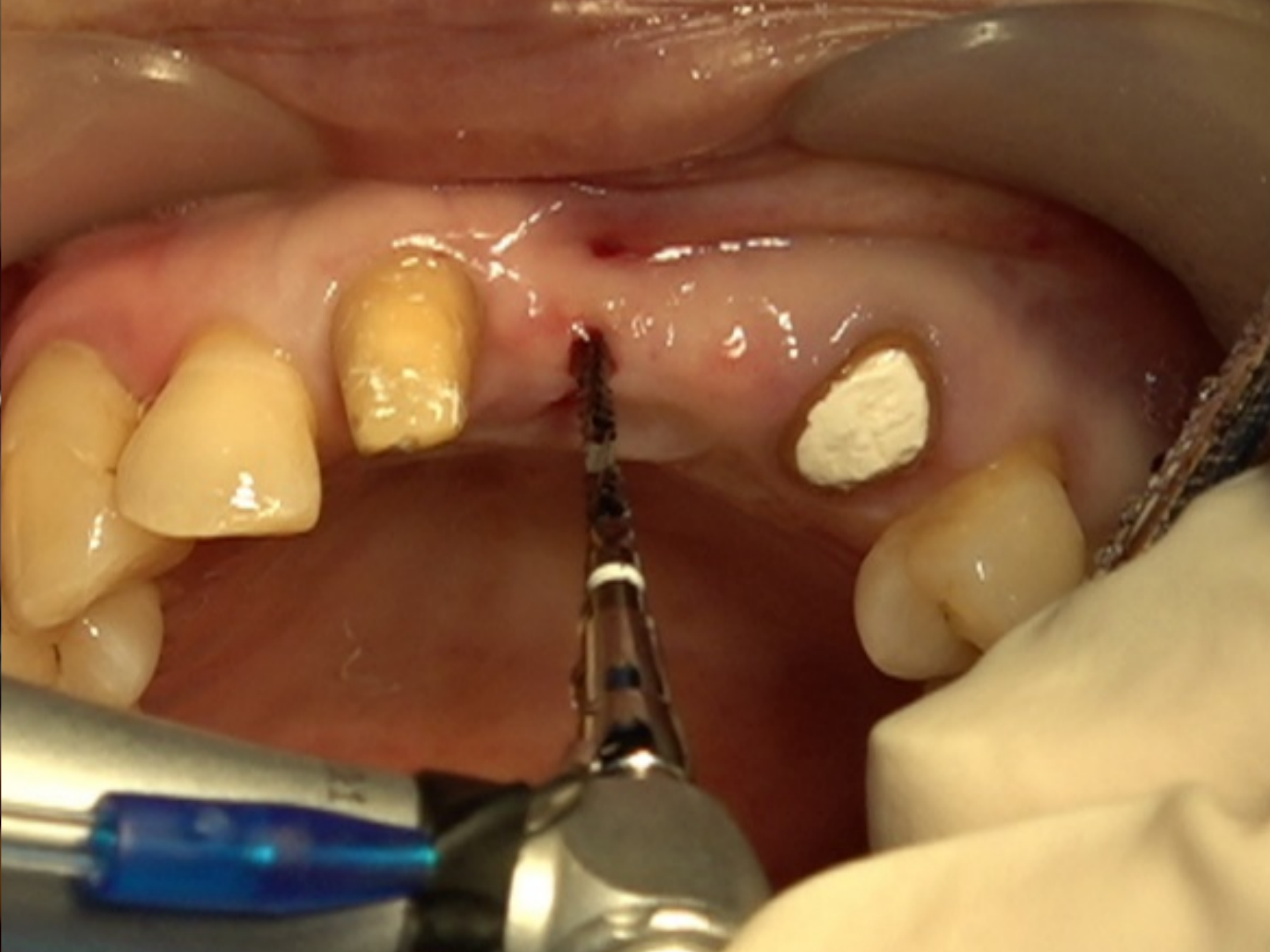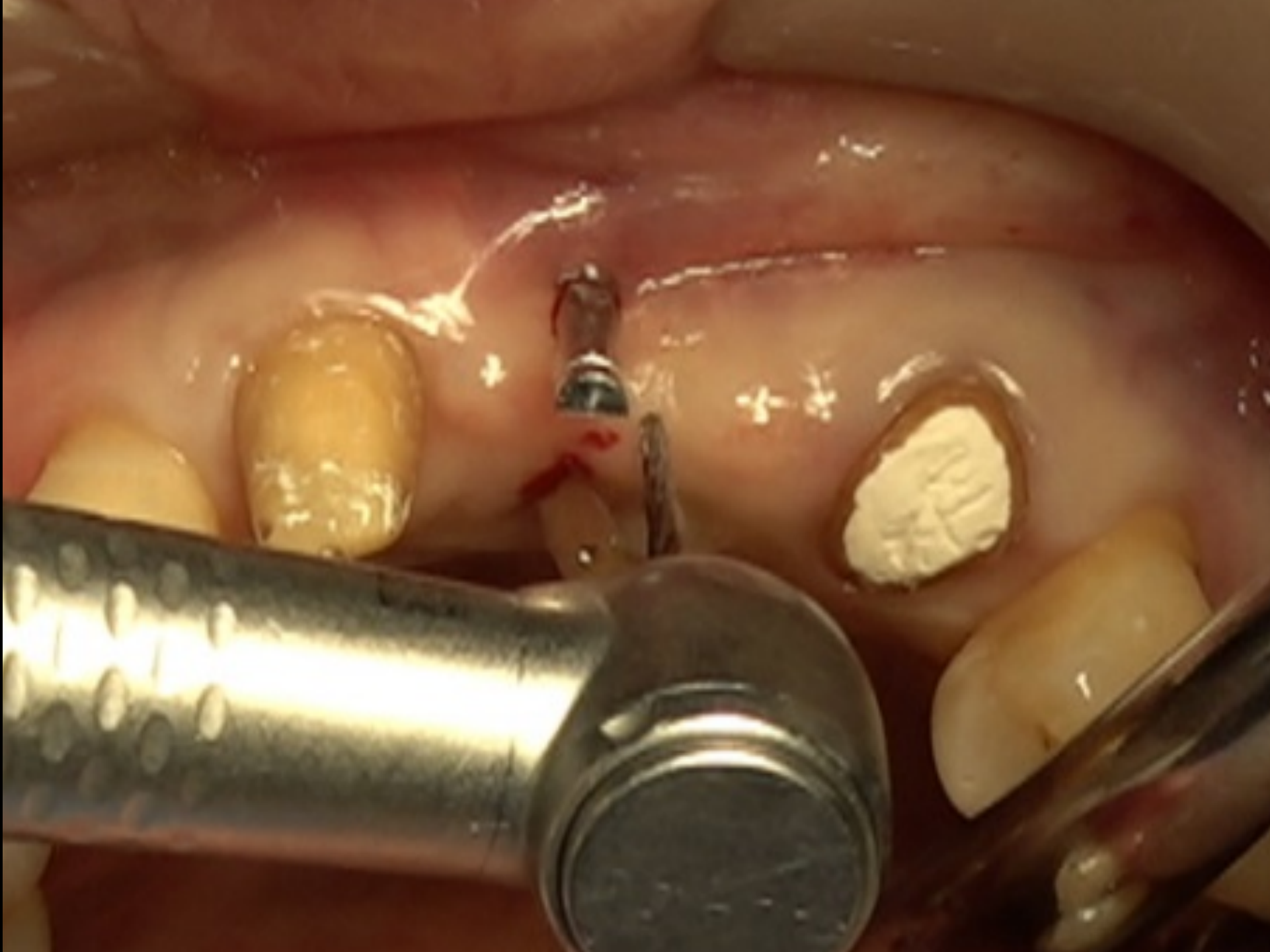
Pre-op (2023-09-06)



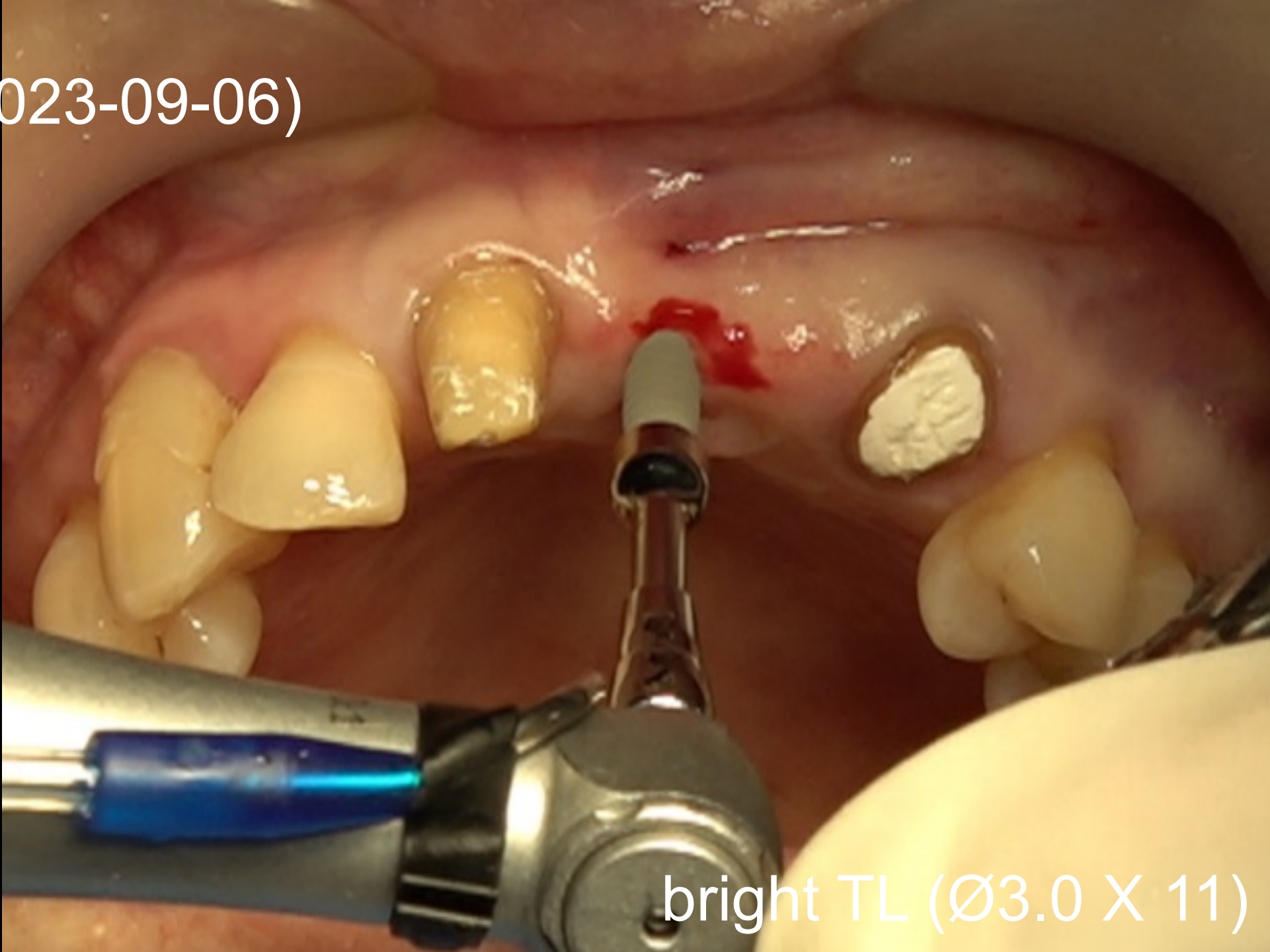Surgery (2023-09-06)



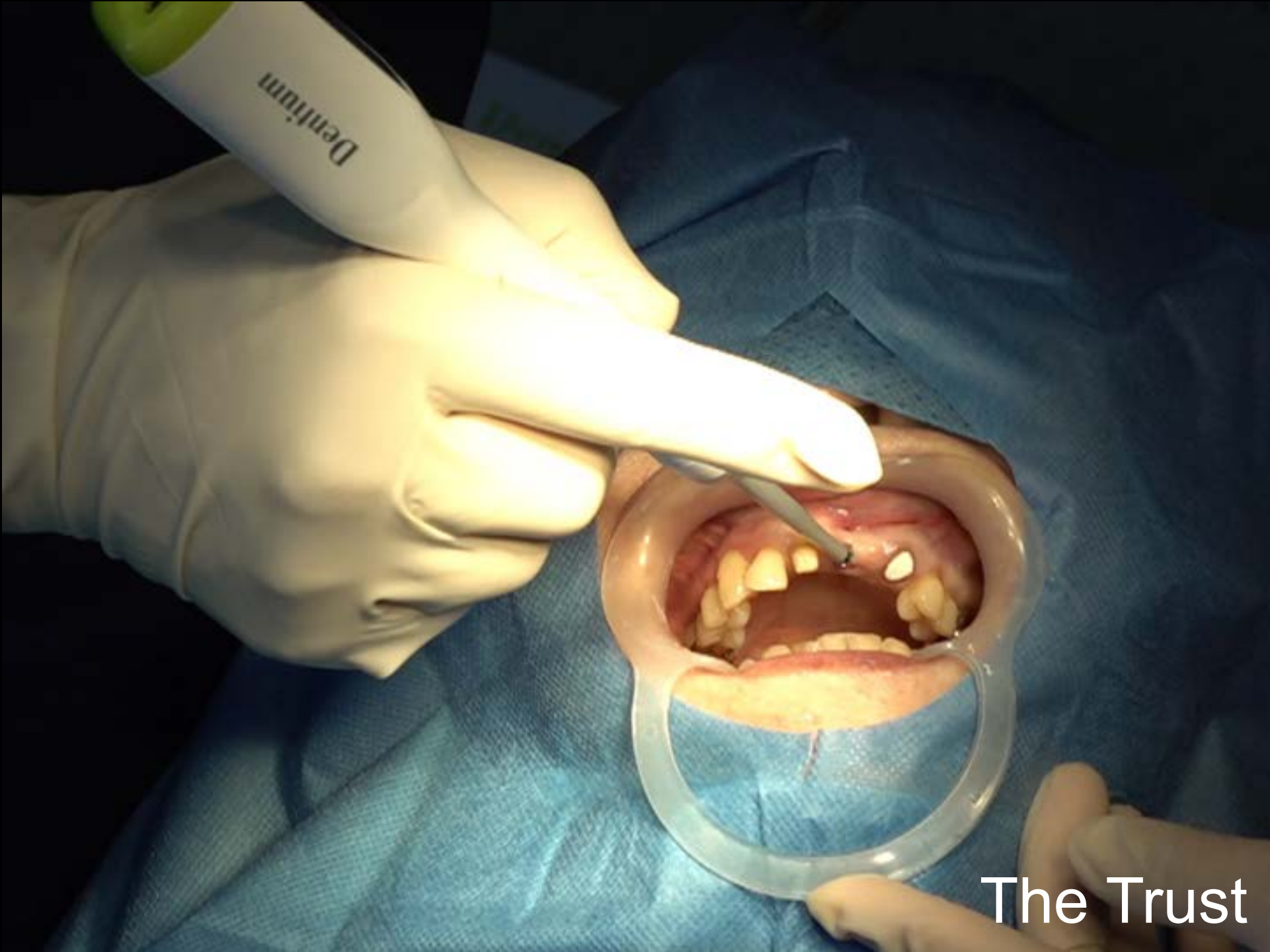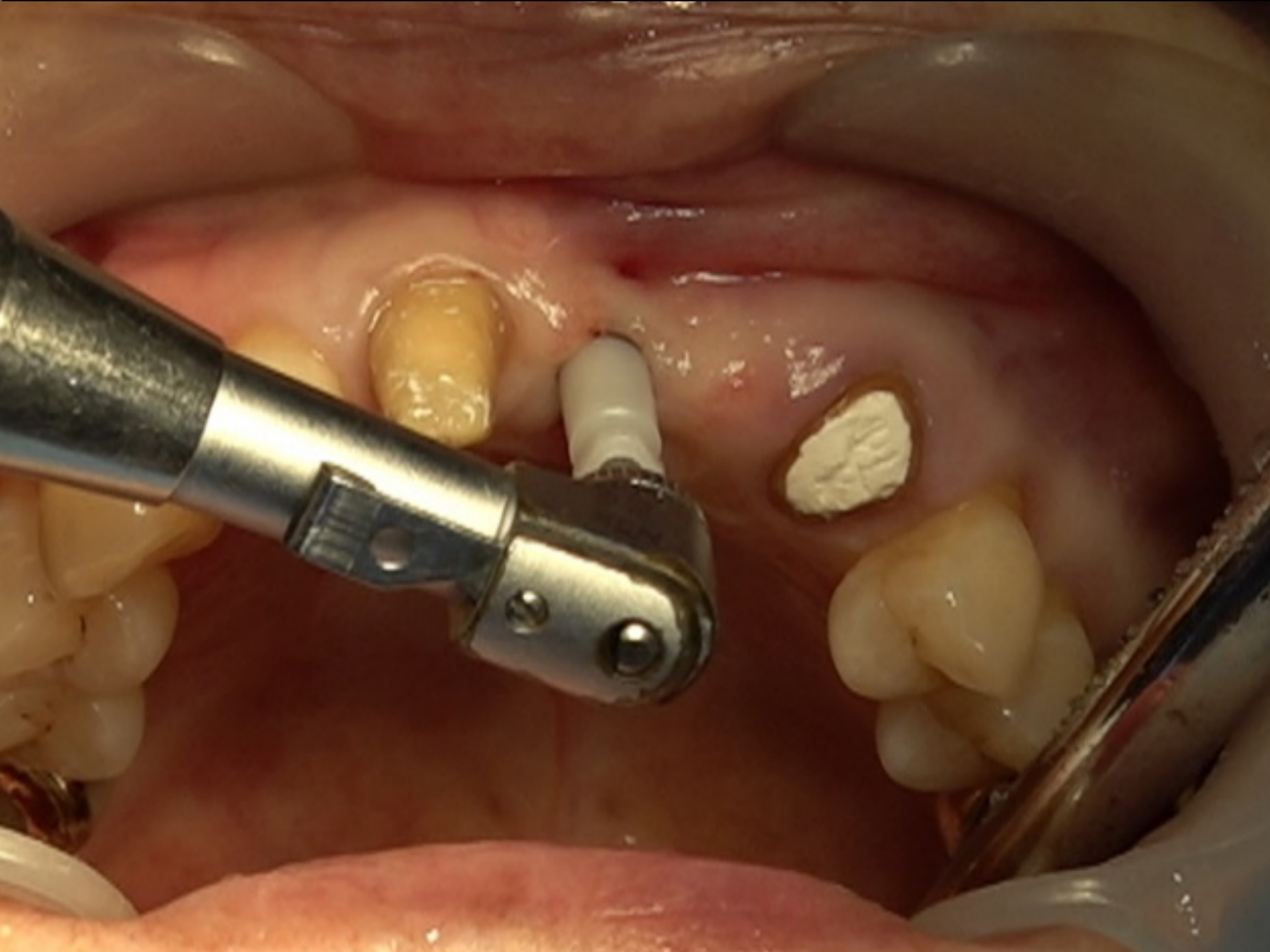
Guide pin



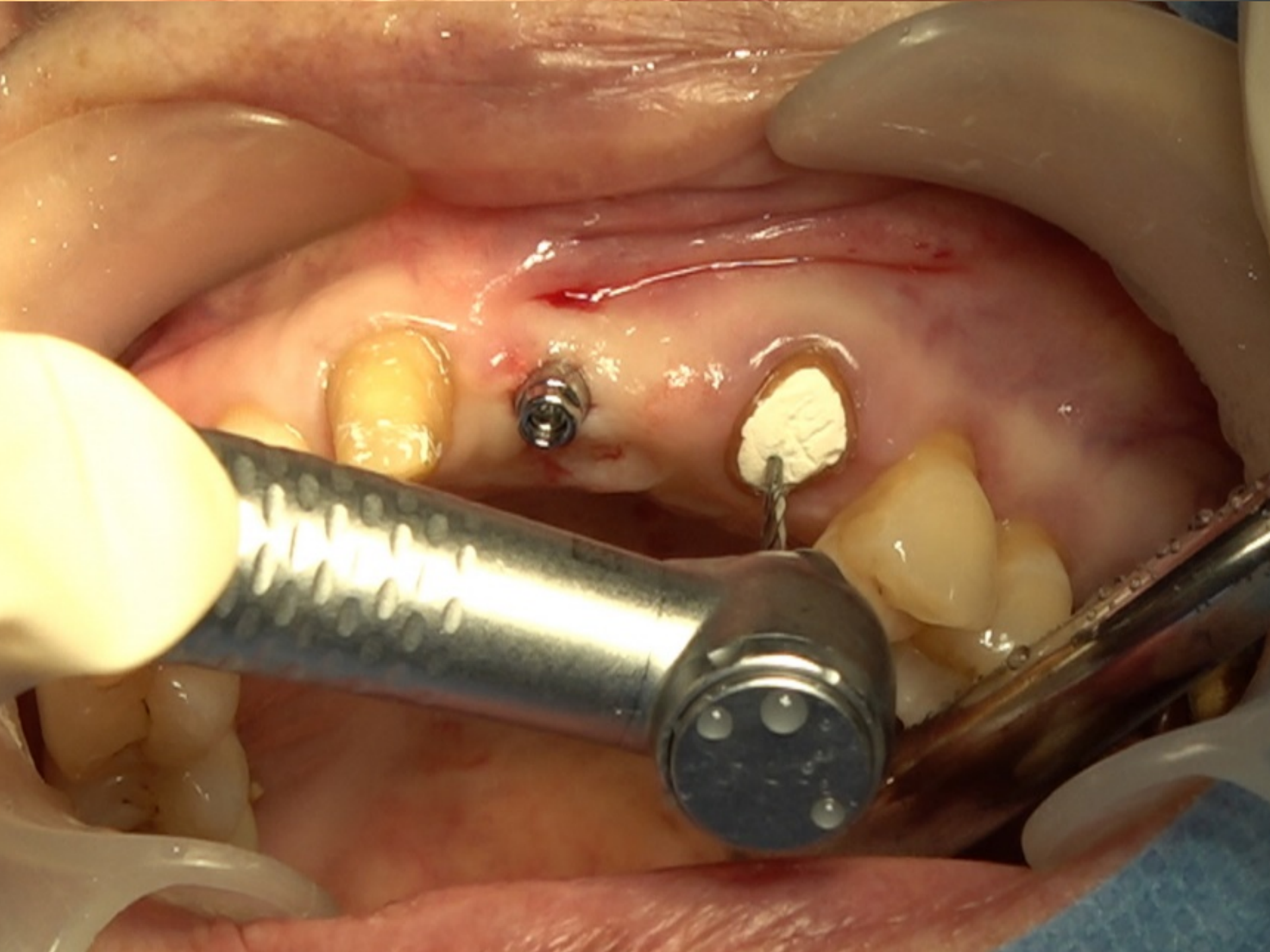
Surgery (2023-09-06)



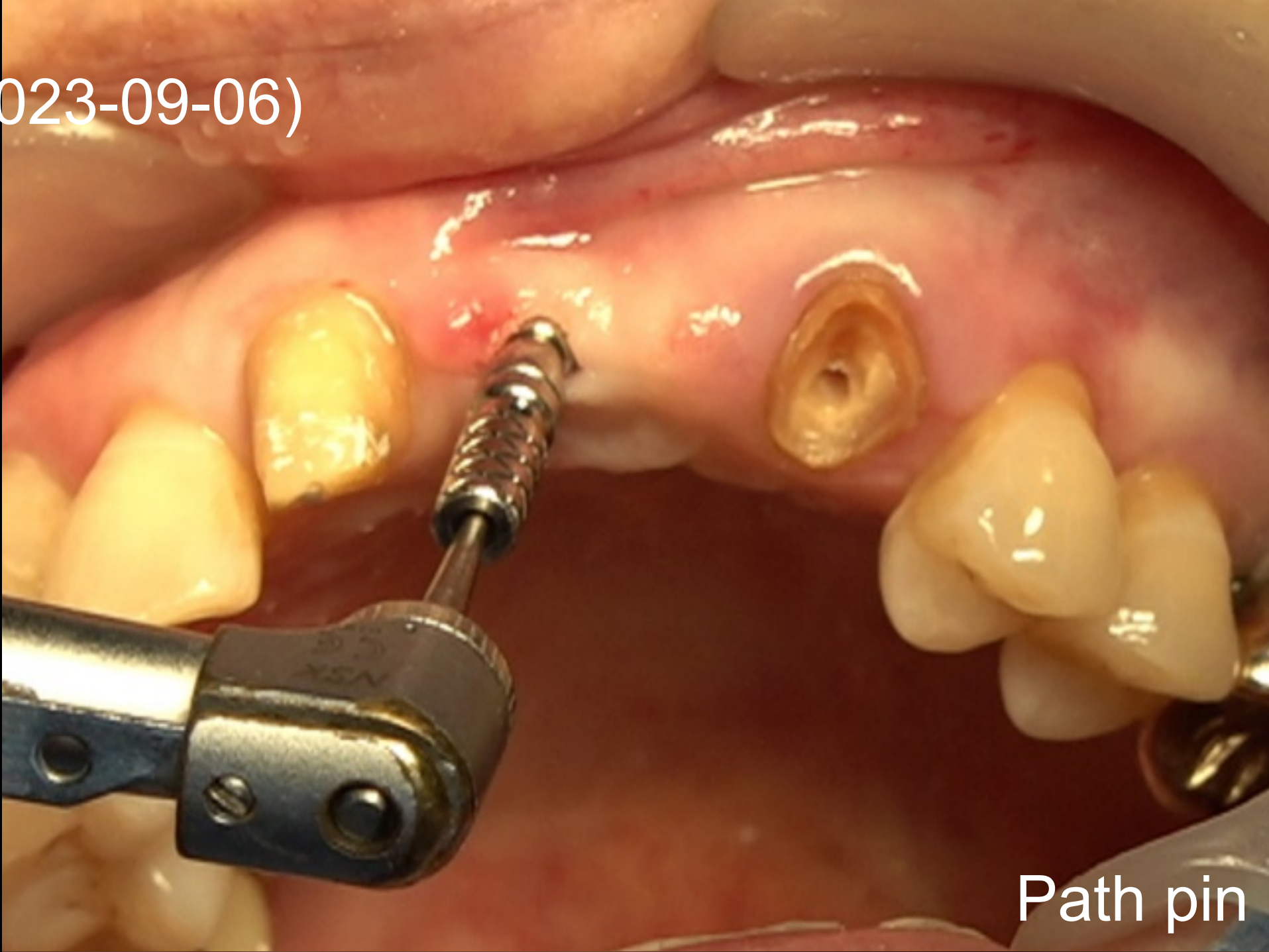
bright TL (Ø3.0 X 11)



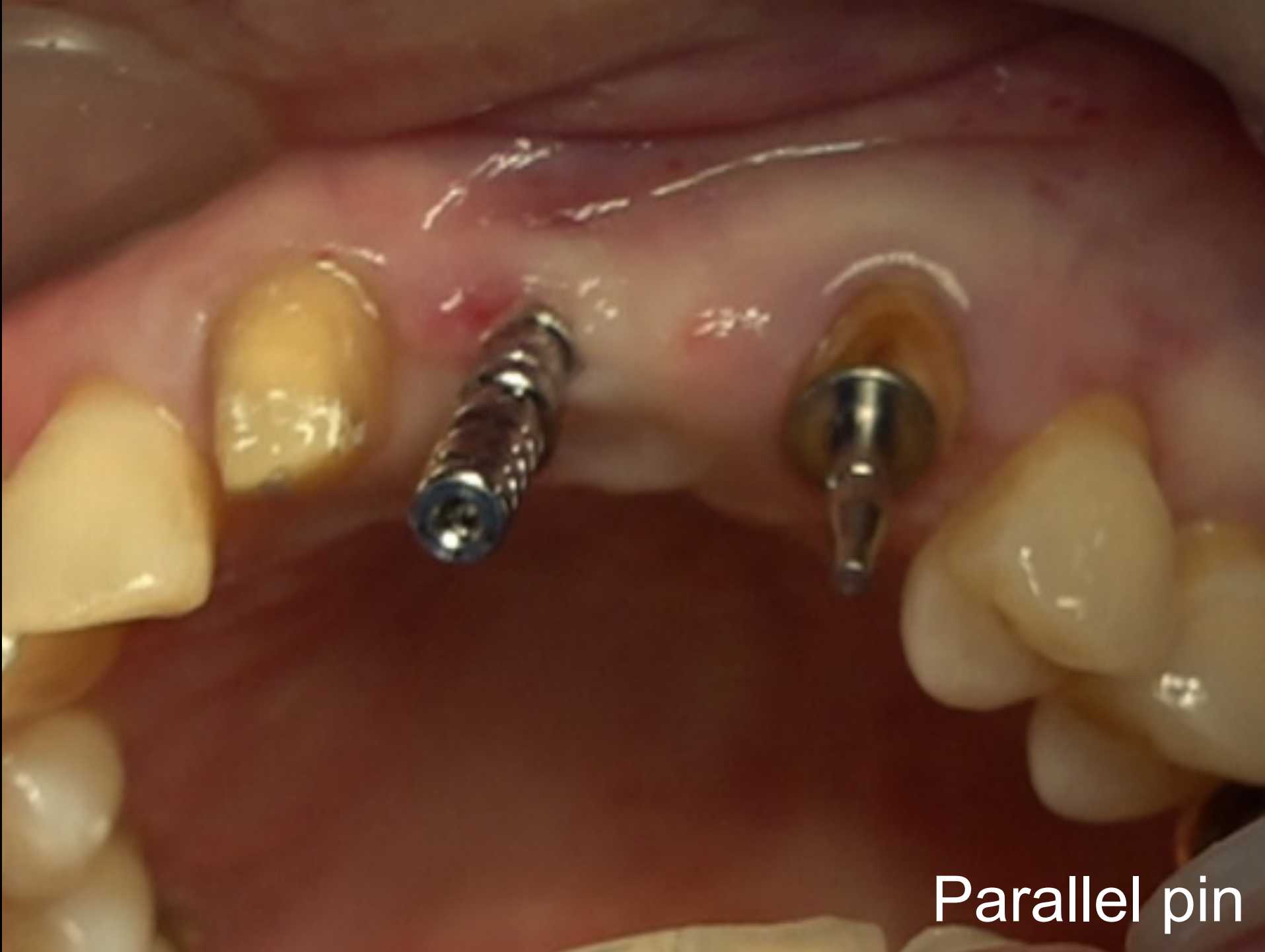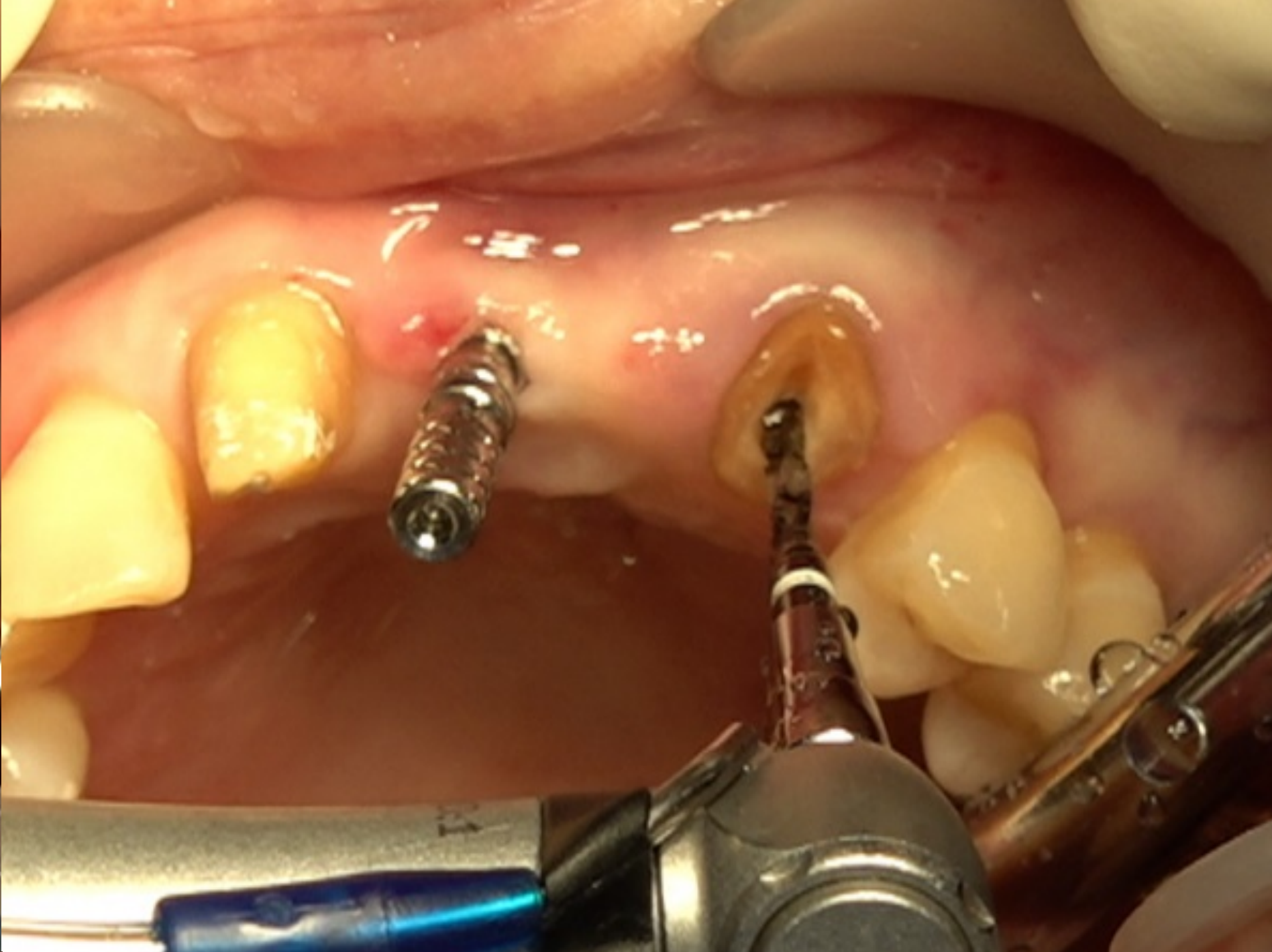The Trust



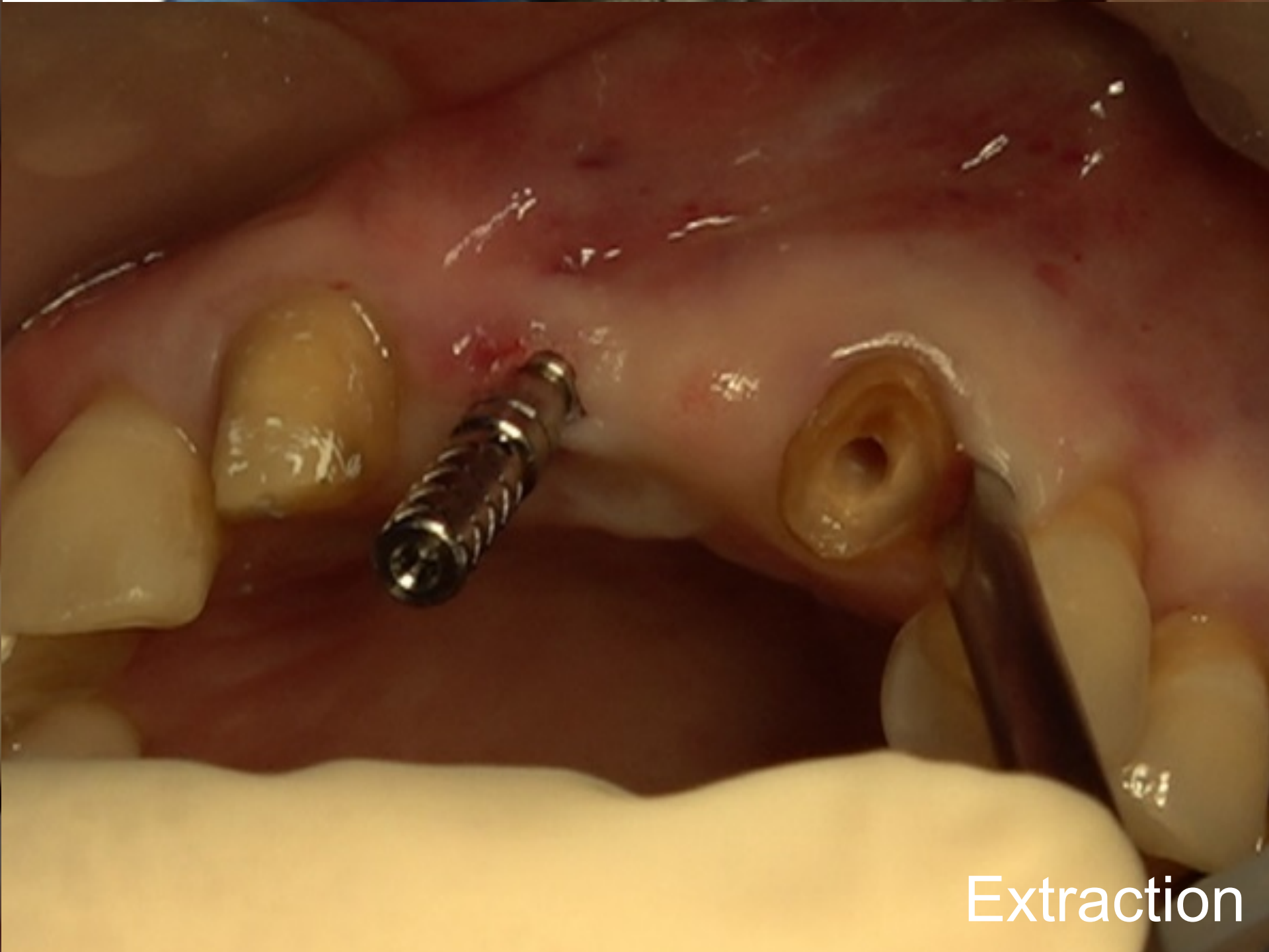
Surgery (2023-09-06)



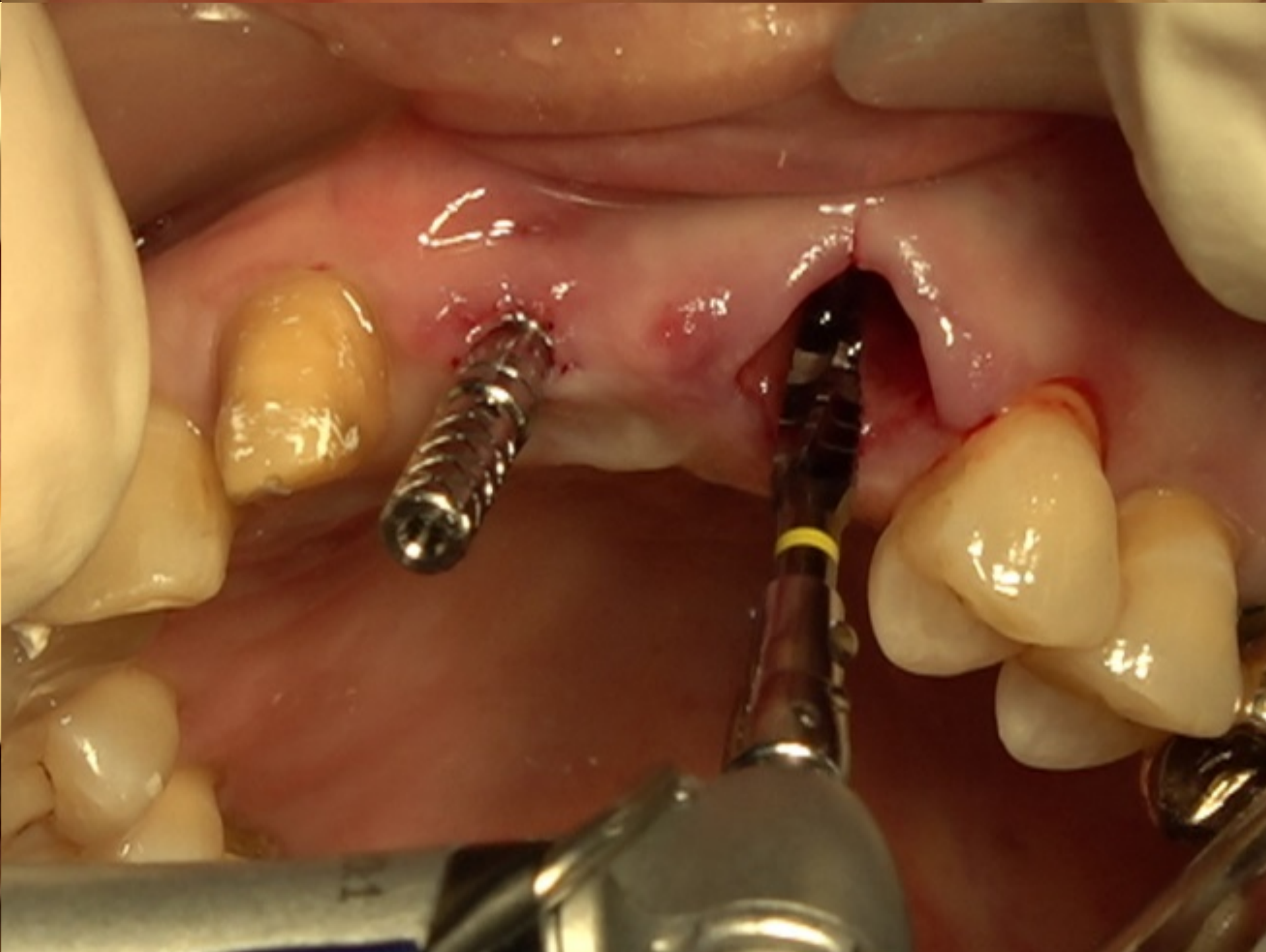
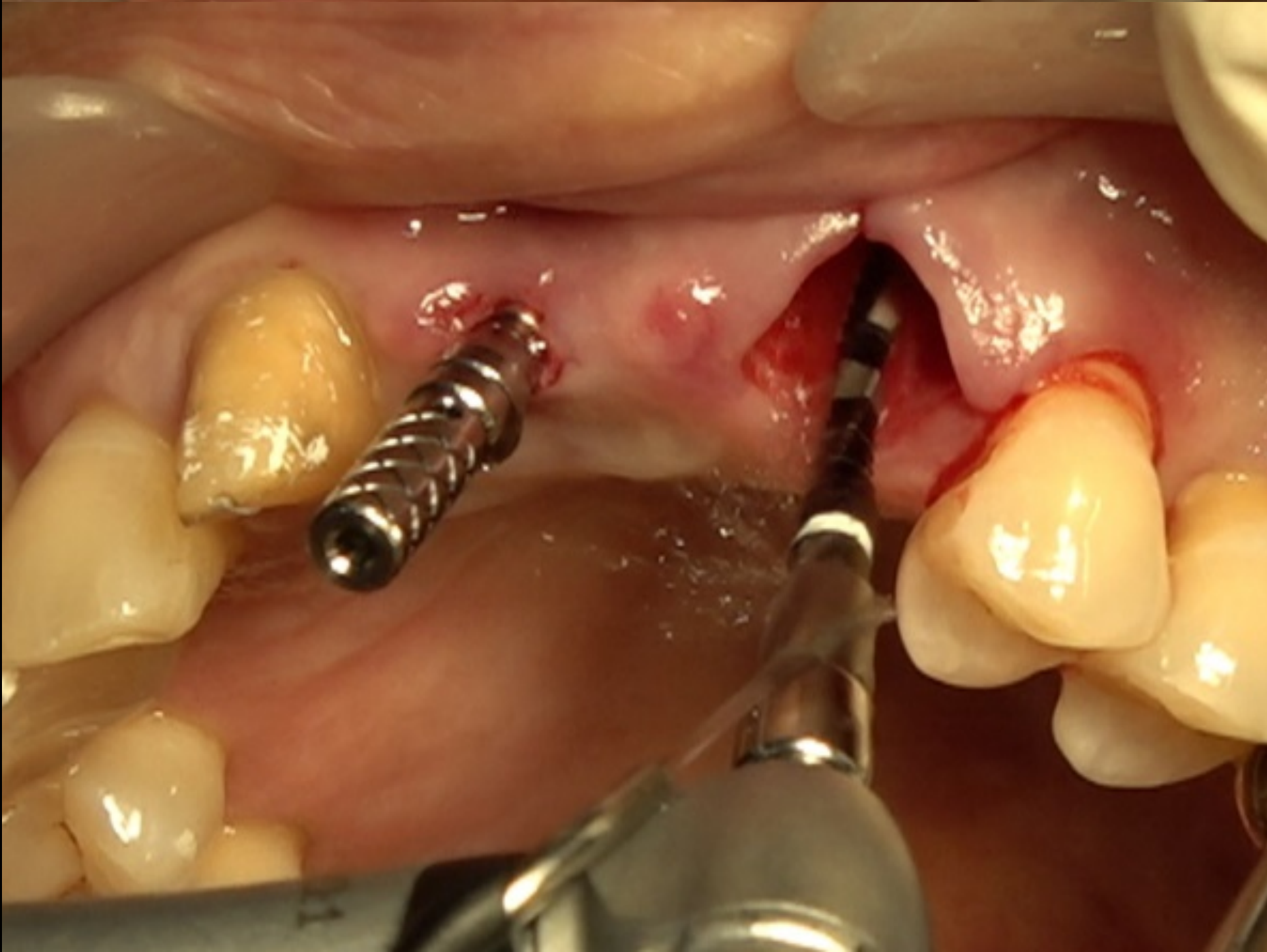
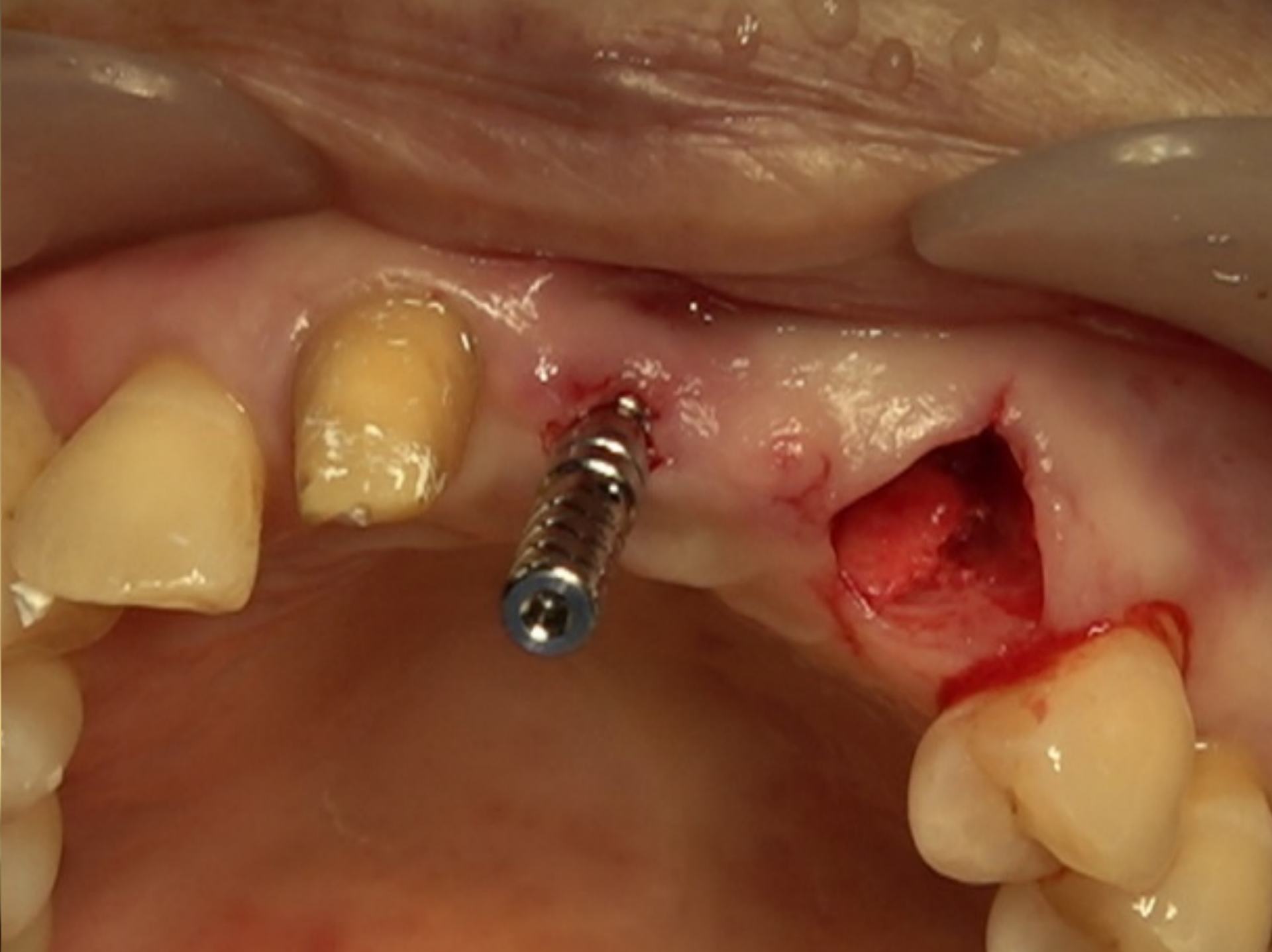
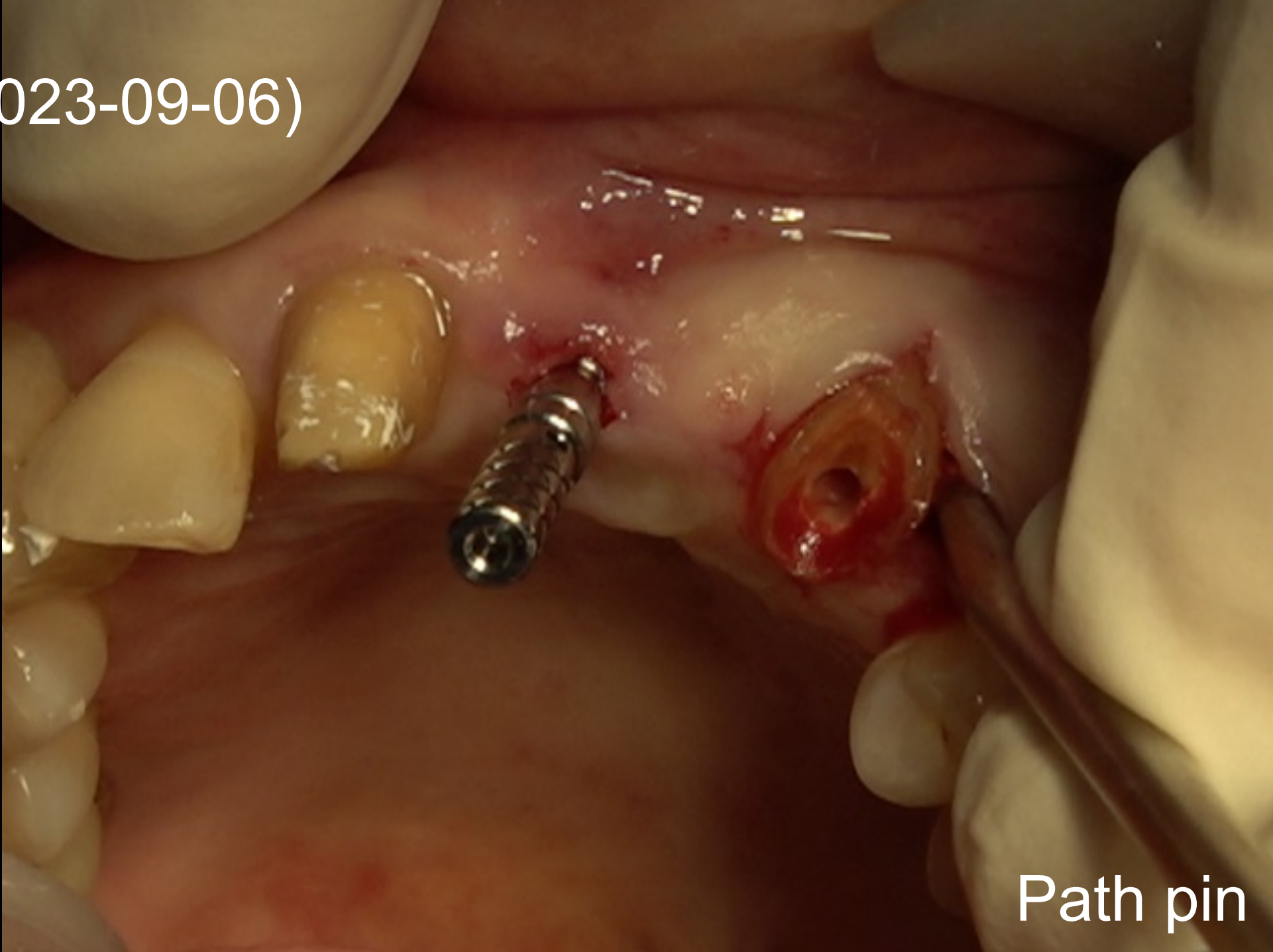
Path pin



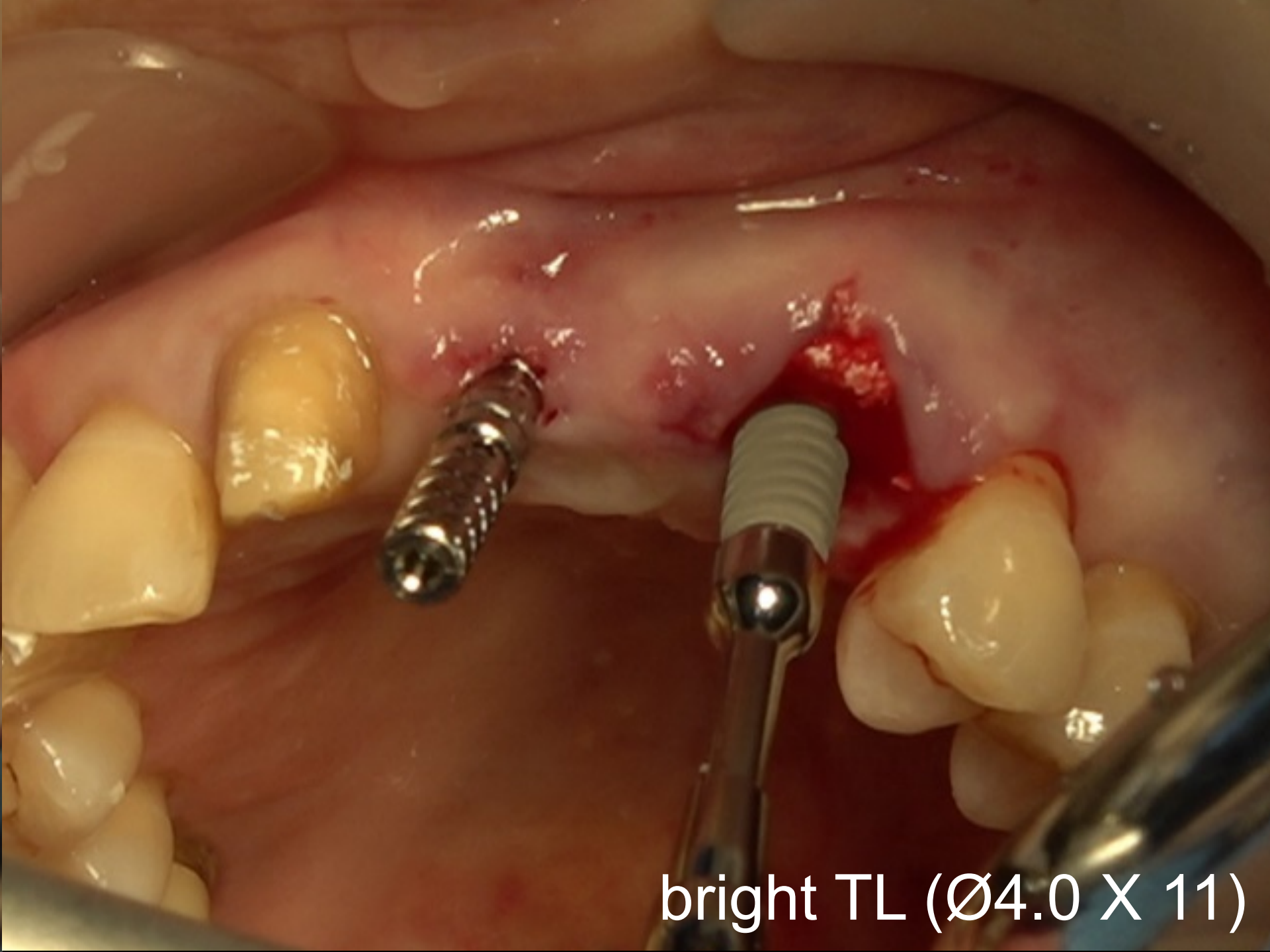
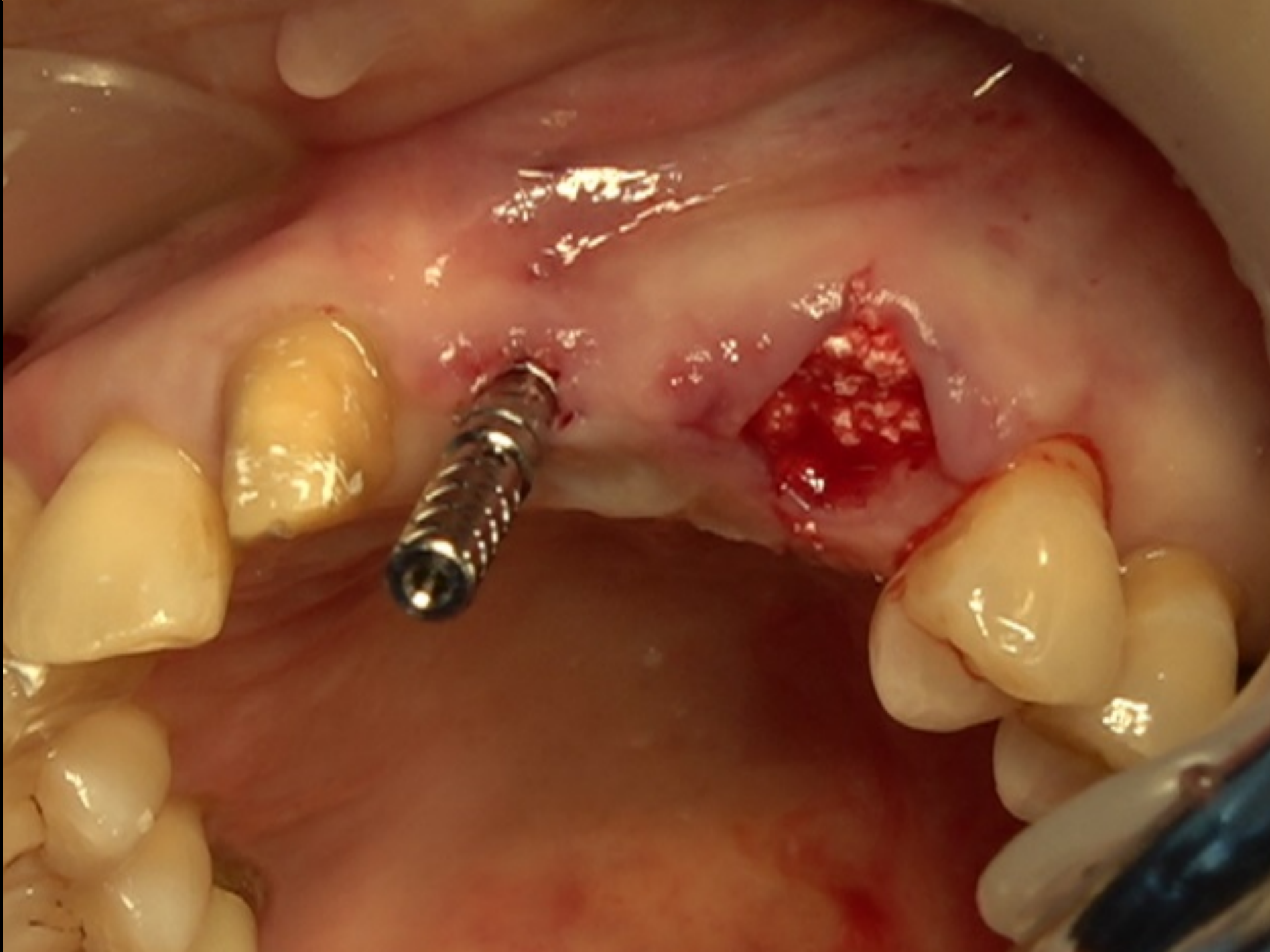
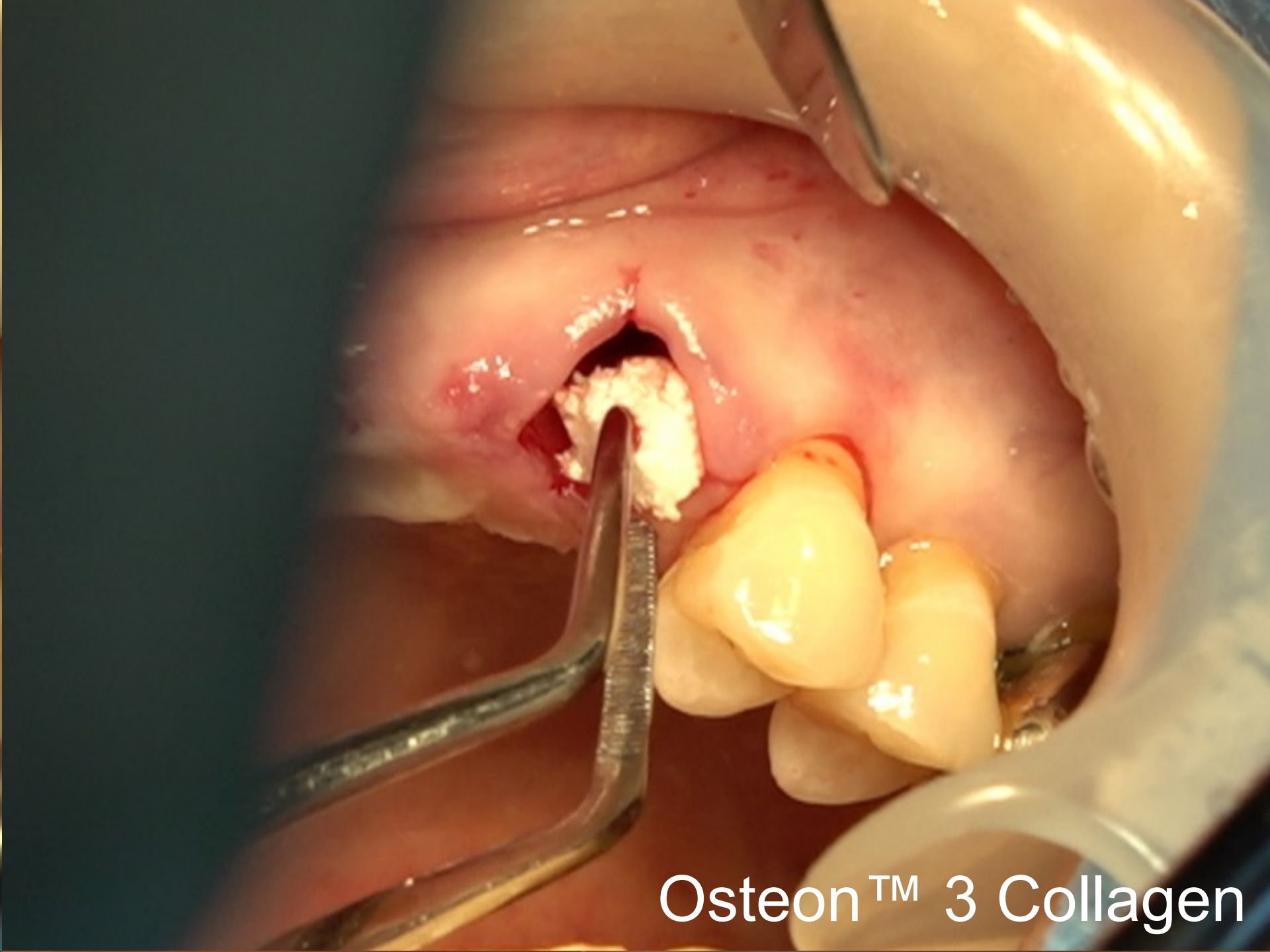
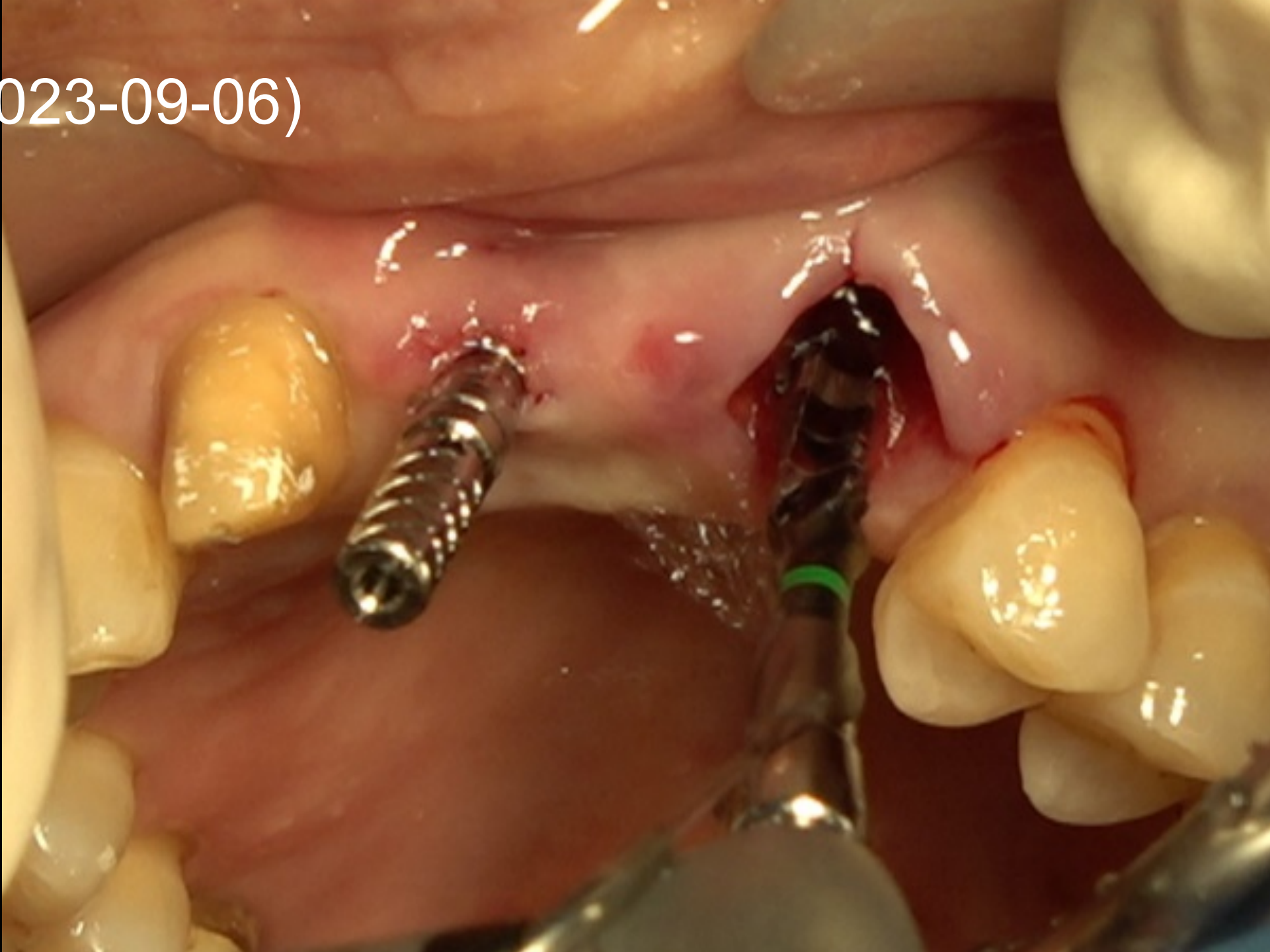Parallel pin



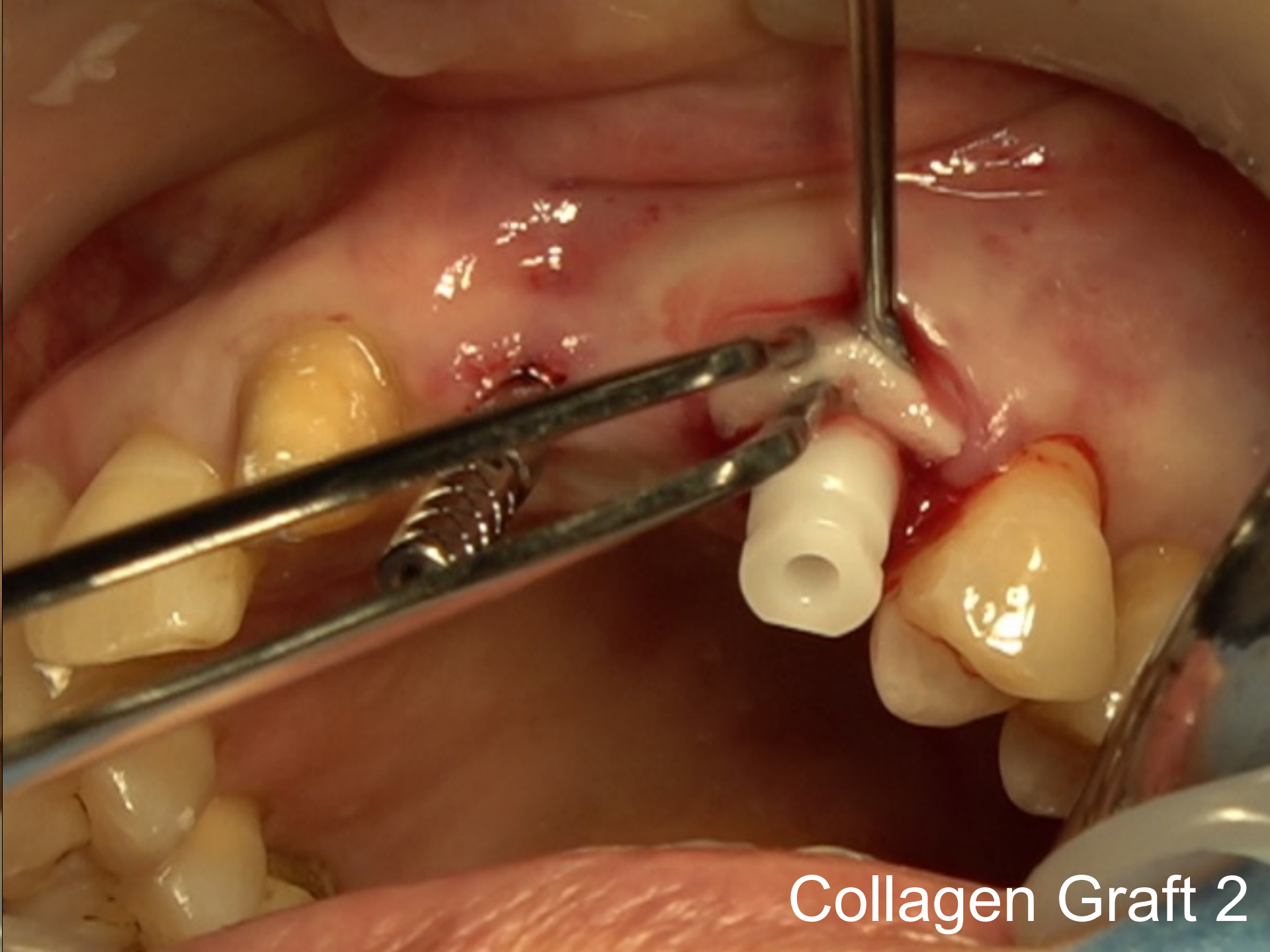
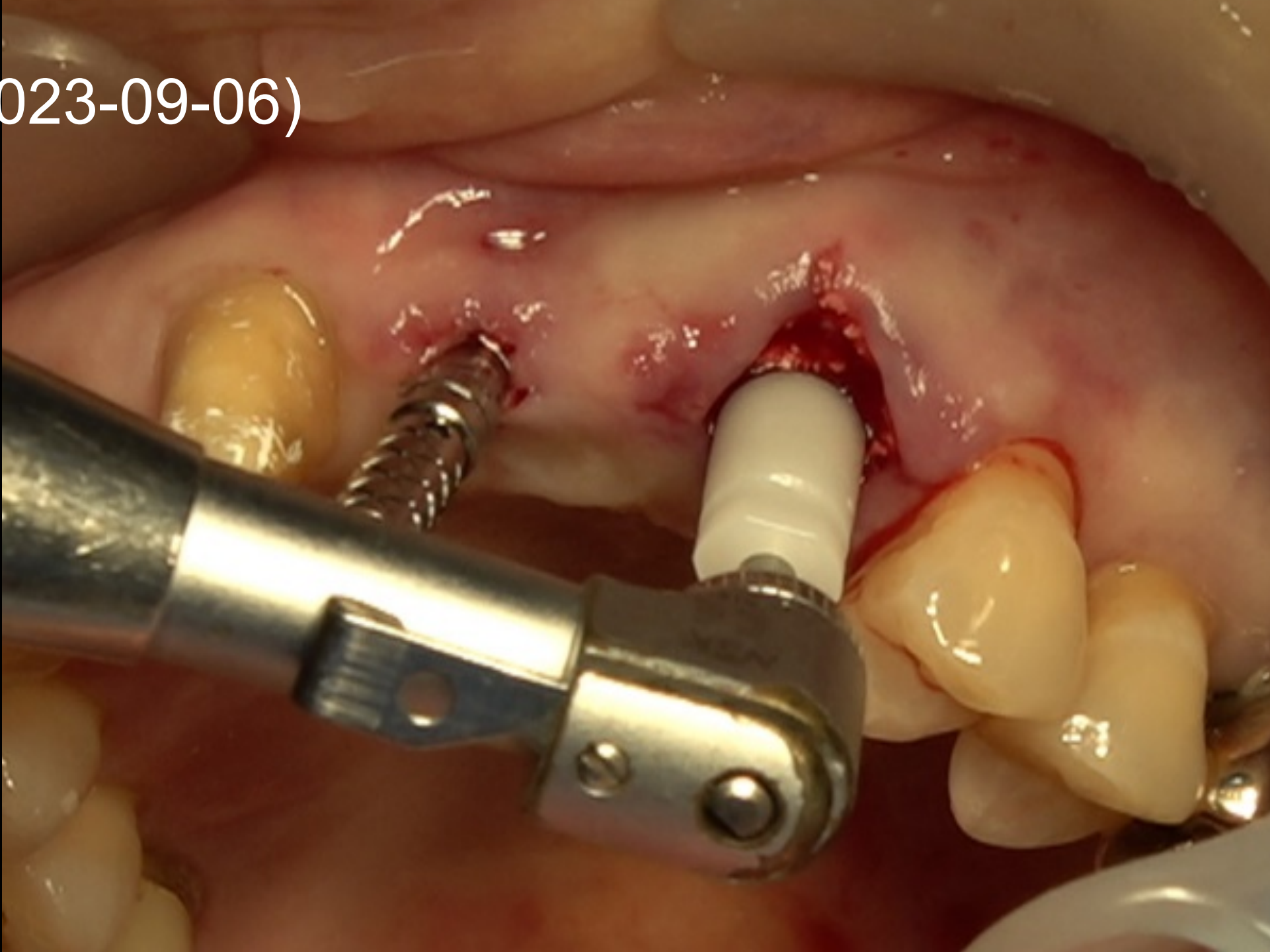
Extraction



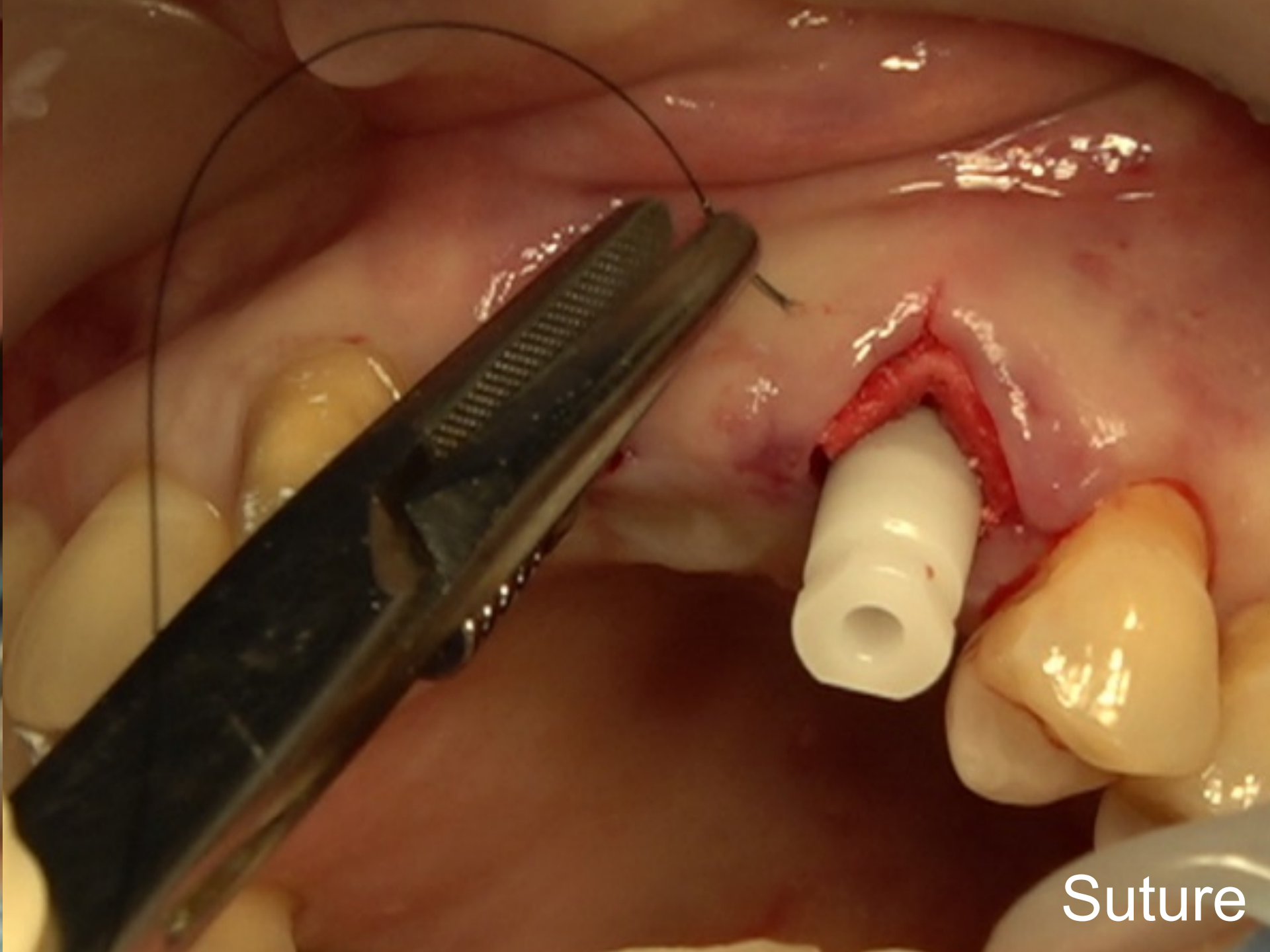
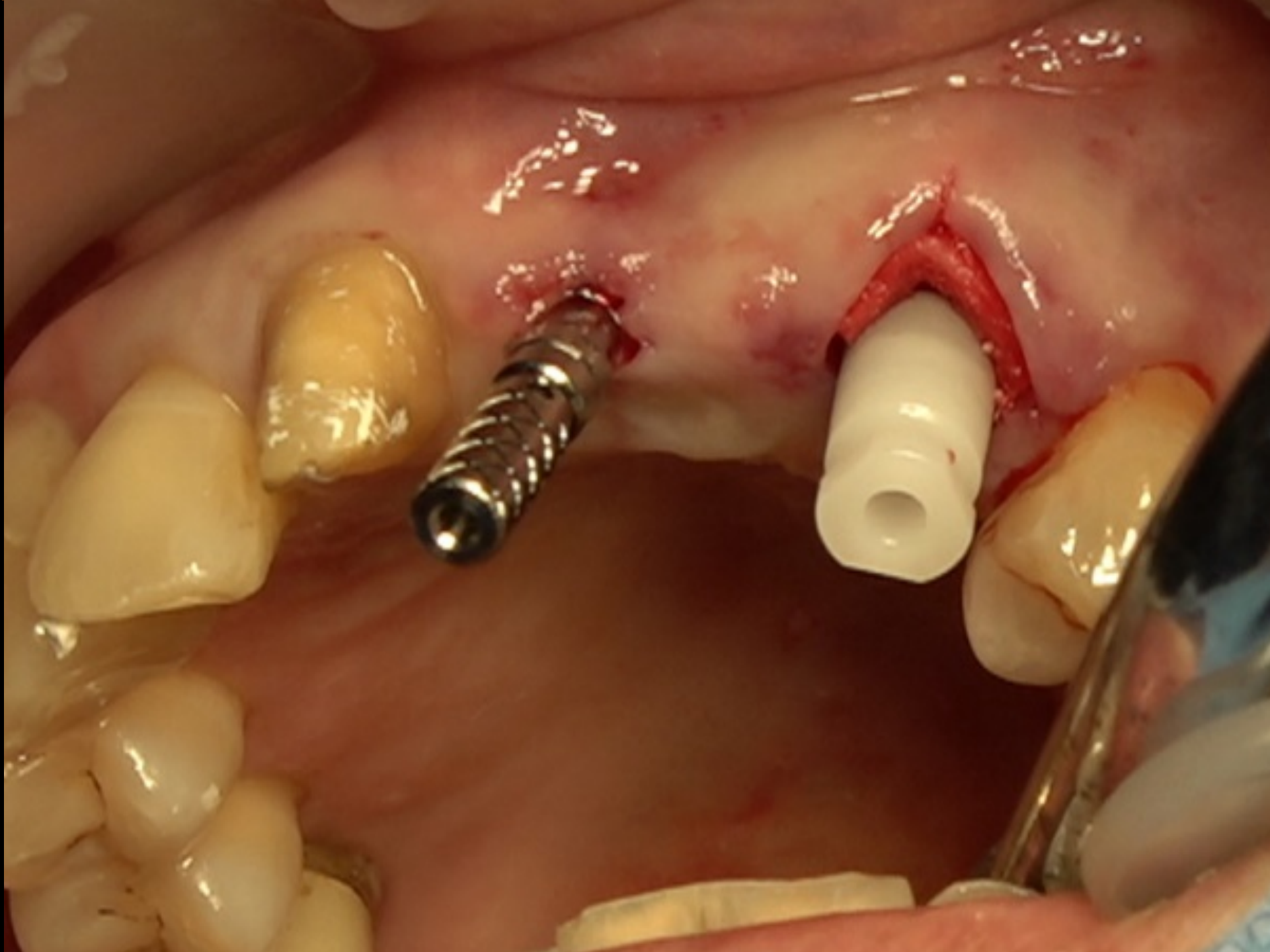
Surgery (2023-09-06)



Surgery (2023-09-06)

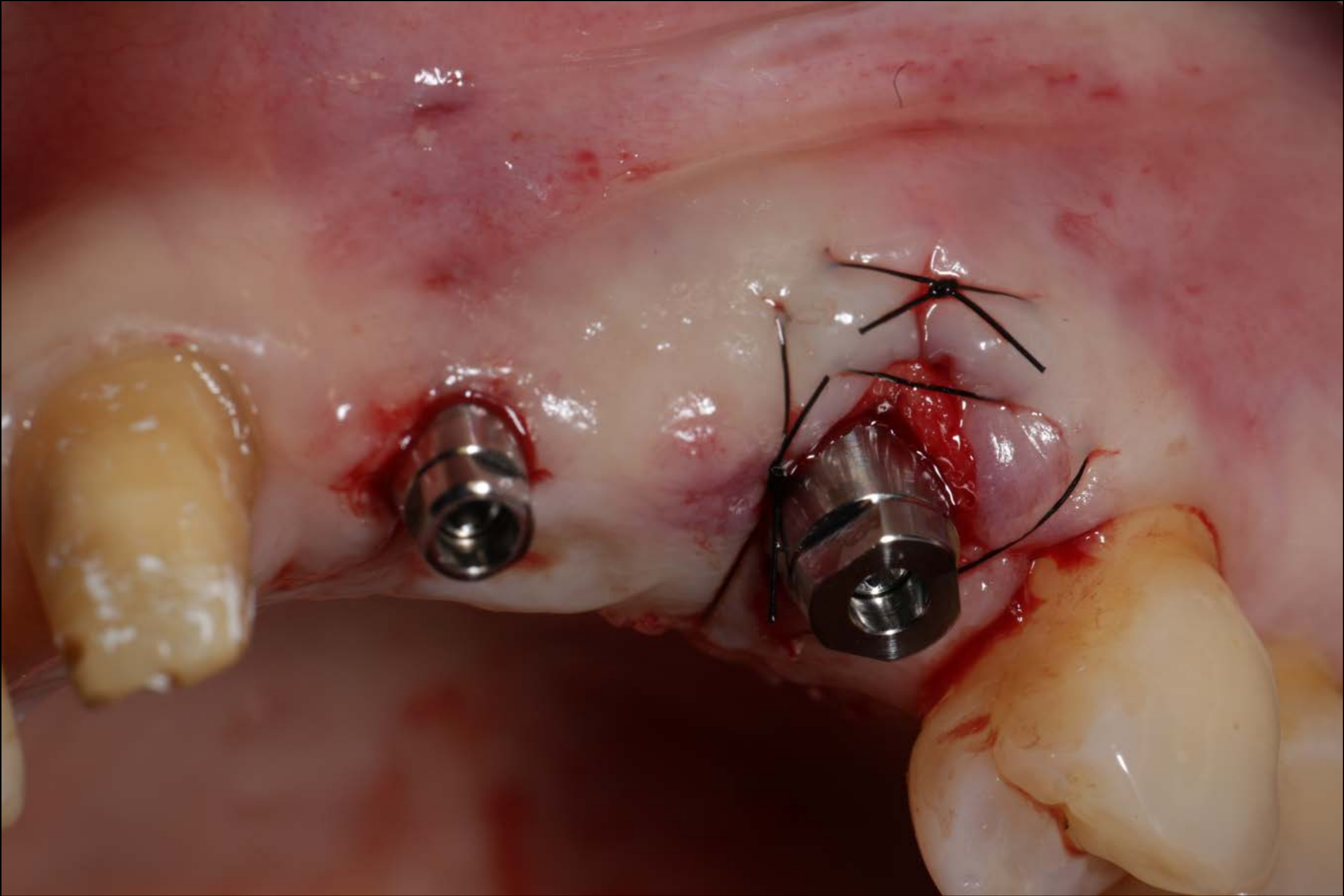

Collagen Graft 2

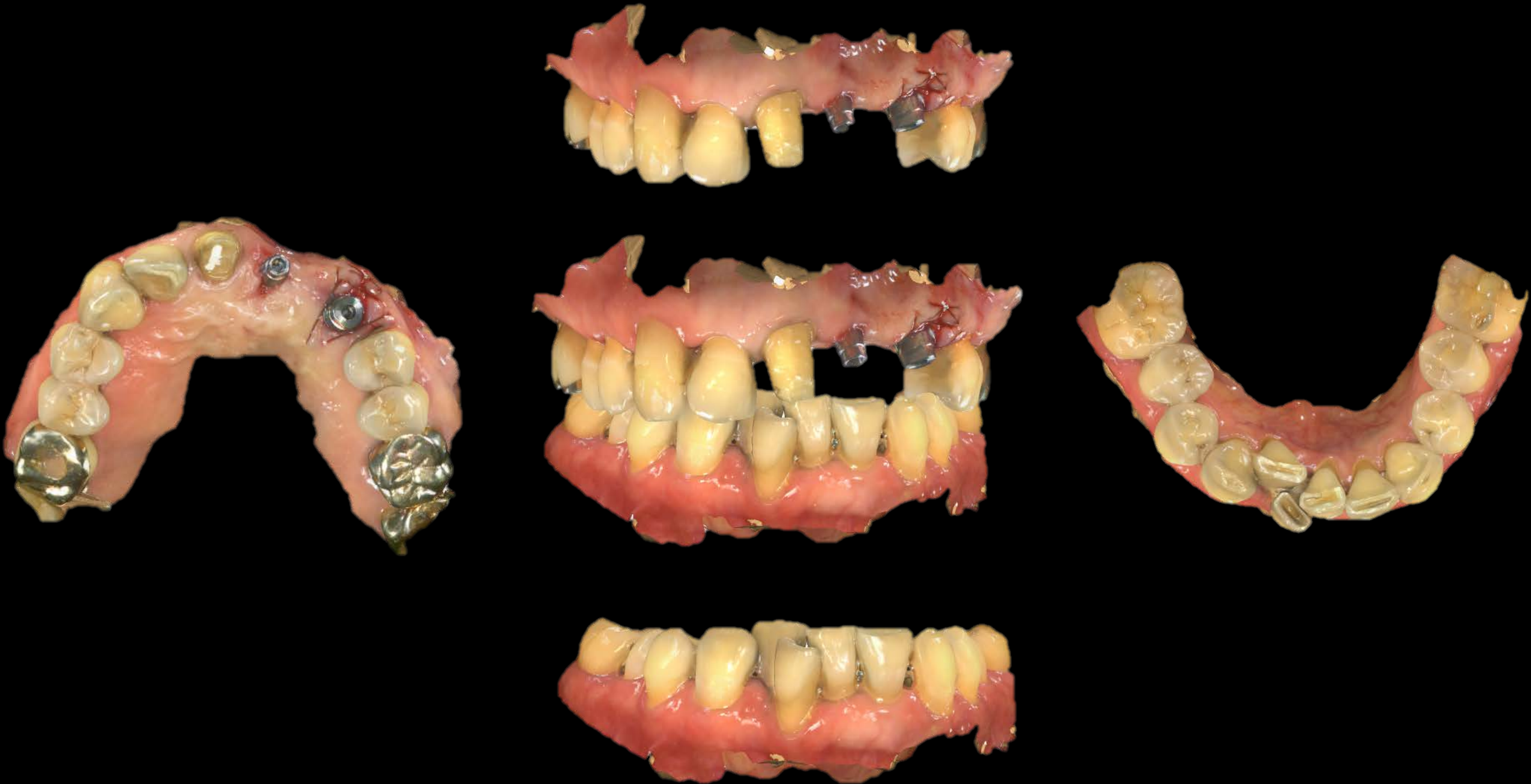

Suture

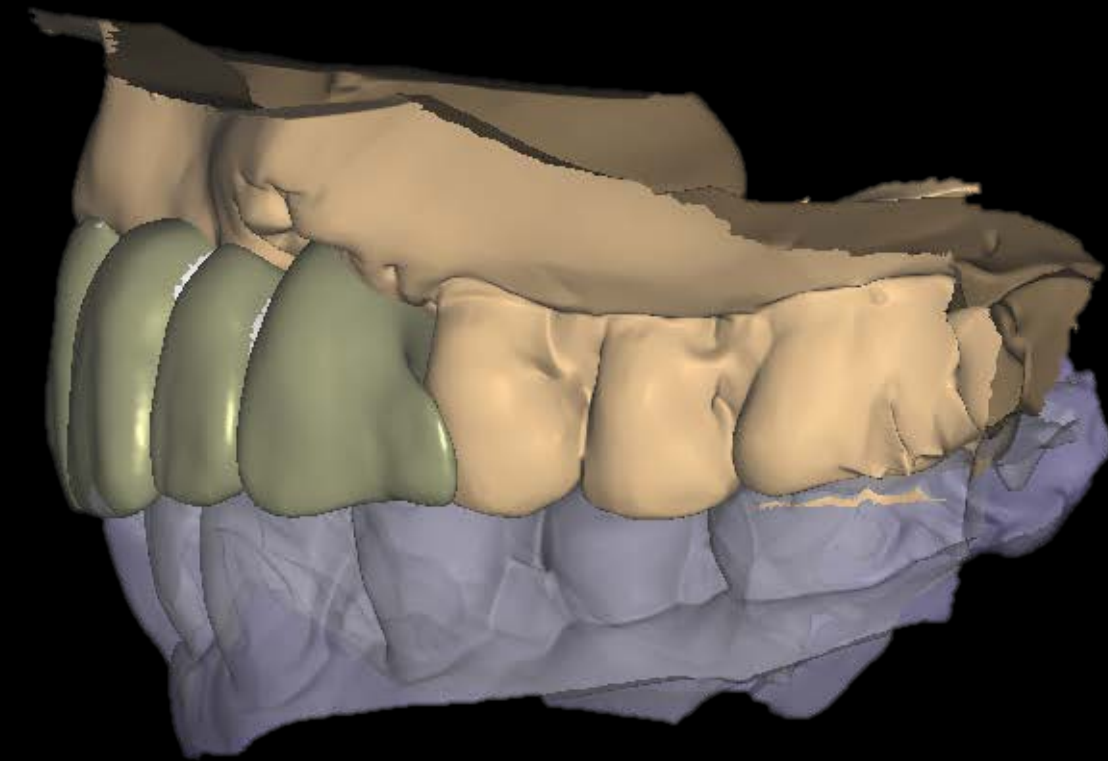
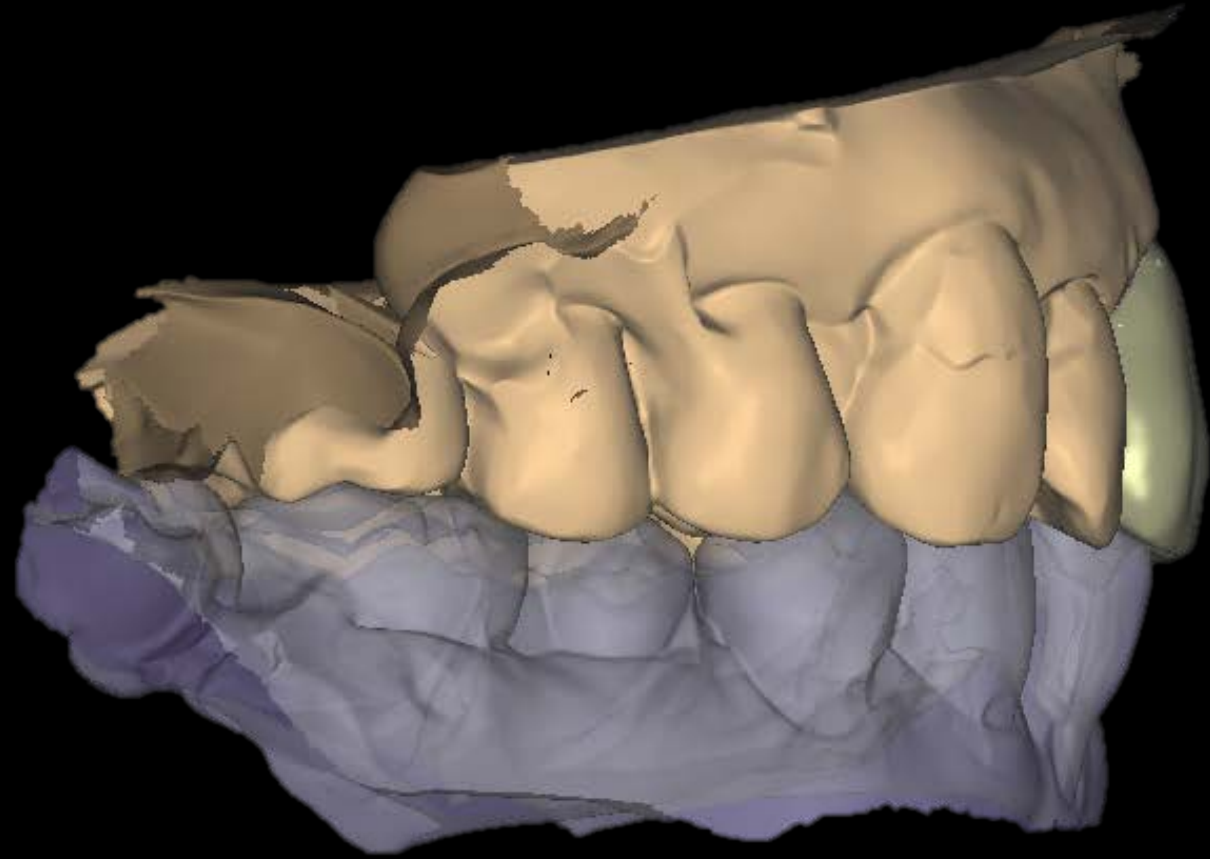
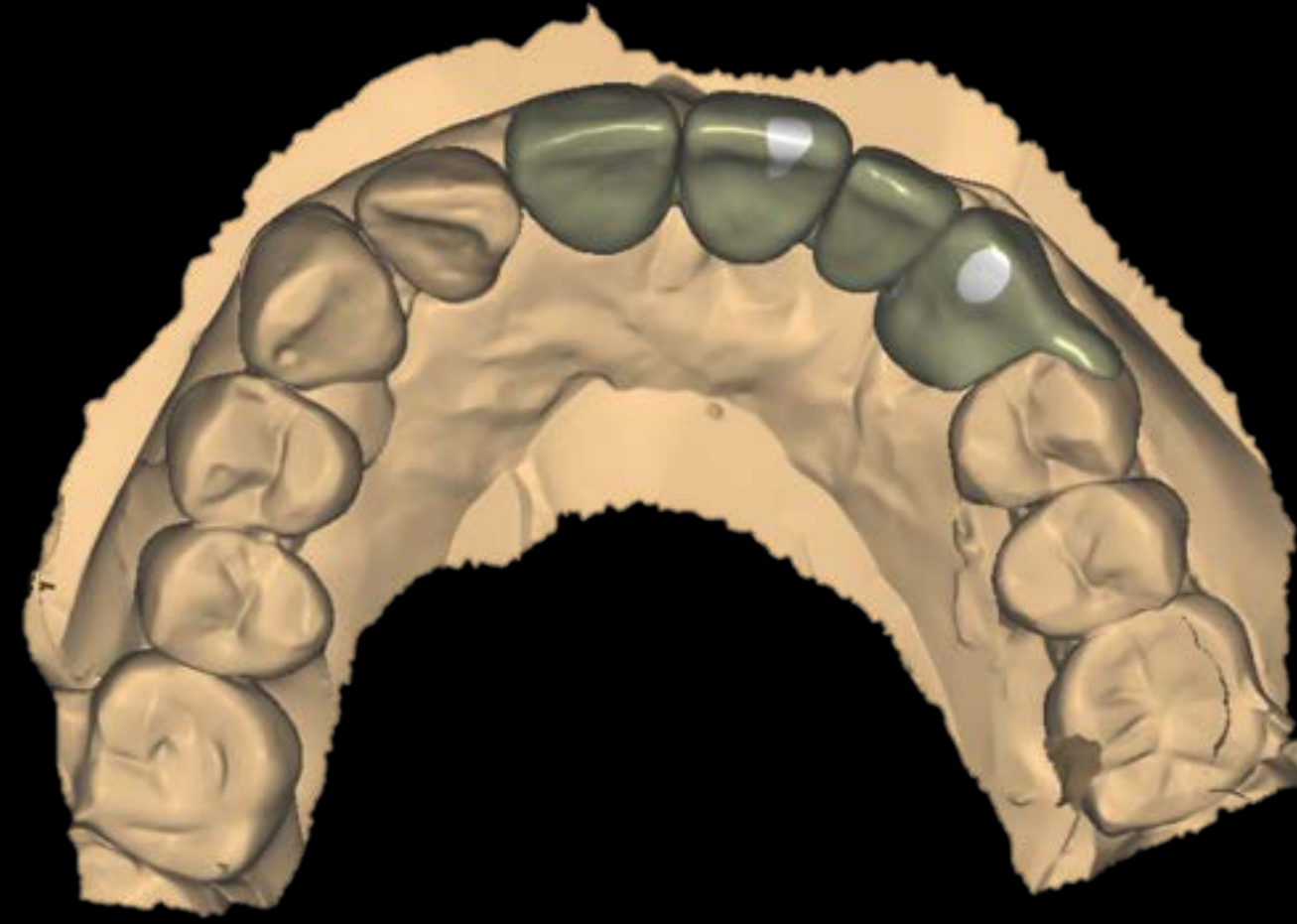
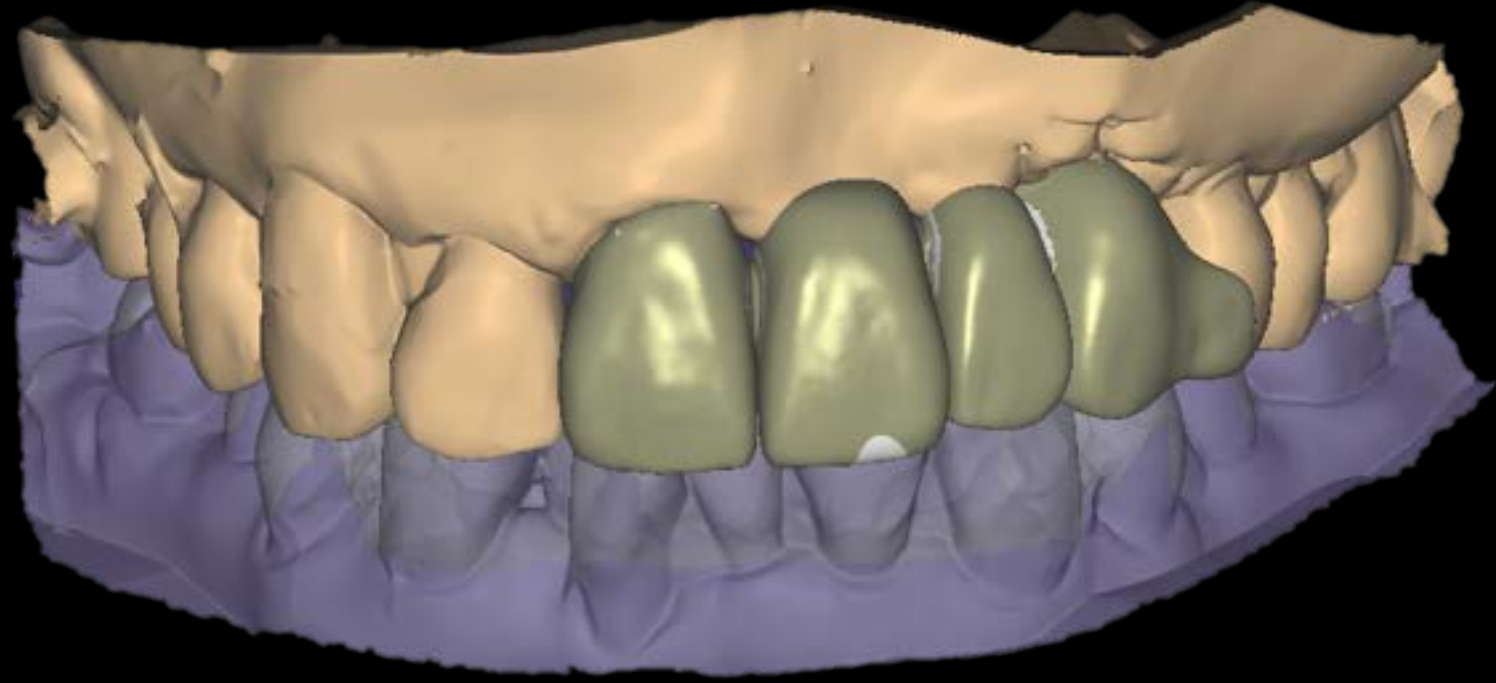
Post-op (2023-09-06)



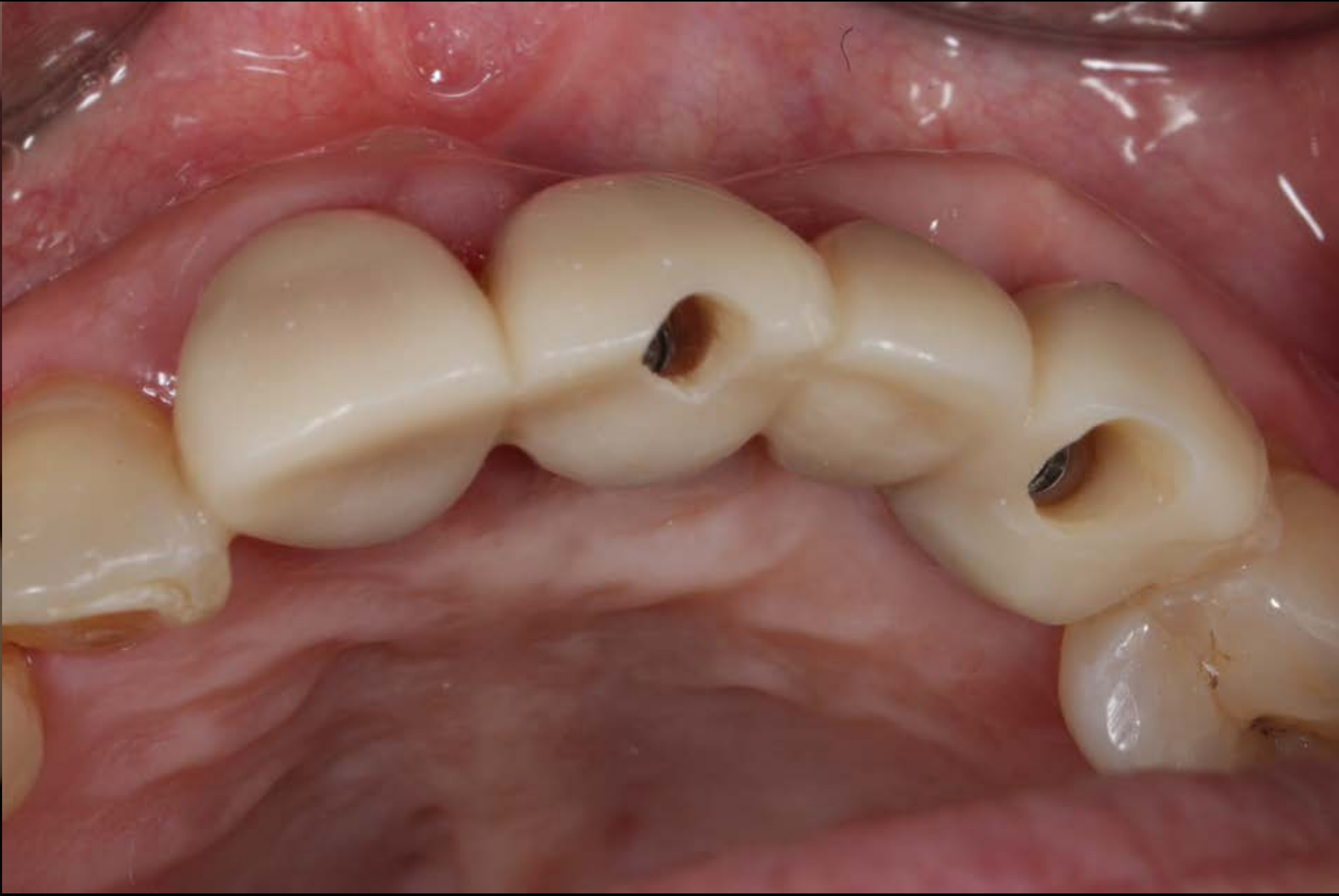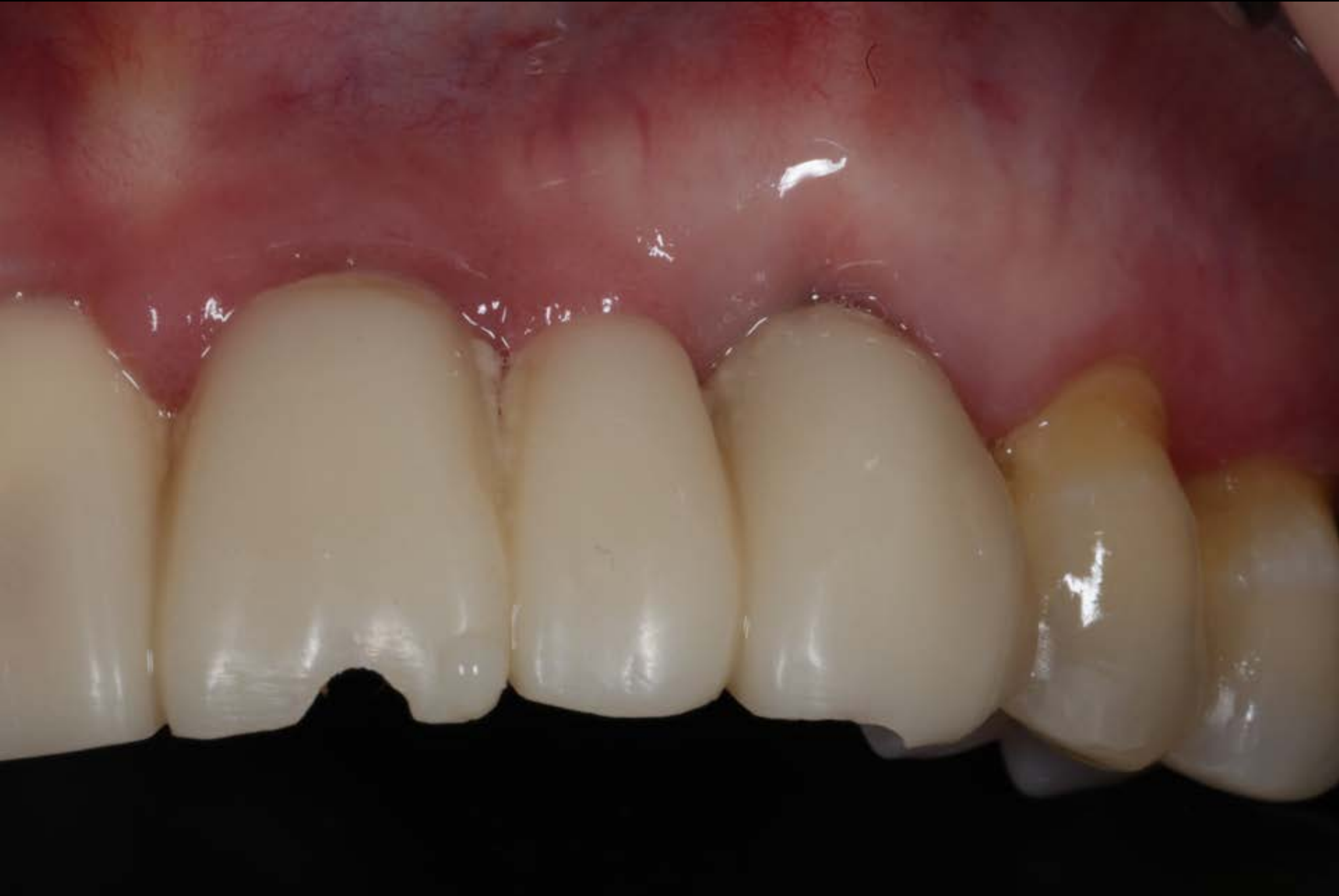Intra-oral scanning



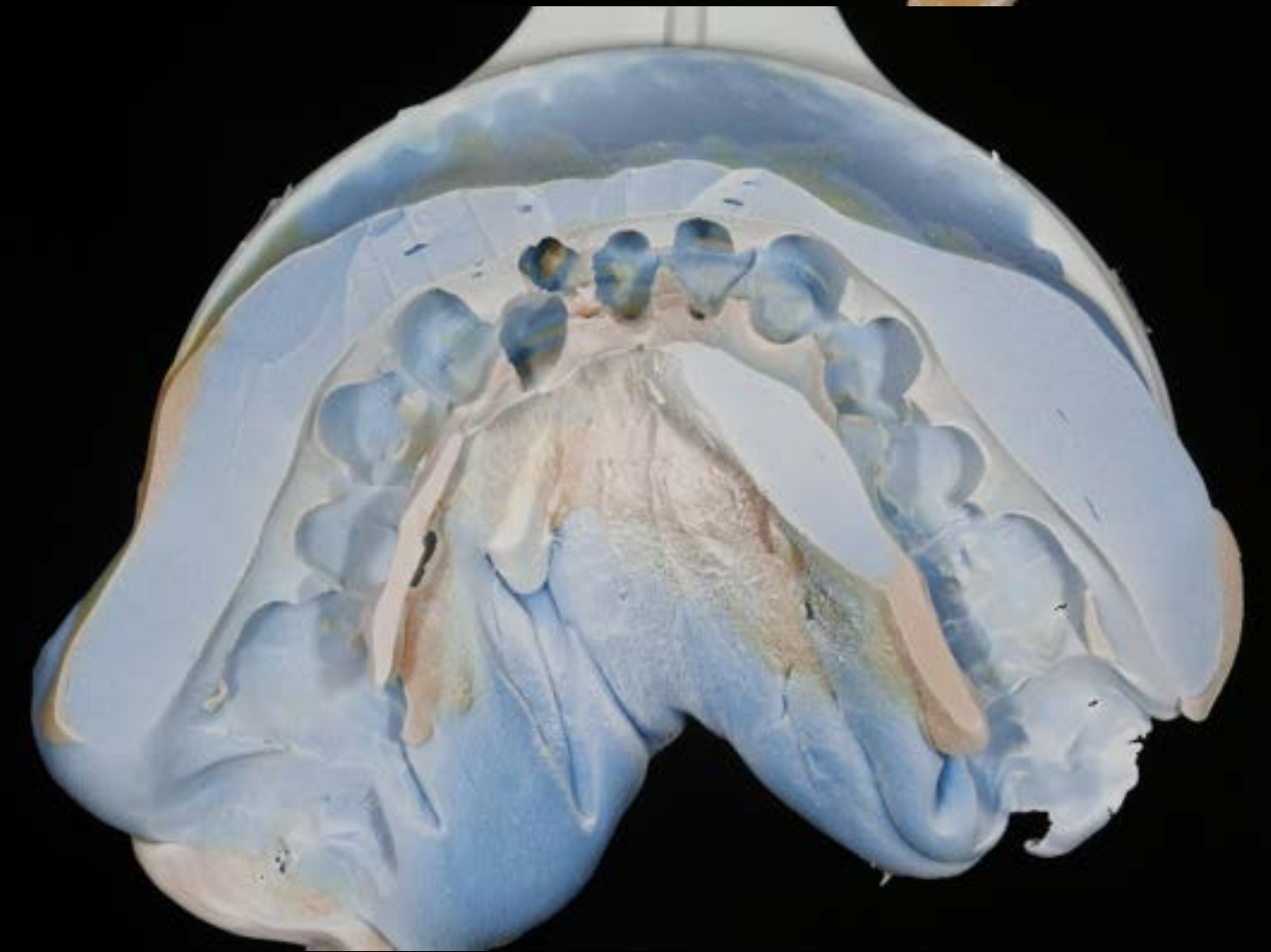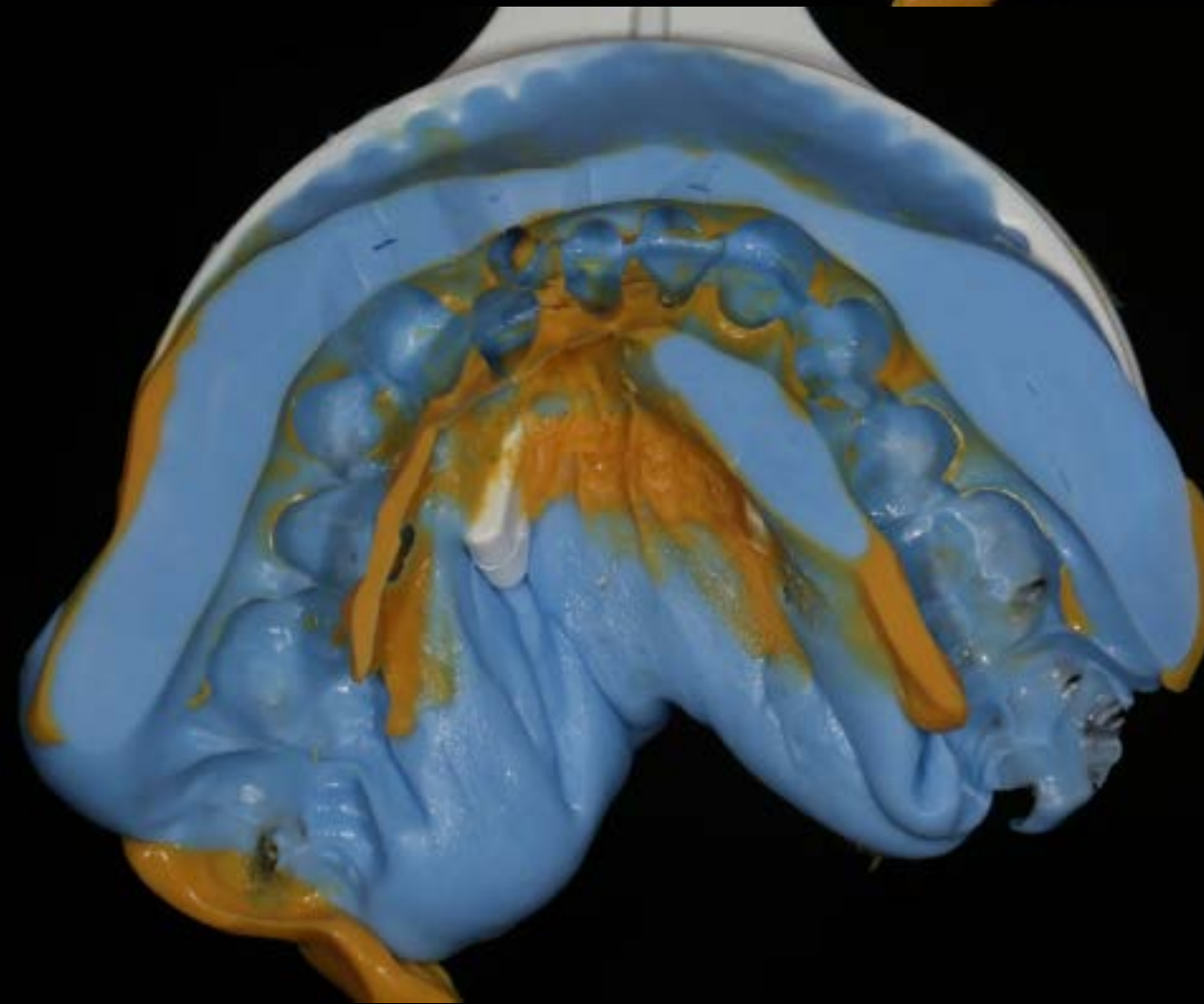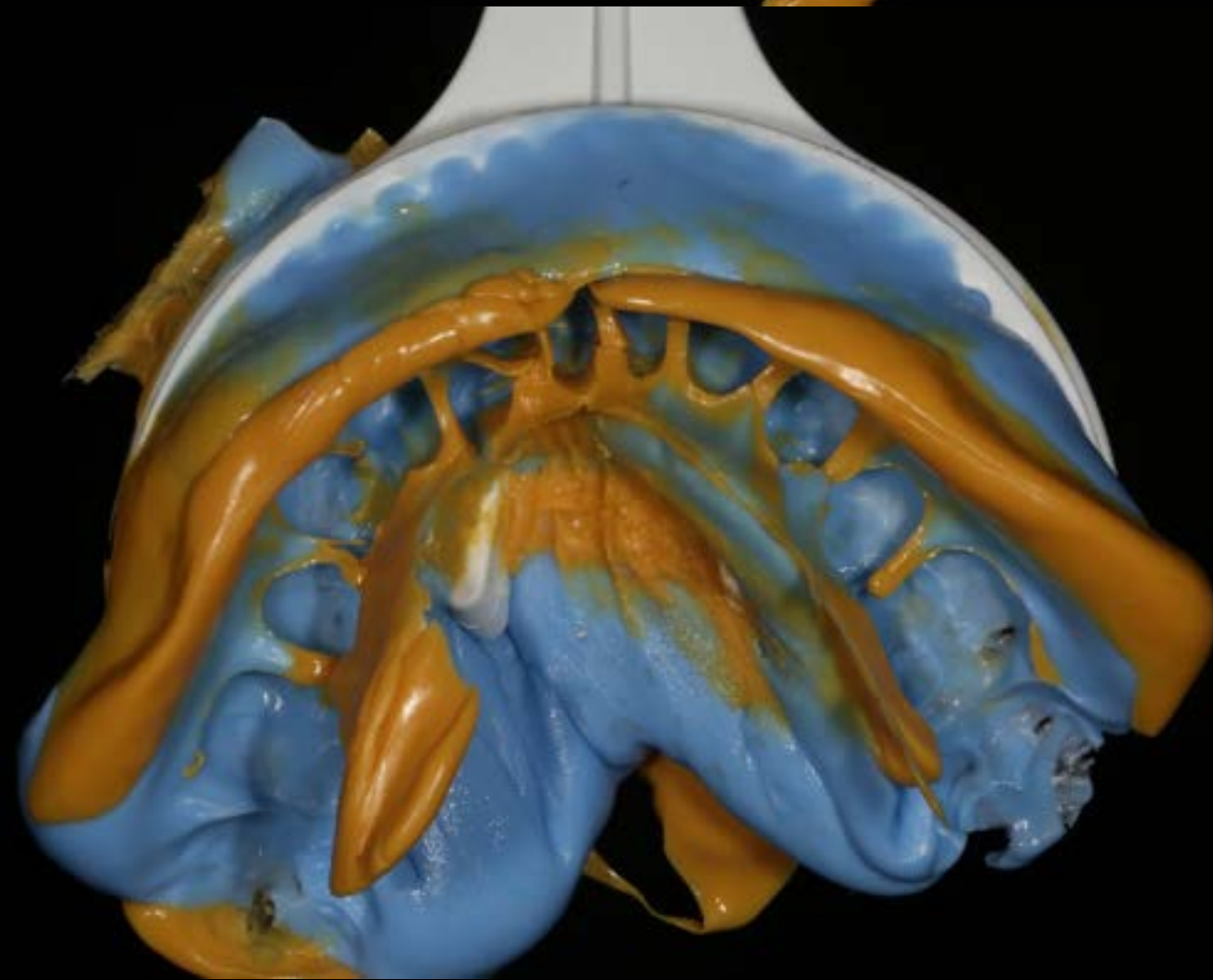
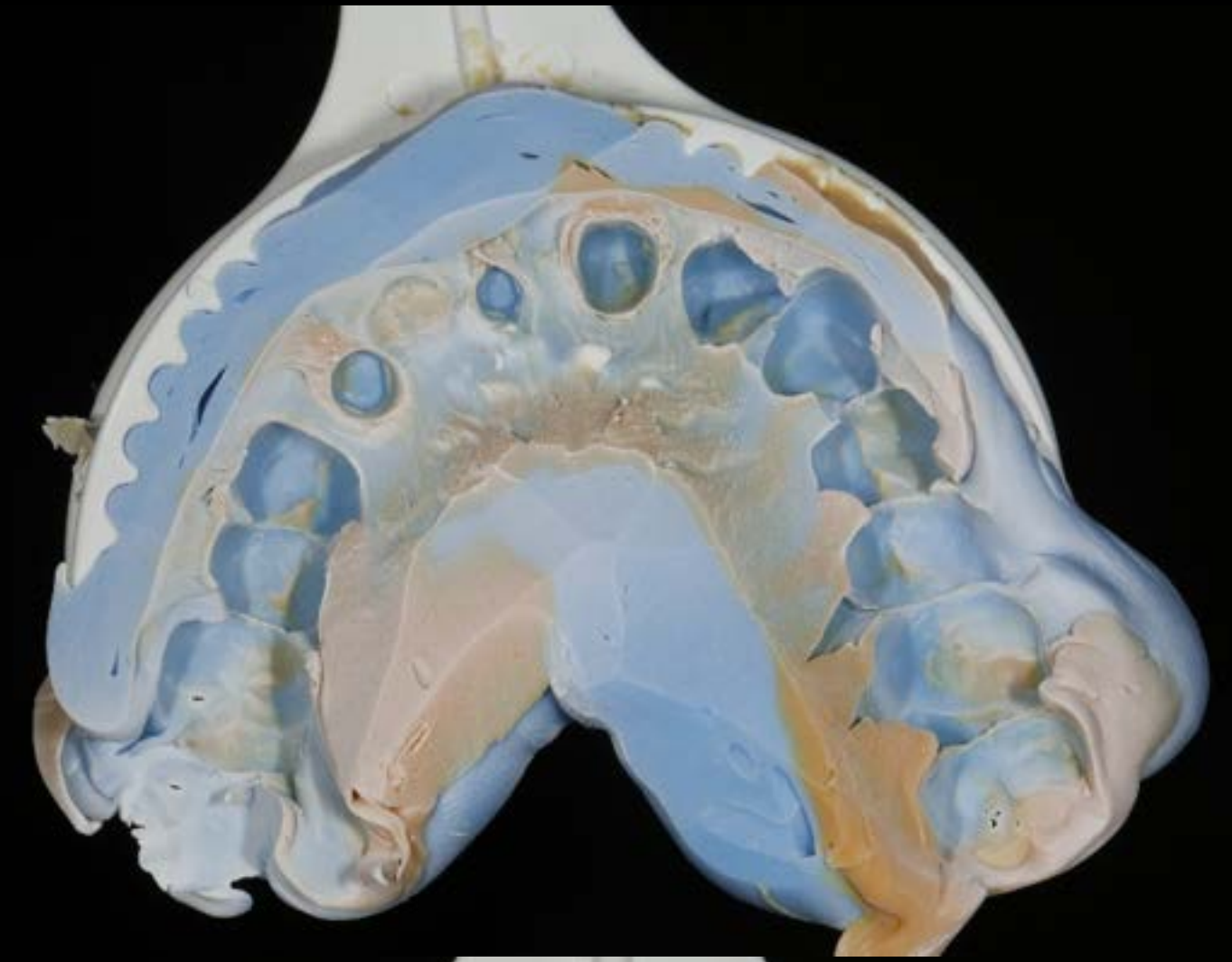
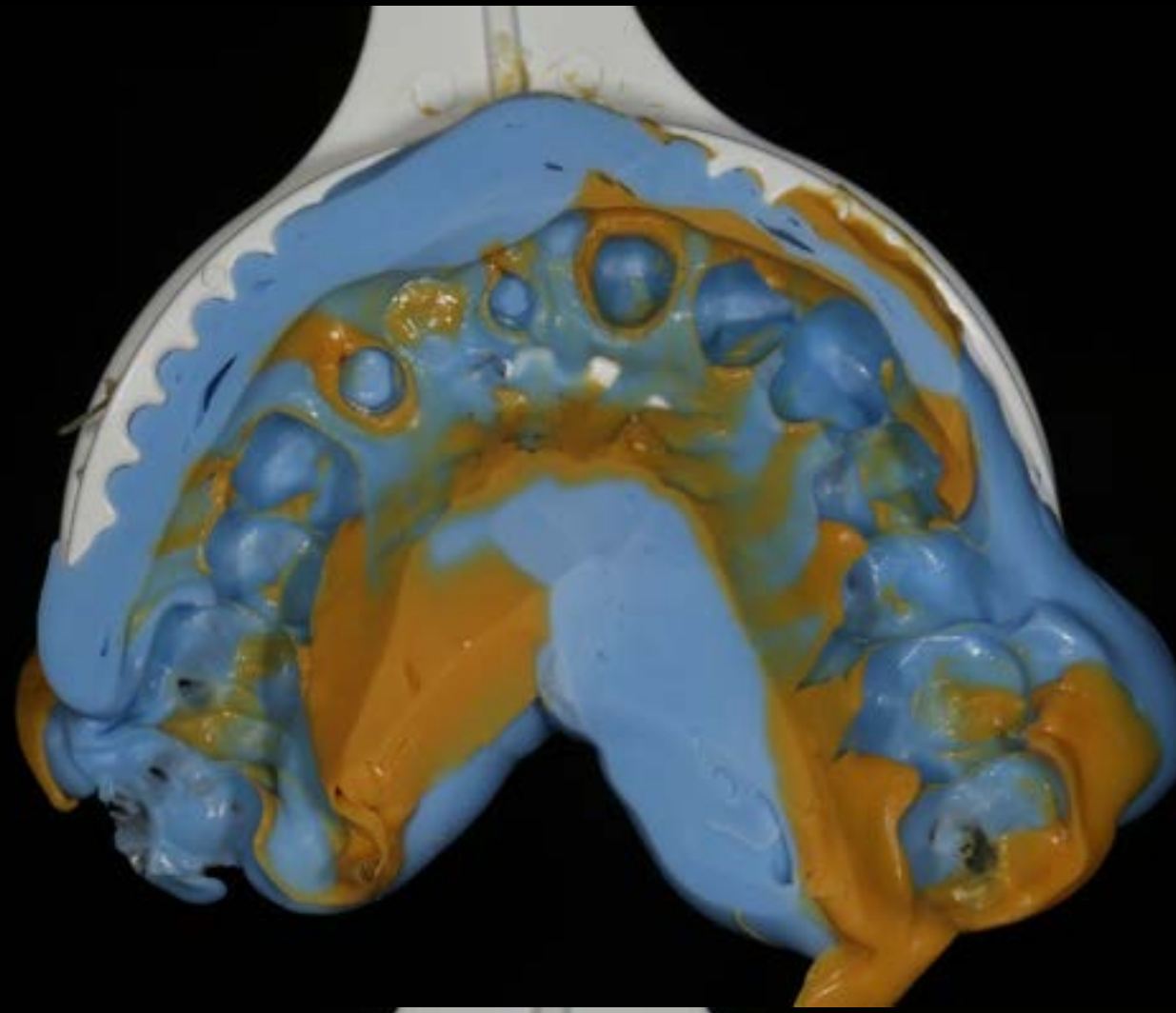
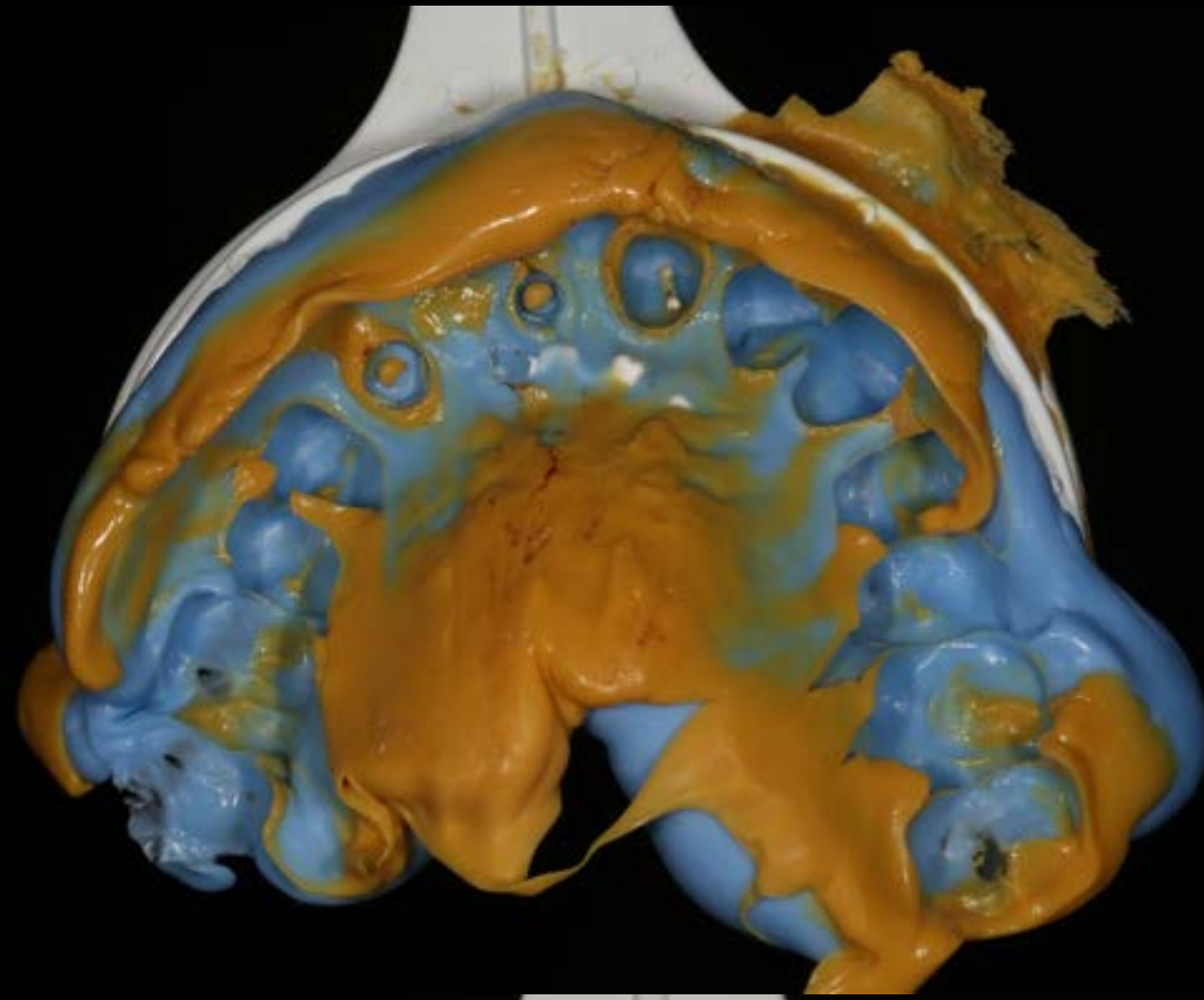
CAD (Temporary)



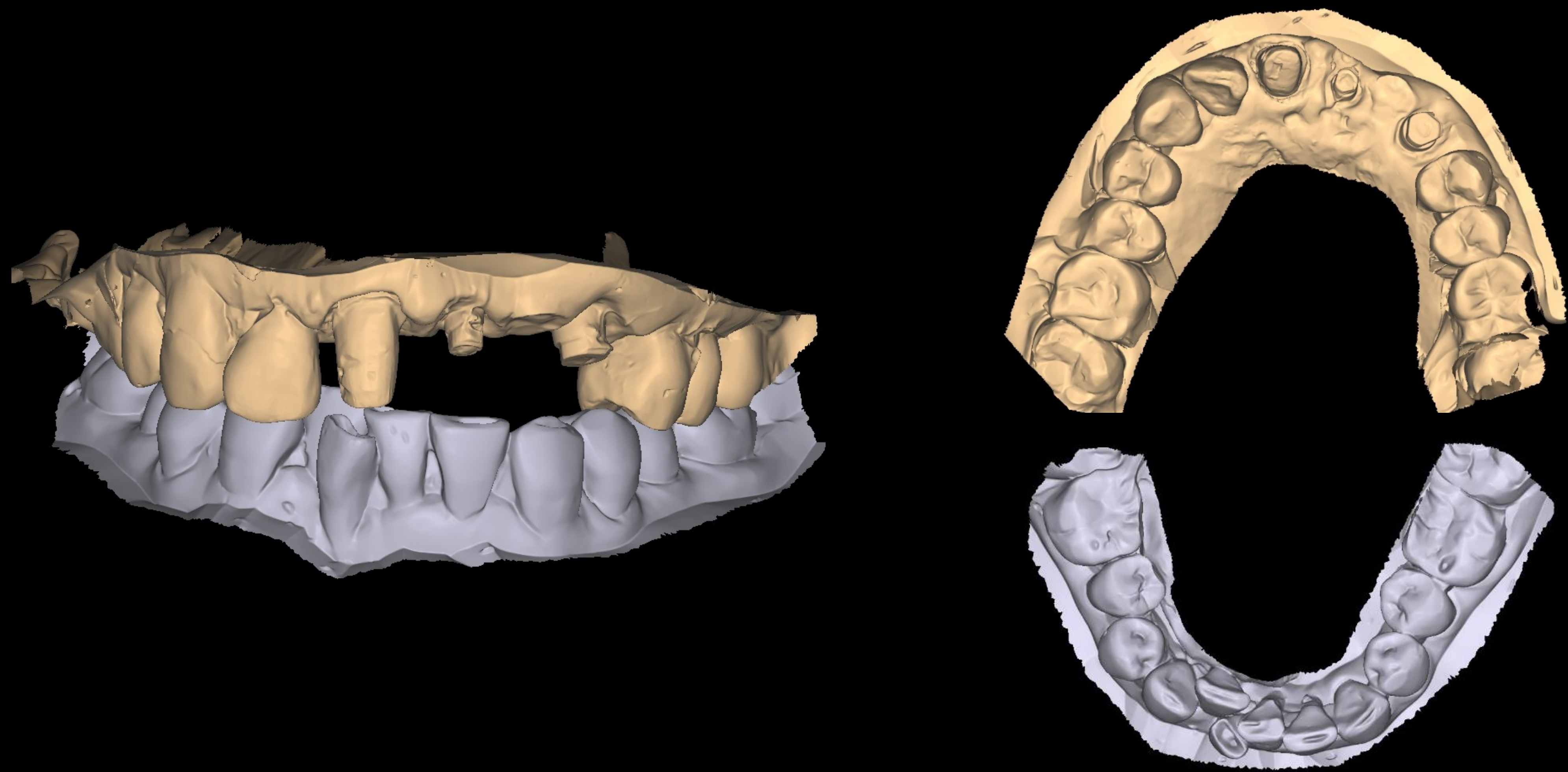
Provisional restoration (2023-11-02)



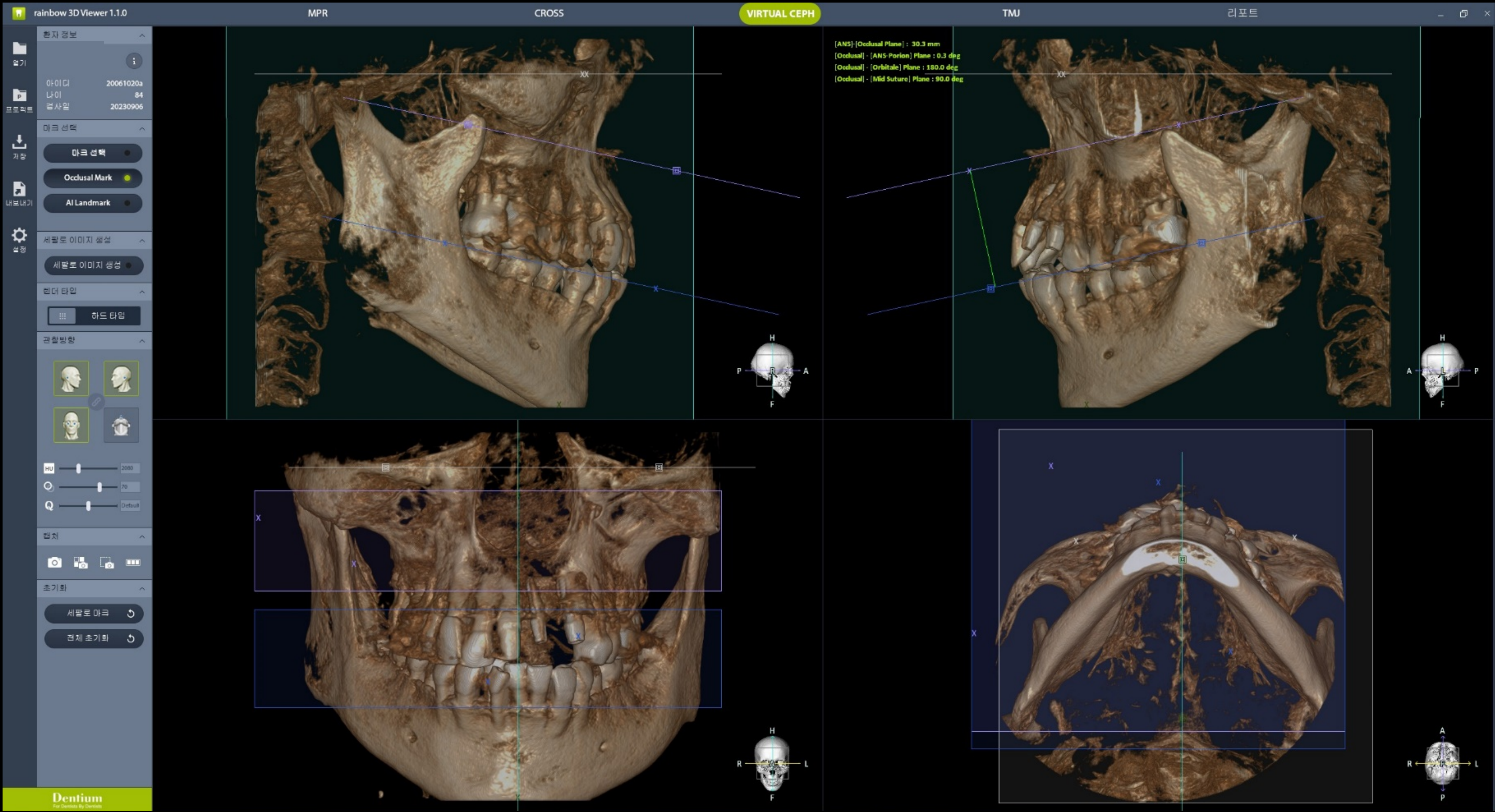
Impression / Trimming / Scan spray



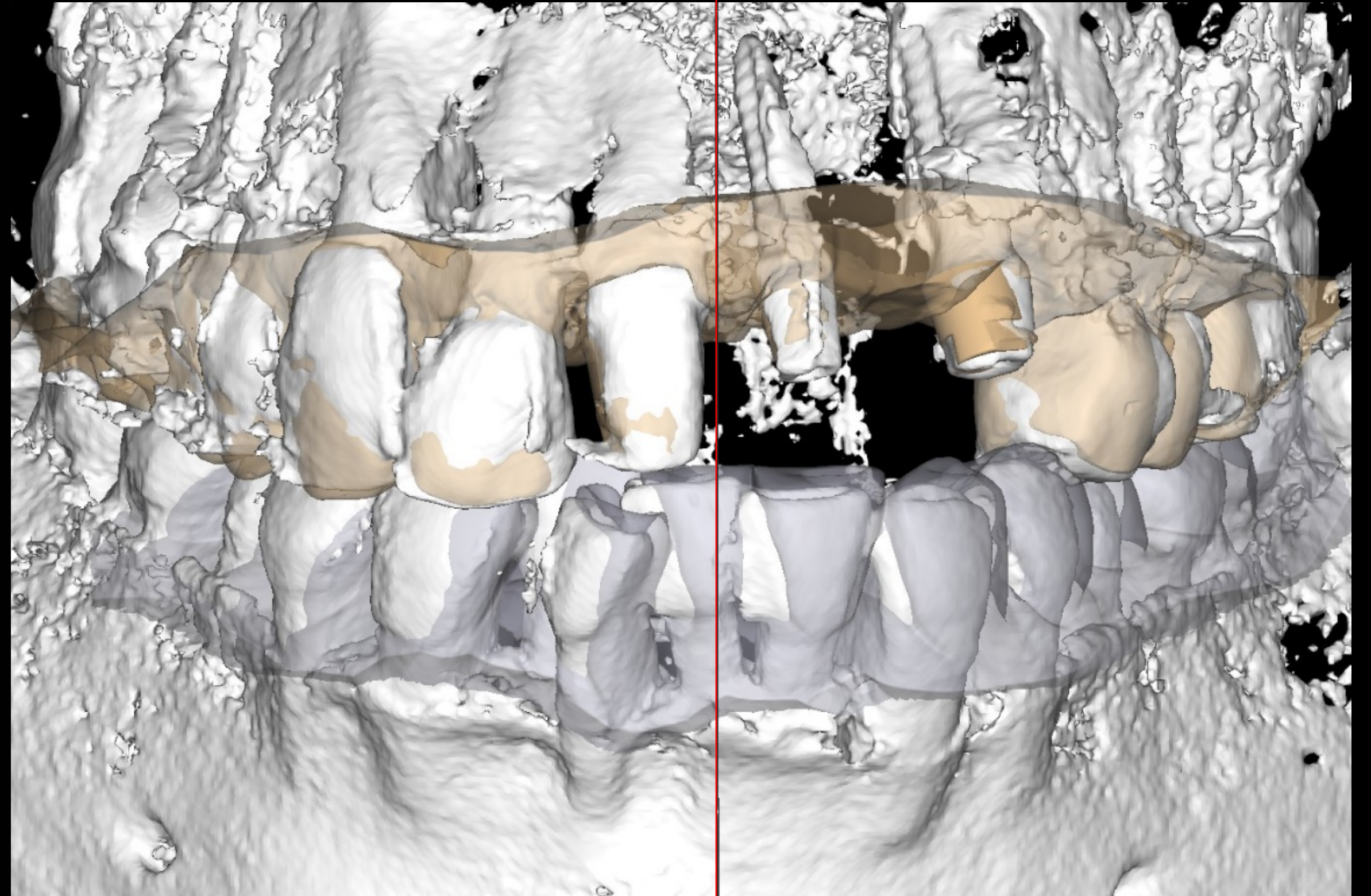
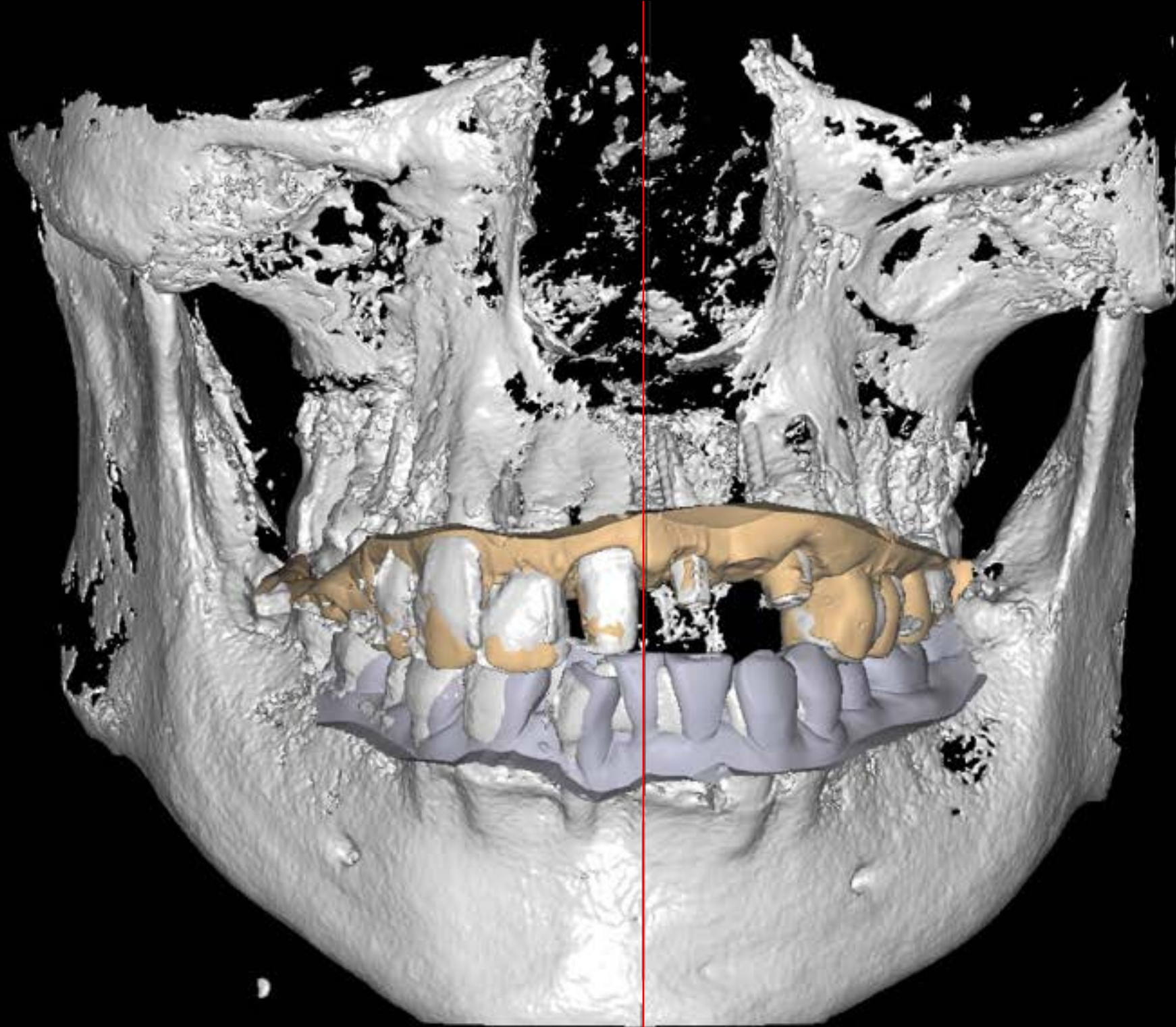
Working Model



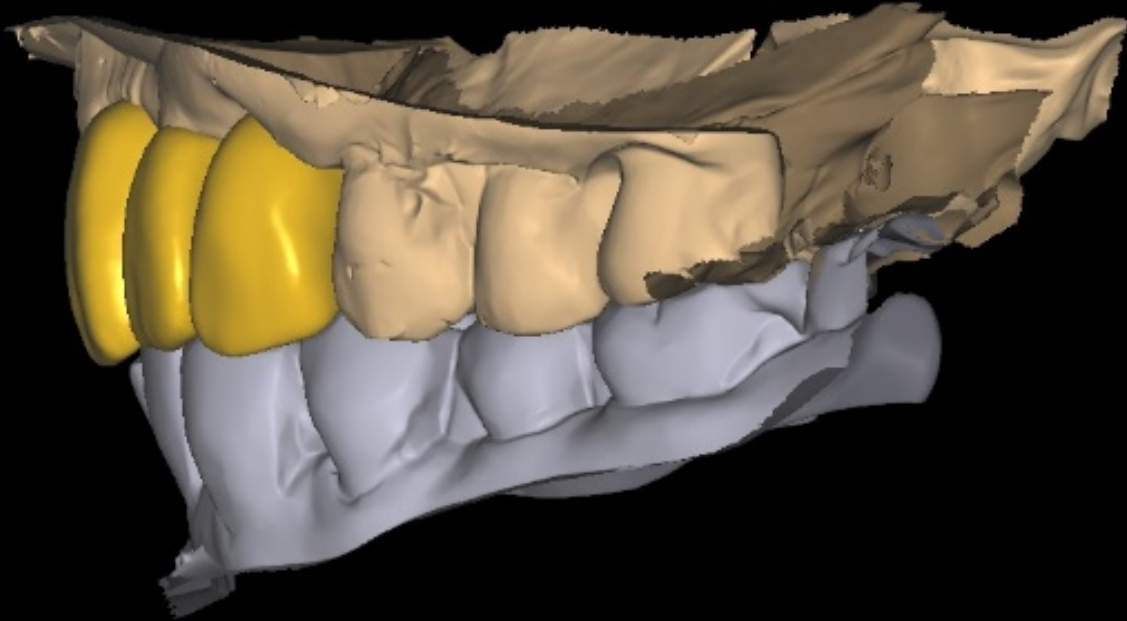
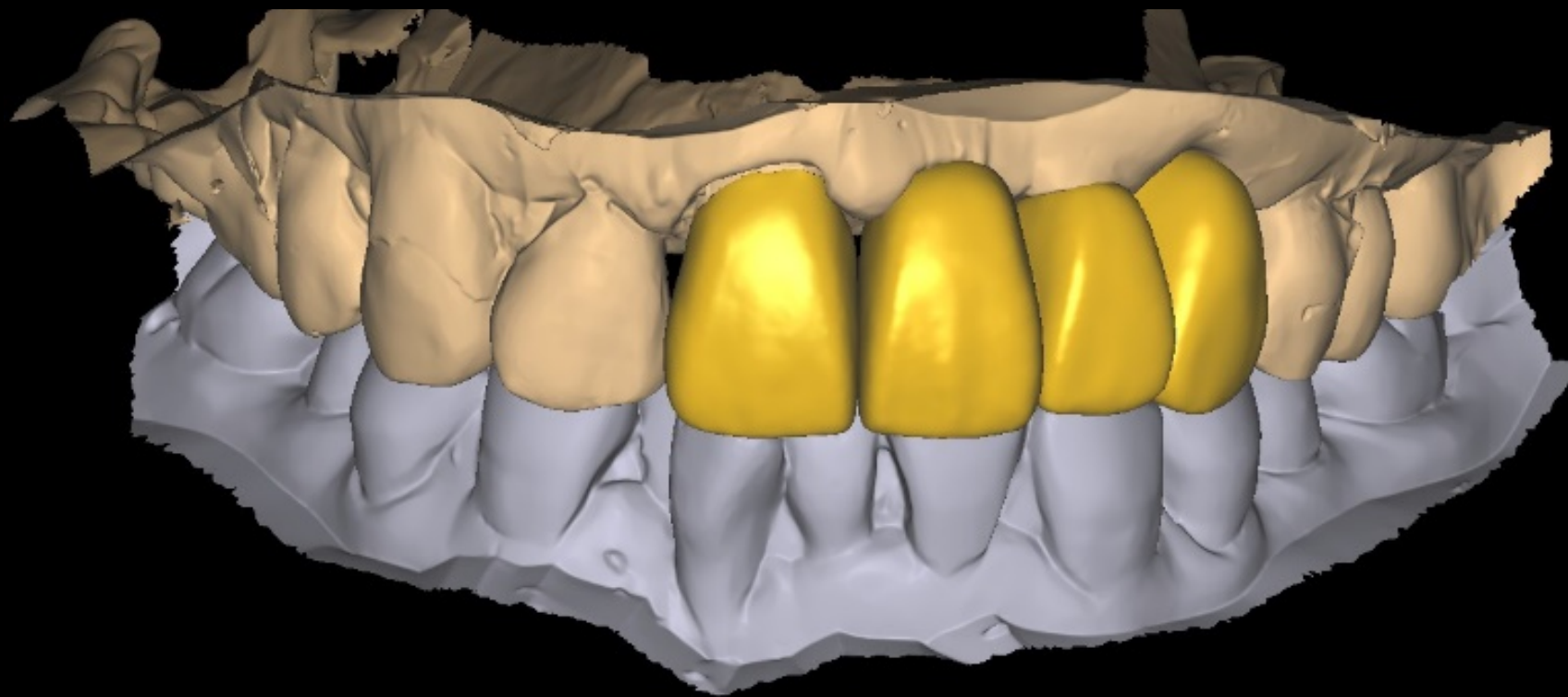
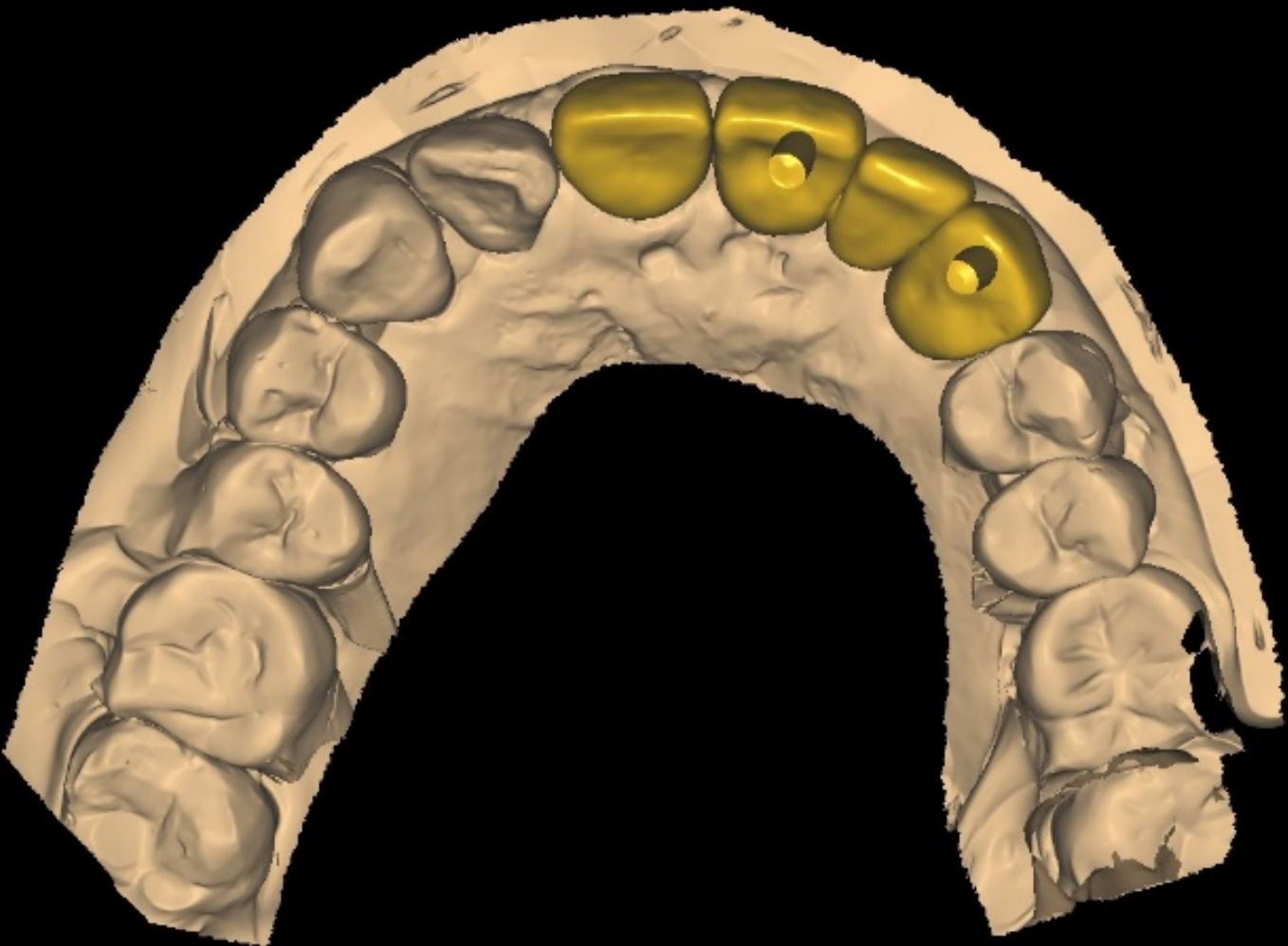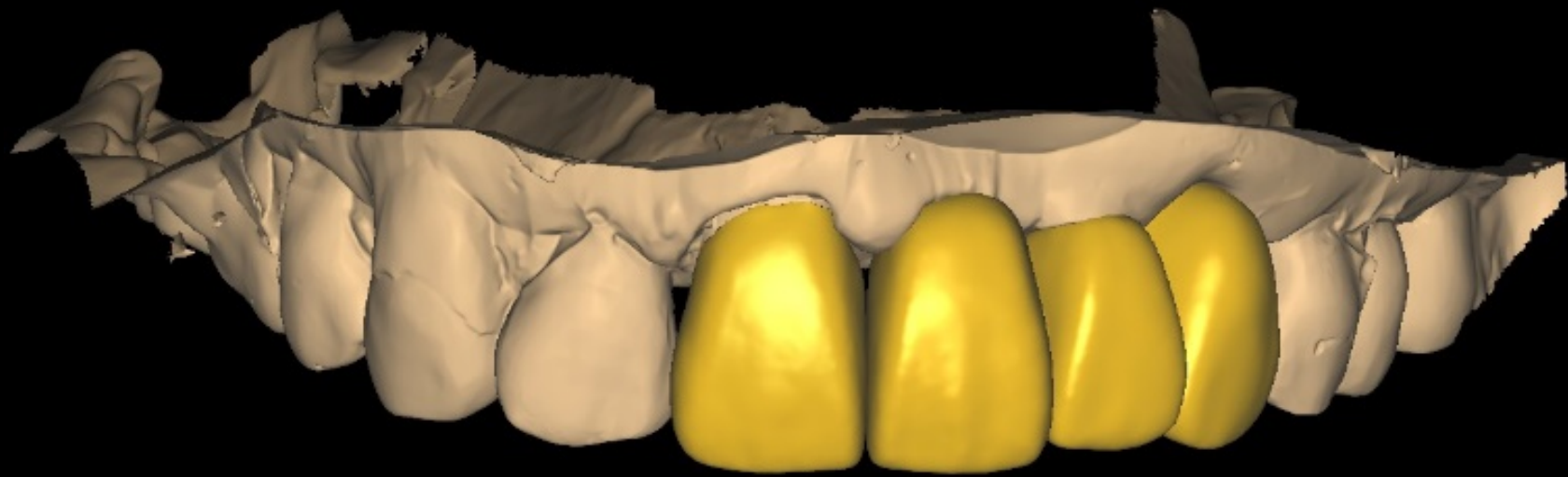
CT STL export (rainbow 3D Viewer)



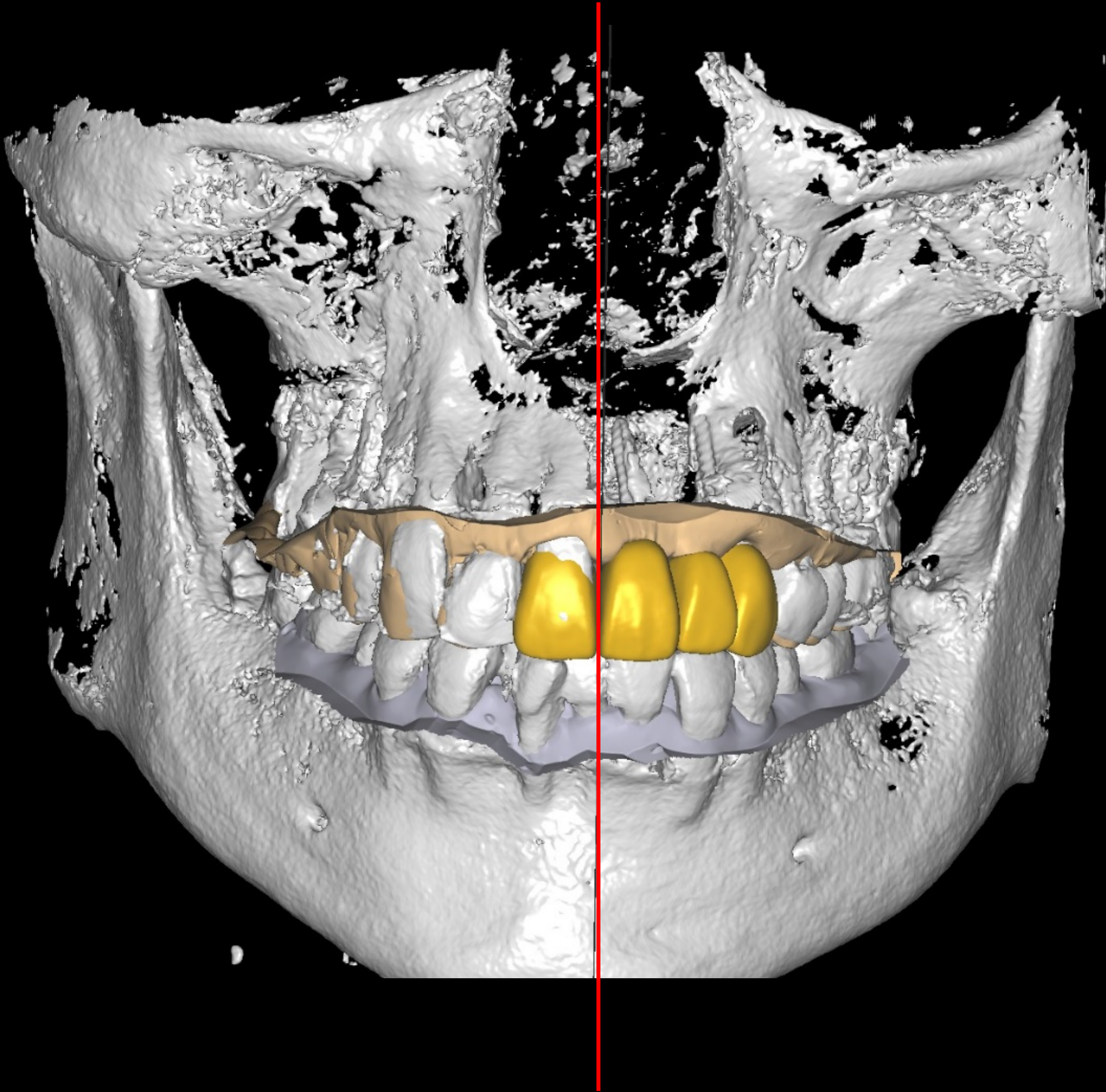
CT STL & working model stitching



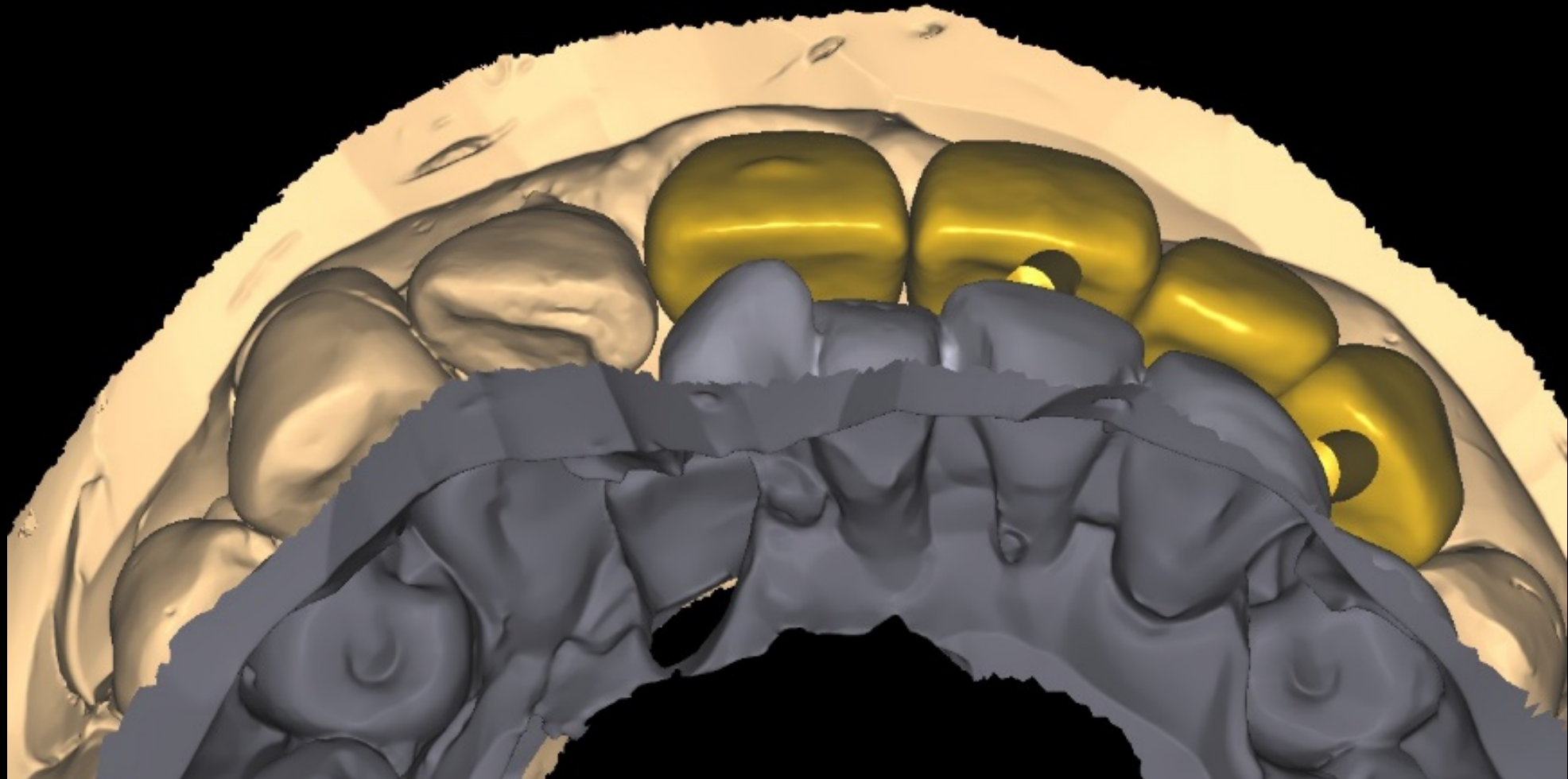
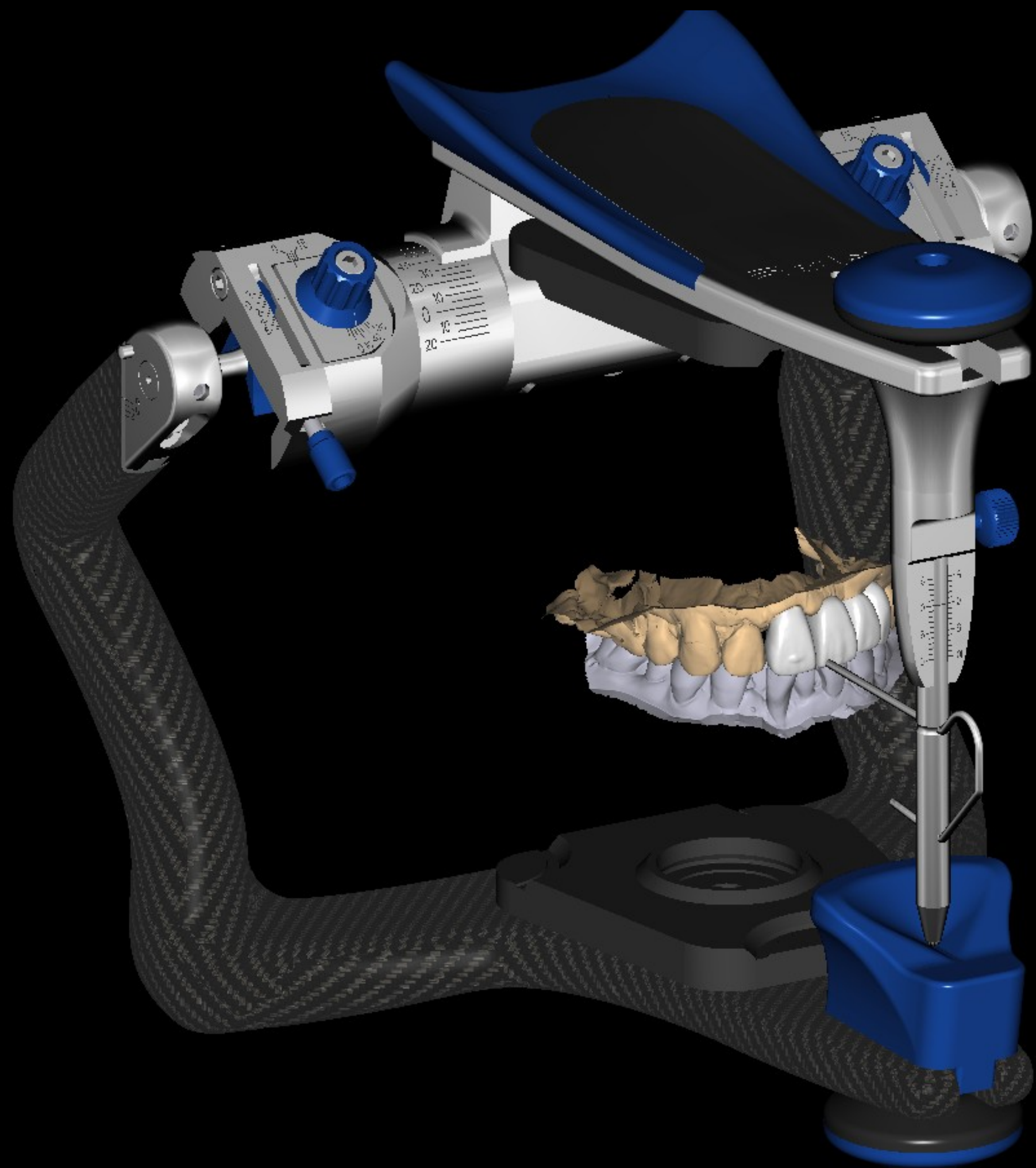
CAD (Final prosthesis)



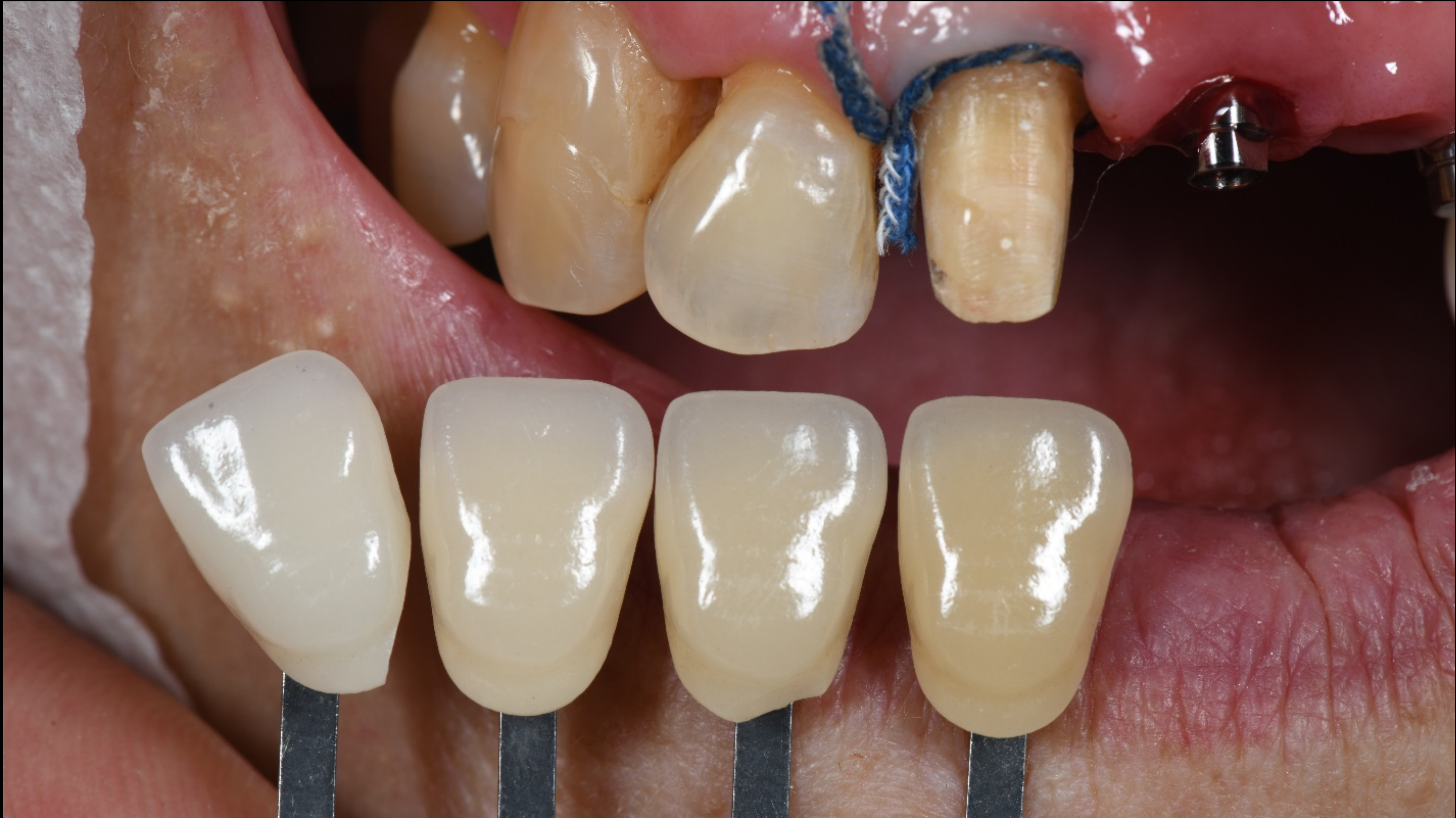CT – Cad design stitching



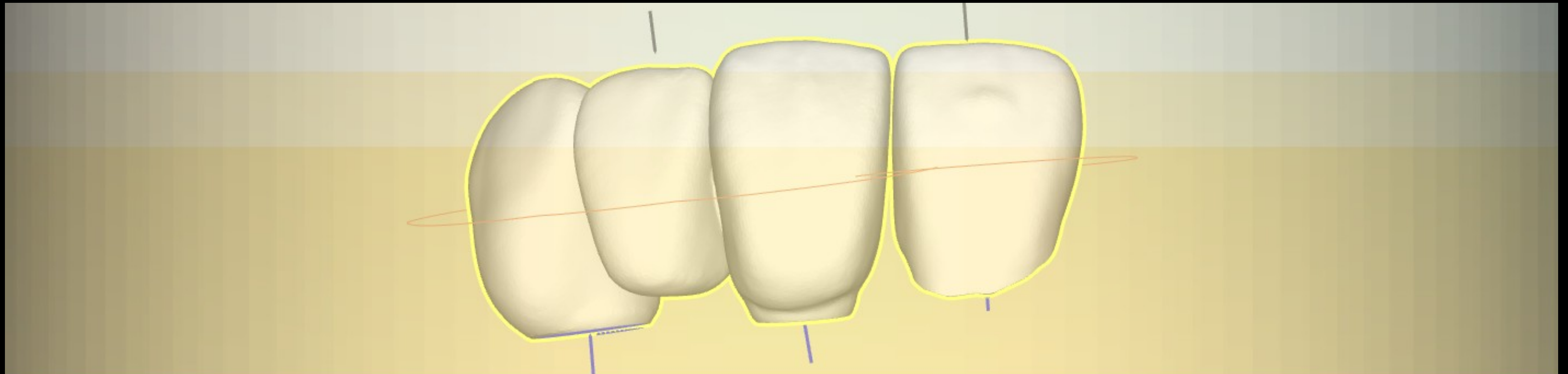
CAD : Mounting with virtual articulator



Shade taking(A3)

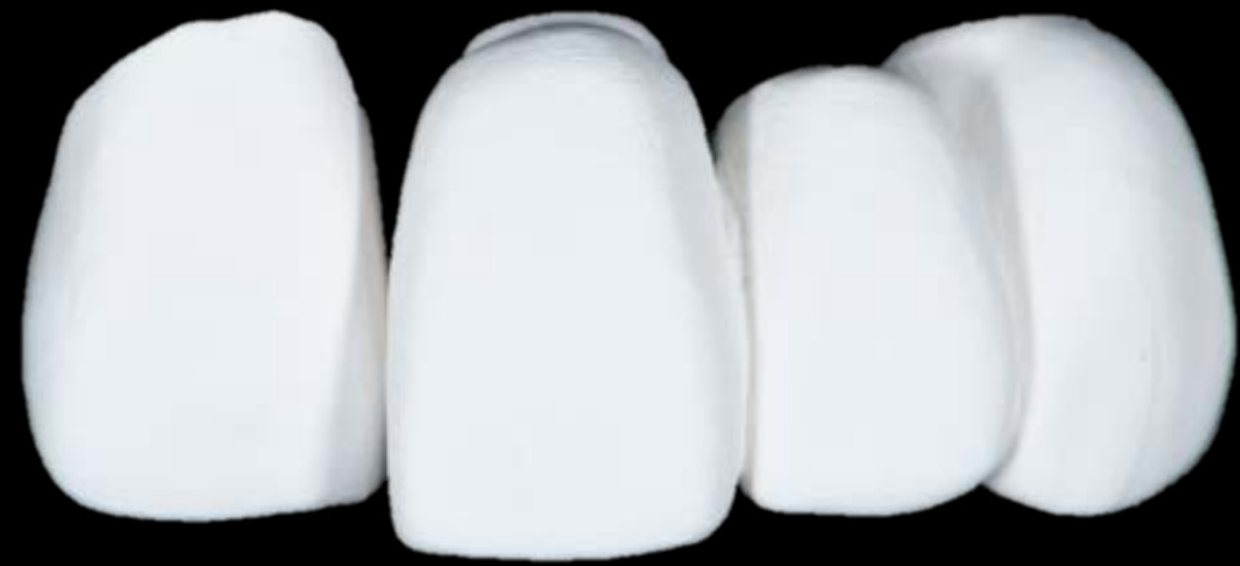

Hyper dent

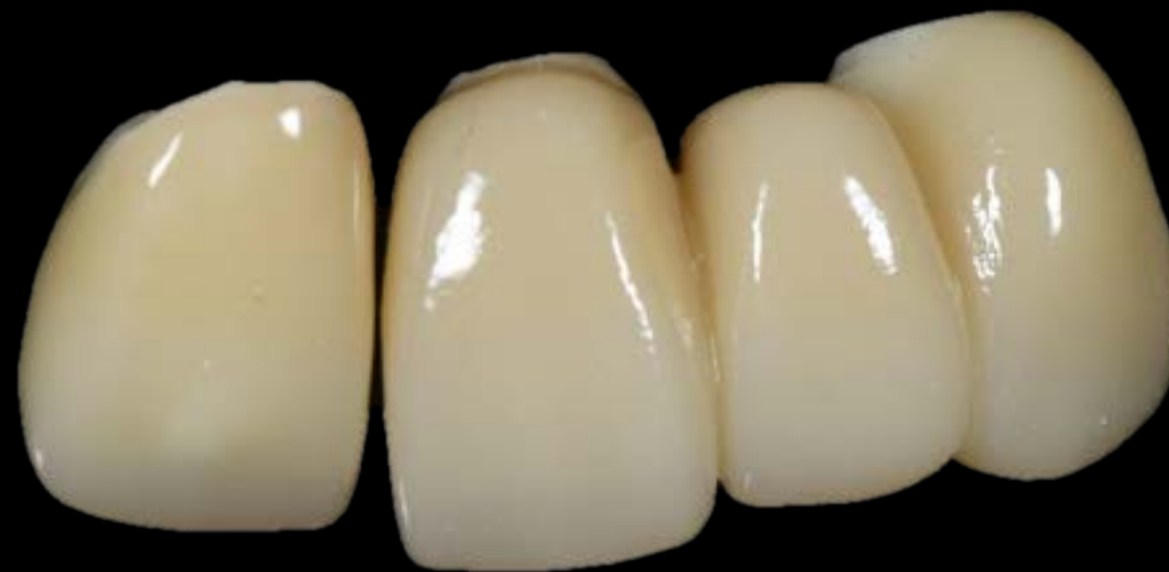
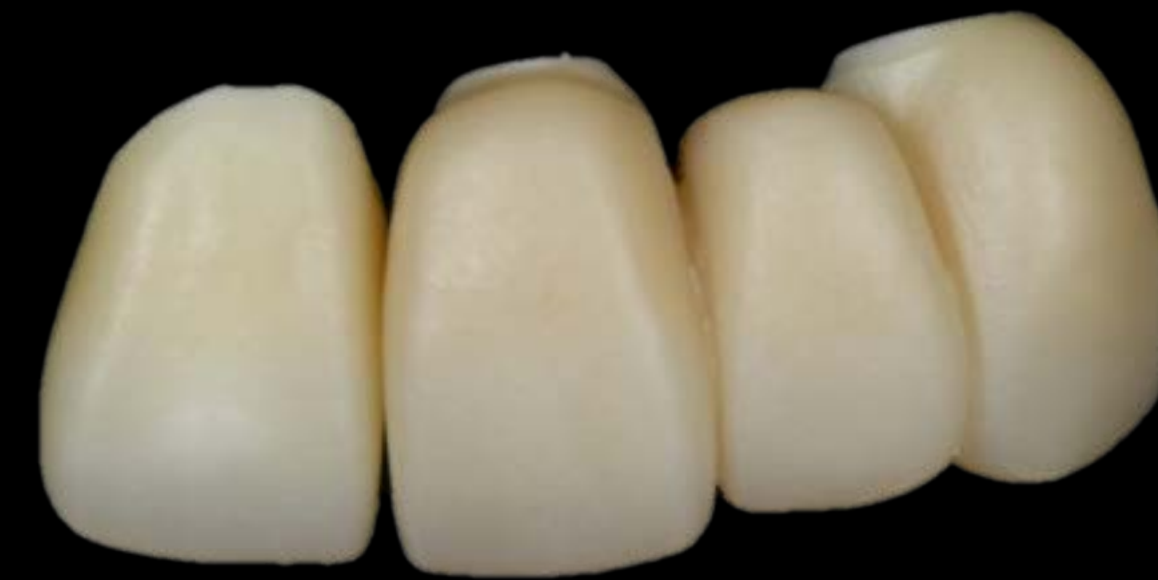
A3 22T 3Layer Block

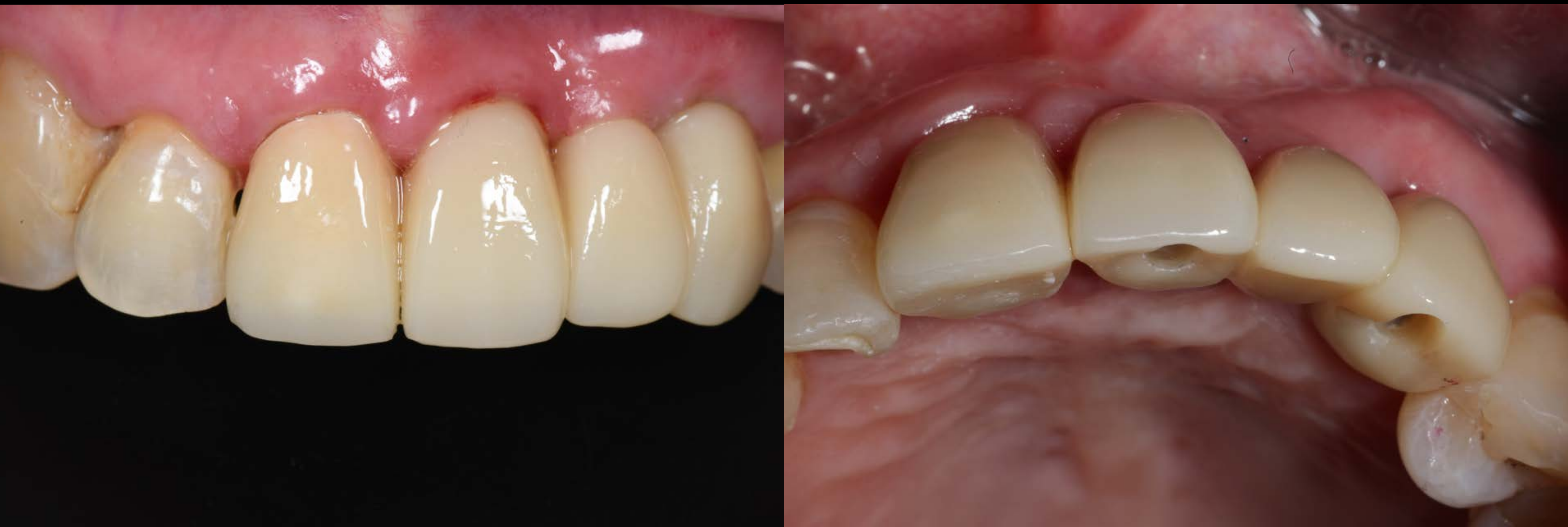Milling / Coloring / Sintering / Glazing



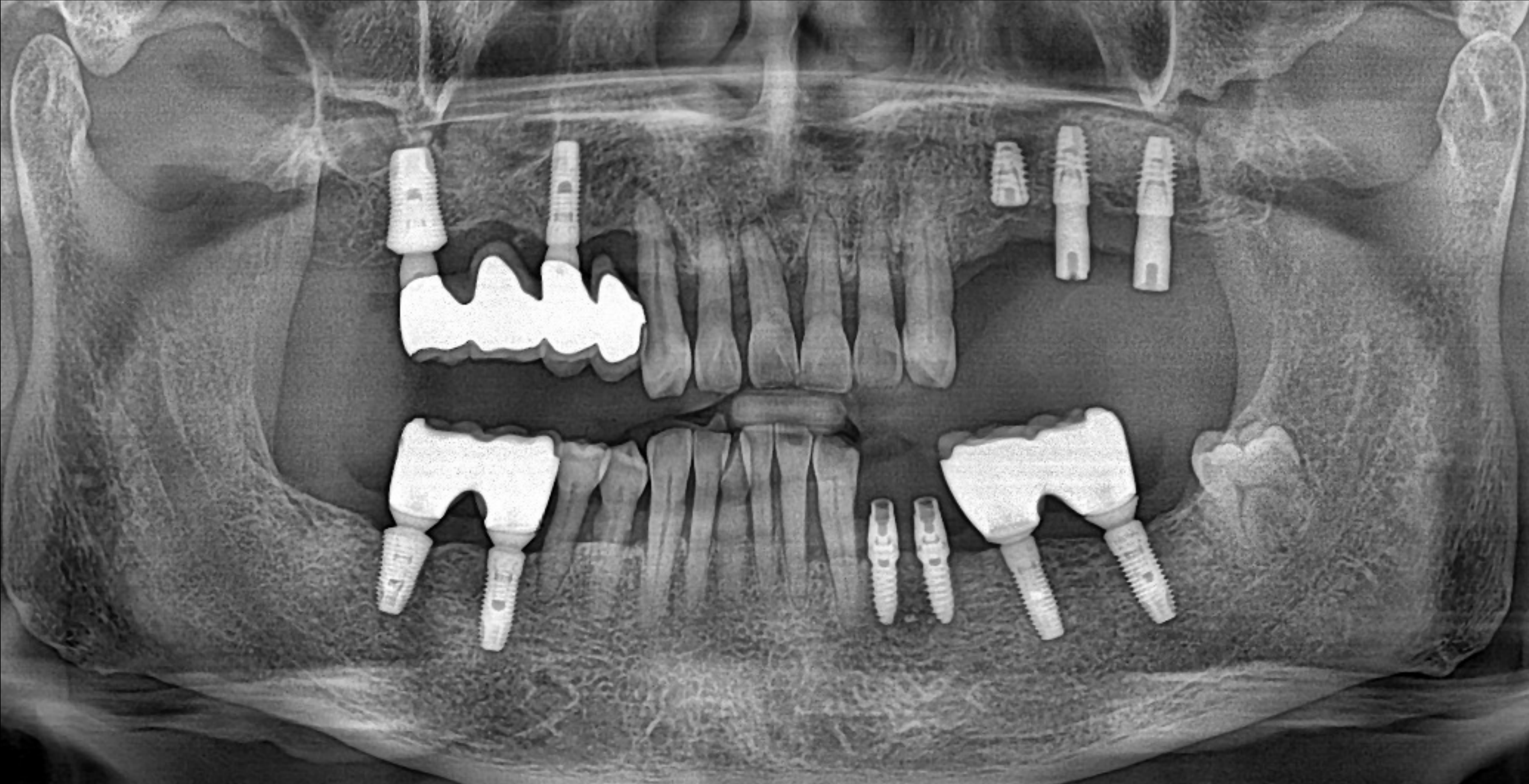
Inner – White Opaque

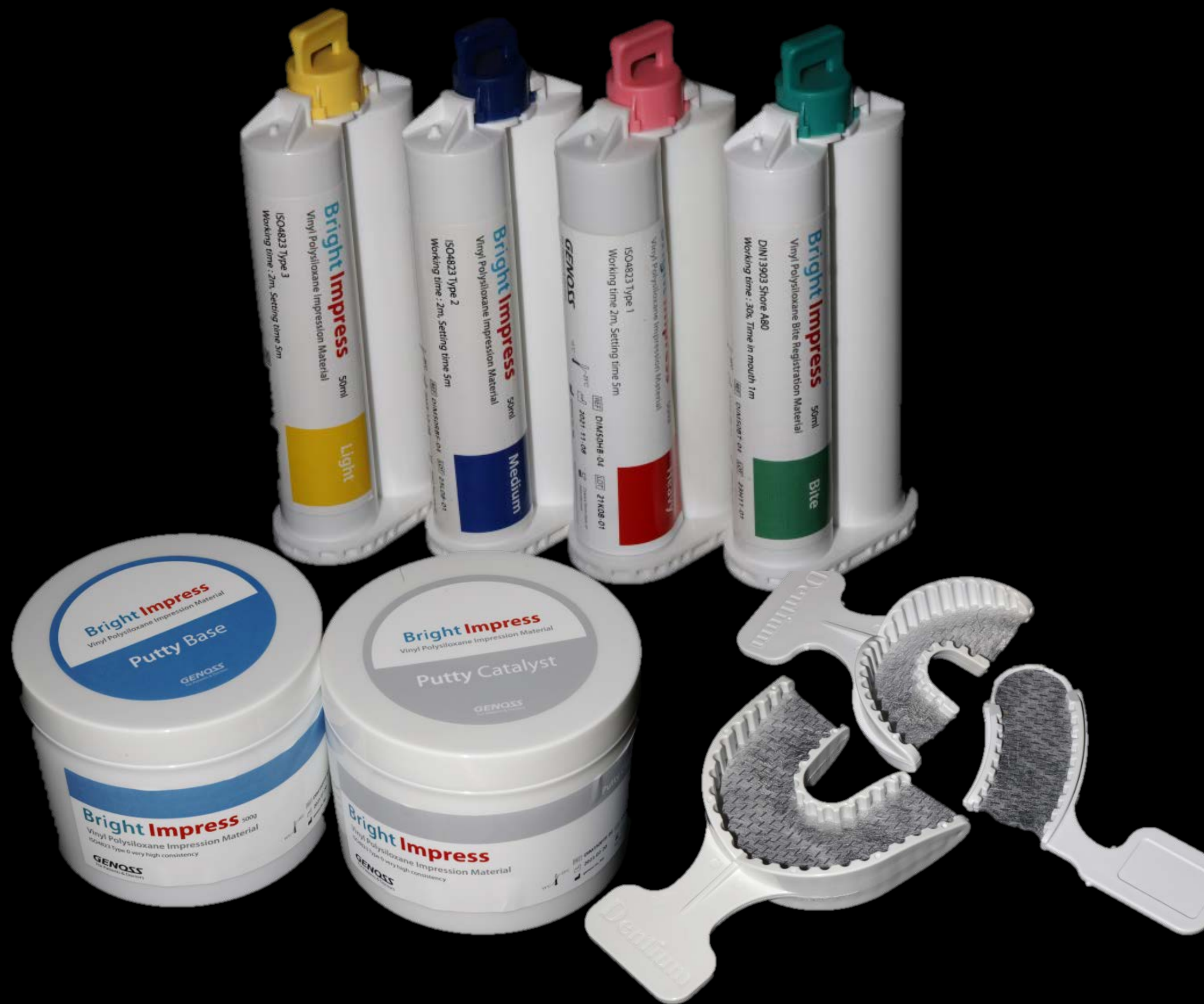

Final prosthesis (2023-11-02)



Oral exam

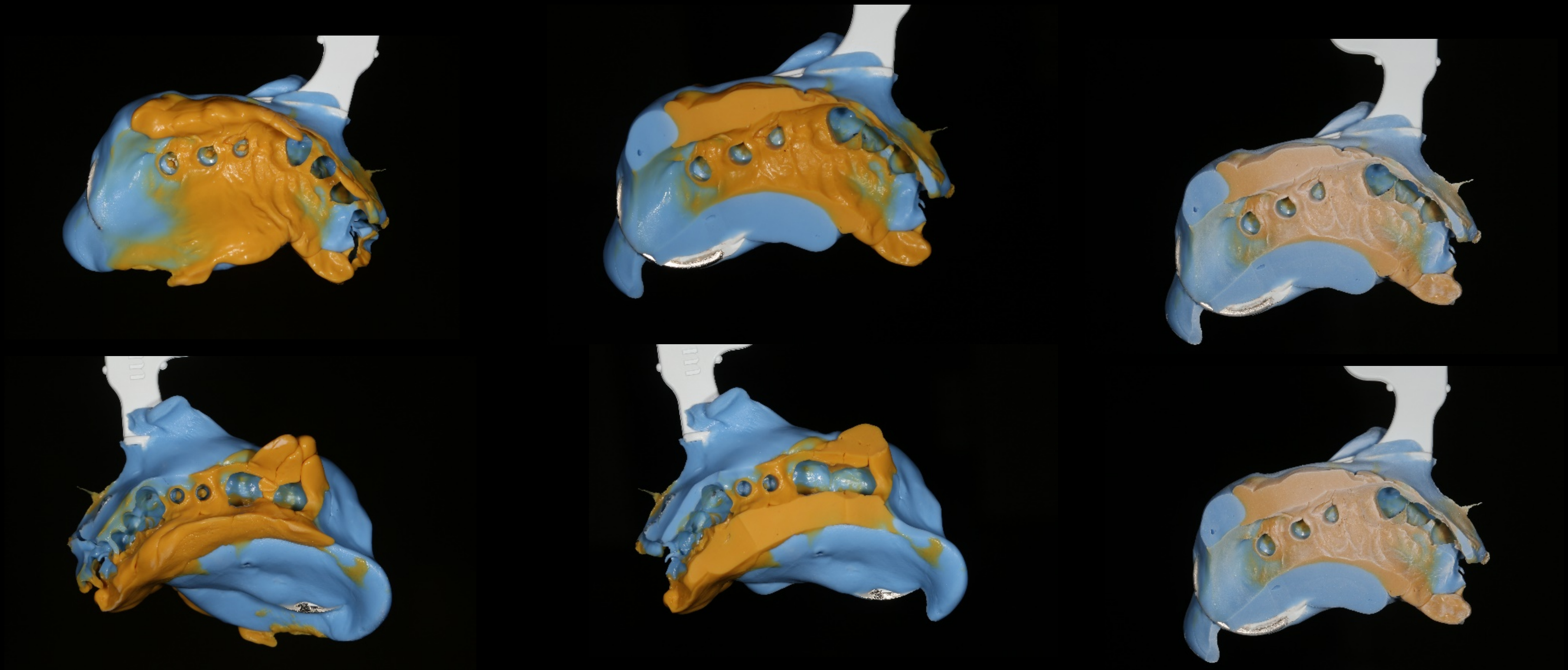




- Bright Impress **Light**
- Bright Impress **Medium**
- Bright Impress **Heavy**
- Bright Impress **Bite**
- Bright Impress **Putty**
- Bright **Bite Tray**

Dentium

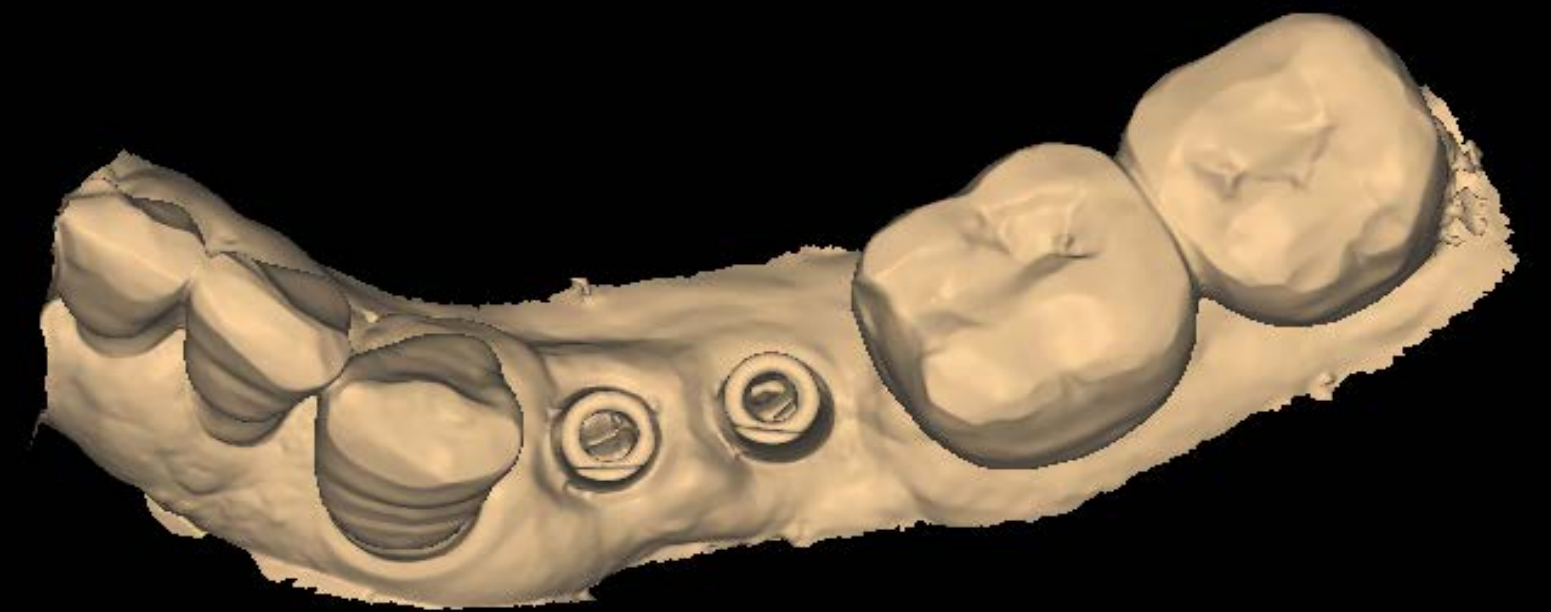
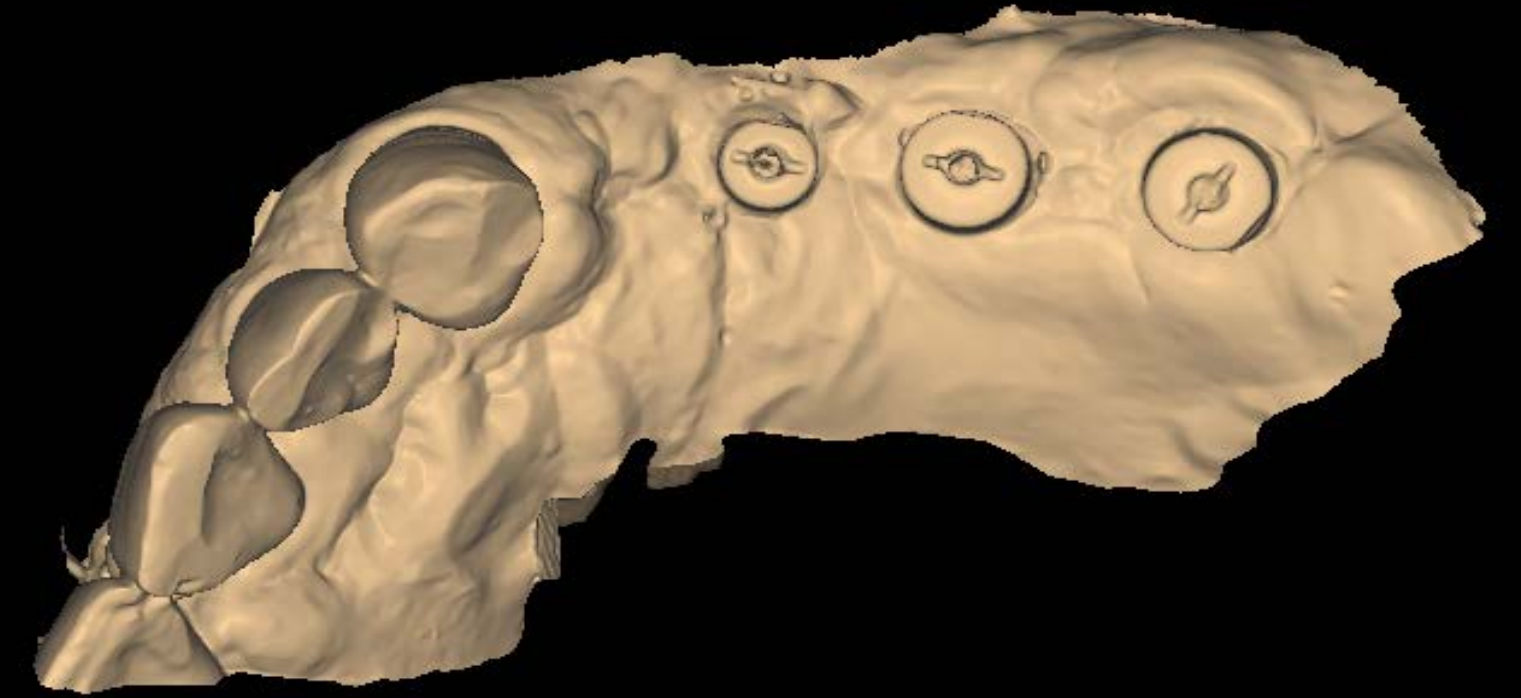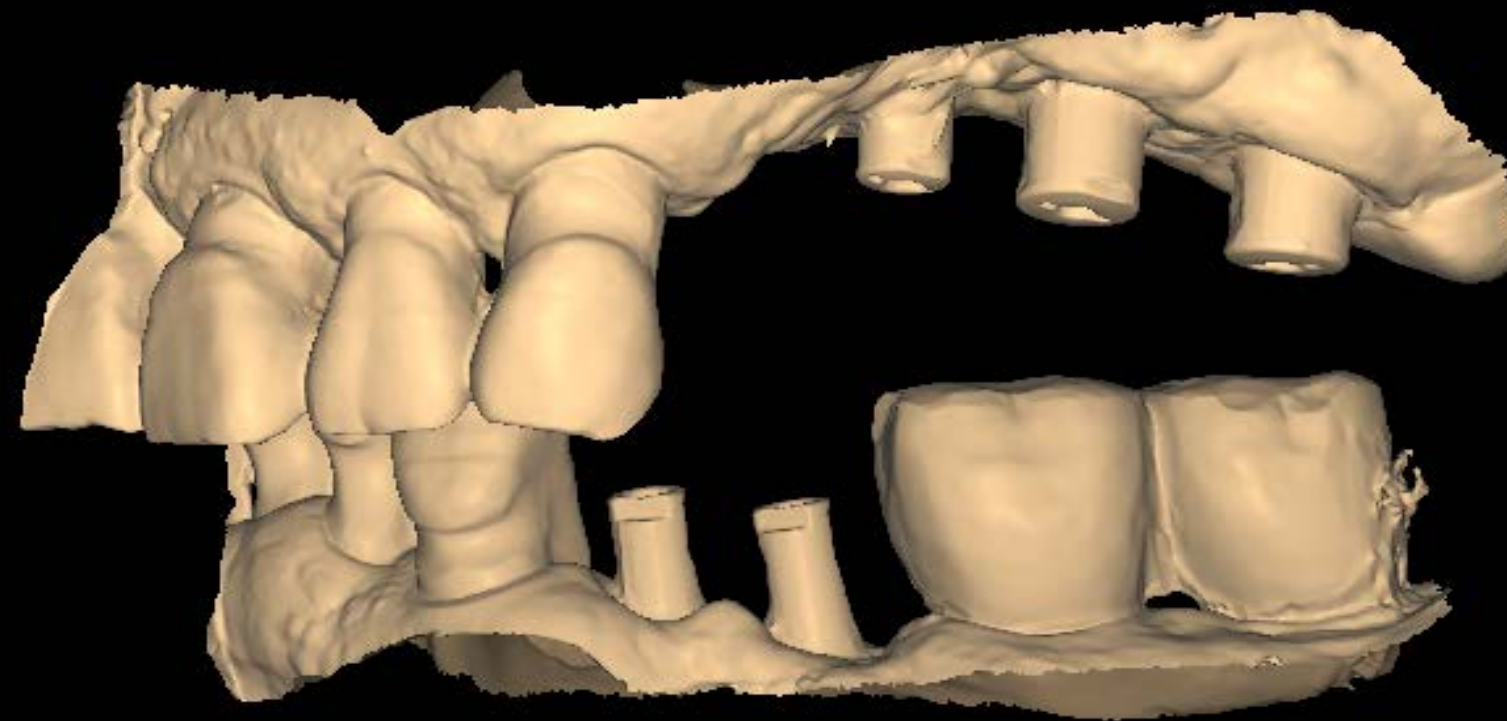
Impression / Trimming / Scan spray



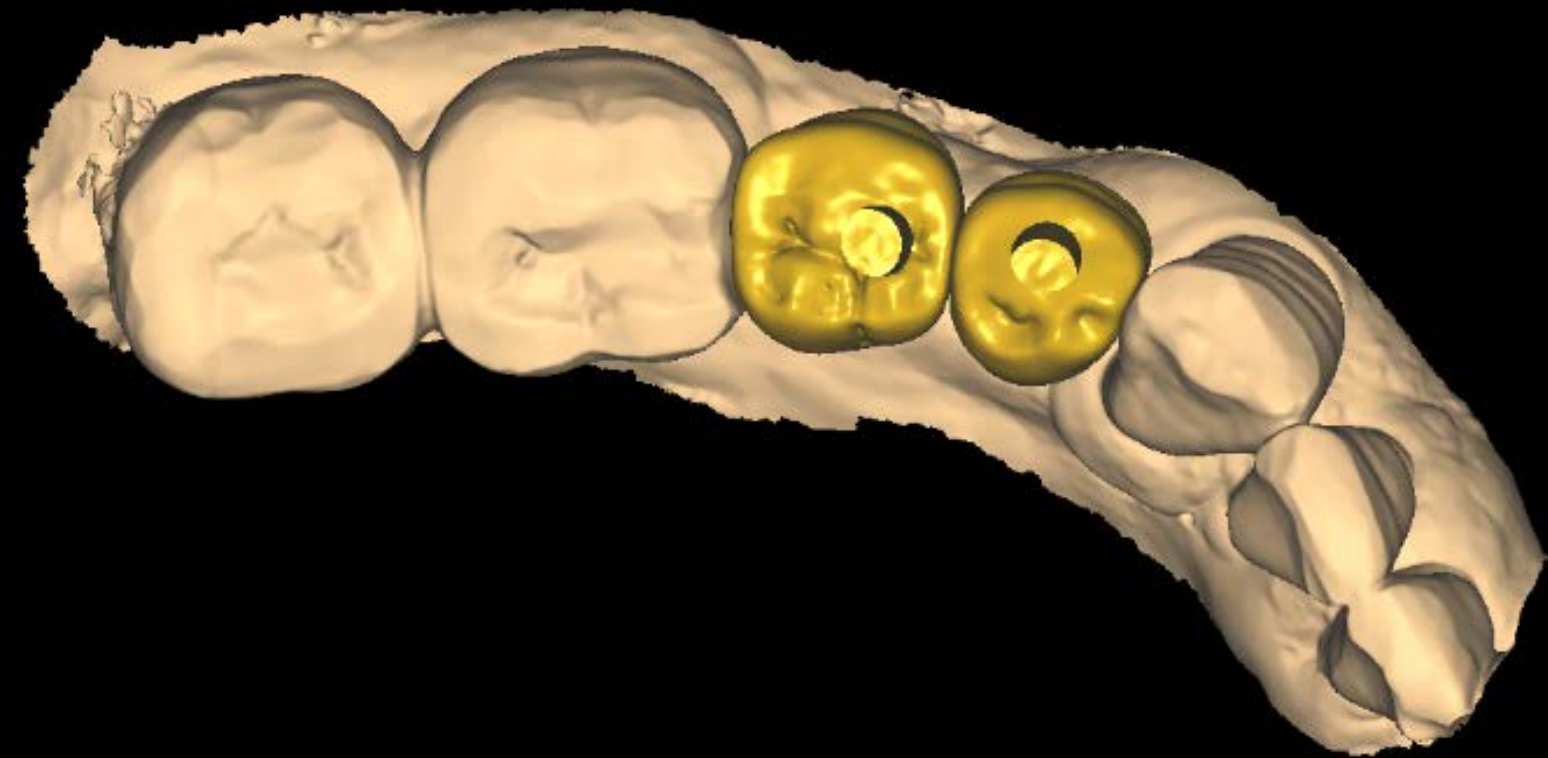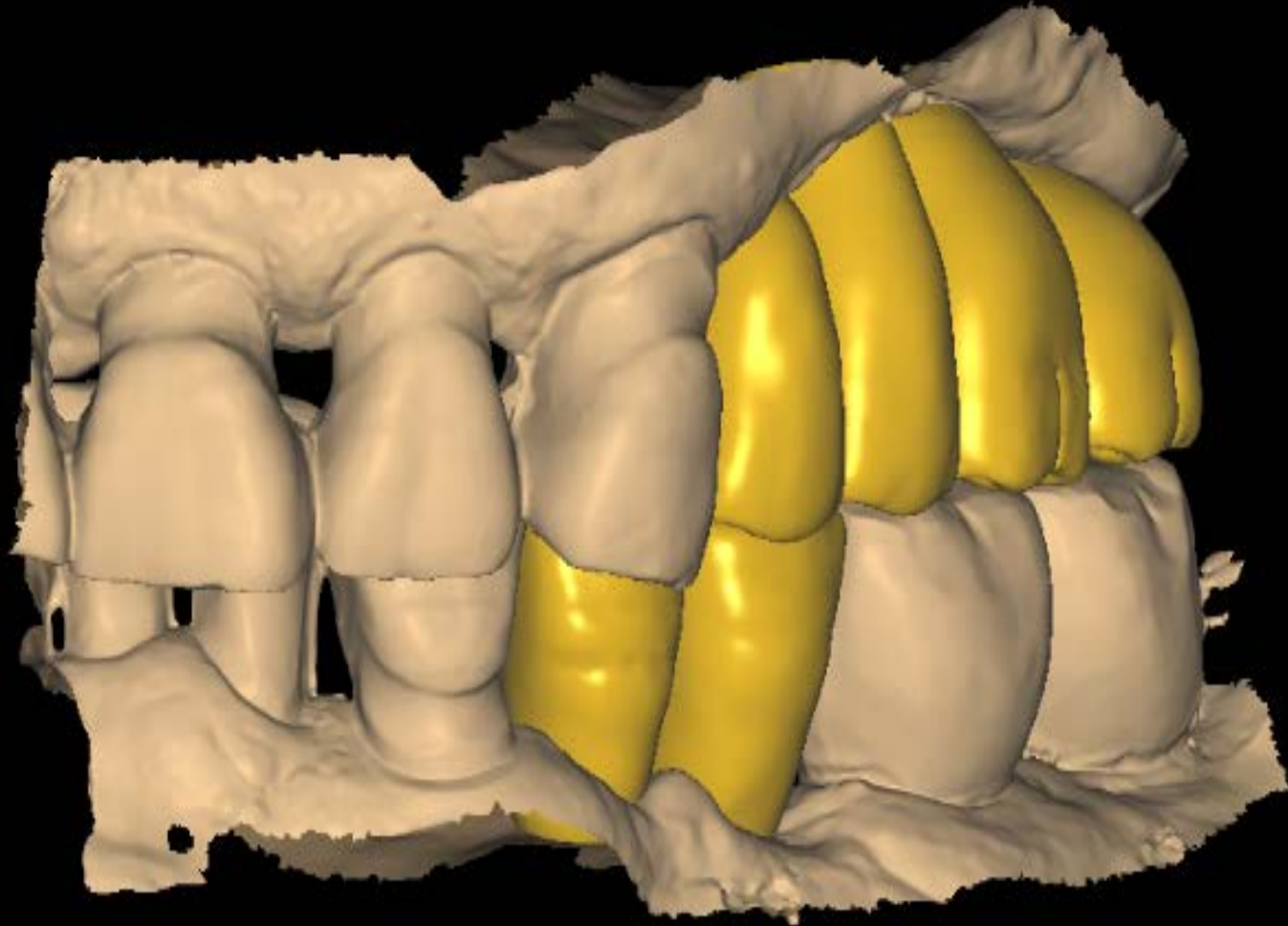
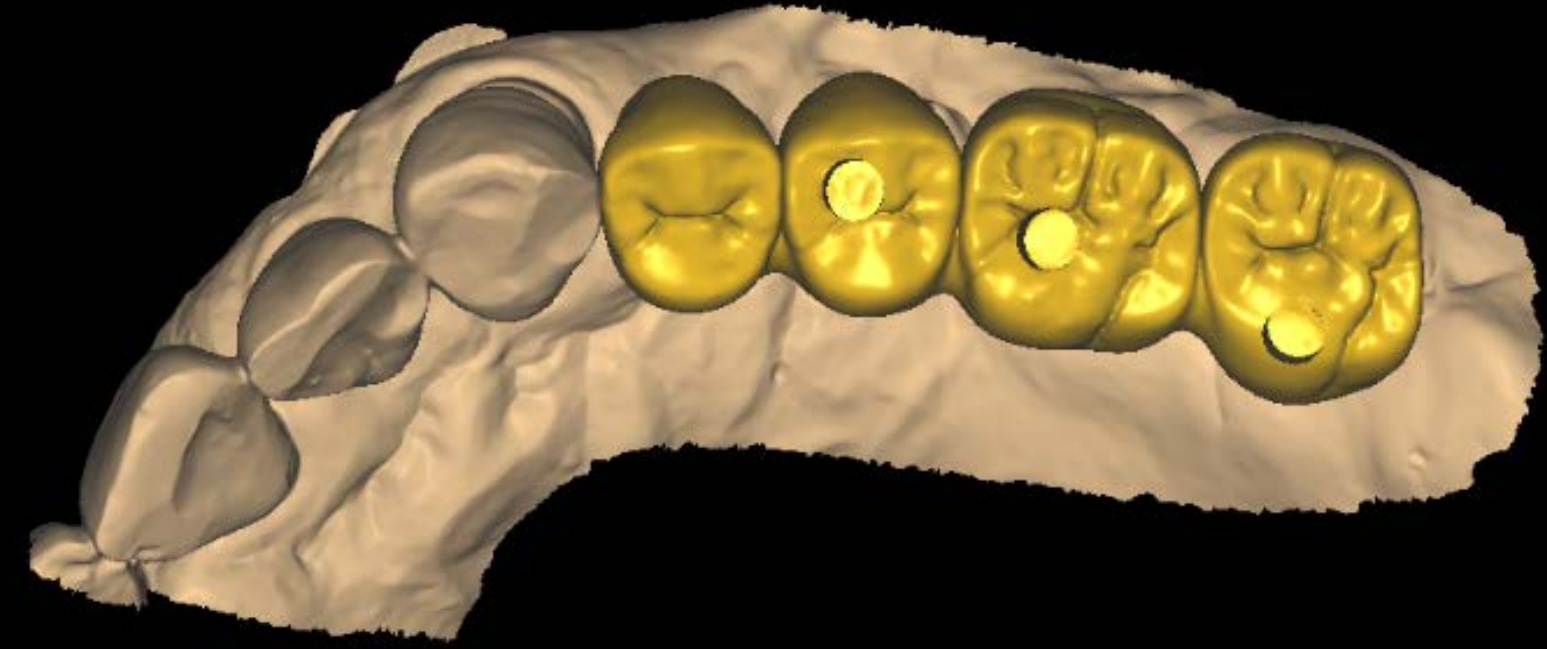
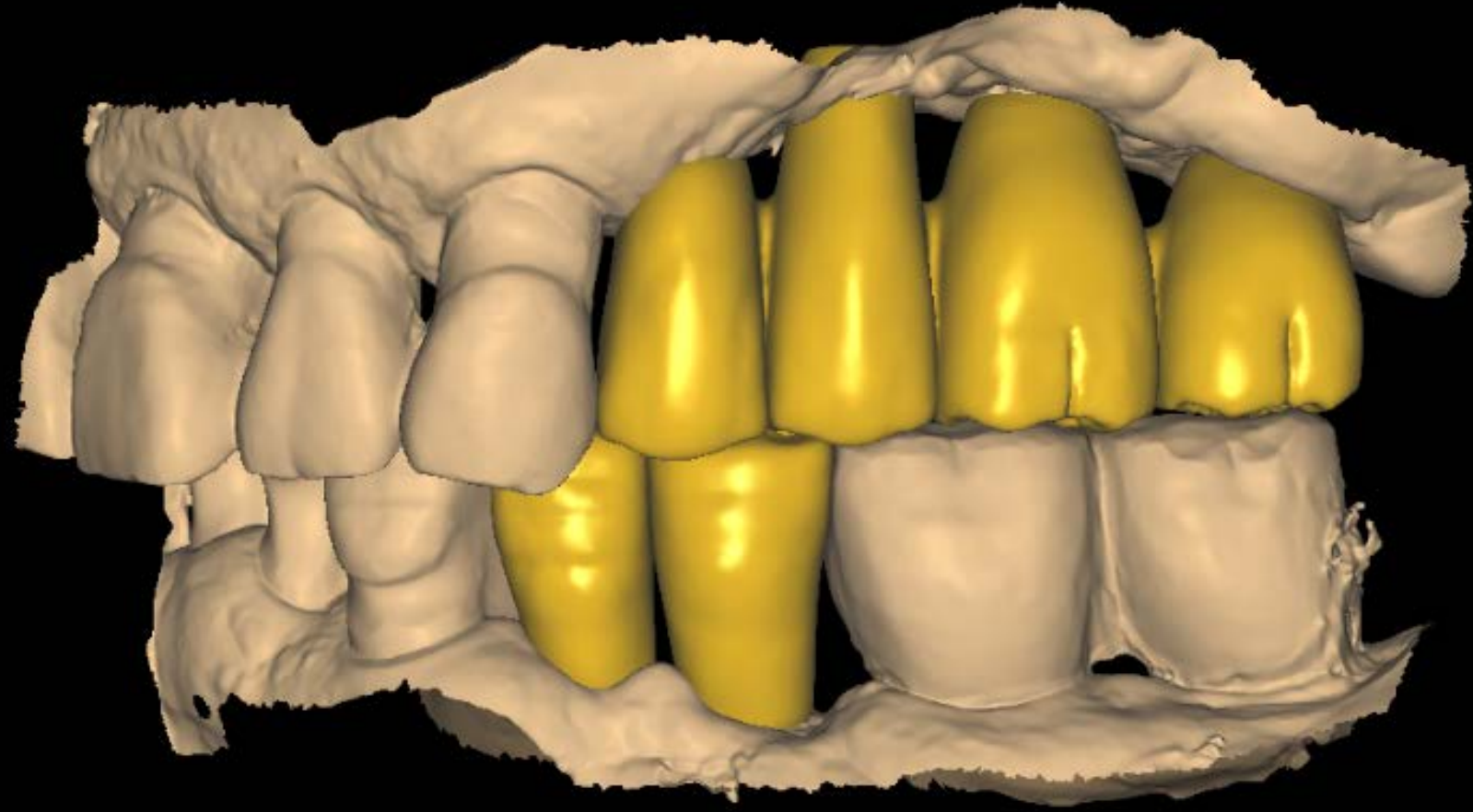
Impression scan / Working Model



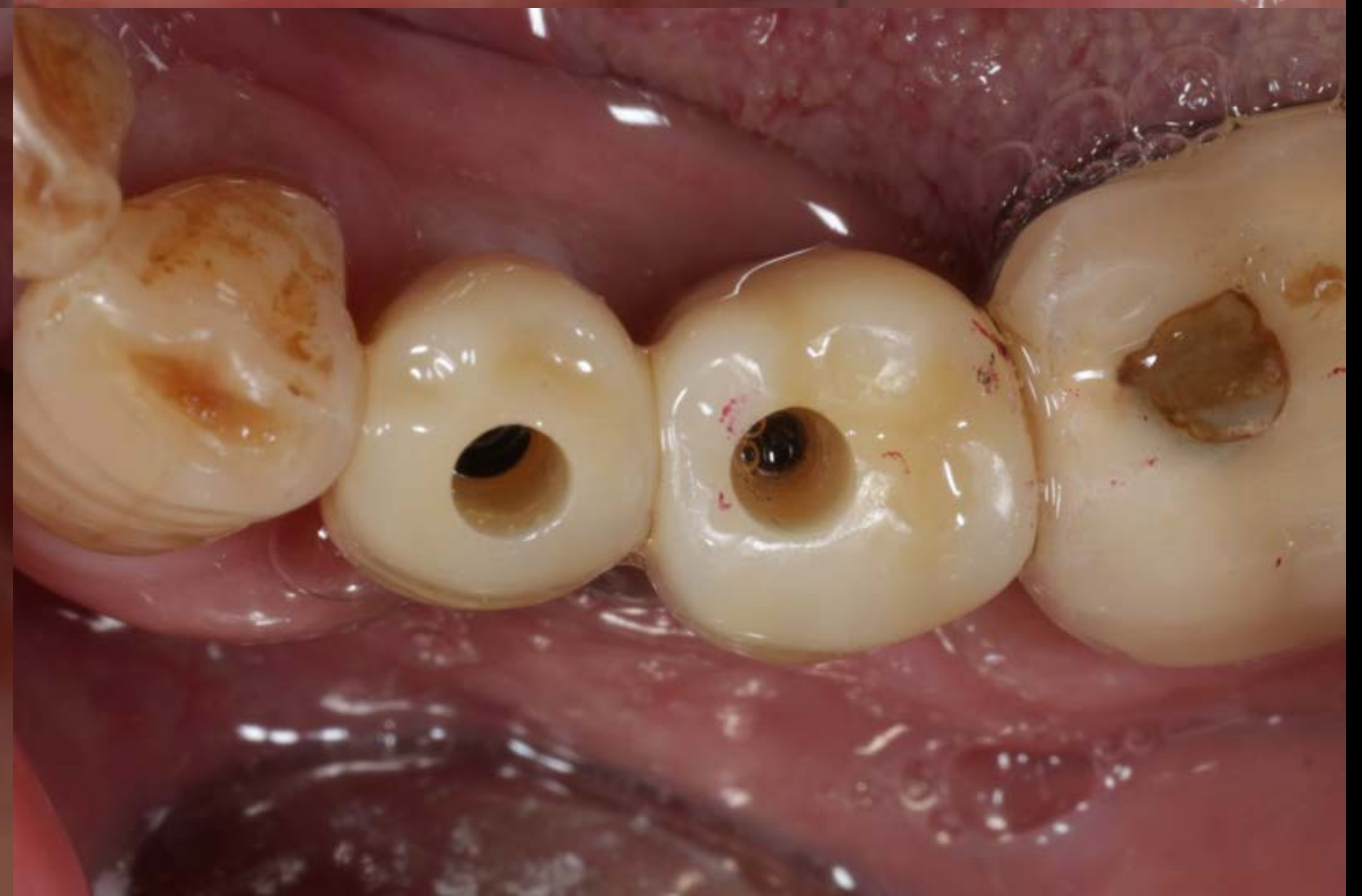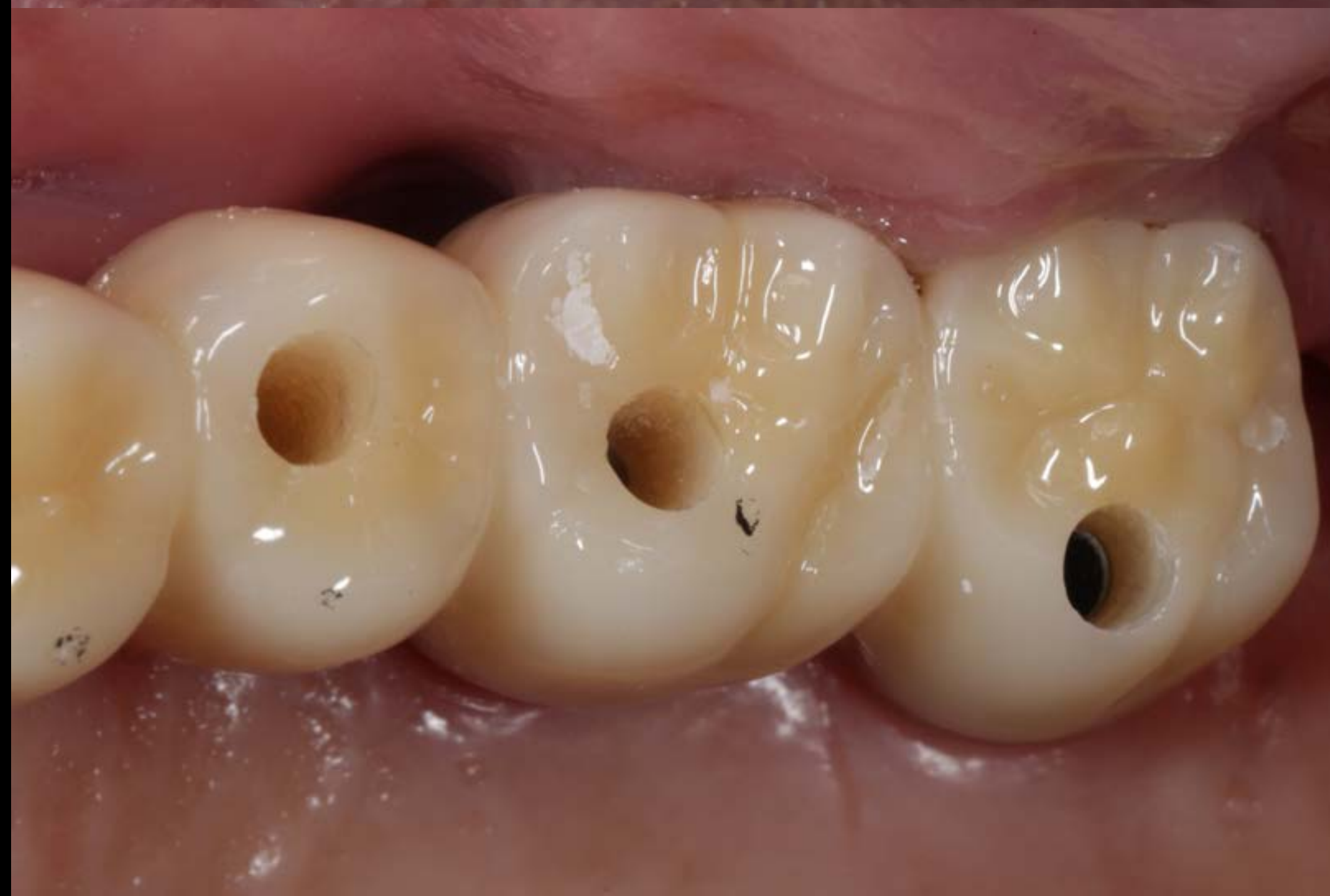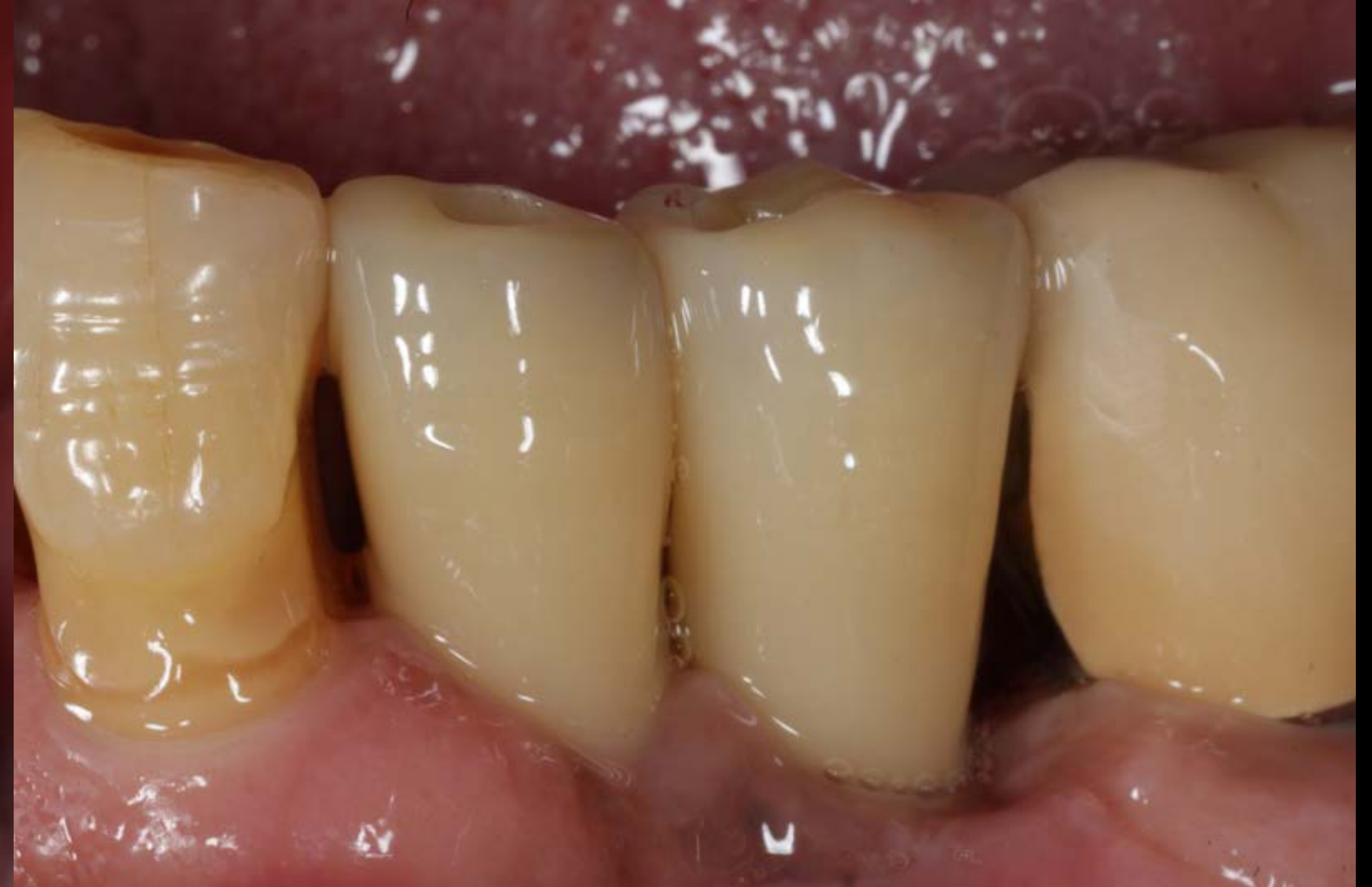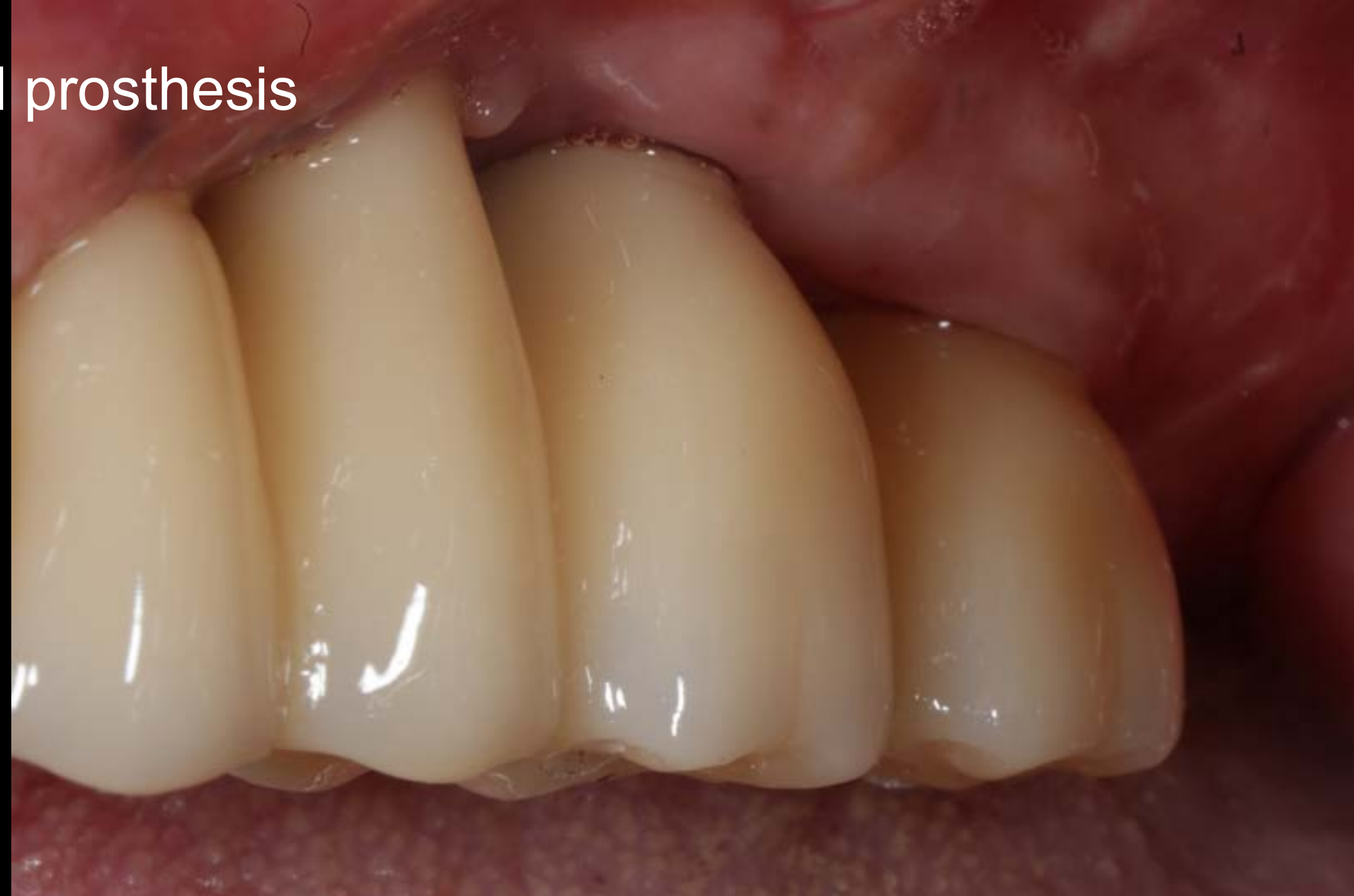Shining 3D
AutoScan-DS-EX Pro (H)



CAD



Final prosthesis



Contents

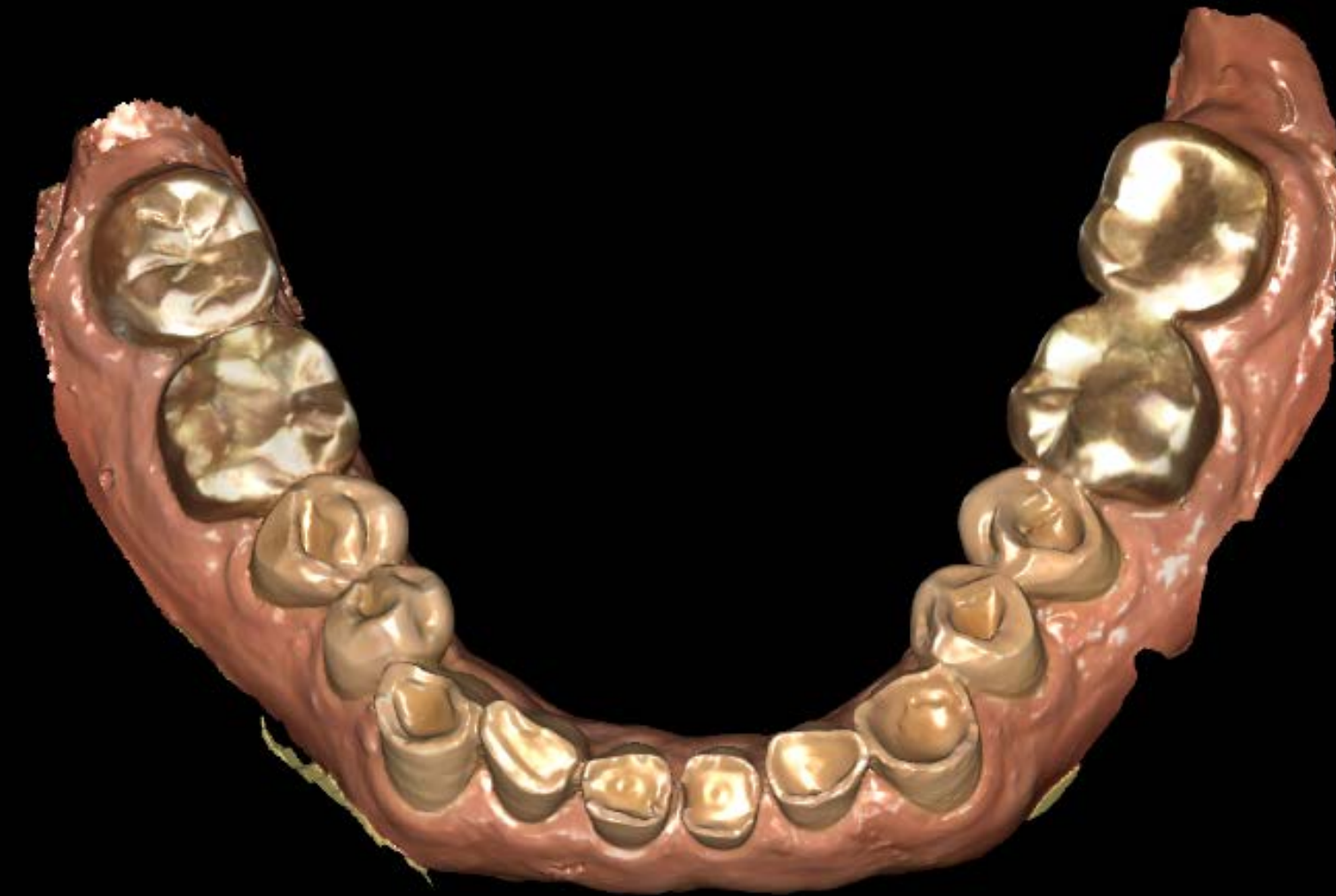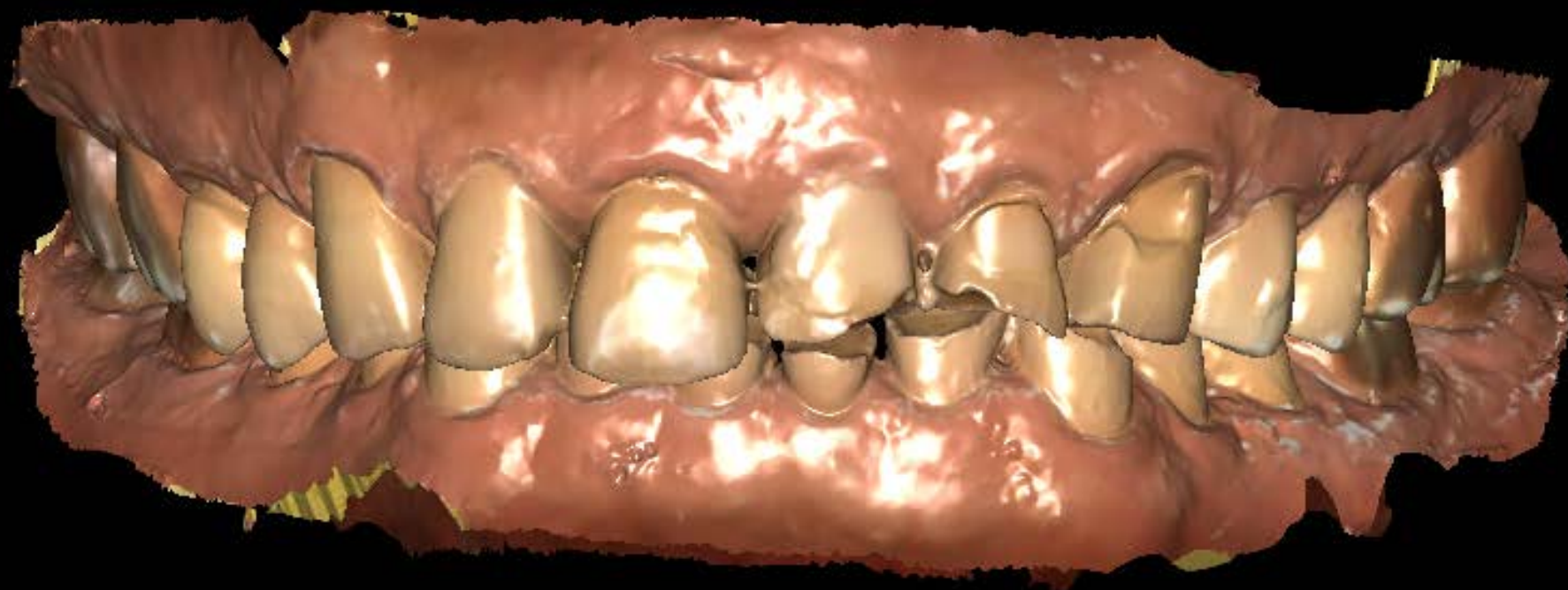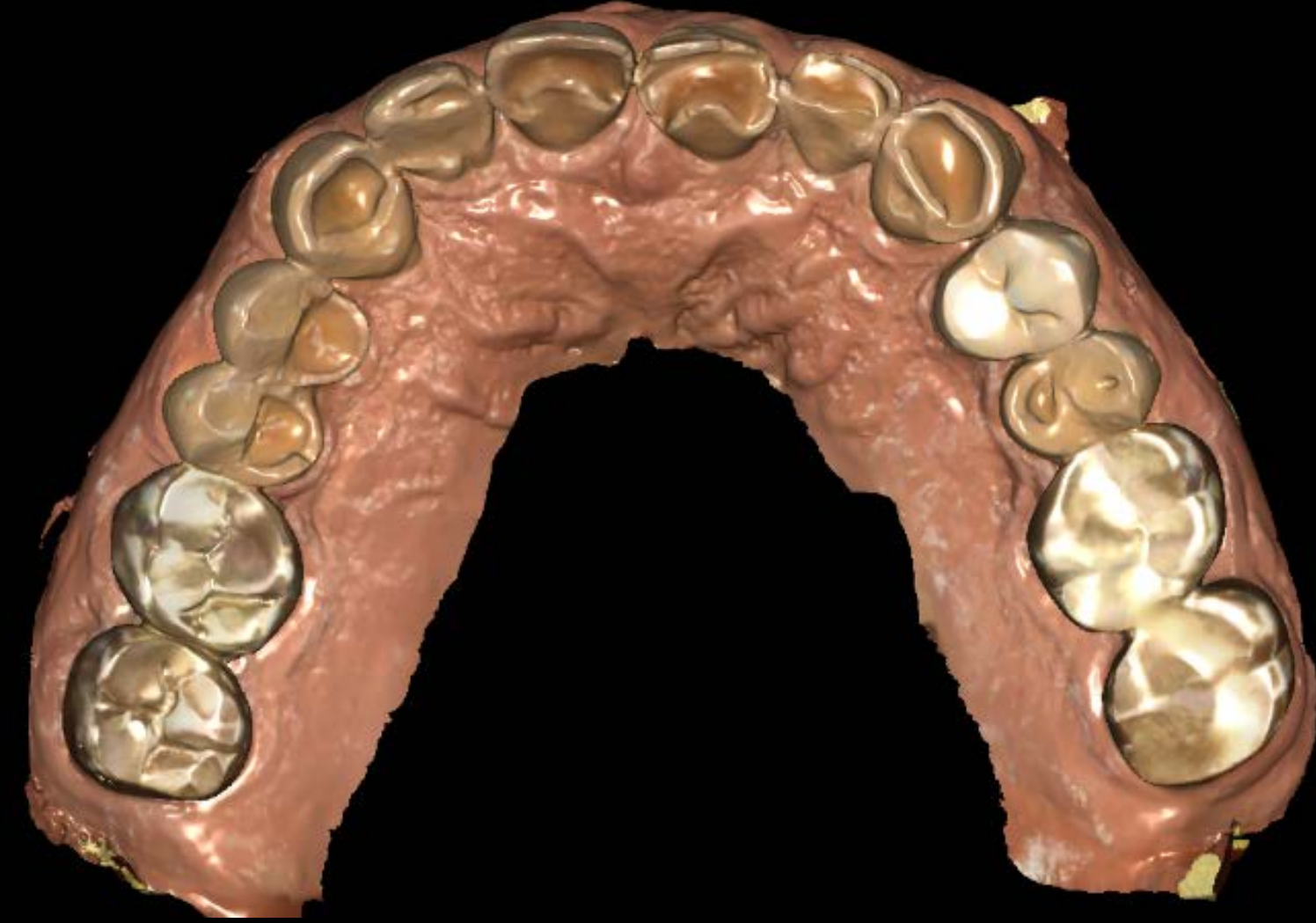BTS

Diverse applications of CT viewers

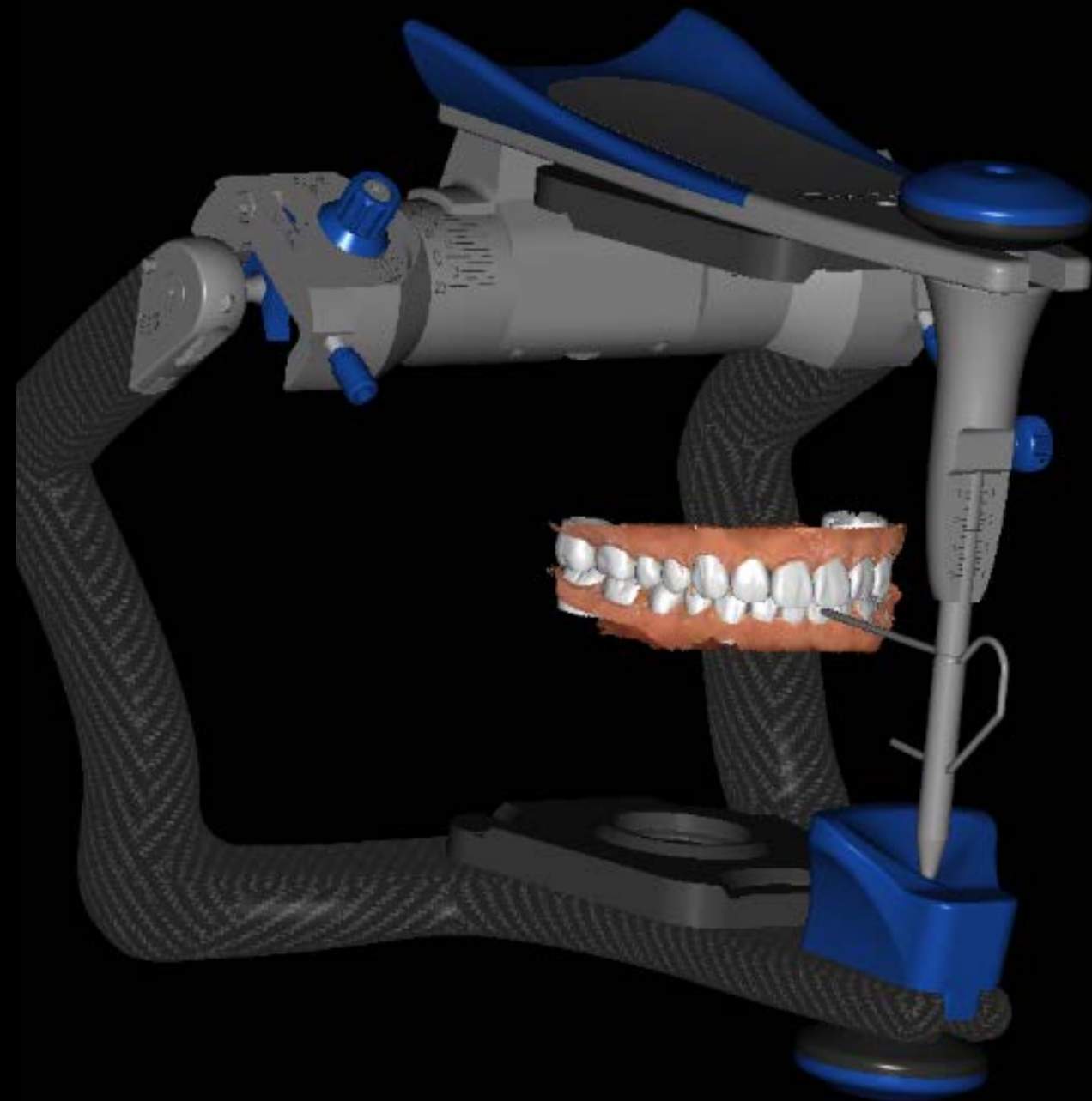
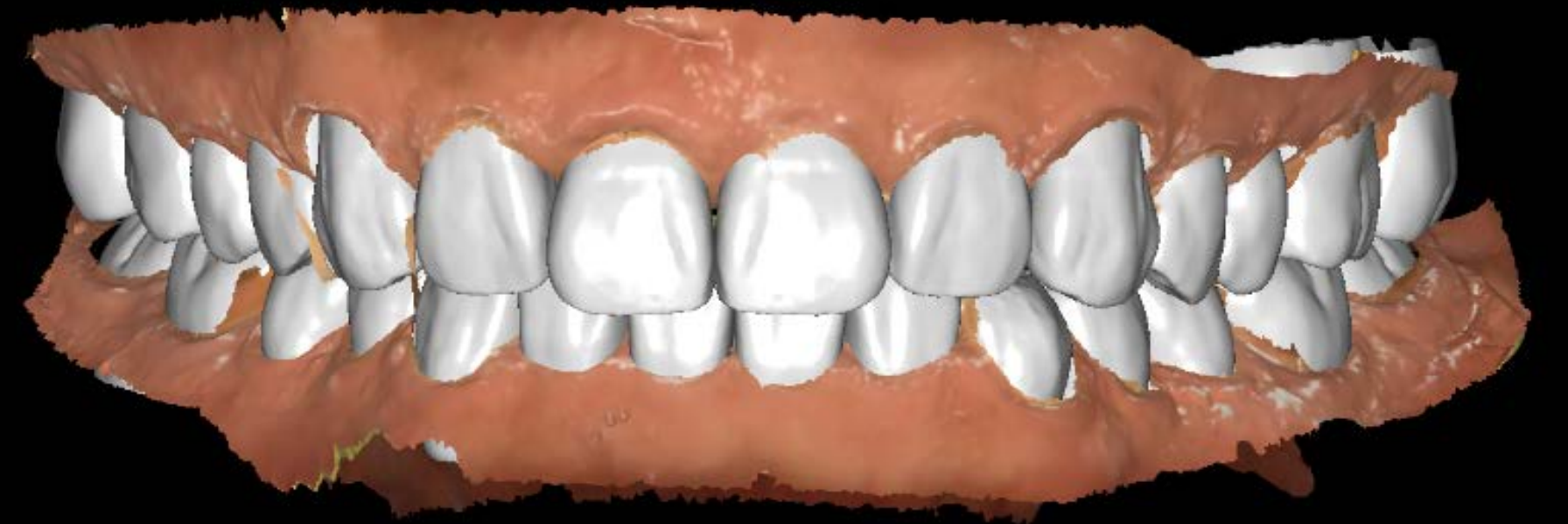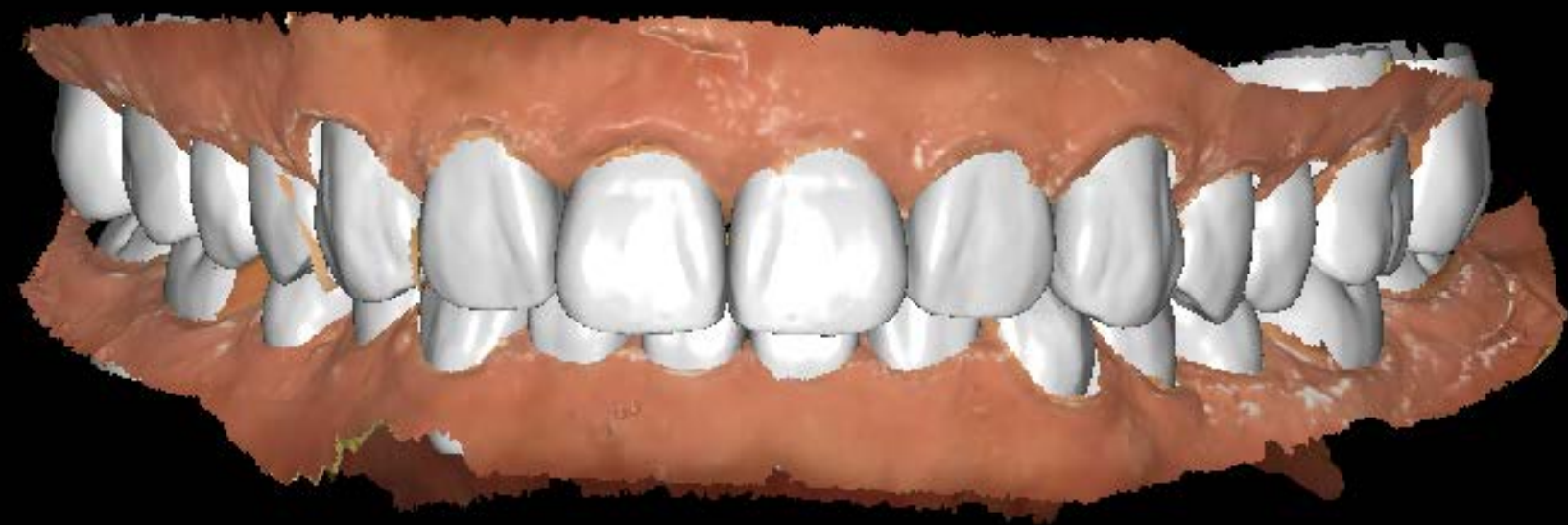Zirconia block

Auxiliary

Virtual Set up



Virtual Set up



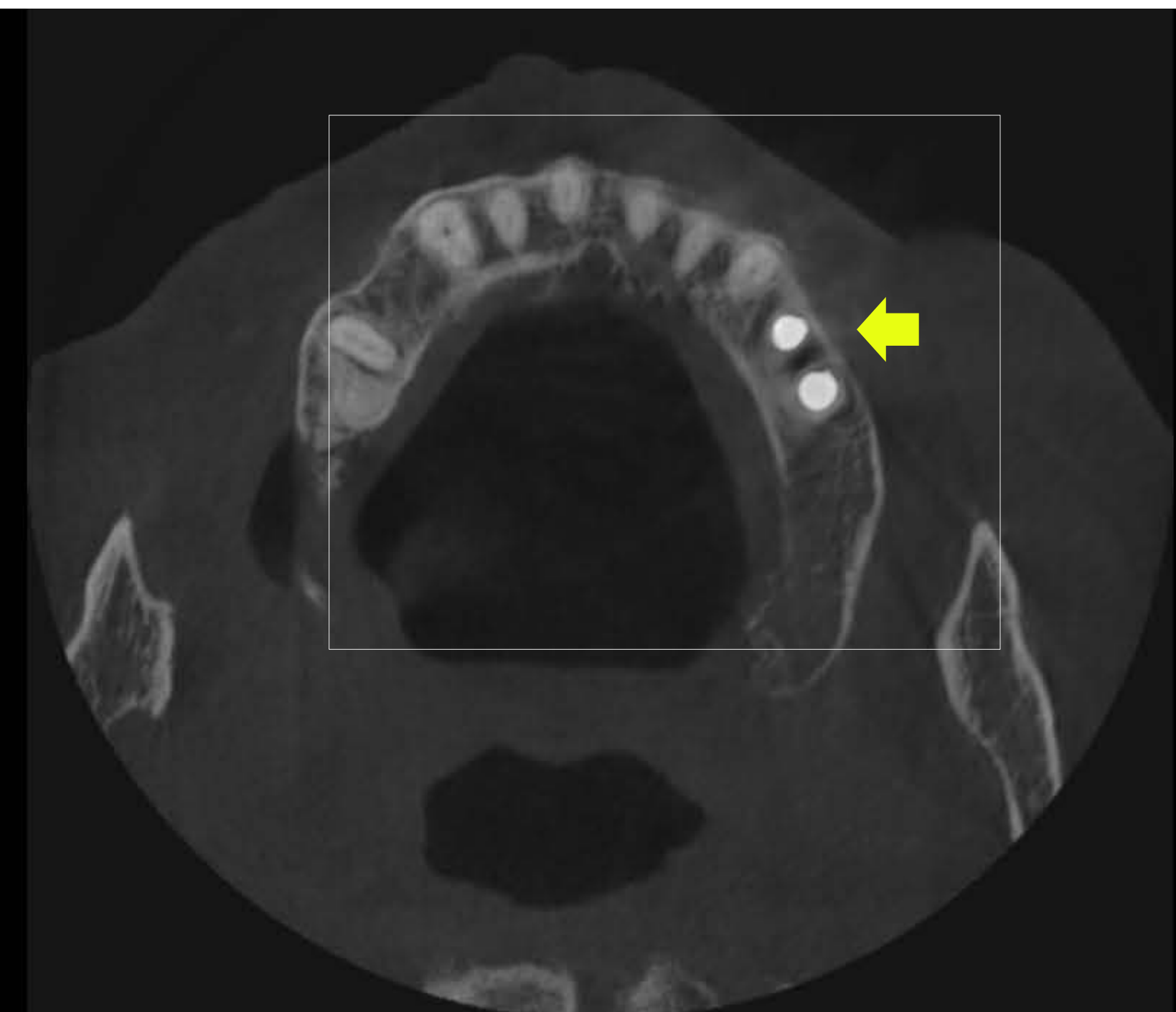
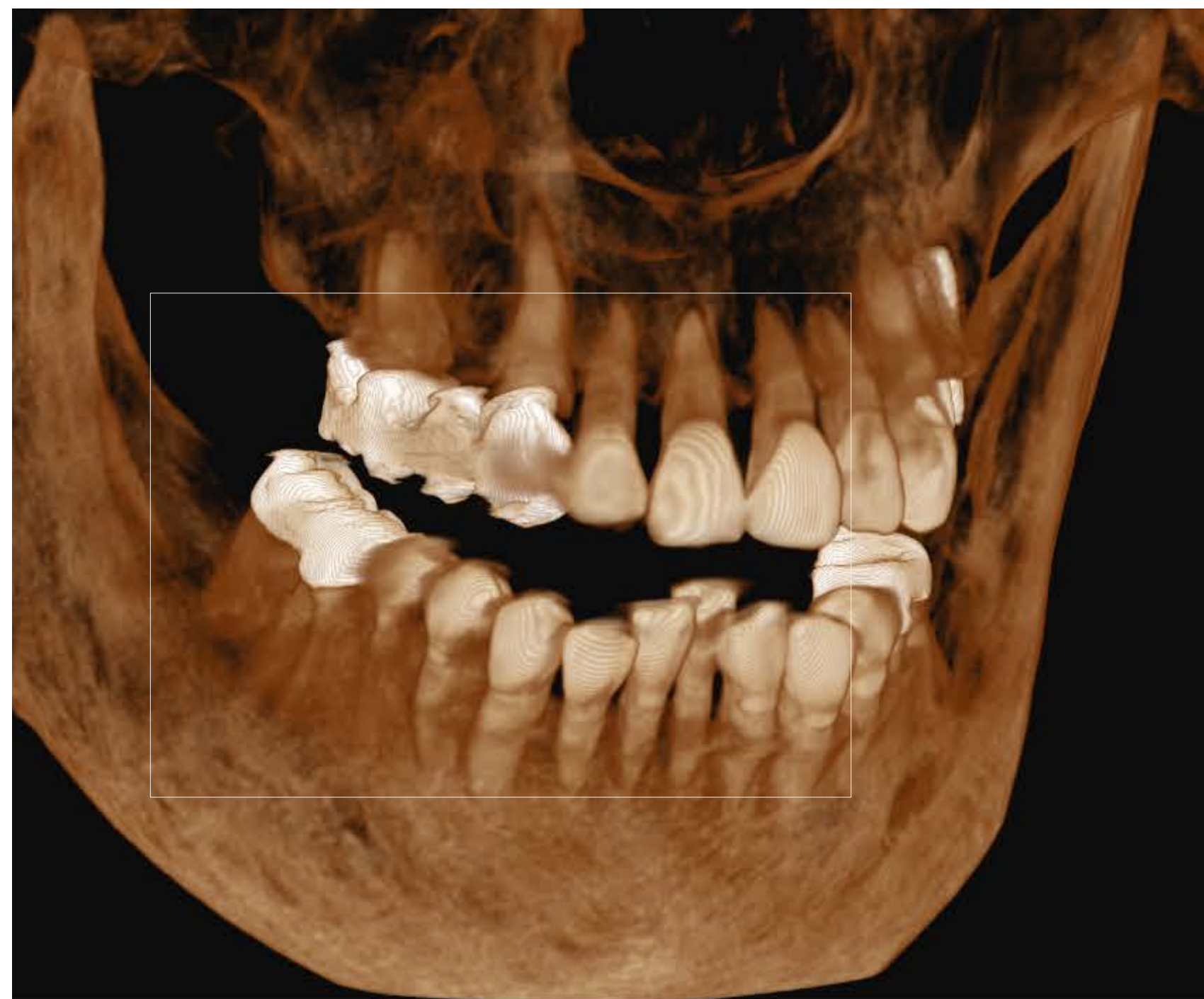VD 2mm ↑



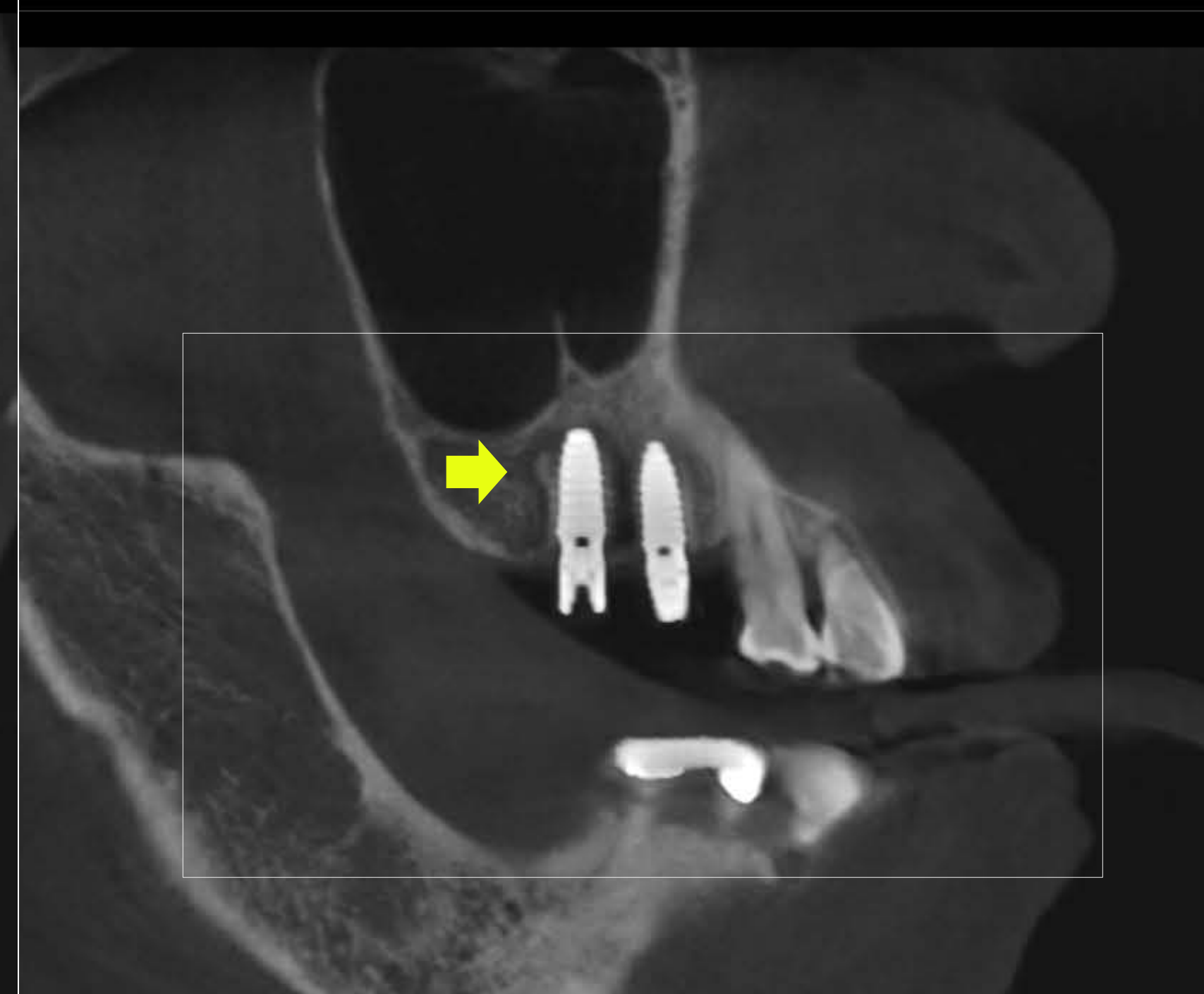
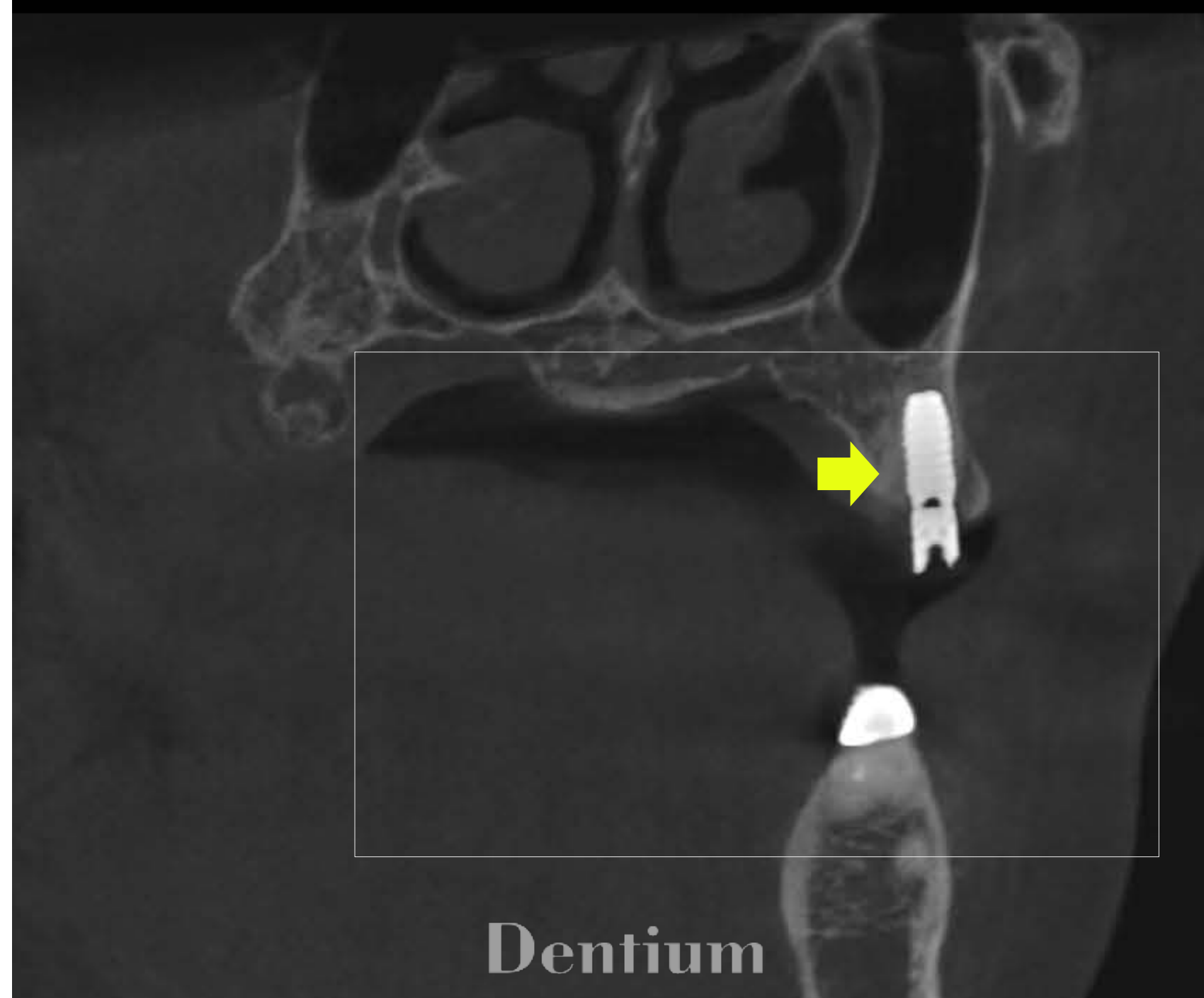
CT viewer
Bright CT and Rainbow CT



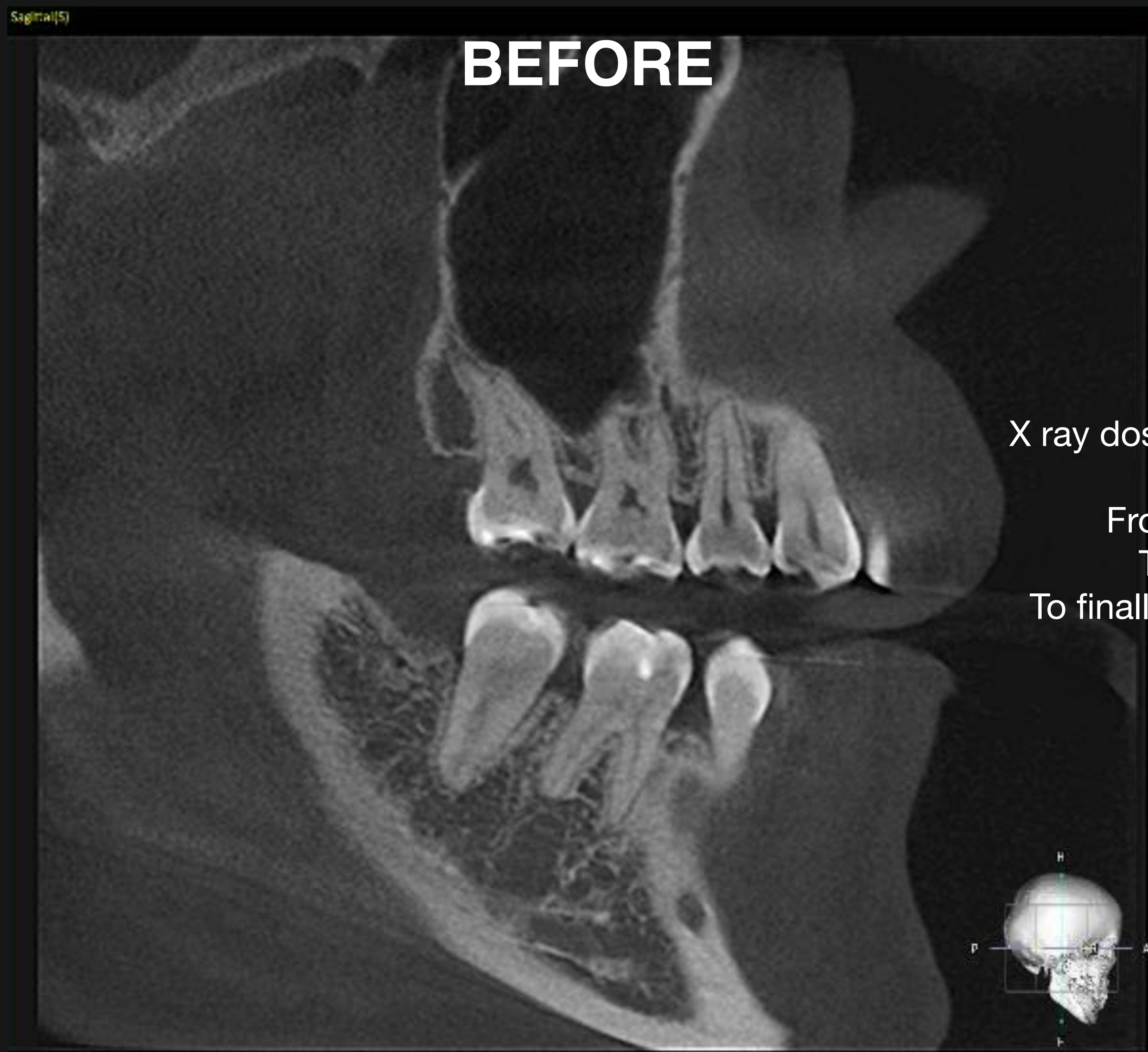
CT viewer of
Bright CT
Rainbow CT



MAR
(Metal Artifact Reduction)

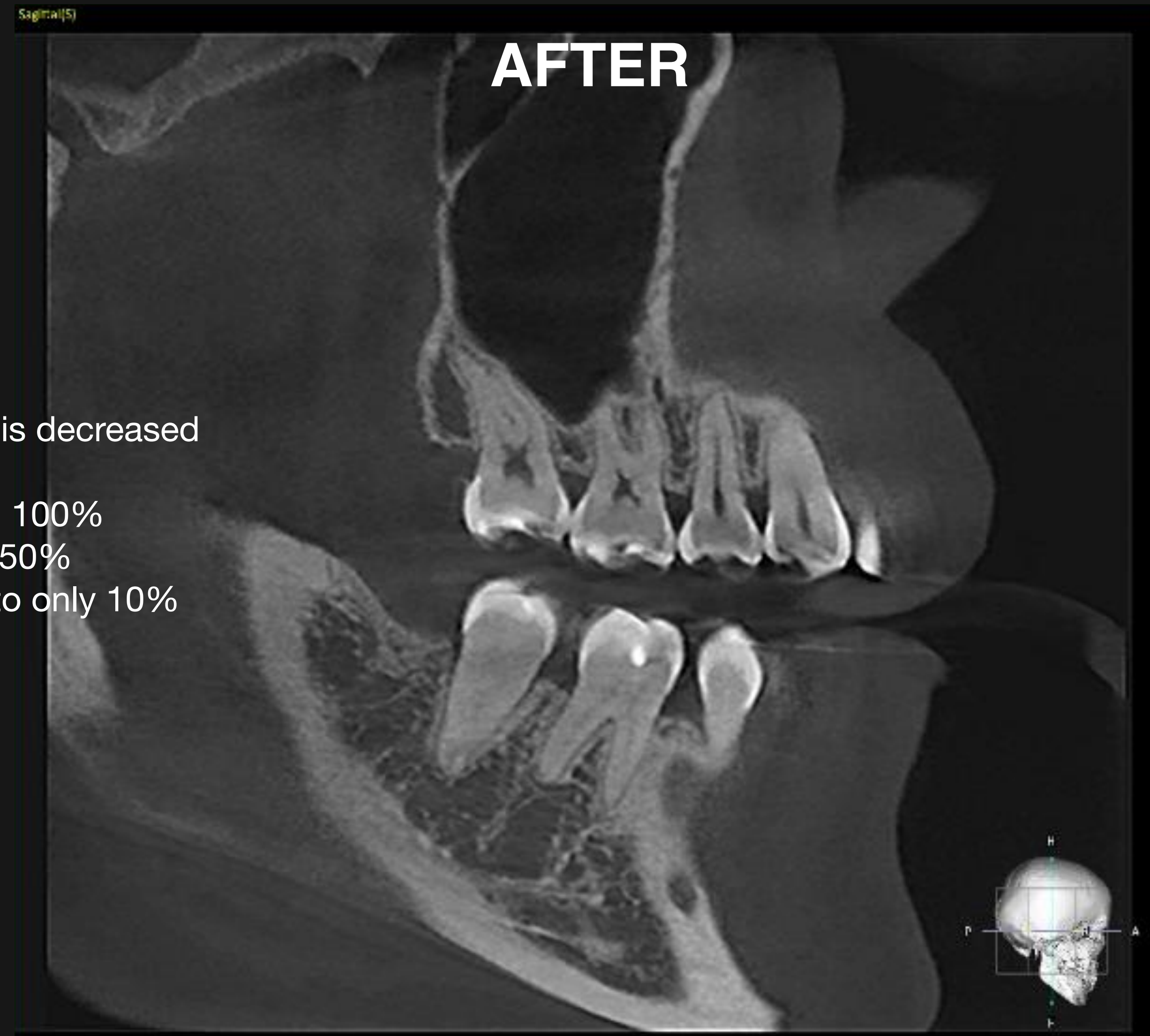


CT Image Upgrade **De-noising with A.I**



X ray dose is decreased

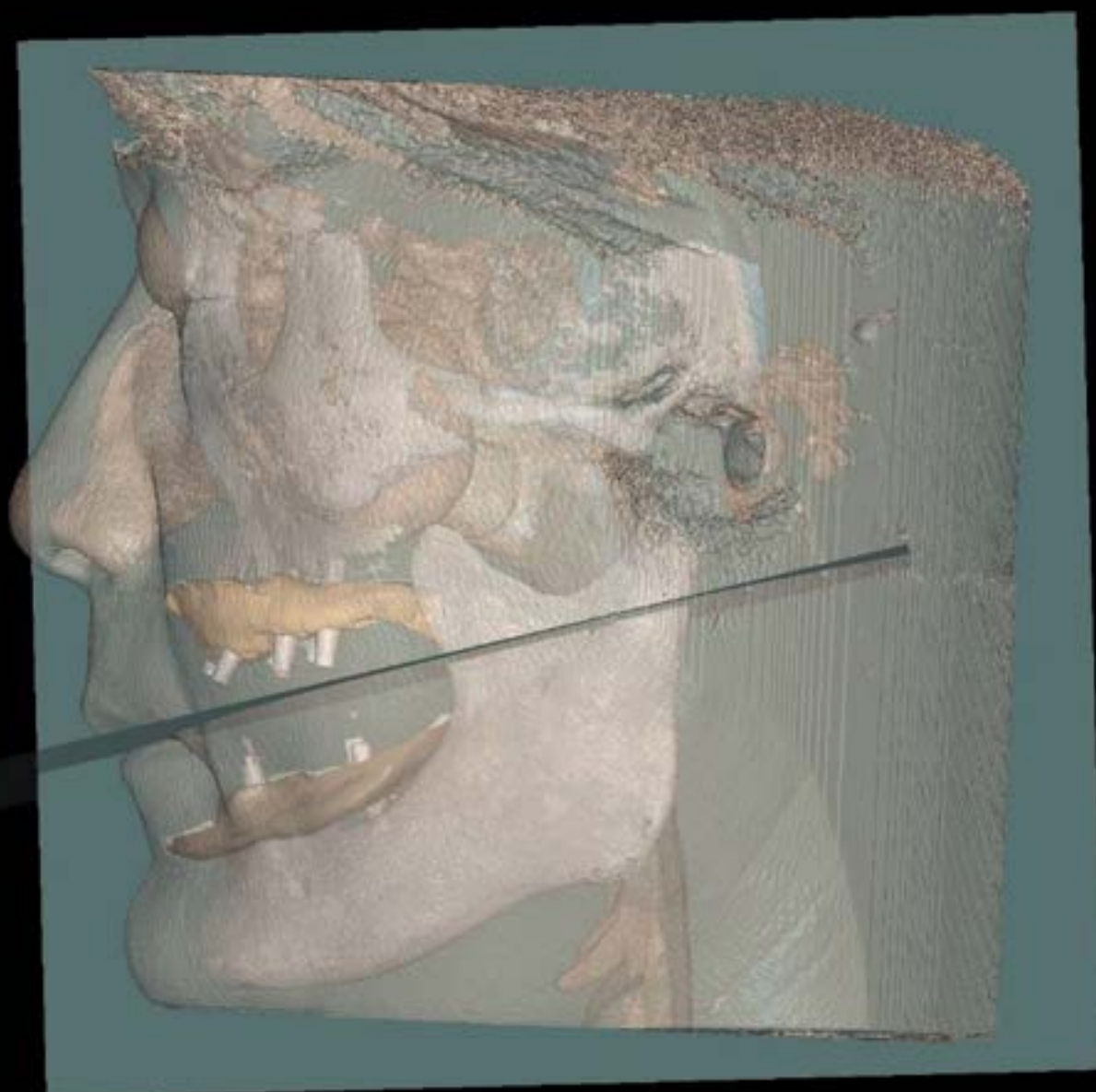
From 100%
To 50%
To finally to only 10%




Dentium



rainbowTM 3D Viewer



Digital dentistry with



AUTO



AUTO



AUTO




AUTO

3D Viewer **AI Occlusal Plane**



Auto Set occlusal plane from anatomical landmark on CT



Dentium

3D Viewer **AI Occlusal Plane**



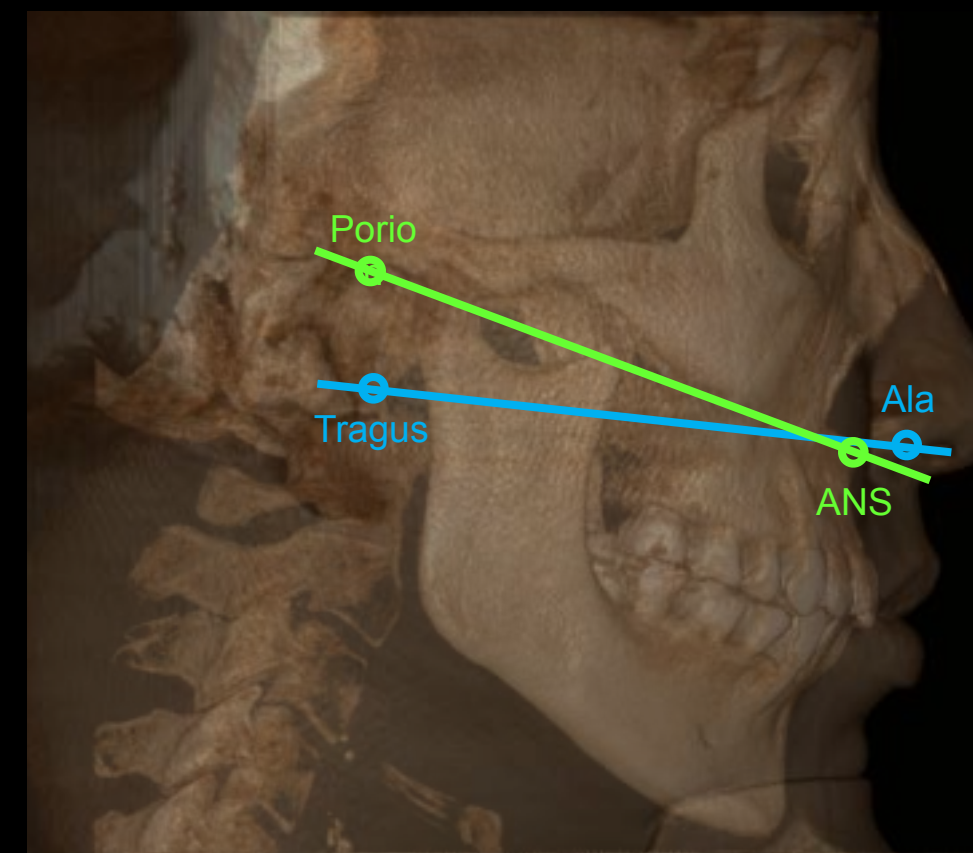
Auto Set occlusal plane from anatomical landmark on CT

1) Auto Set the plane

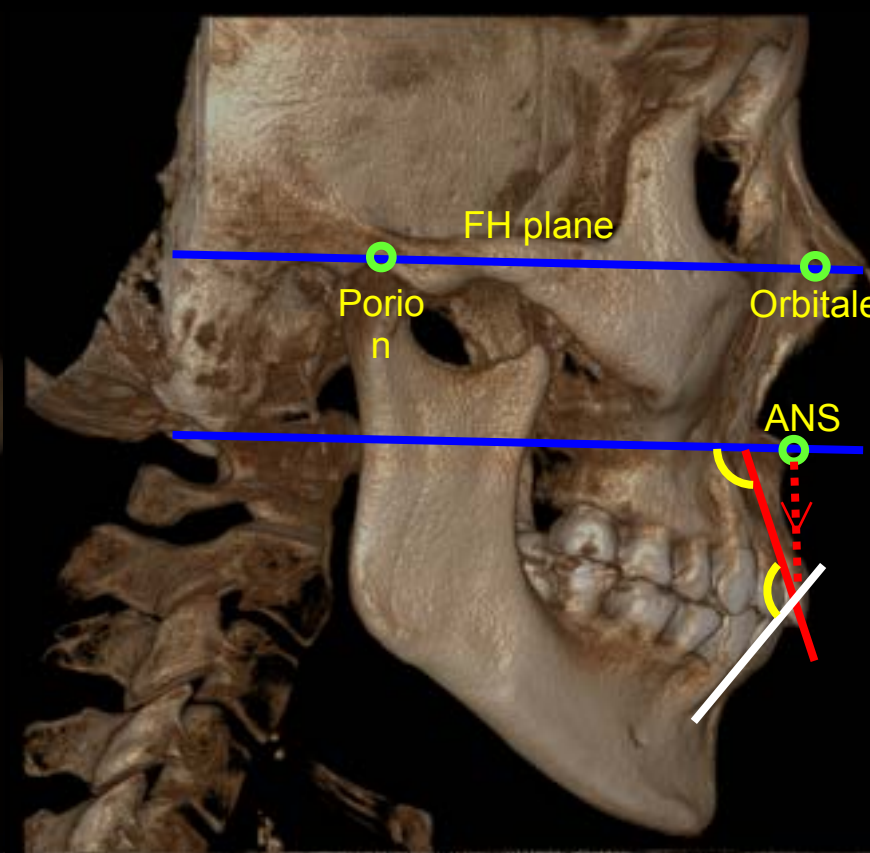
2) Export the CT data

3) All of data stitching

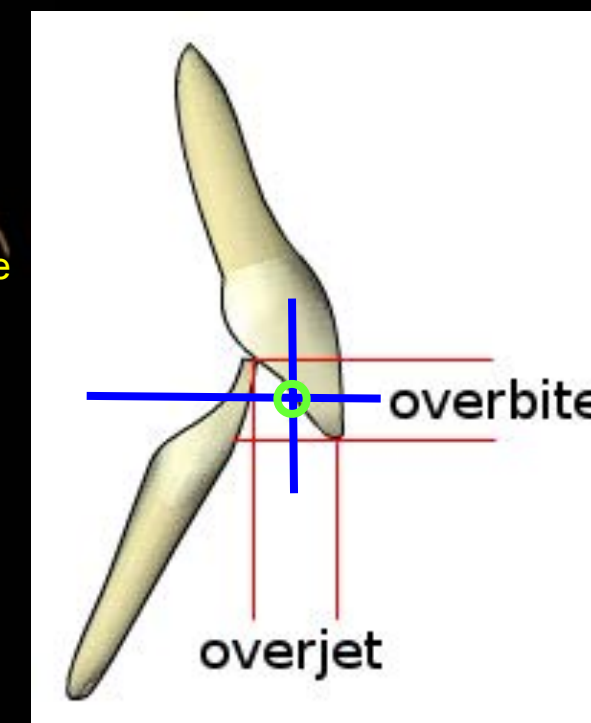
4) Prosthesis Design



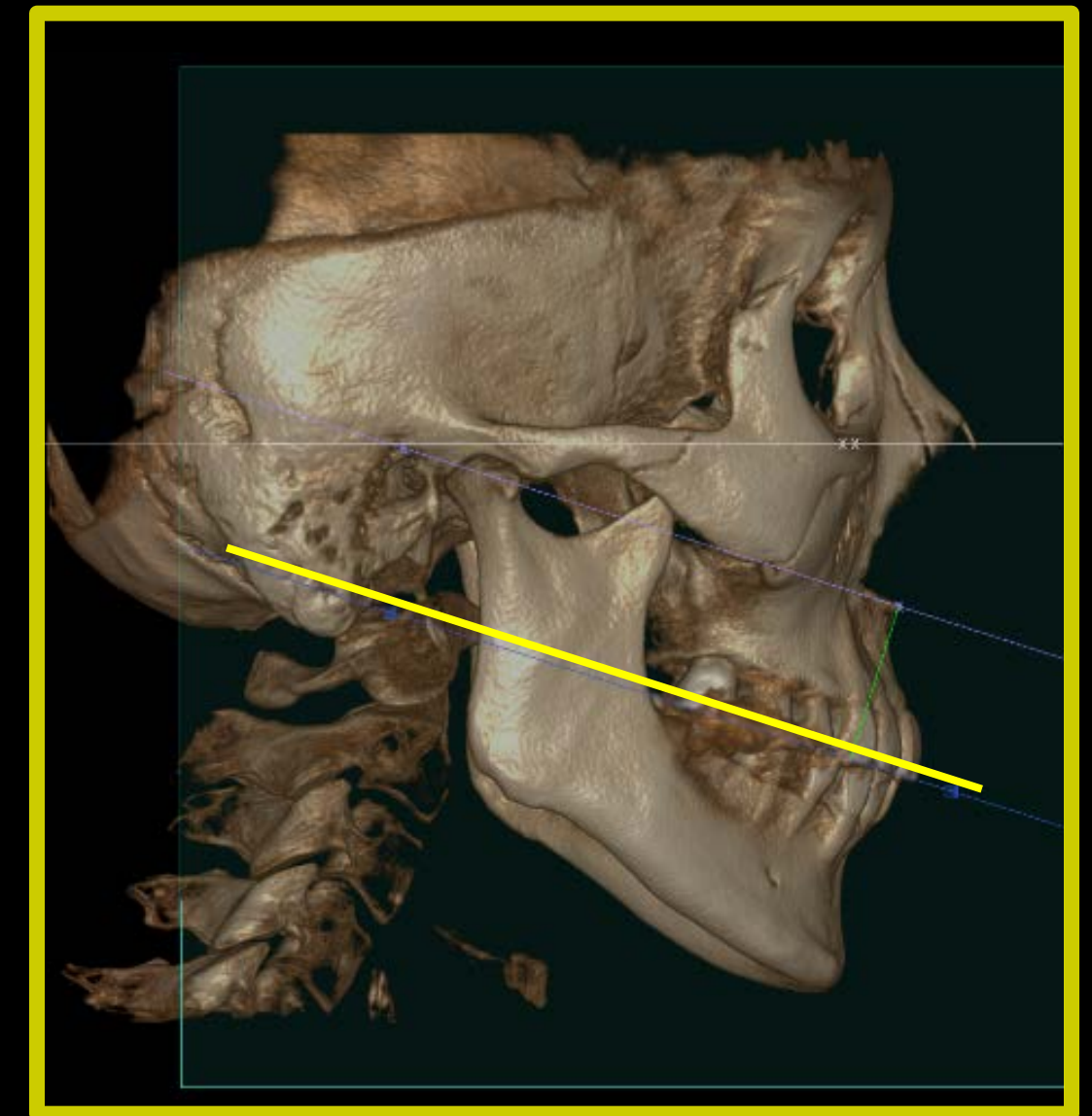1) Occlusal plan **angle**



2) Occlusal plan **Vertical height**



overbite, overjet : 2~3mm



3D Viewer **AI Occlusal Plane**



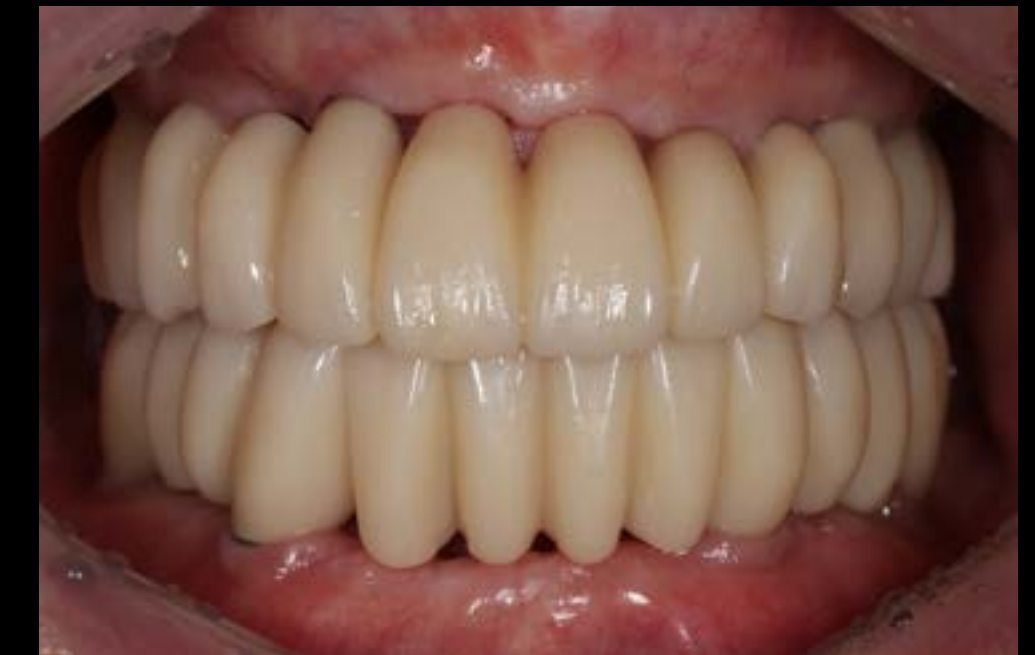
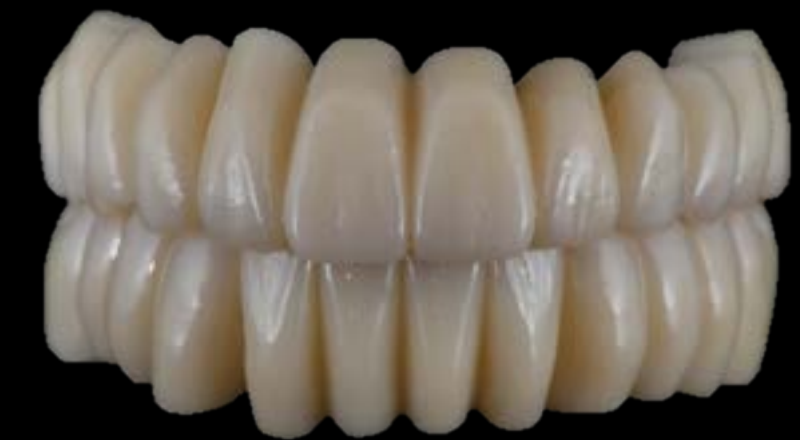Auto Set occlusal plane from anatomical landmark on CT

1) Auto Set the plane

2) Export the CT data


3) All of data stitching

4) Prosthesis Design

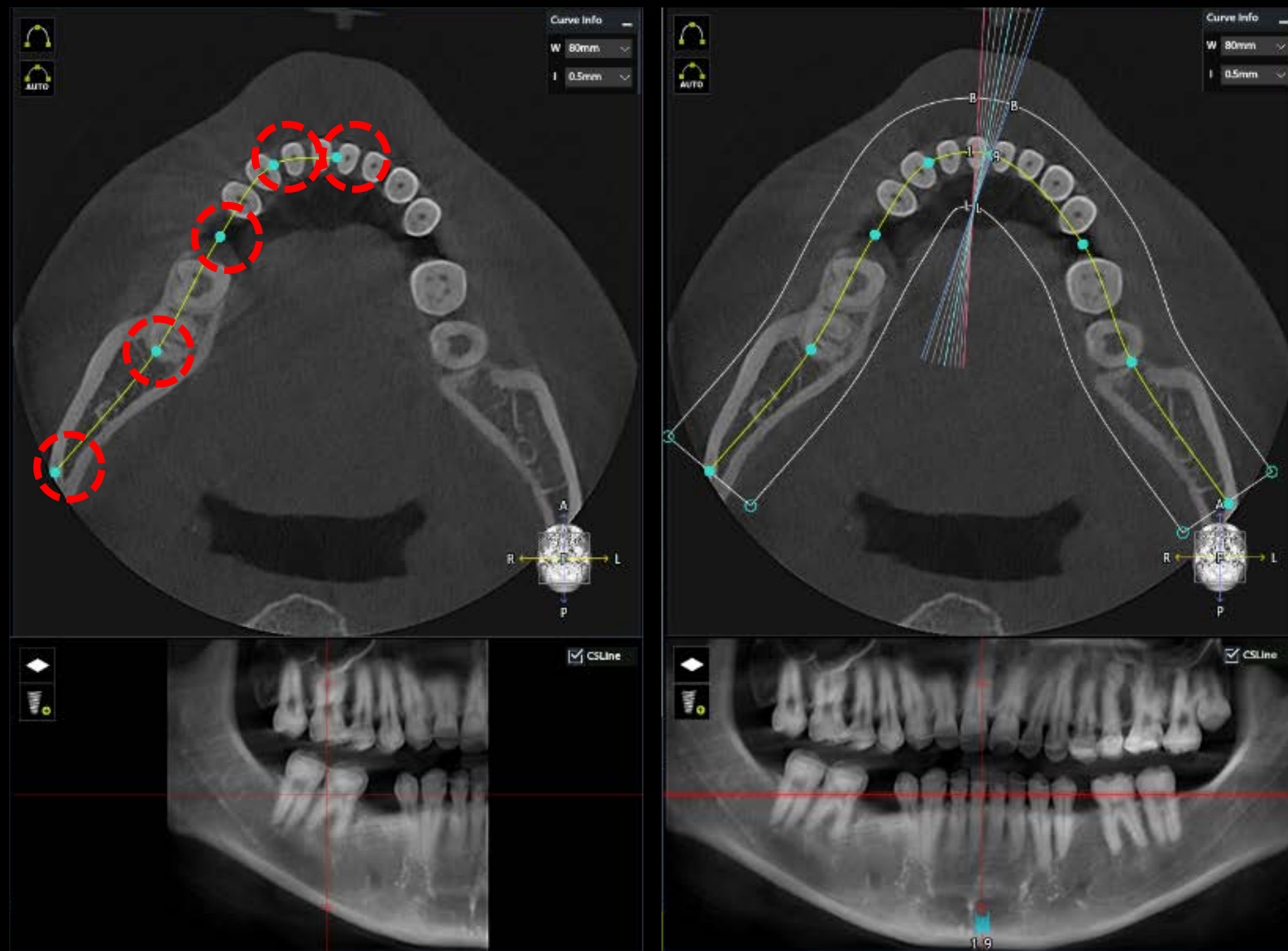


Final prosthesis

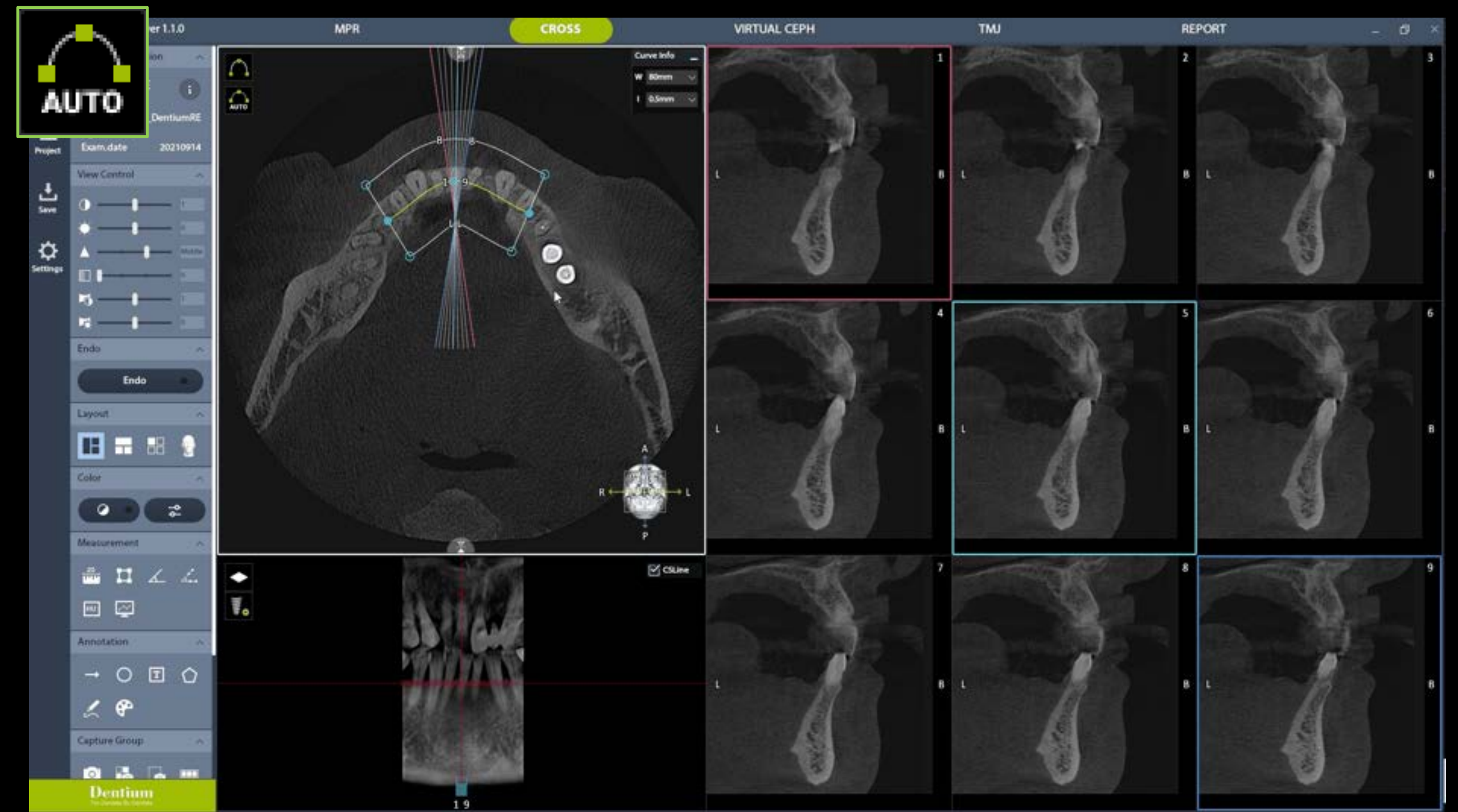

3D Viewer **AI Auto Arch Detection**



AI Auto Arch Detection



Manual

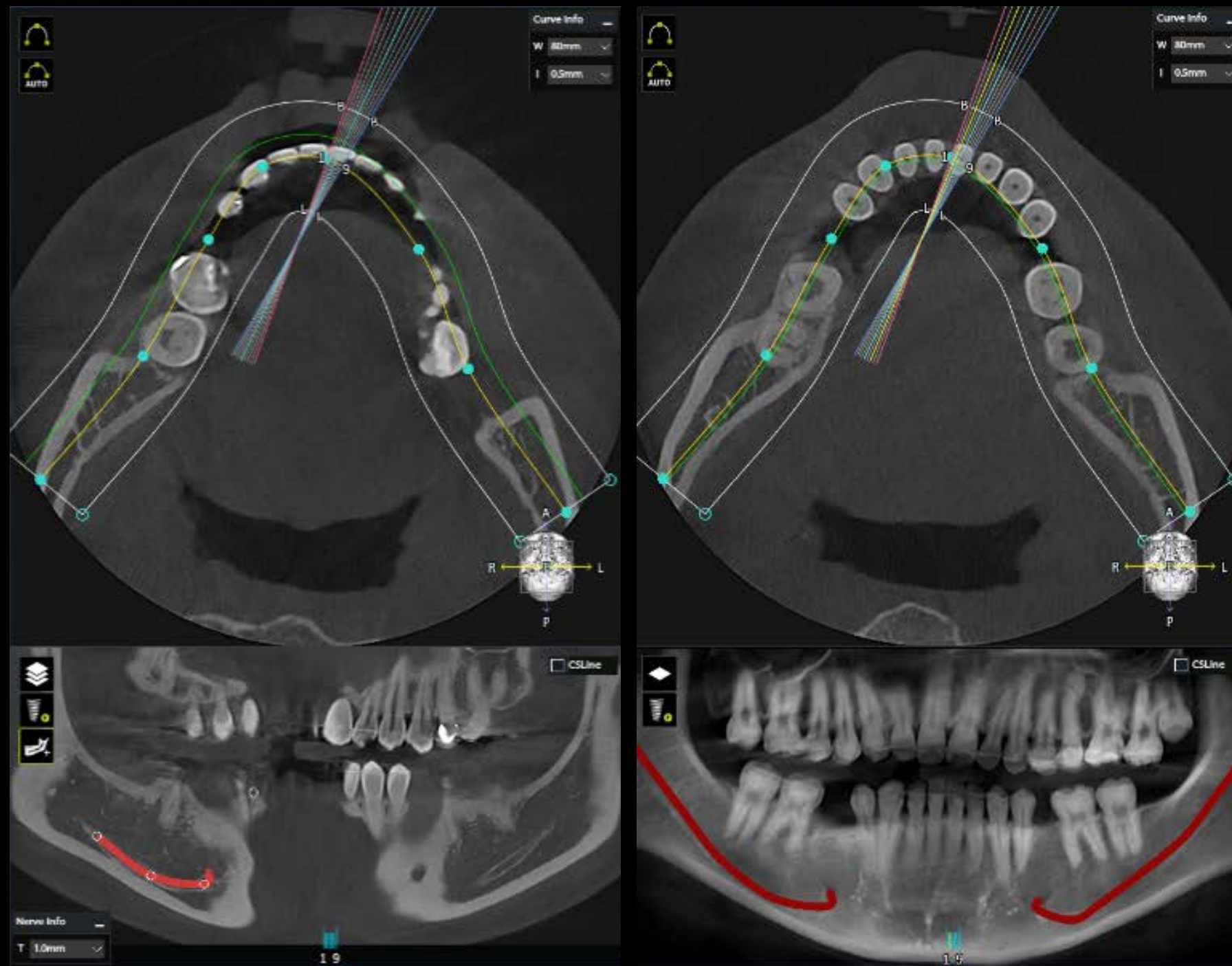


AI dental arch auto detection, error $<1.14\text{mm}$

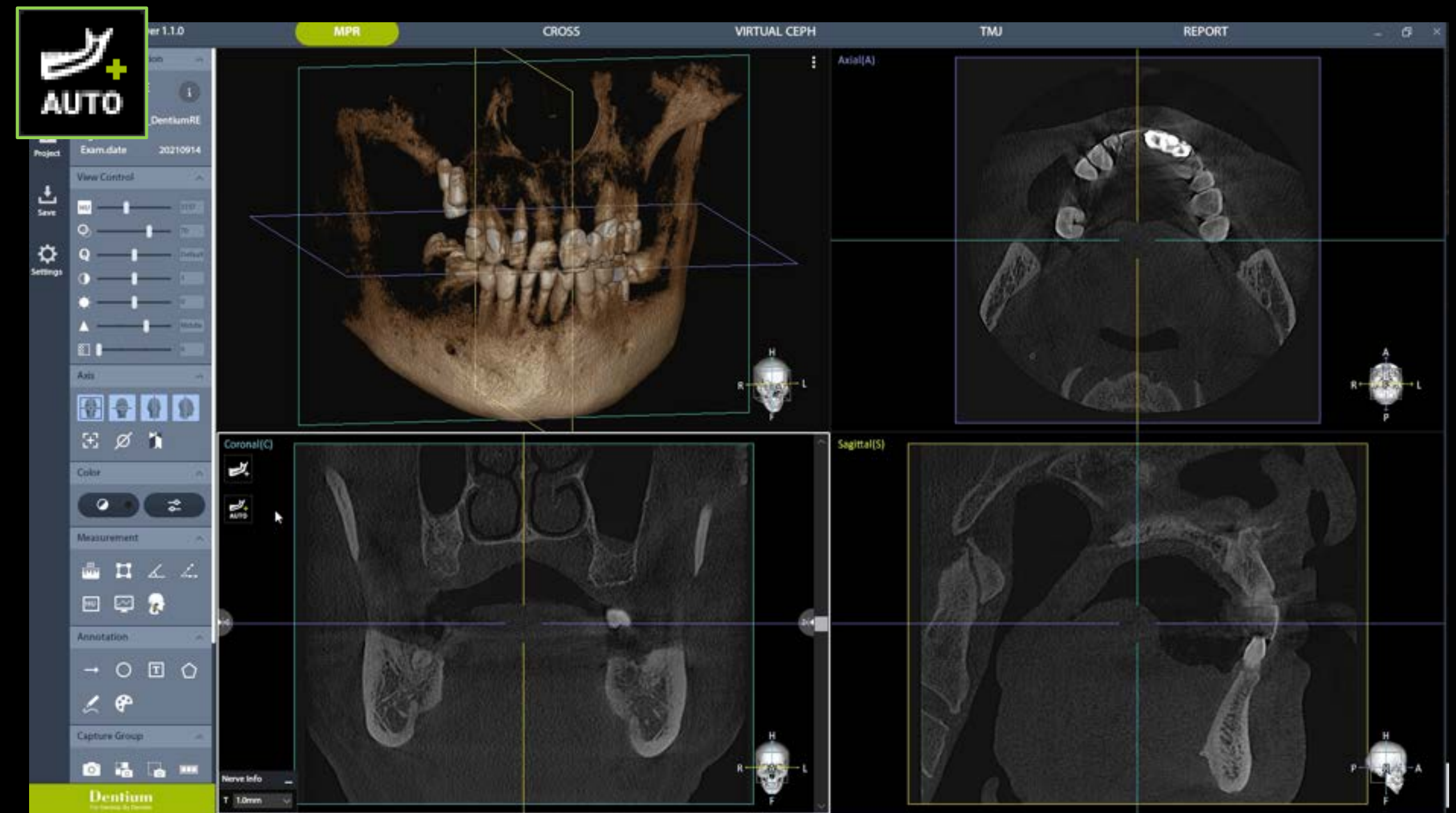
3D Viewer **AI Auto Nerve Detection**



AI Auto Nerve Detection



Manual



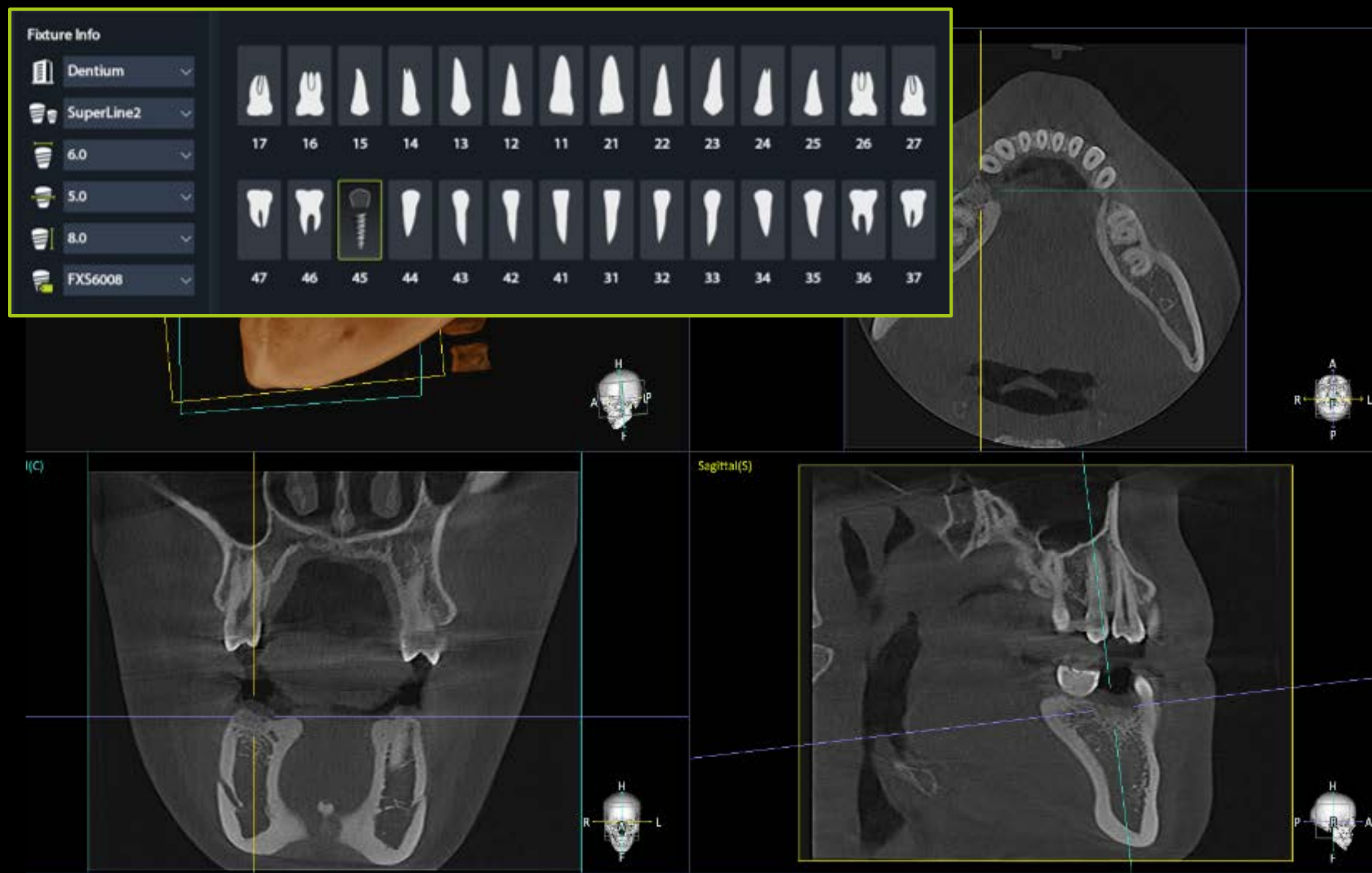
AI nerve auto detection, error < 0.42mm

Dentium

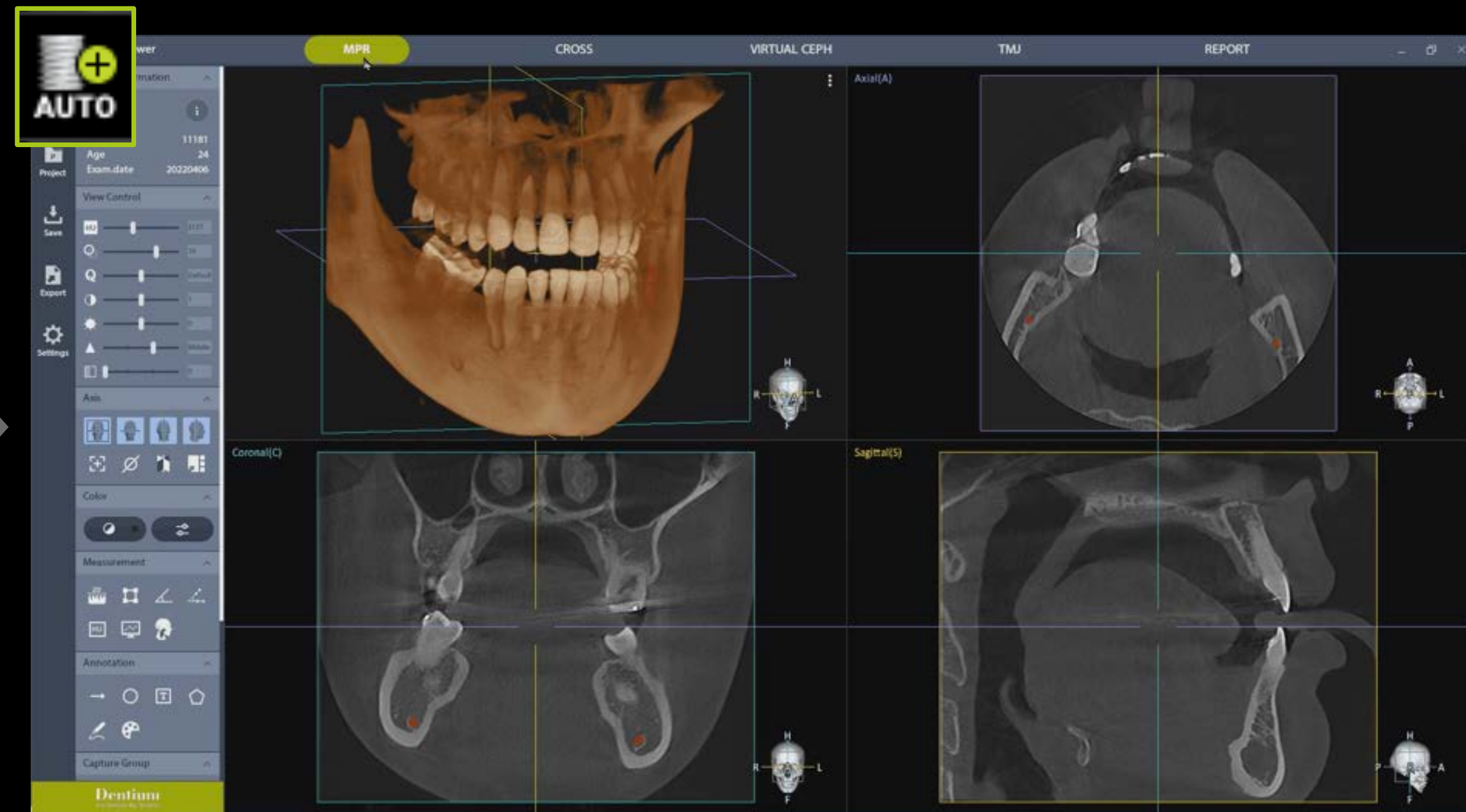
3D Viewer **AI Auto Fixture Placement**



AI Auto Fixture Placement



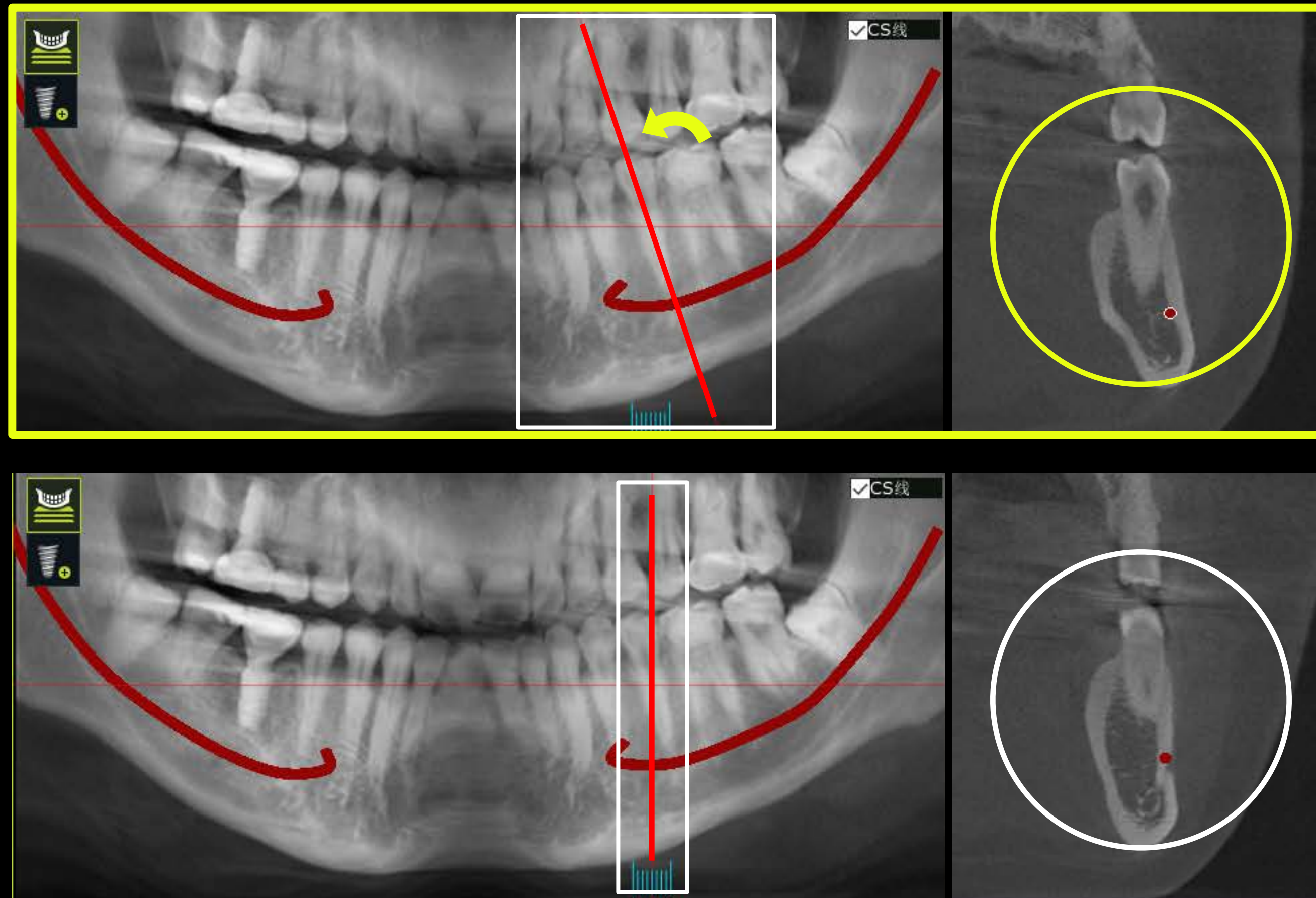
Manual



AI Fixture Initial Positioning

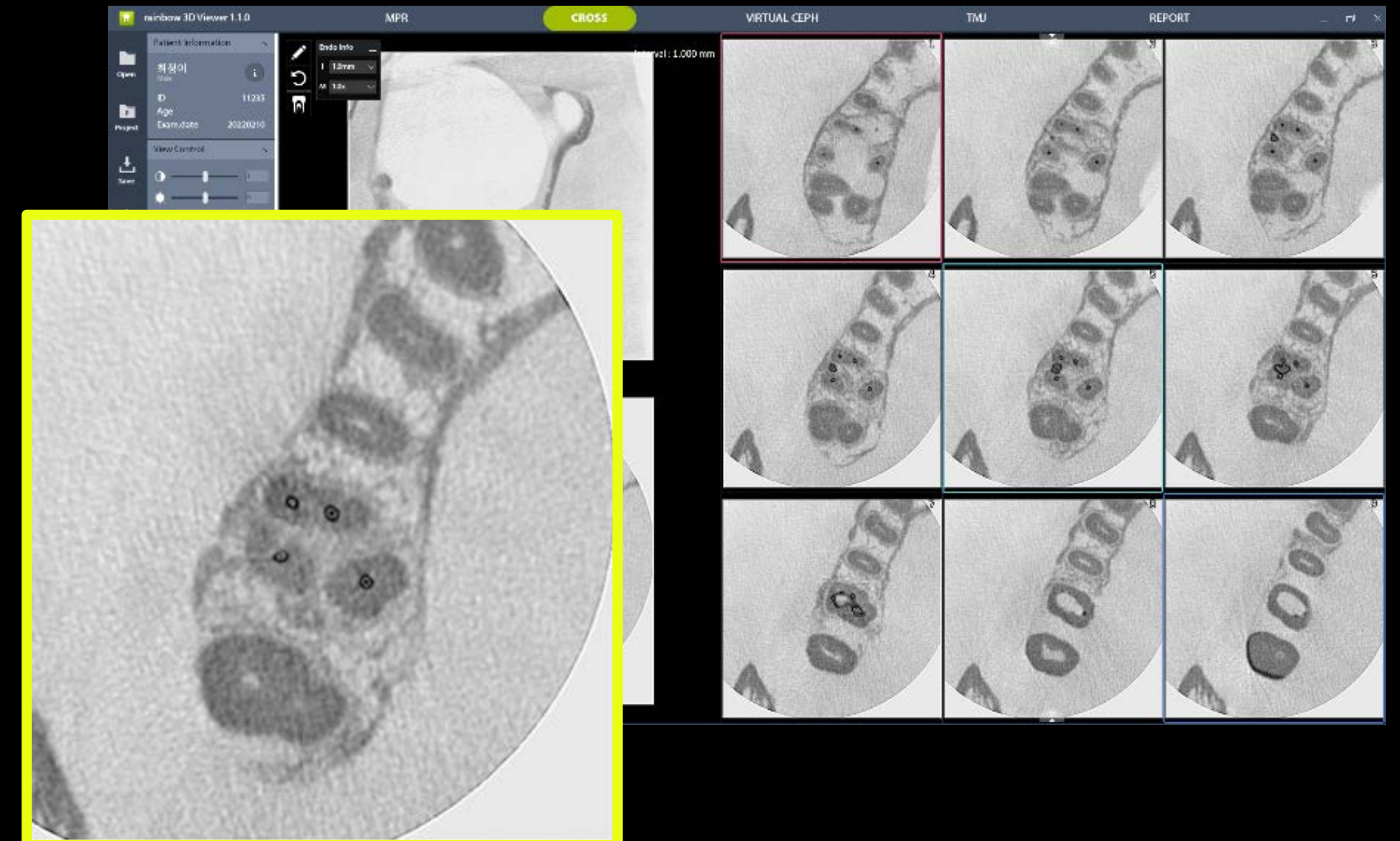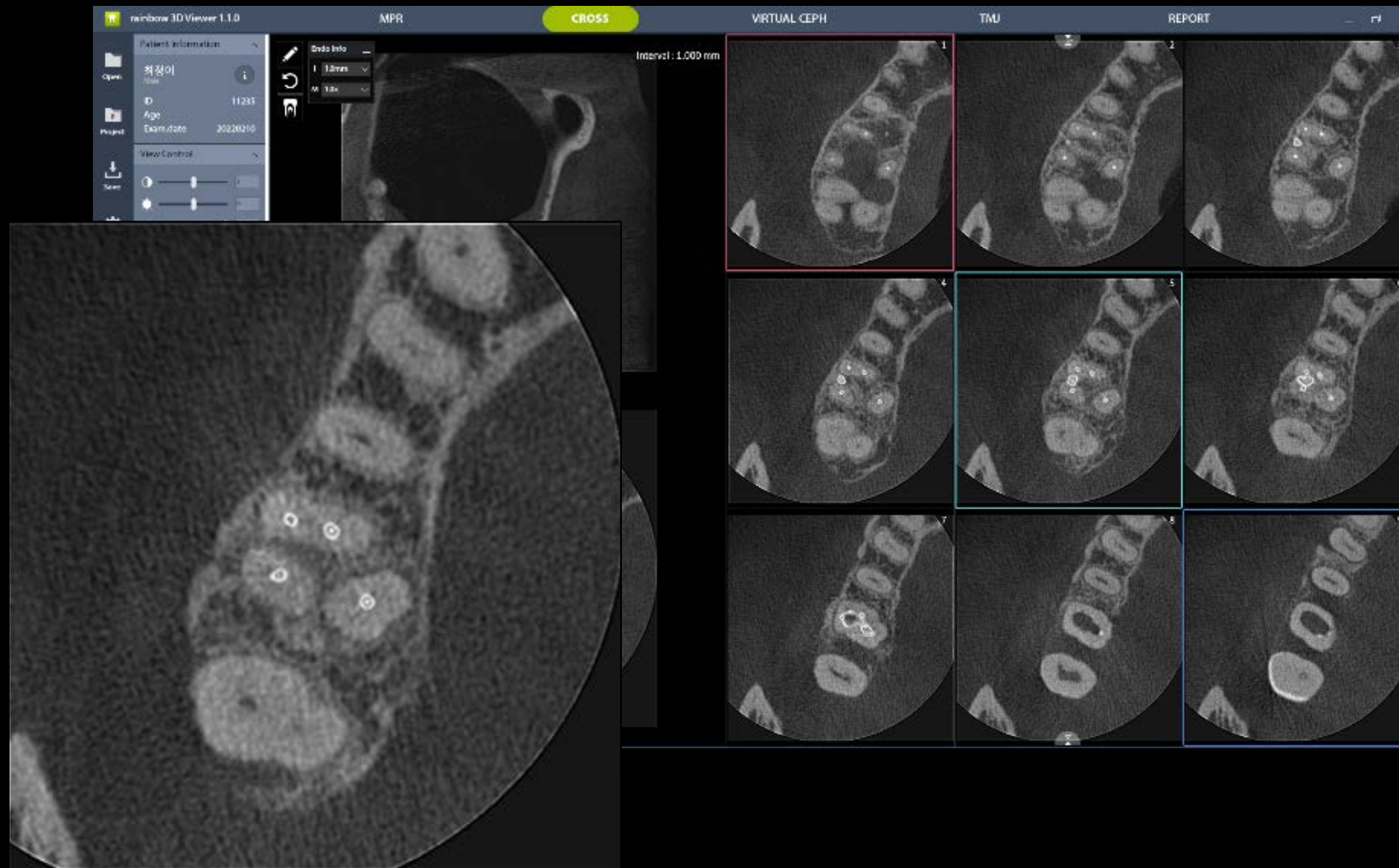
Root Axis Viewer

Supports cross-sectional images base on the root axis in panorama



3D Viewer **Endo View Visualization**

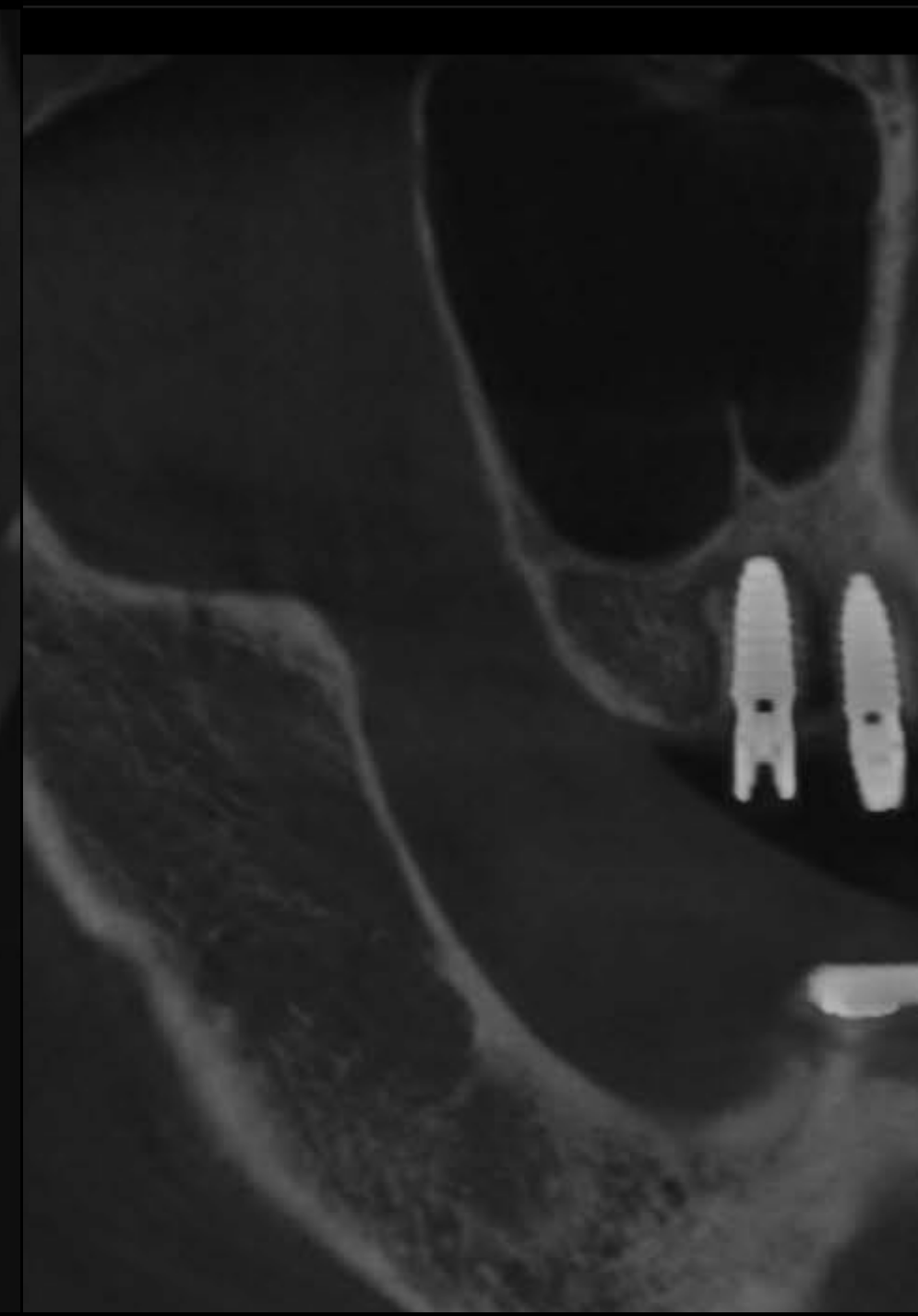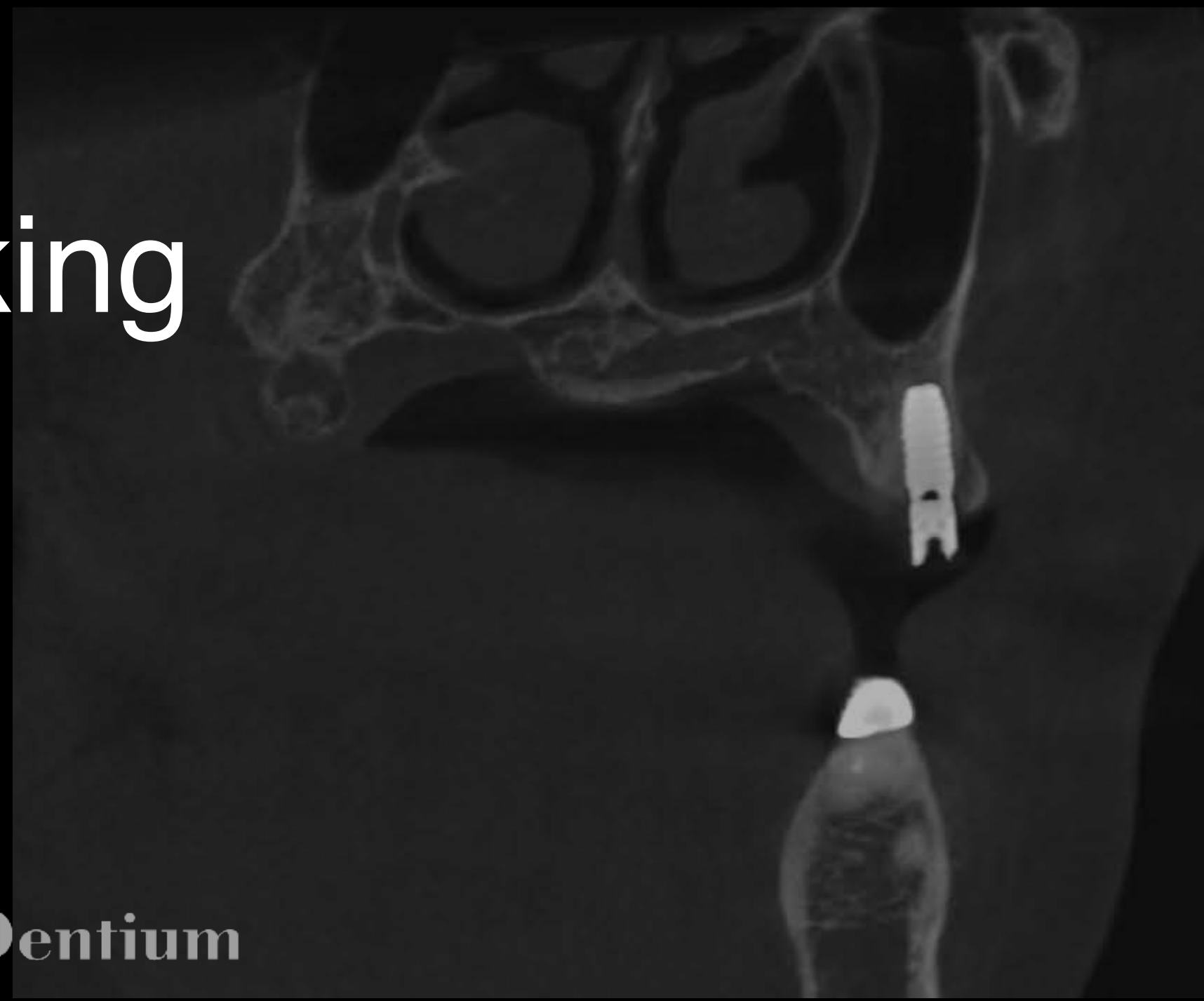
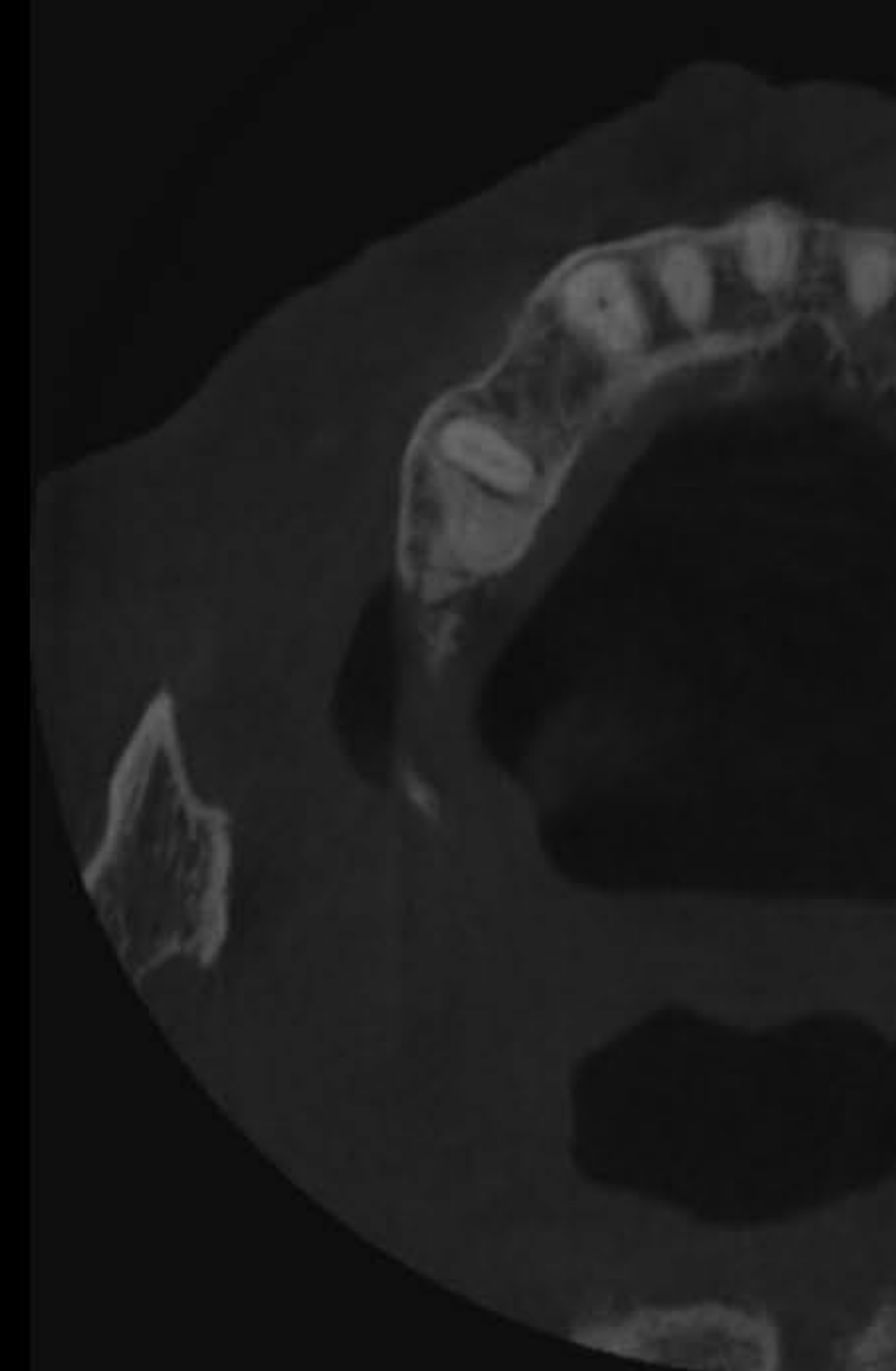
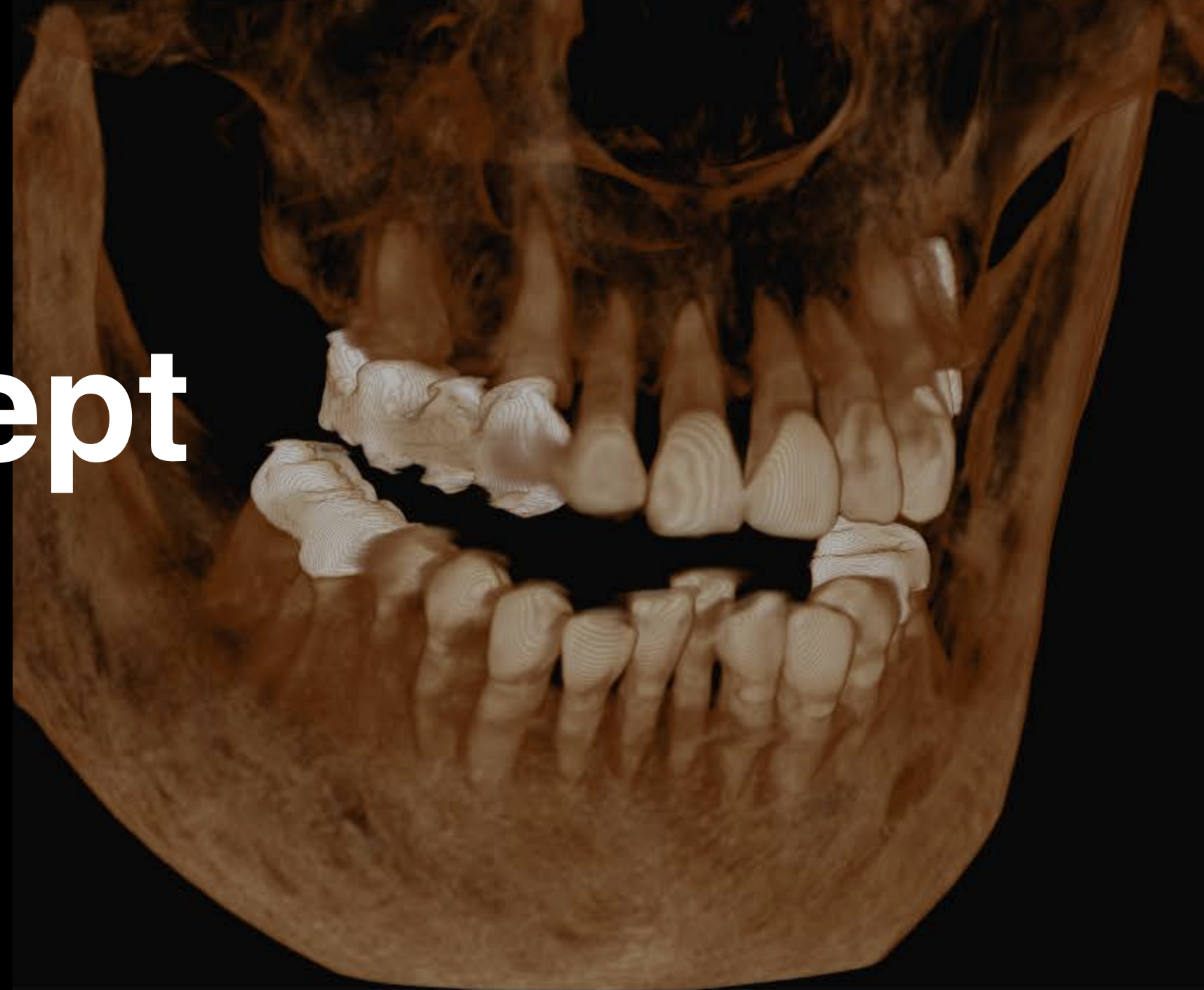Endo View Visualization



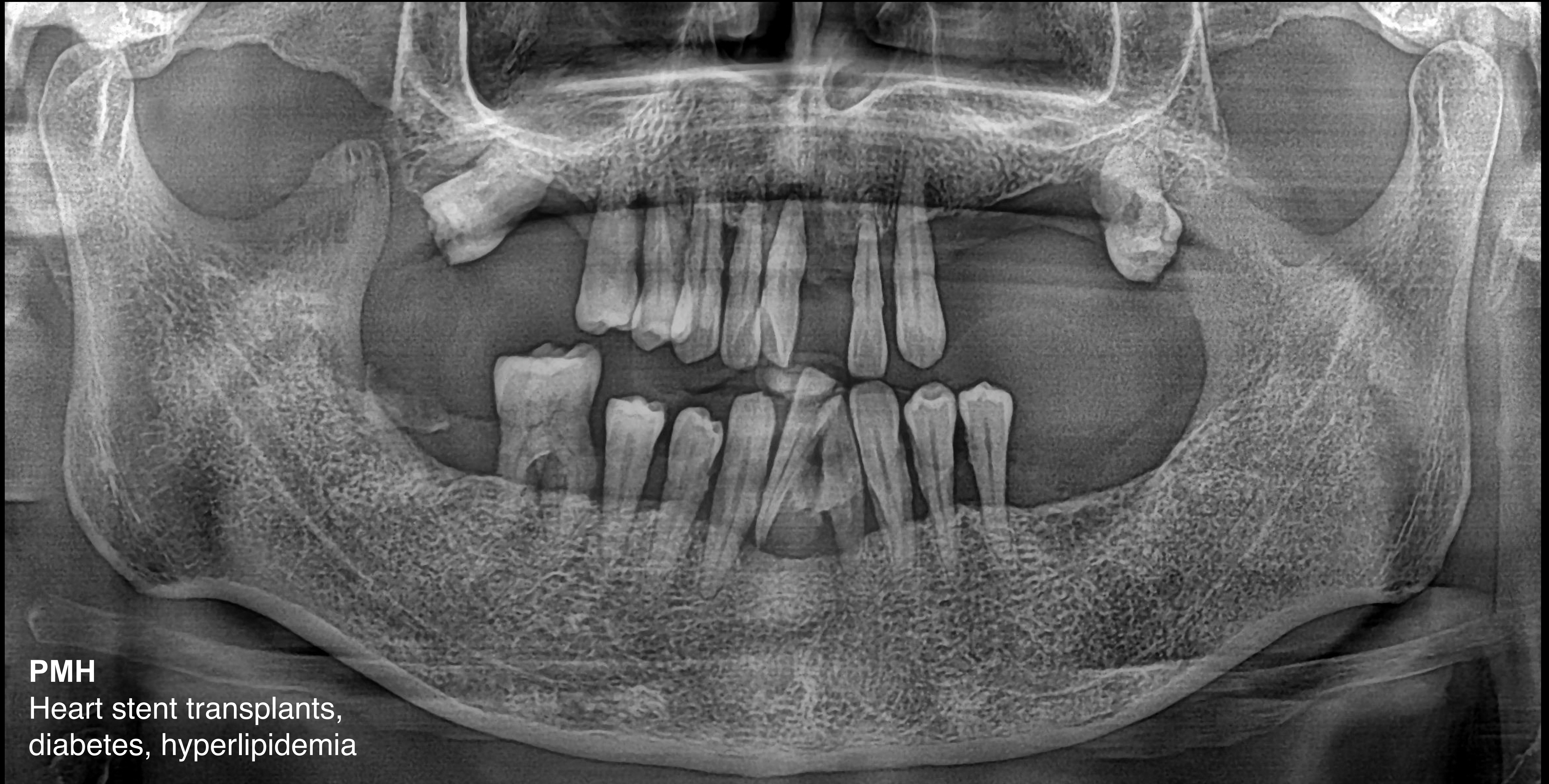Practical digital concept

Utilization of CT data

- CT stitching for bite taking
- AI Occlusal plane



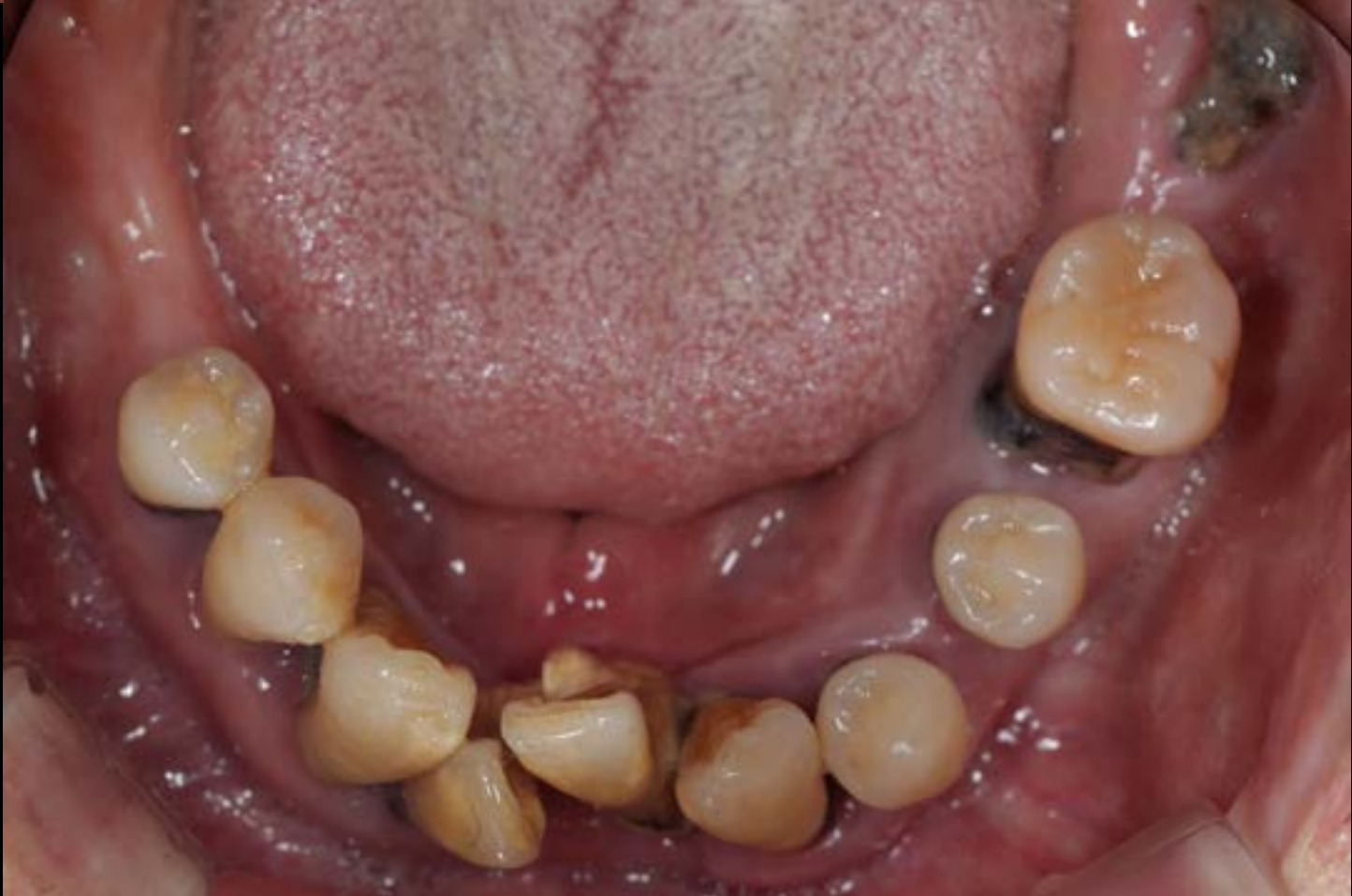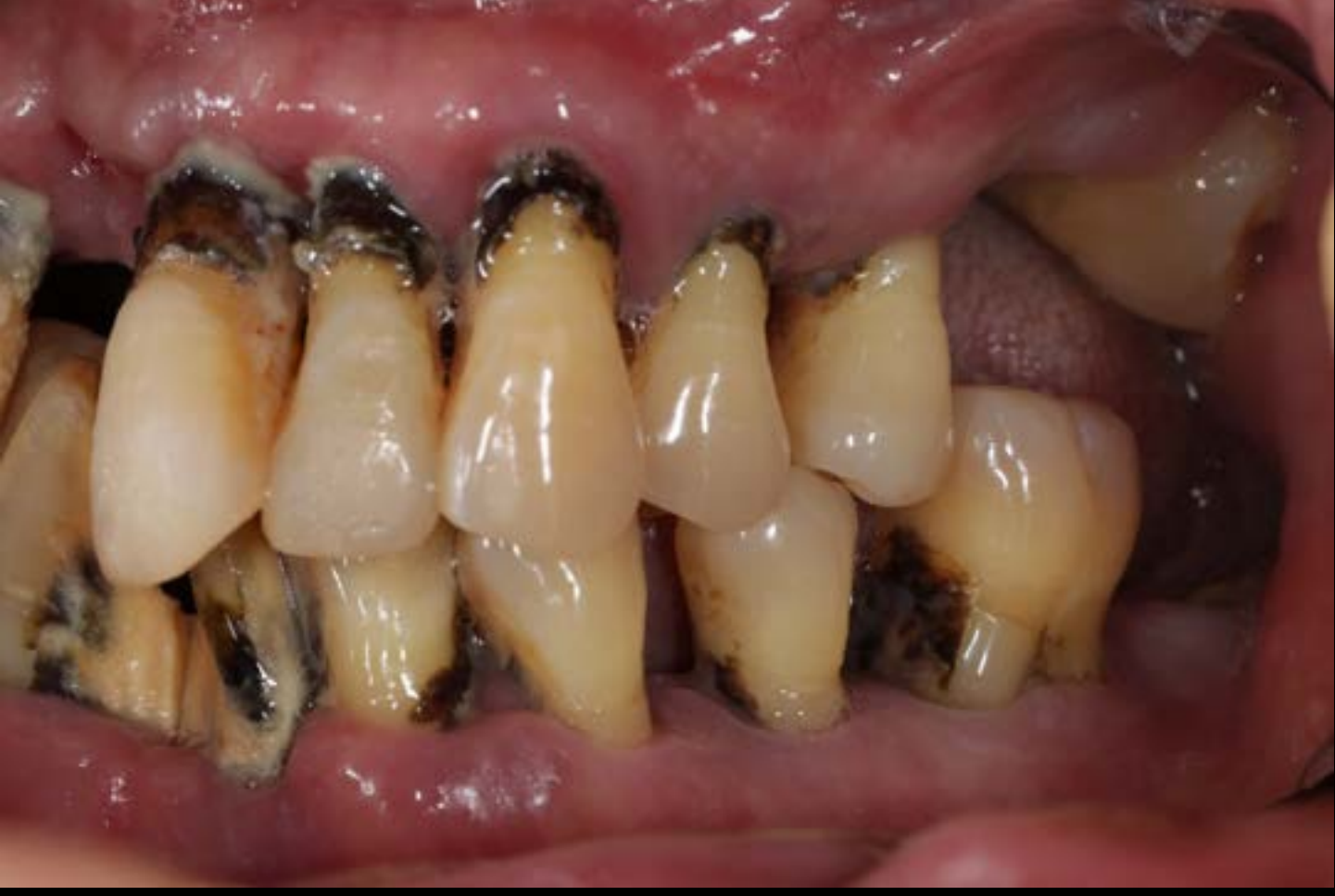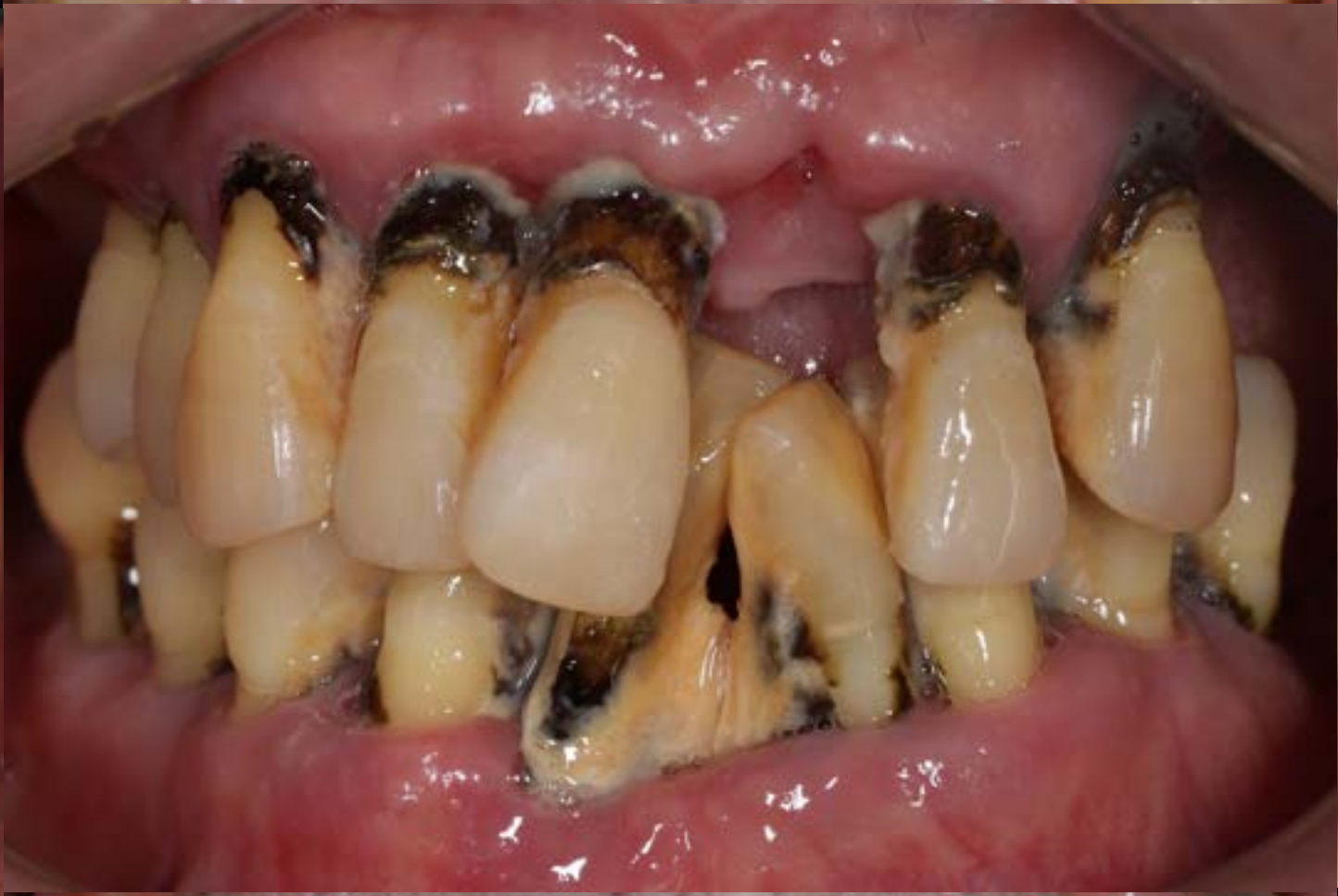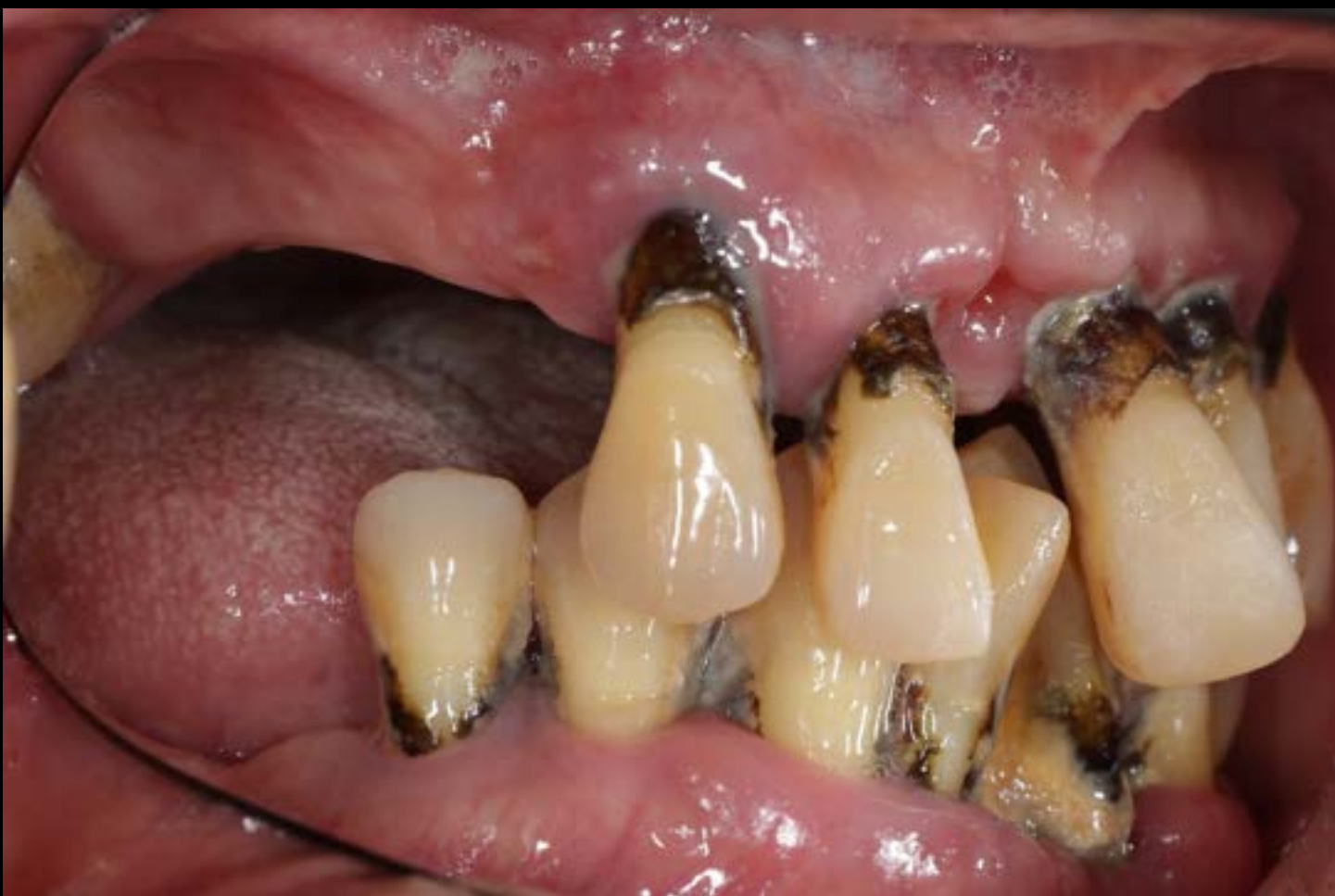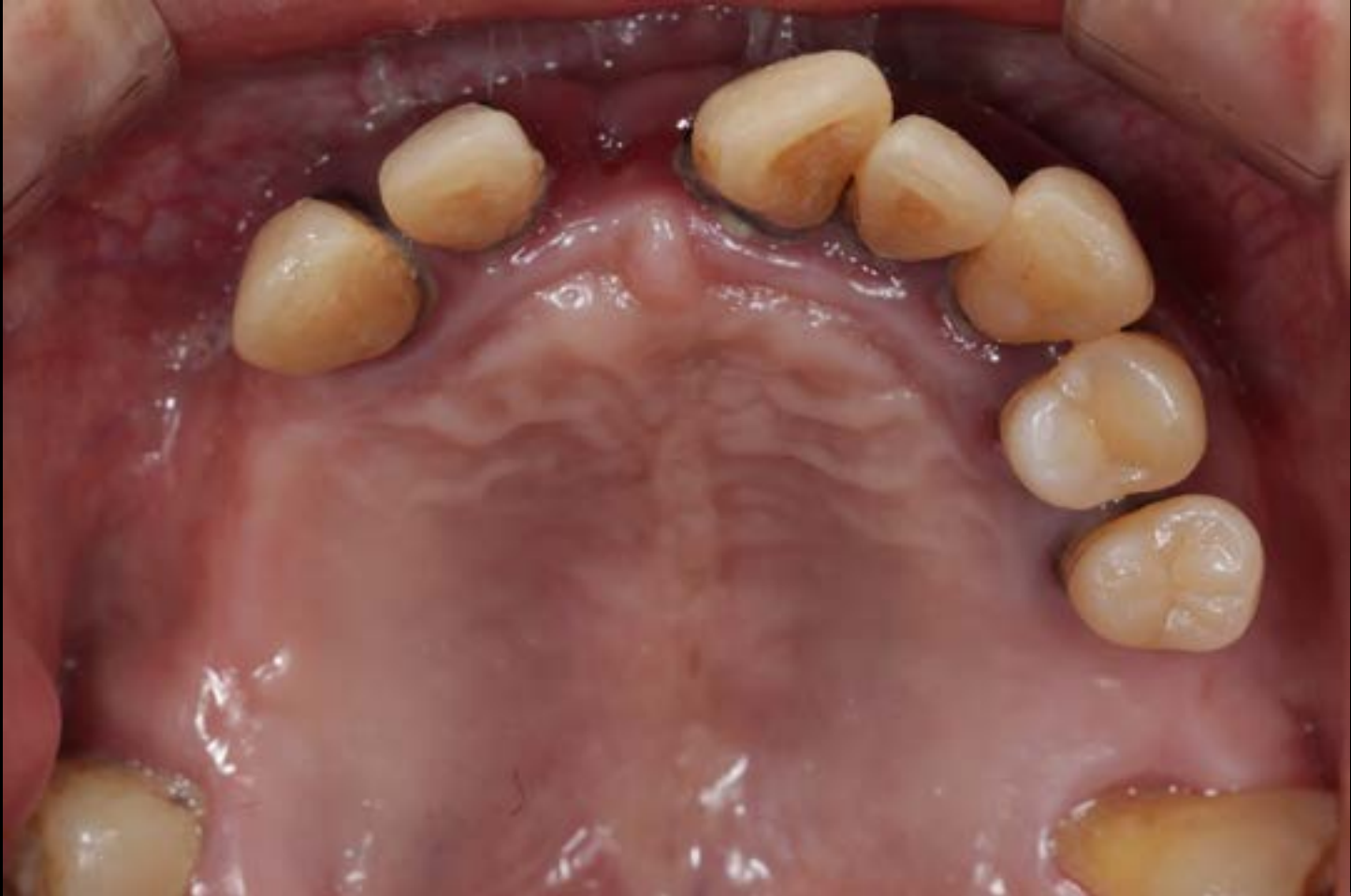Pre-op (2023-08-08)



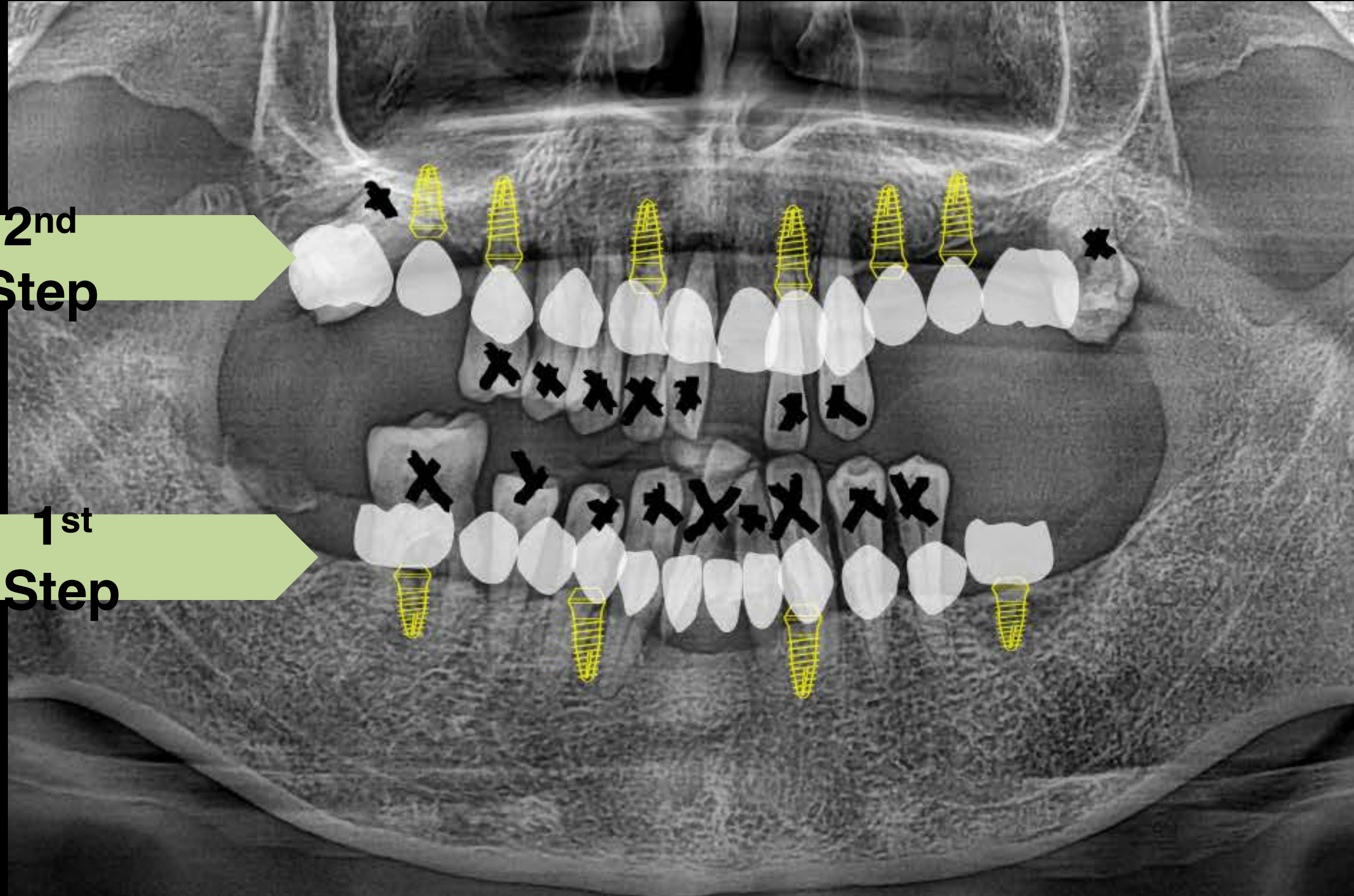
PMH

Heart stent transplants,
diabetes, hyperlipidemia

Pre-op (2023-08-10)



Surgery plane with X-ray



1st Step

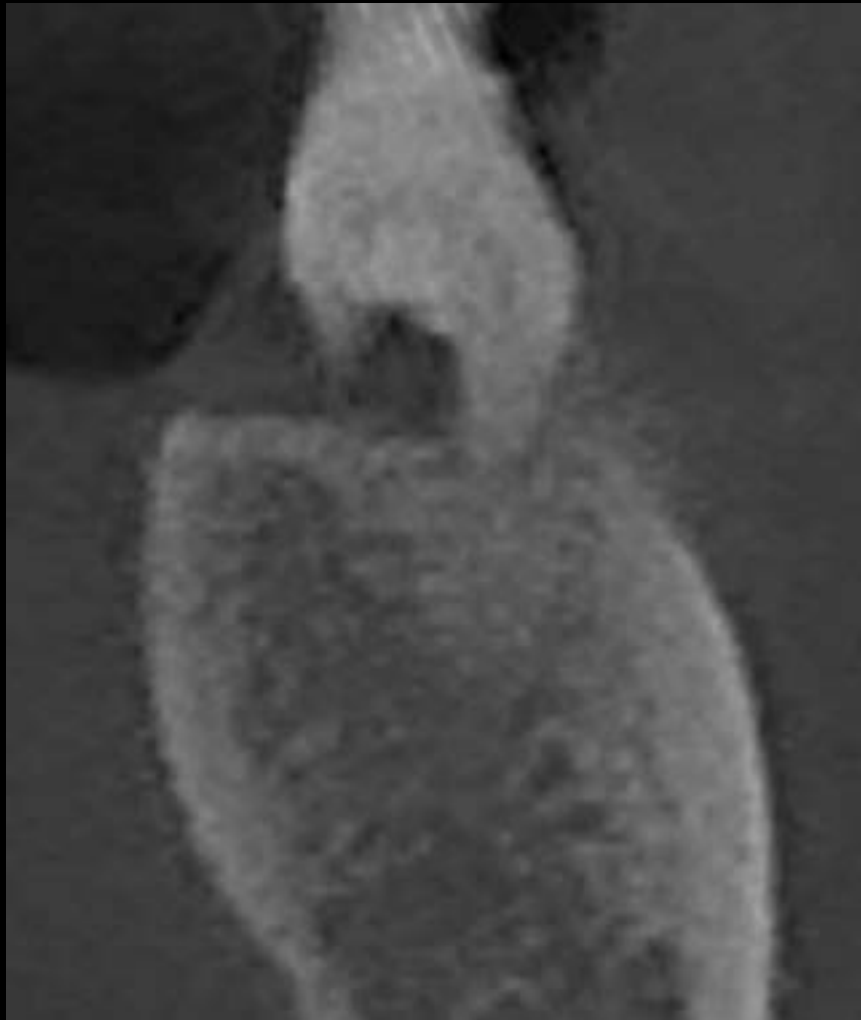
Full mouth extraction

All on 4 immediate implantation on **Lower** arch

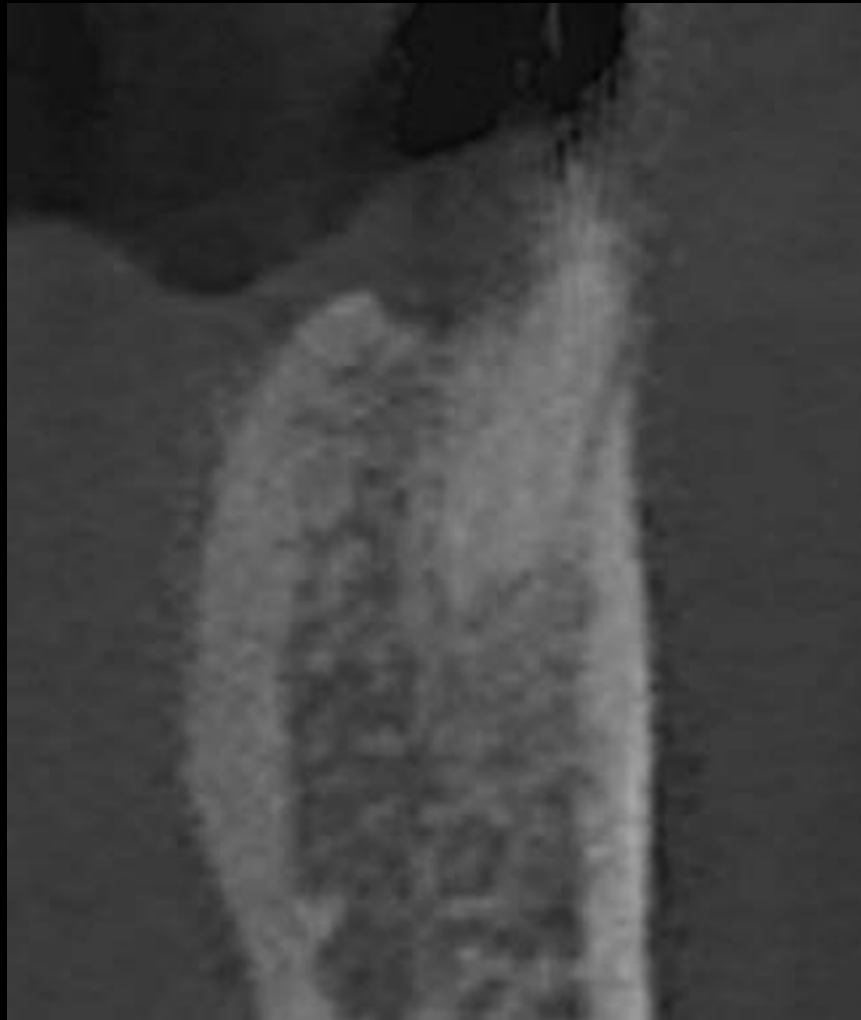2nd Step

All on 6 implantation on **upper** arch

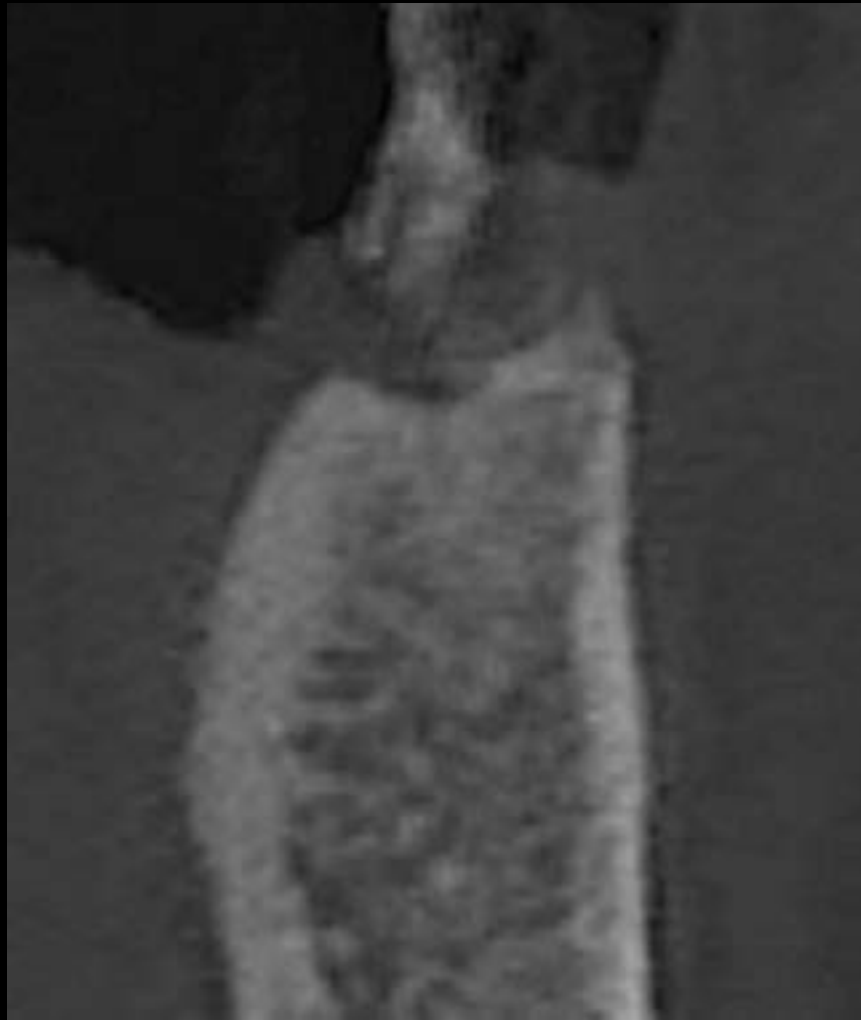
Pre-op CT (2023-08-10)



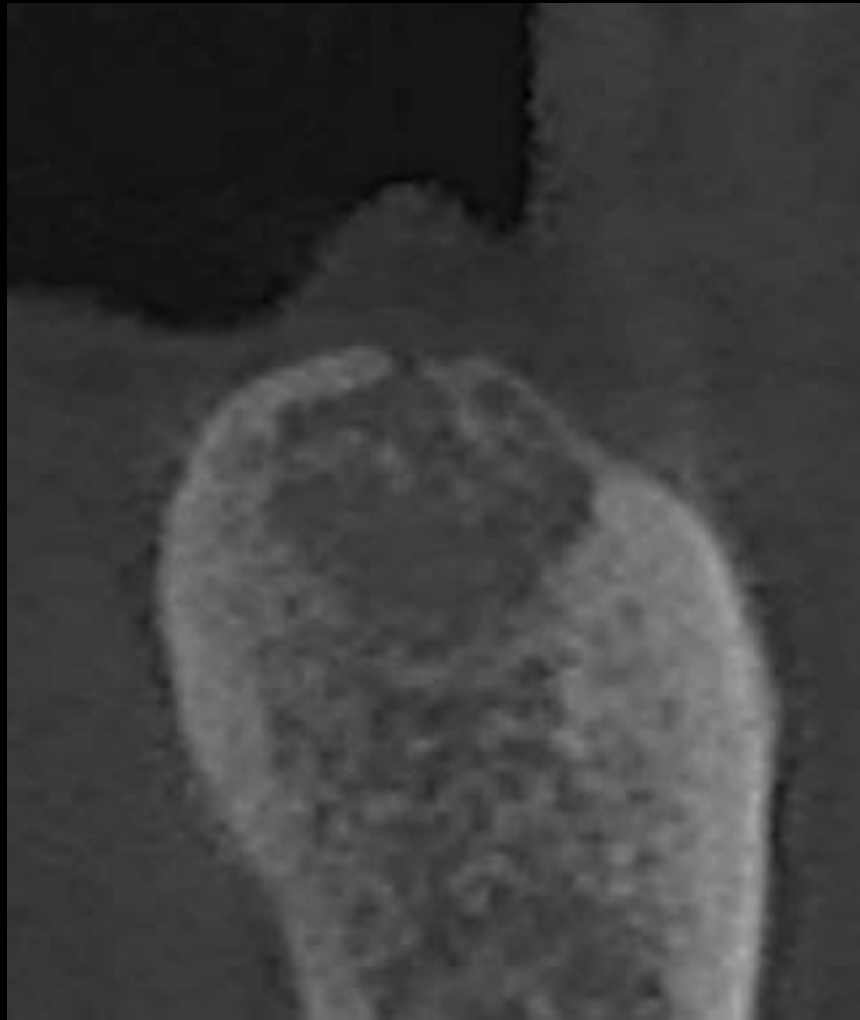
#46



#33

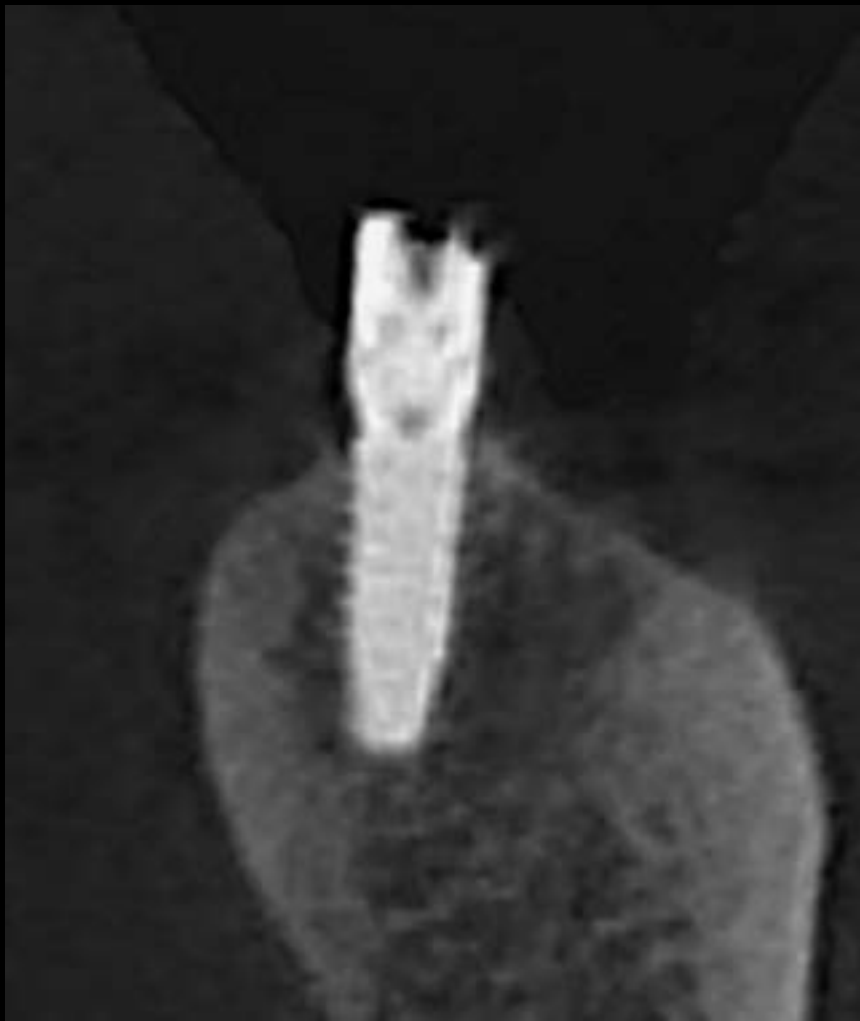

#43

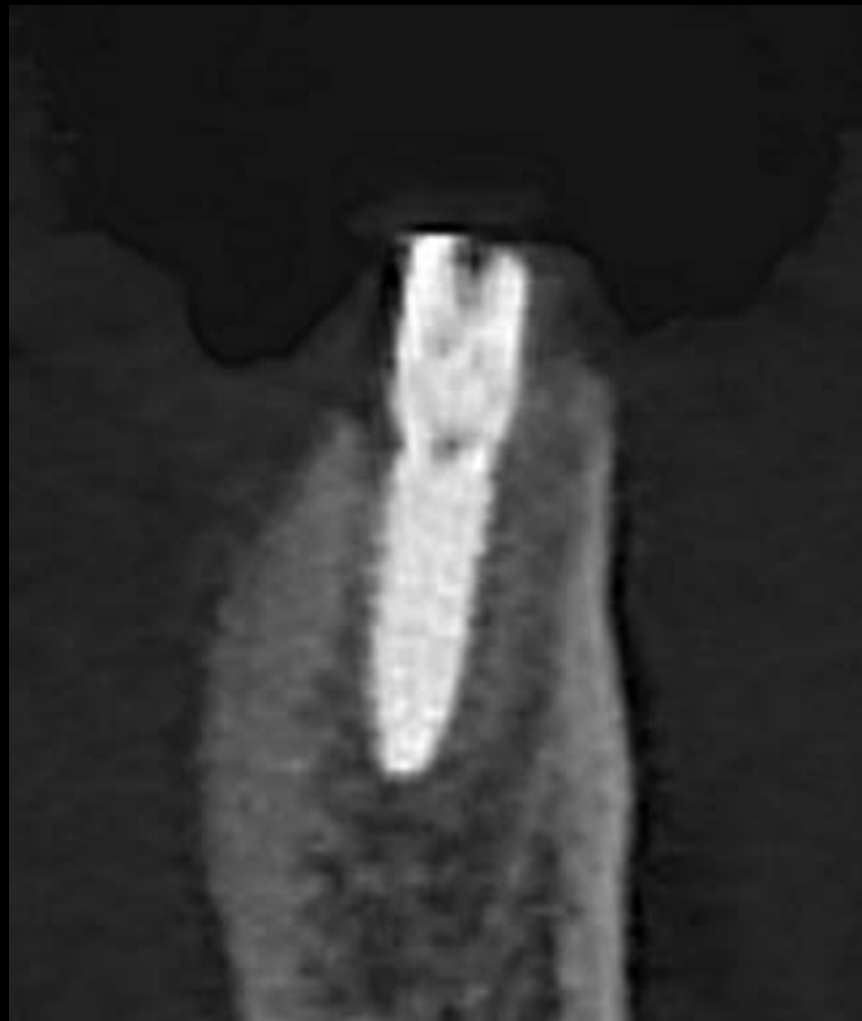

#46

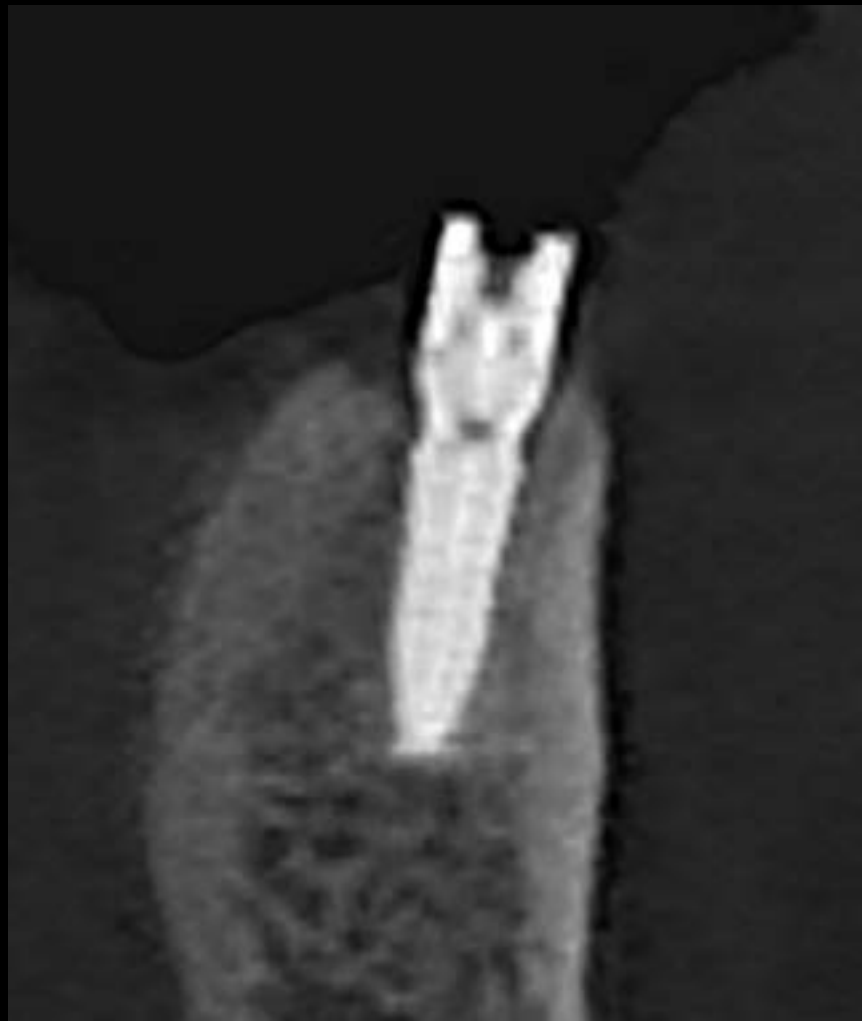Post-op CT (2023-08-10)



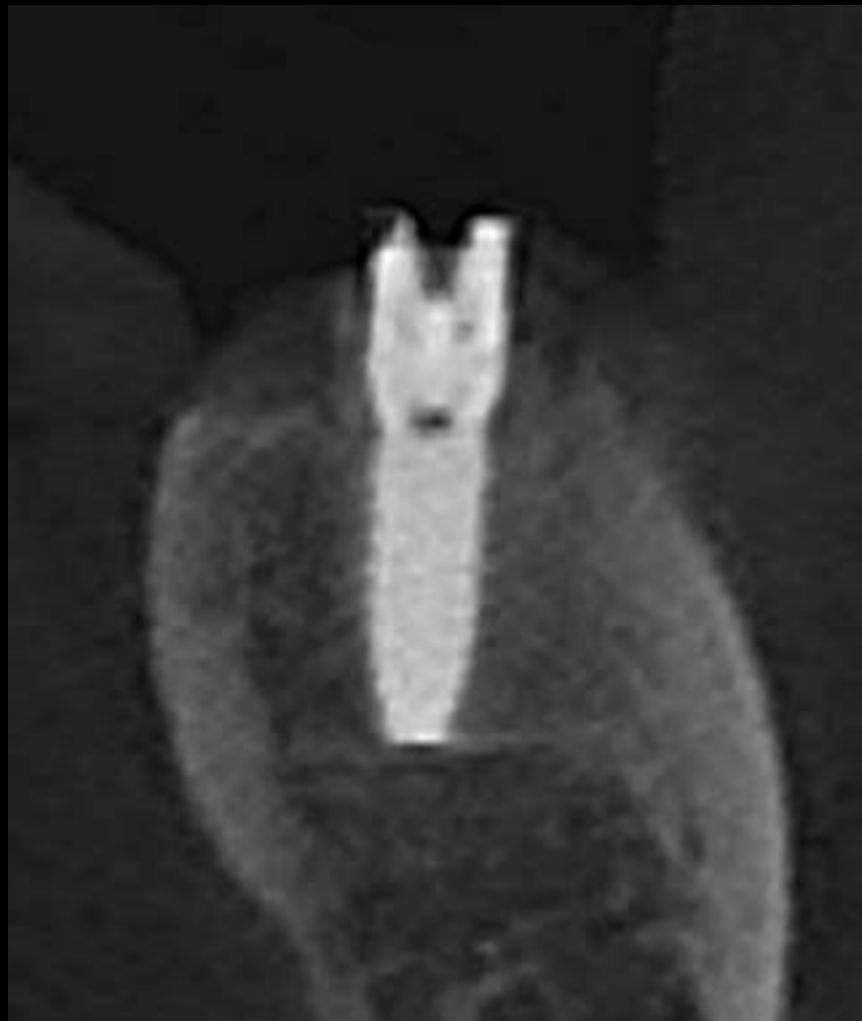#46



#33



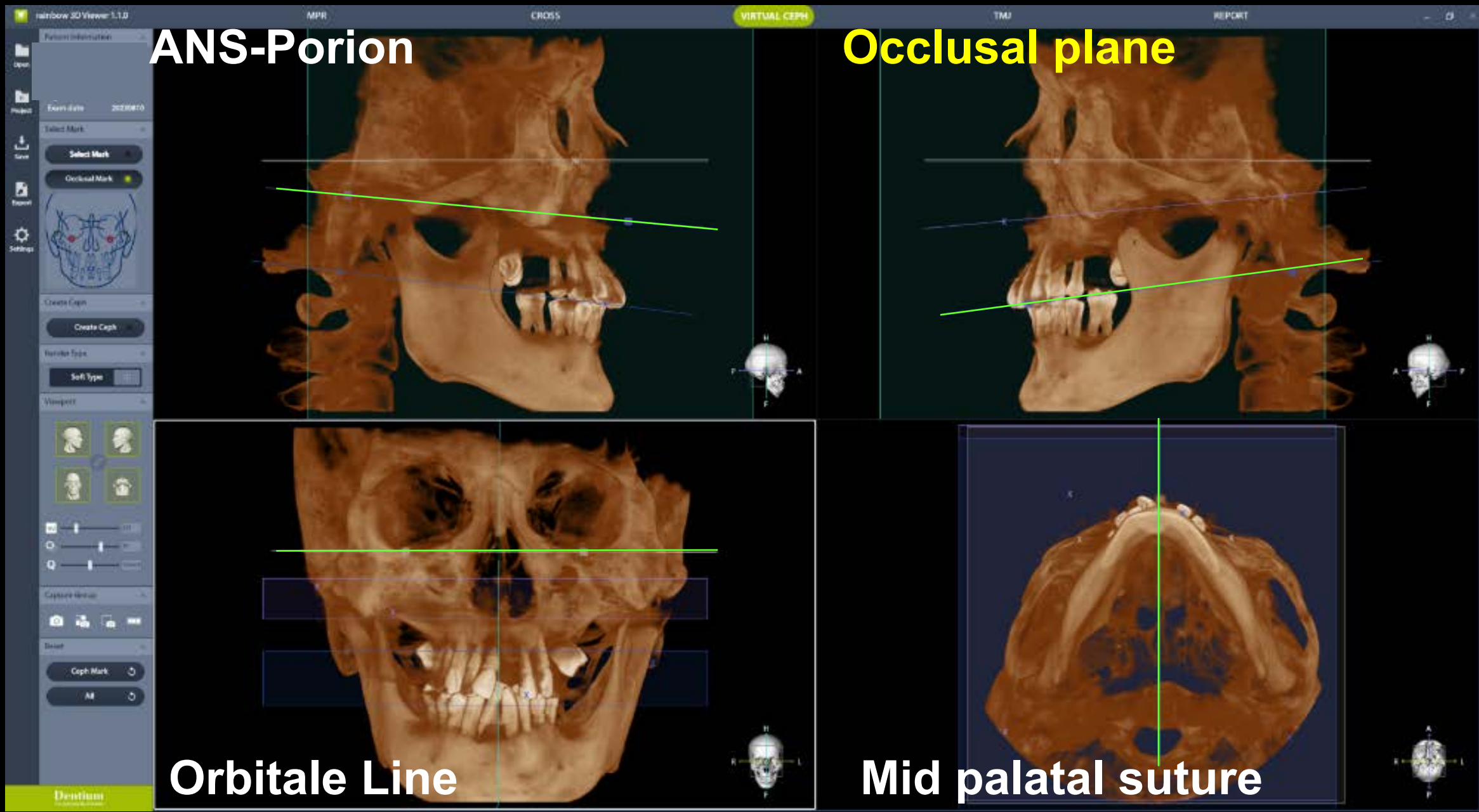
#43



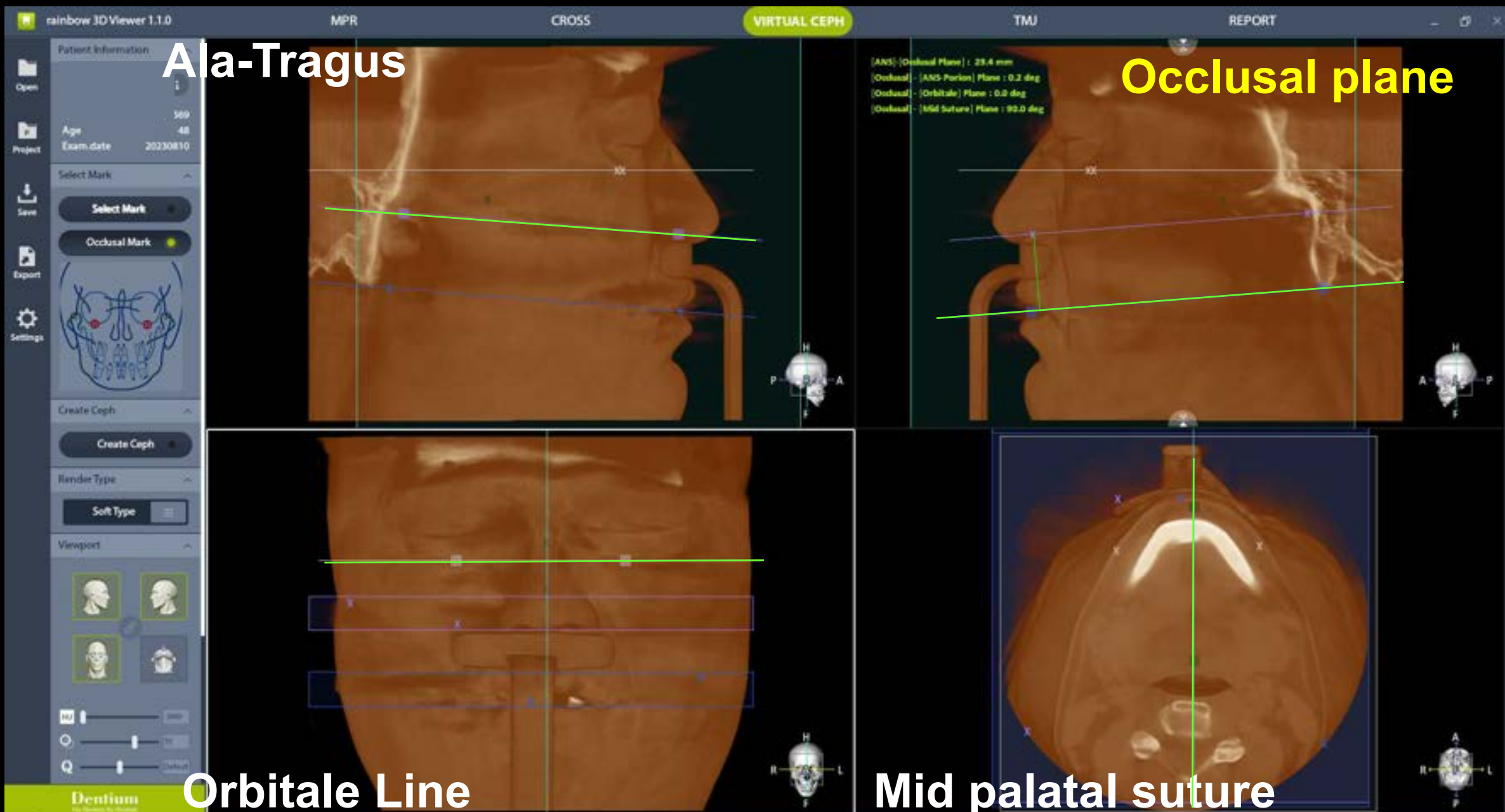
#46

CT viewer 활용 평면 설정

Hard tissue

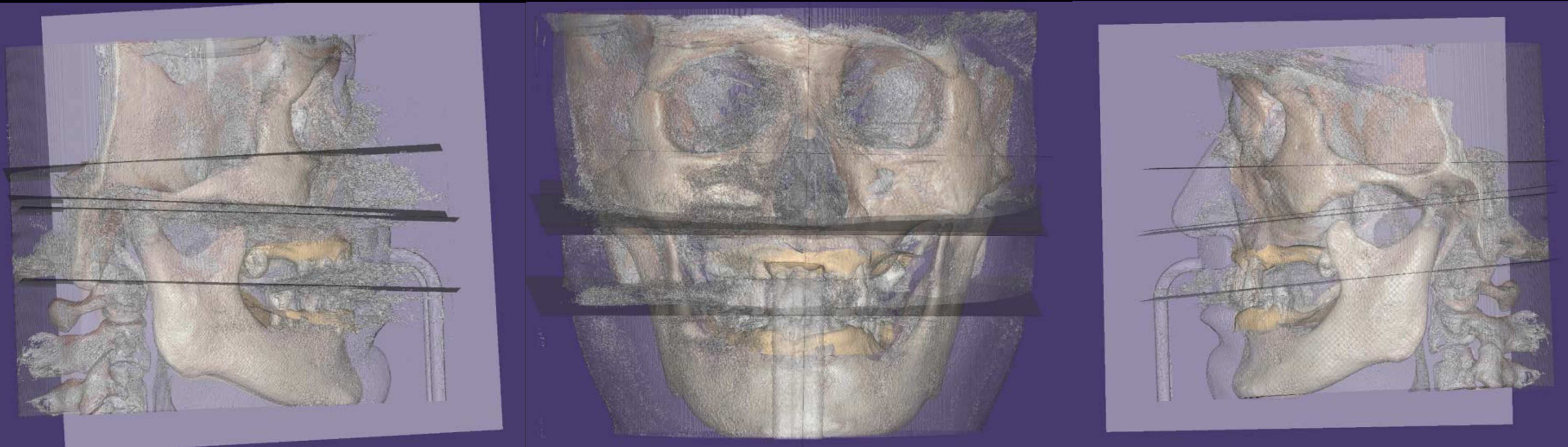


Soft tissue



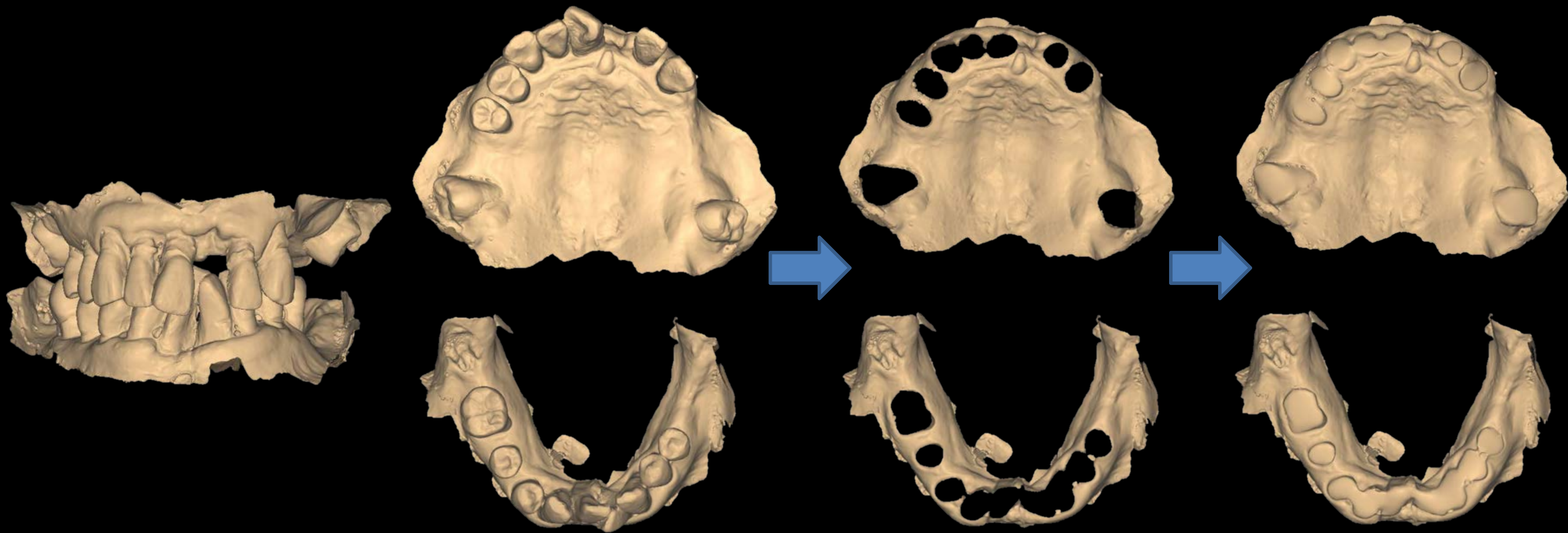
HU값 조절을 통해 Hard/ Soft tissue 모두 pointing 가능

Data stitching
(CT DICOM + CT plane STL + working model)

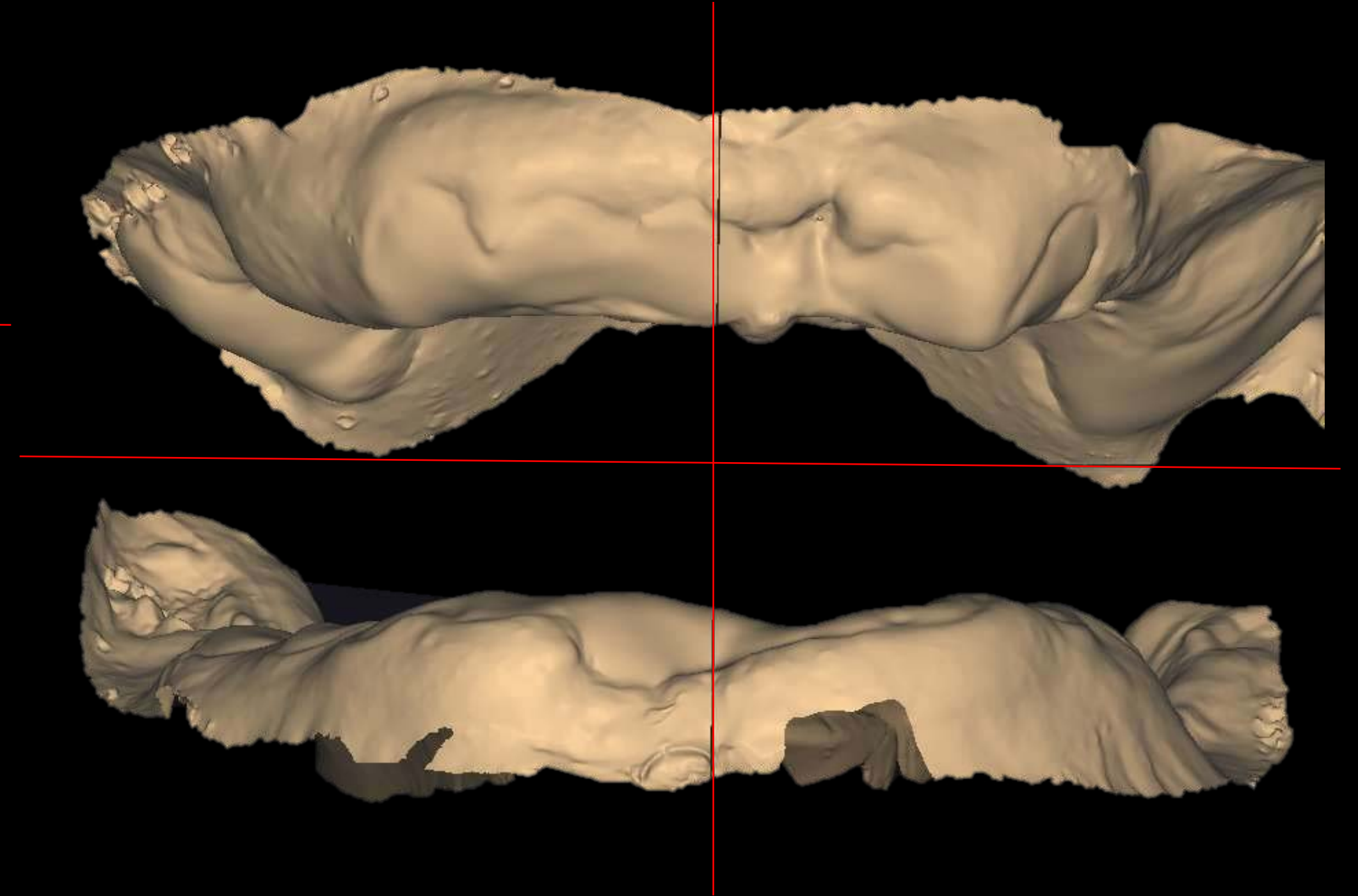
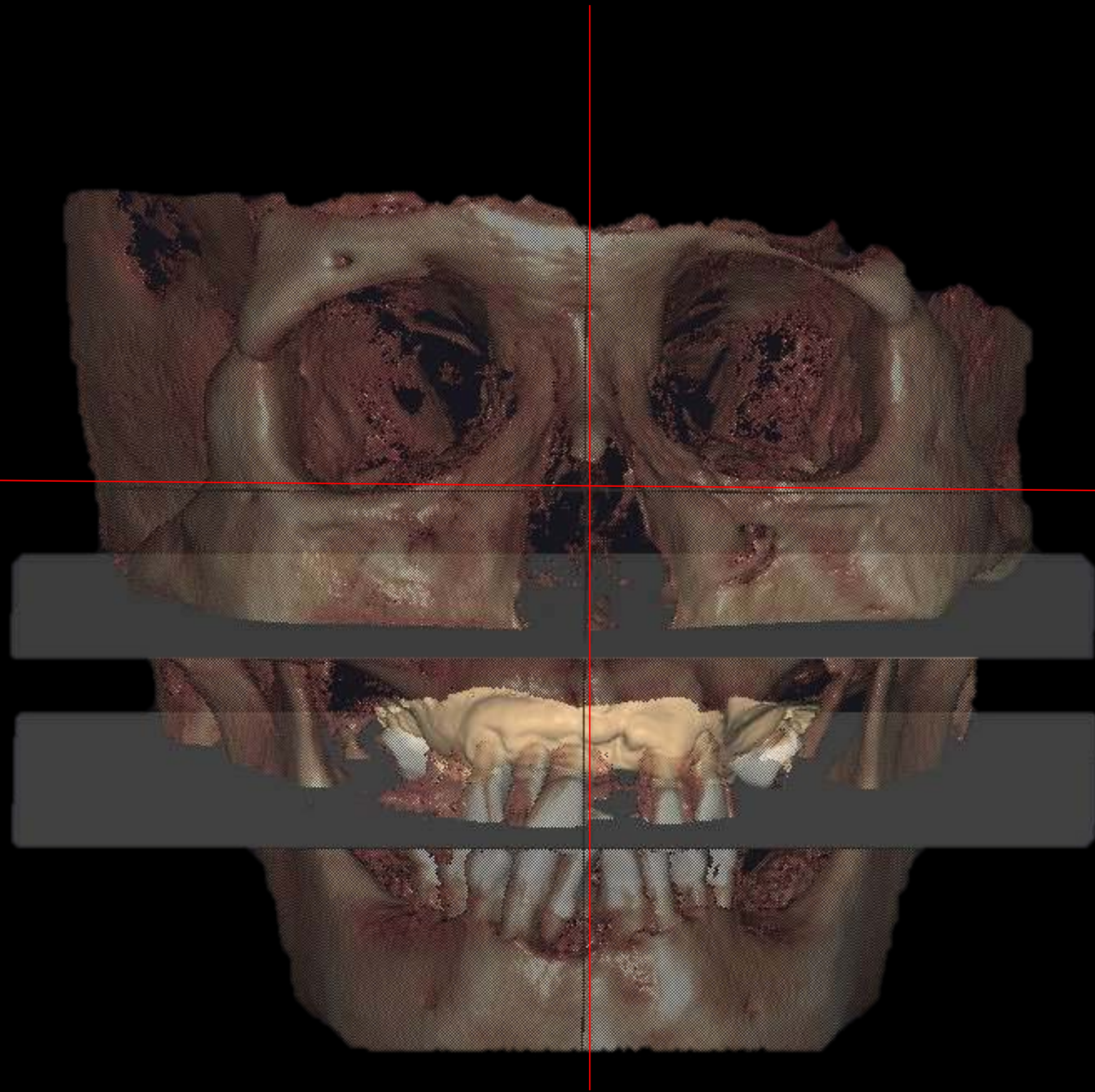


CT STL (soft / hard) + plane STL + IOS

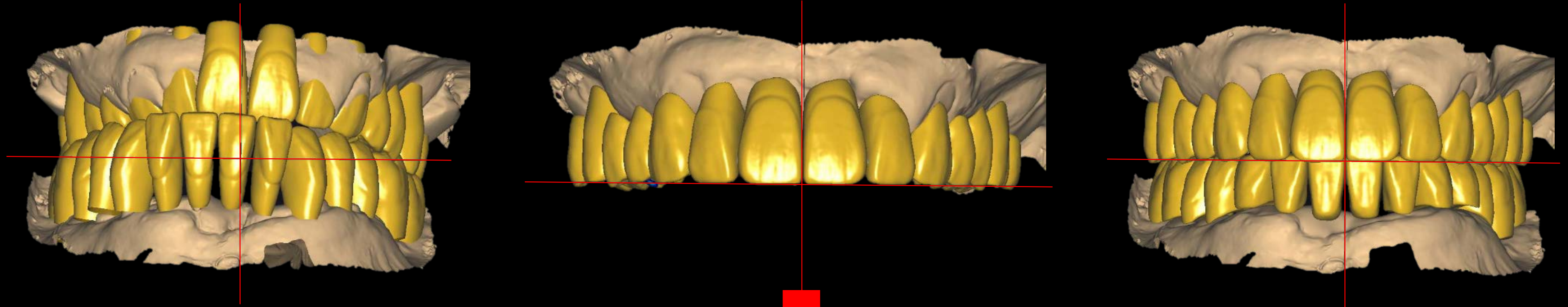
Working model
(Intra Oral Scan data editing)



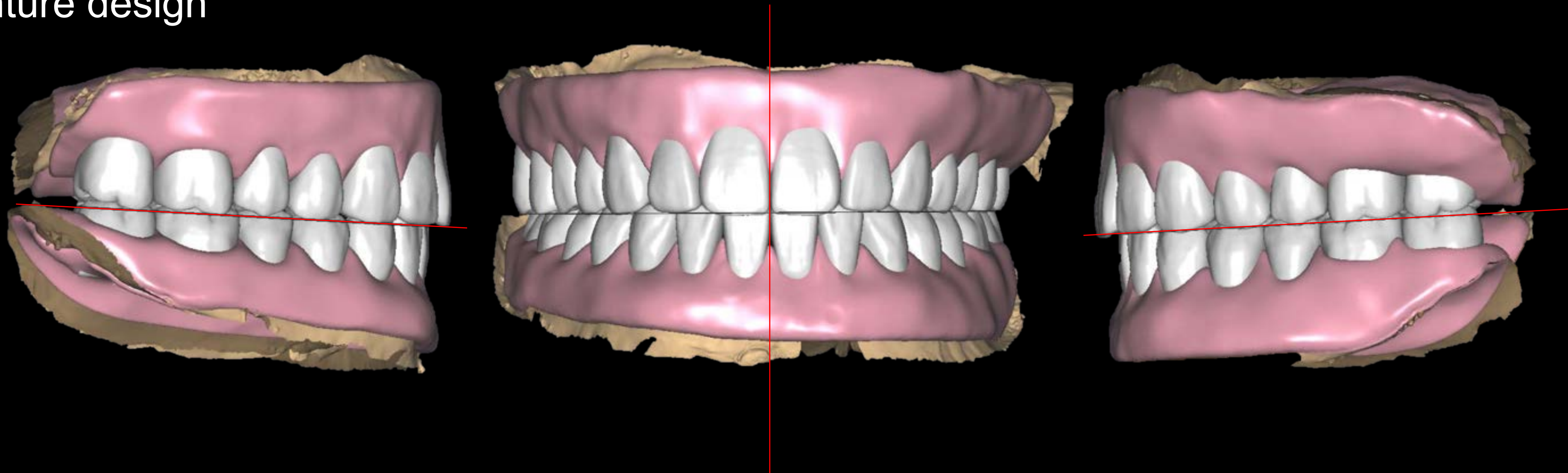
Data stitching
(CT DICOM + CT plane STL + working model)



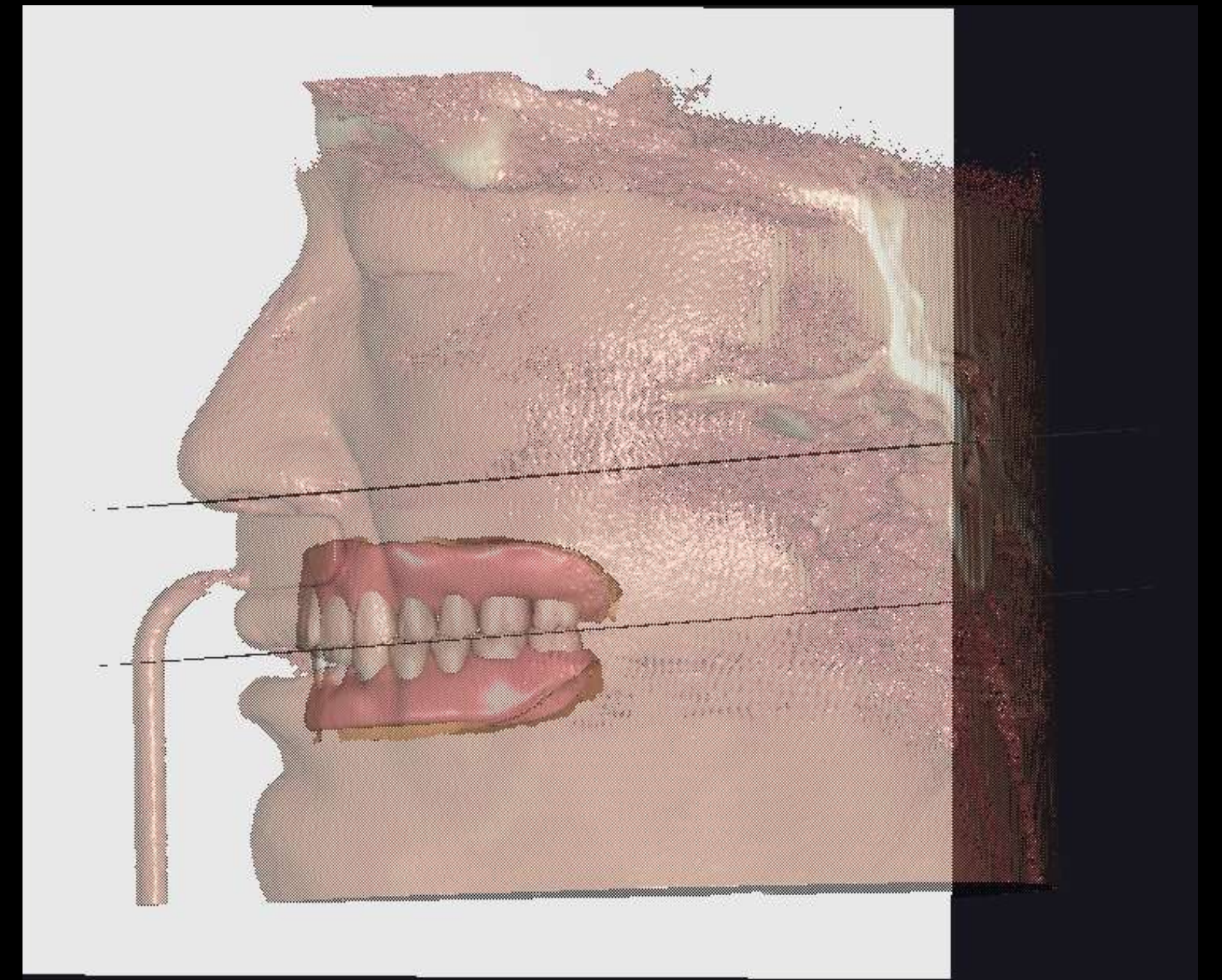
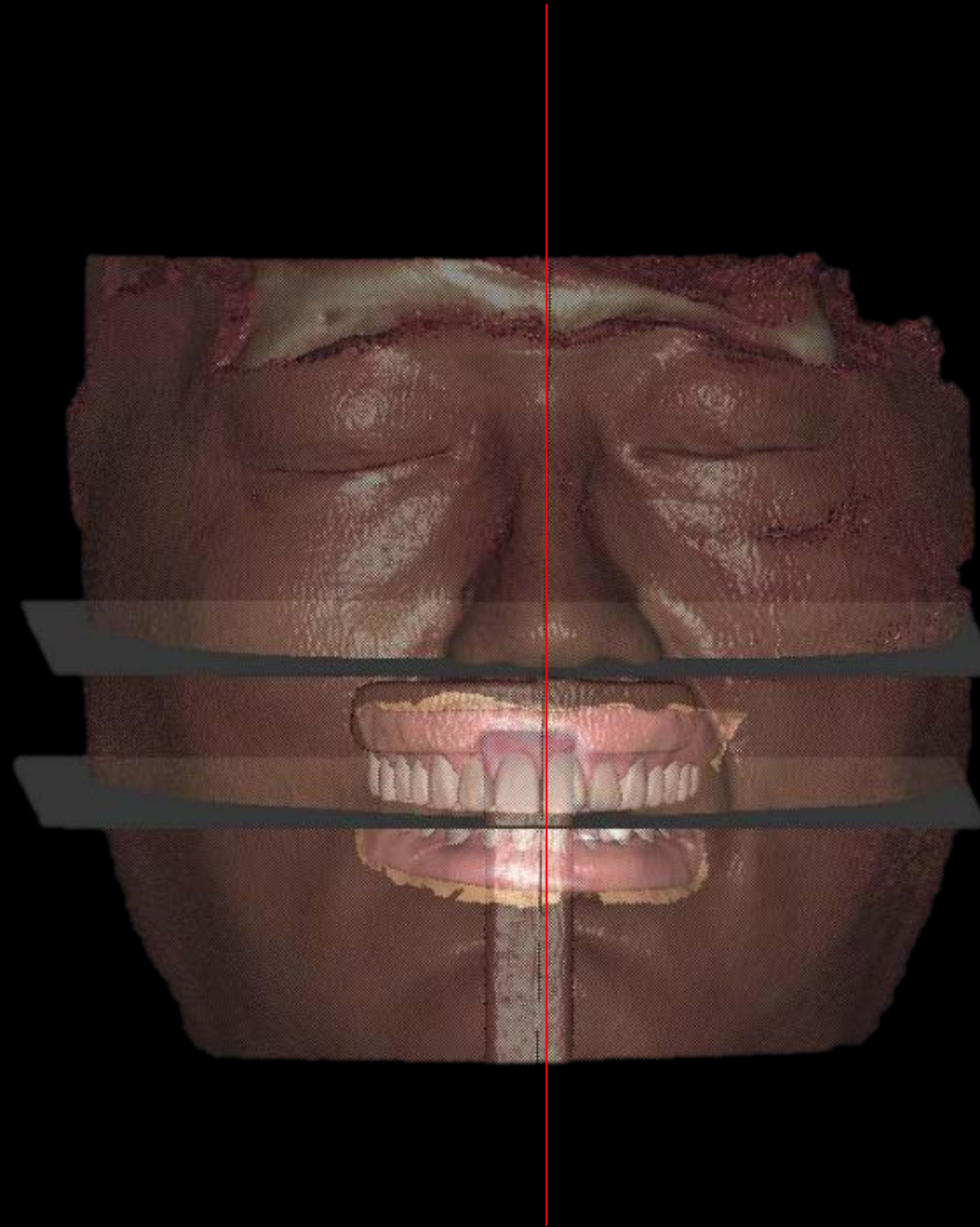
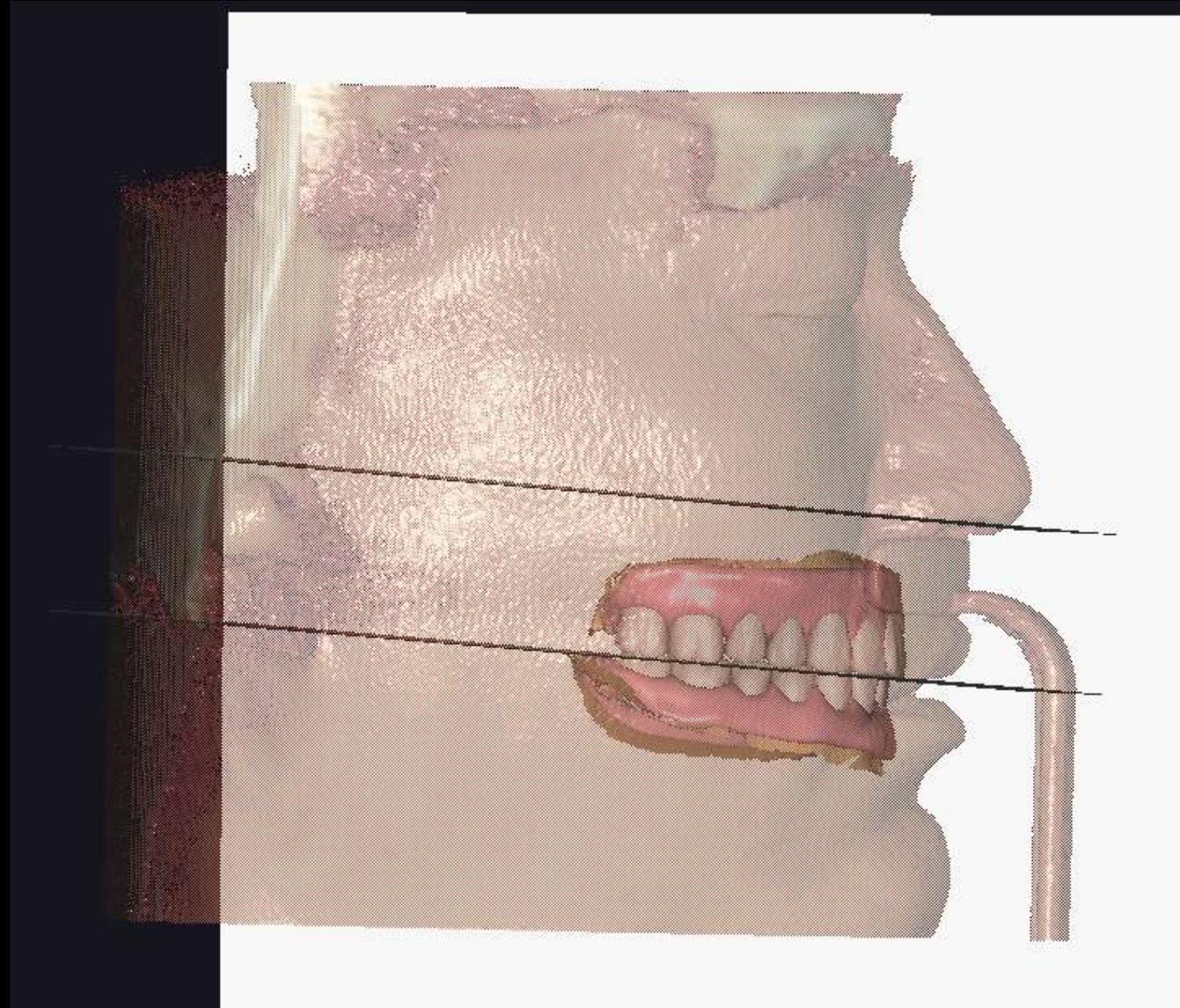
Virtual Set-up



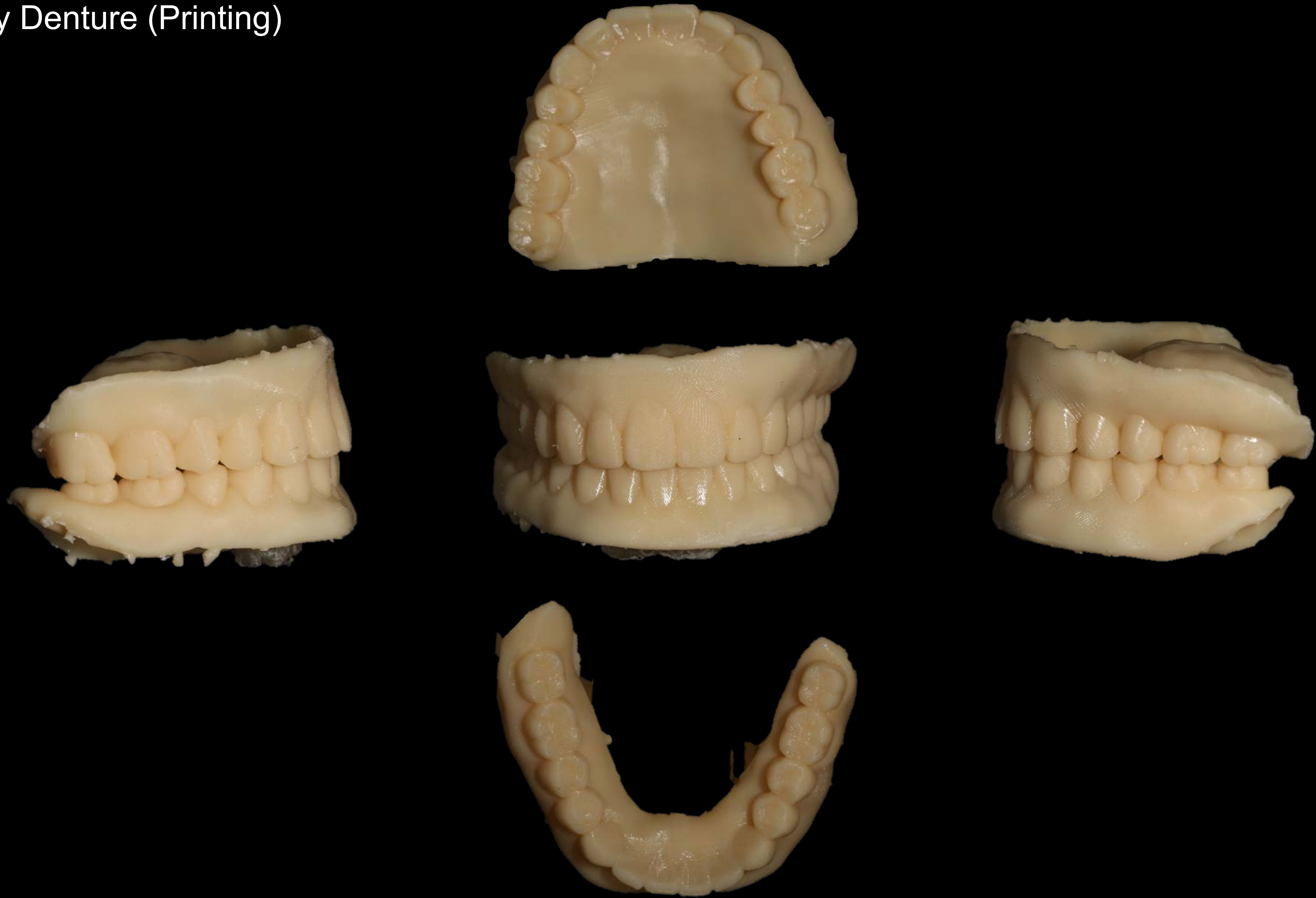
Temporary denture design



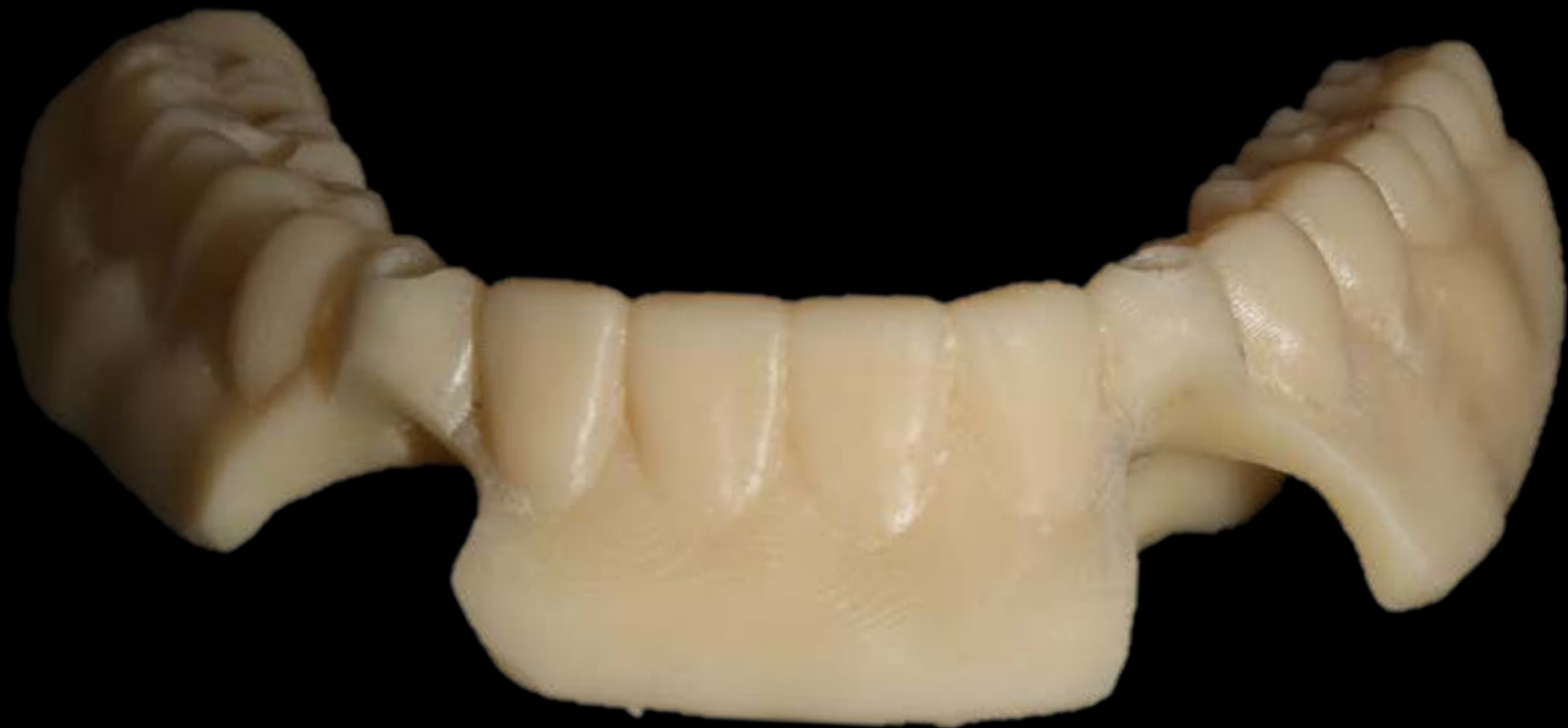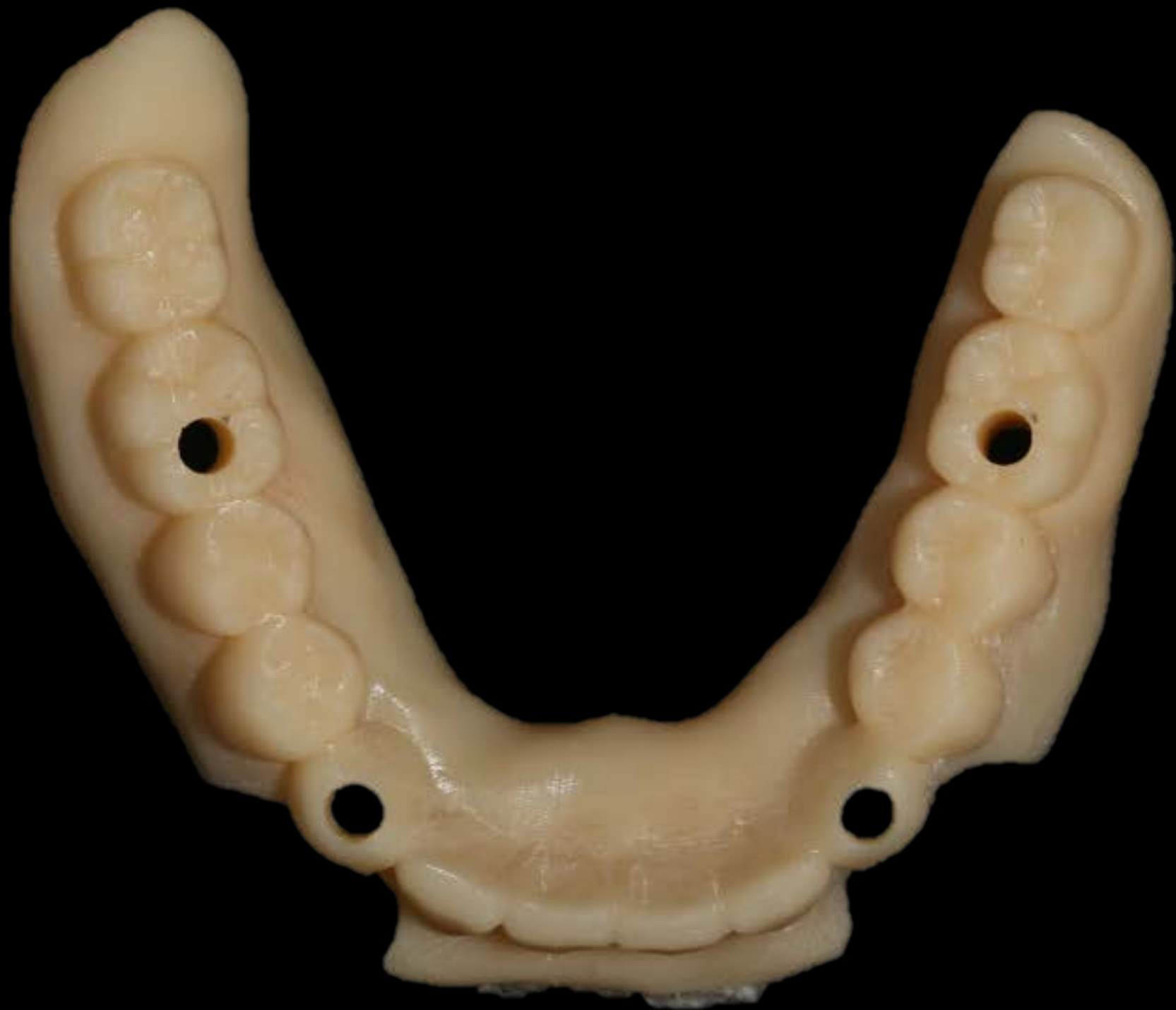Temp denture design



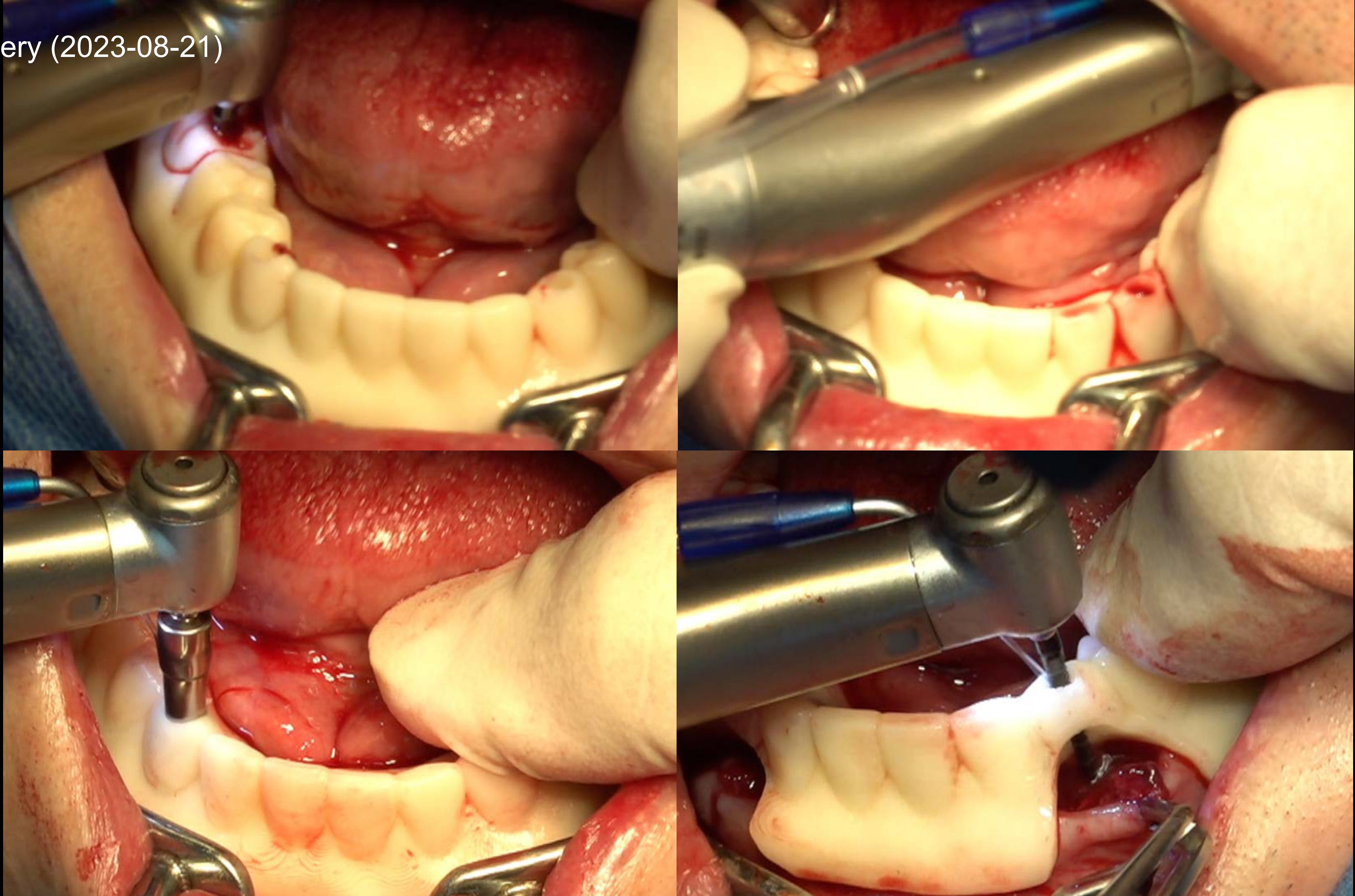
Temporary Denture (Printing)



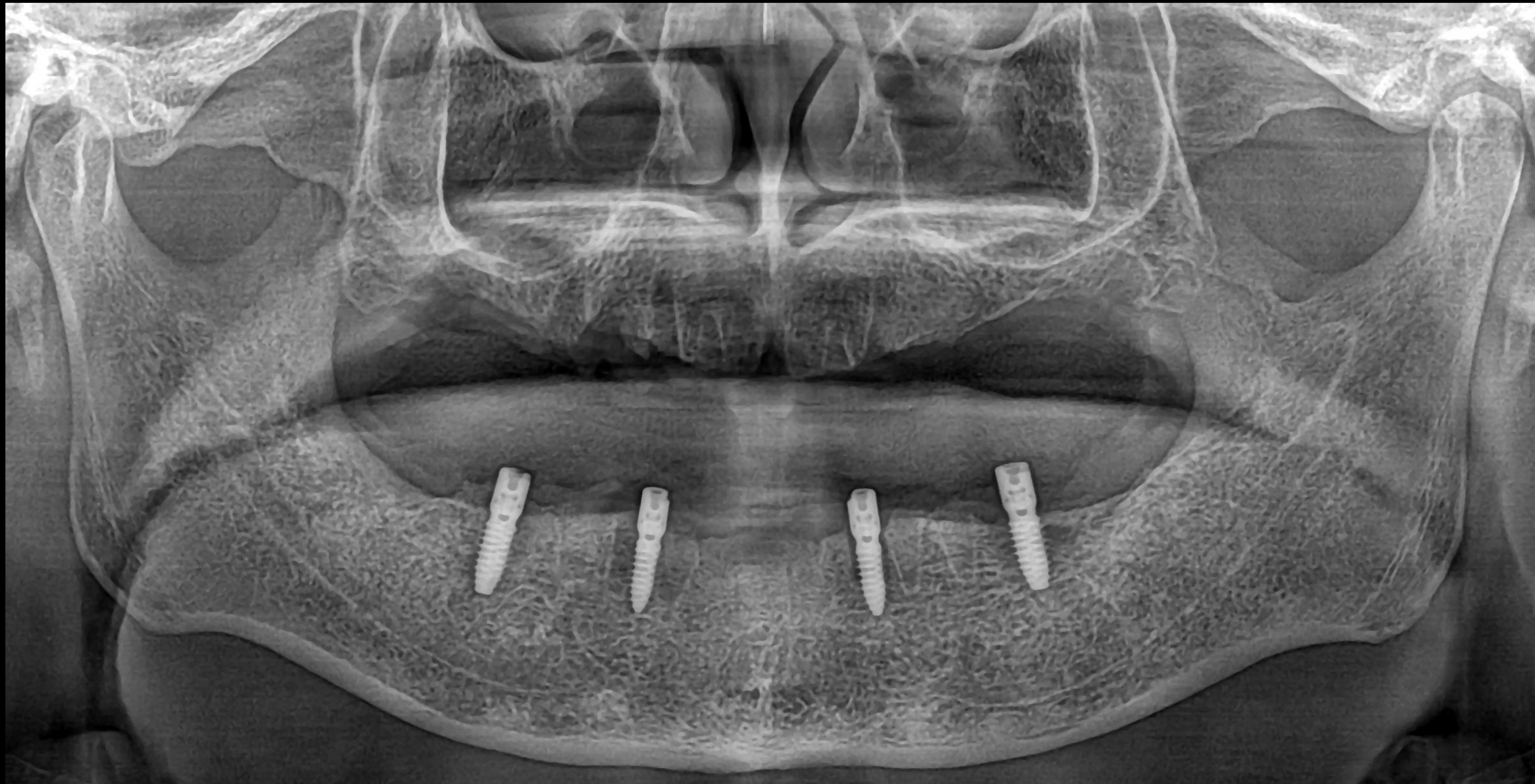
Marking hole on Lower printing denture



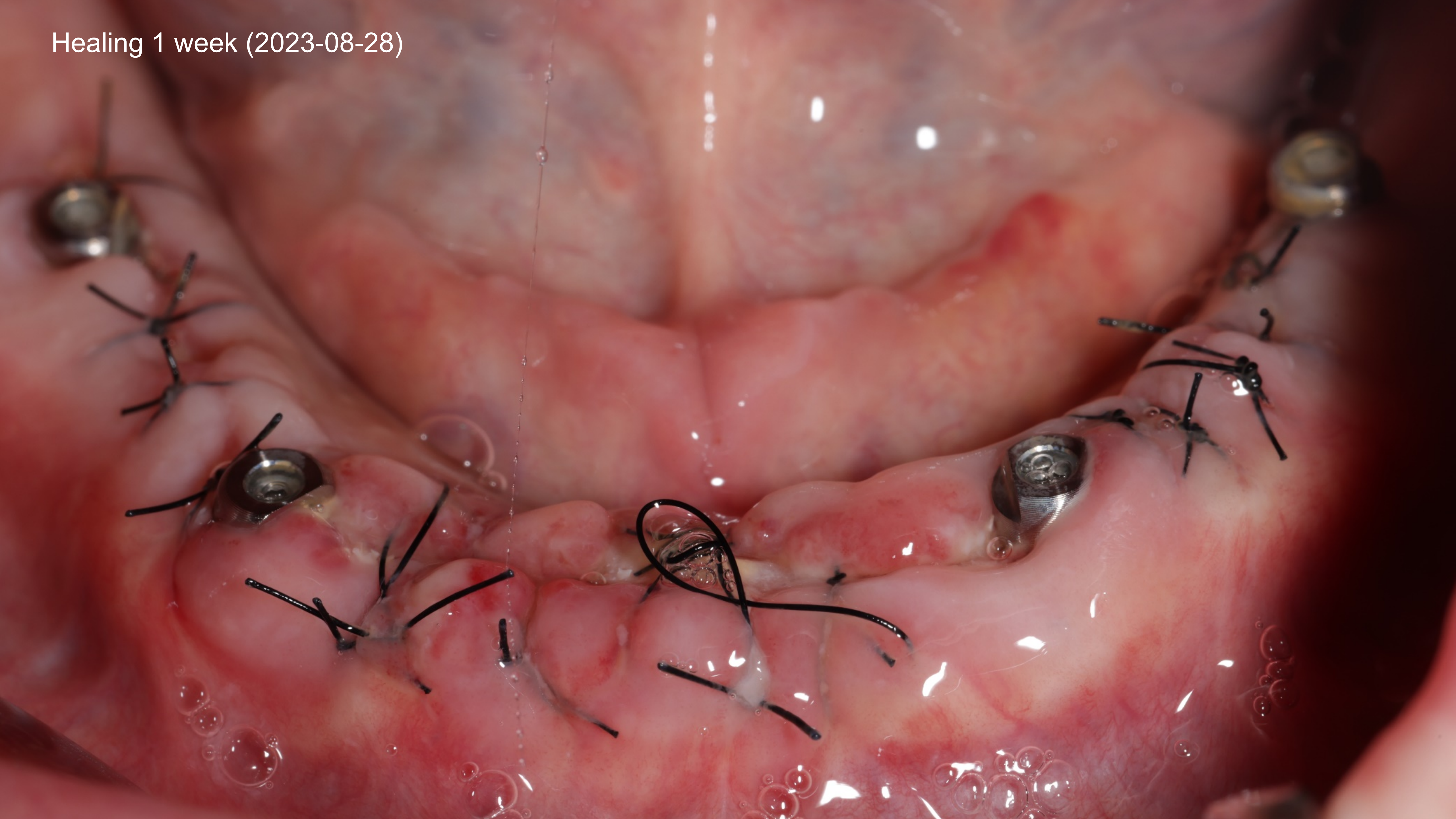
Surgery (2023-08-21)



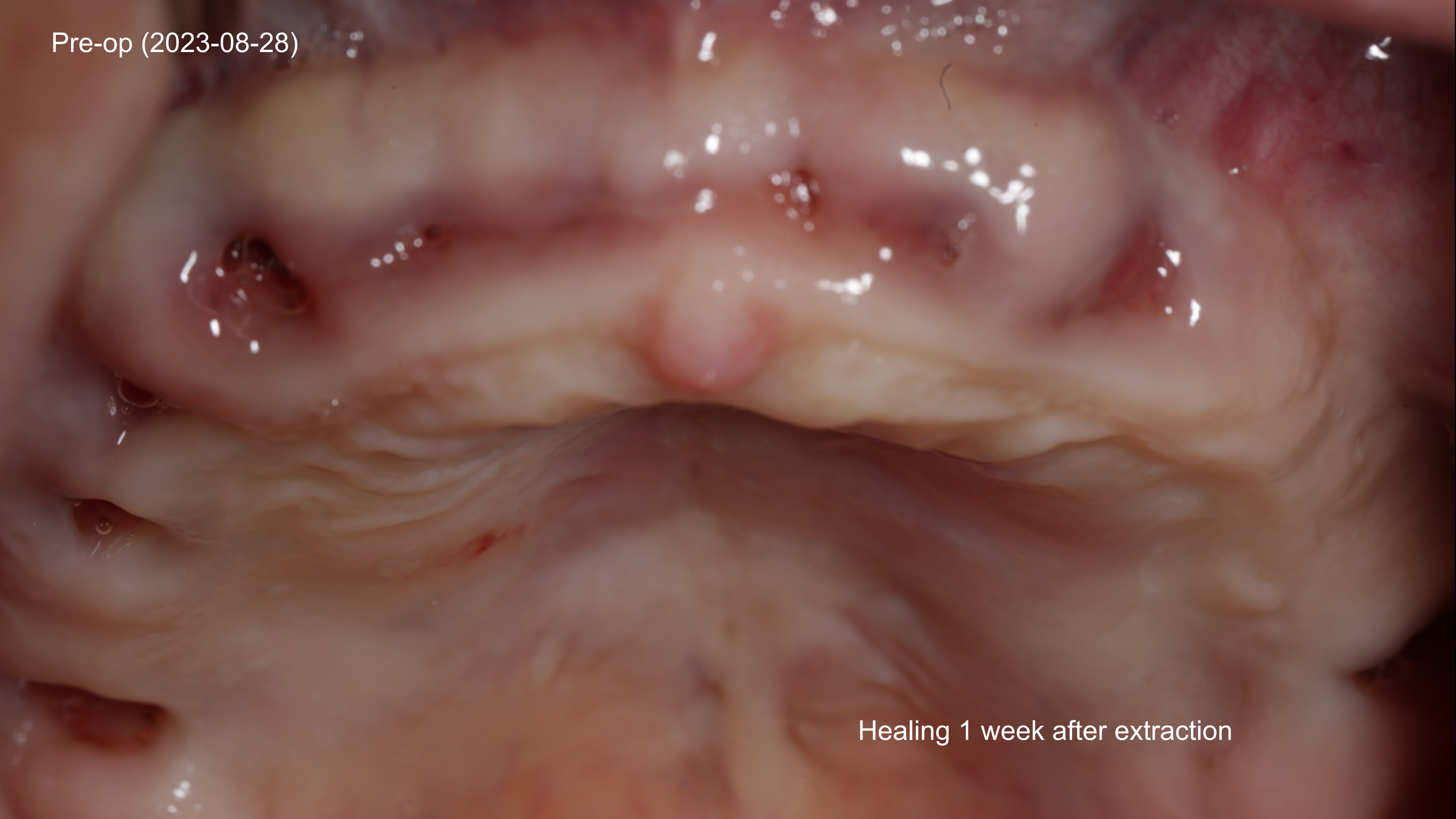Post-op (2023-08-21)



Healing 1 week (2023-08-28)



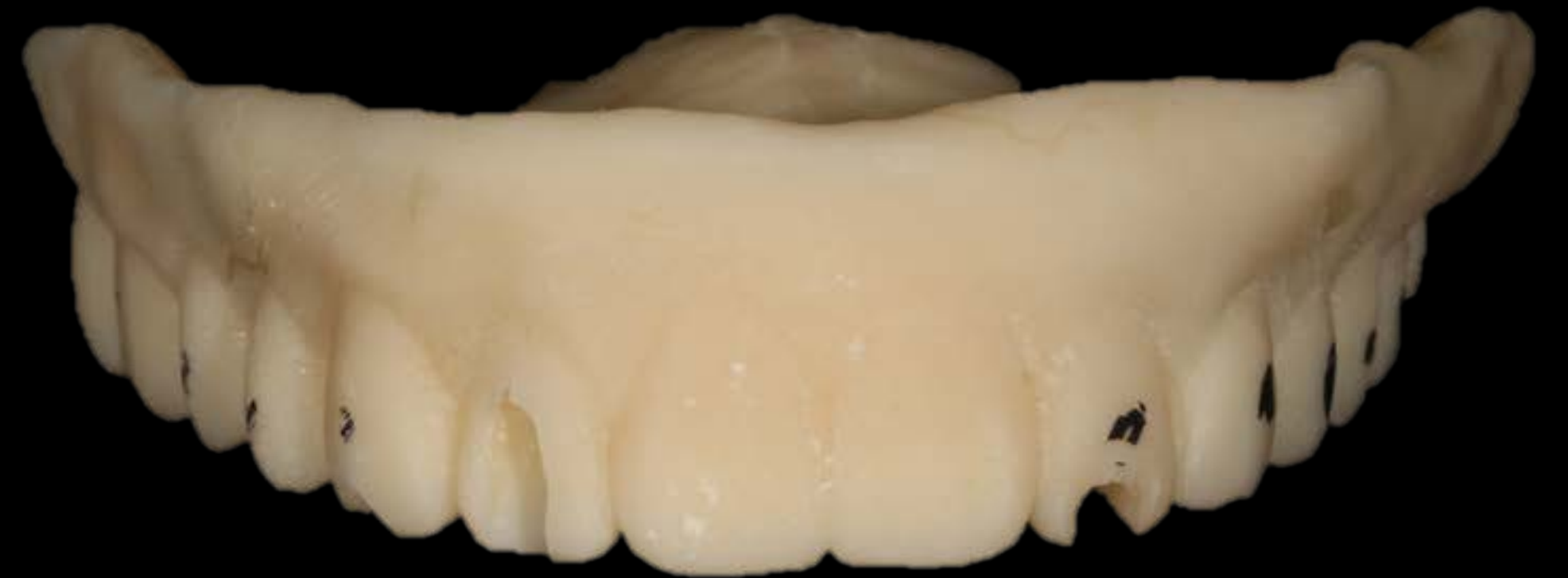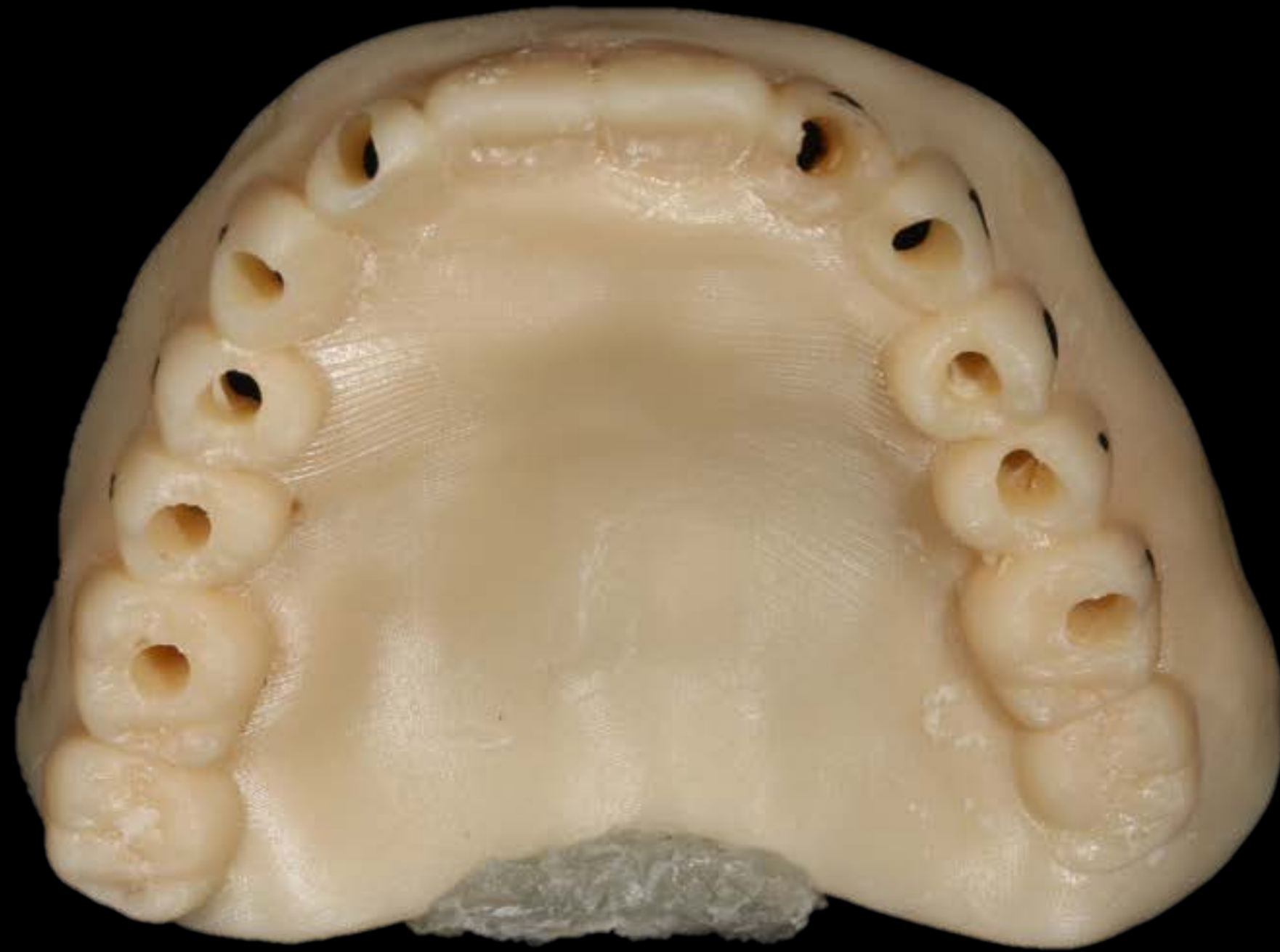Pre-op (2023-08-28)



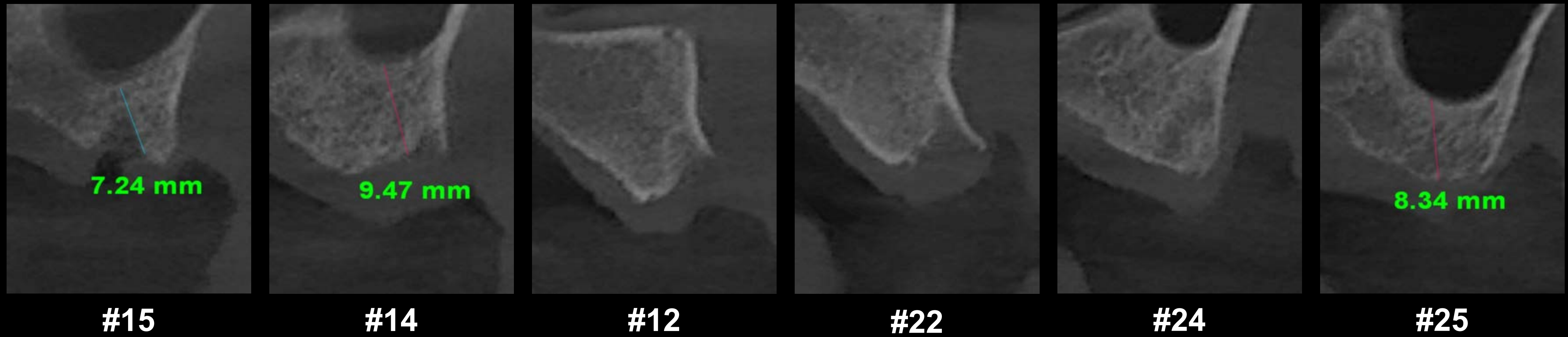
Healing 1 week after extraction



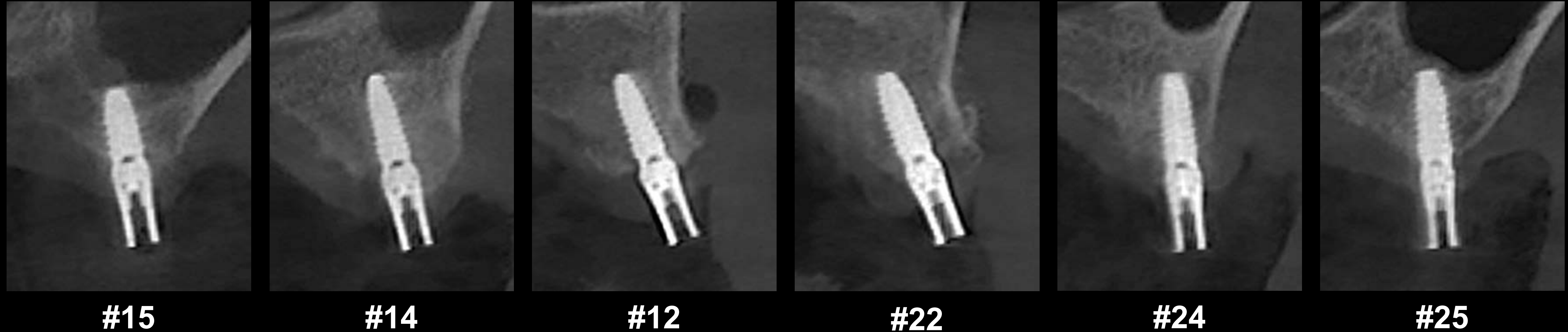
Marking hole on upper printing denture



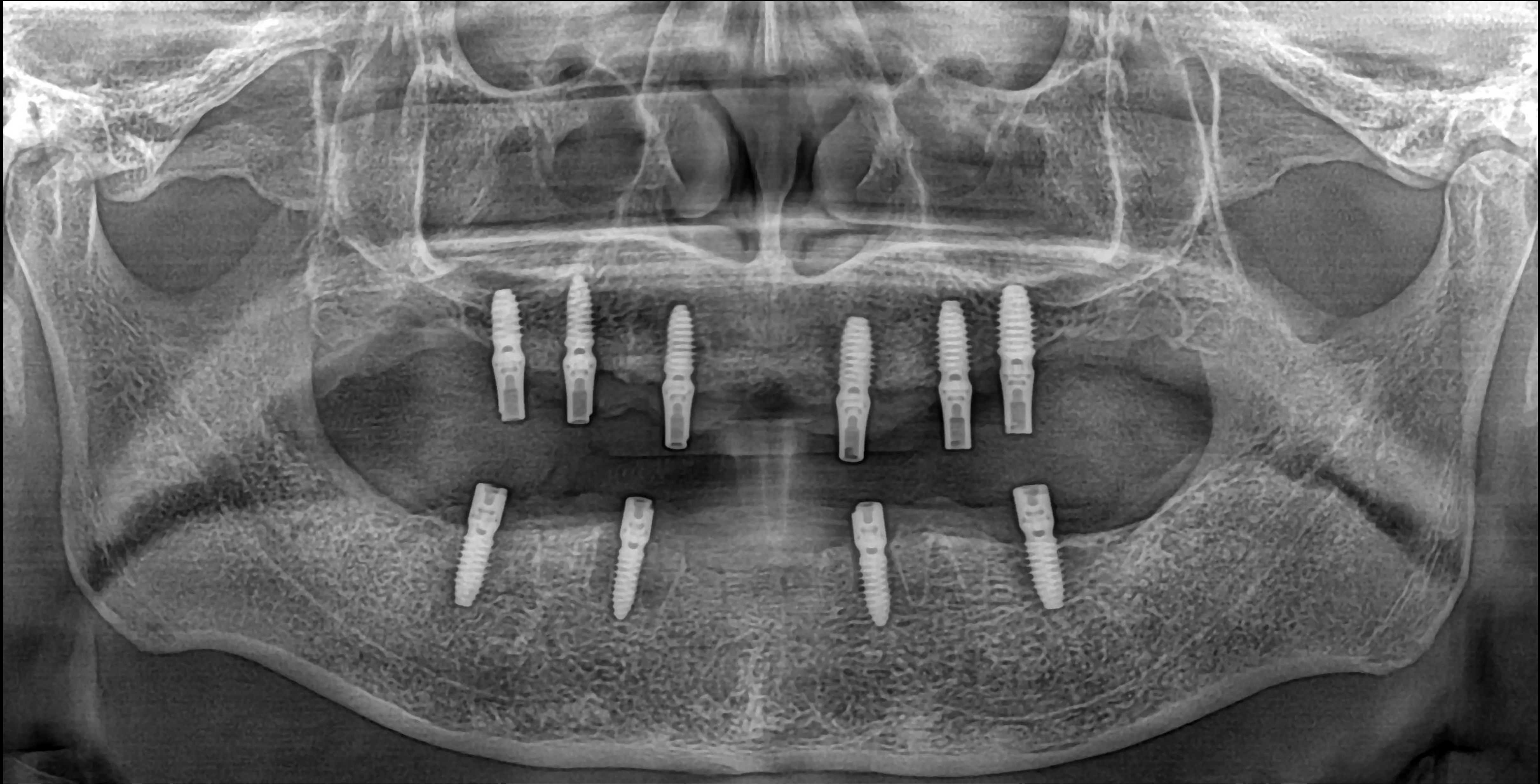
Pre-op CT (2023-08-21)



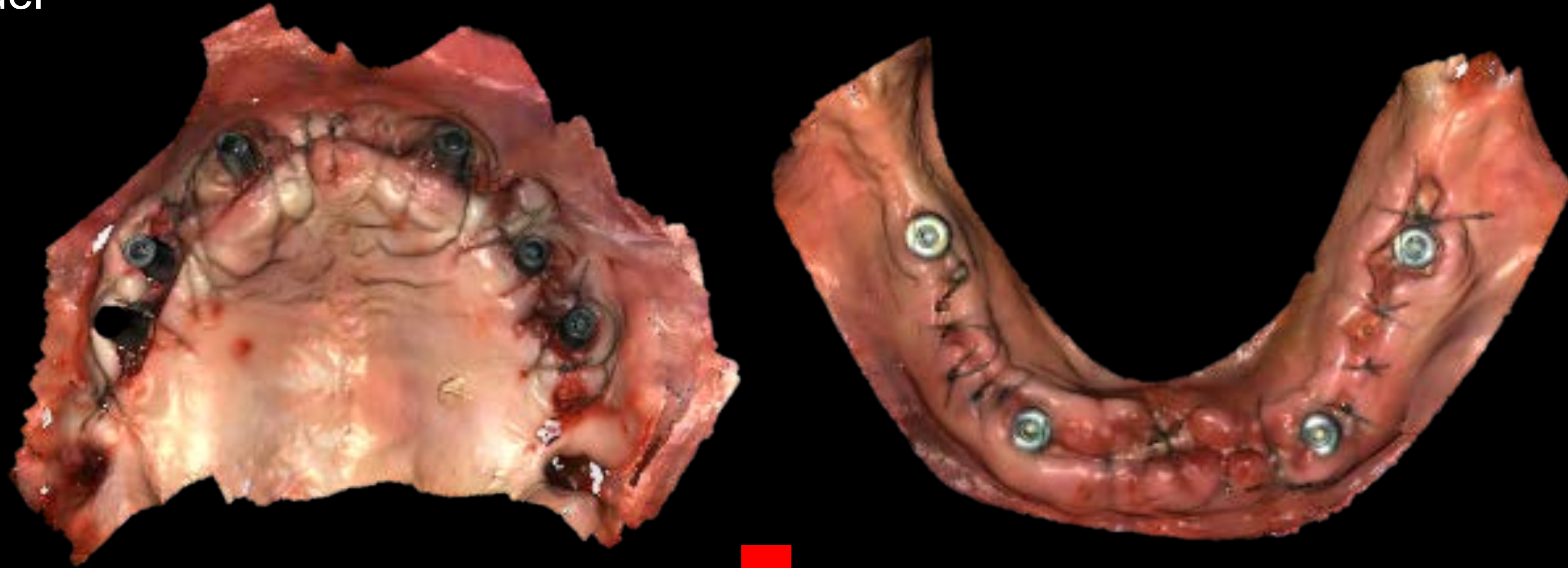
Post-op CT (2023-08-28)



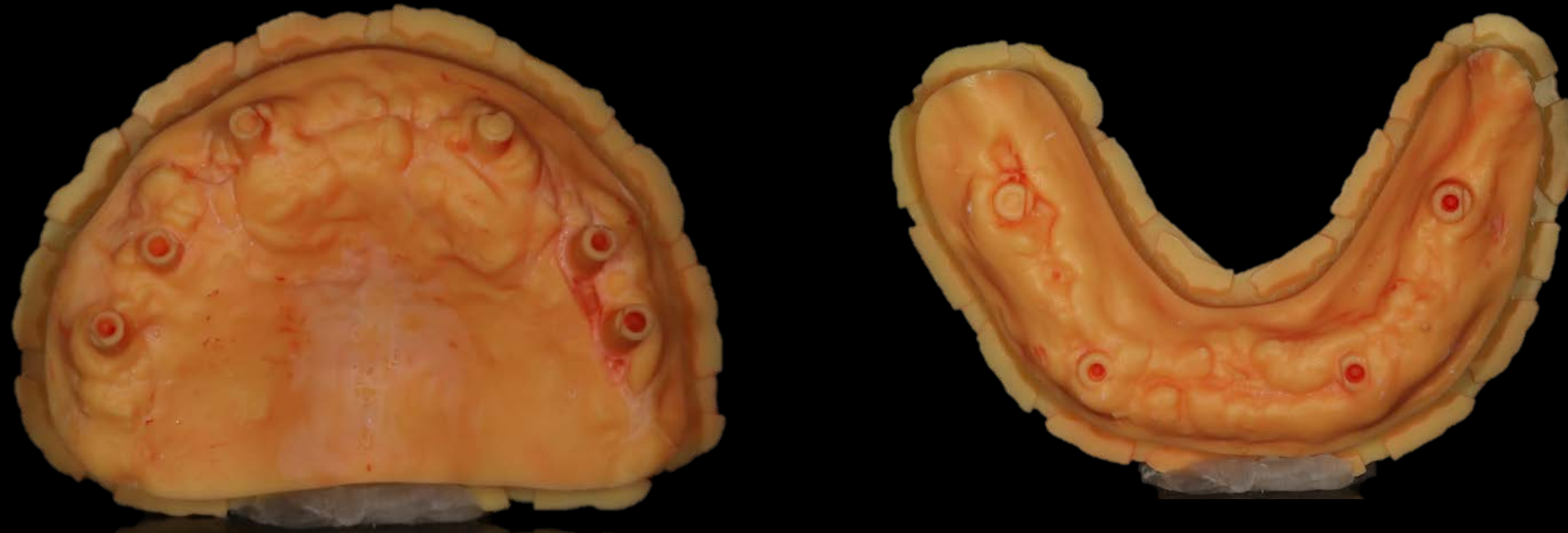
Post-op (2023-08-28)



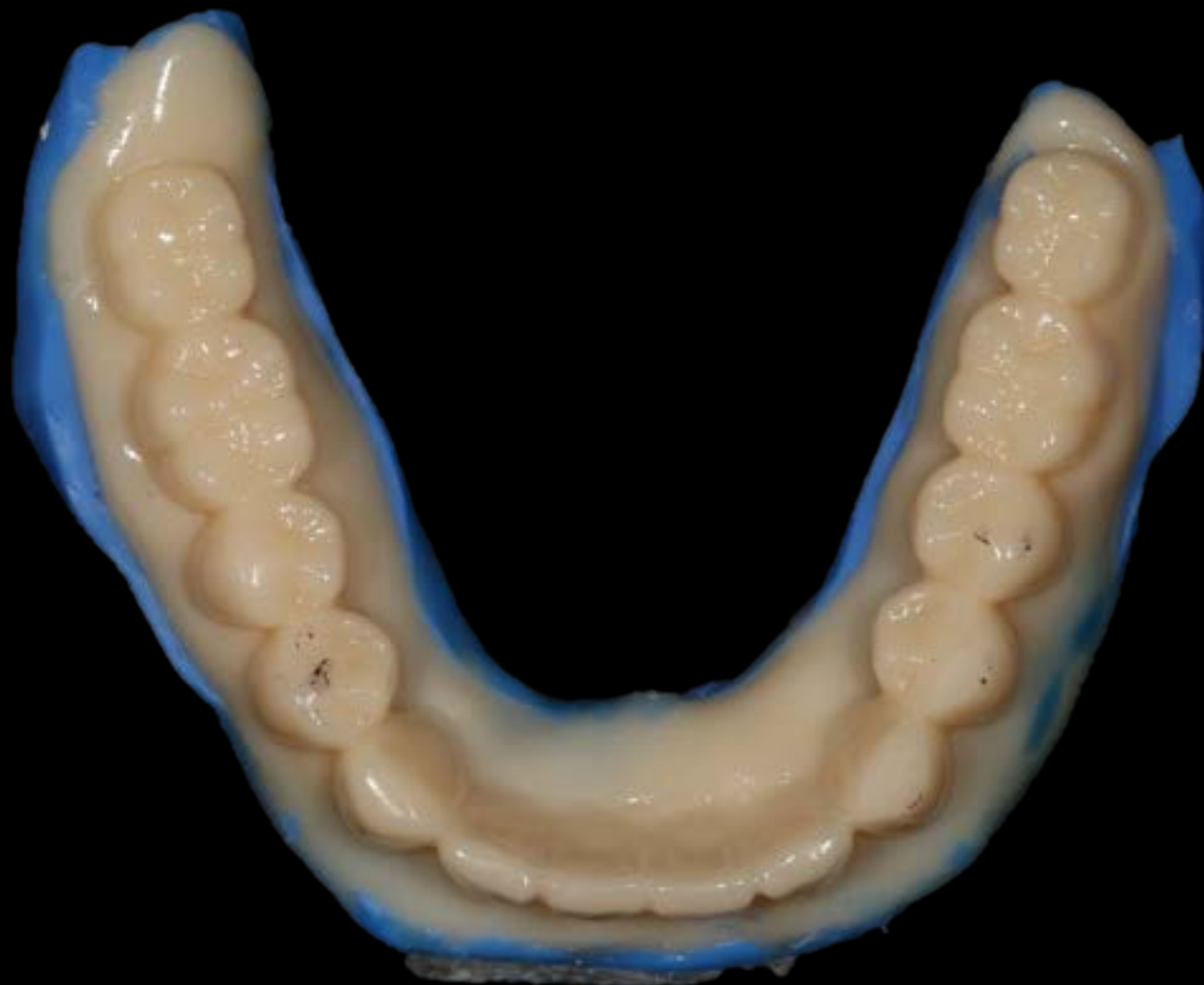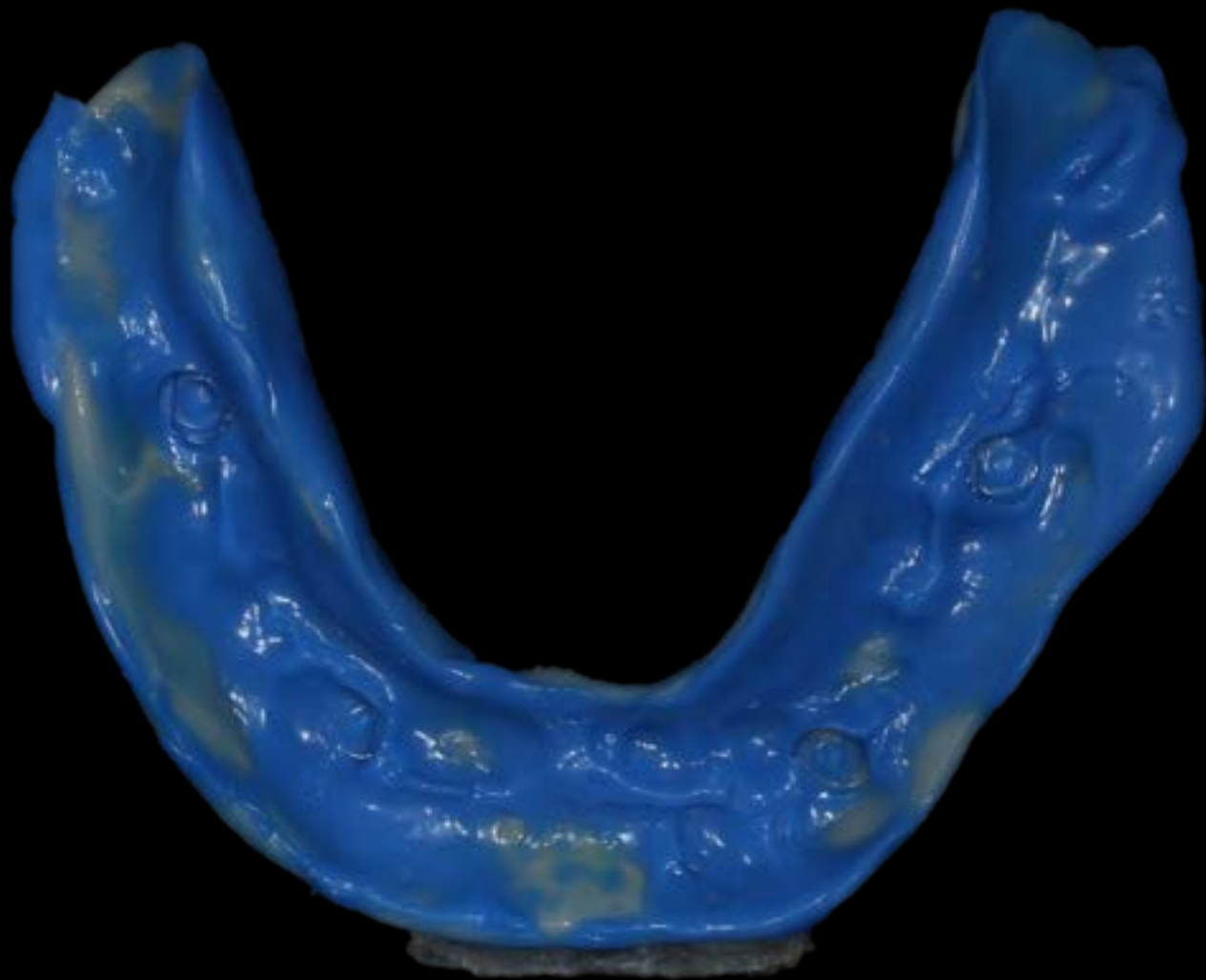
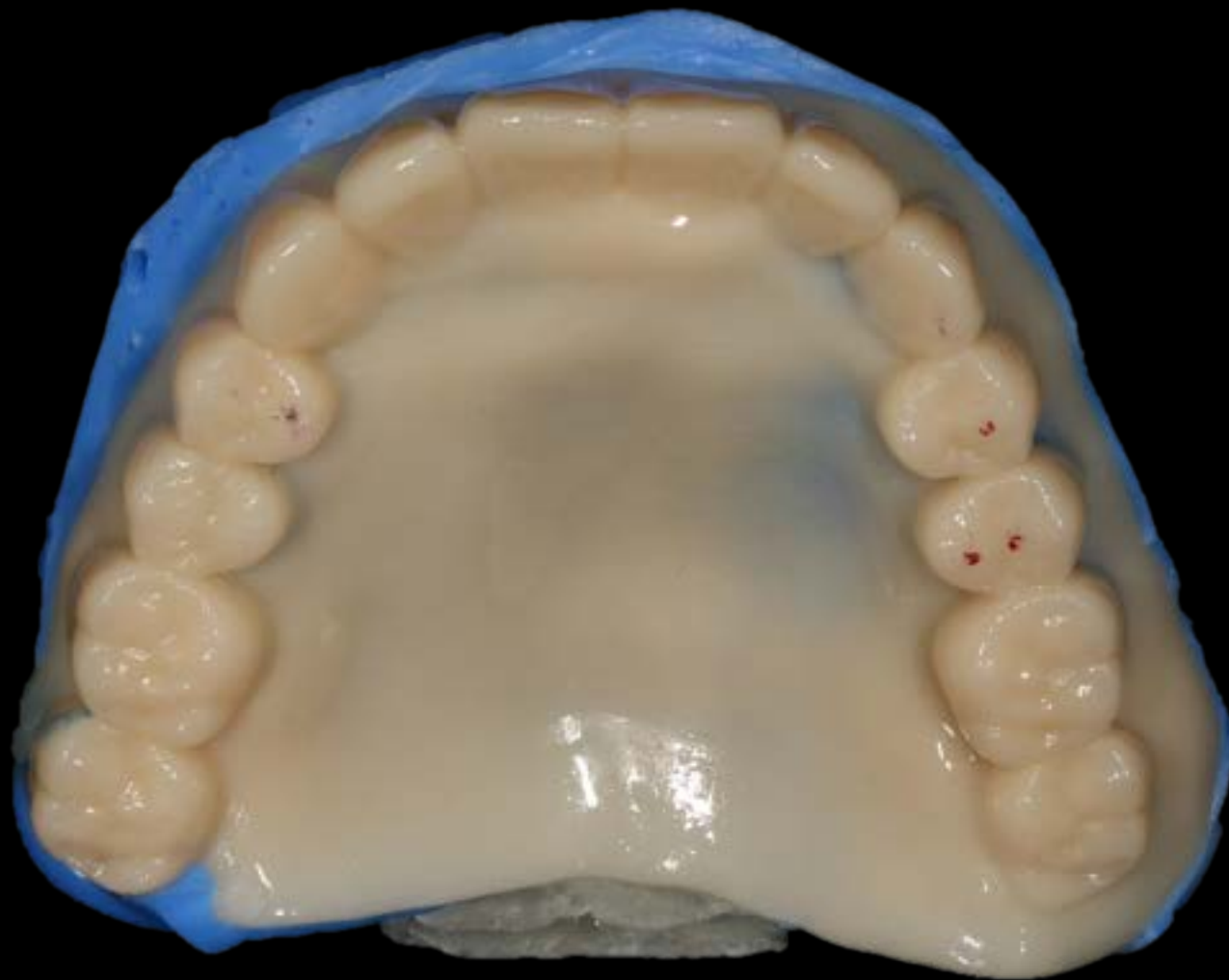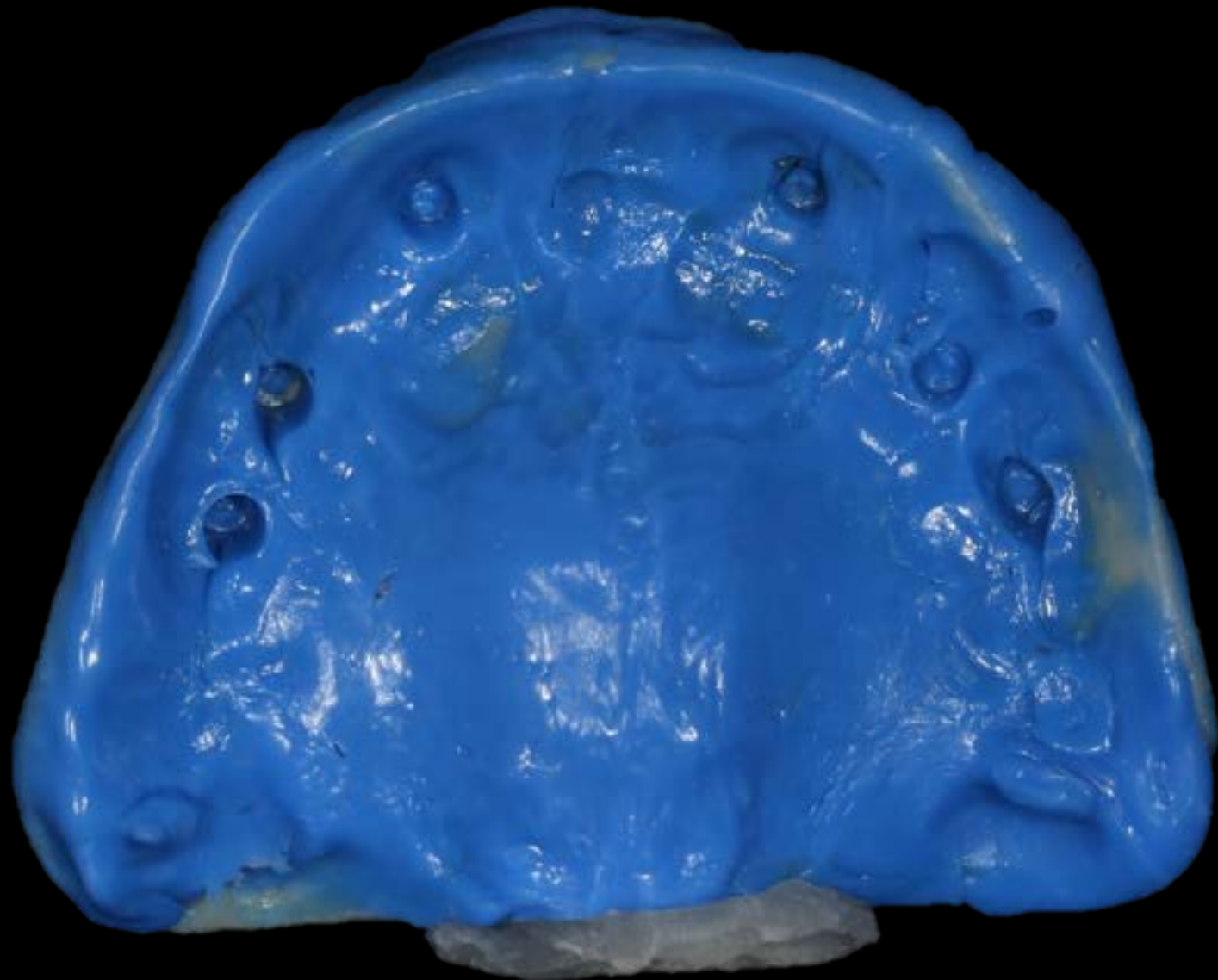
IOS for printing model



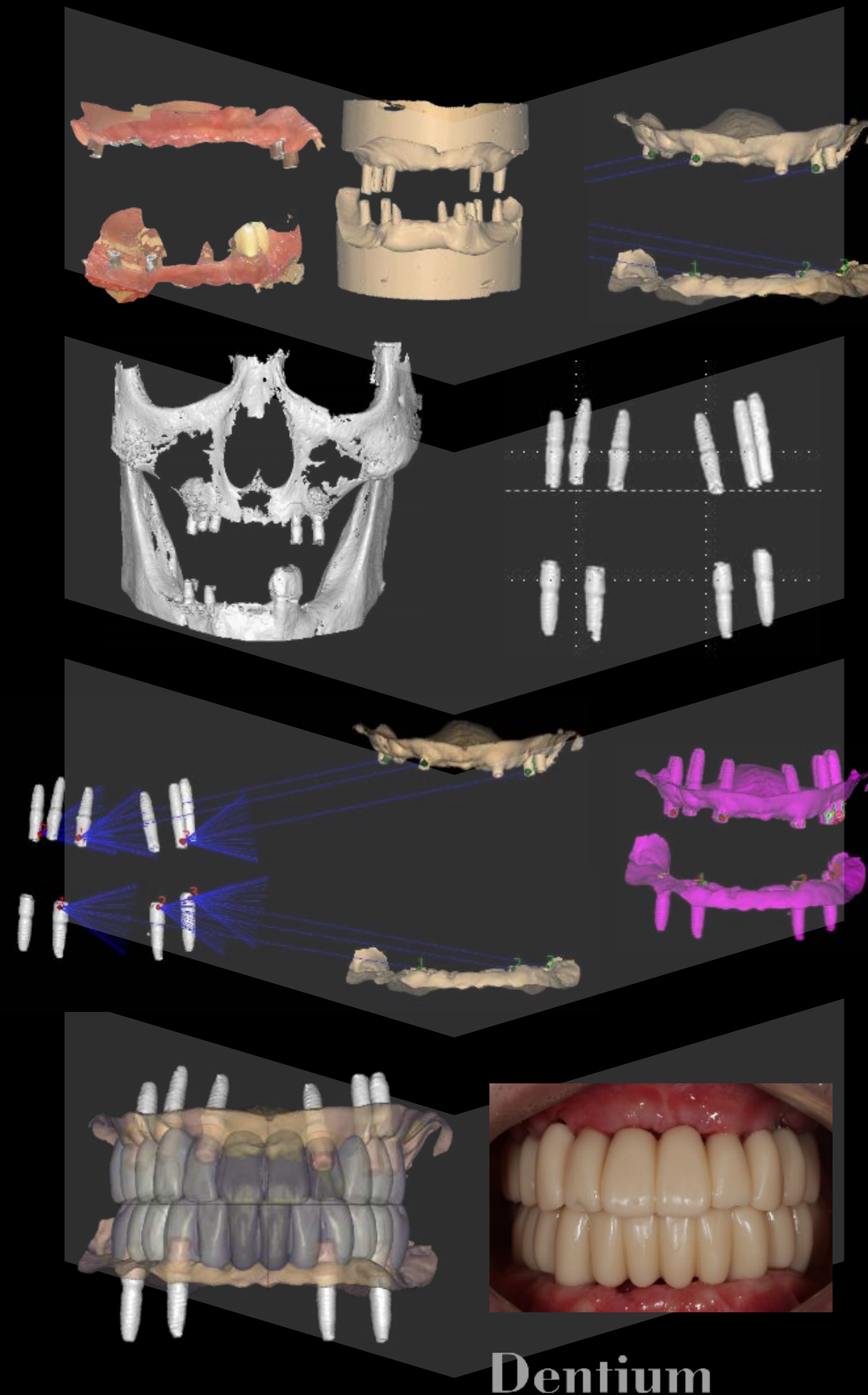
Printing model for Temporary denture relining



Denture duplication for Provisional prosthesis



CT stitching for bite taking Process



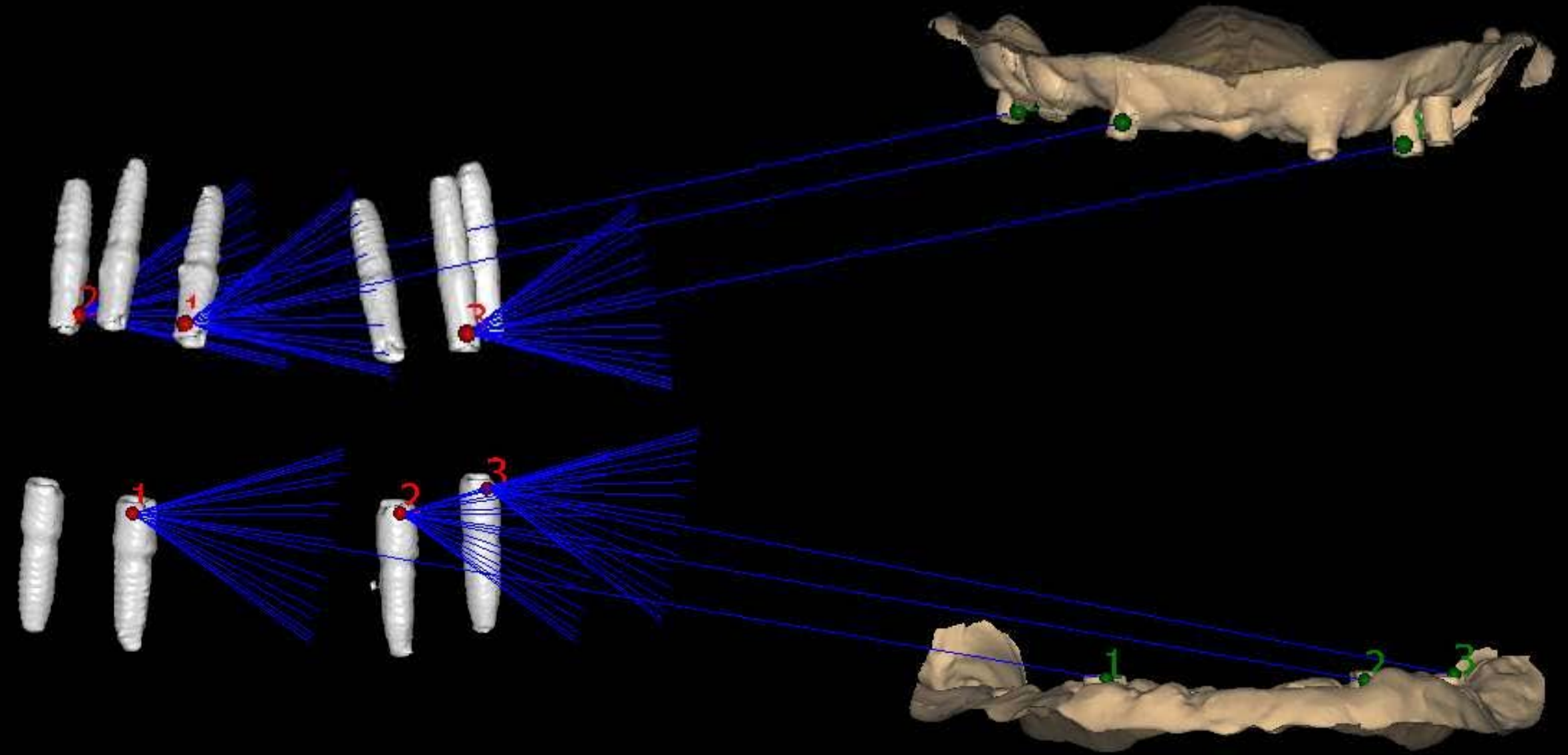
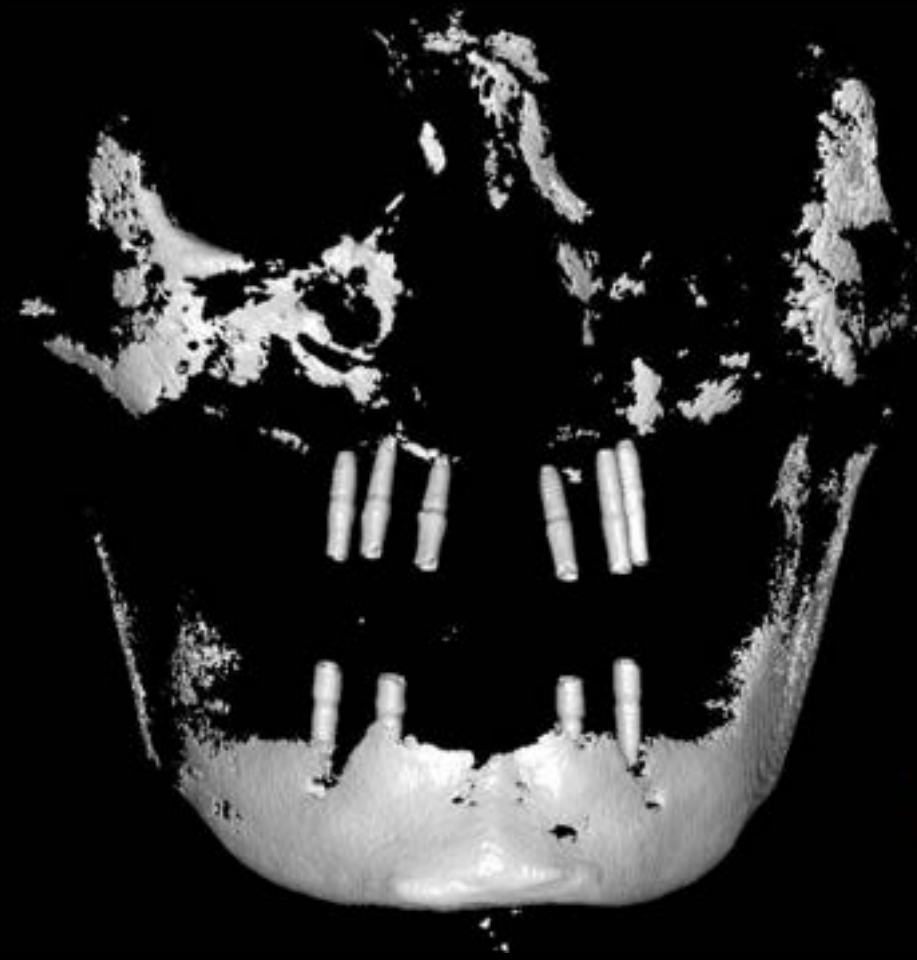
1) Impression taking
(IOS, model scan, **impression scan** etc.)

2) CT DICOM → STL export & editing

3) CT STL + Impression data stitching

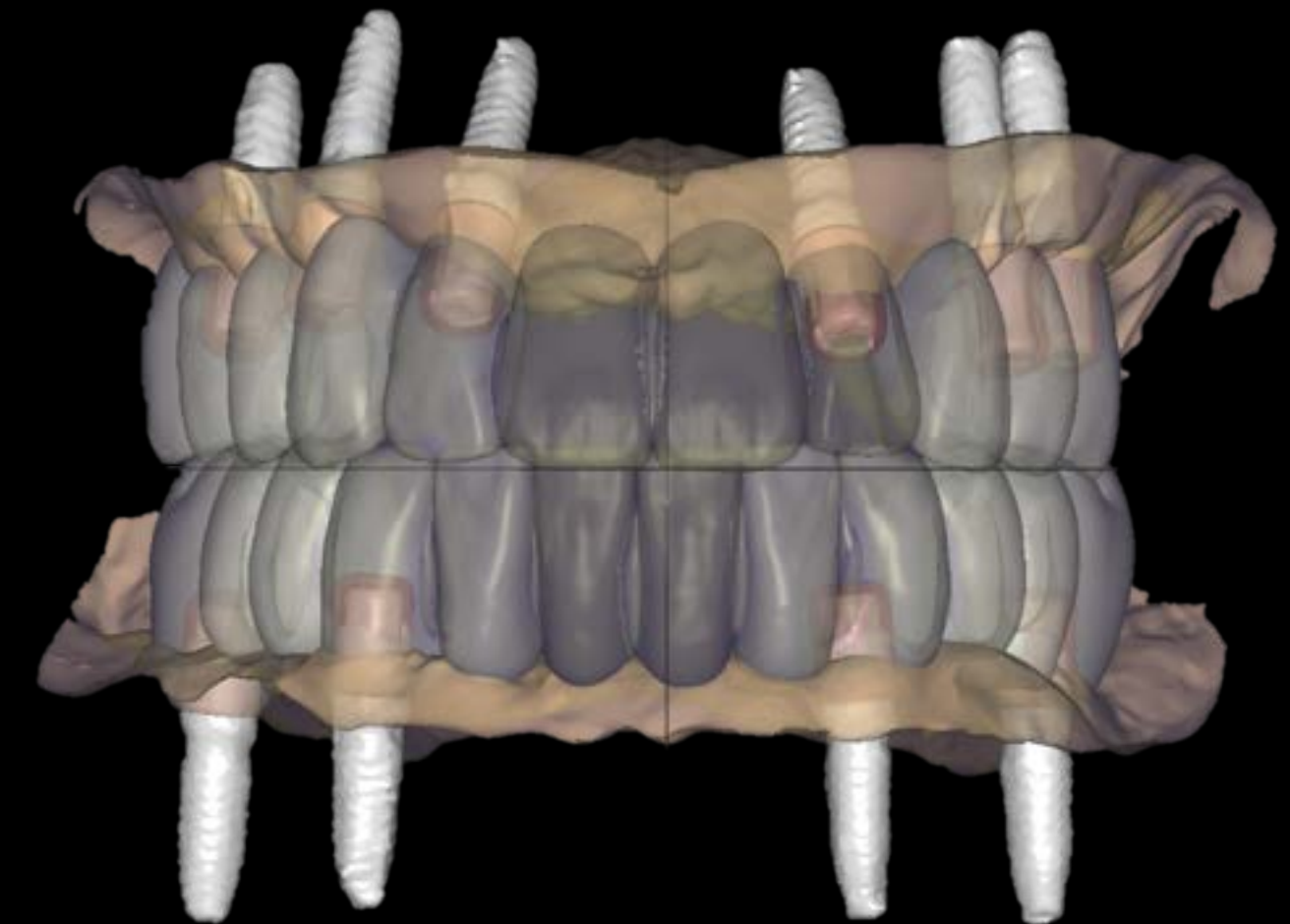

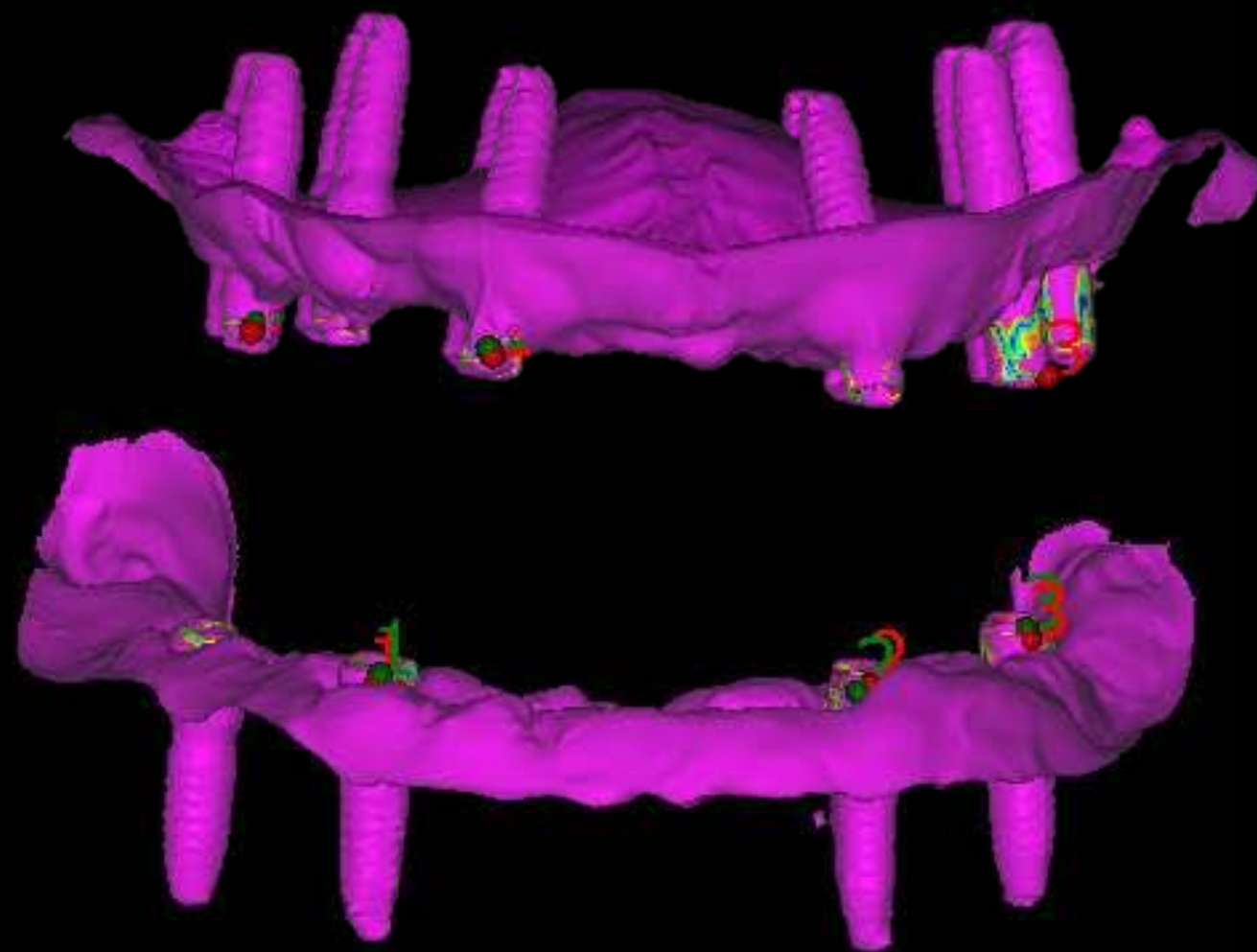

4) Dental CAD design & prosthesis delivery

CT stitching



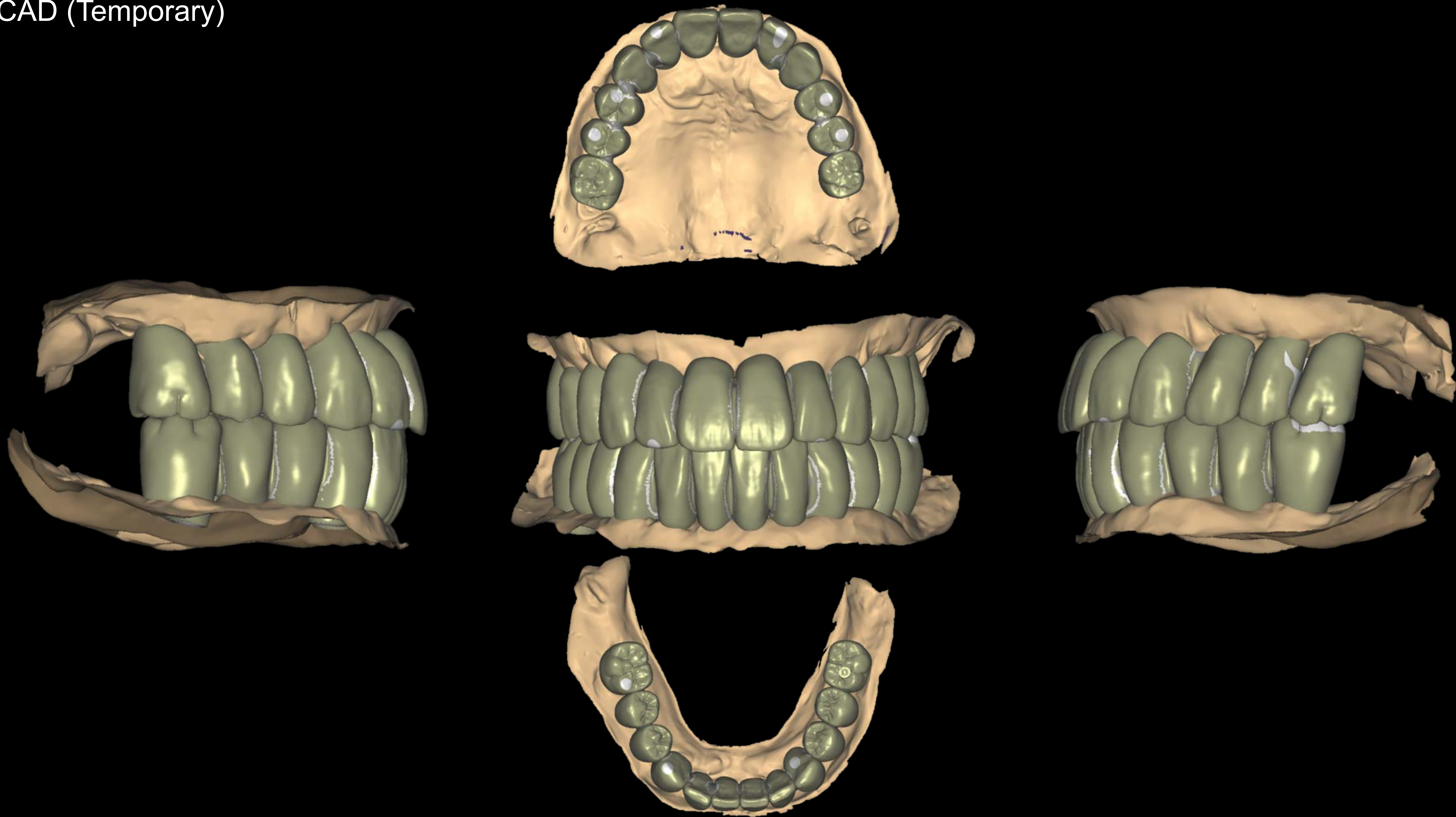
CT STL export & editing

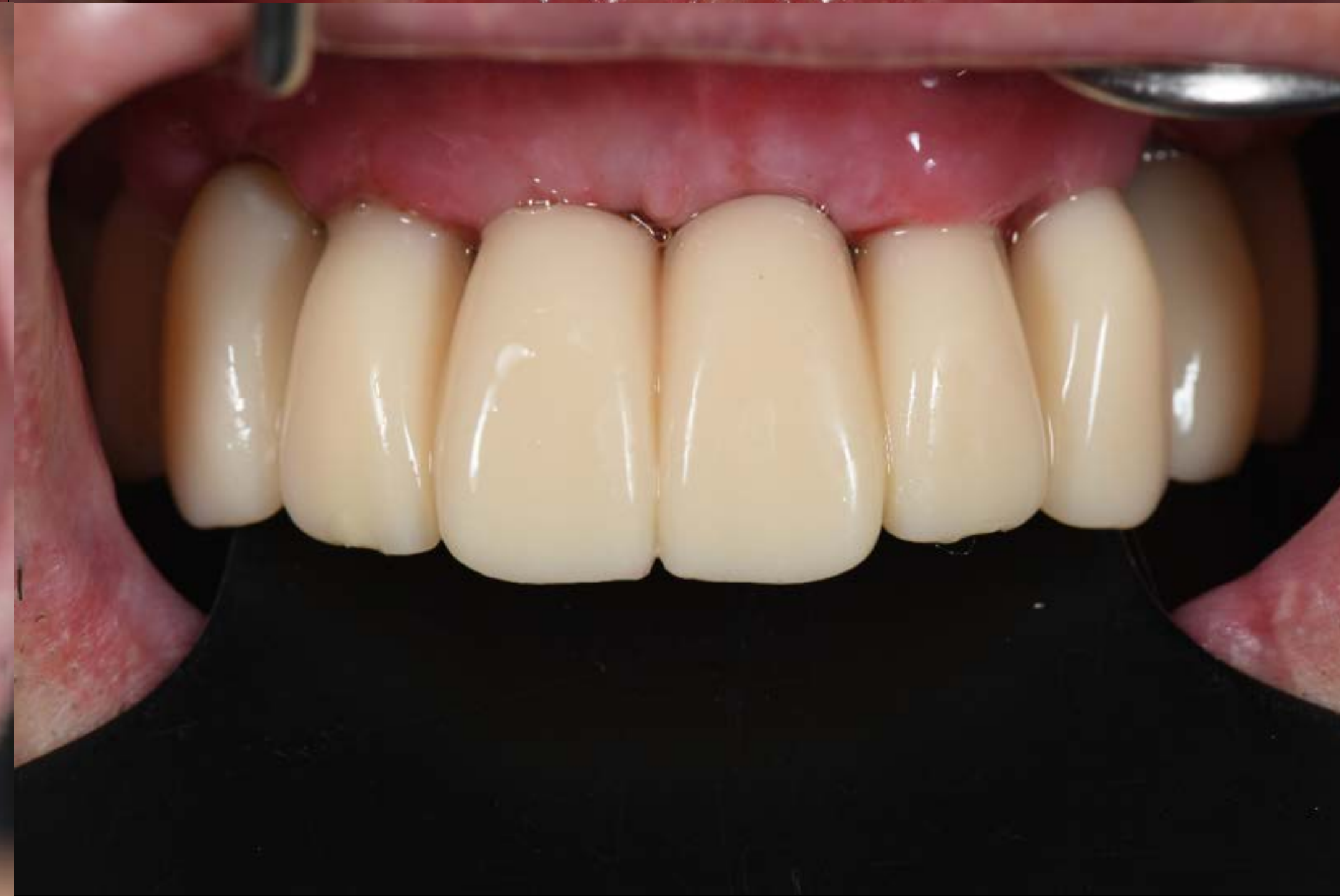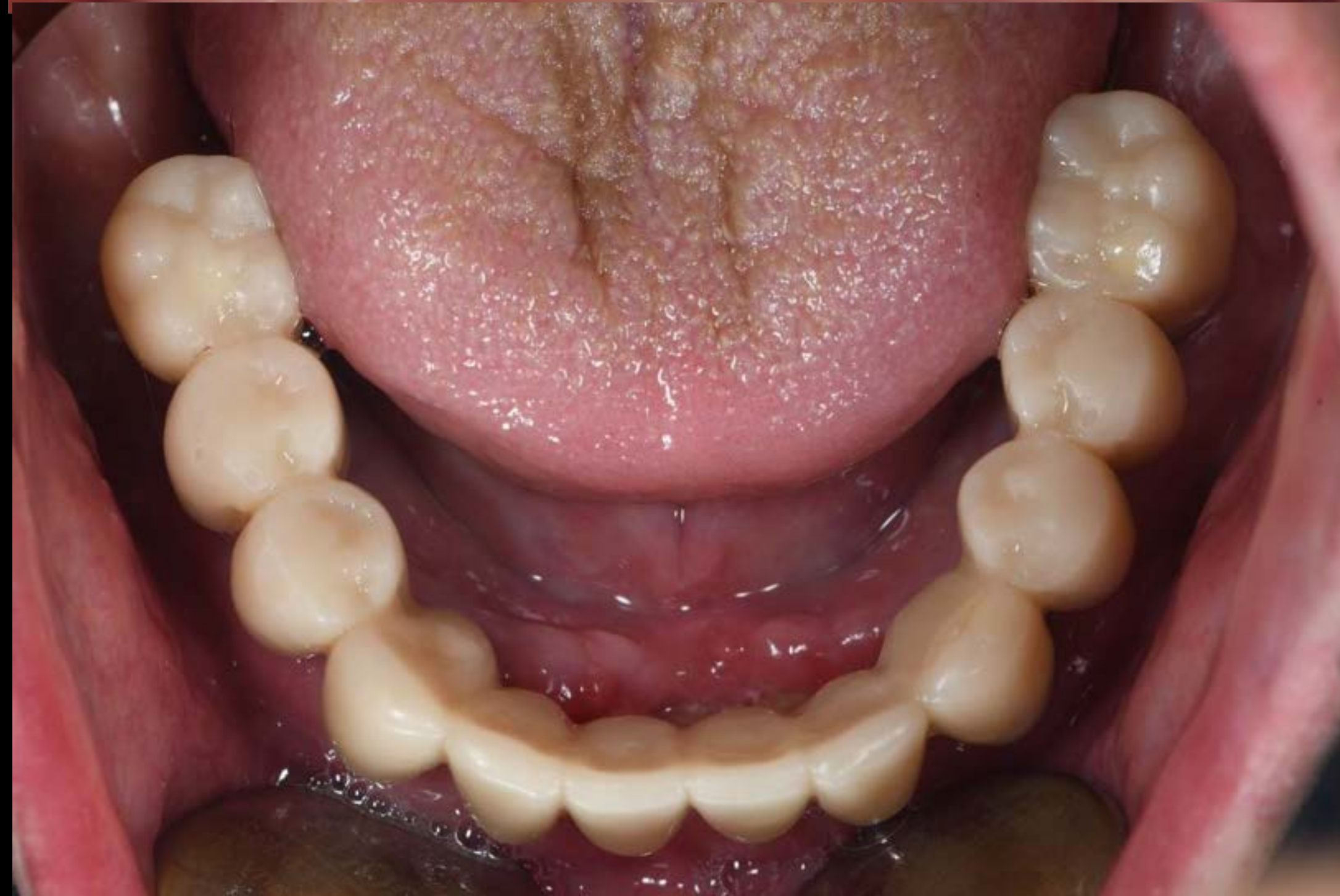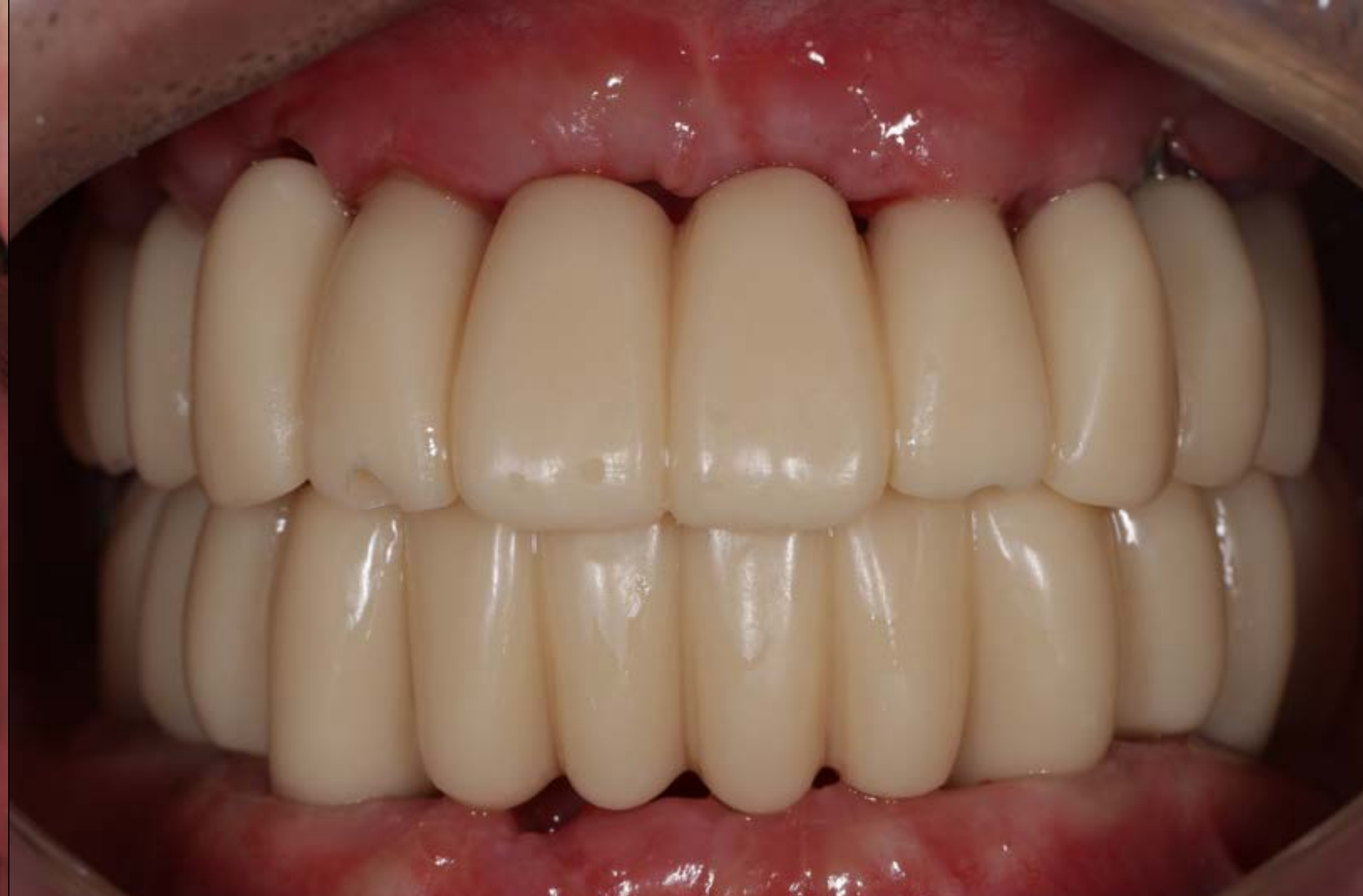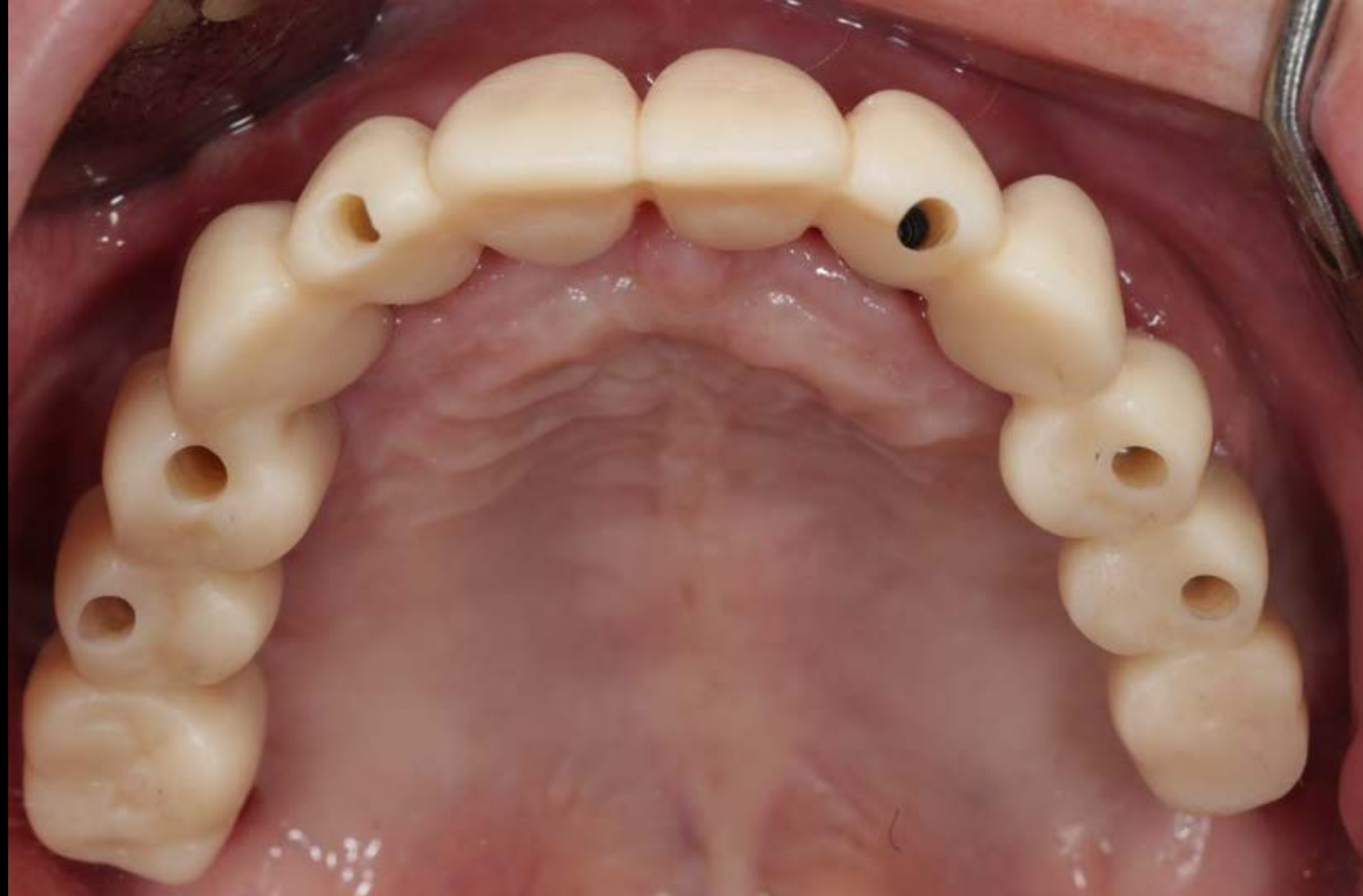
CT STL & working model stitching



Crown design

CAD (Temporary)

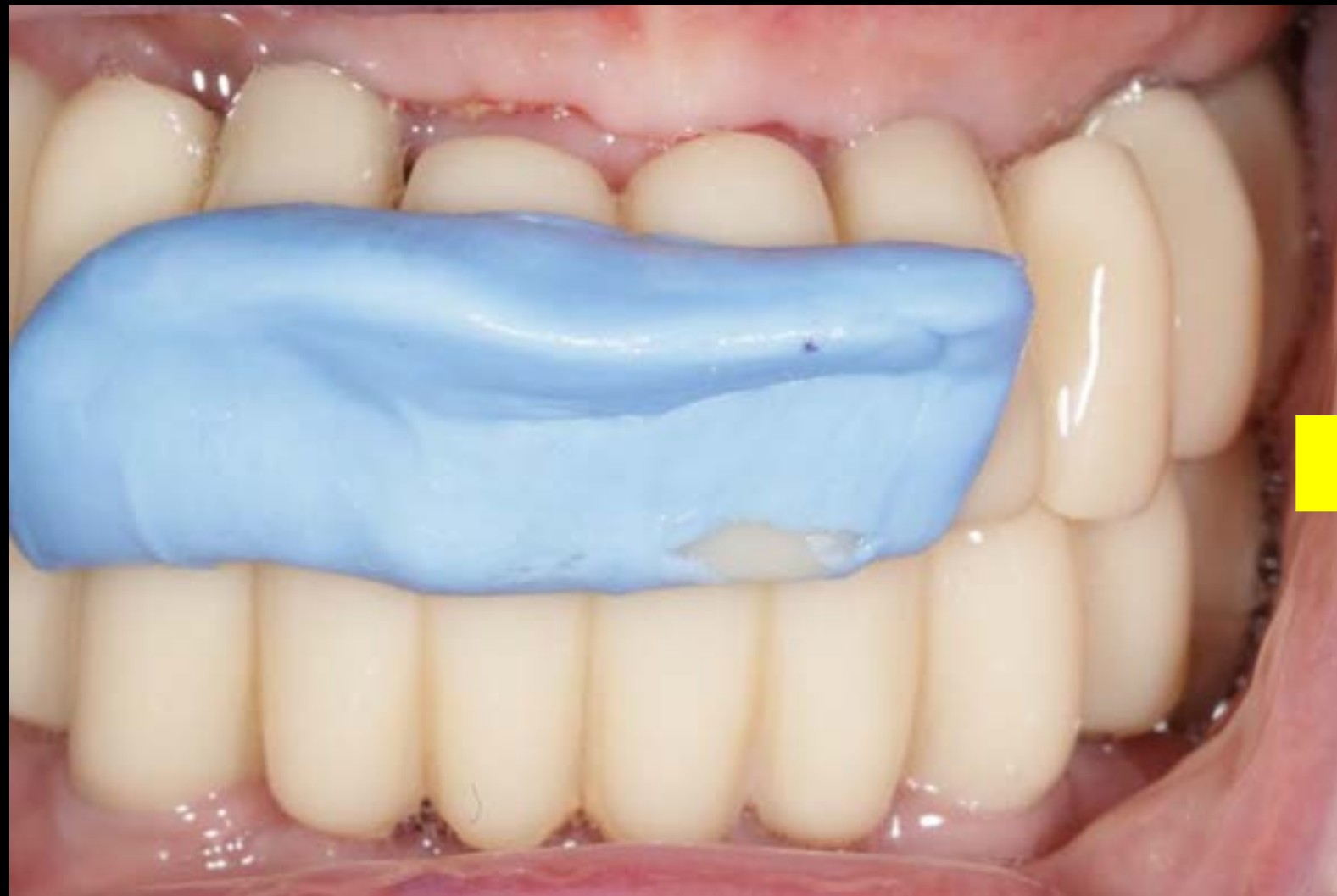



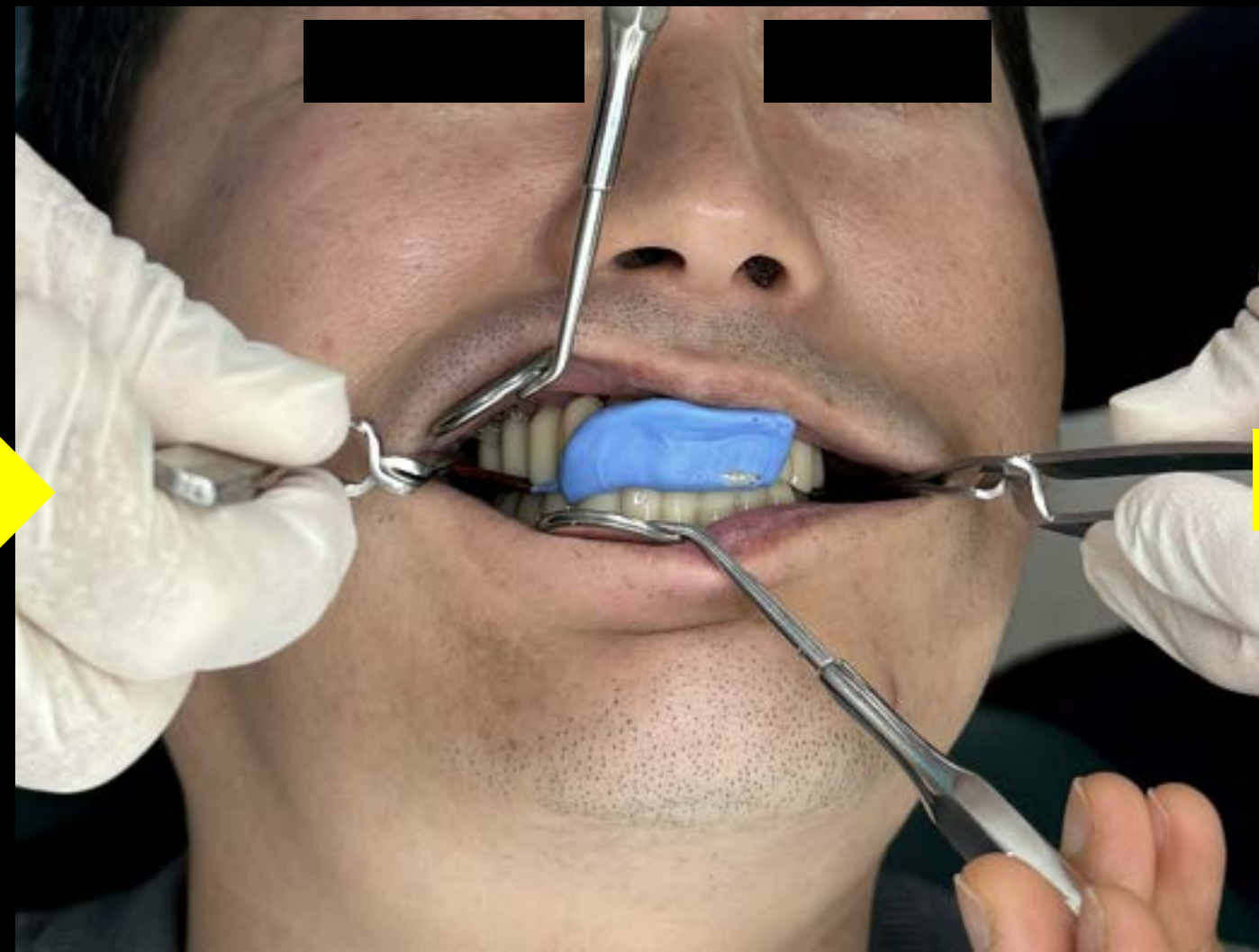
Final impression process with Digital

1) CT taking with putty index

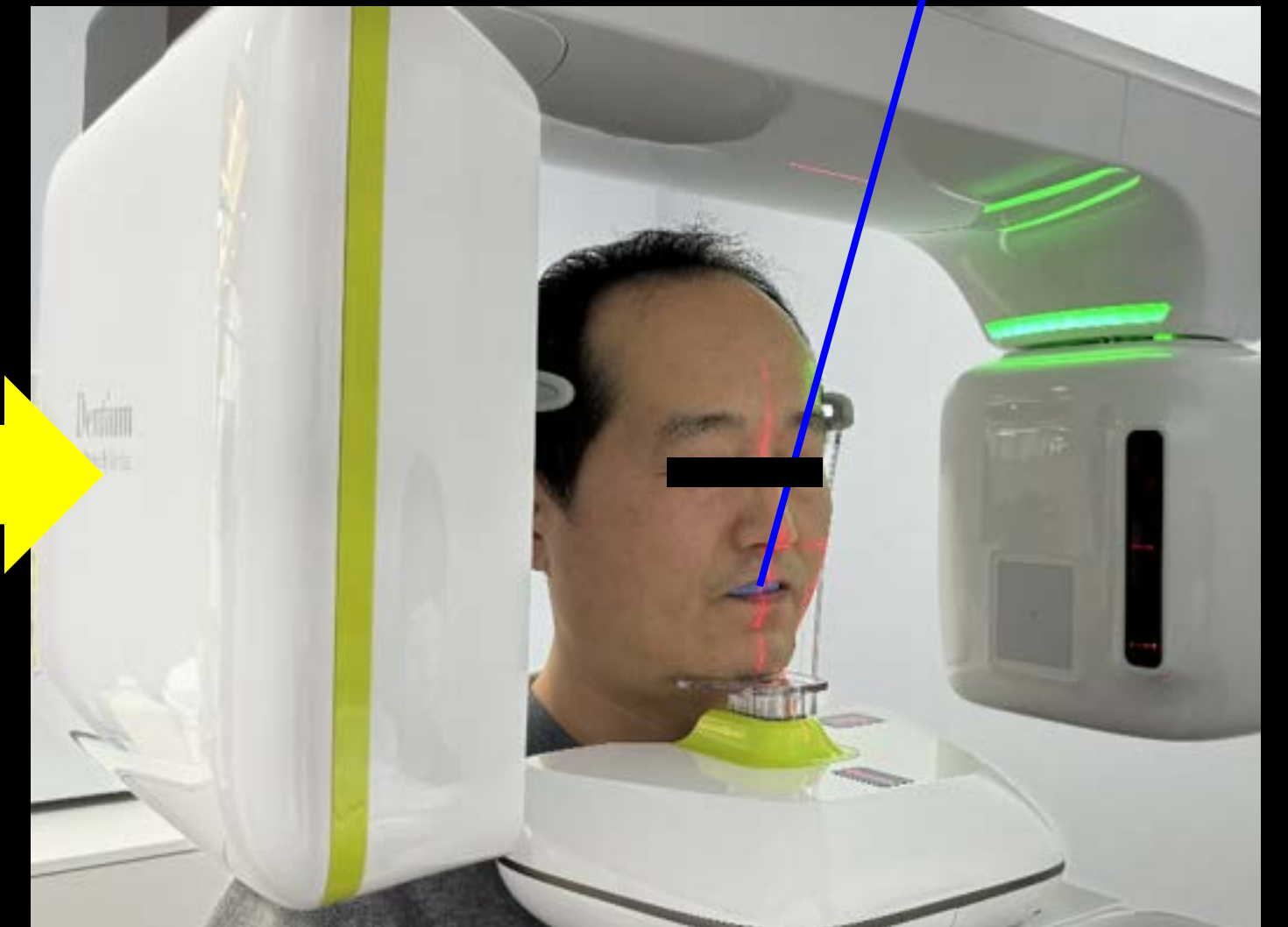
Purpose of fixing the precise occlusal state



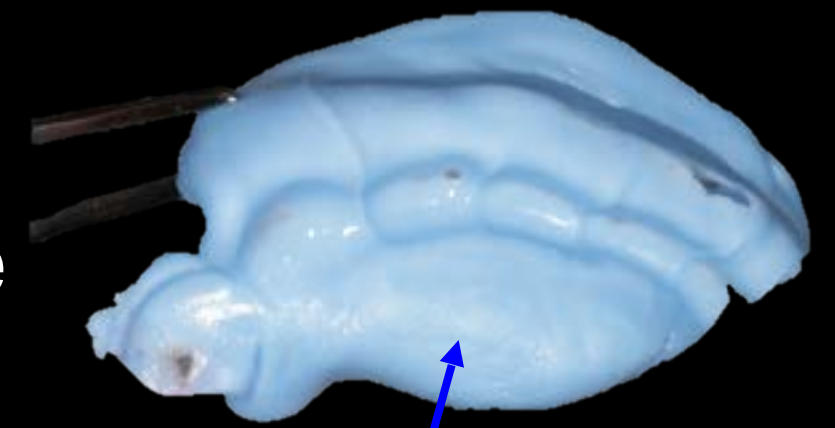
Putty index



Bite checking



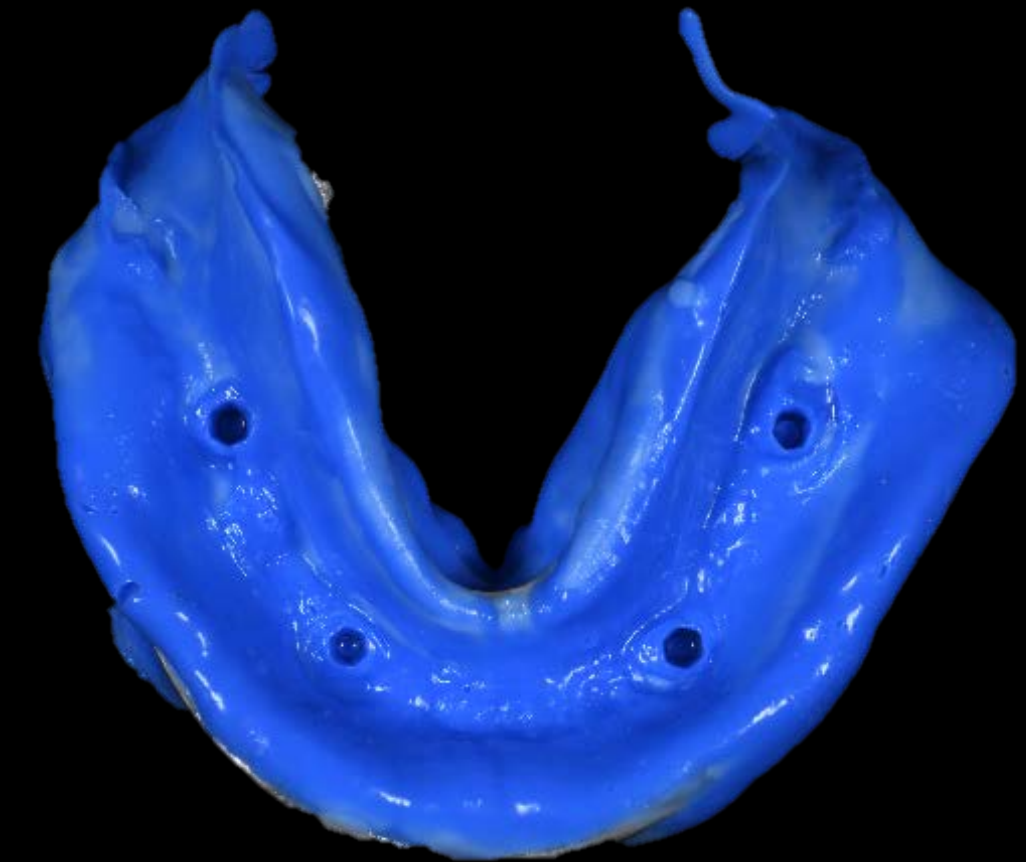
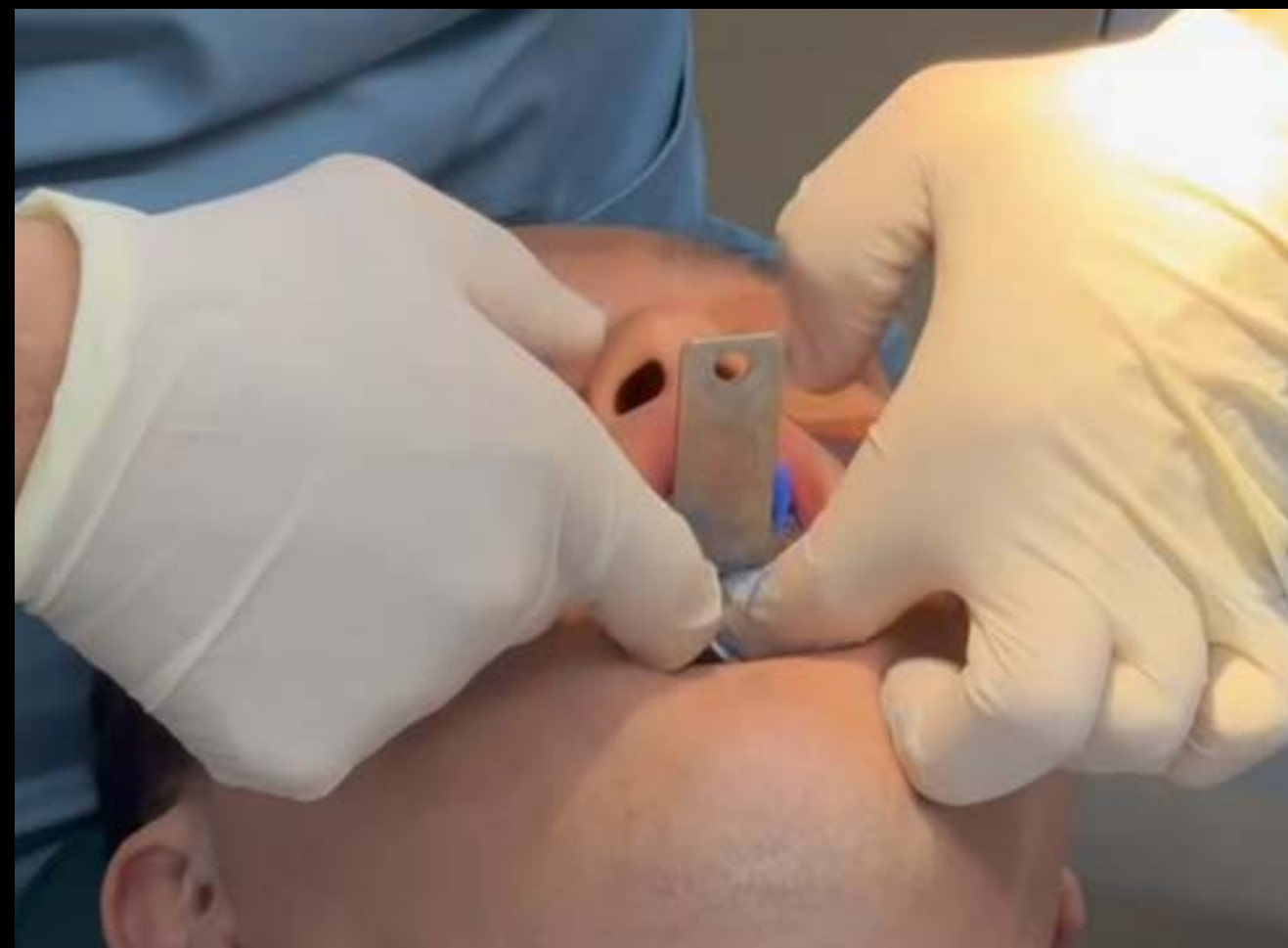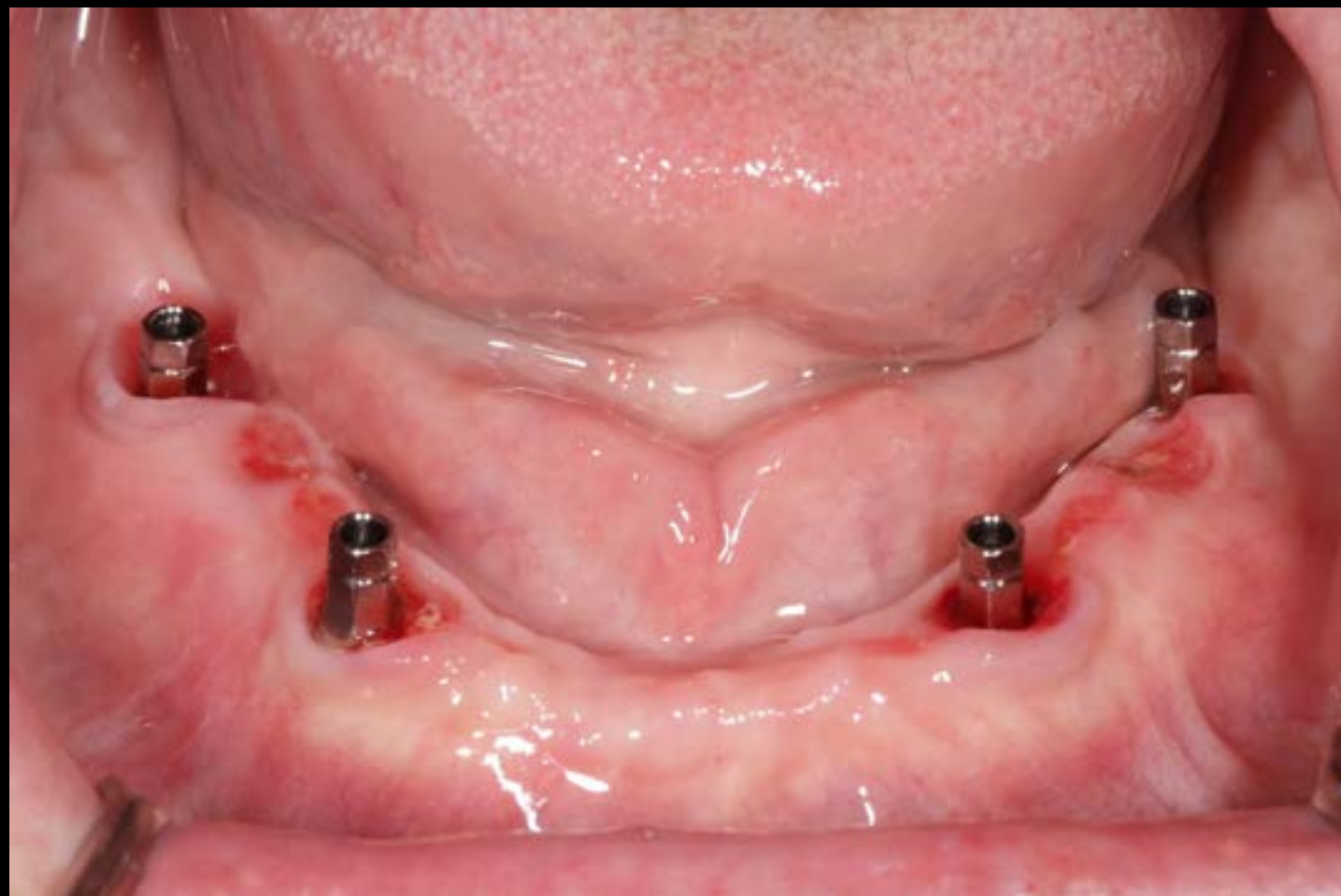
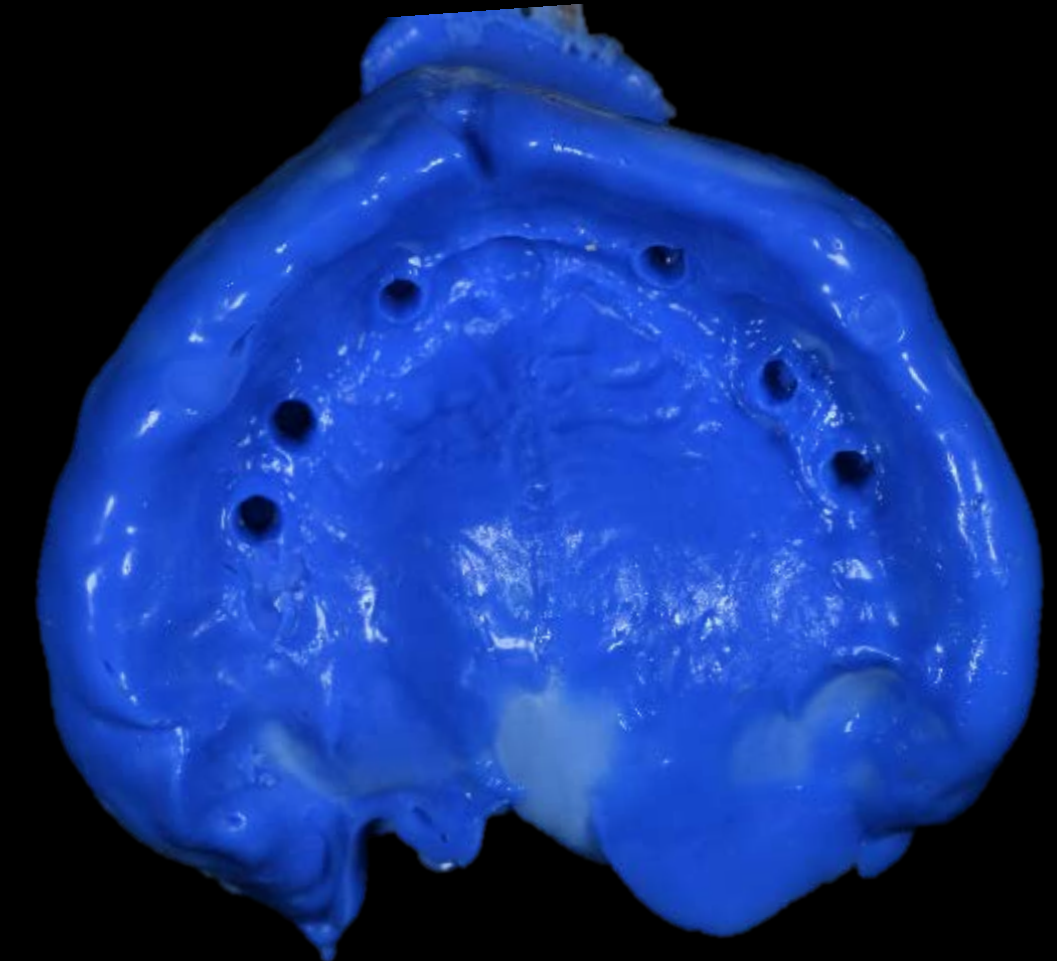
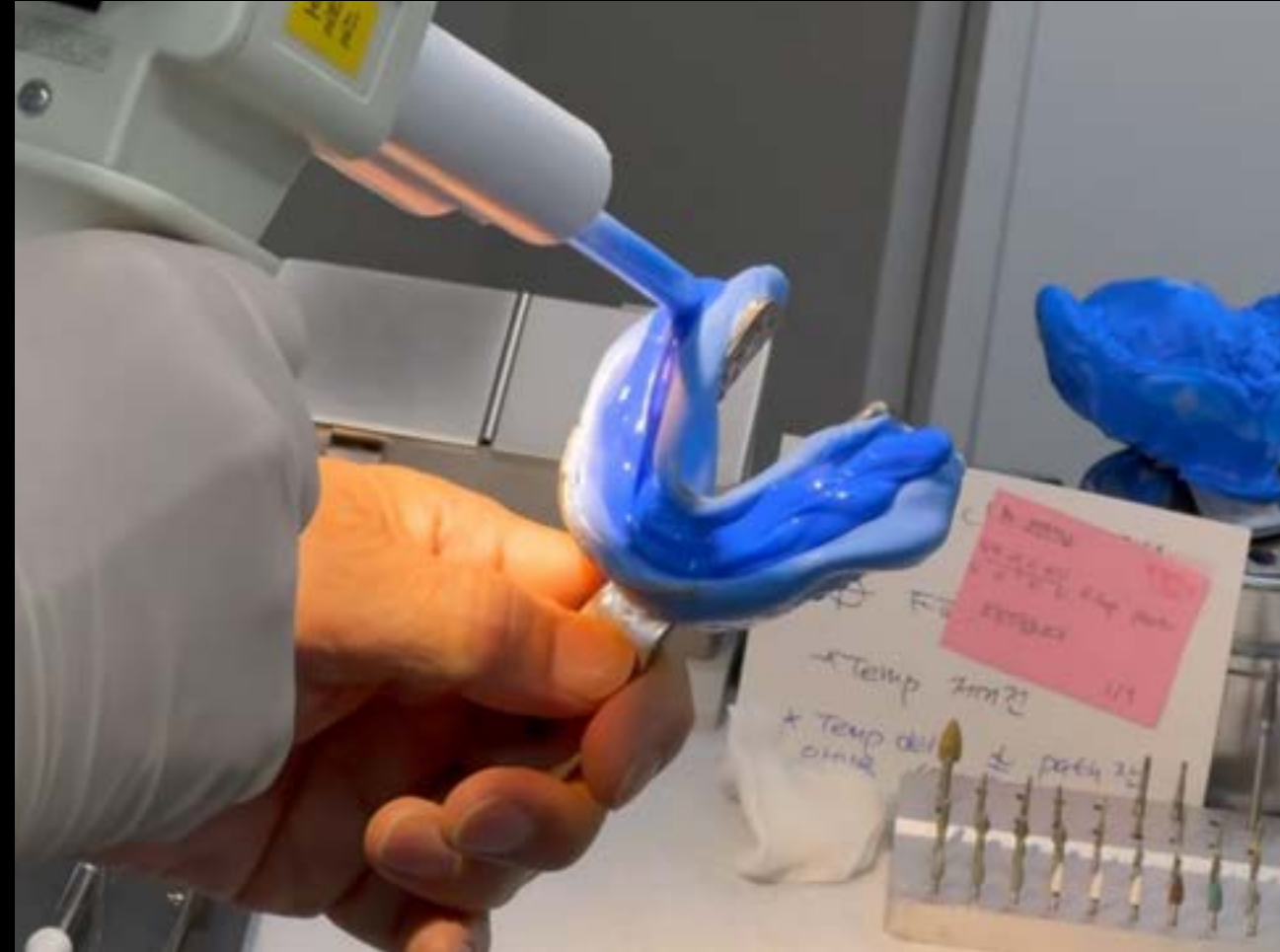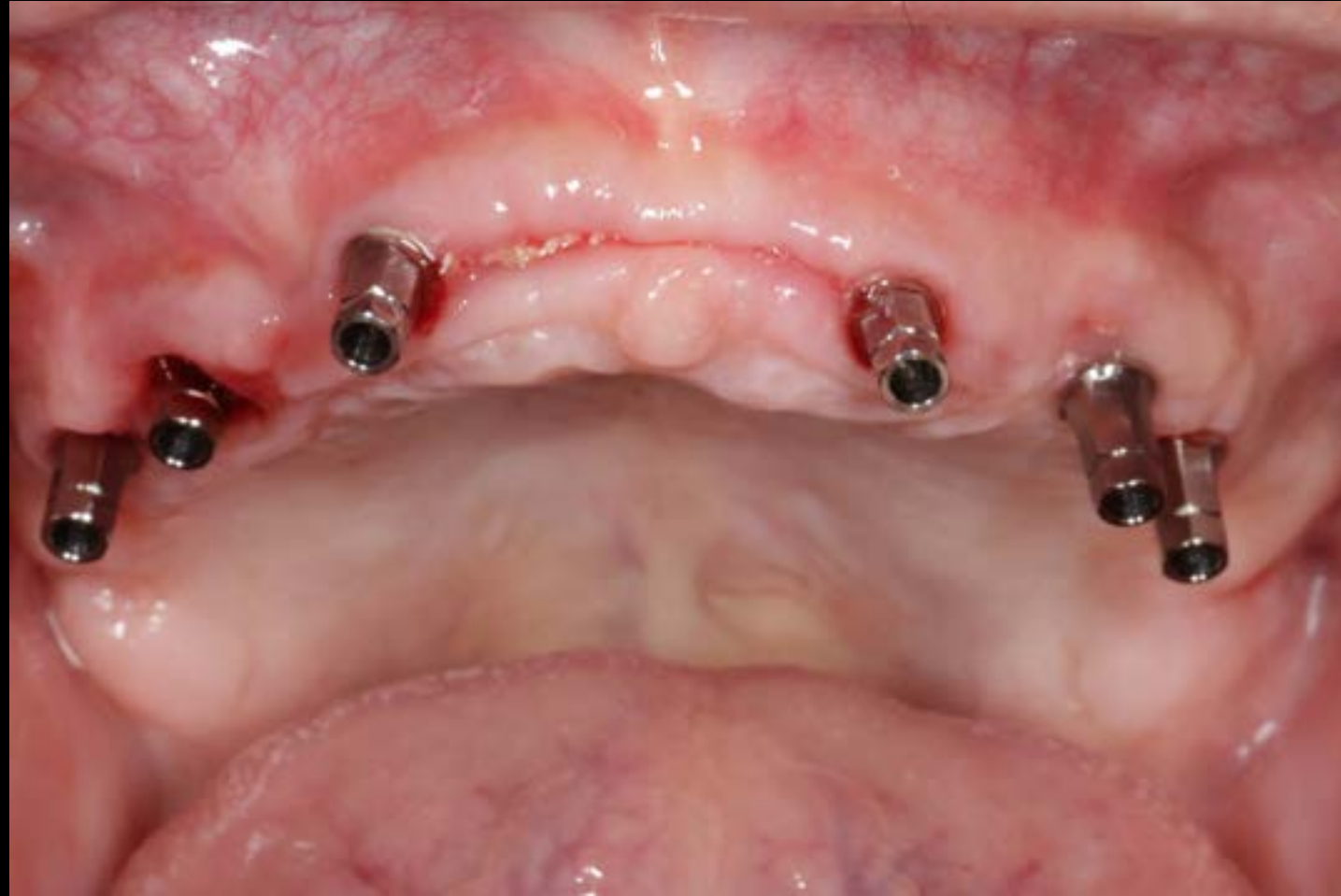CT taking



Final impression process with Digital

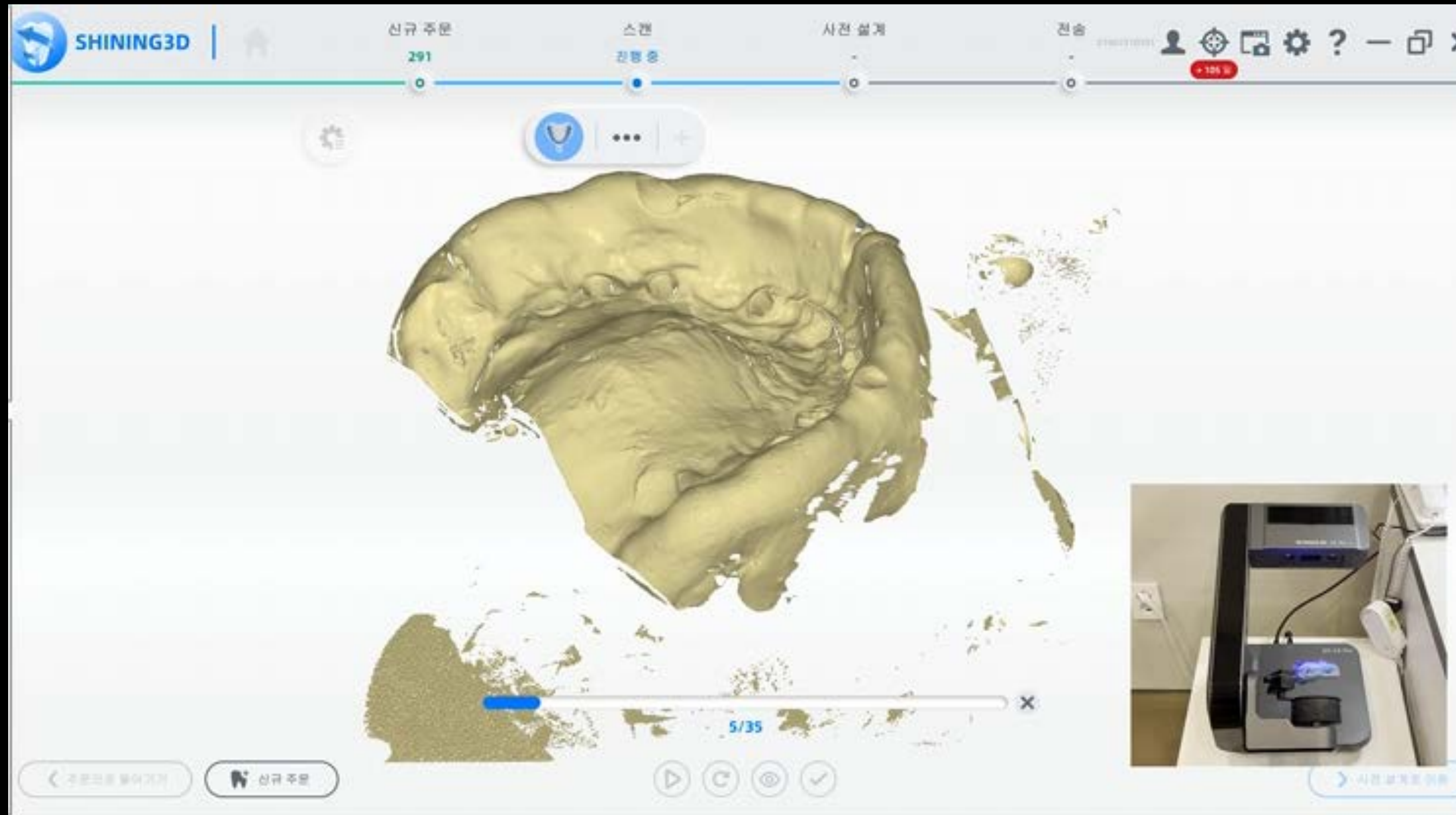
2) 2 Step impression

1 step : putty impression
2 step : regular body impression

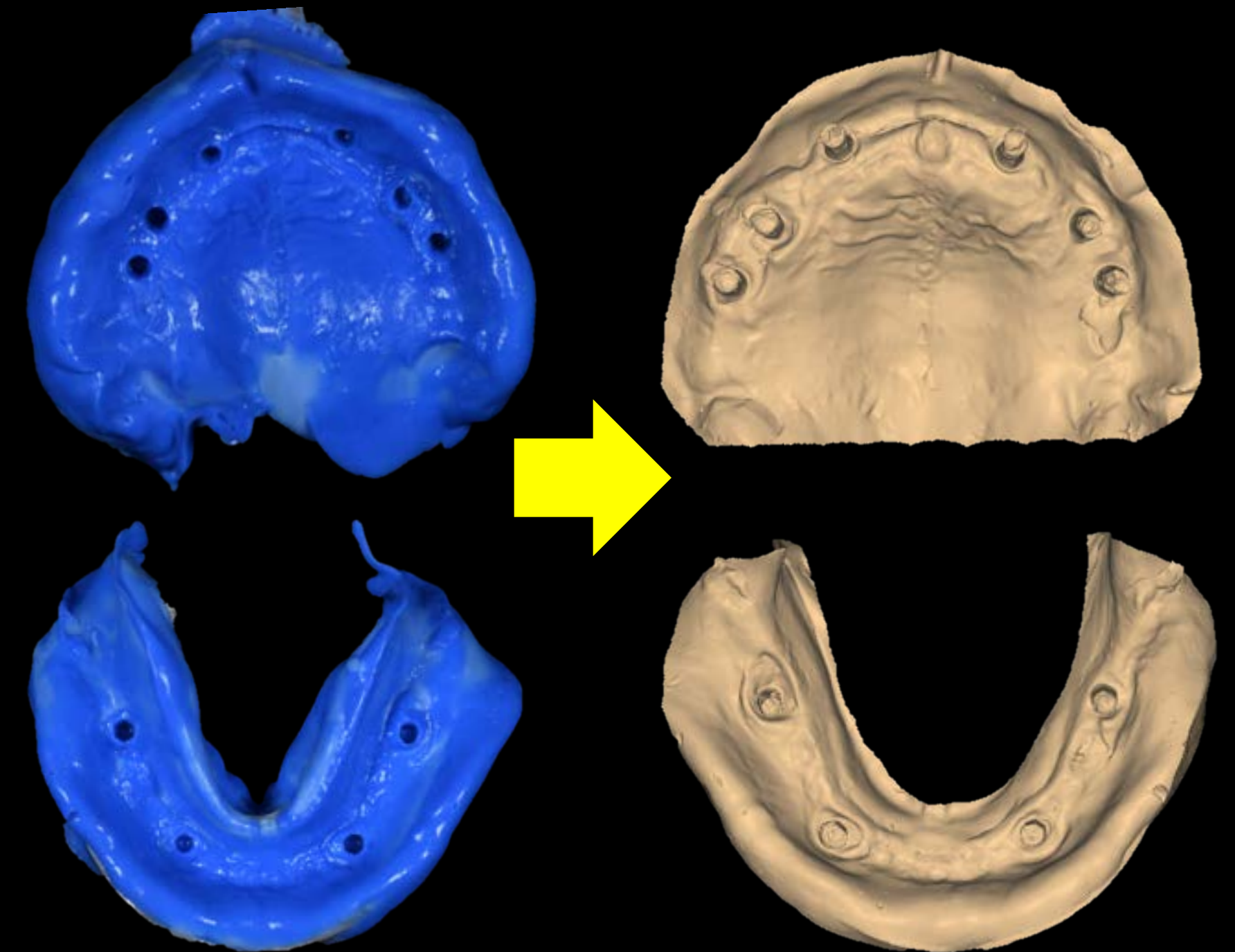


Final impression process with Digital

3) Impression scan without model

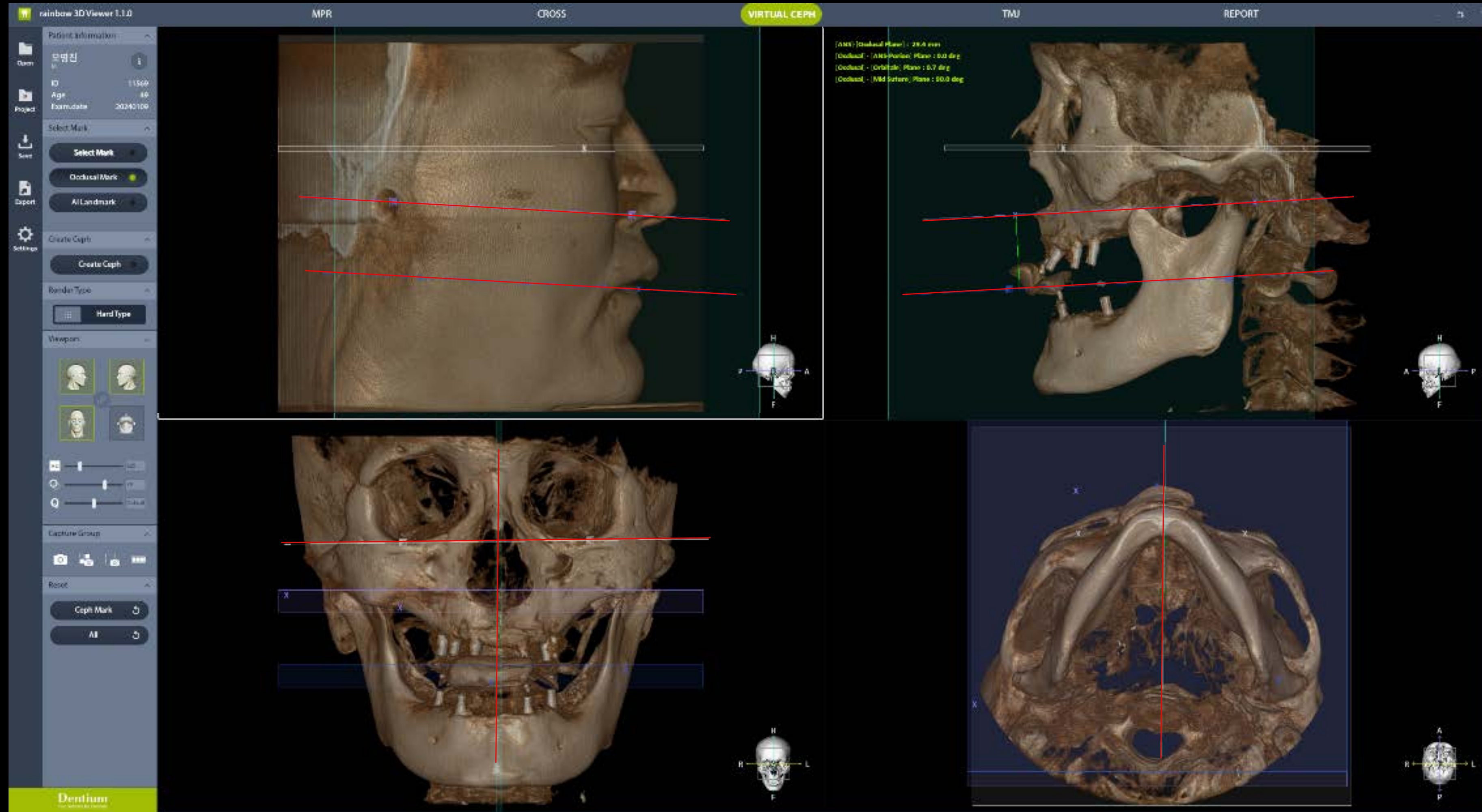


Impression scan with model scanner



Final impression process with Digital

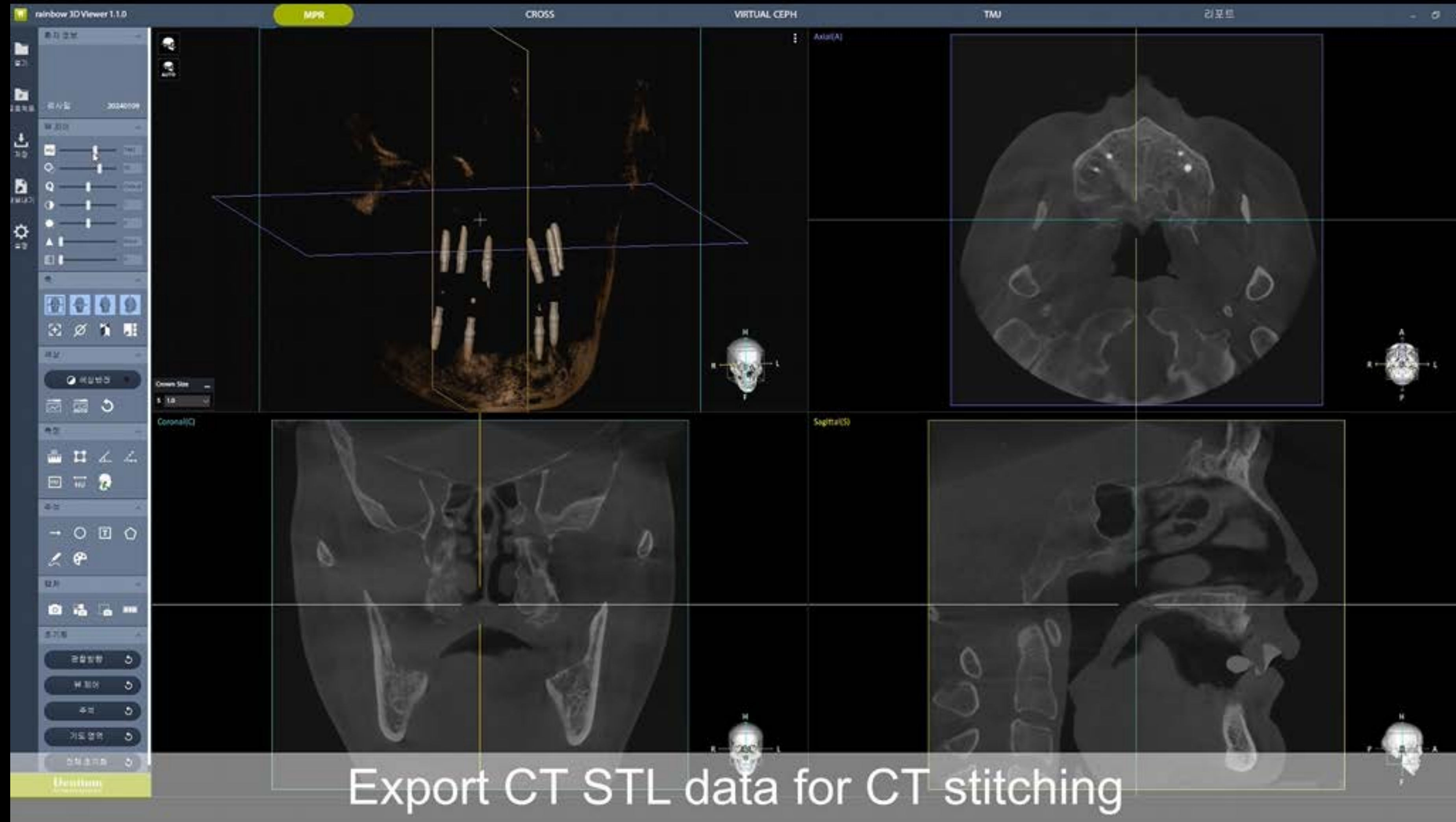4) Rainbow 3D viewer : CT data 활용



AI Occlusal plane

Final impression process with Digital

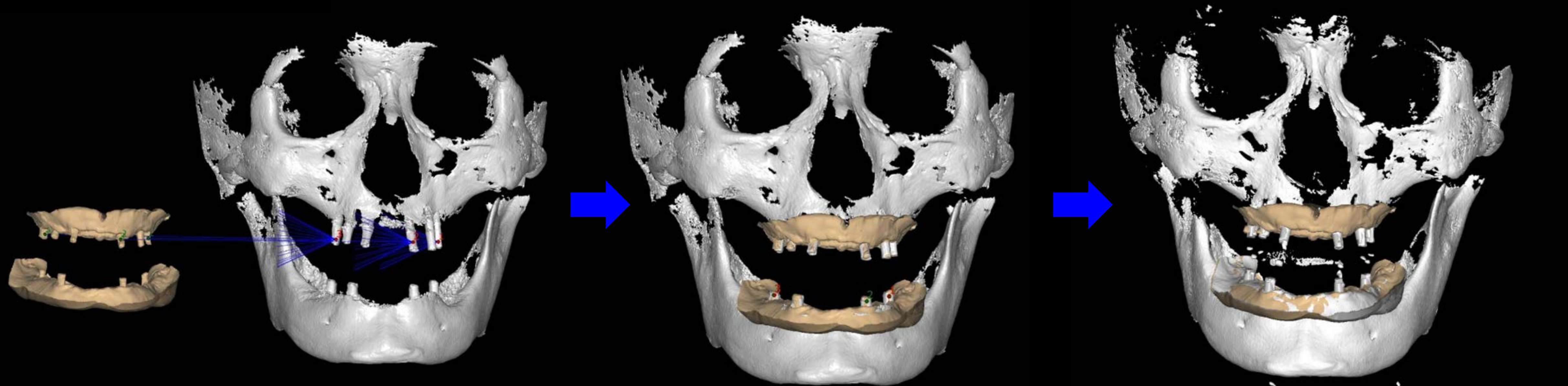
4) Rainbow 3D viewer : CT data 활용



CT STL export

Final impression process with Digital

5) Dental CAD : data stitching for Digital mounting



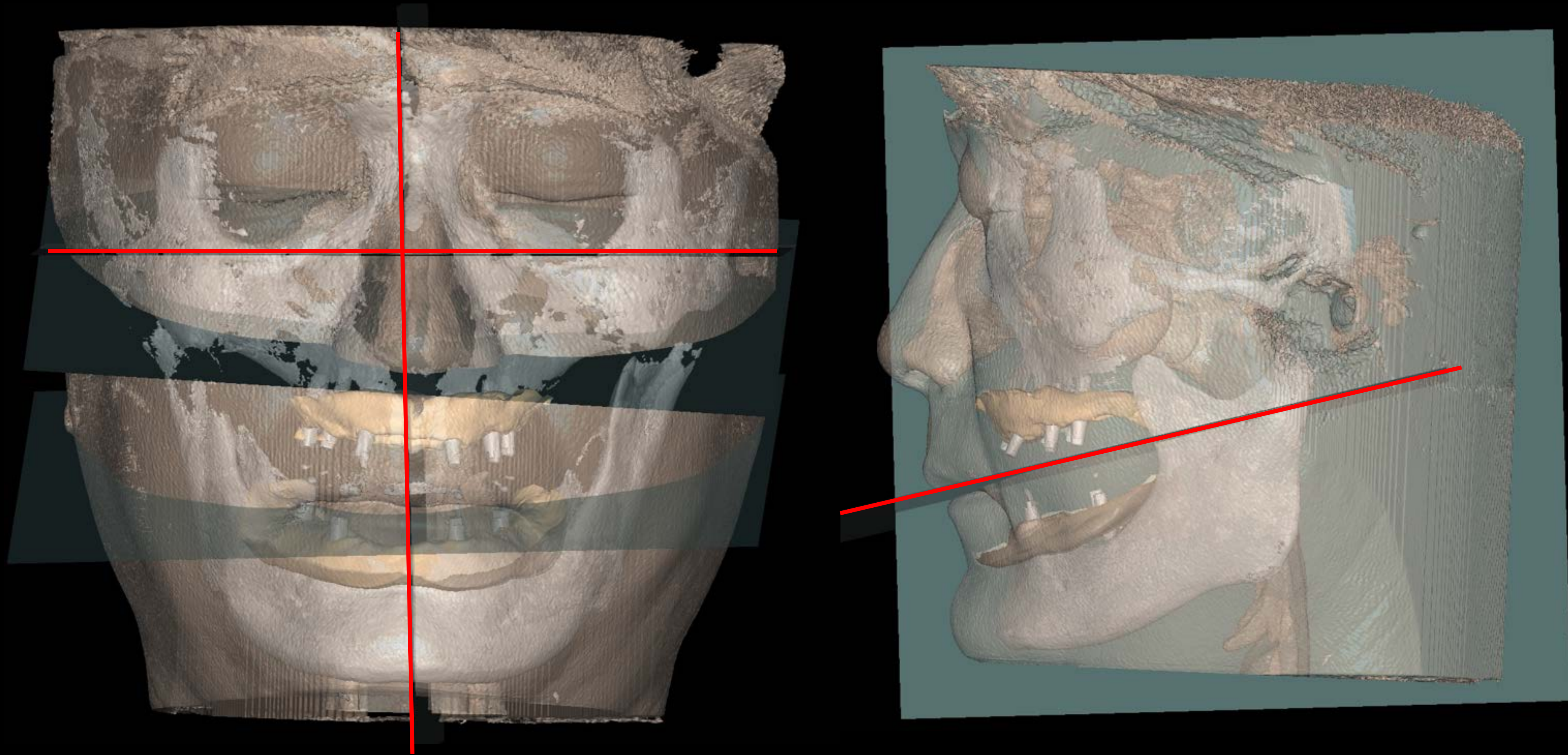
CT STL (Hard tissue) + working model

→ CT의 교합관계 기준으로
working model 정합

abutment (Ti-base) library stitching

Final impression process with Digital

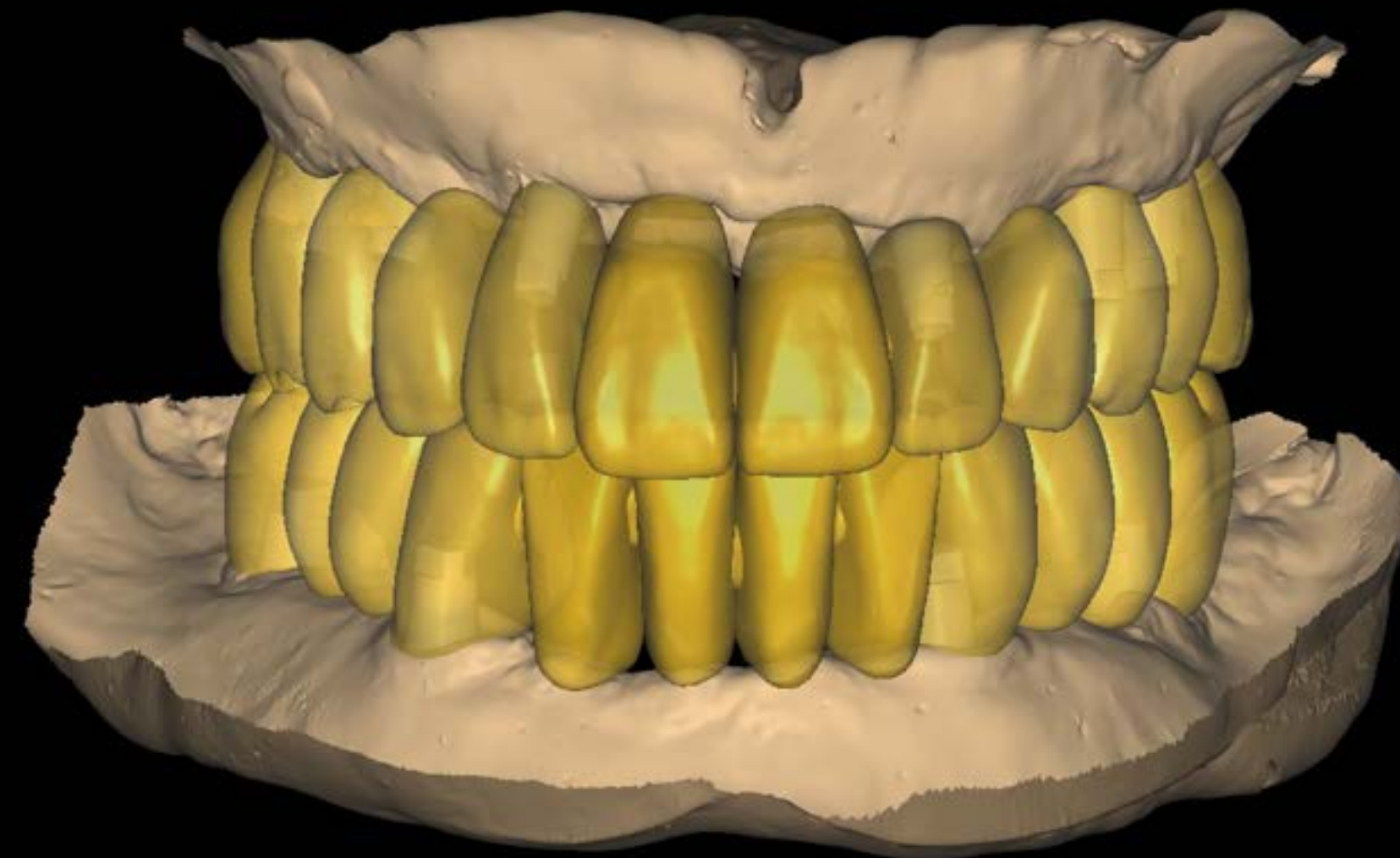
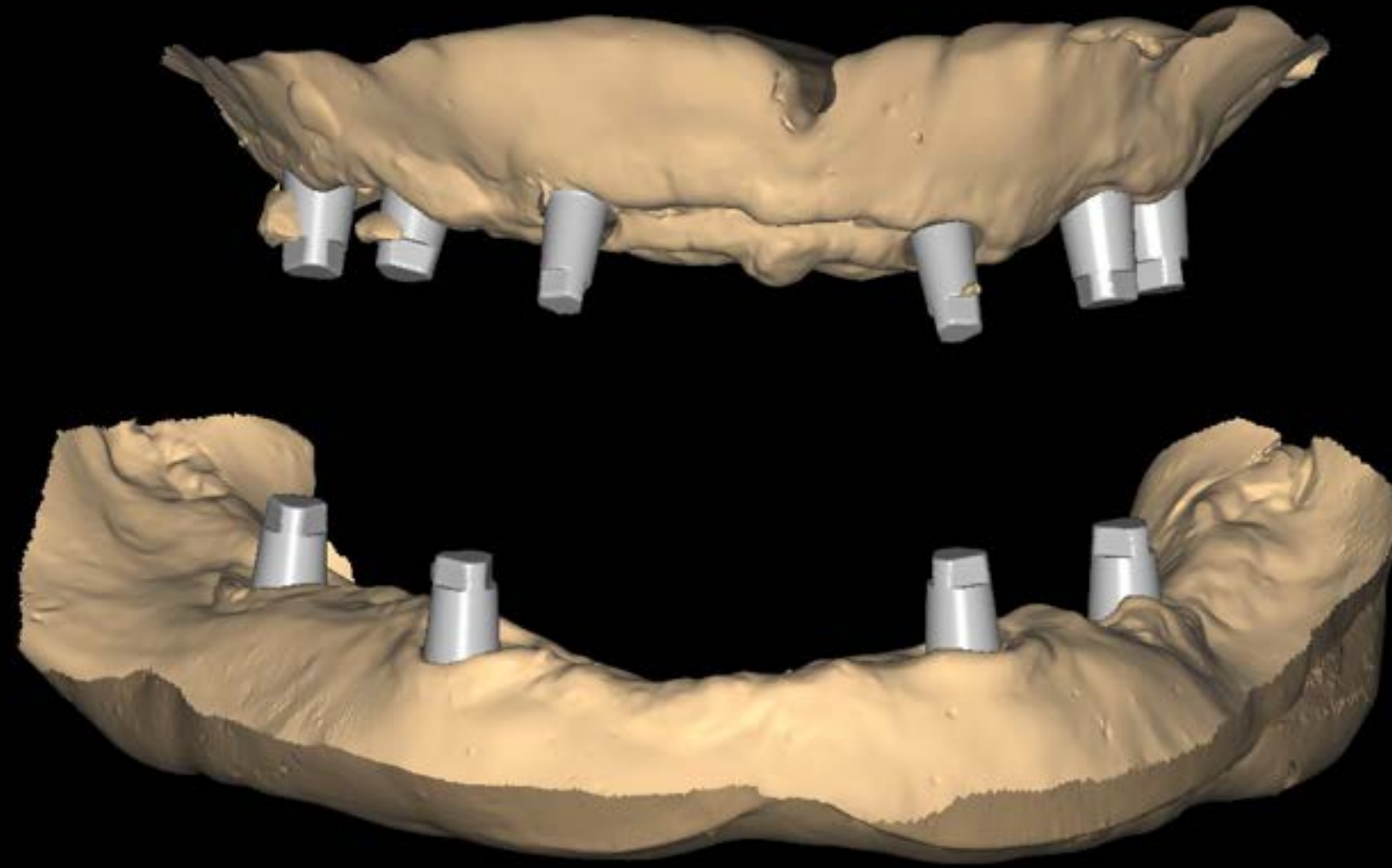
5) Dental CAD : data stitching



CT STL(hard tissue, soft tissue) + Plane + working model


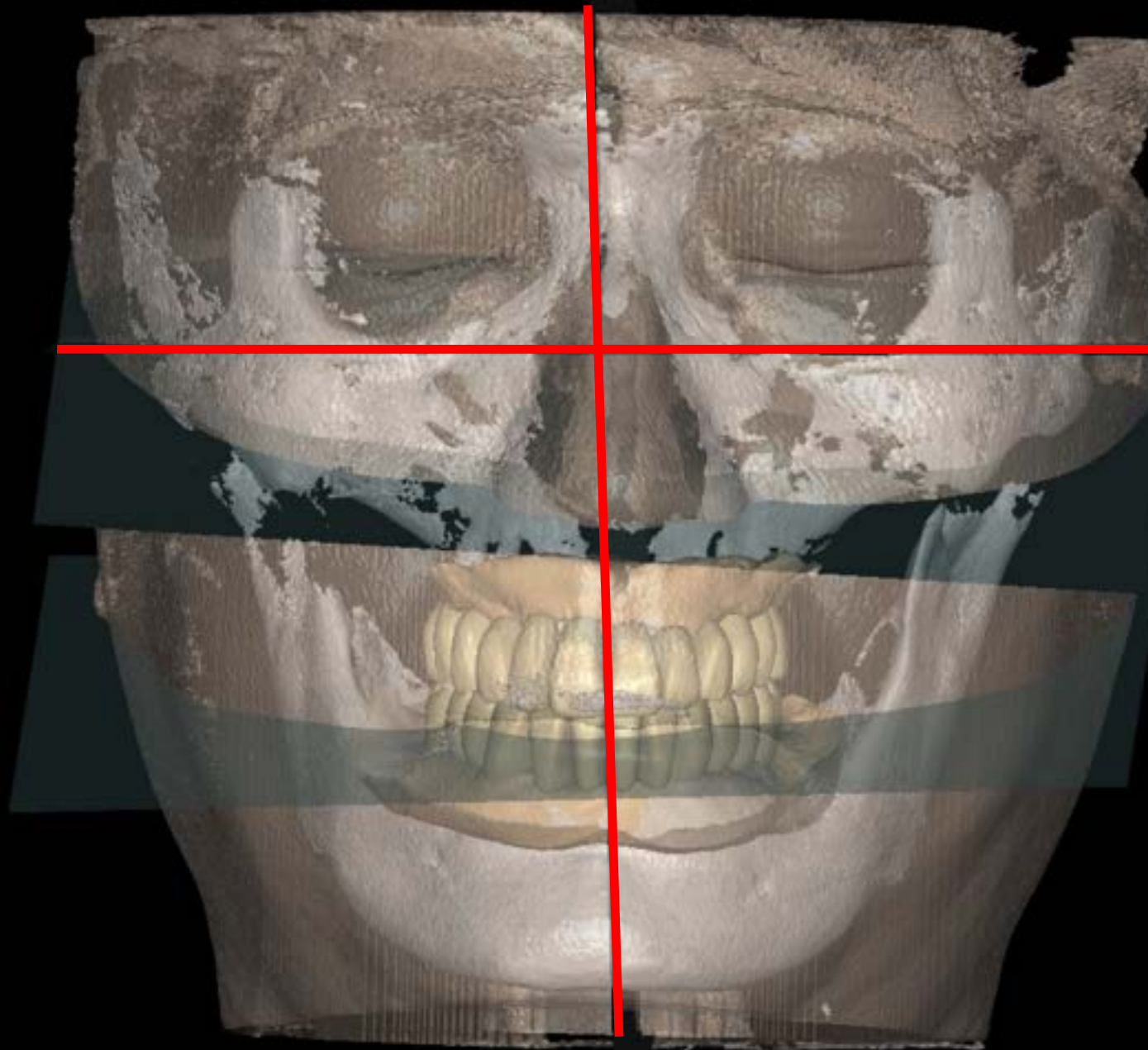

Final impression process with Digital

5) Dental CAD : Crown design

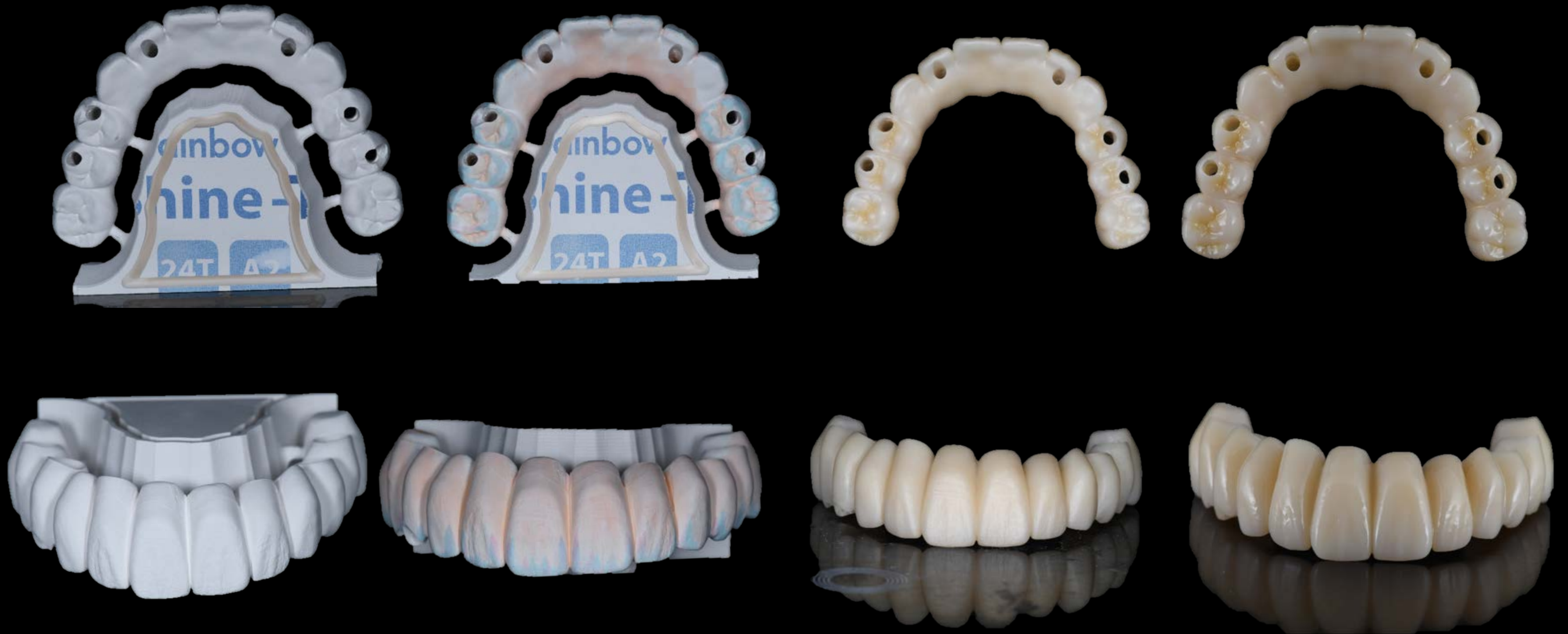

Final impression process with Digital

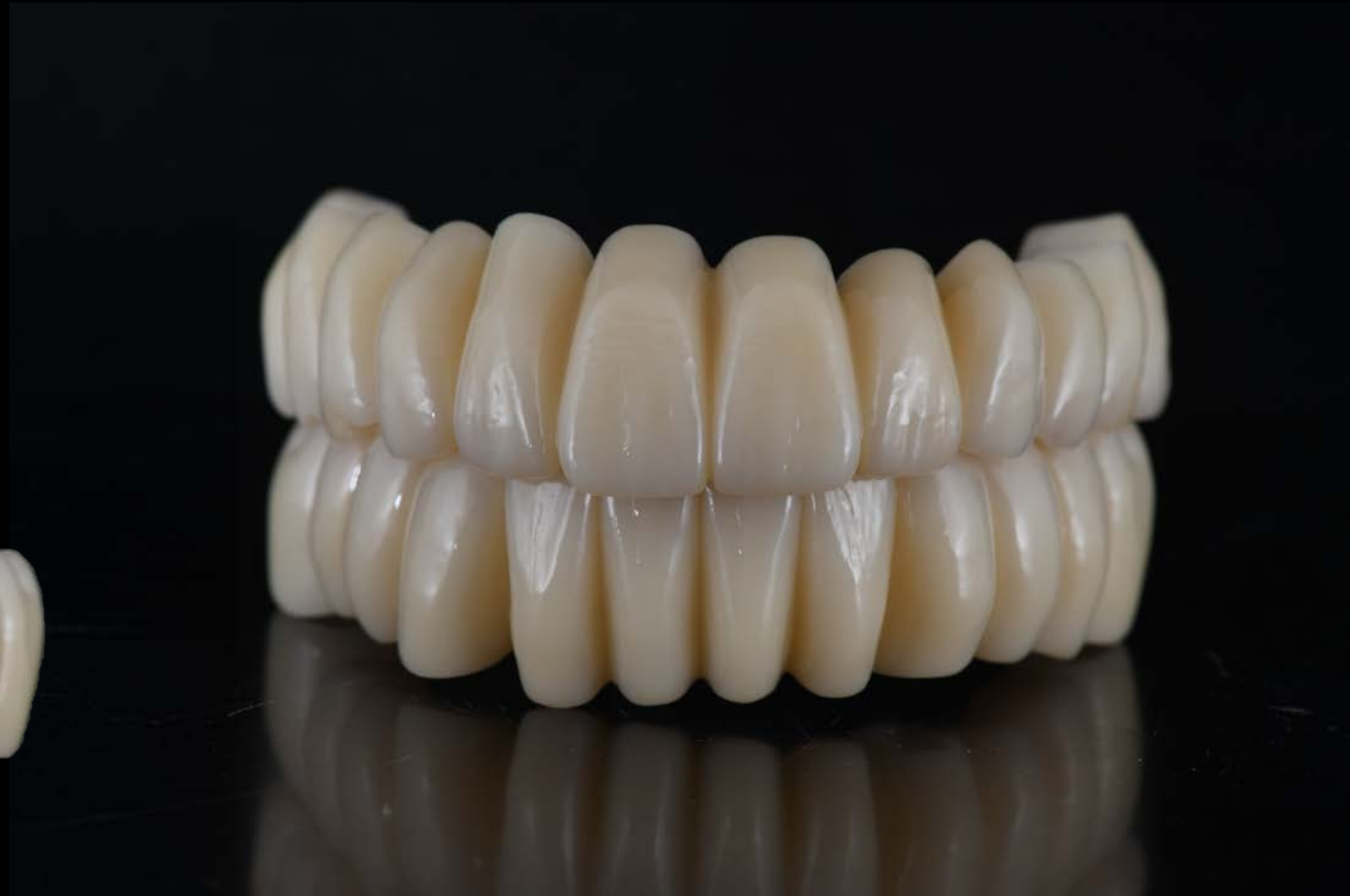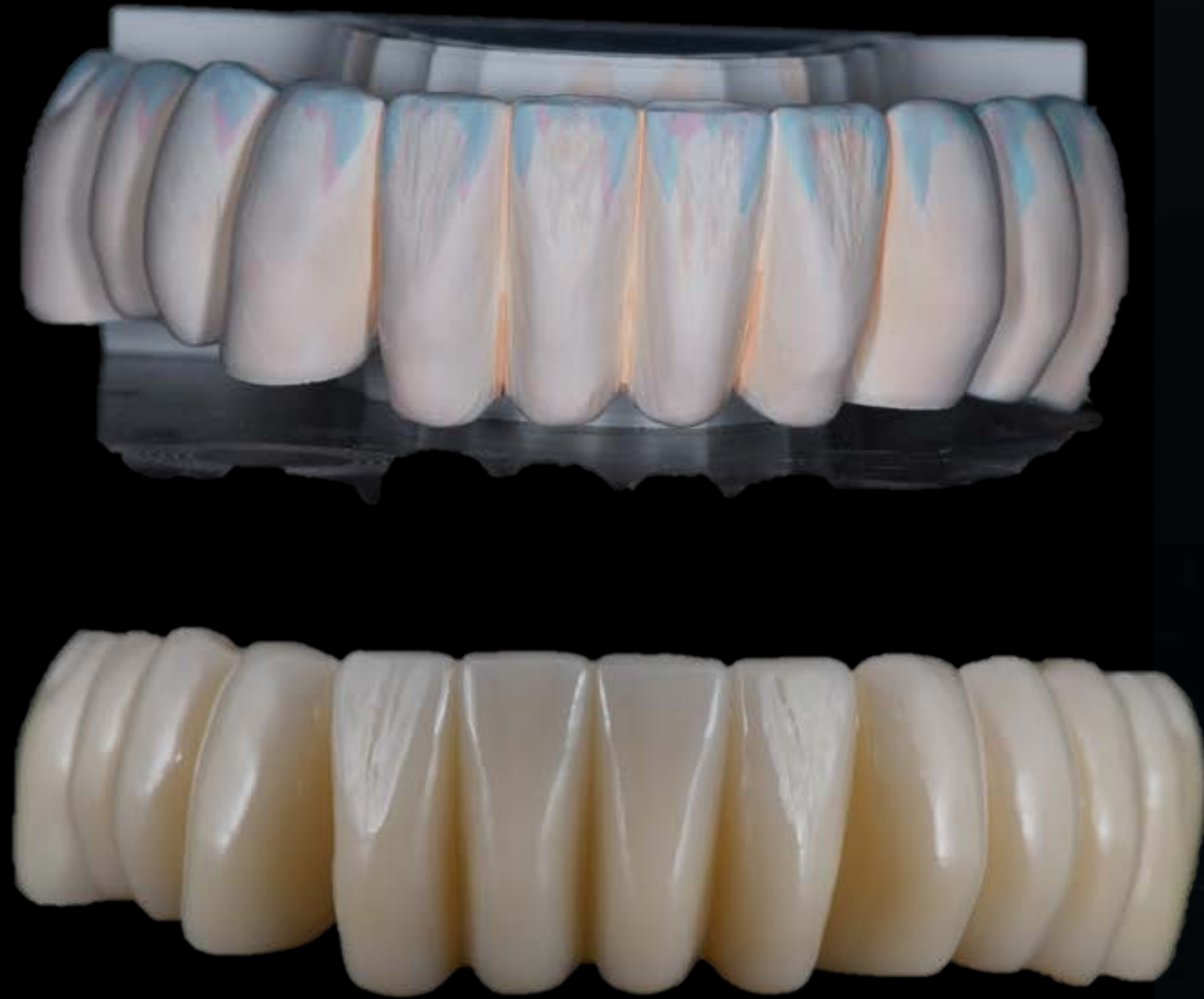5) Dental CAD : Crown design



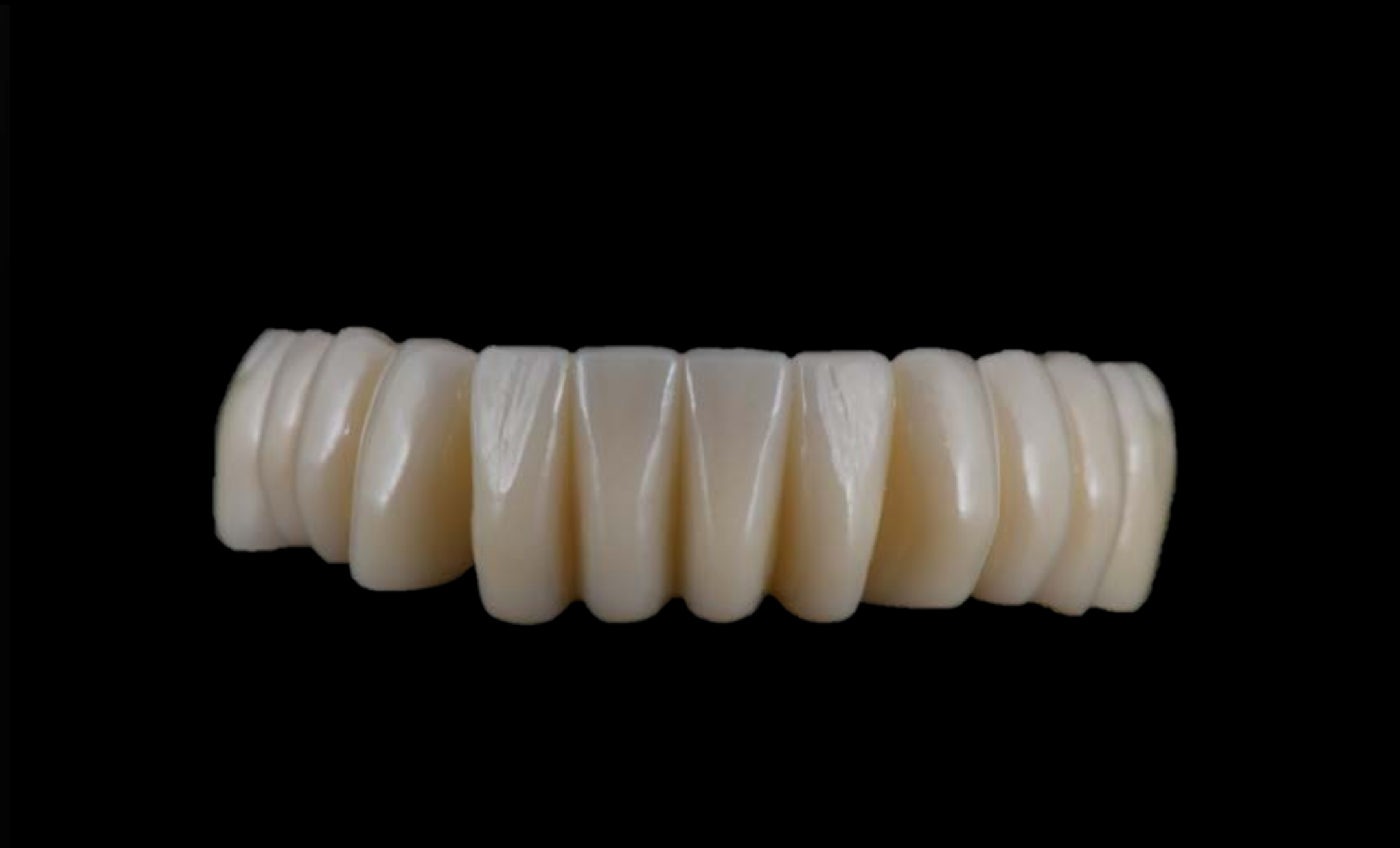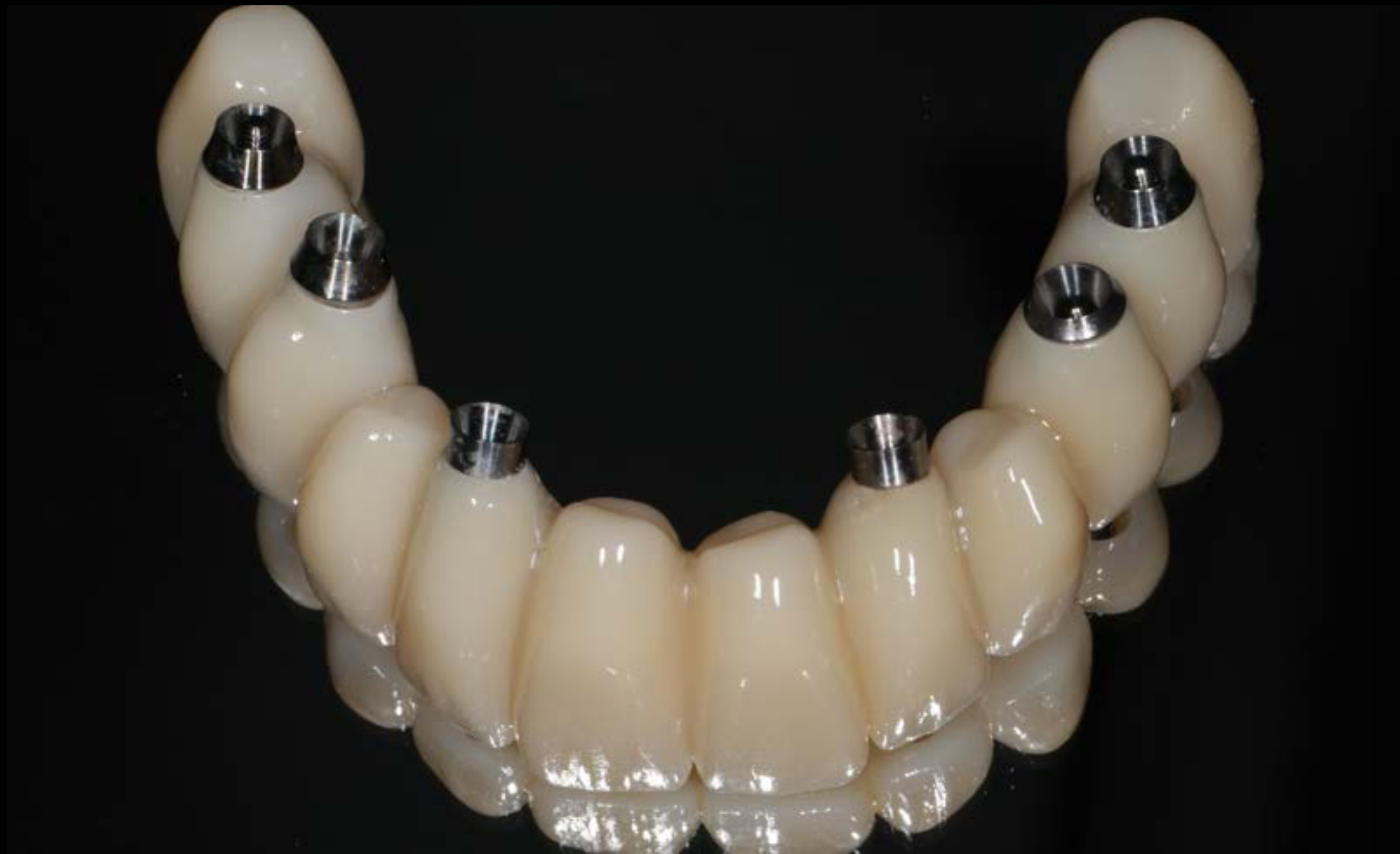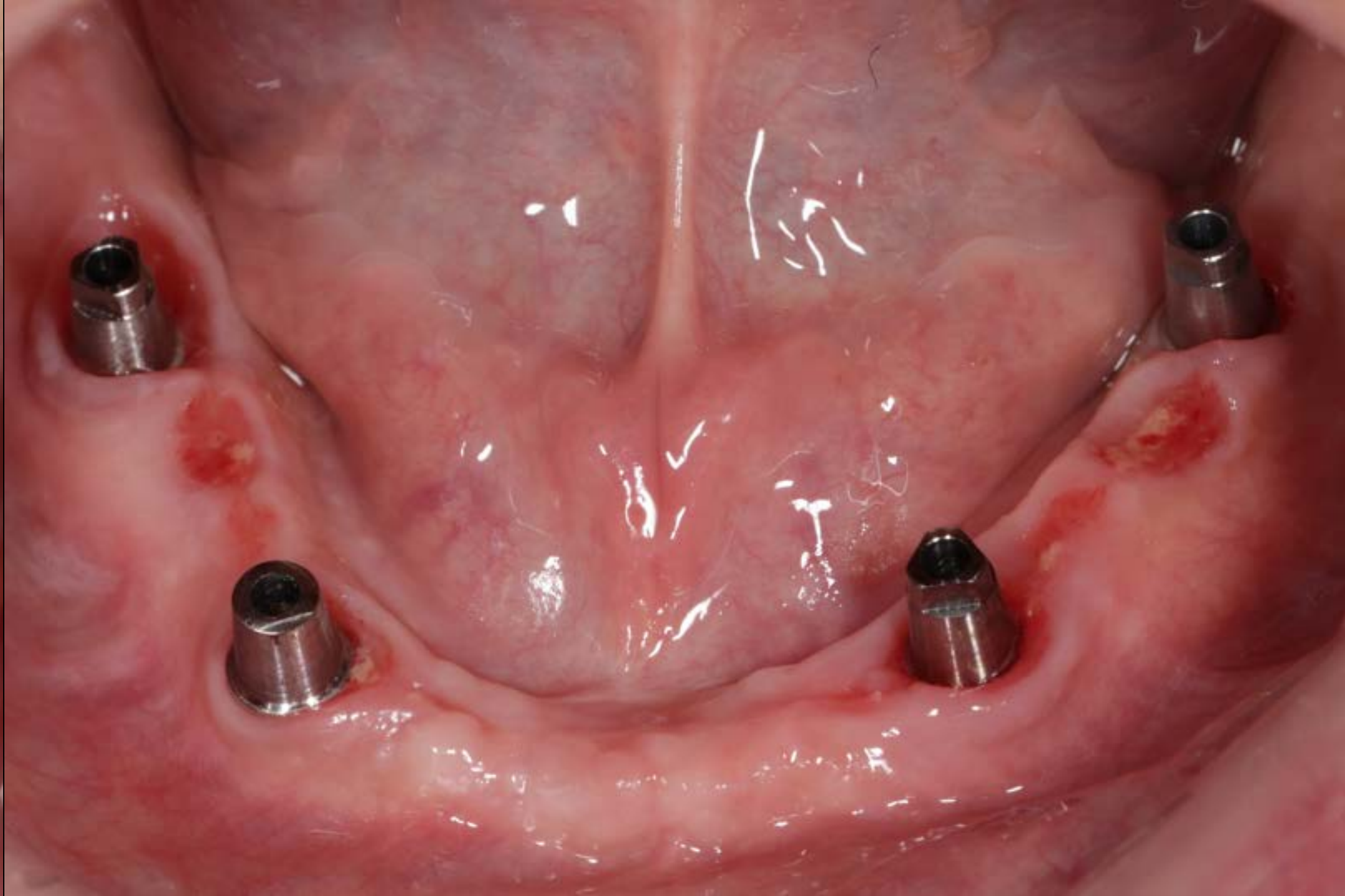
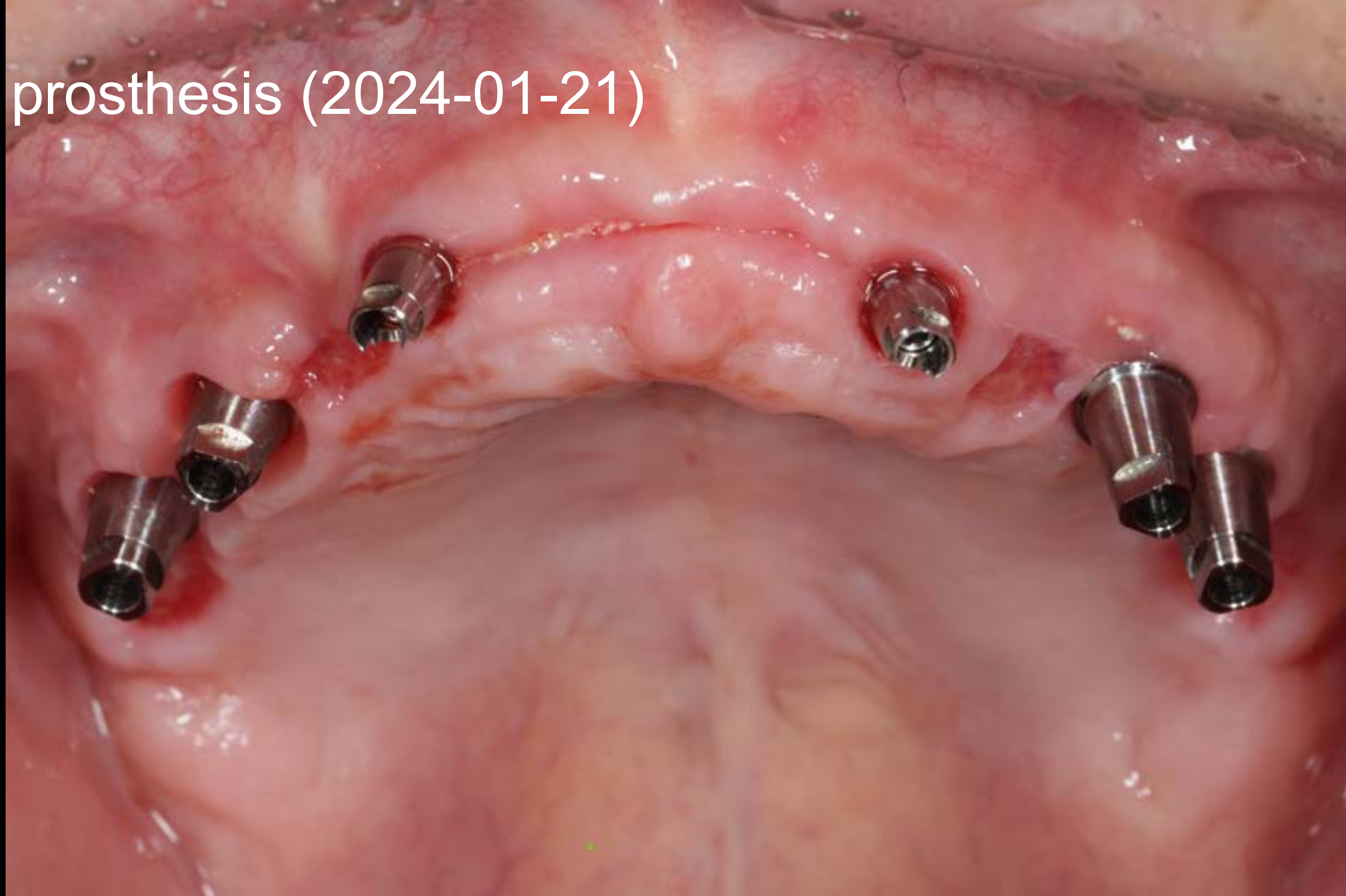Milling / coloring / Sintering / Glazing



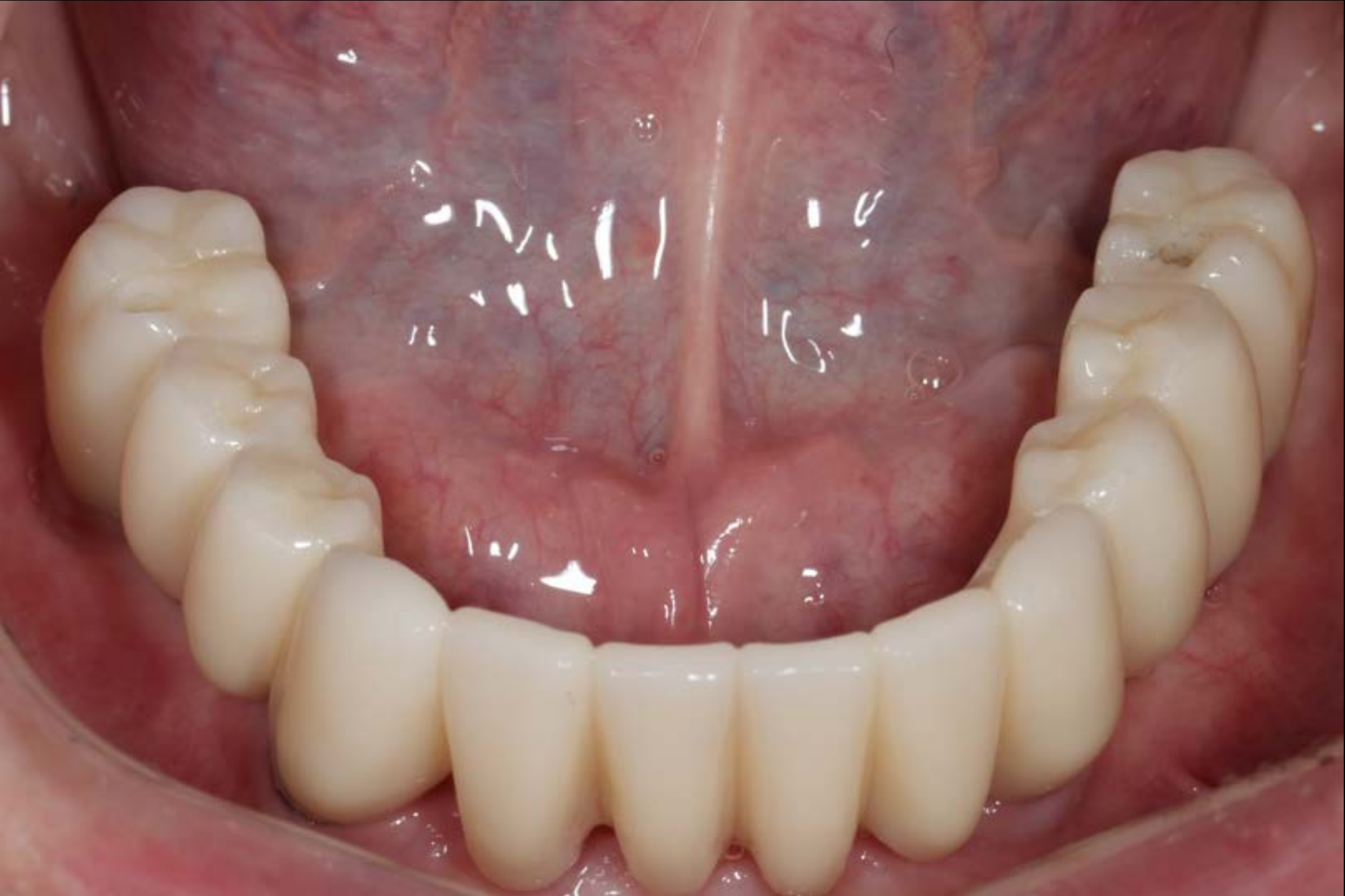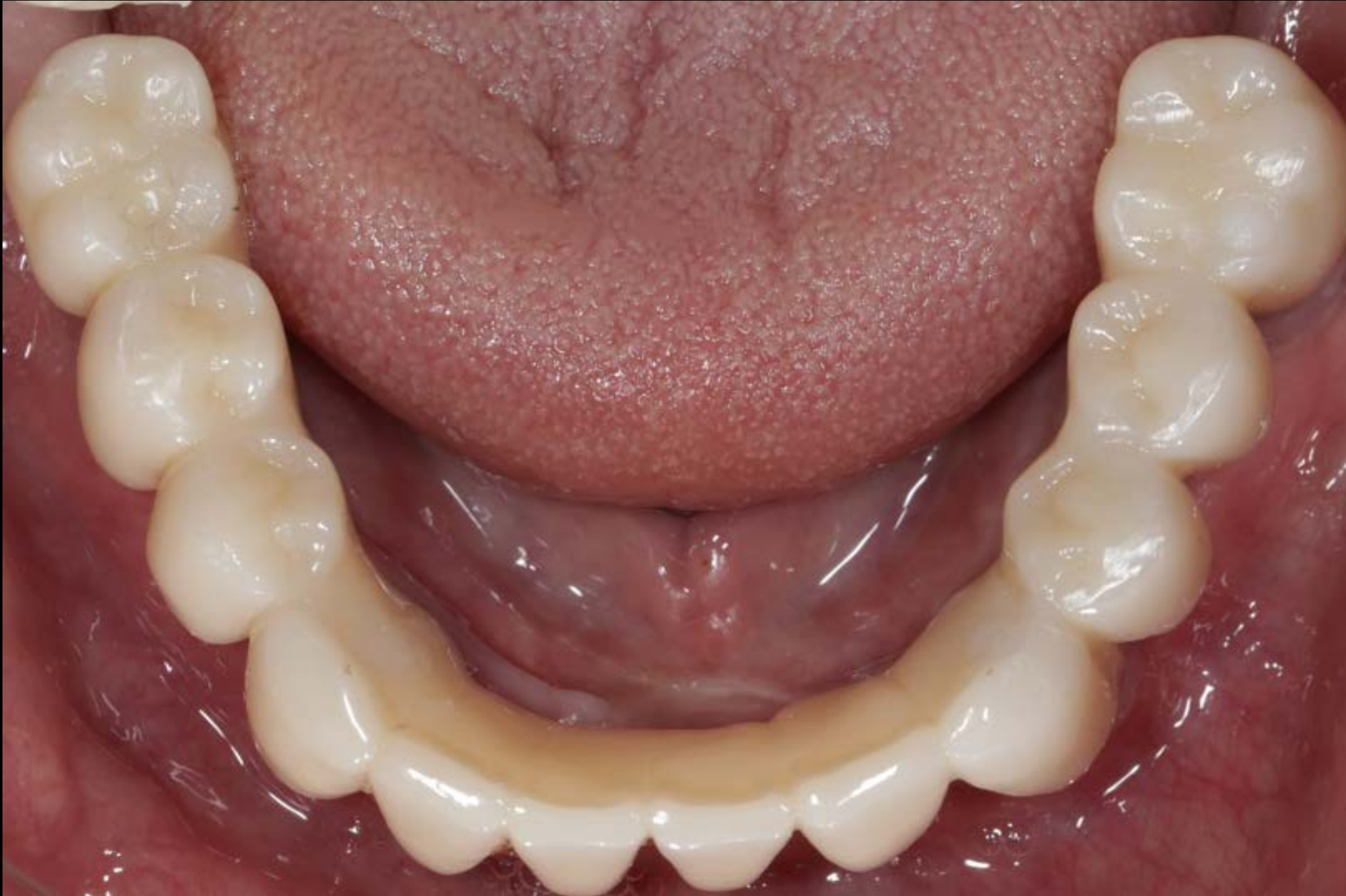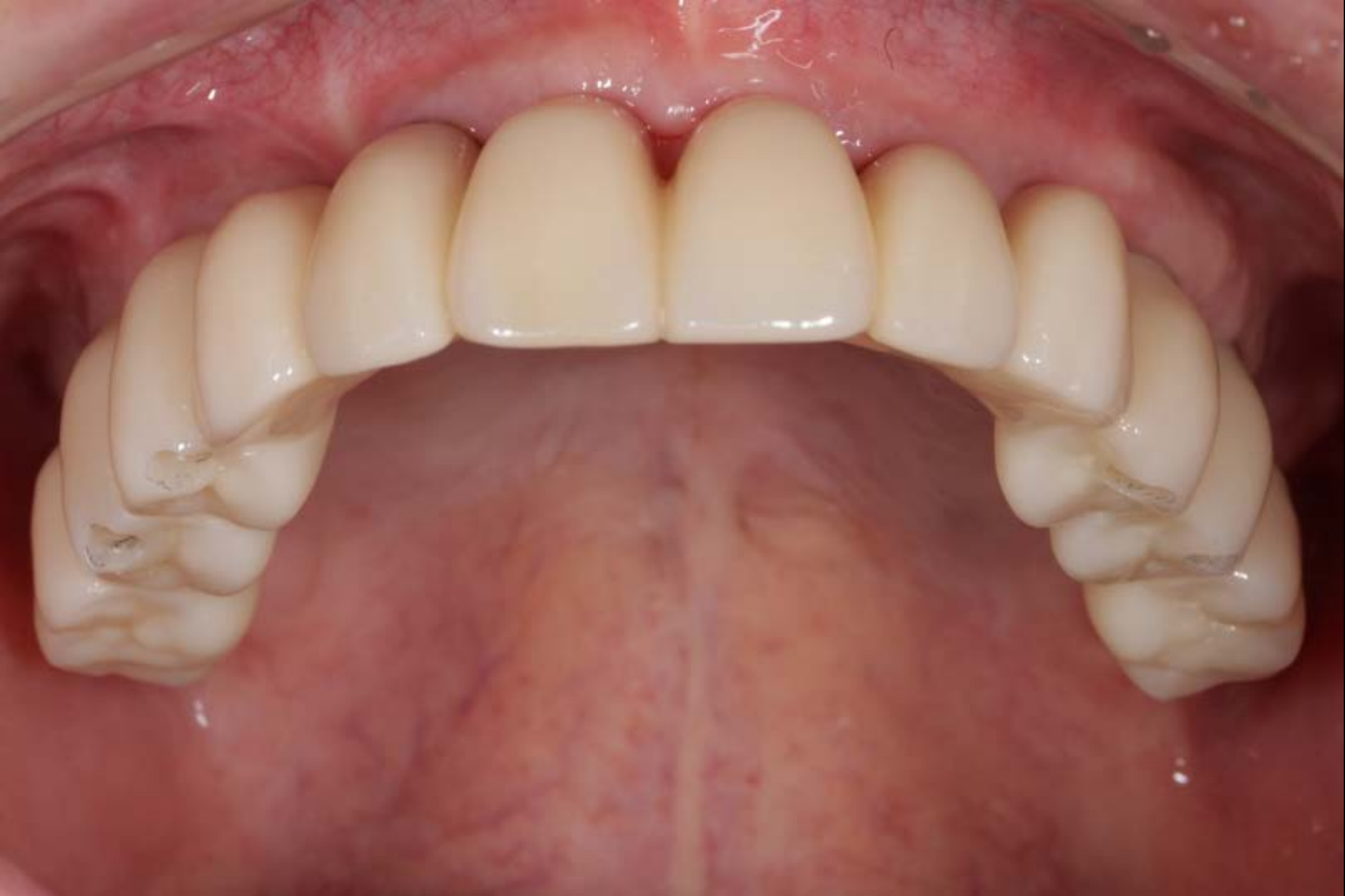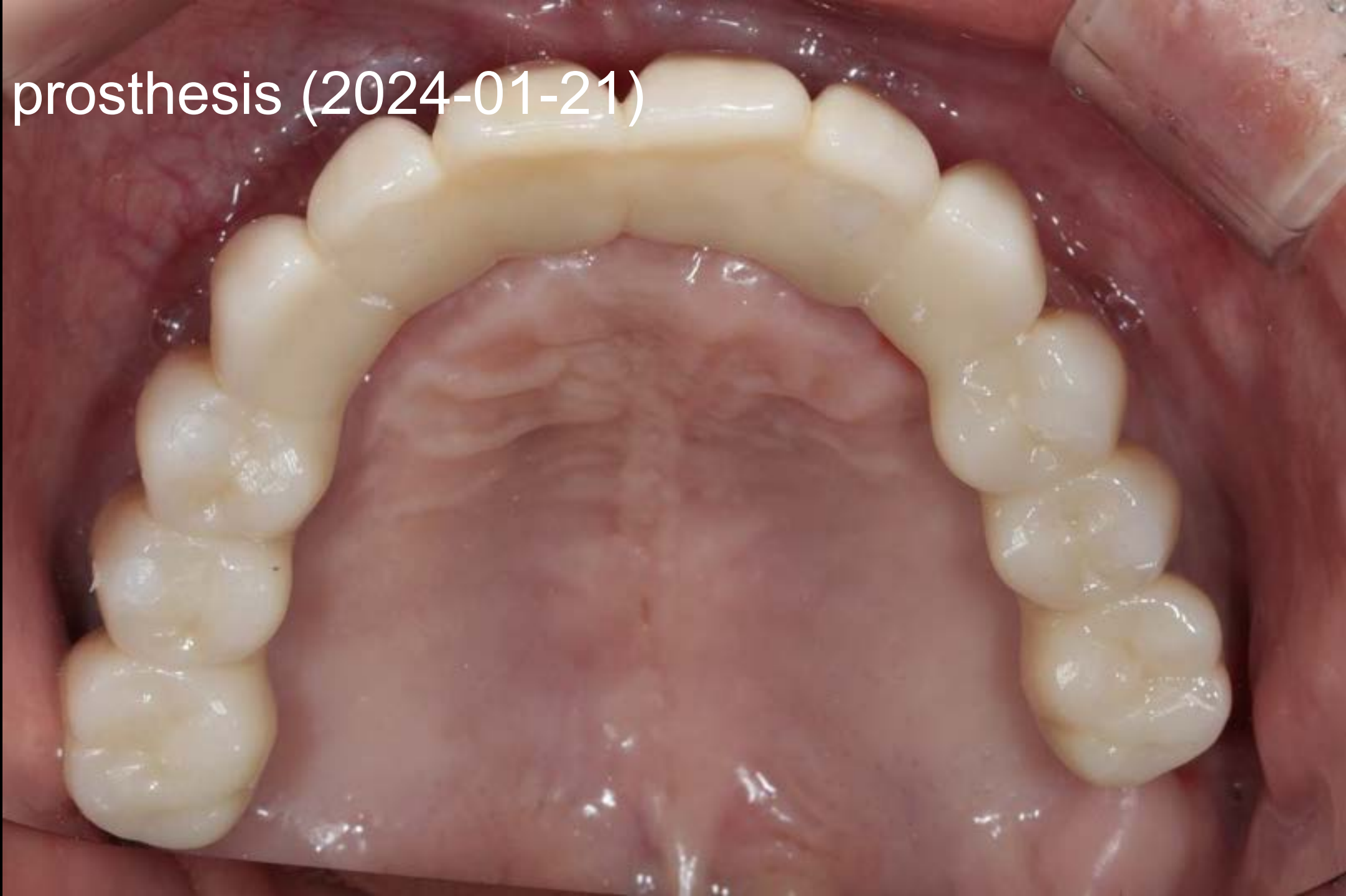Milling / coloring / Sintering / Glazing



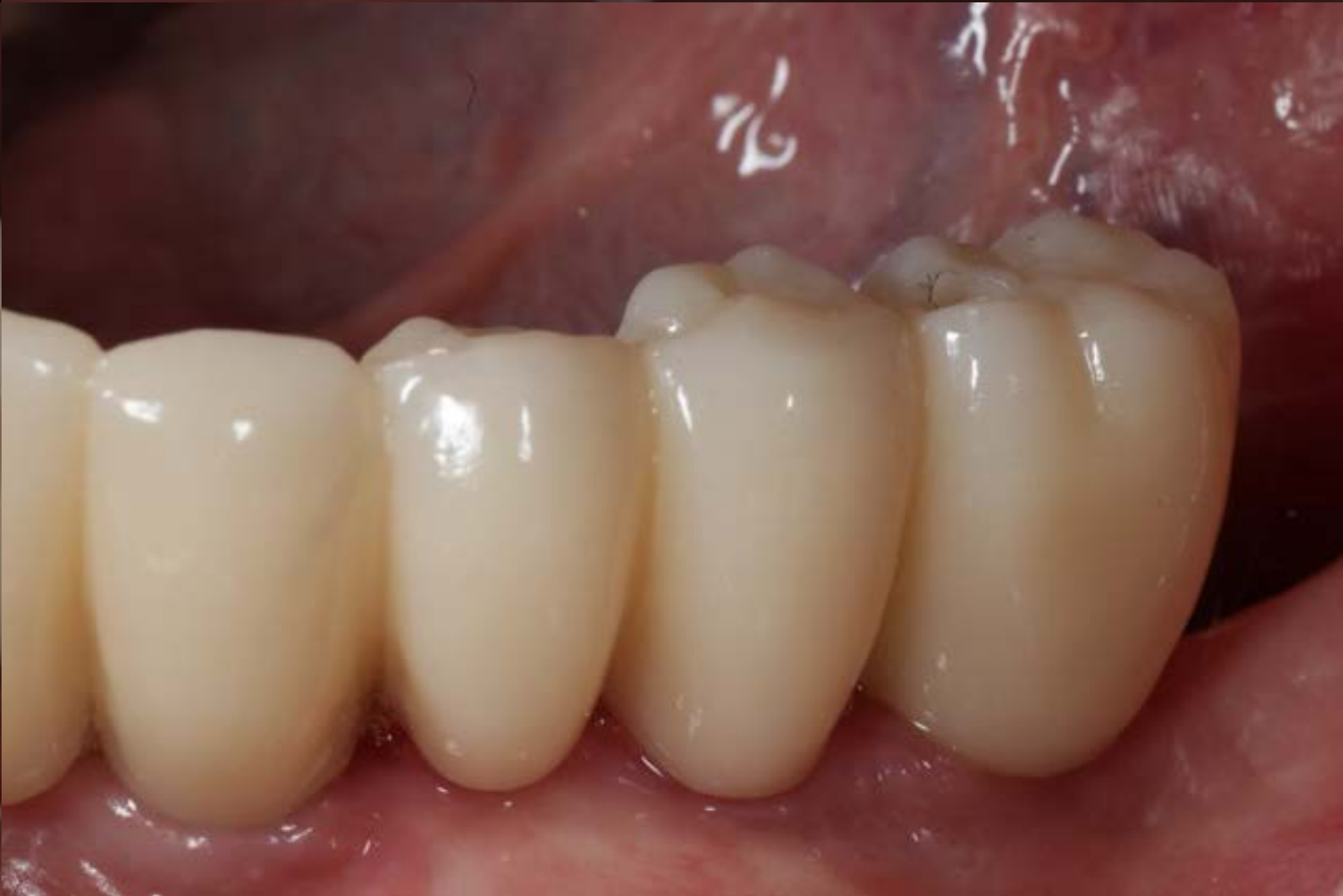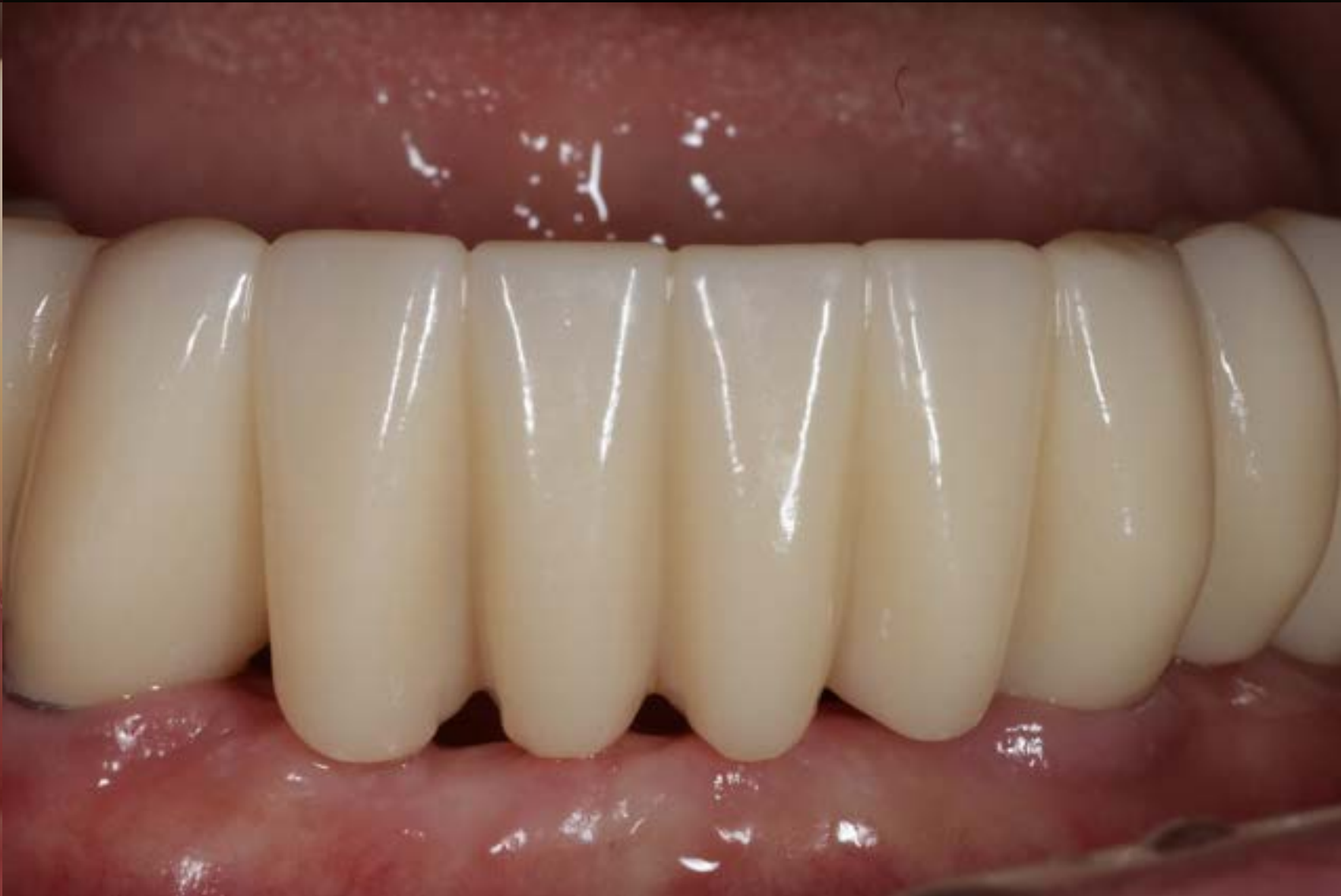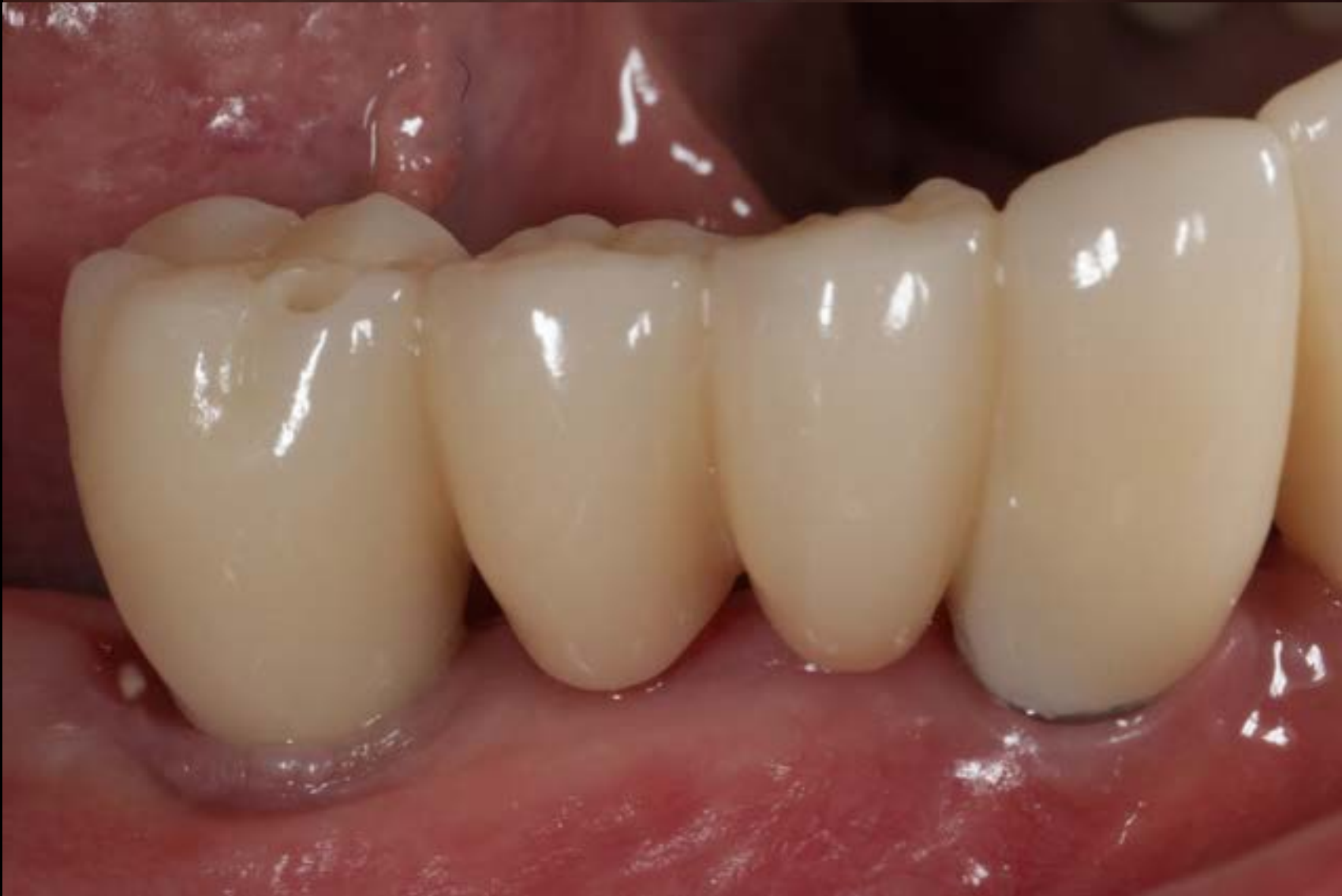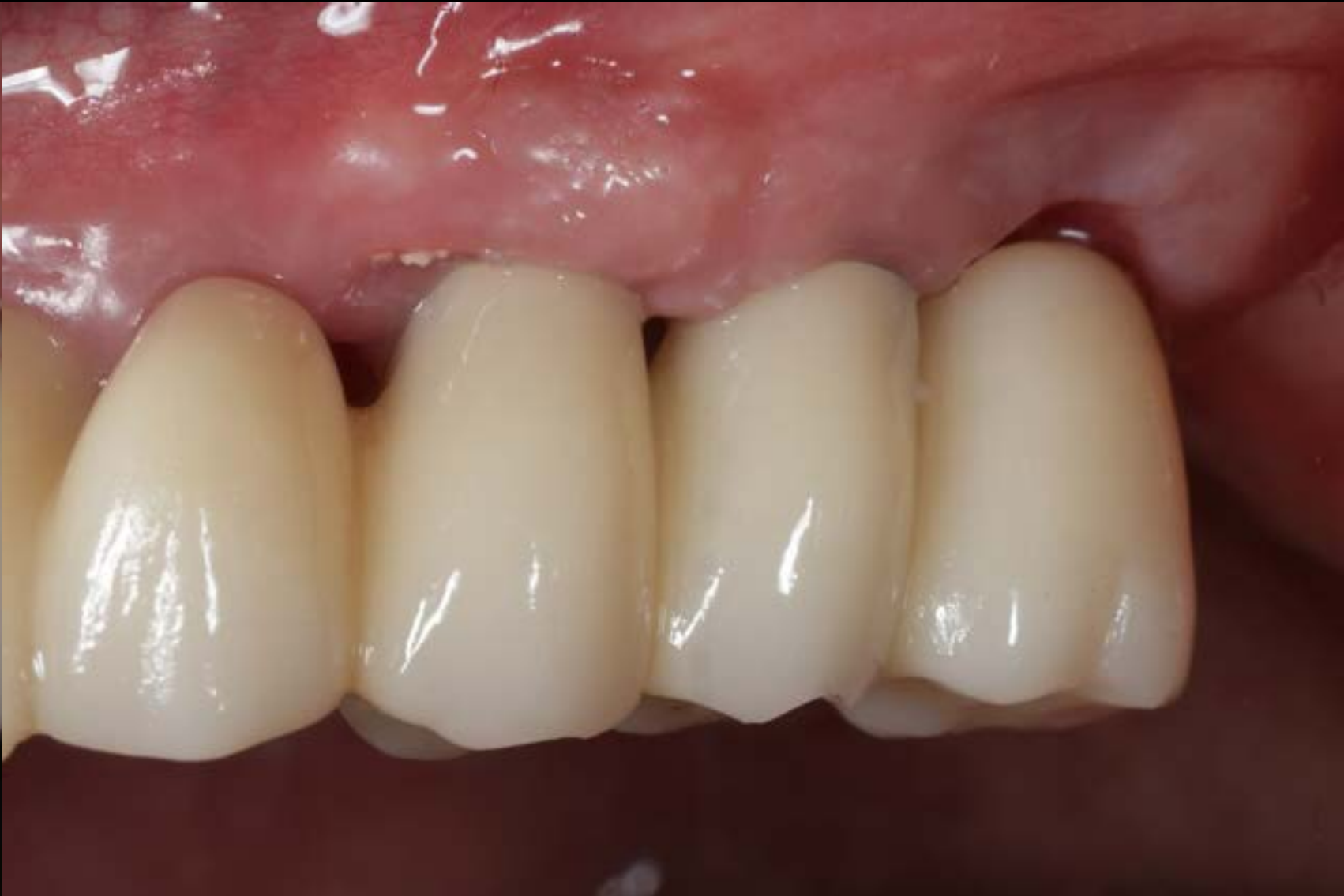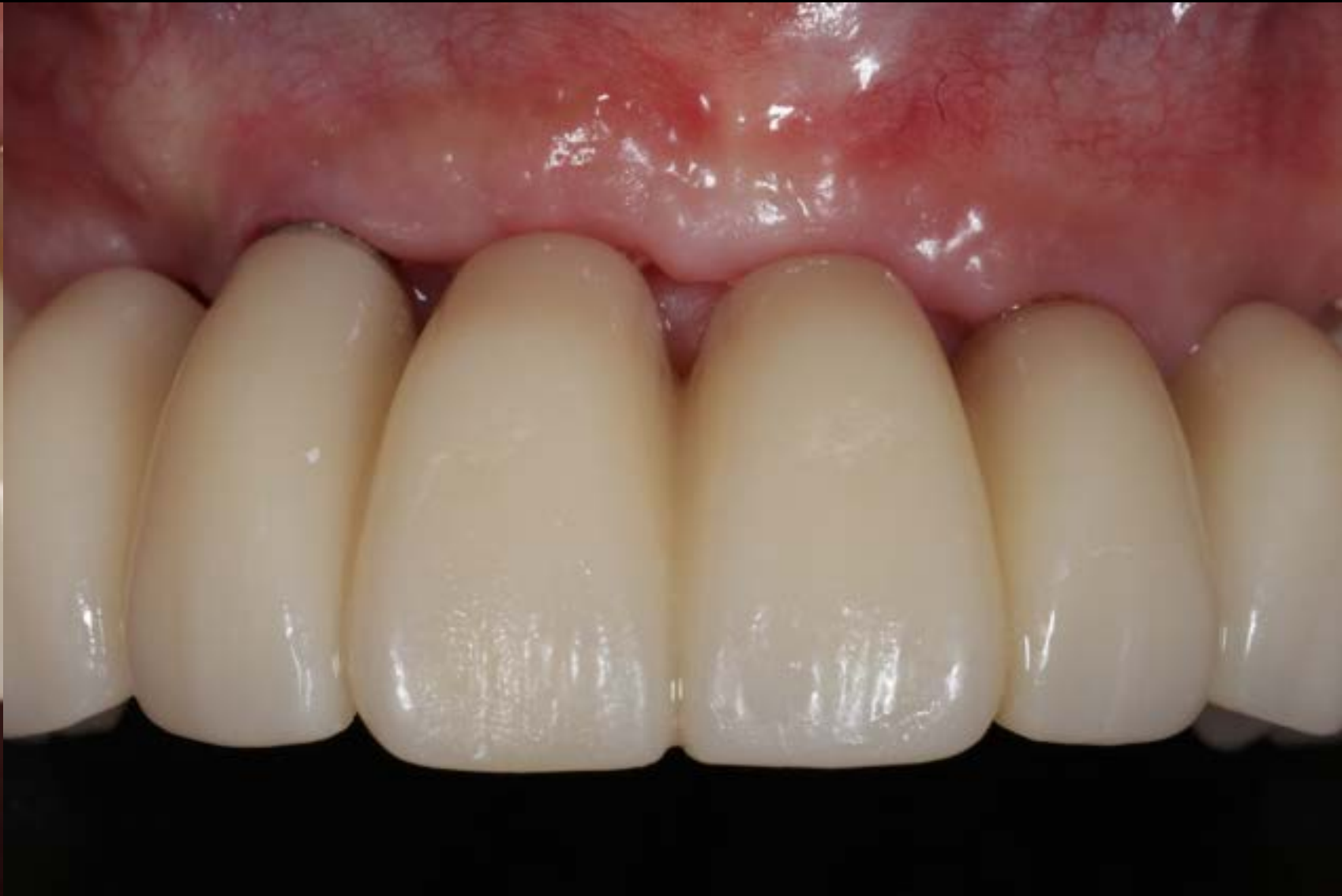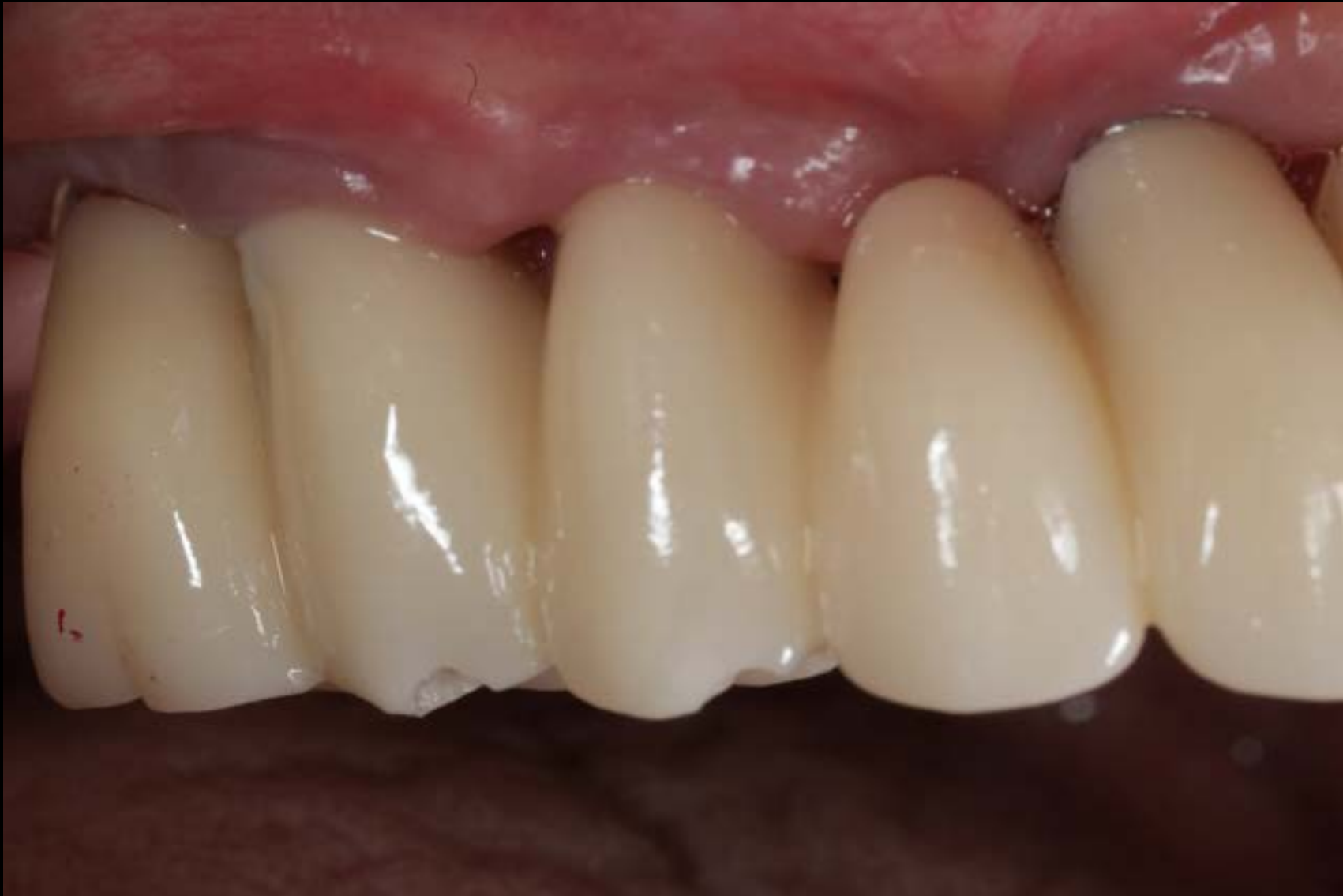Final prosthesis (2024-01-21)



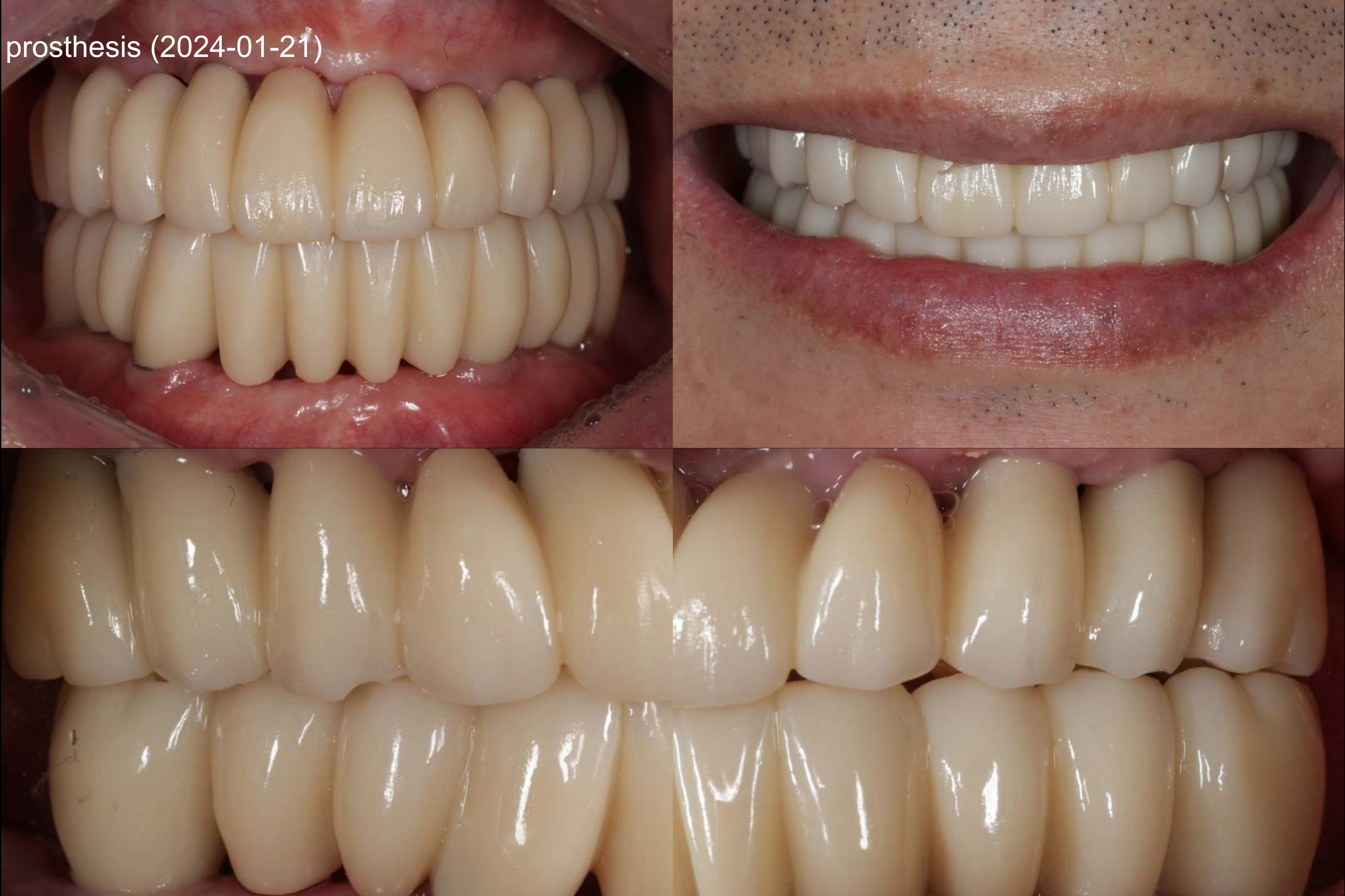Final prosthesis (2024-01-21)

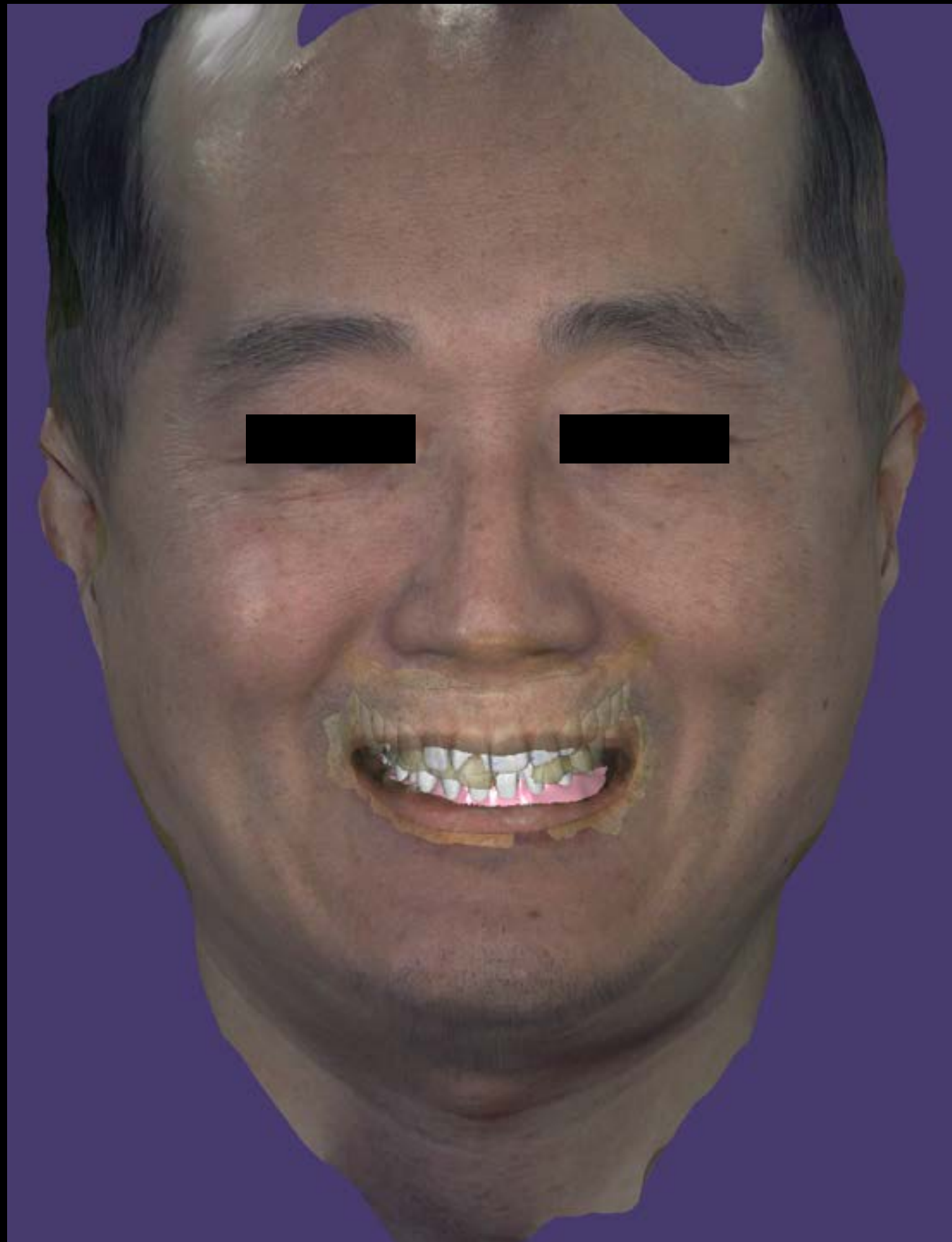


Final prosthesis (2024-01-21)

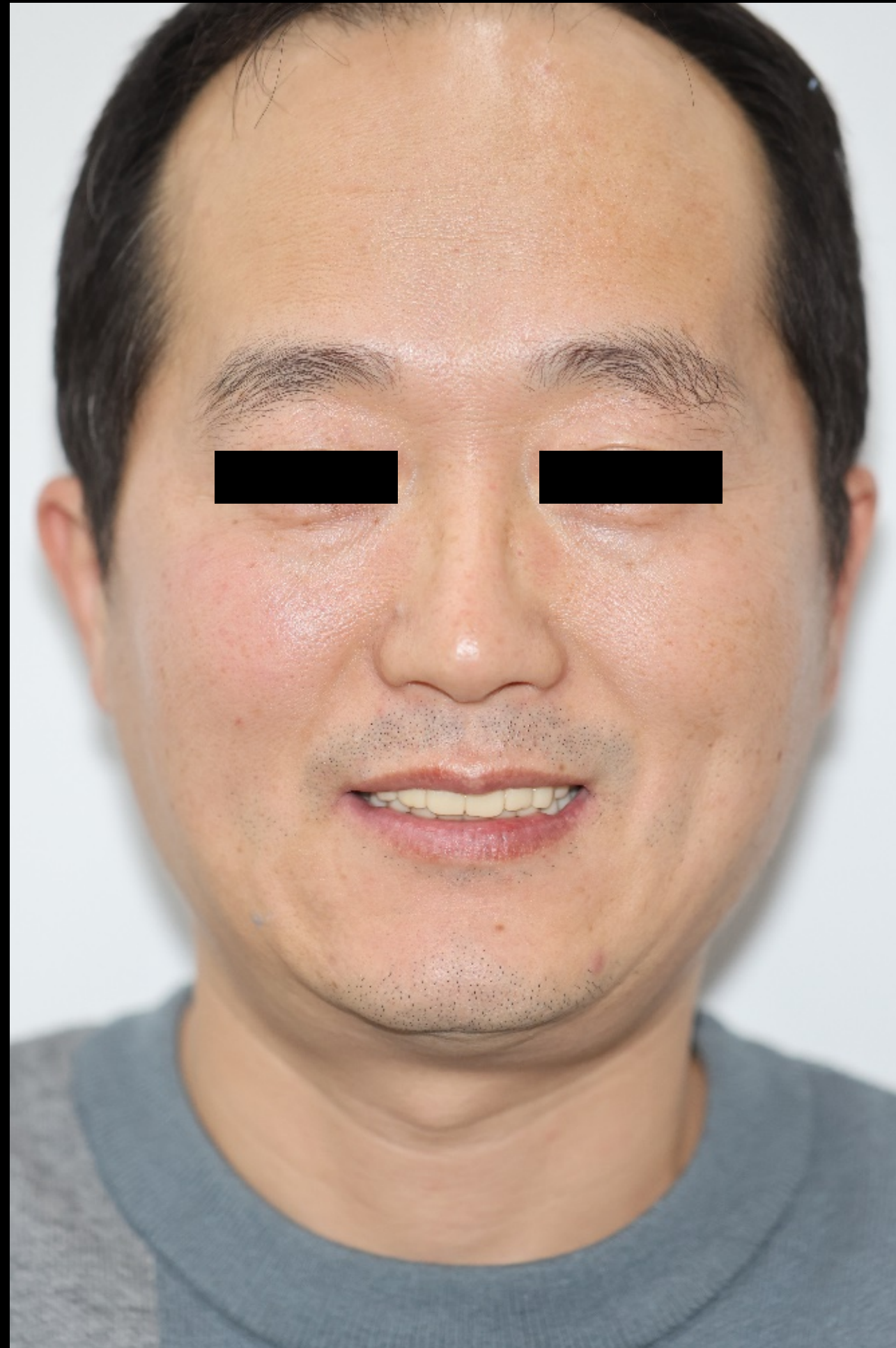


Final prosthesis (2024-01-21)

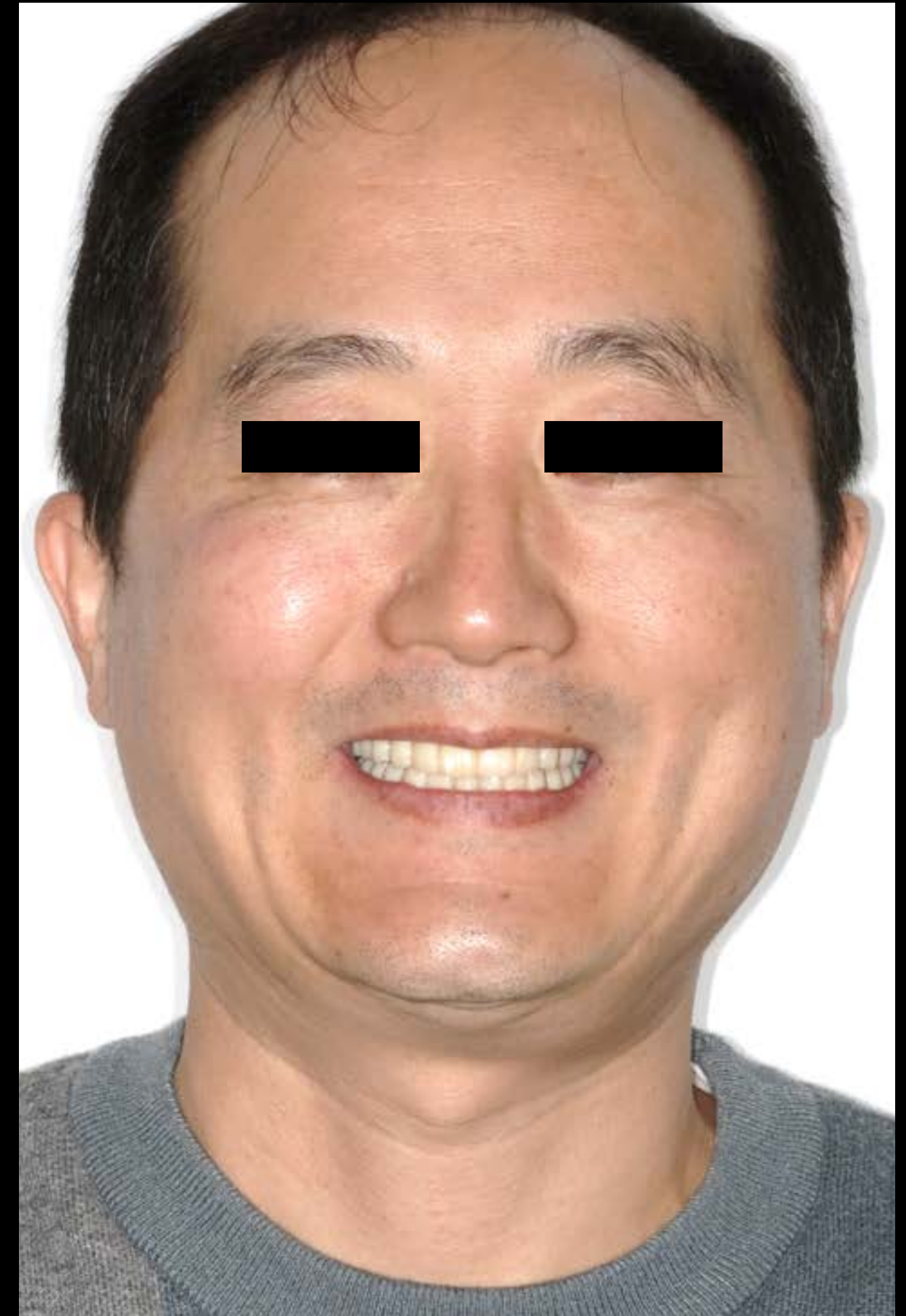




Initial State

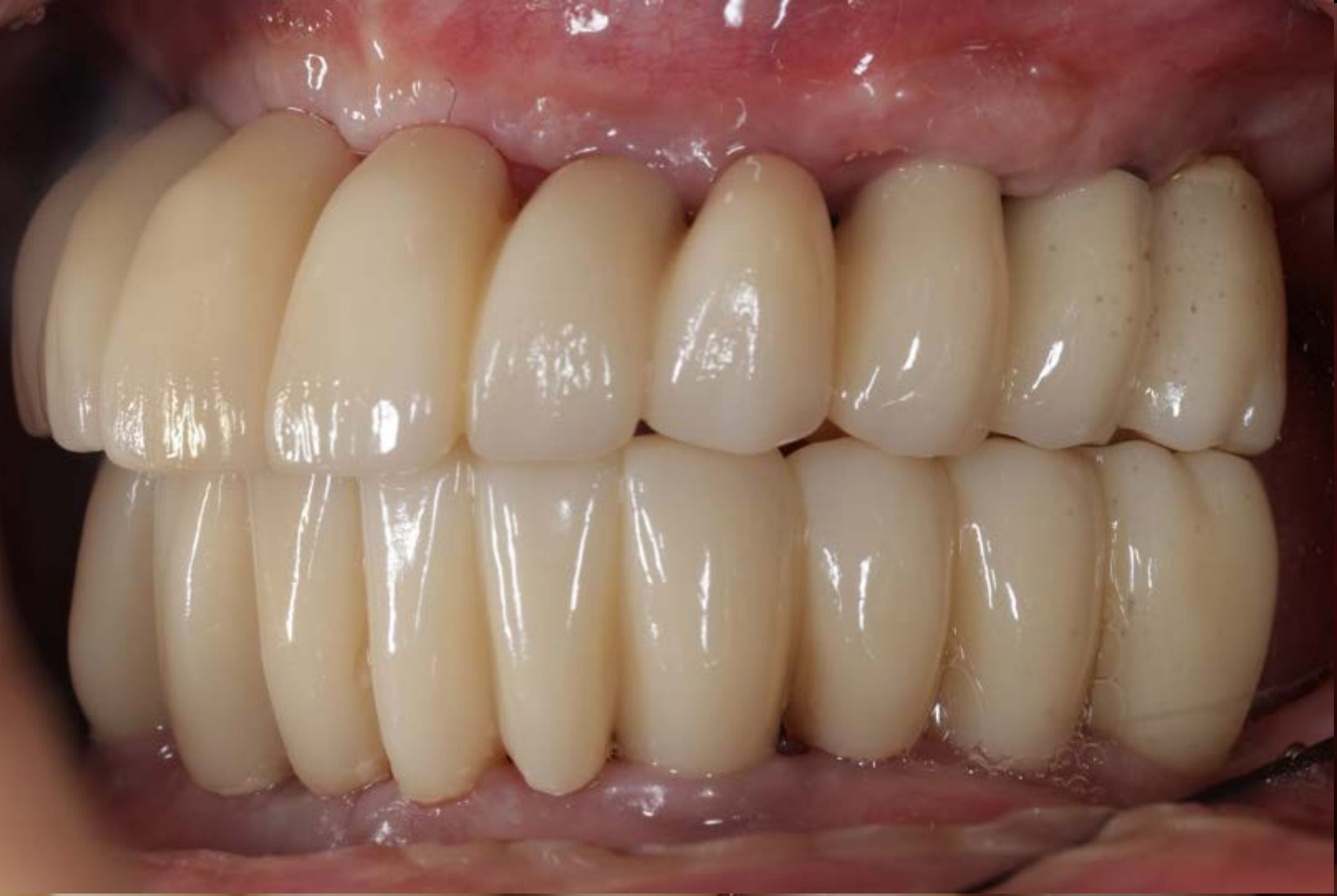
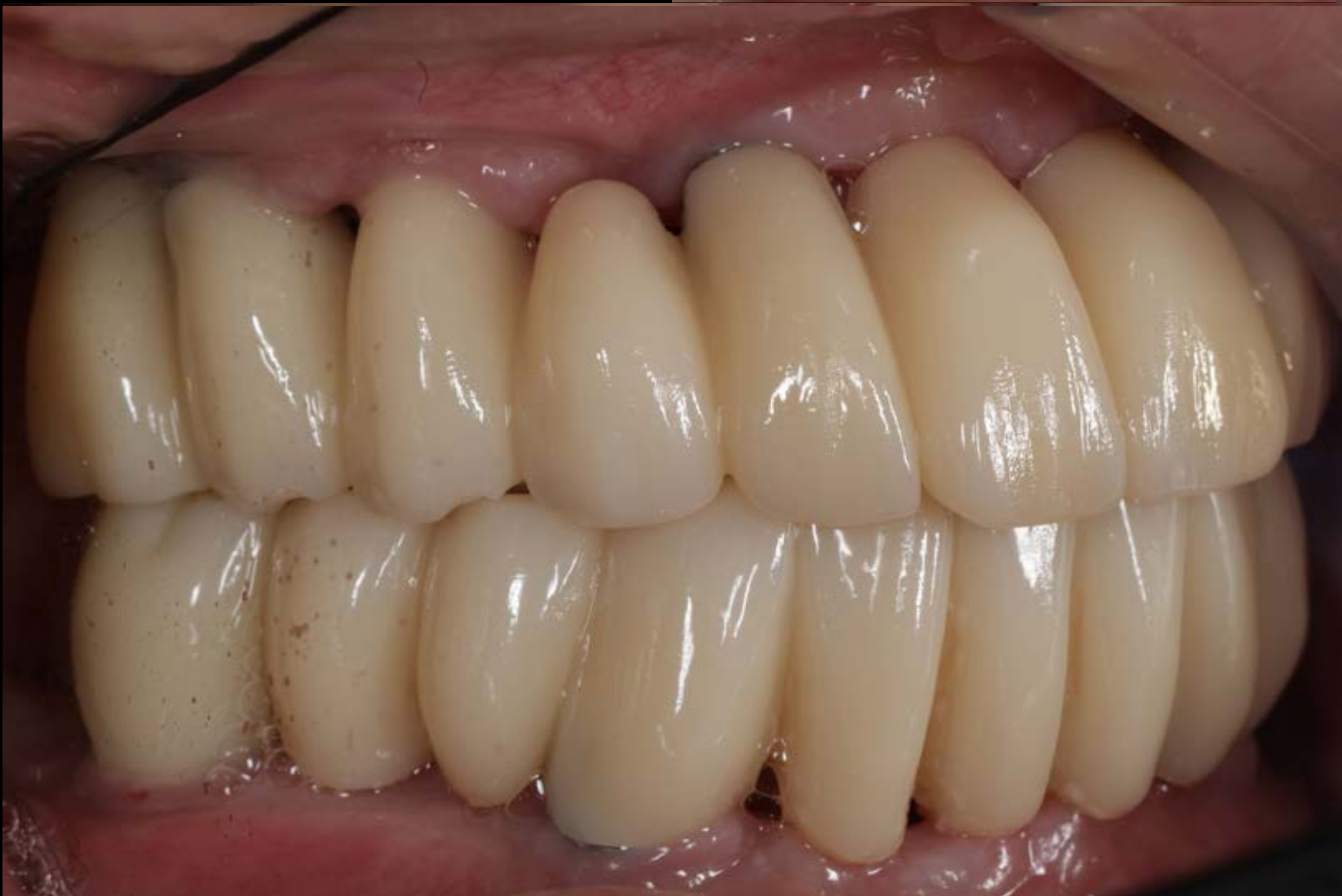
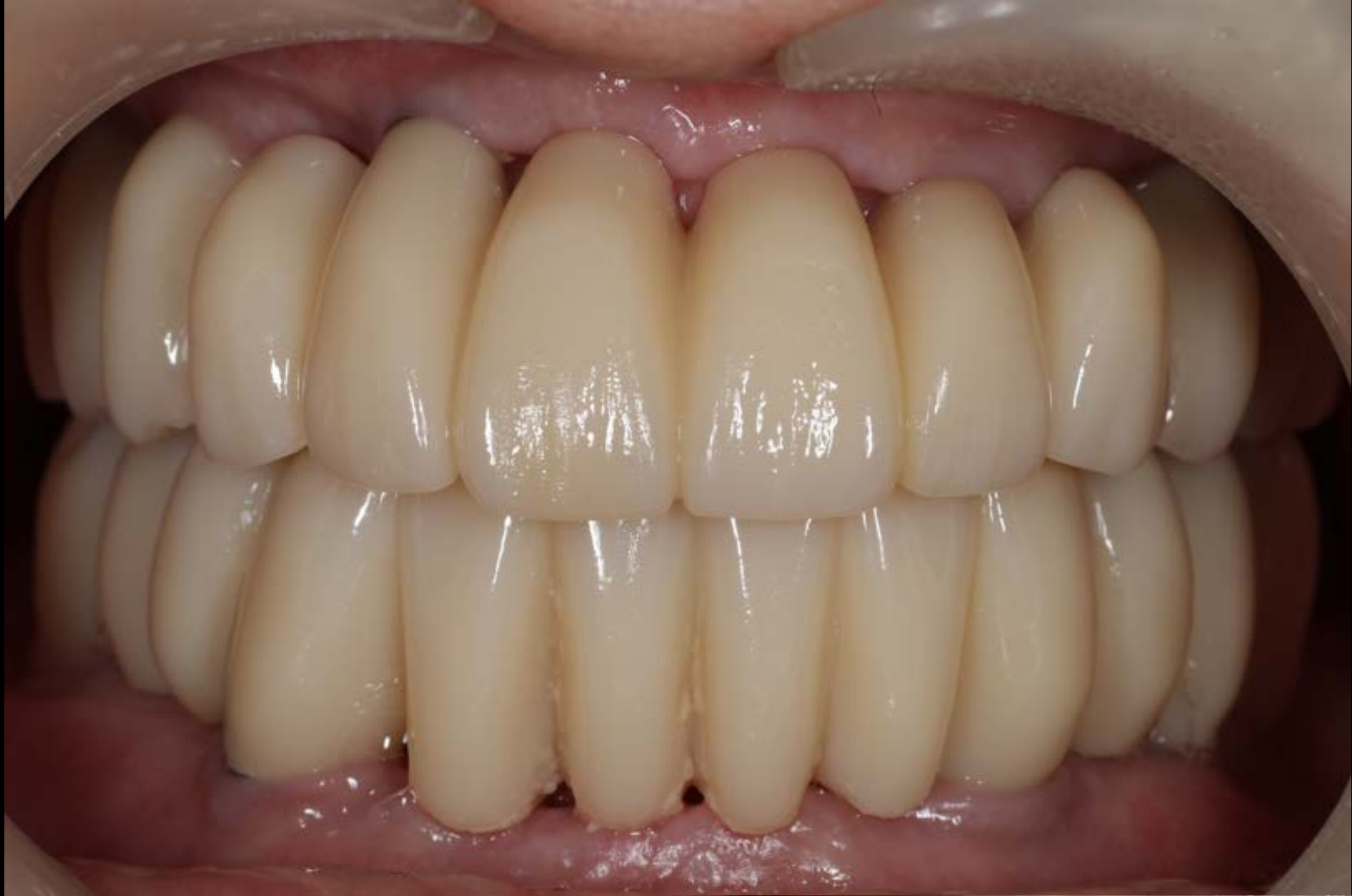Provisional restoration

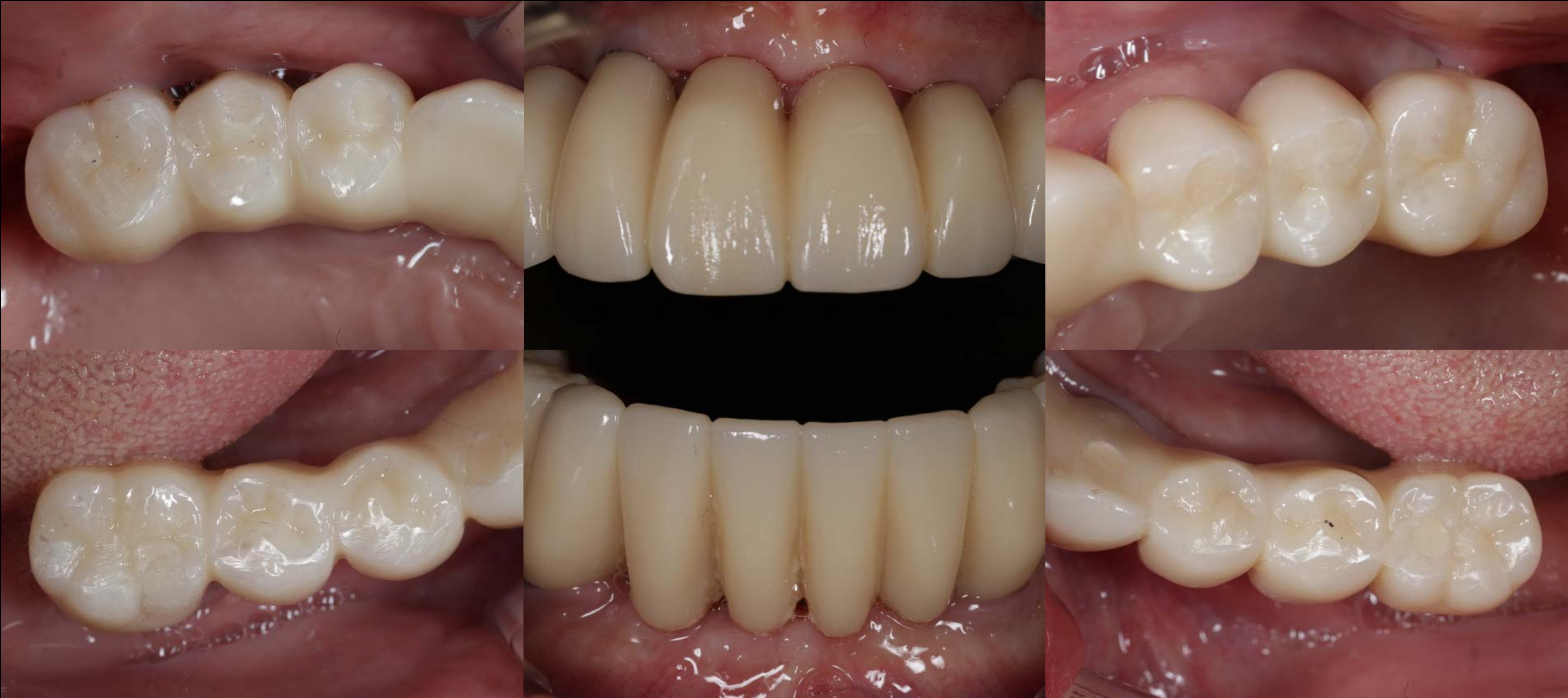

Final prosthesis

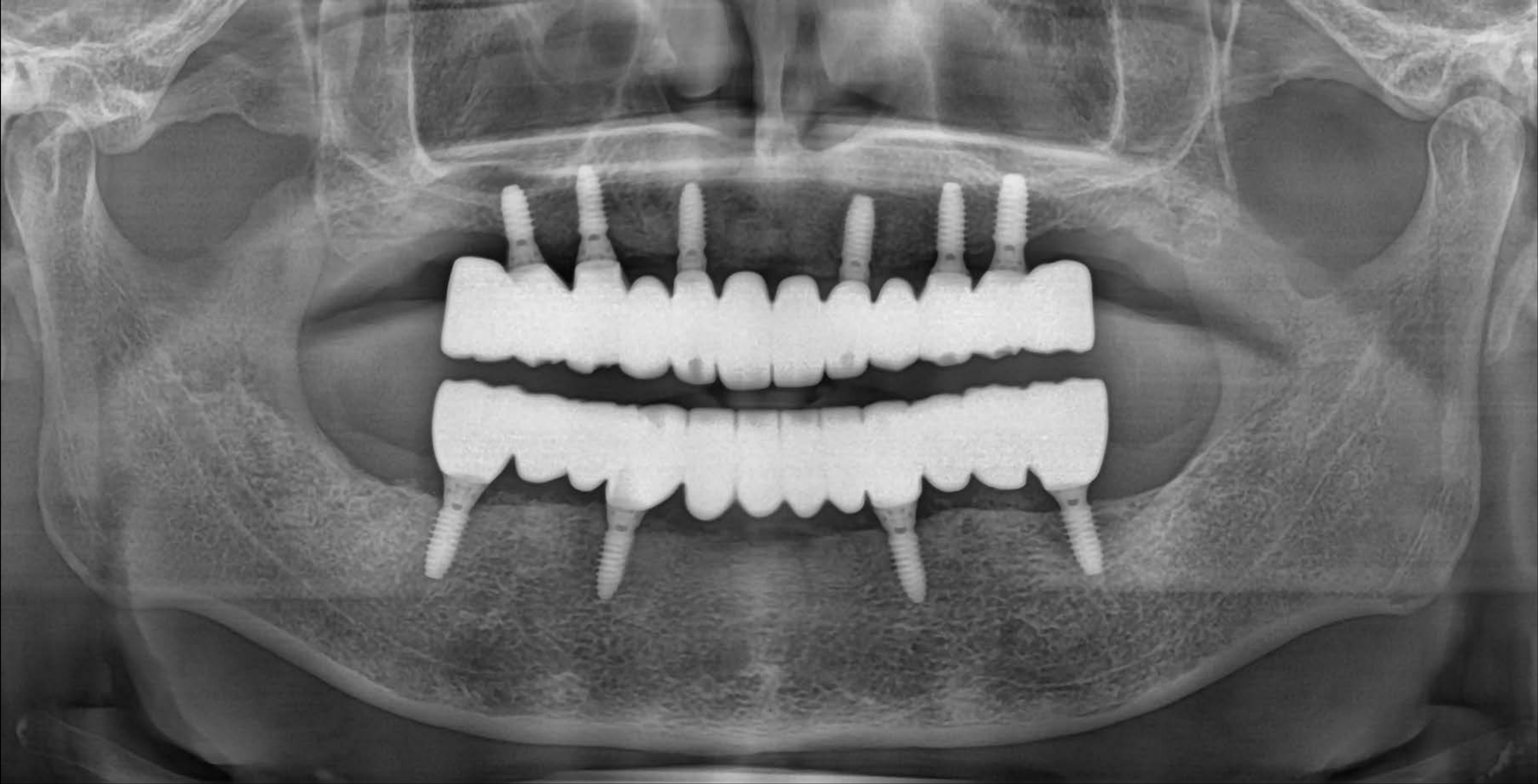Bite check (2024-02-20)



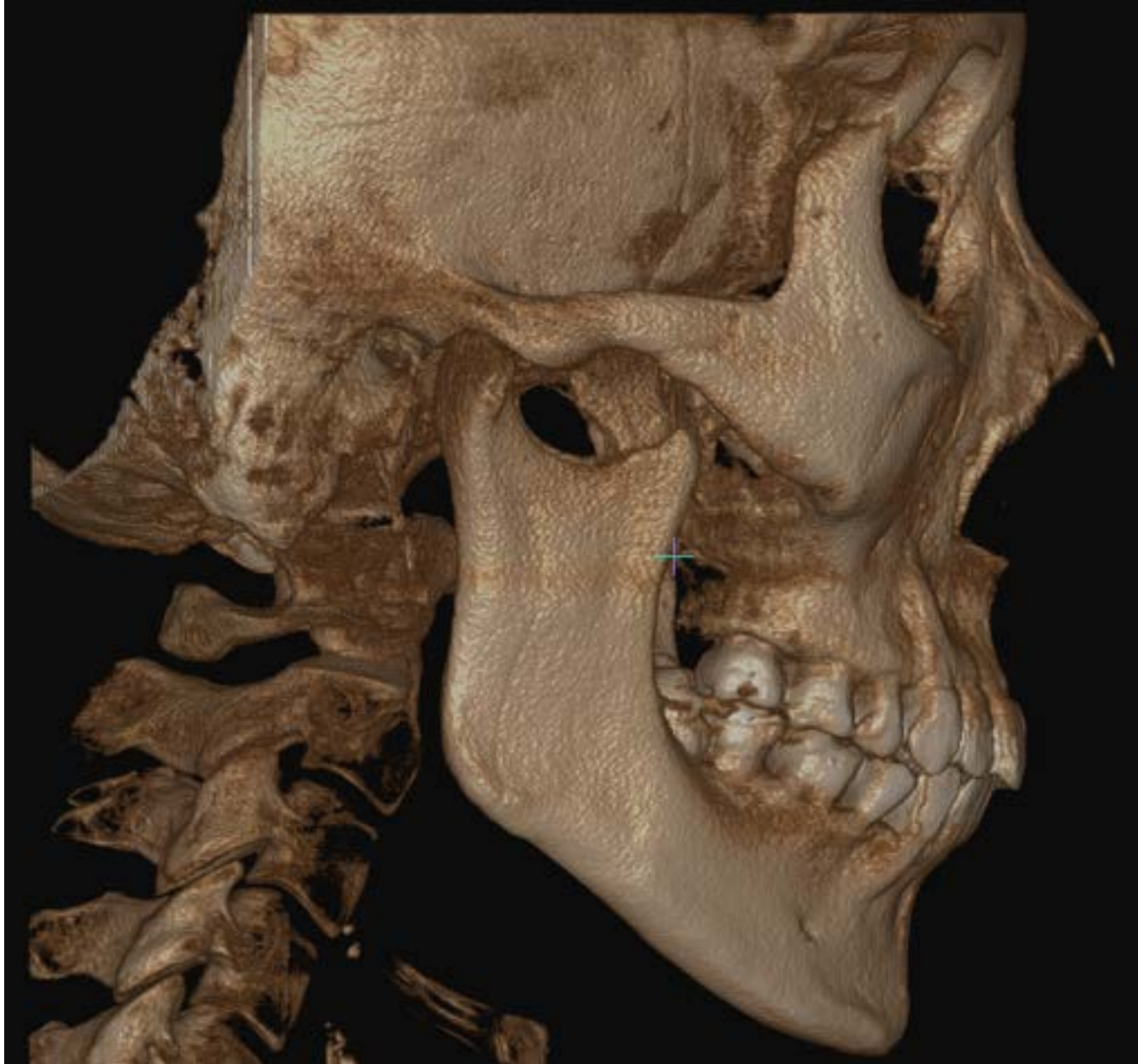
Bite check (2024-02-20)



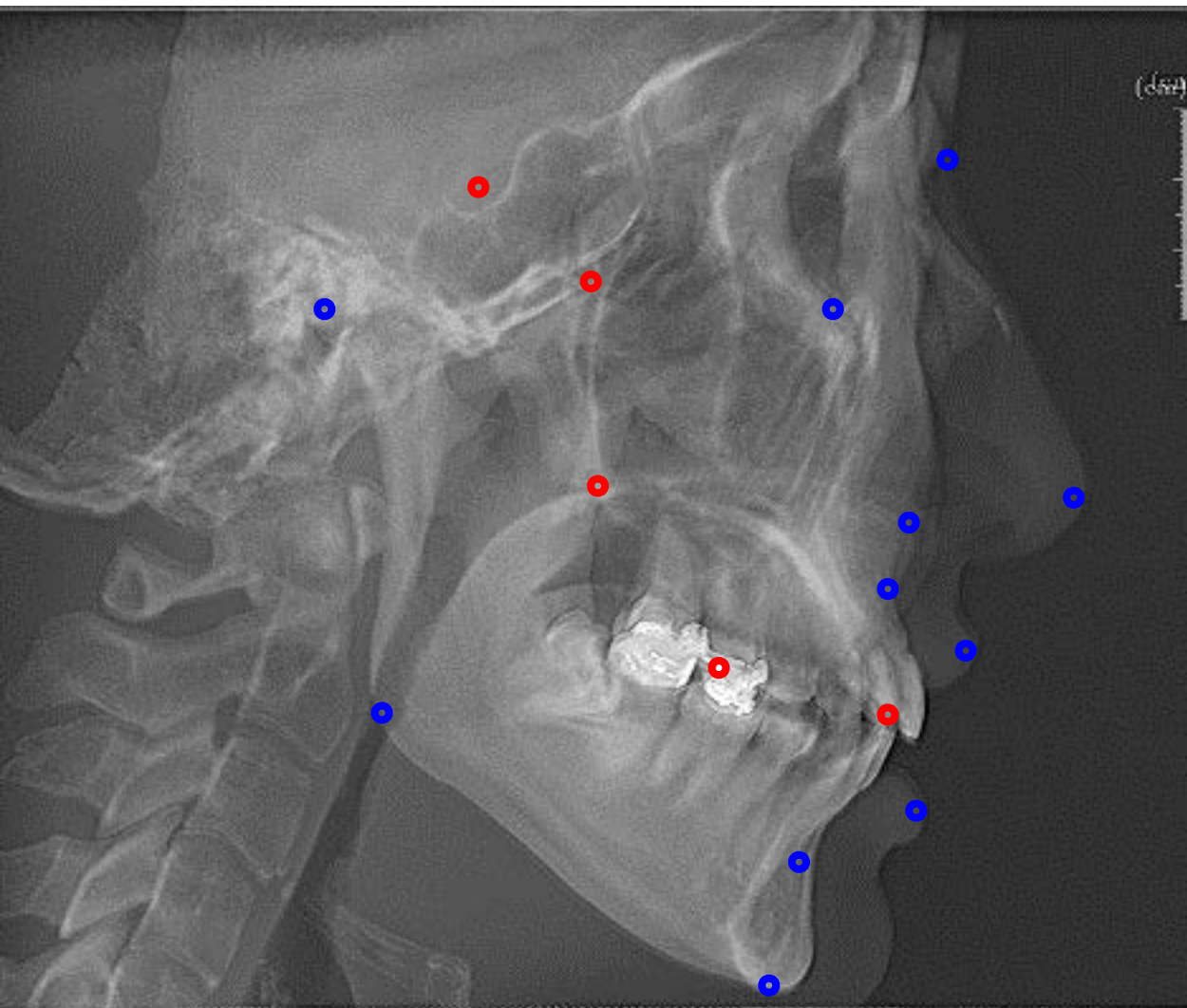
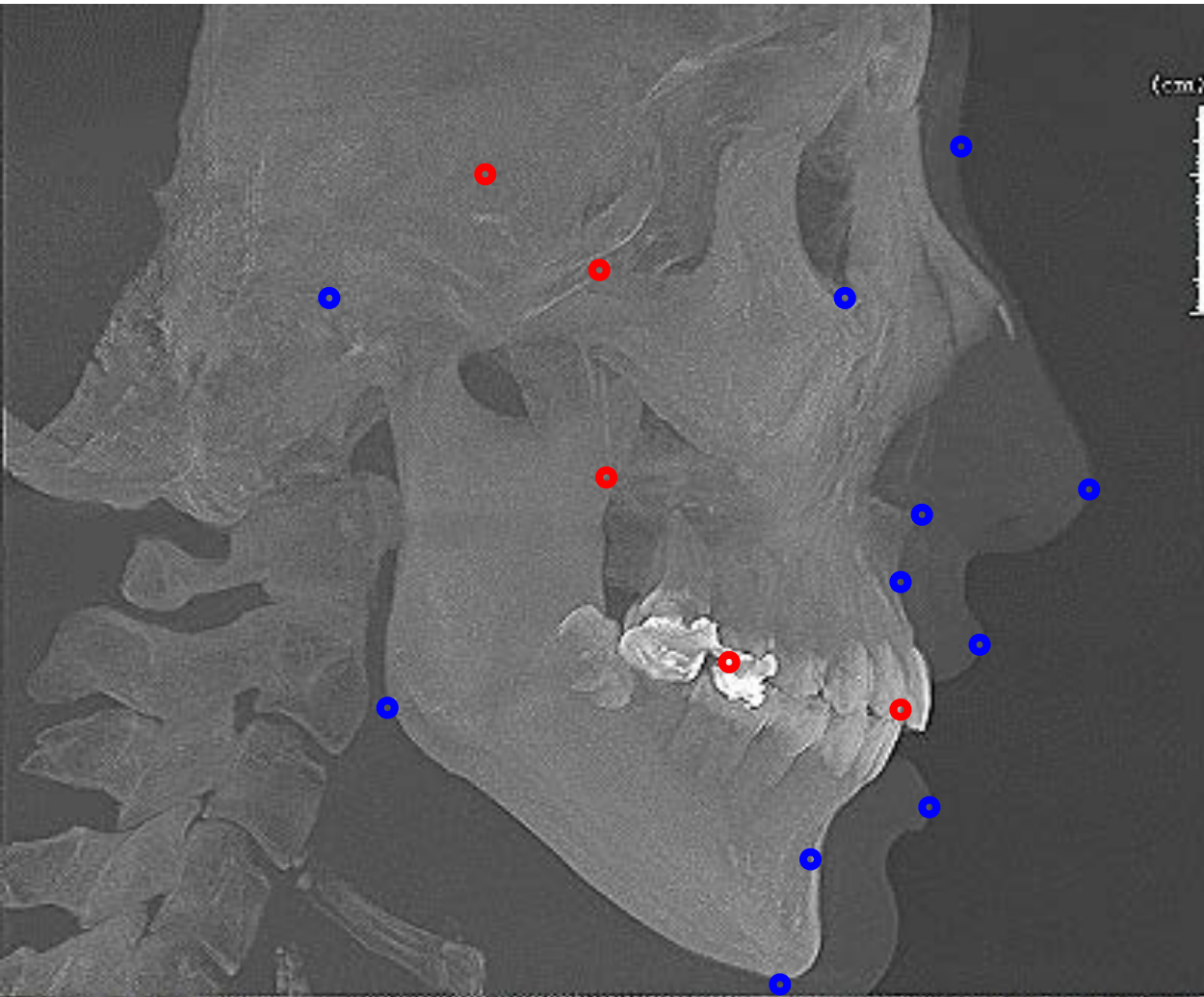
Final prosthesis (2024-01-16)



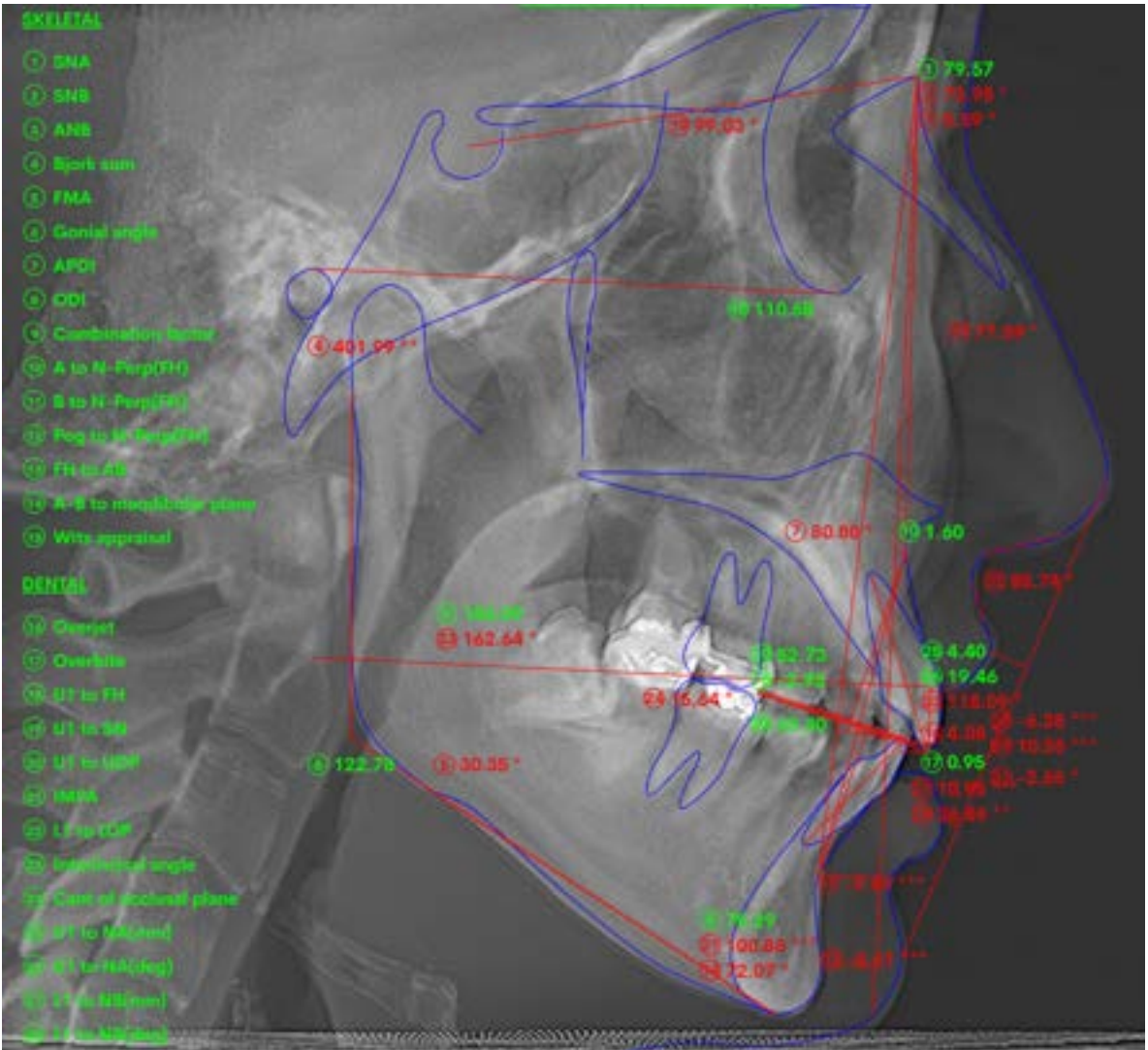
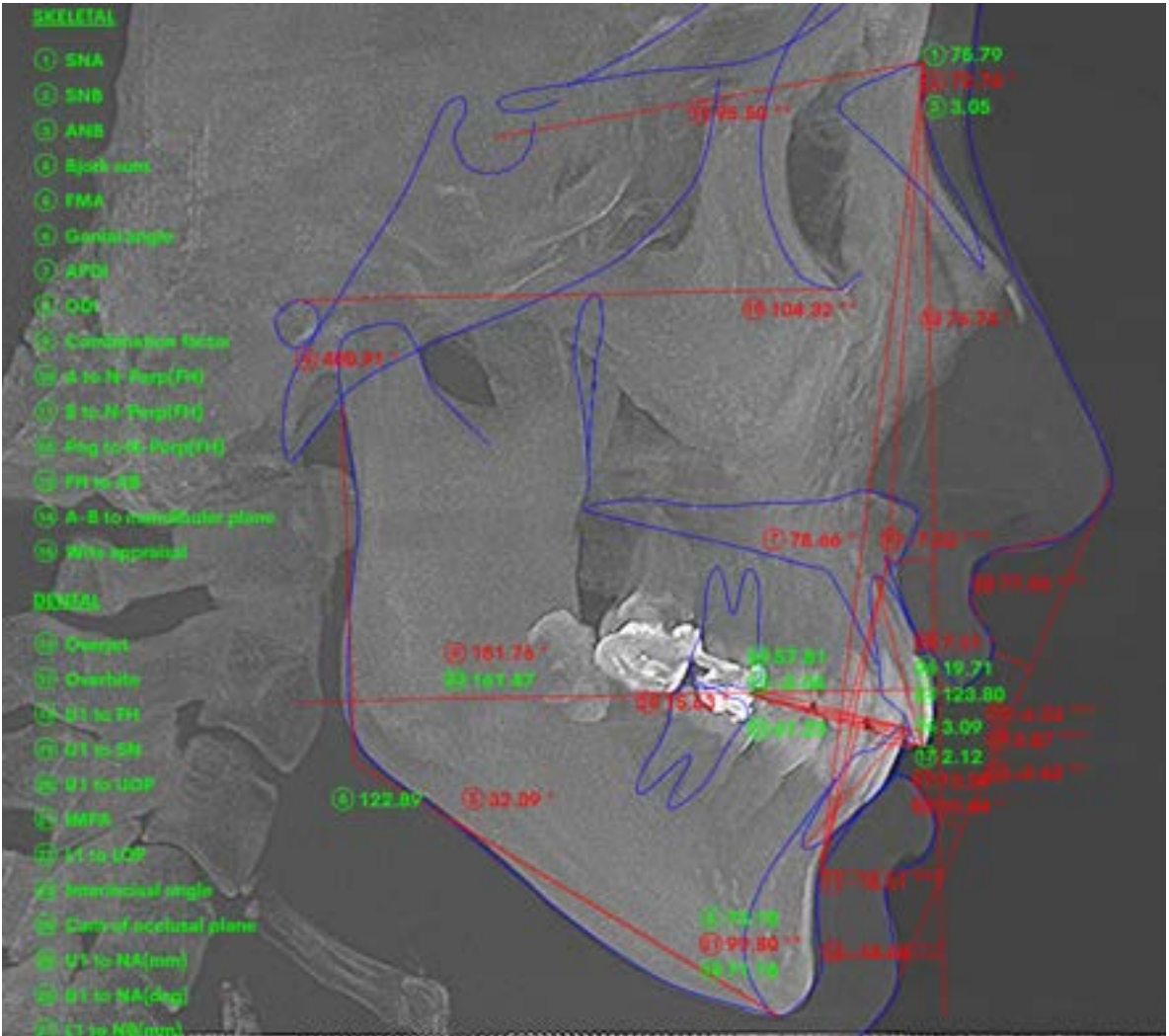
CT (2TS)



Virtual Ceph



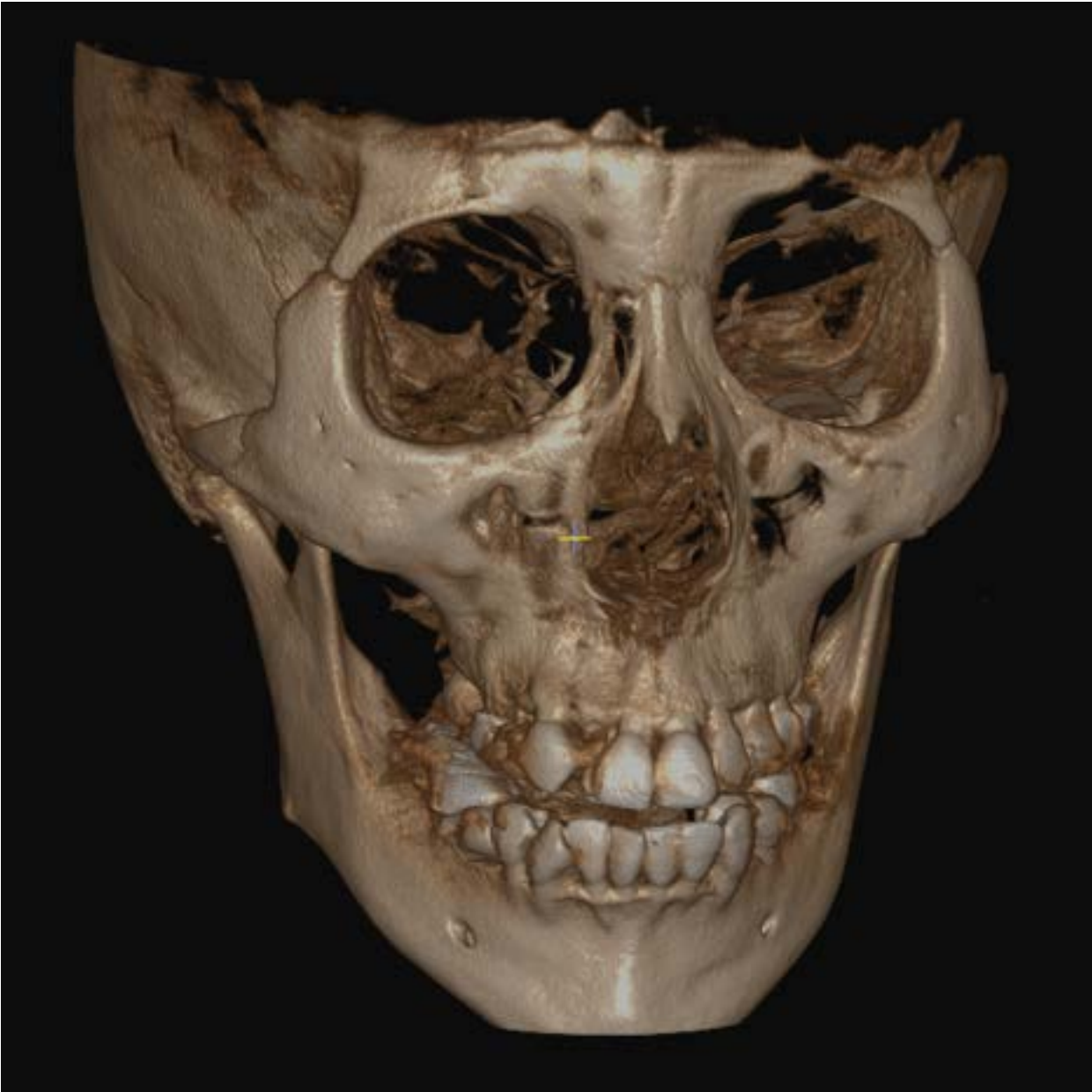
AI auto-tracing



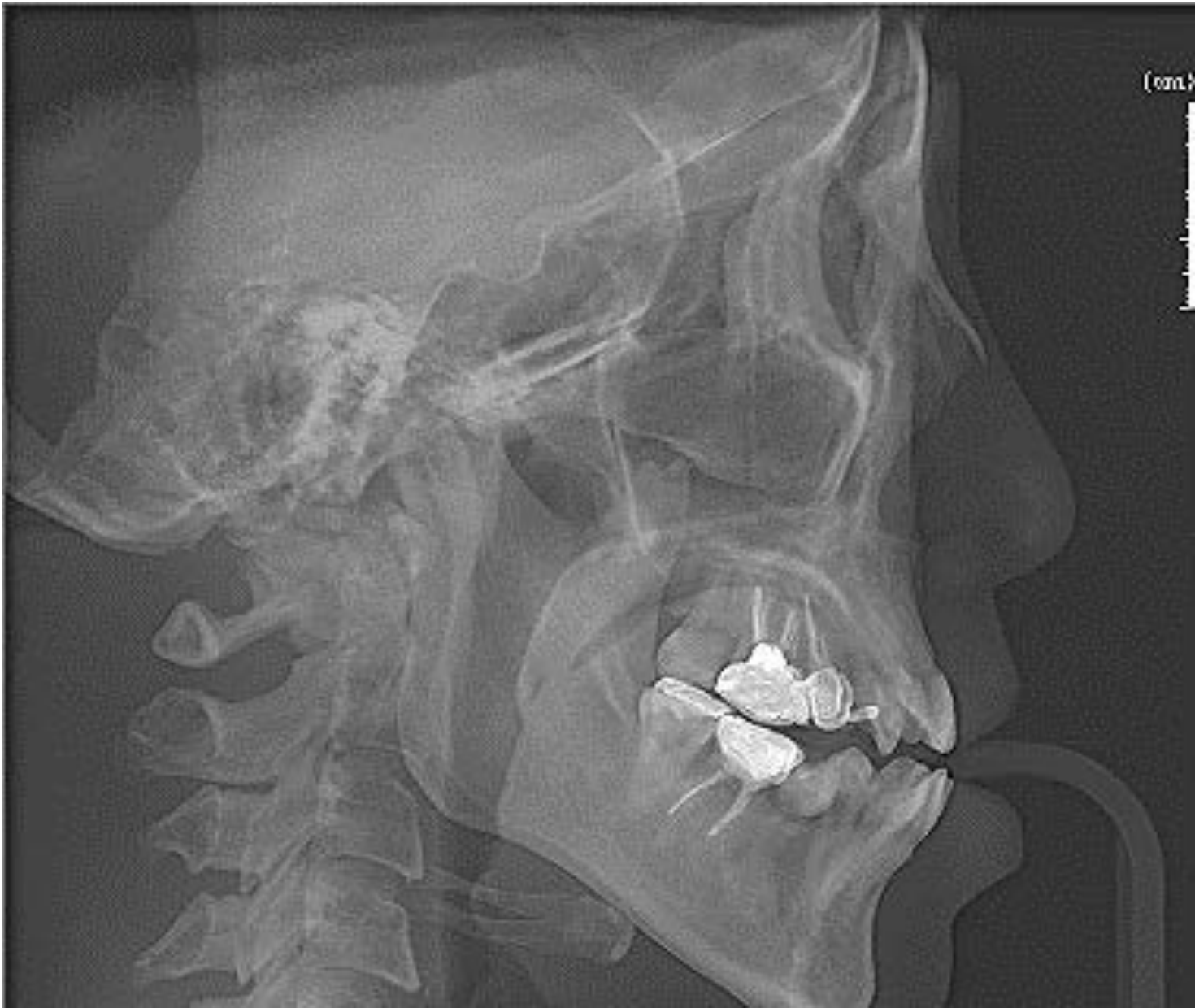CT(2-tile stitching) based Virtual Ceph

Clear image, anatomical landmark

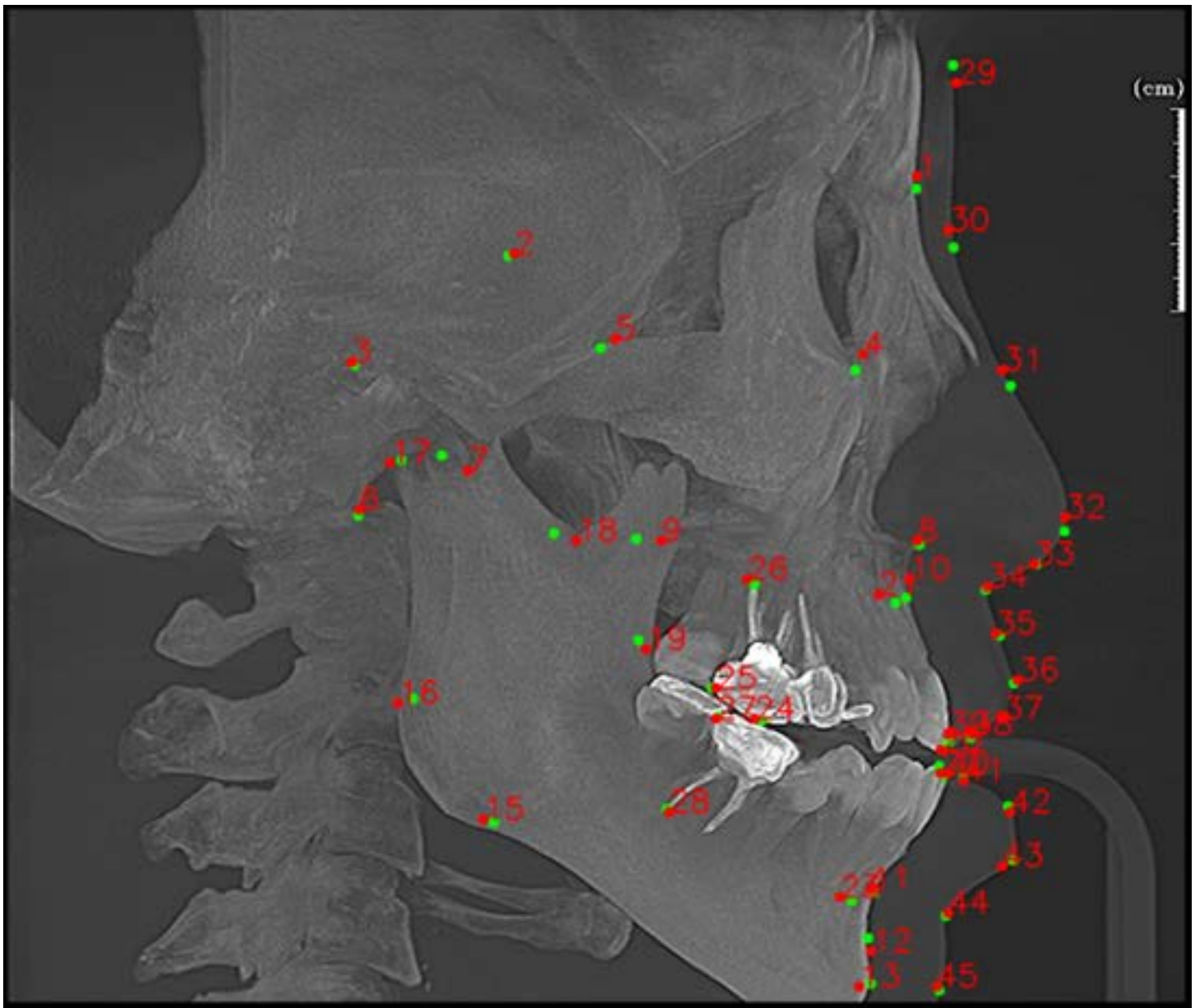
CT (2TS)



Virtual Ceph



AI Landmark

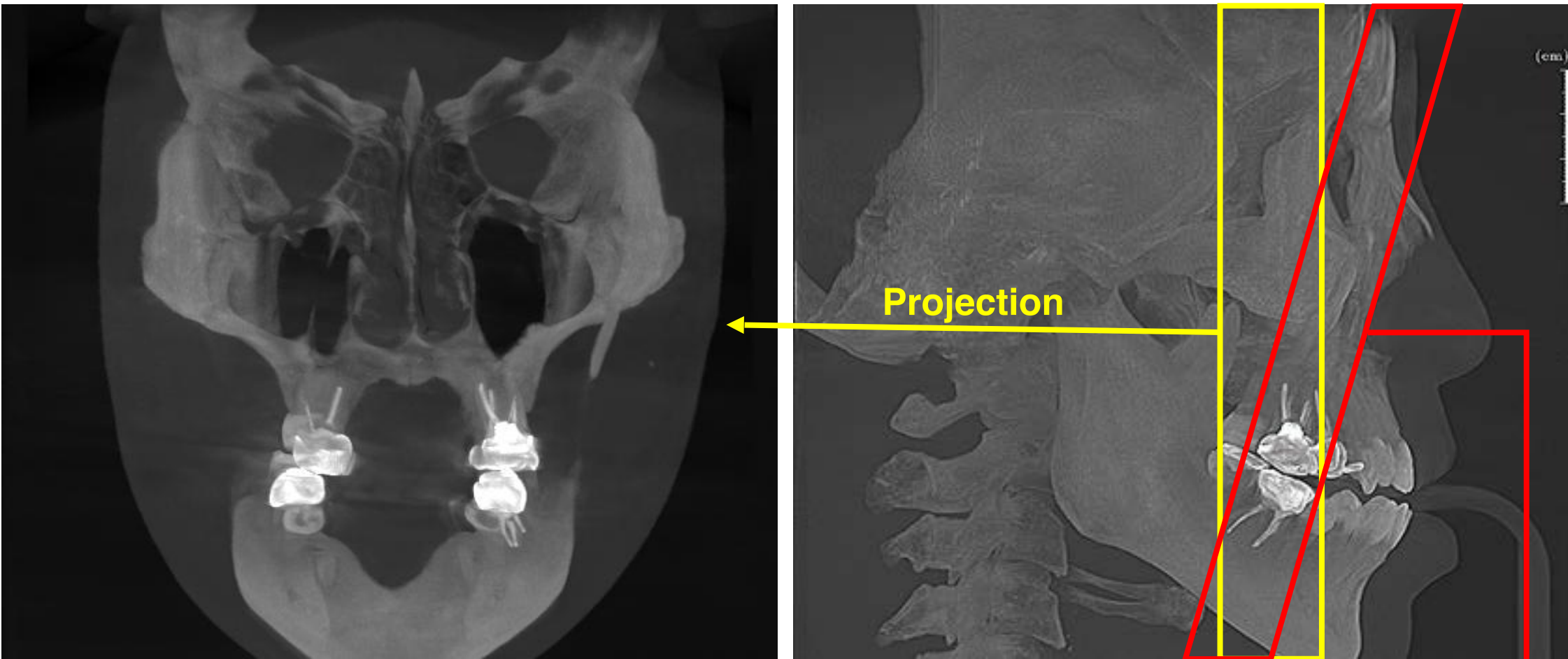
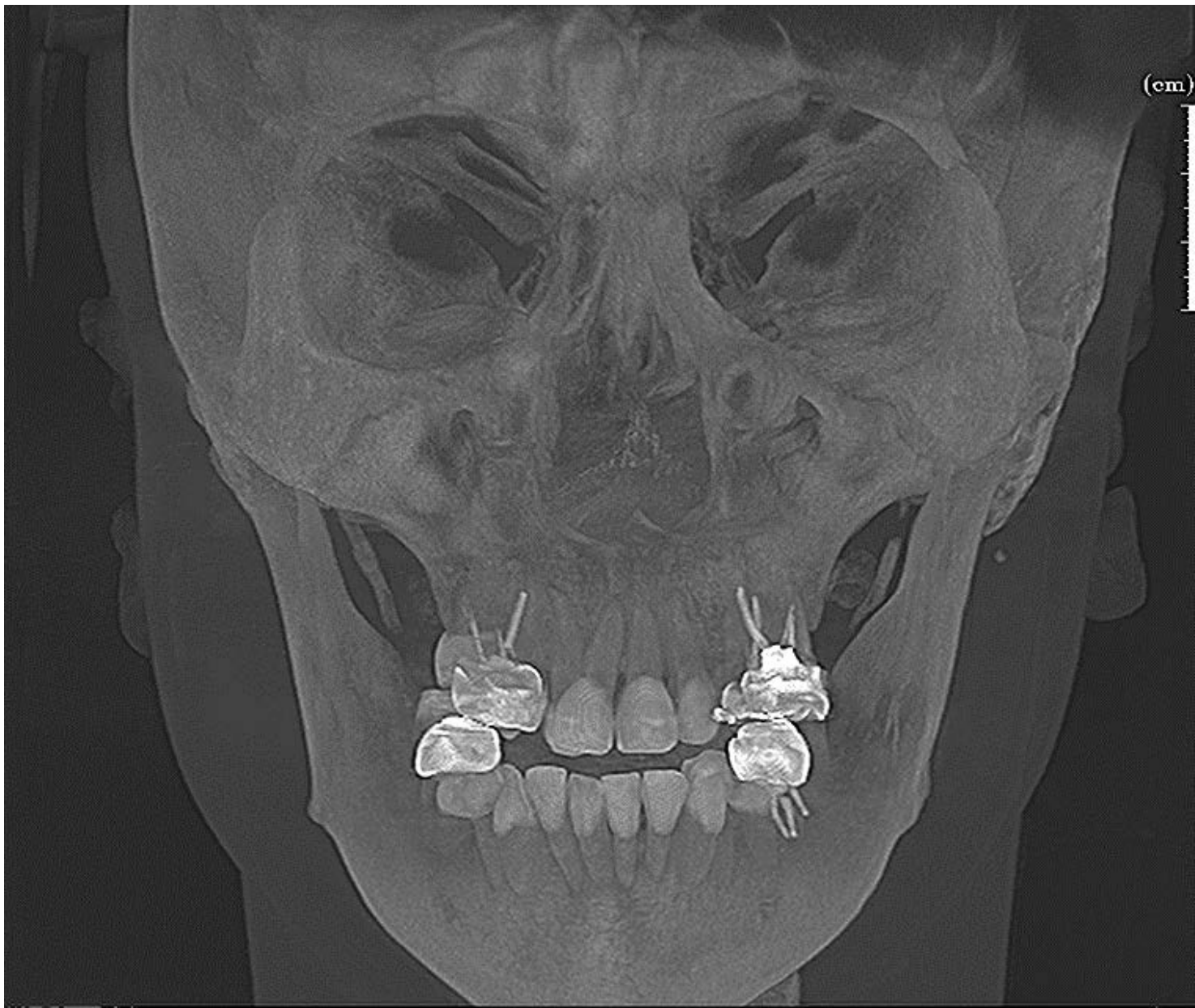


Green : ground truth
Red : prediction

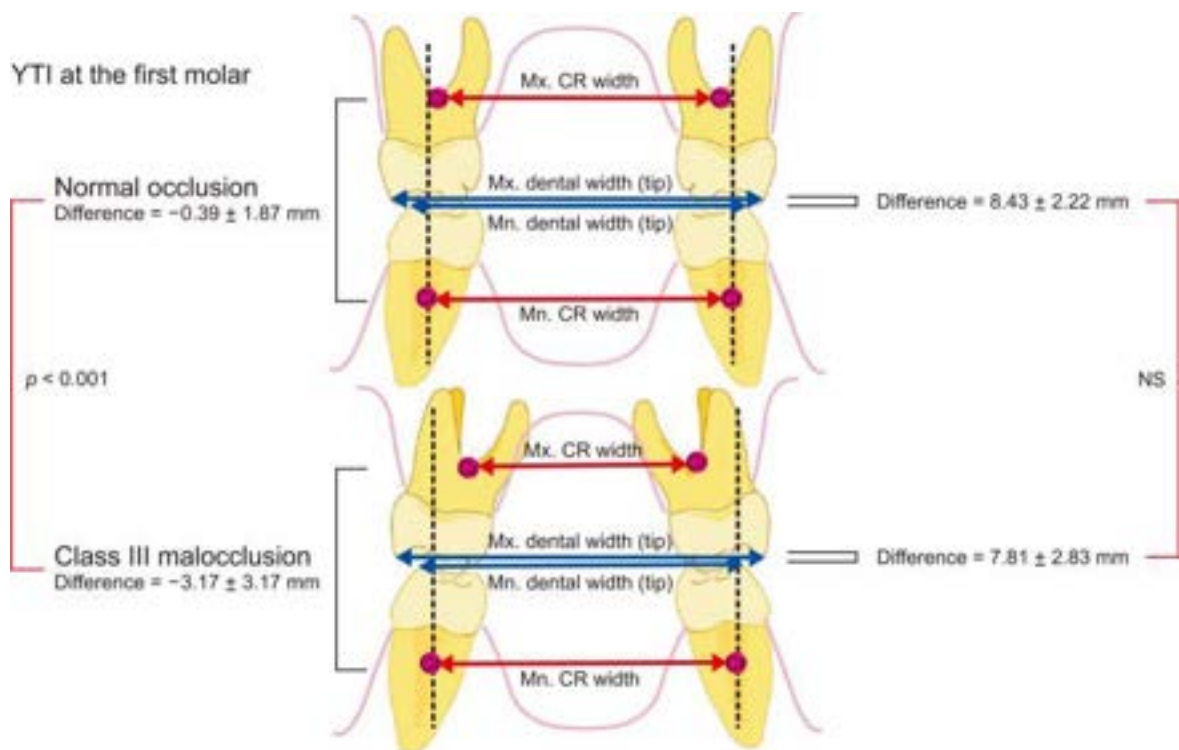
Multi-planar Virtual Ceph ; PA

Facial Asymmetry, Mandibular Yawing, Transvers Occlusion

Virtual Ceph
(PA)



ROI(region of image) Projection



Occlusal plane based projection

YTI (Yonsei Transverse Index)

2 types of Zirconia

2 hour fast sintered mono block

3 layer of different value









bright Mono



4.5Y 2h

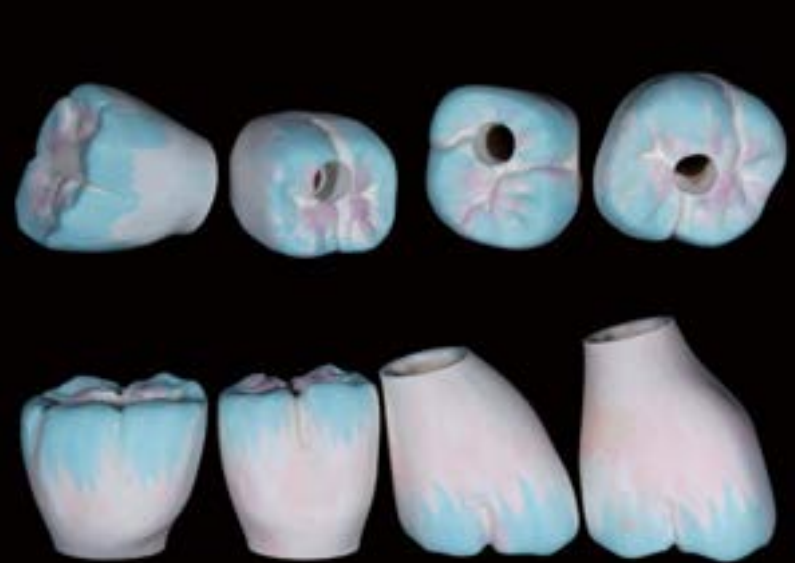Only 1 Layer
(45%, 600MPa)

Fast Sintering

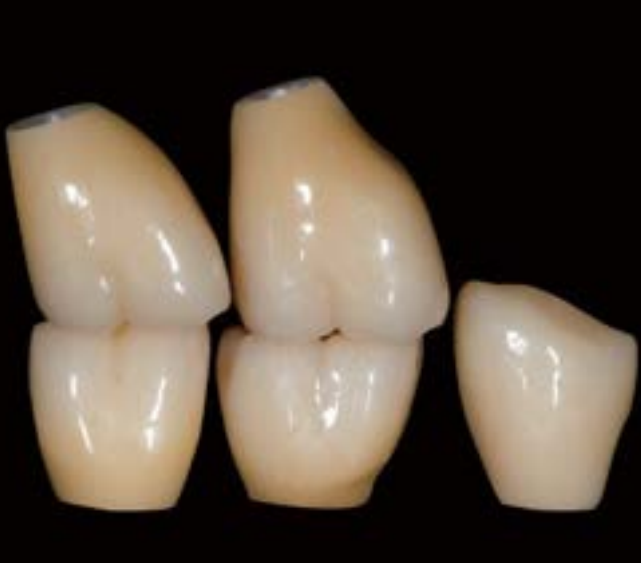Case	Single Crown		Bridge(3-unit-Bridge)	
	Anterior	Posterior	Anterior	Posterior
Block				
bright Mono				

● Recommend ○ Possible

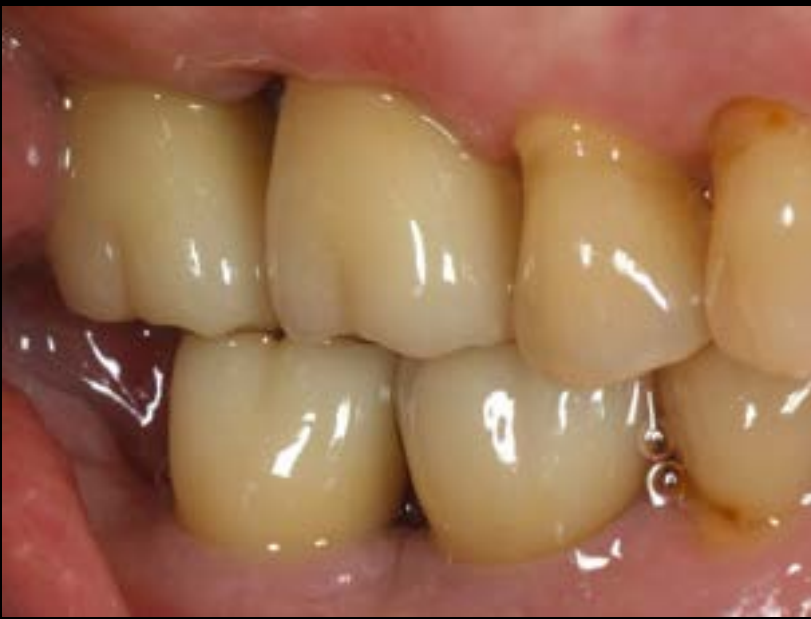2hr Fast Sintering



Coloring

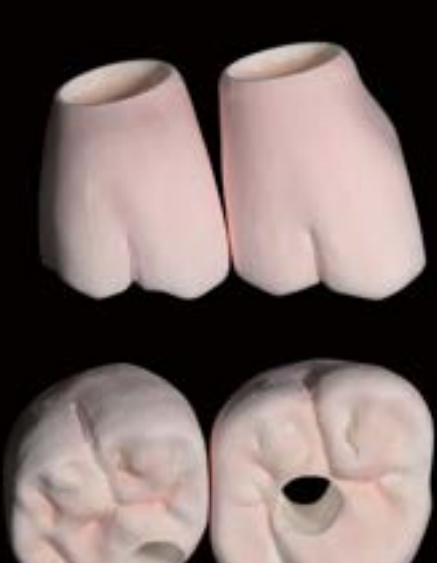

Sintering

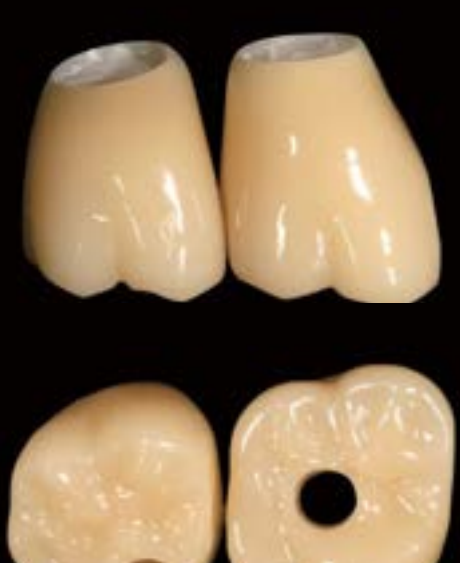

Final Prosthesis

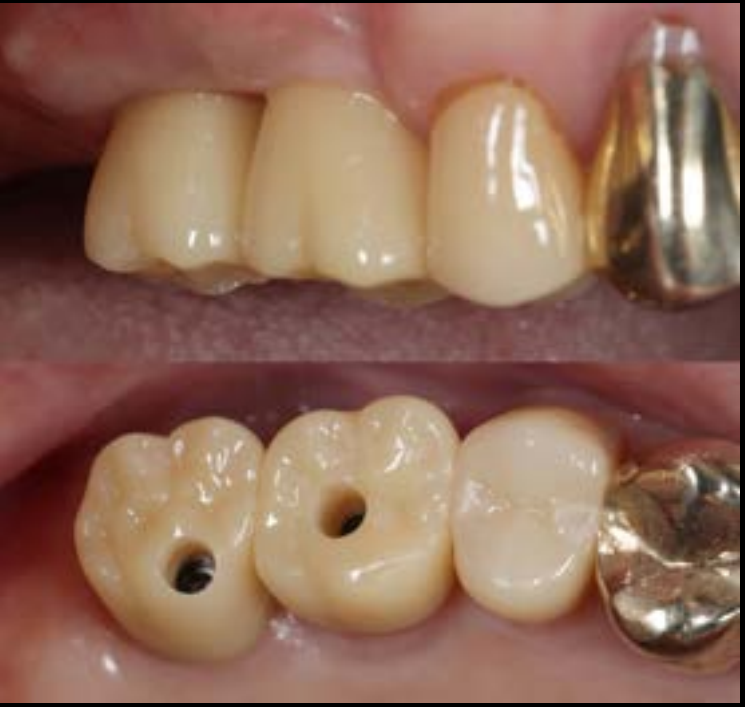2hr Fast Sintering



Coloring

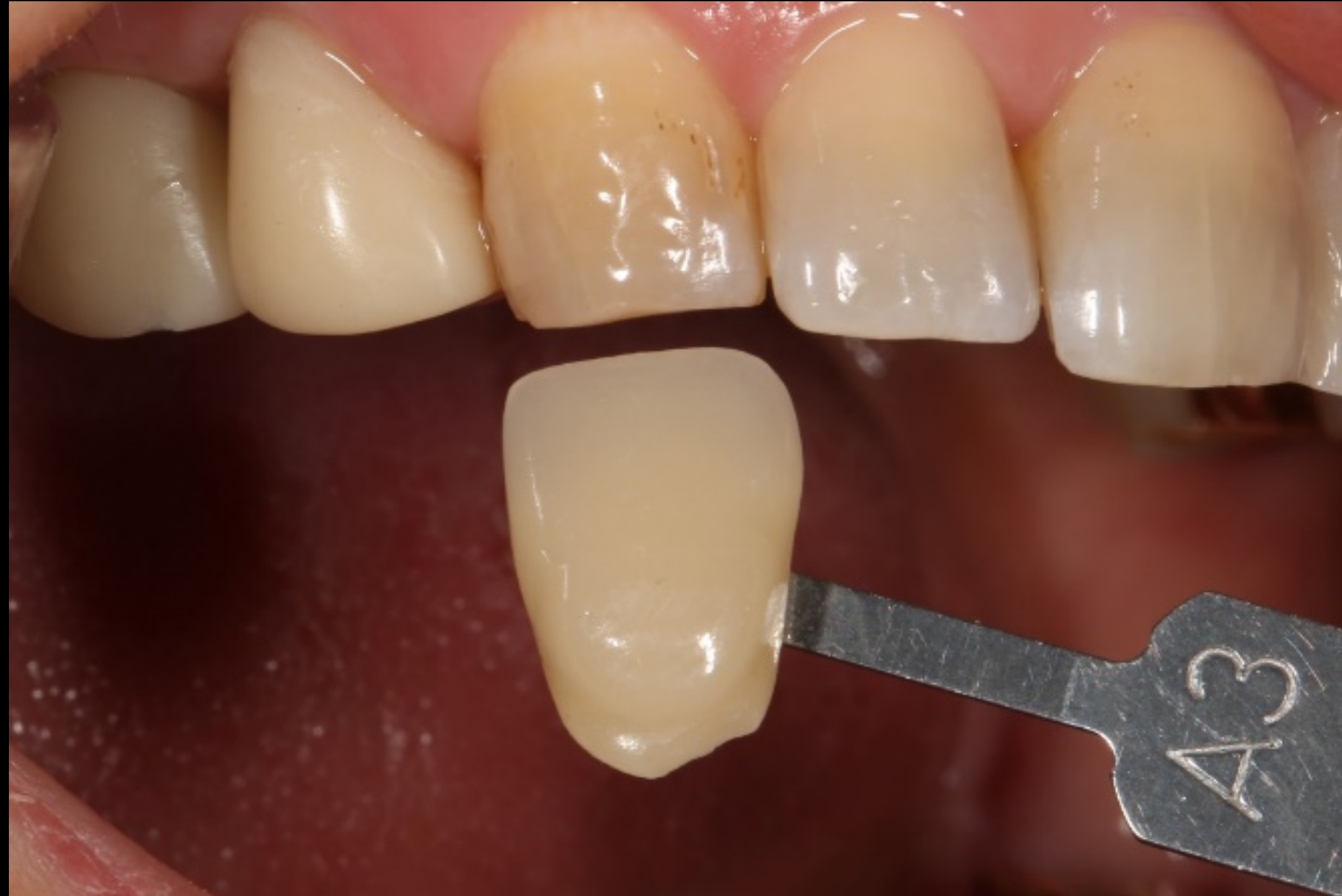

Sintering

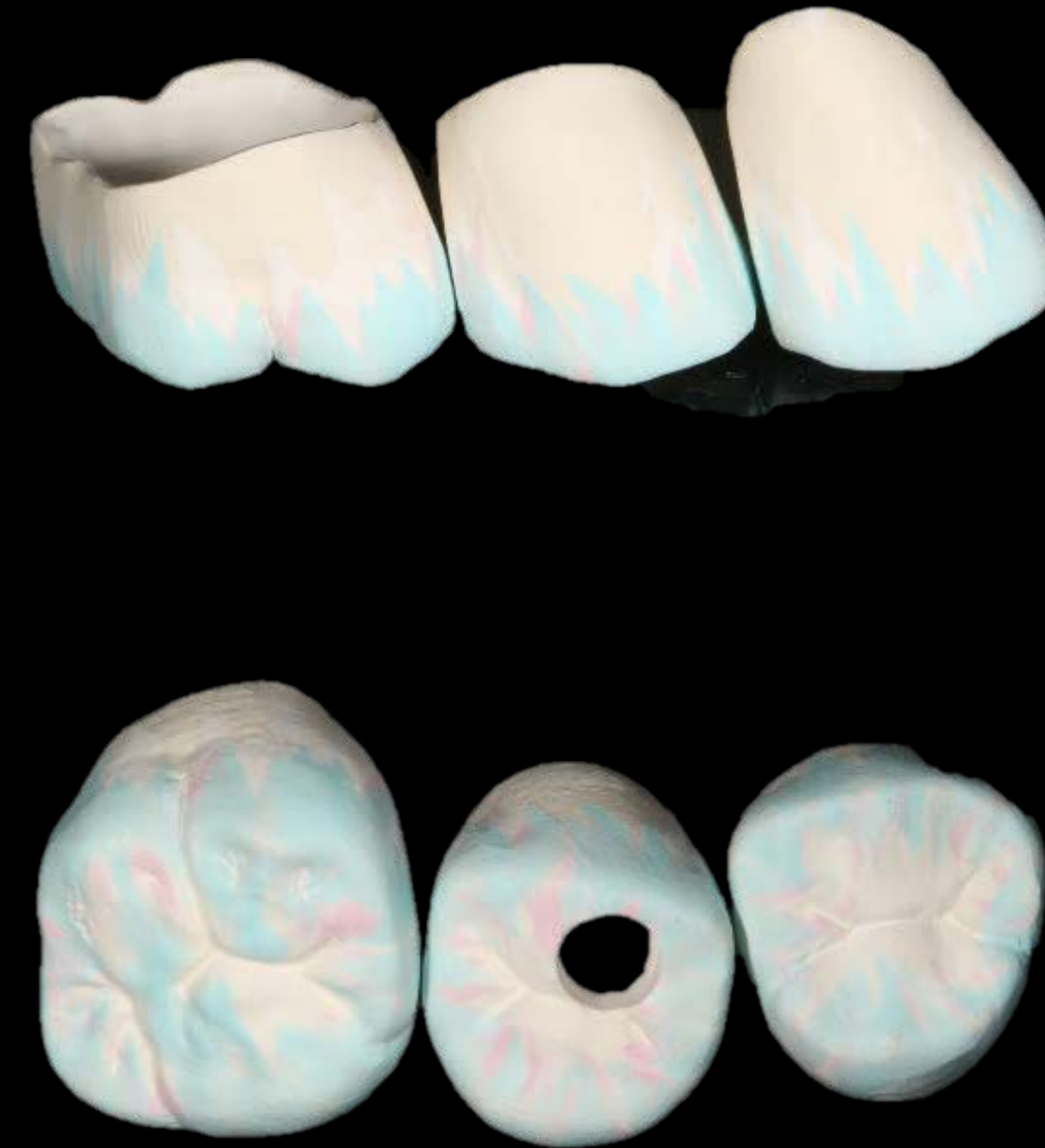

Final Prosthesis

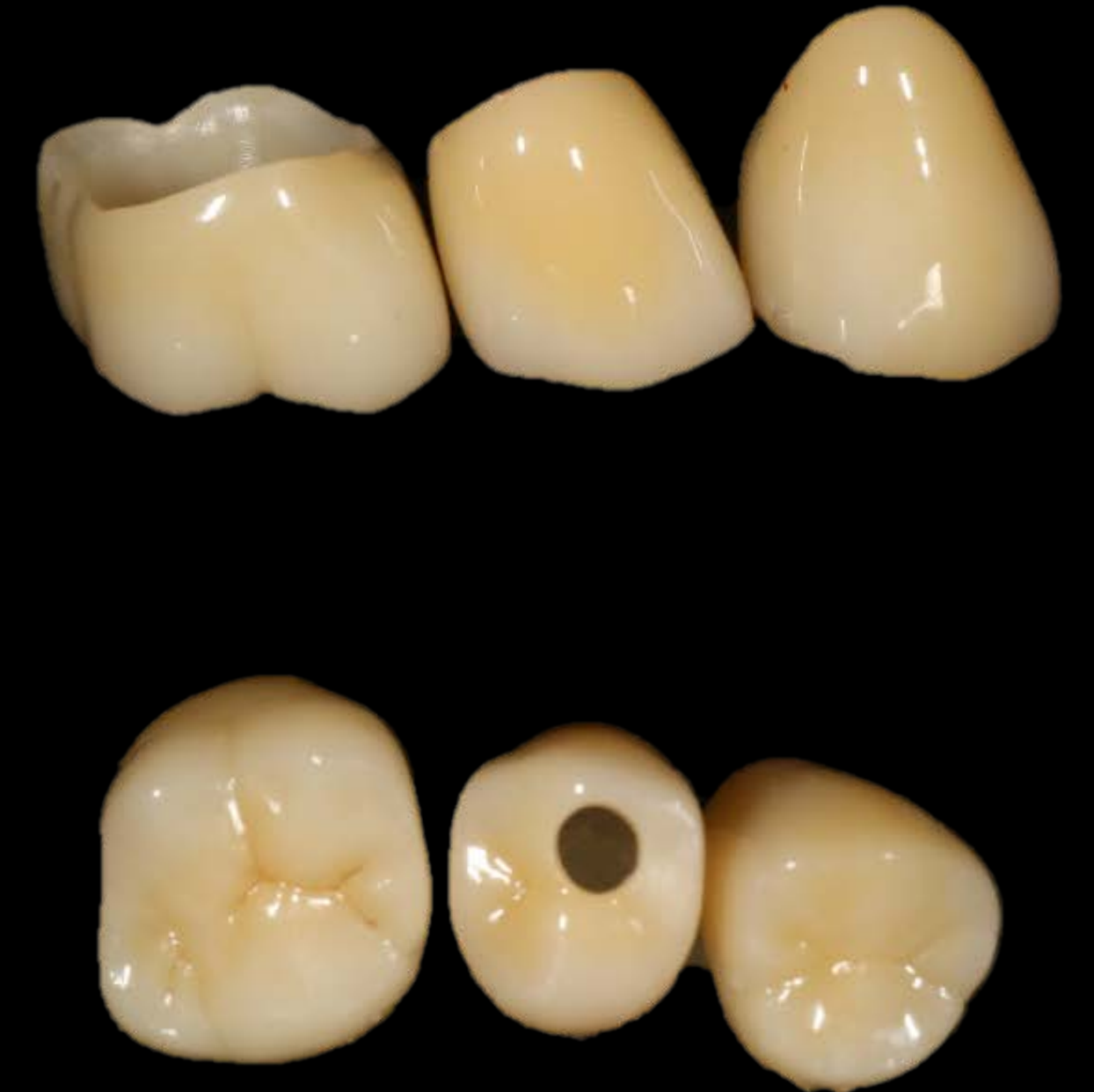Natural tooth Case_2



Shade Taking : A3

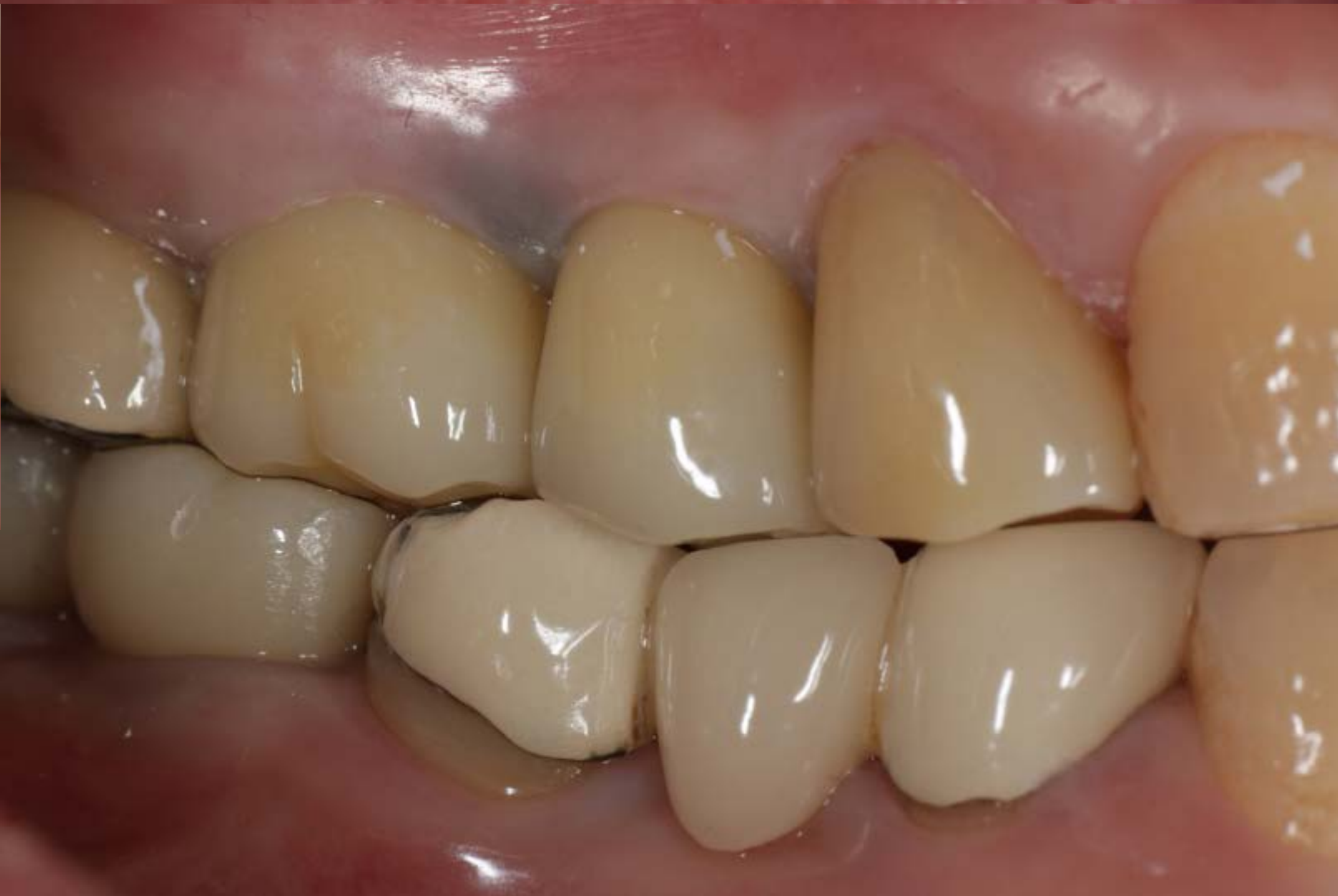
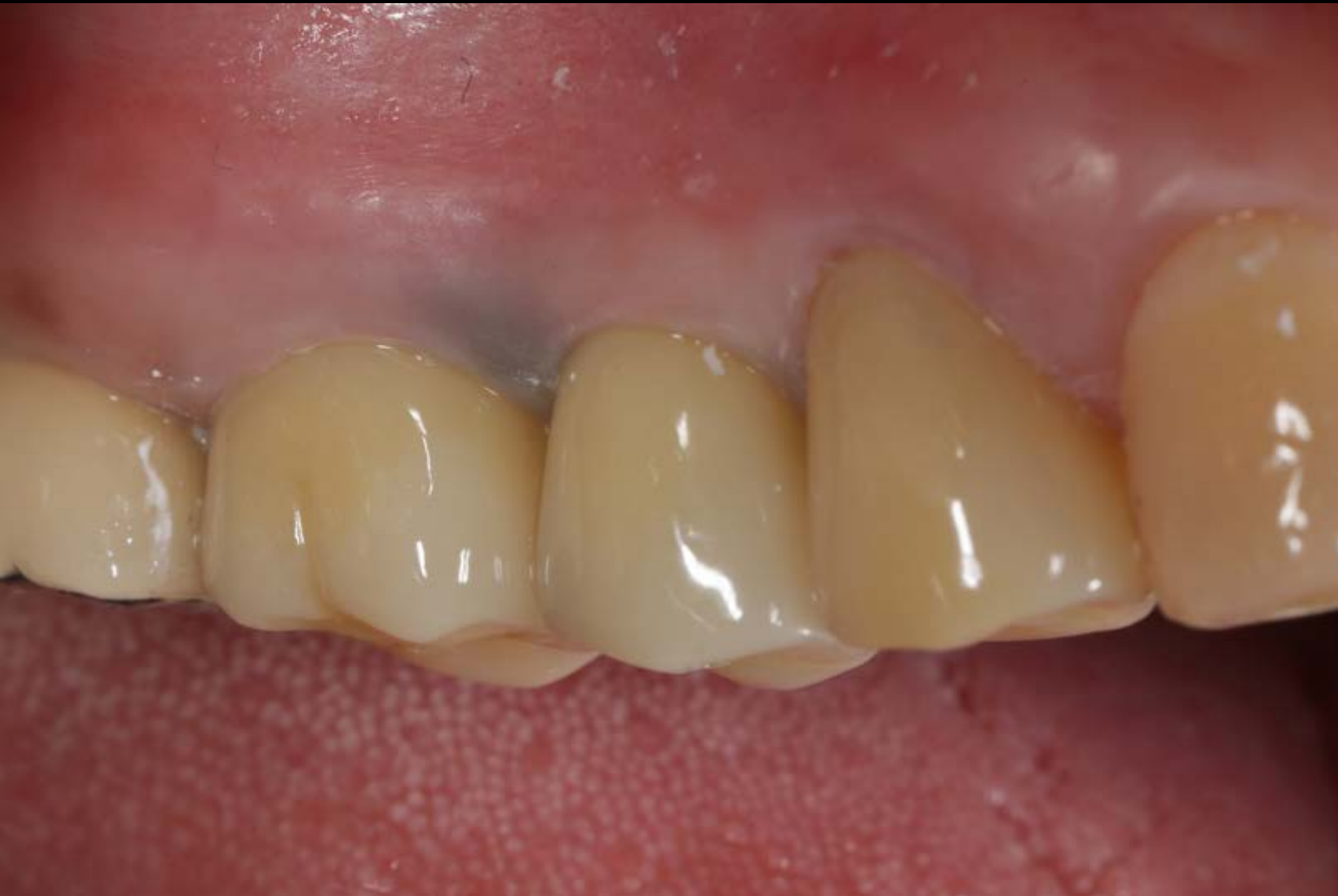
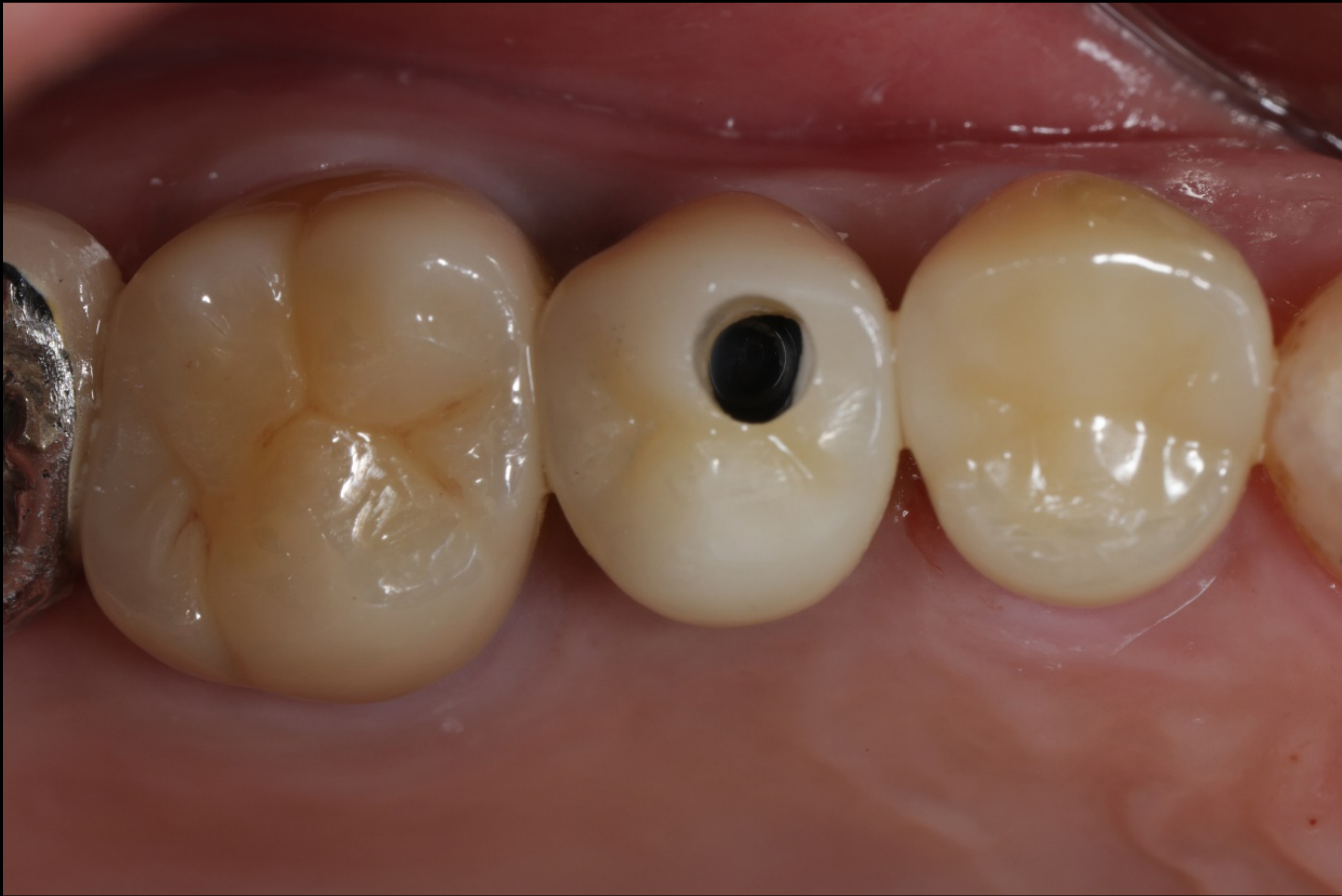Inner – White Opaque
Occlusal - Trans violet
Light gray

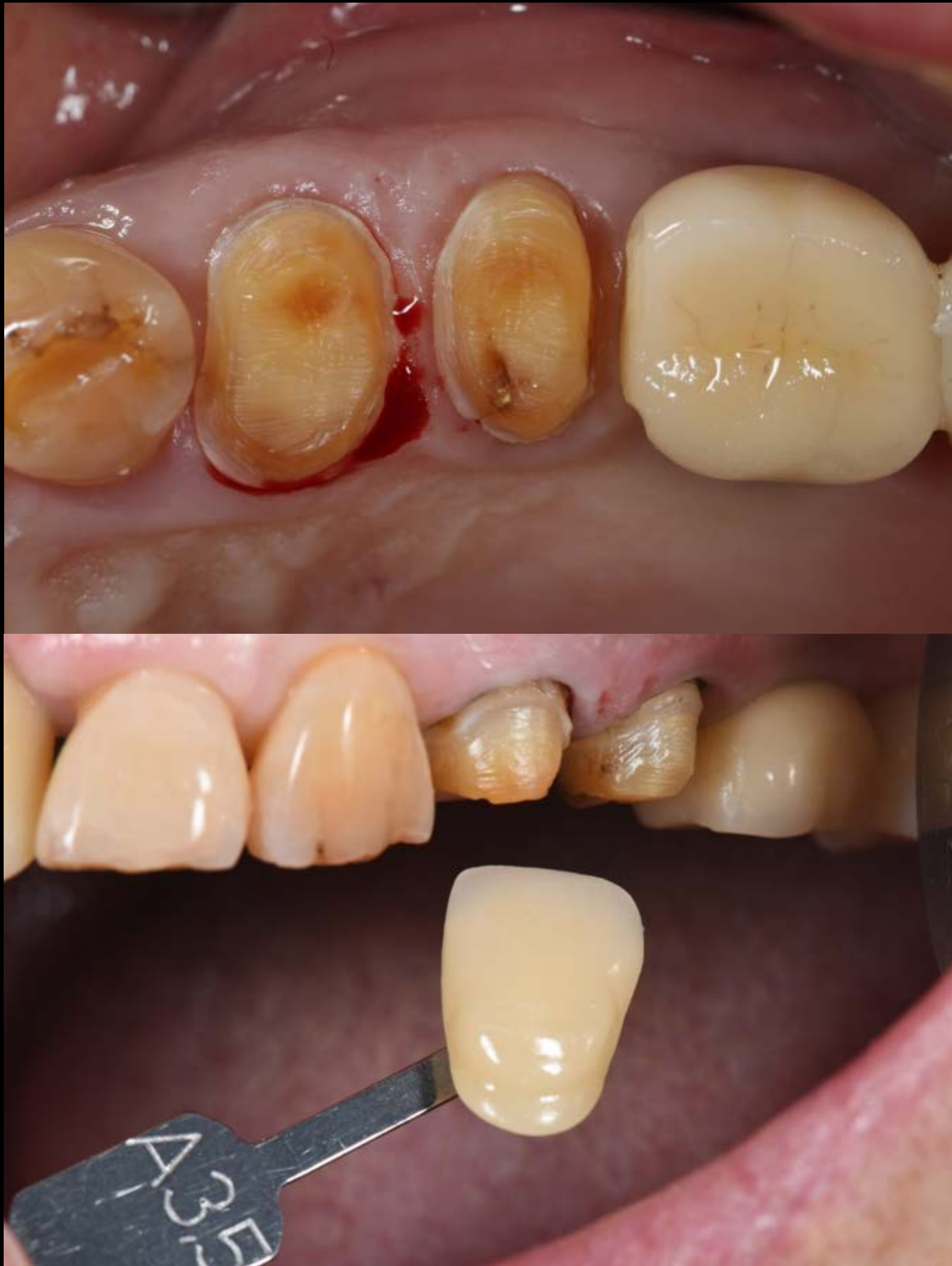

2h Fast Sintering

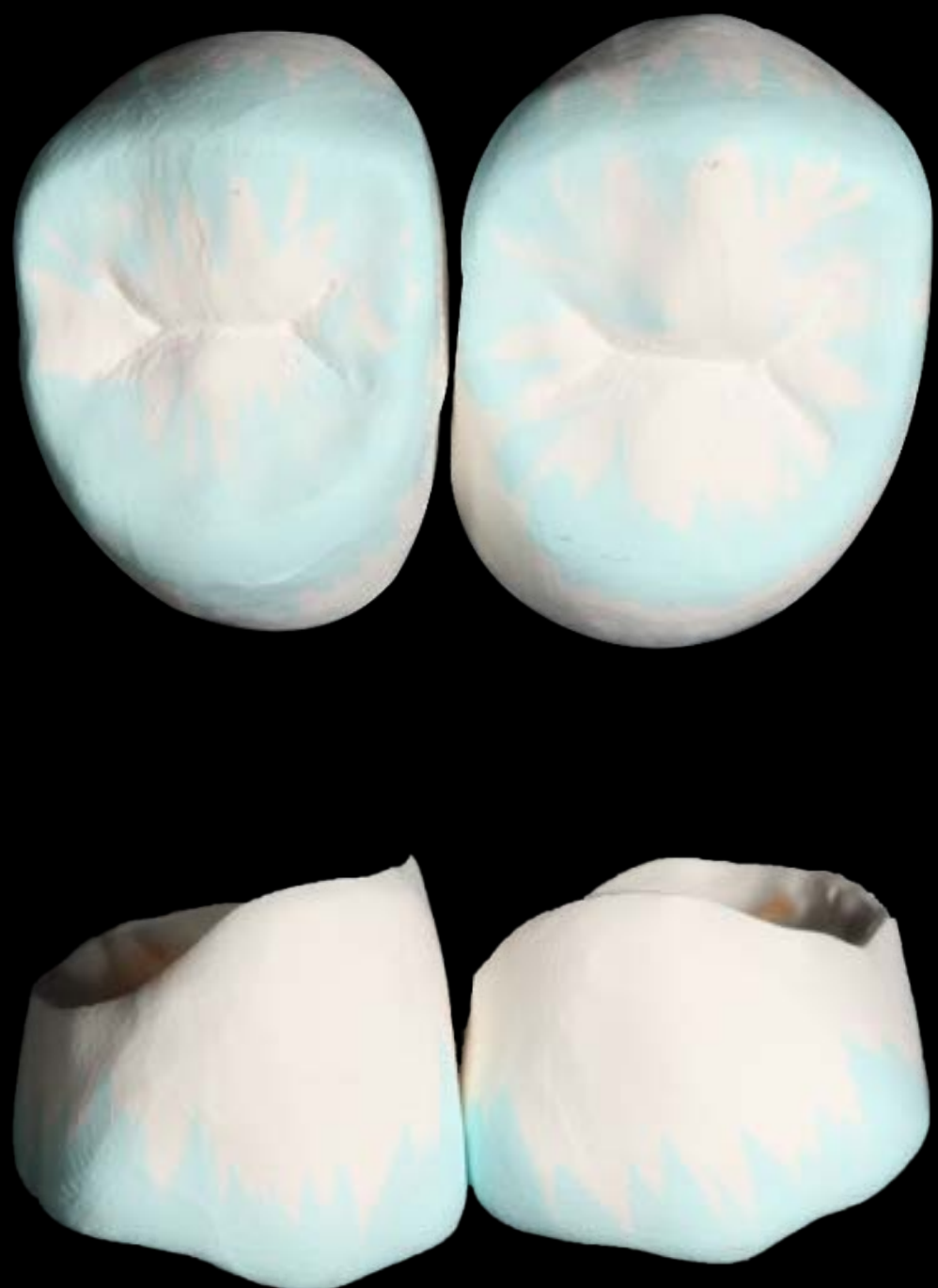
Natural tooth Case_2



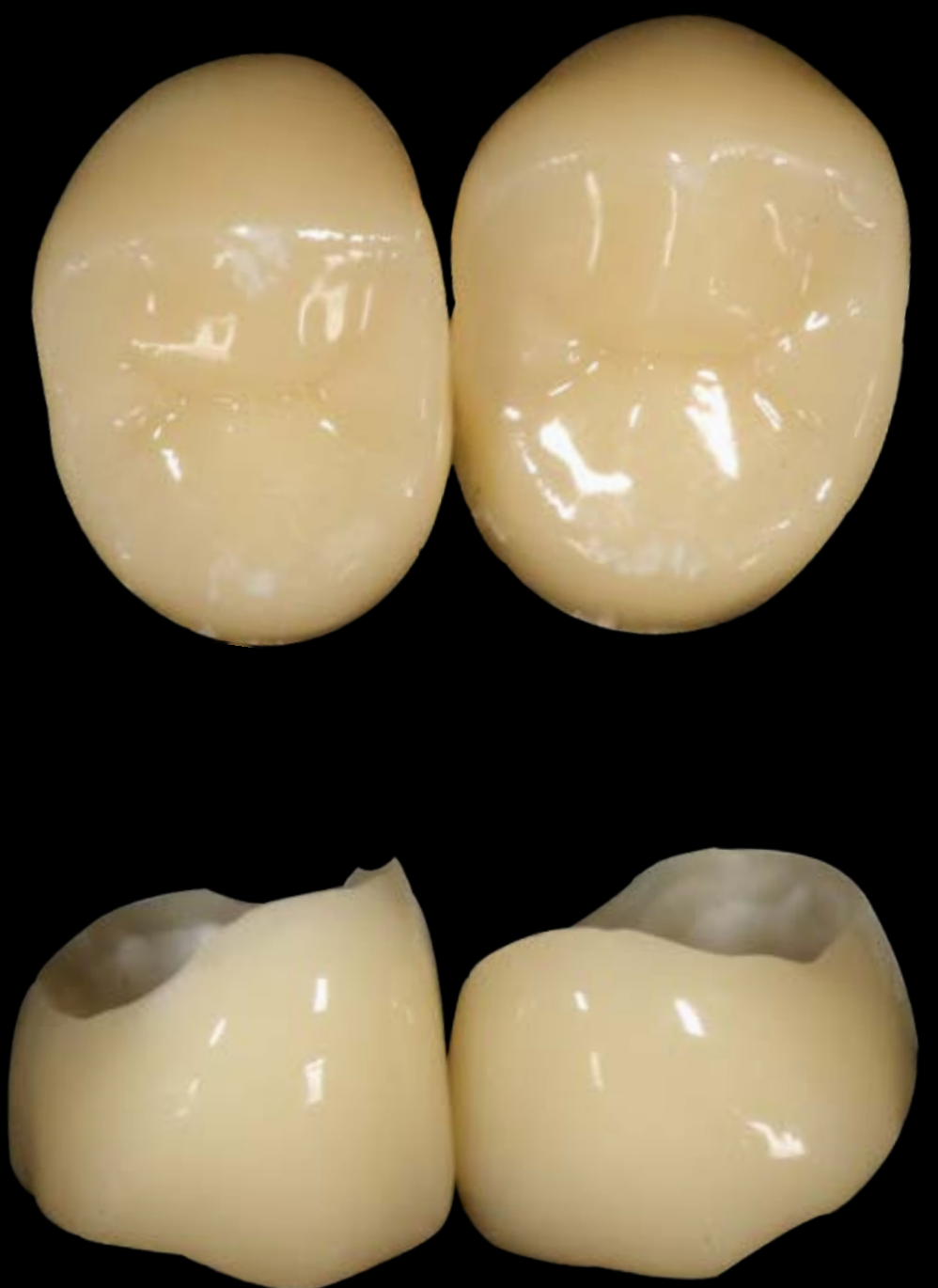Natural tooth Case_3



Shade Taking : A3.5

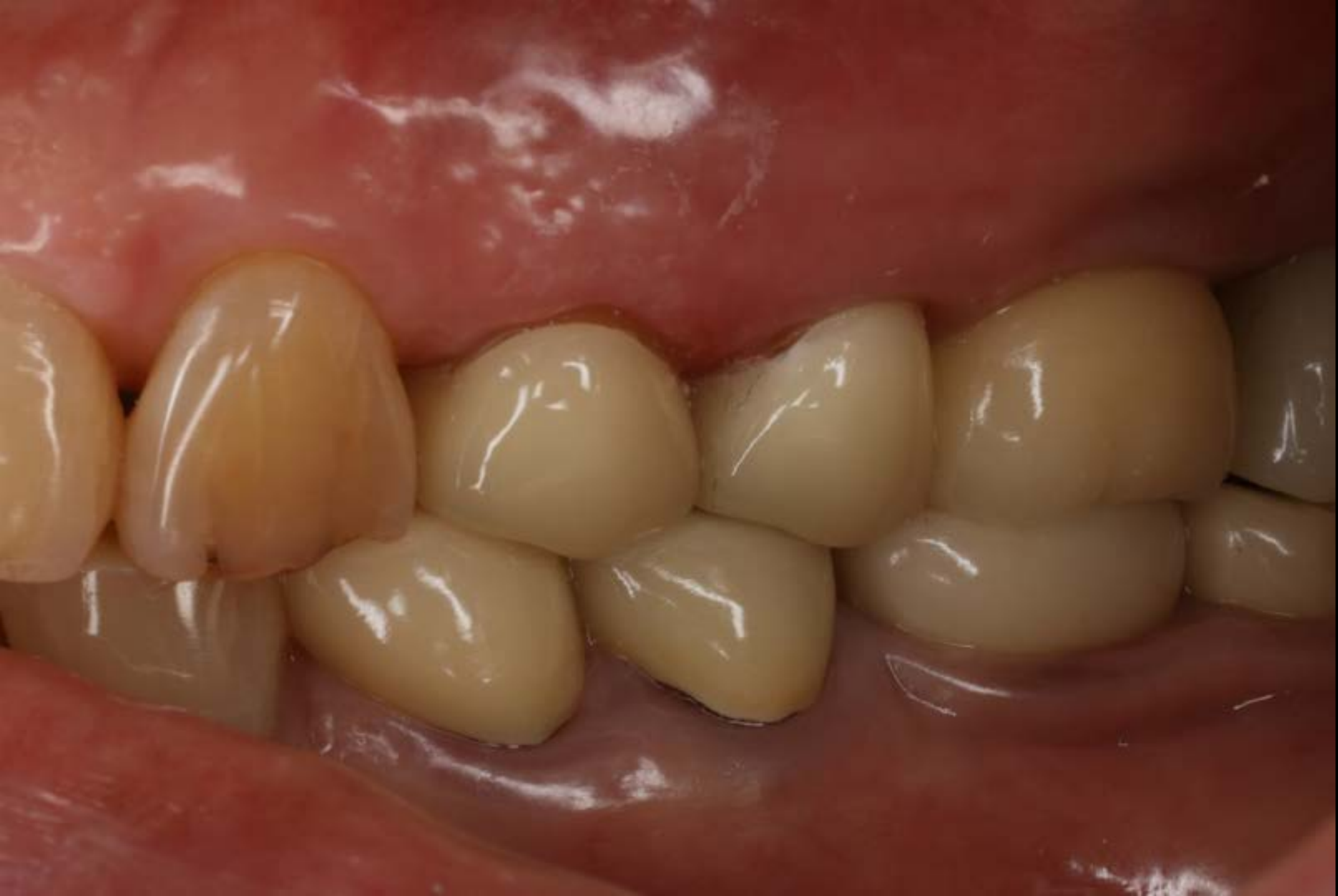
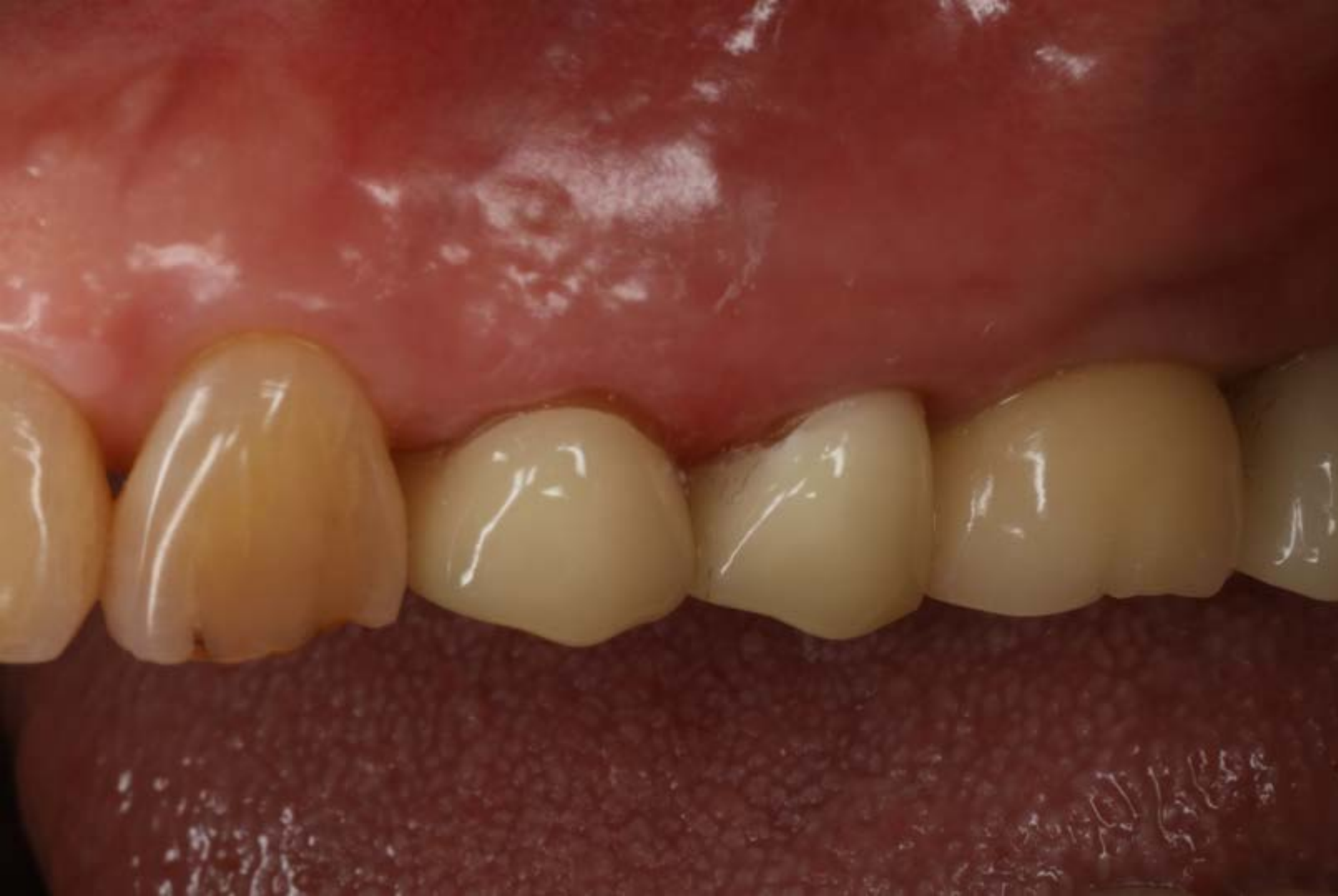
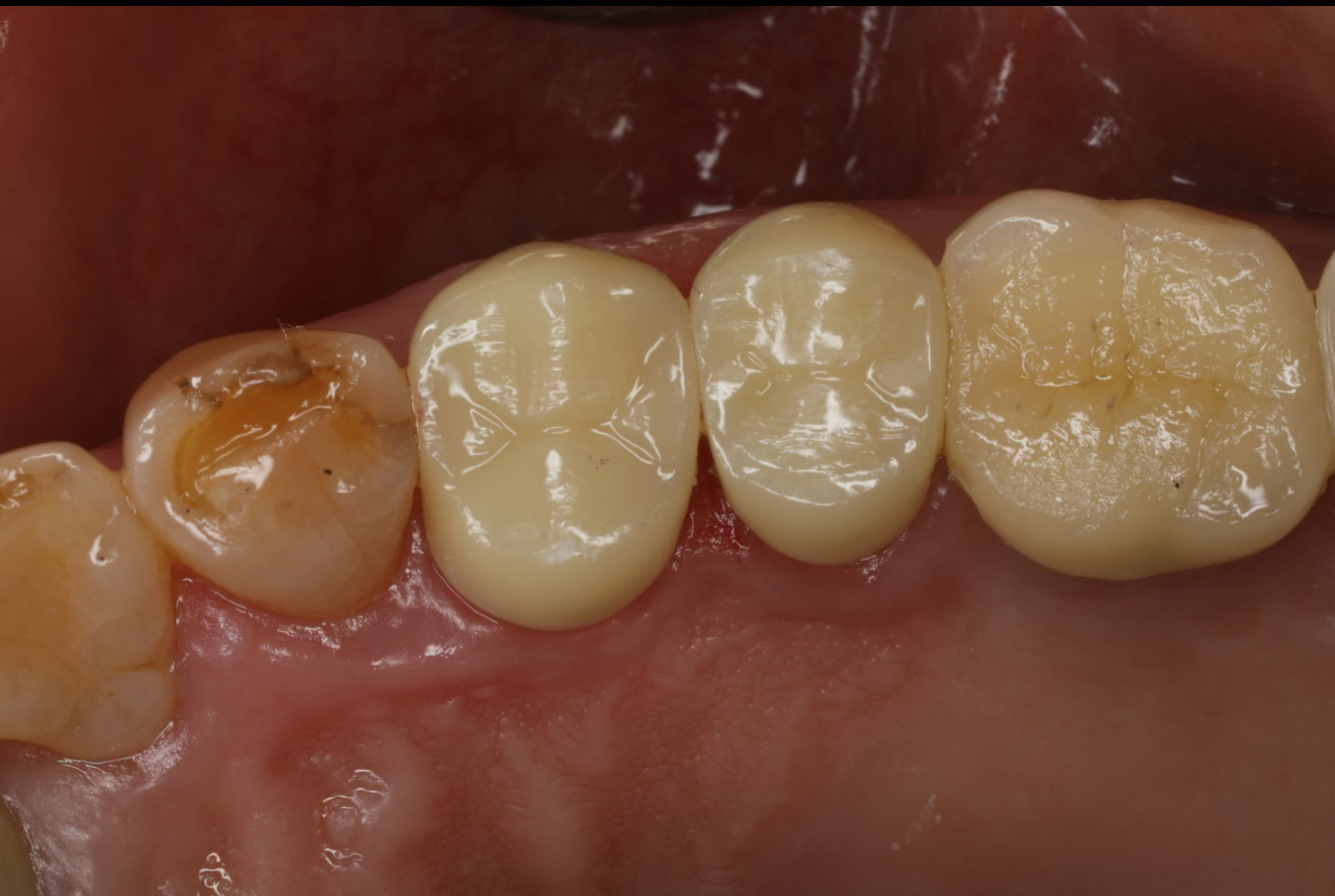Inner – White Opaque
Occlusal - Trans violet

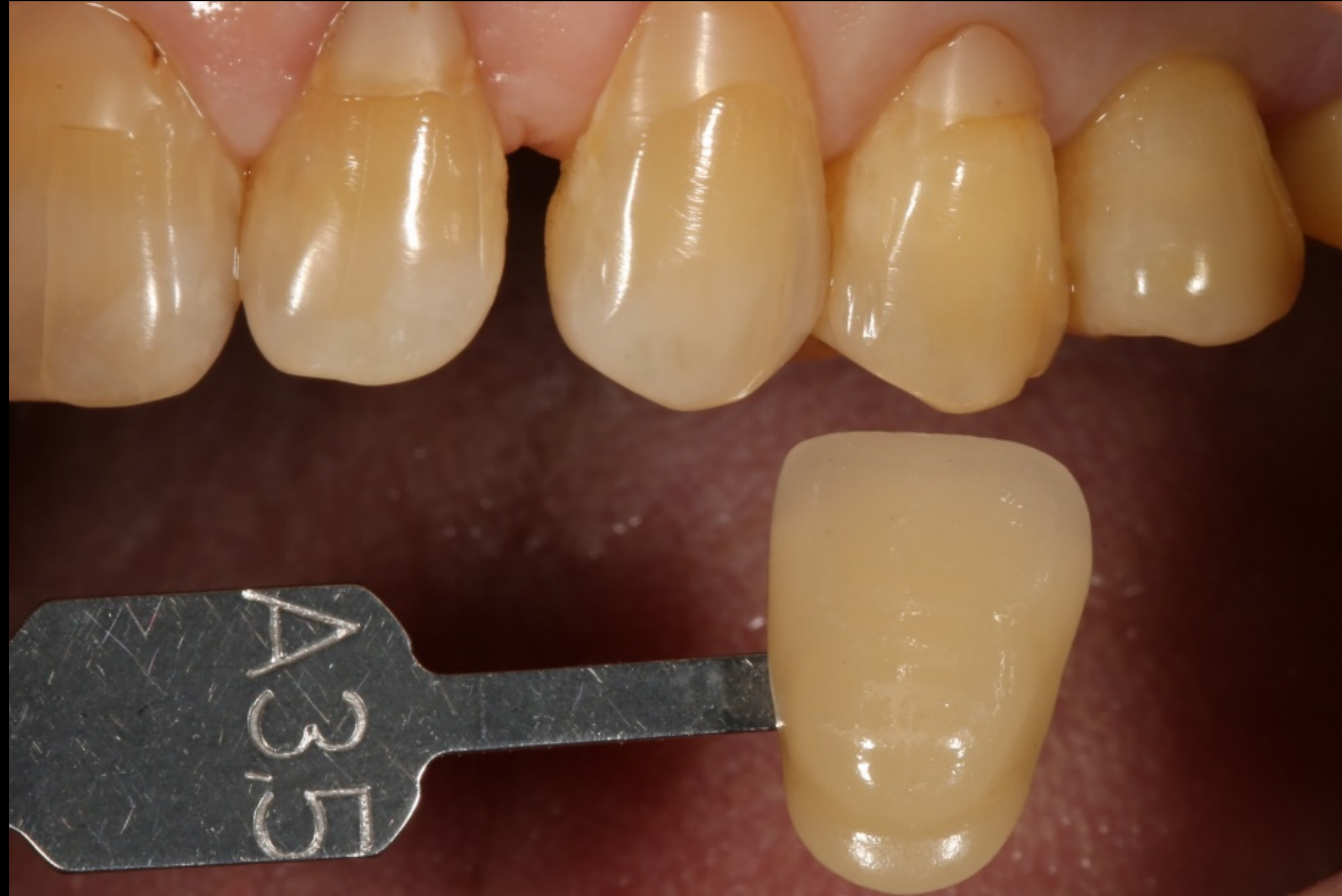

2h Fast Sinterng

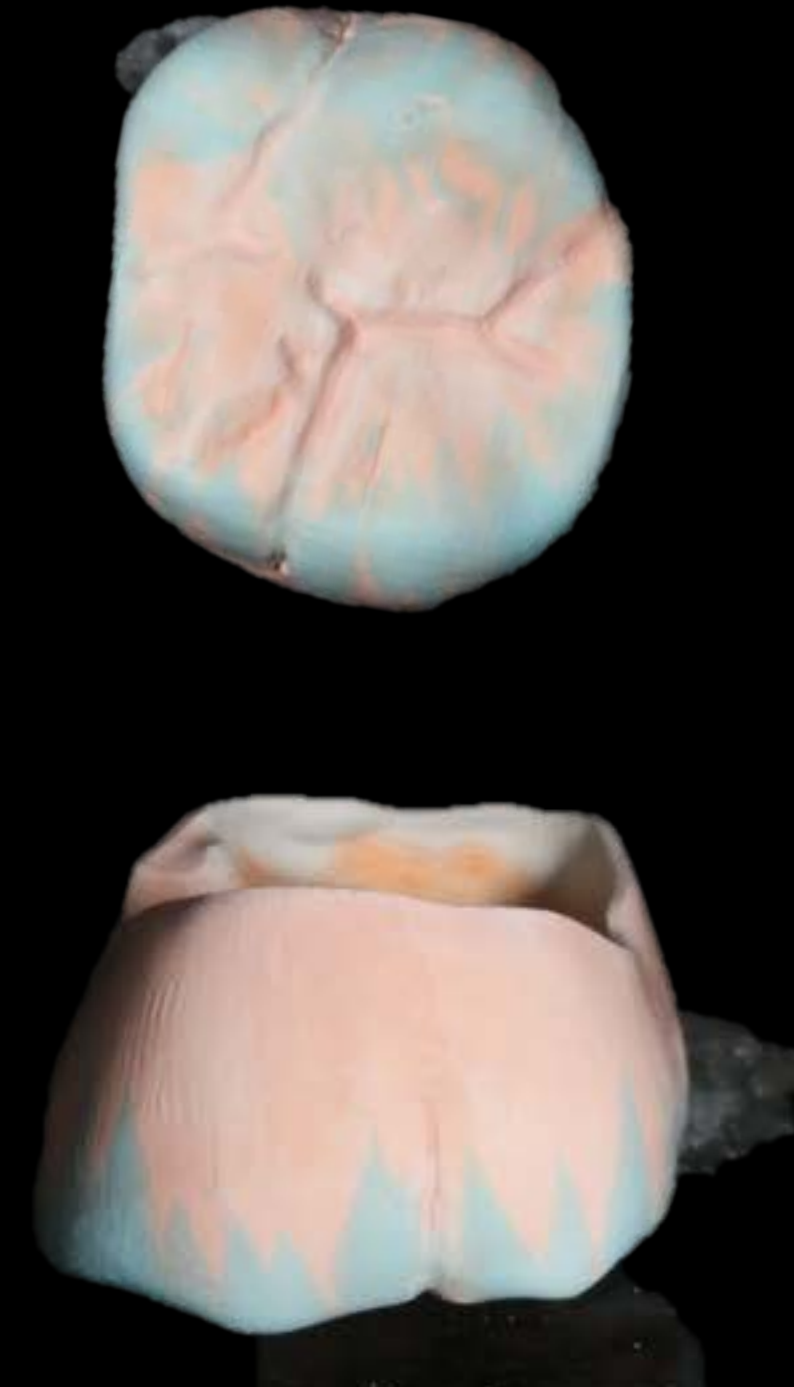
Natural tooth Case_3



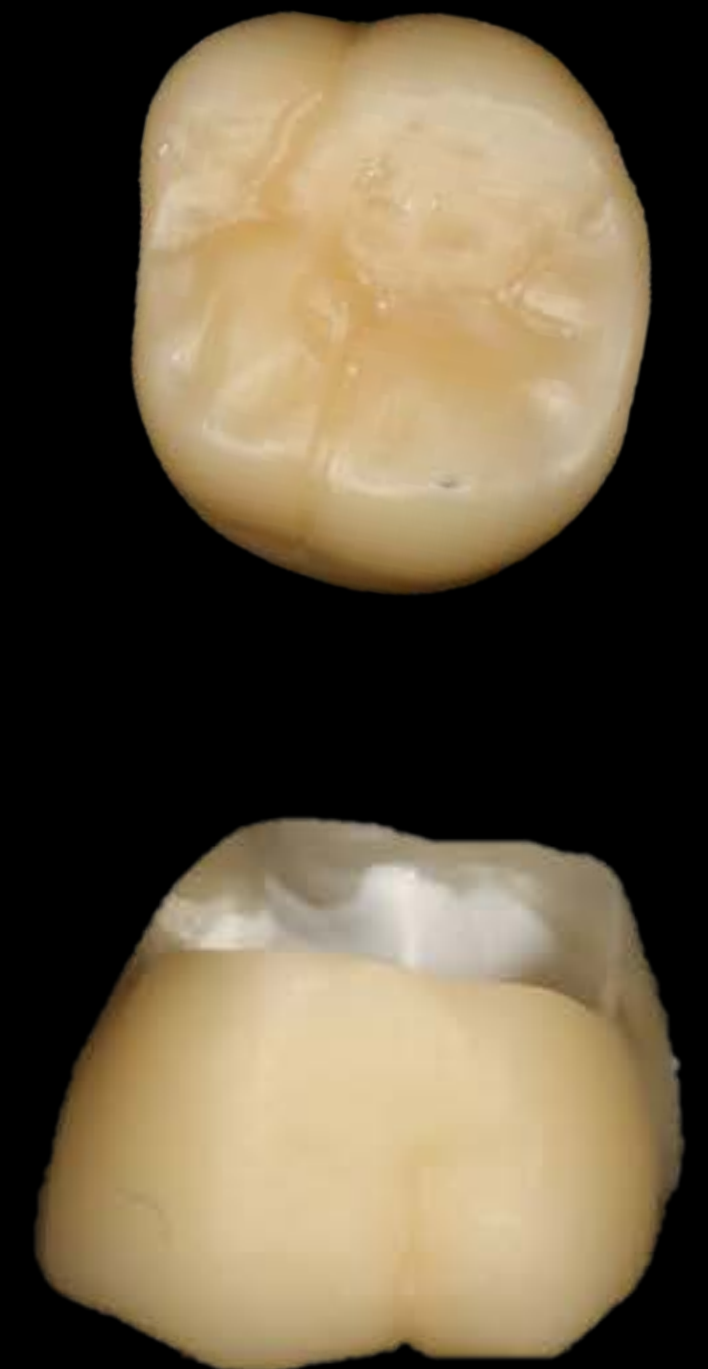Natural tooth Case_4



Shade Taking : A3

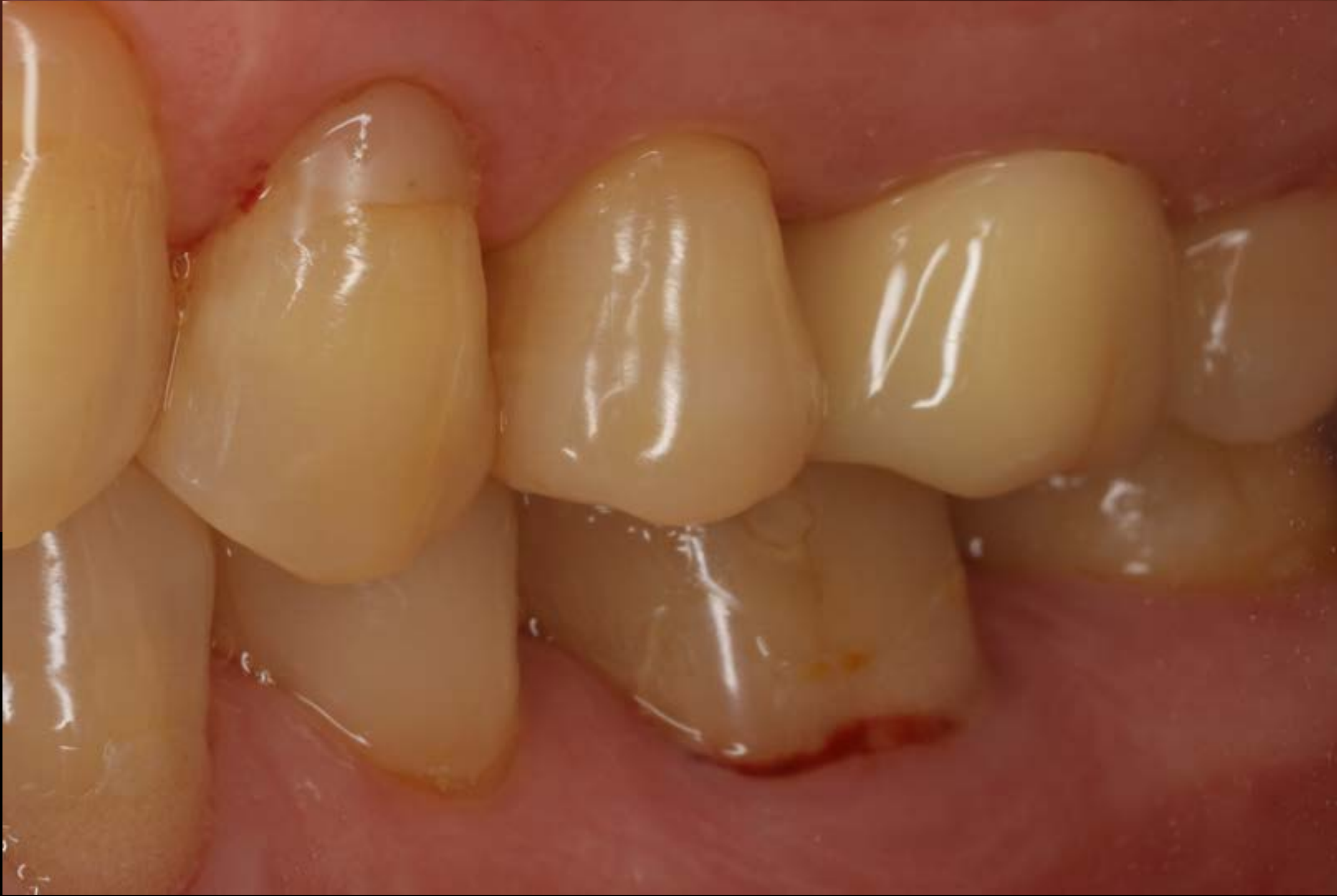
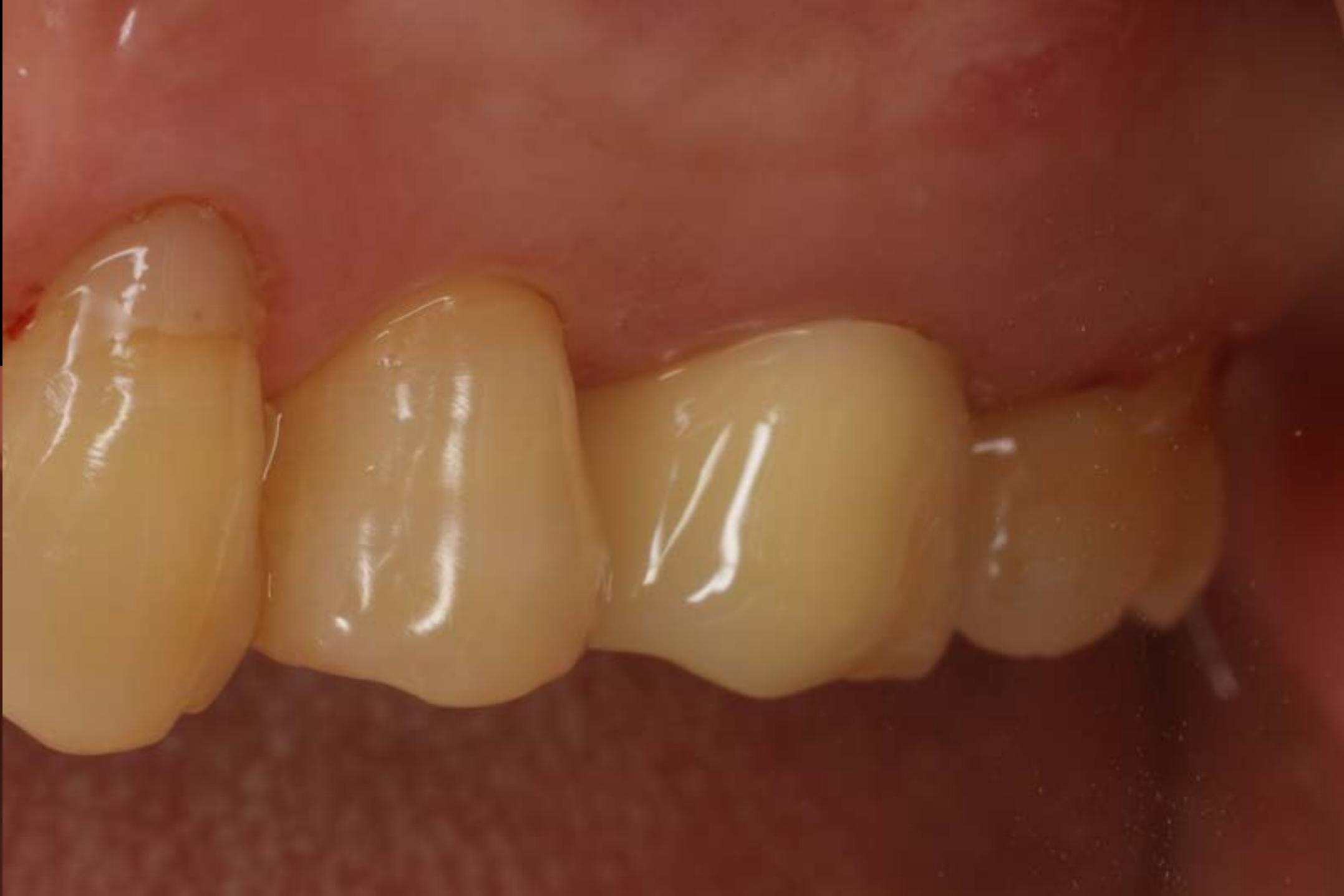
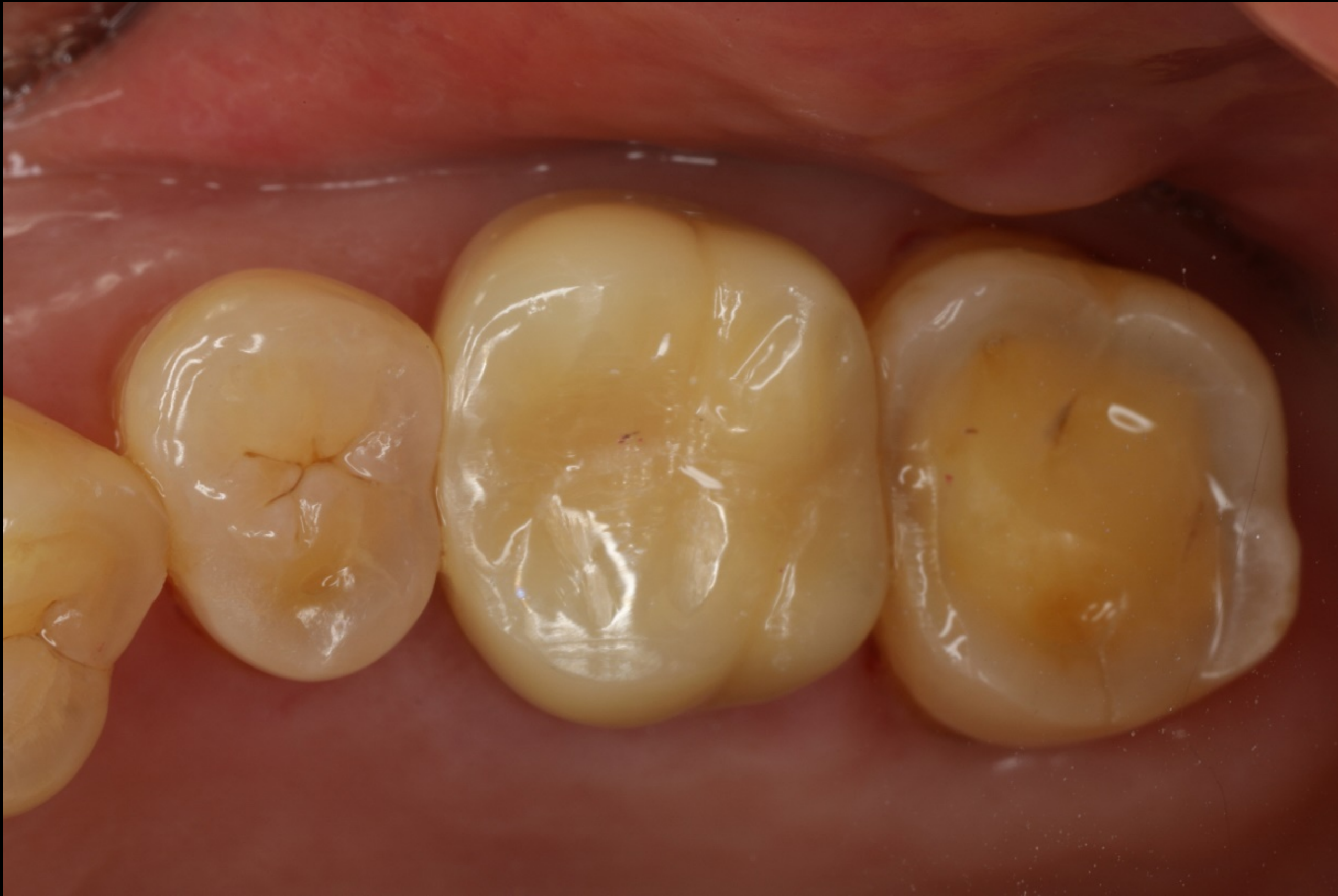Inner – White Opaque
Body – A3
Occlusal - Trans violet



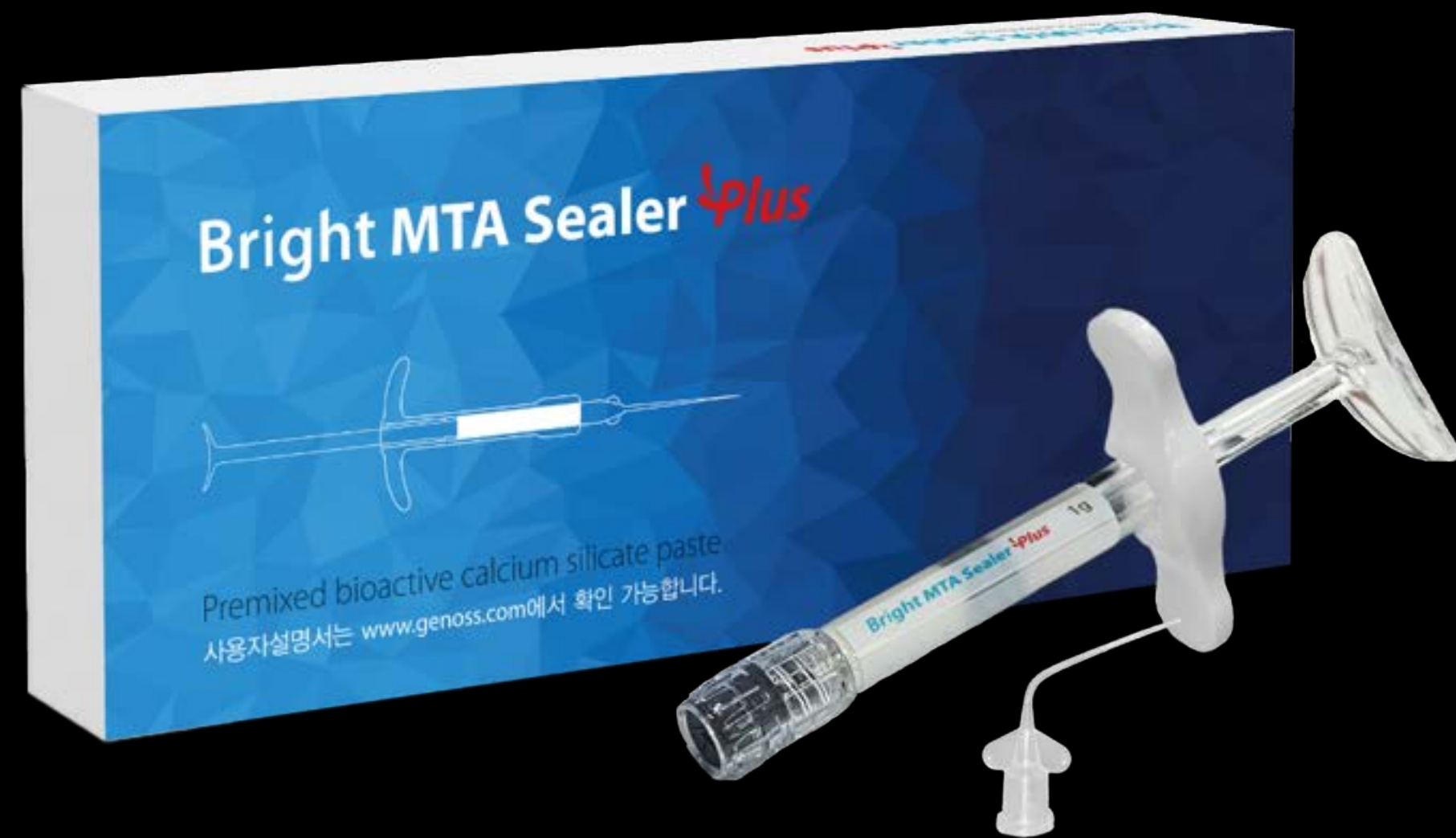2h Fast Sintering

Natural tooth Case_4



Bright MTA Sealer *Plus*

Root Canal Sealing Material



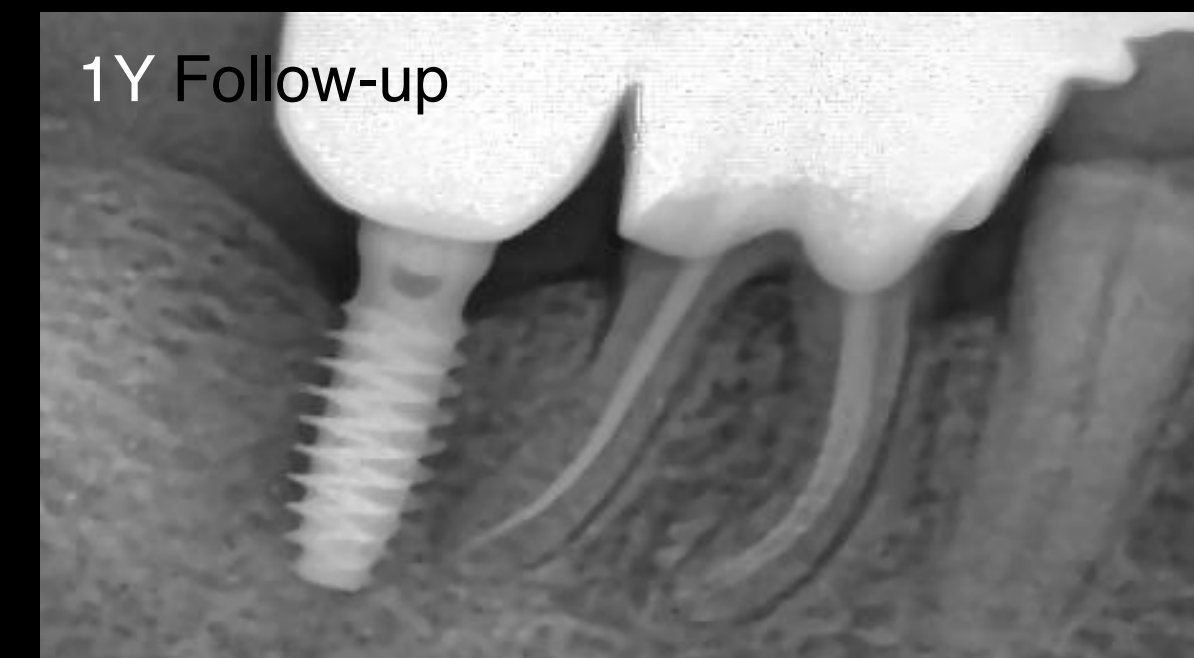
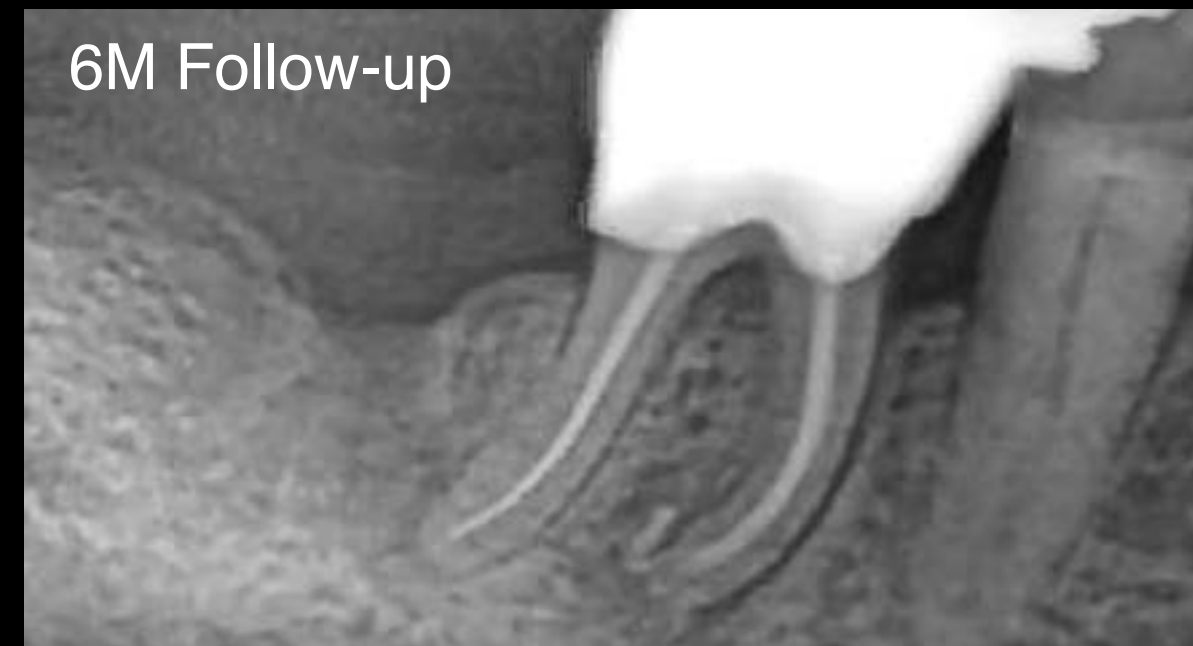
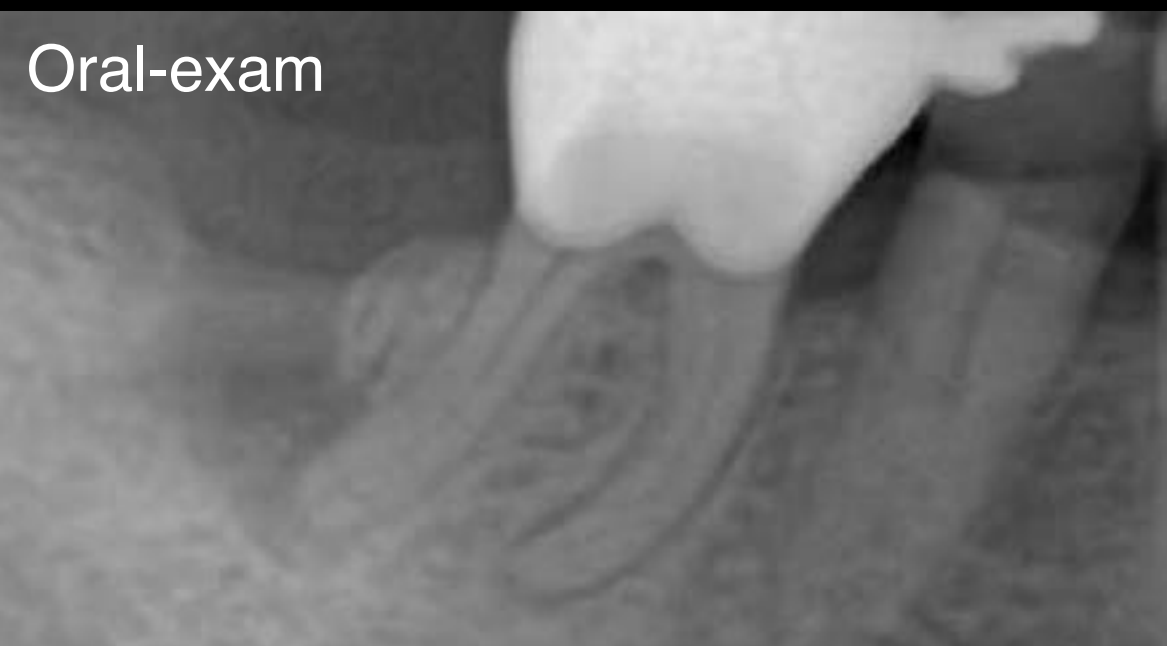
Excellent sealing and regeneration

Ultra Antibacterial Effect

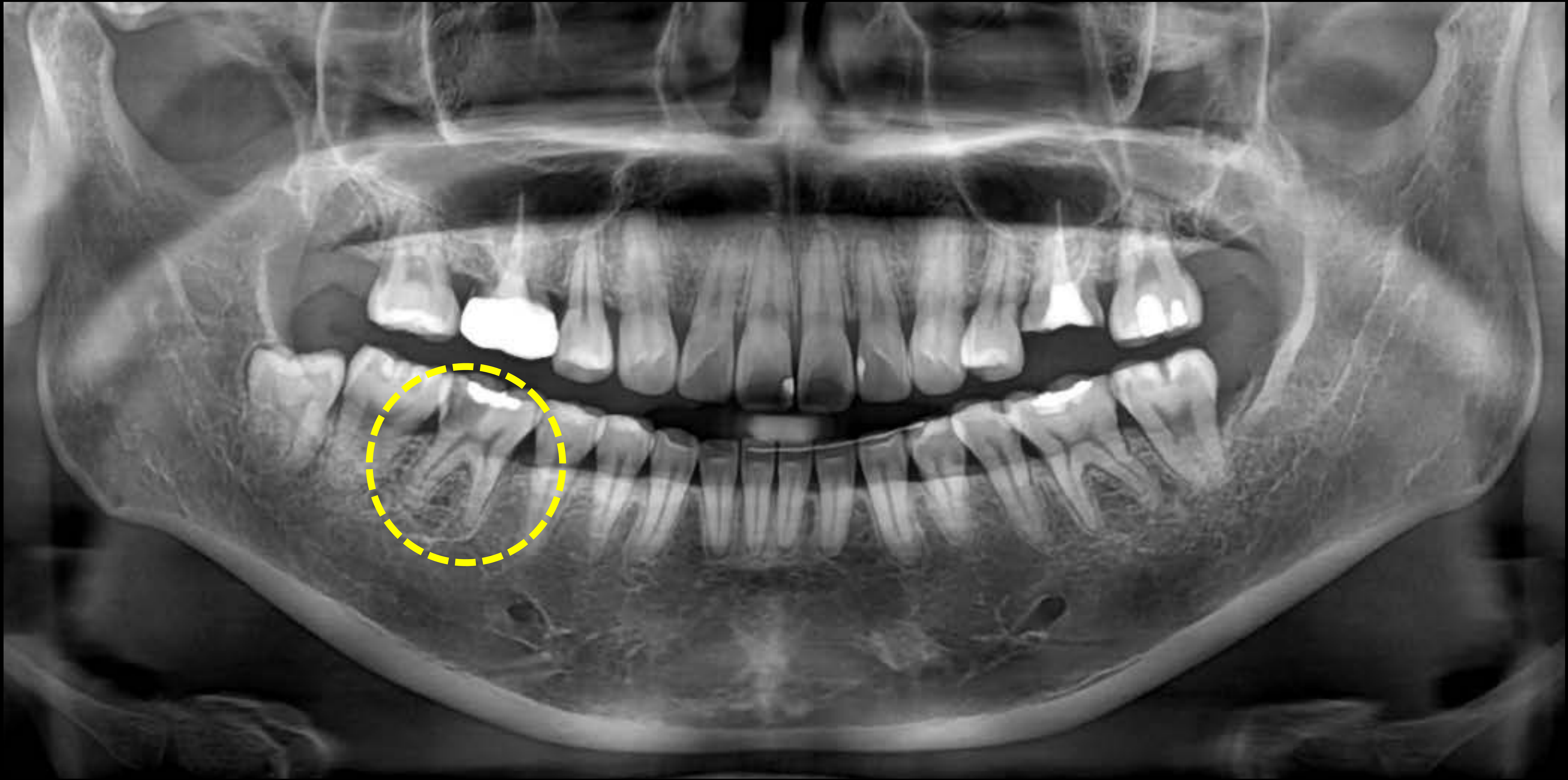
Calcium Silicate → Mineralization

High Flowability → Convenience Handling

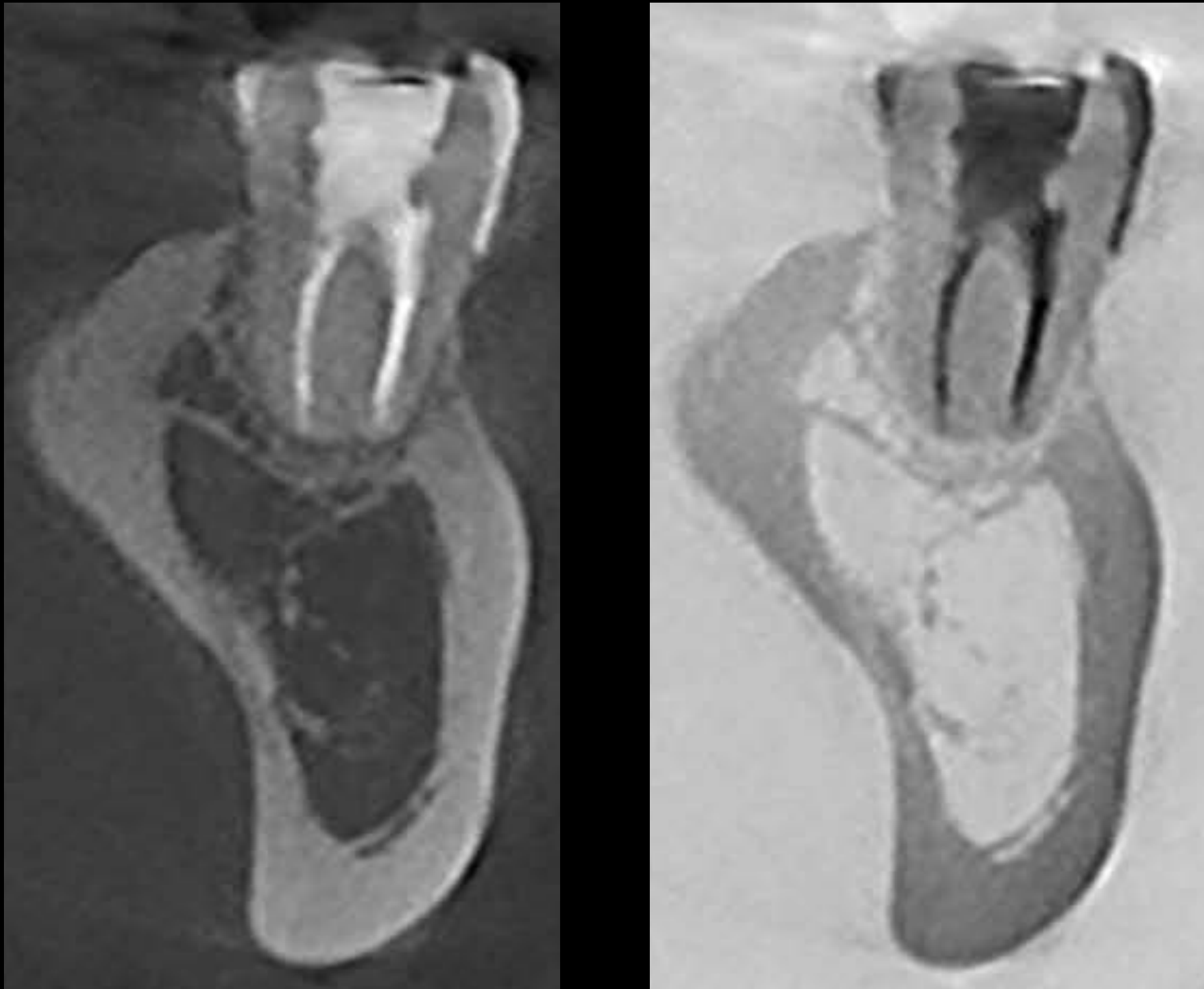
Excellent Radiopaque



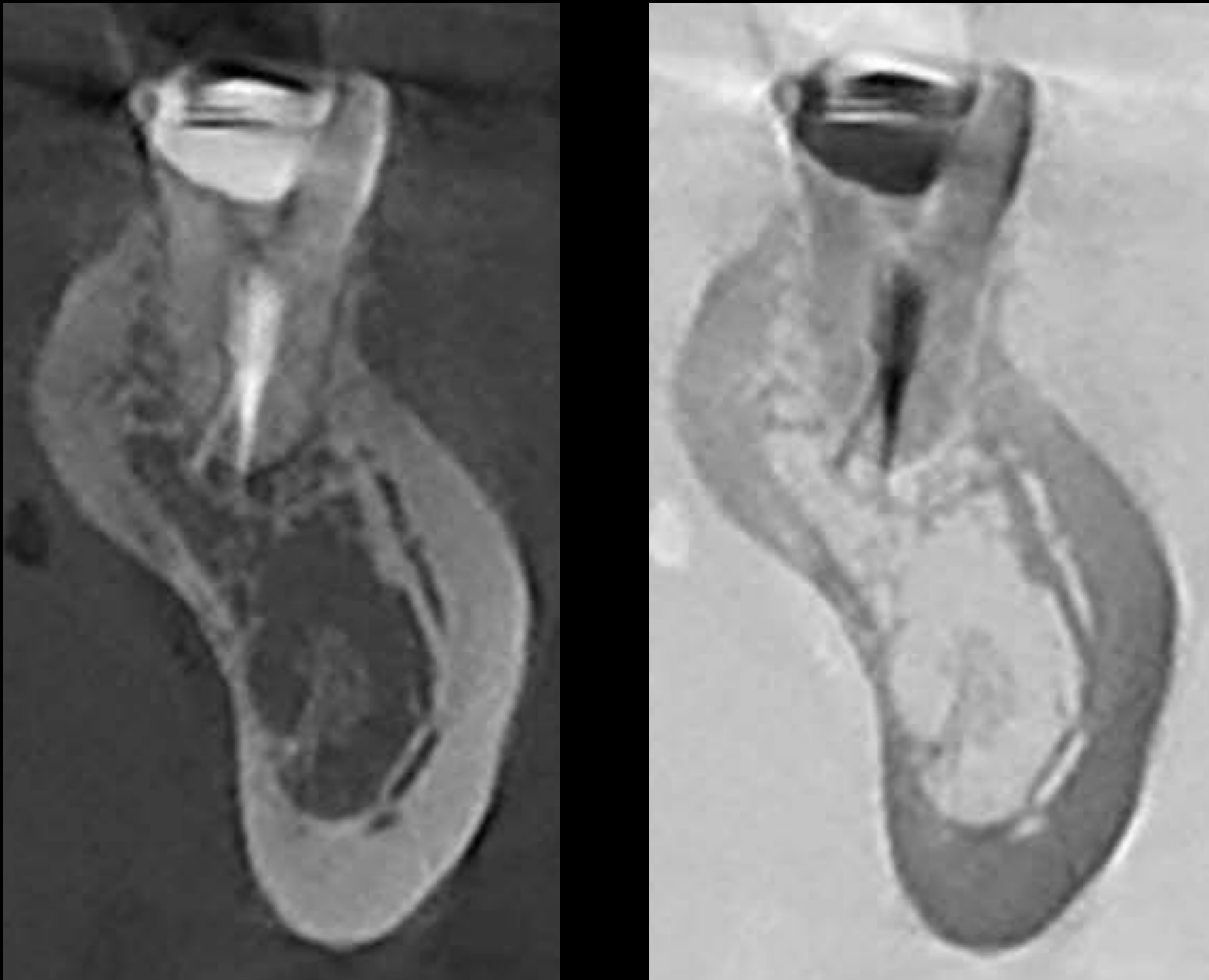
Oral exam (2023-11-18)



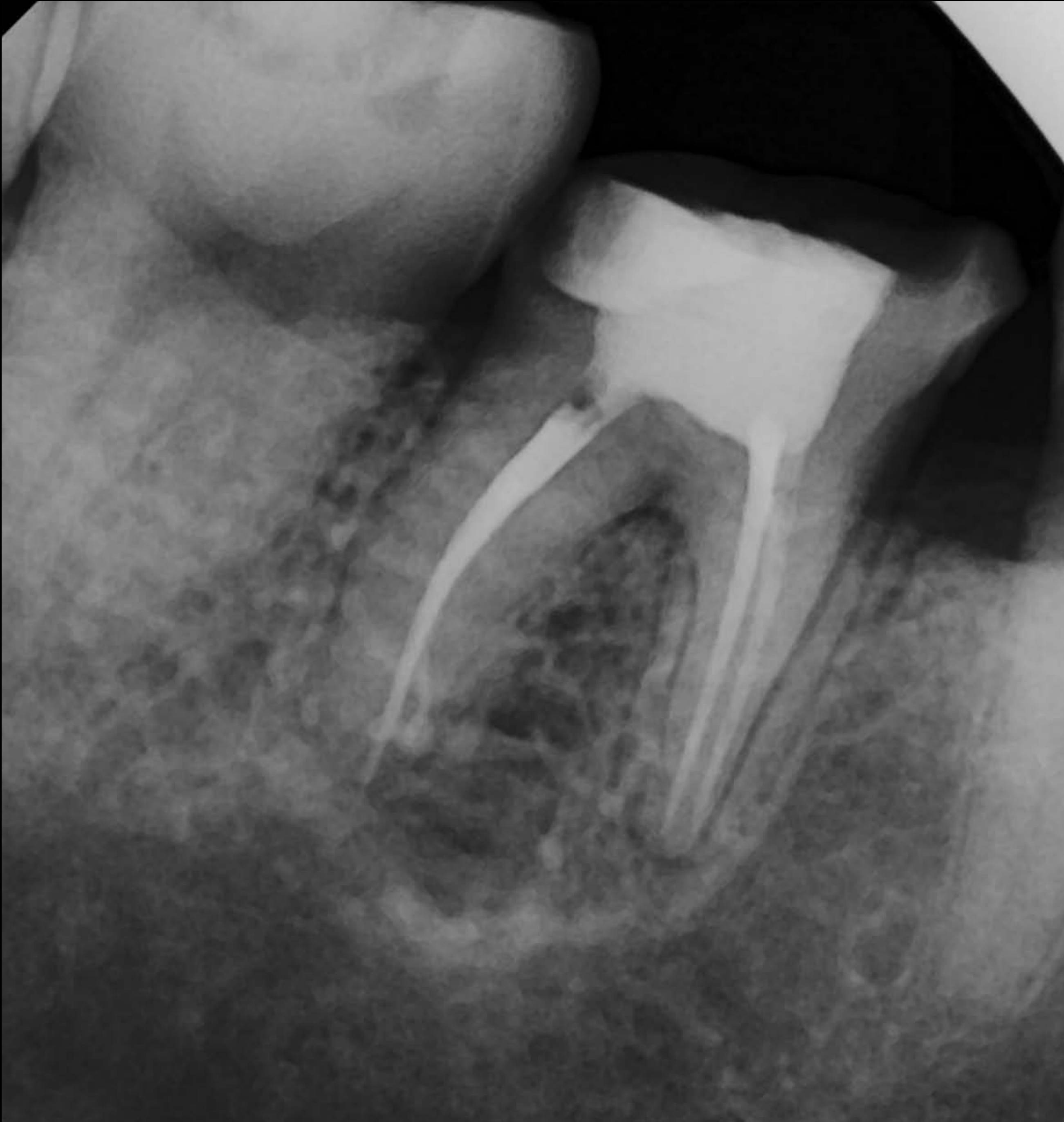
< Mesial canal >



< Distal canal >

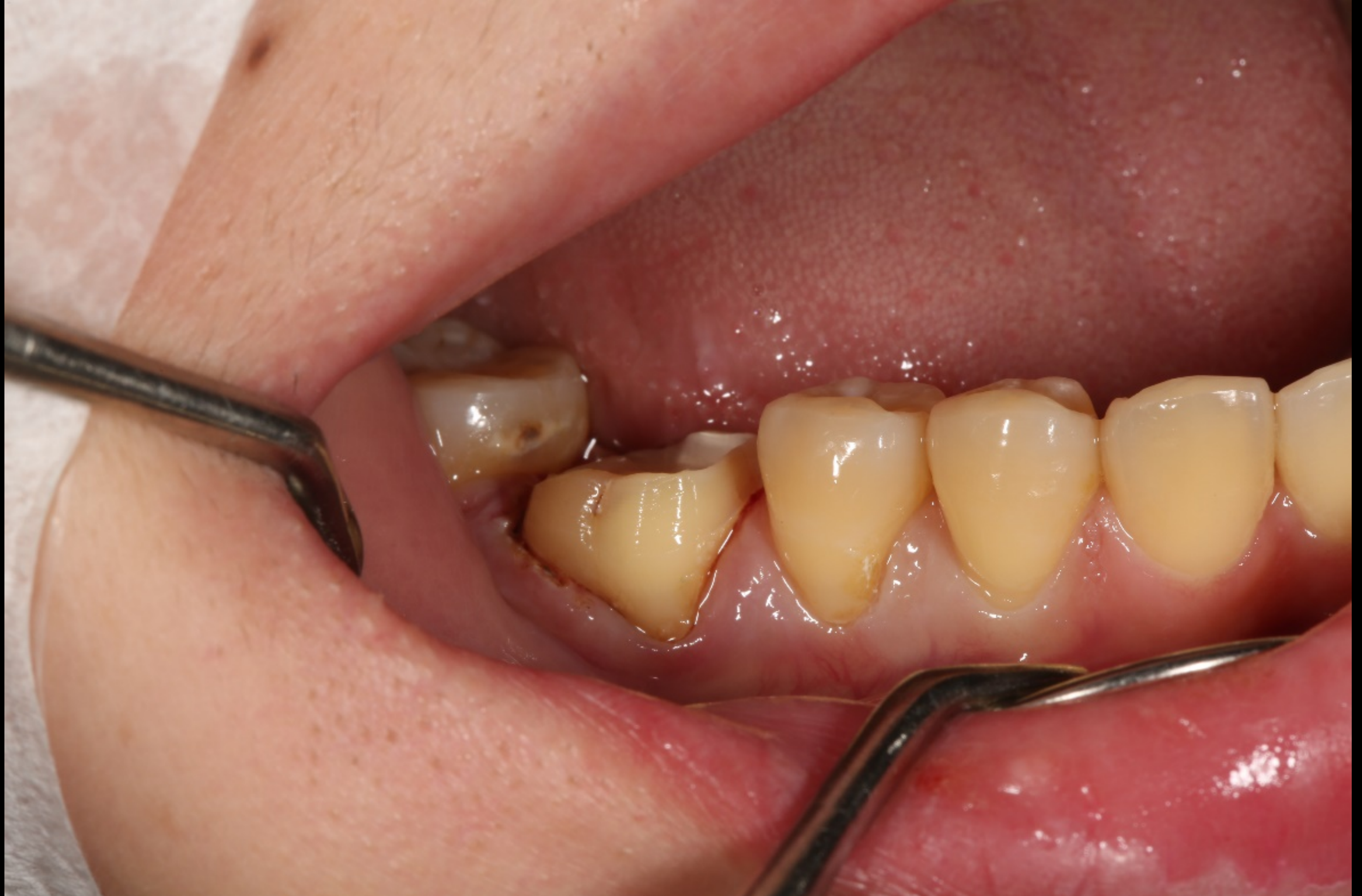

Follow up : 7 week (2024-03-27)

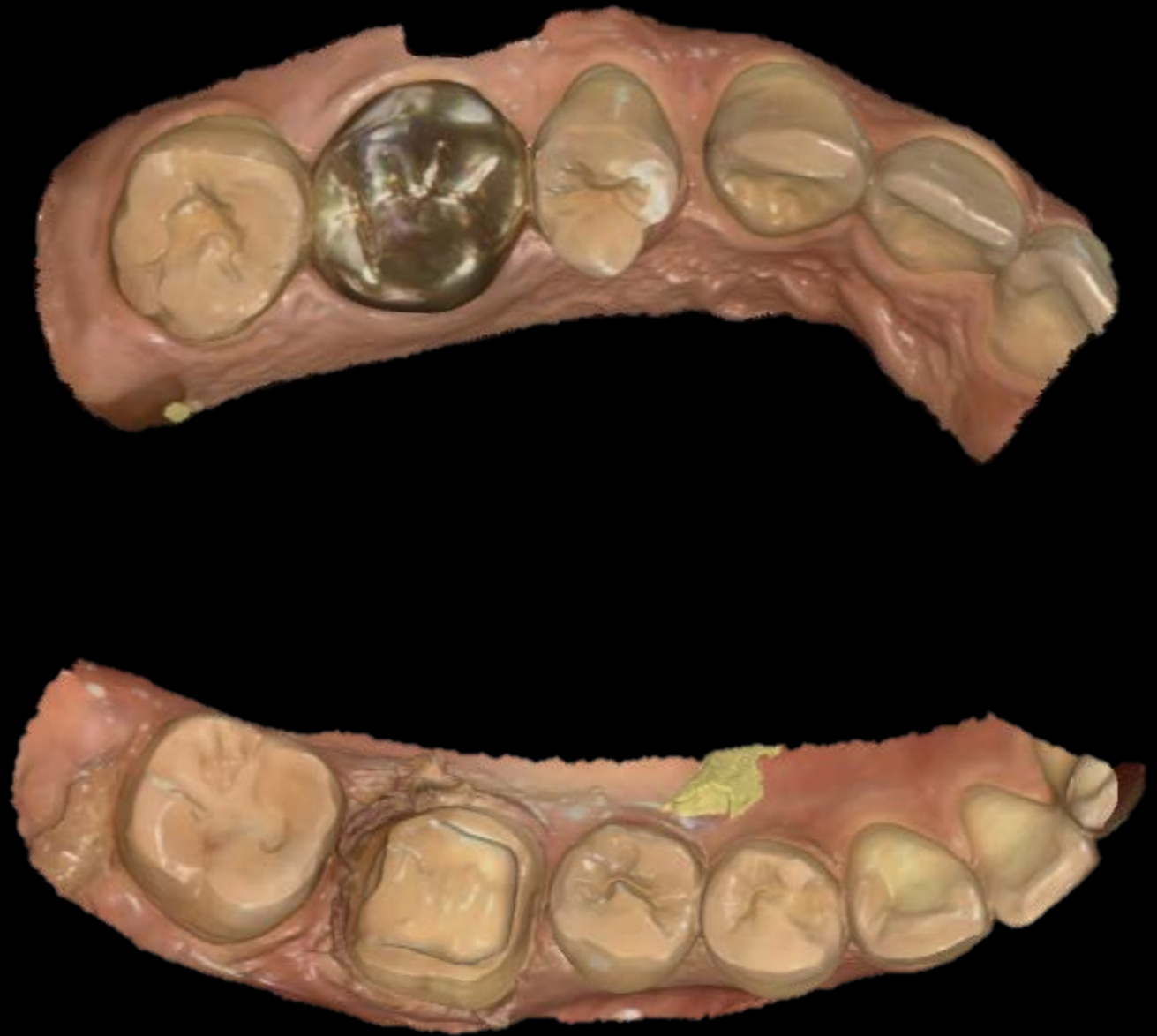
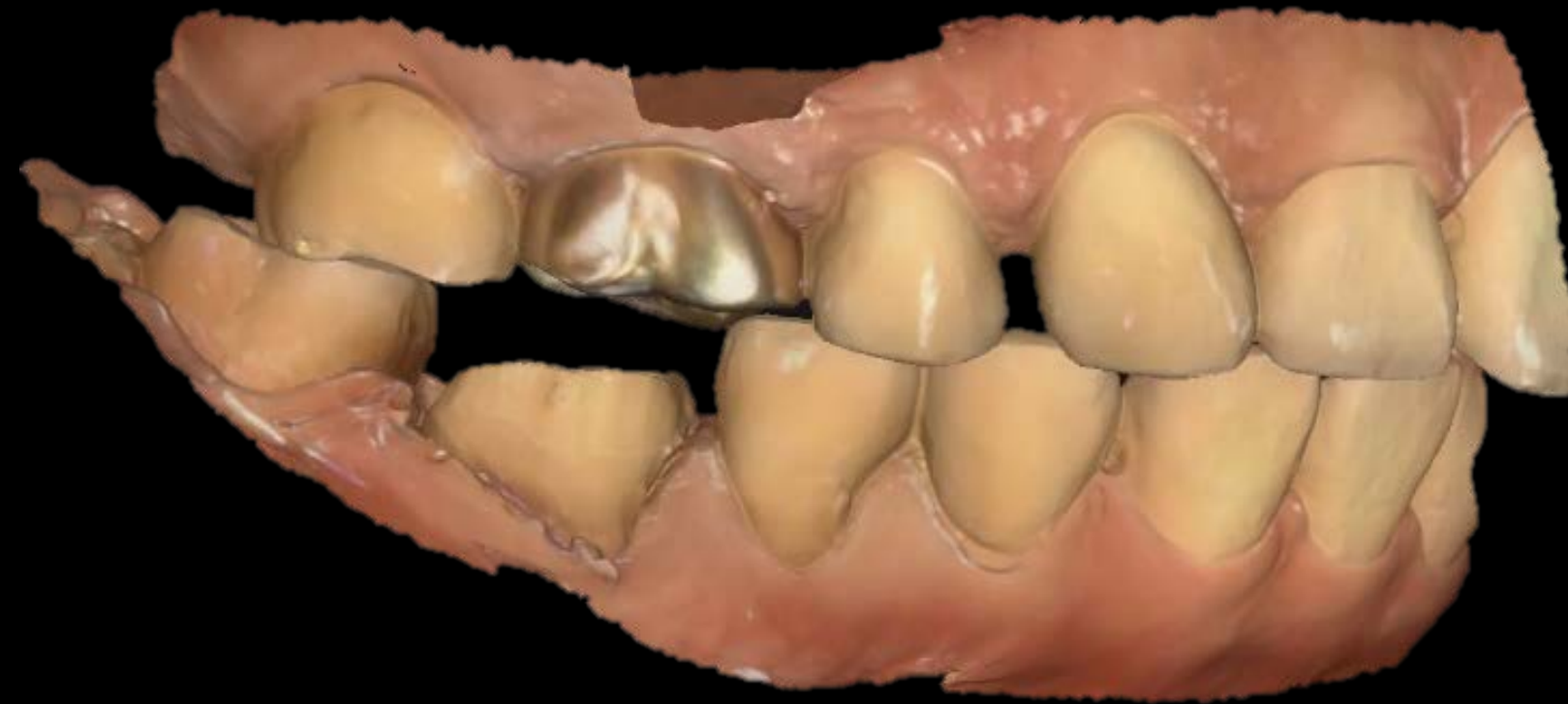
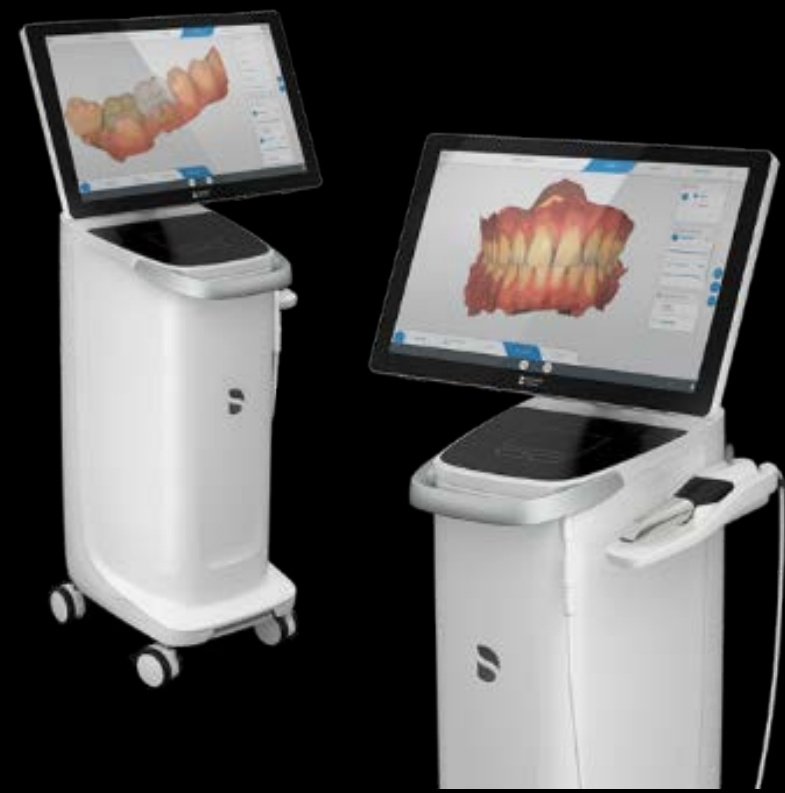Case 2

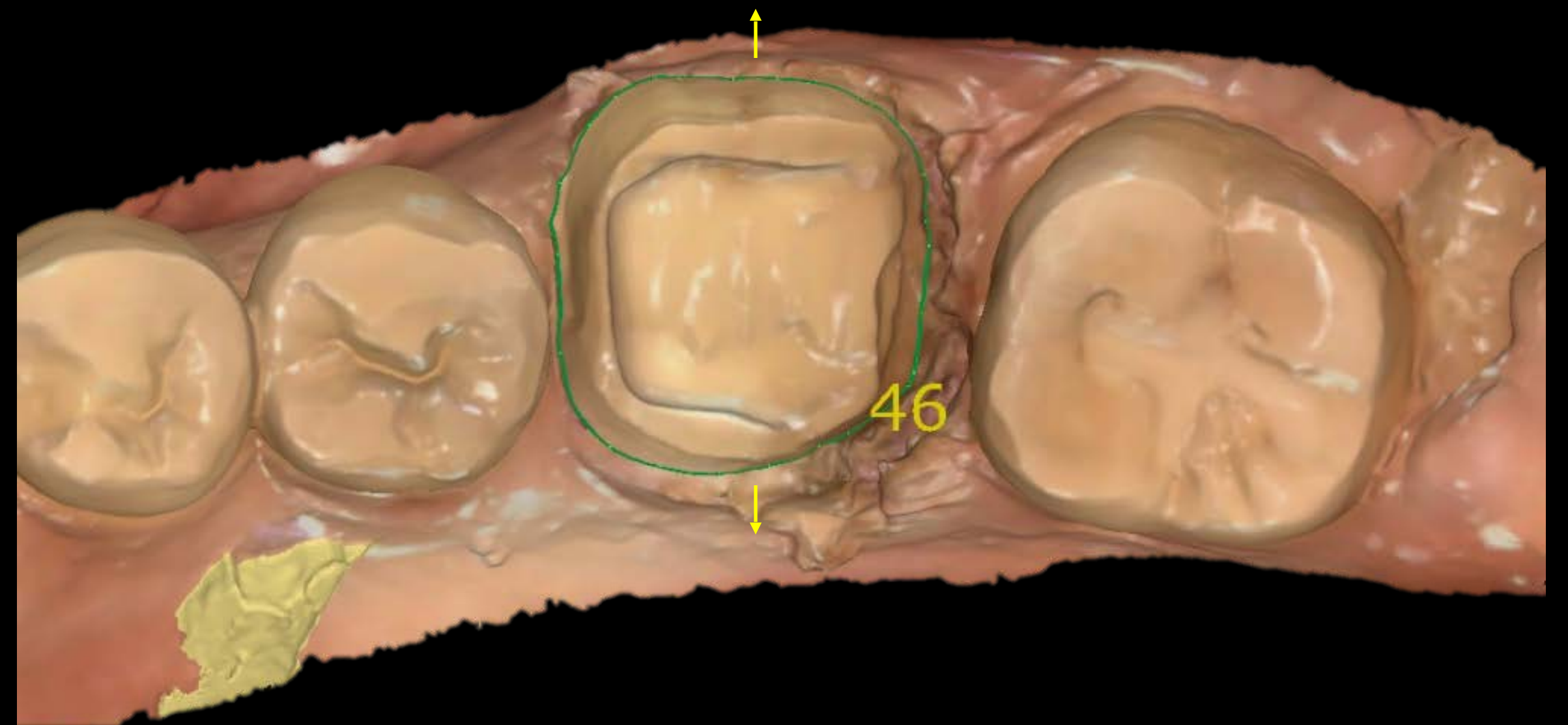
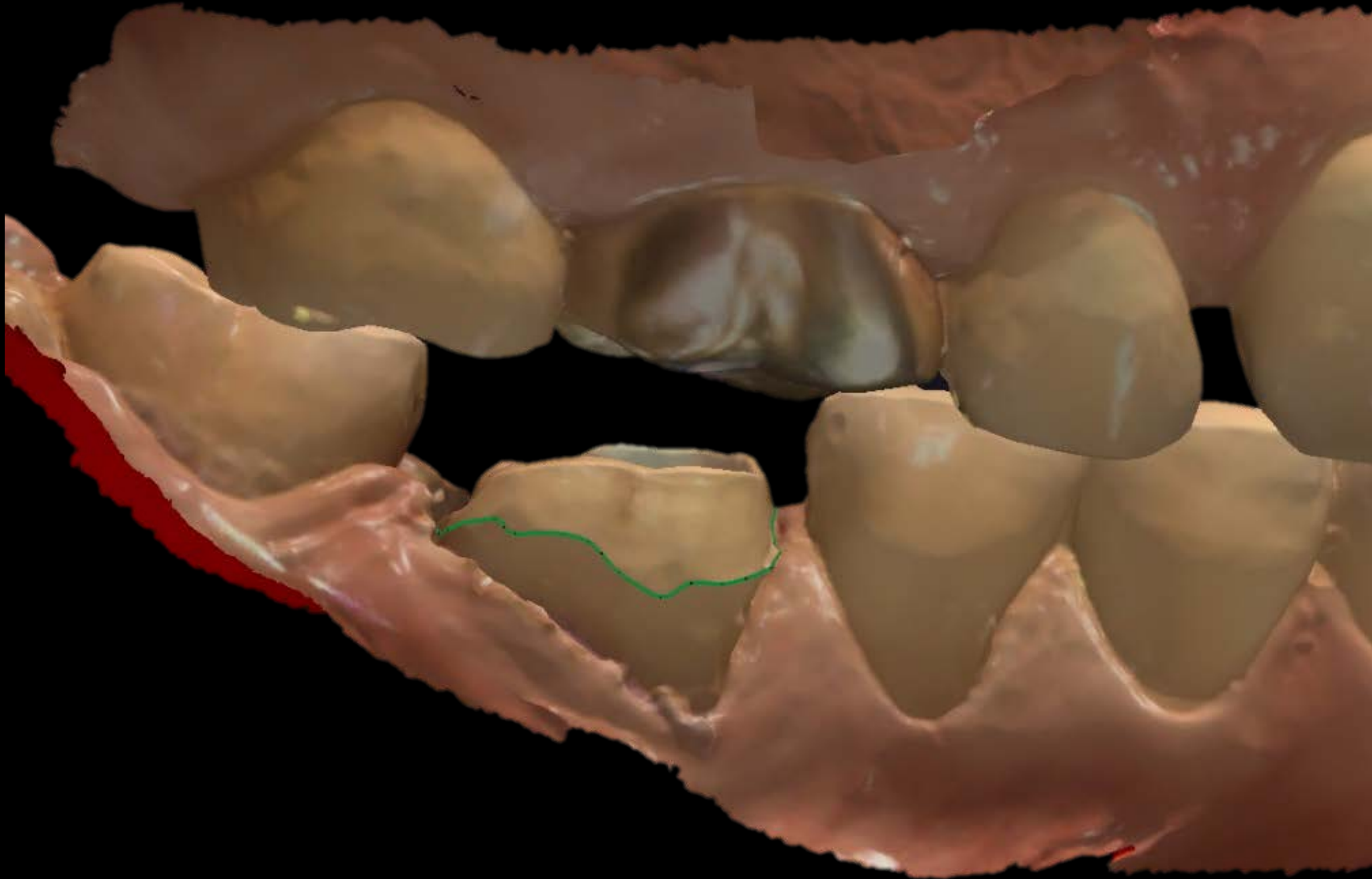
- #46
- Natural Tooth
- Shade A3.5
- Shade Block



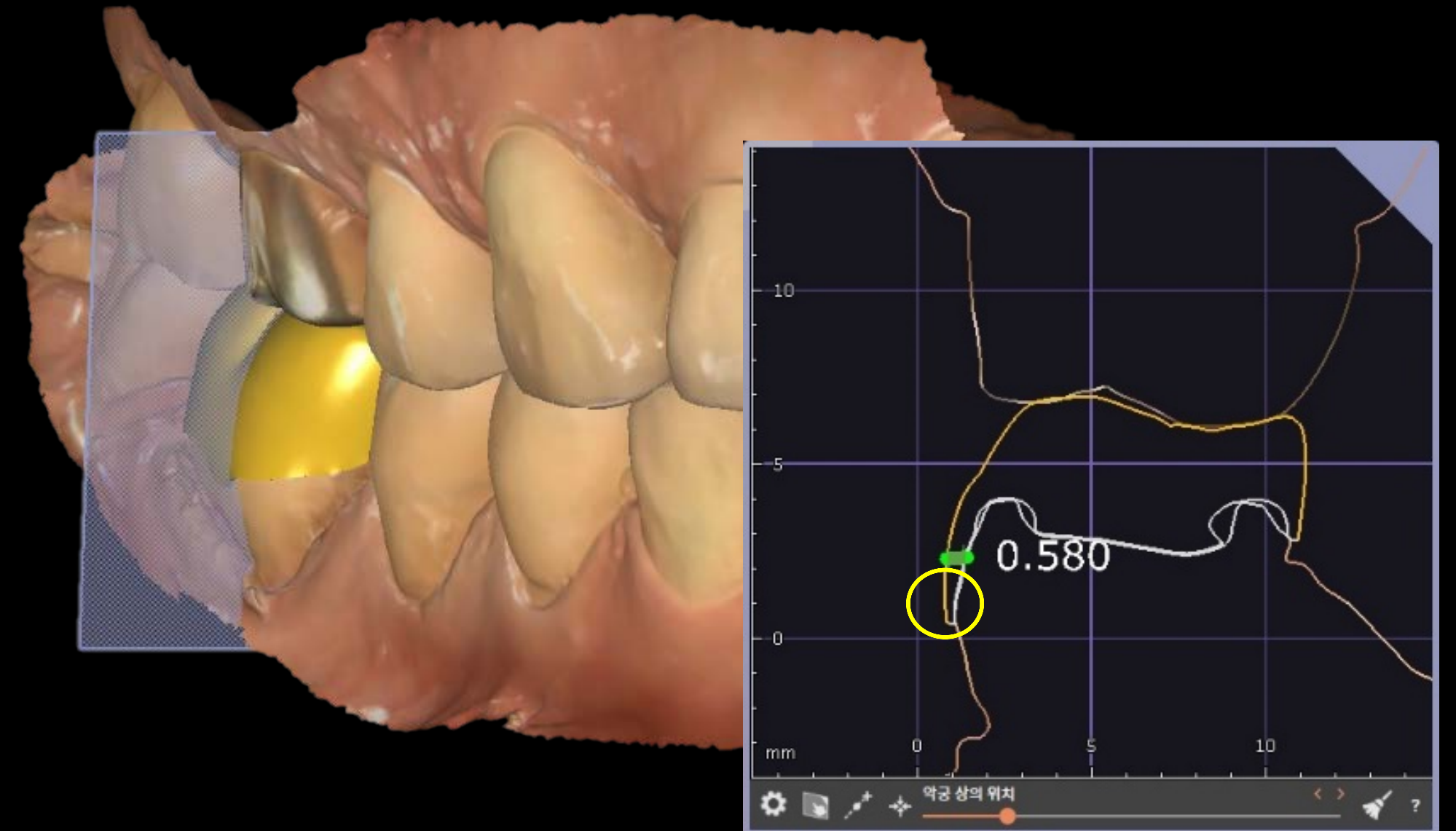
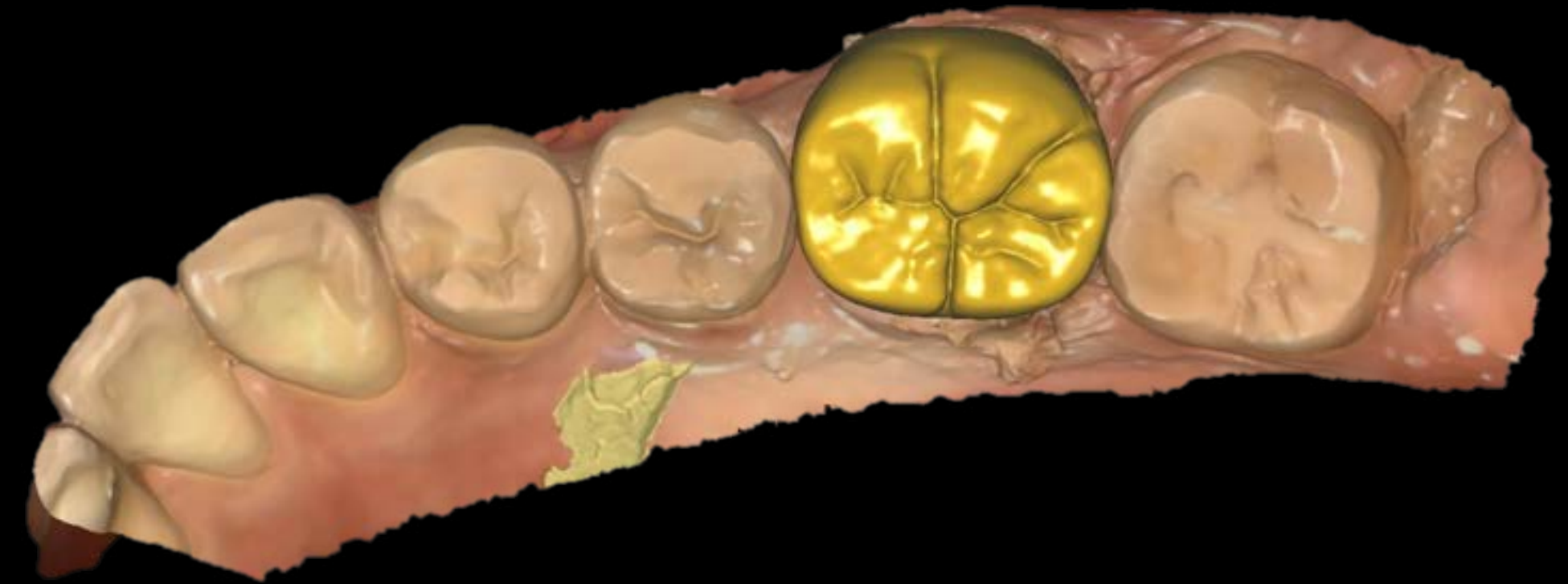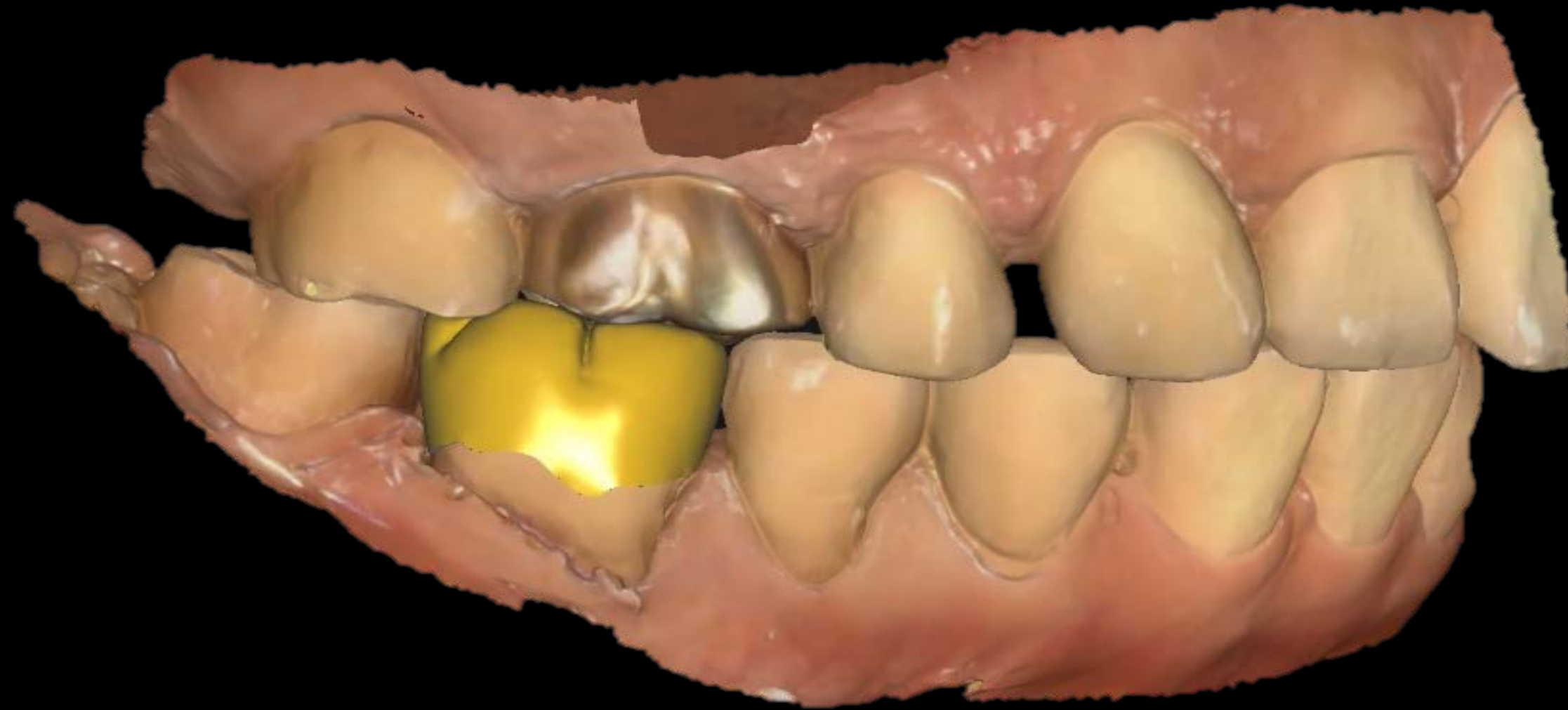
Working model



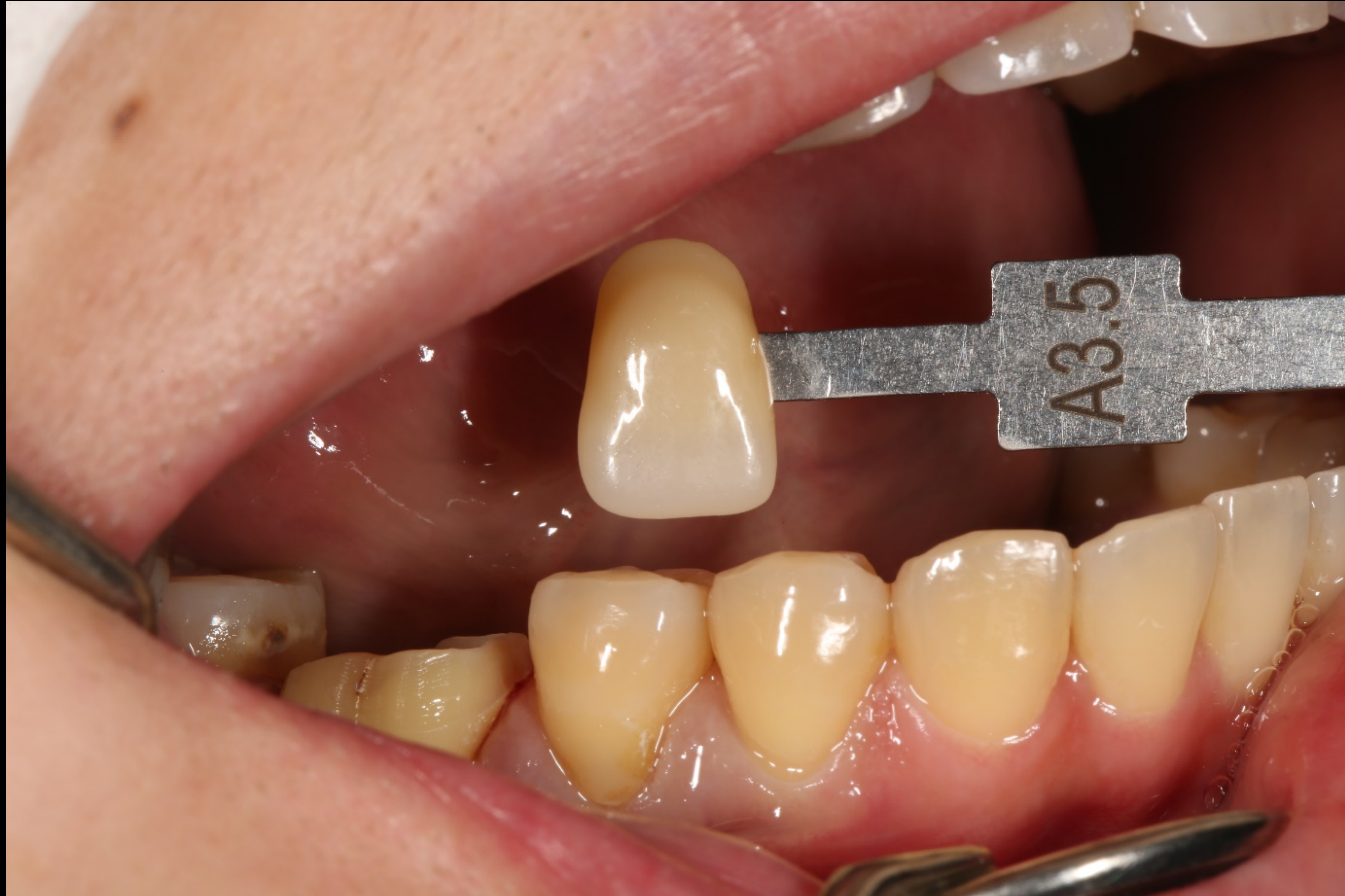Working Model



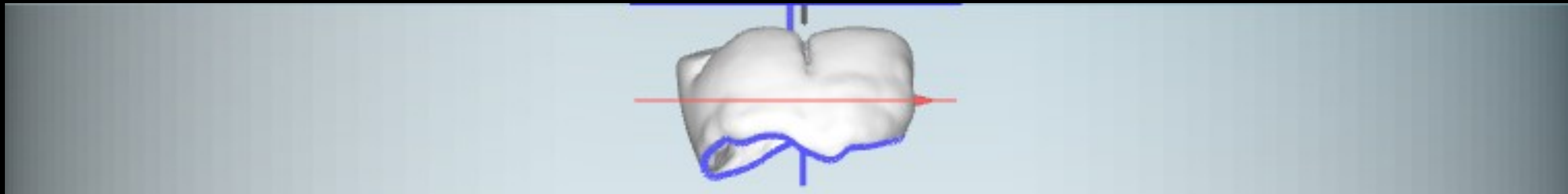
Cad Design



Shade Taking

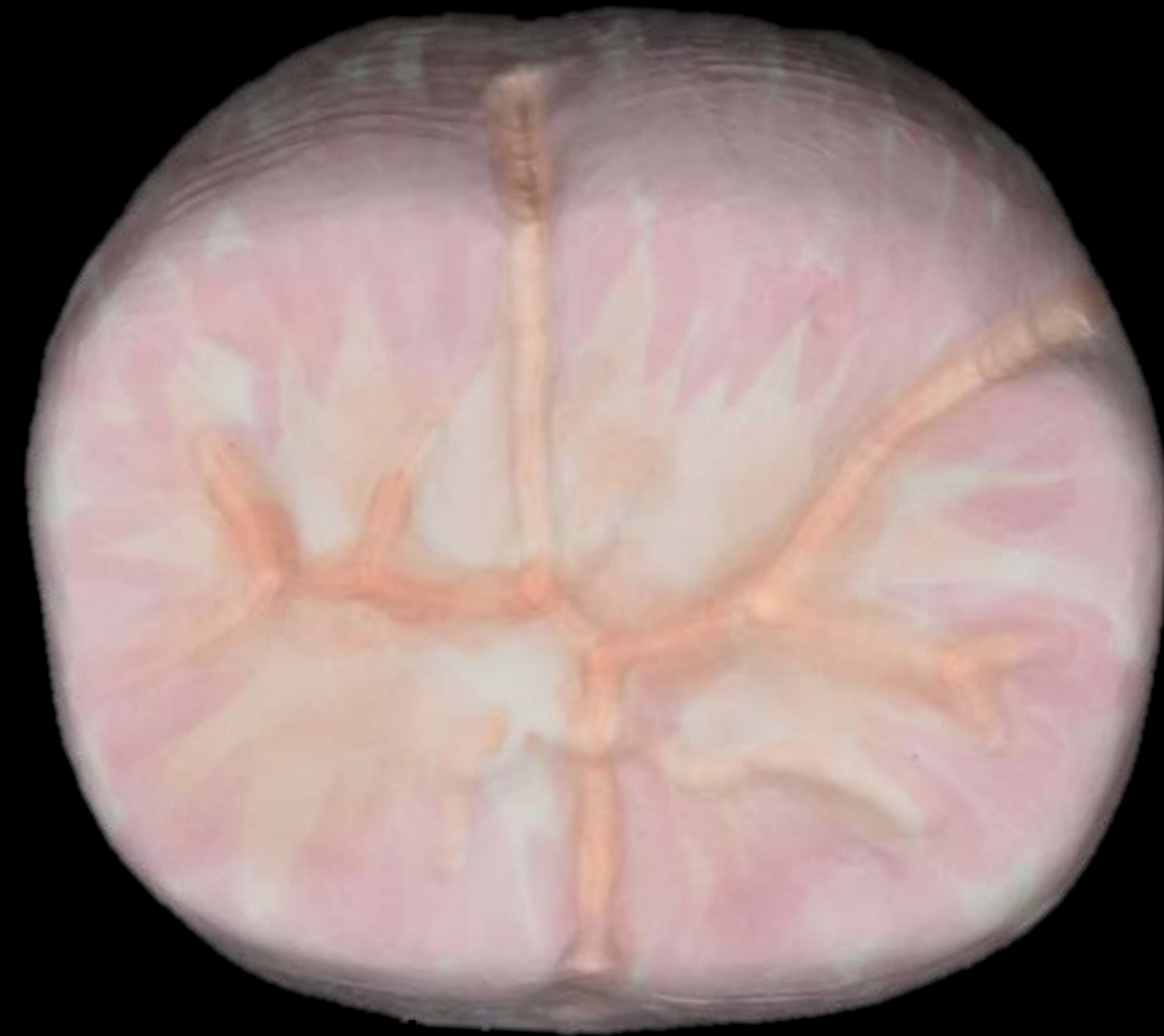
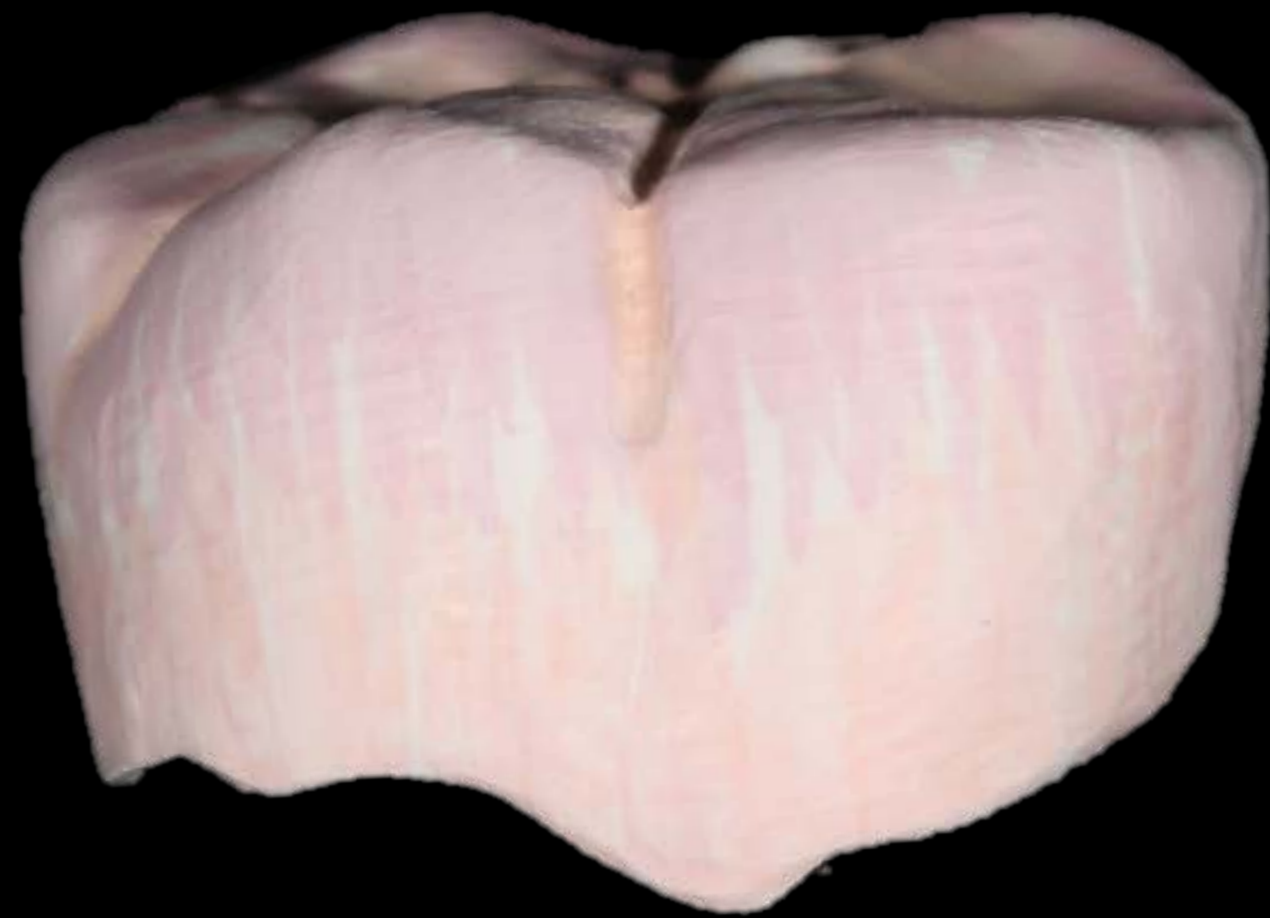
Hyper Dent



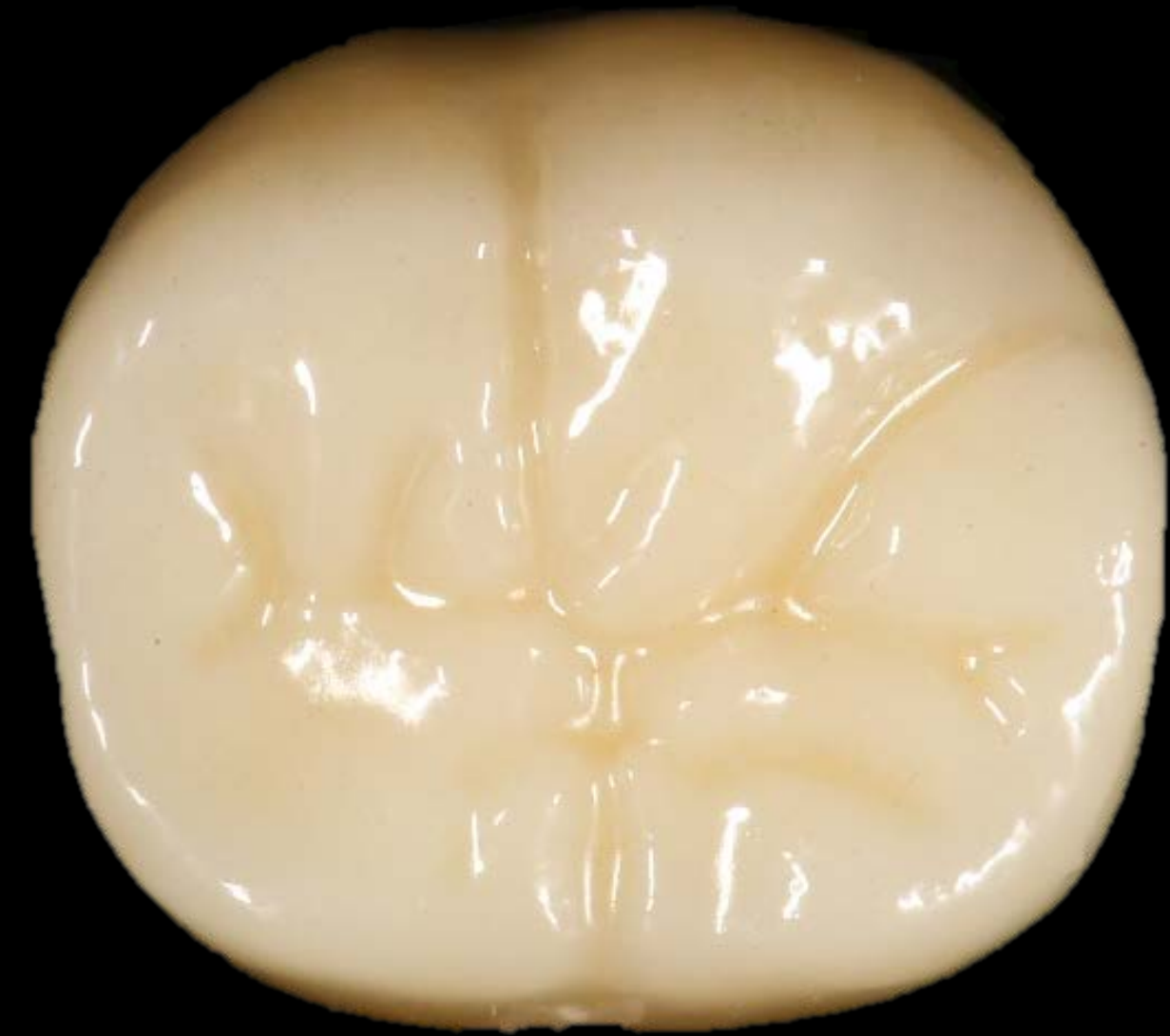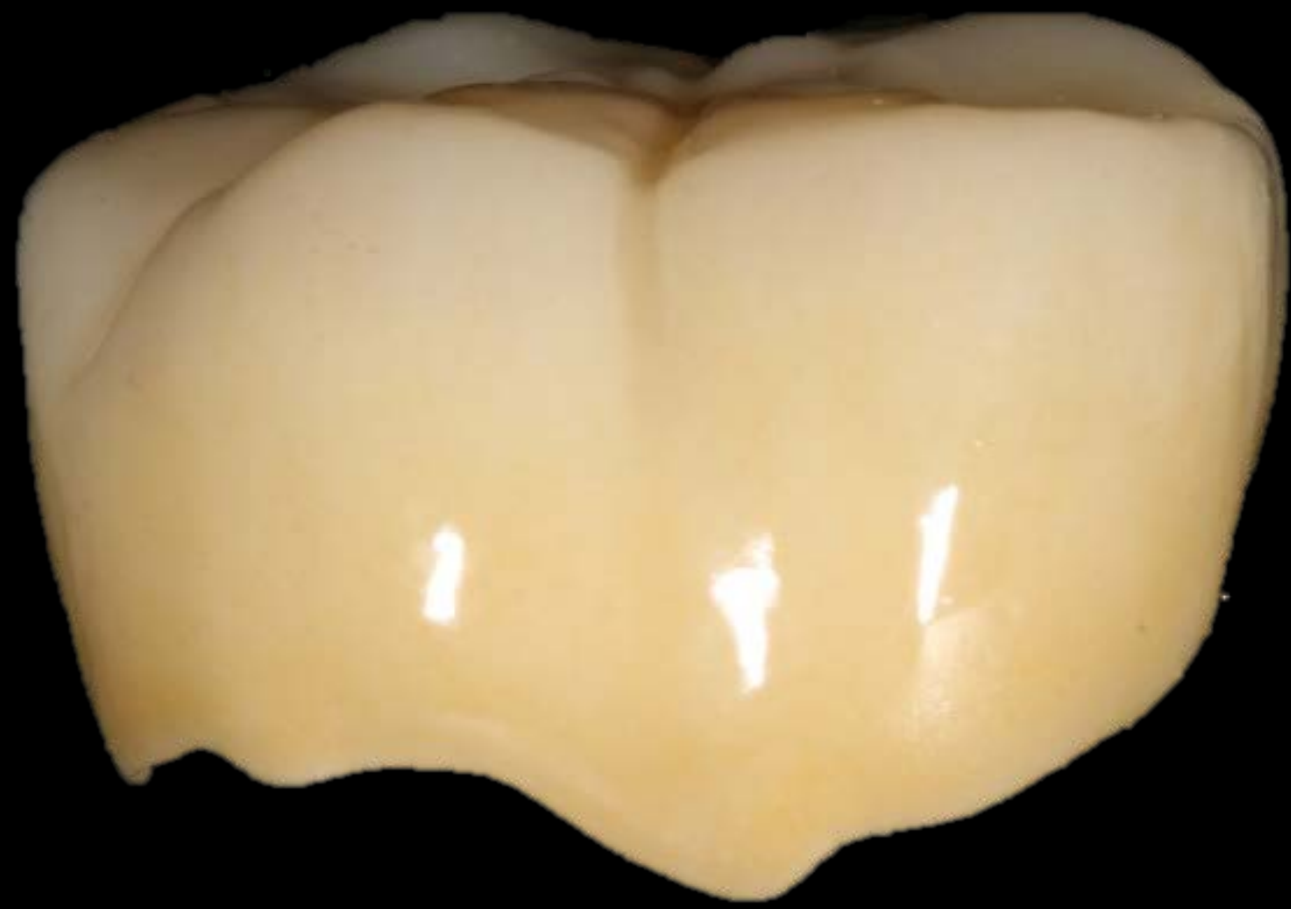Shade Block A2

Coloring

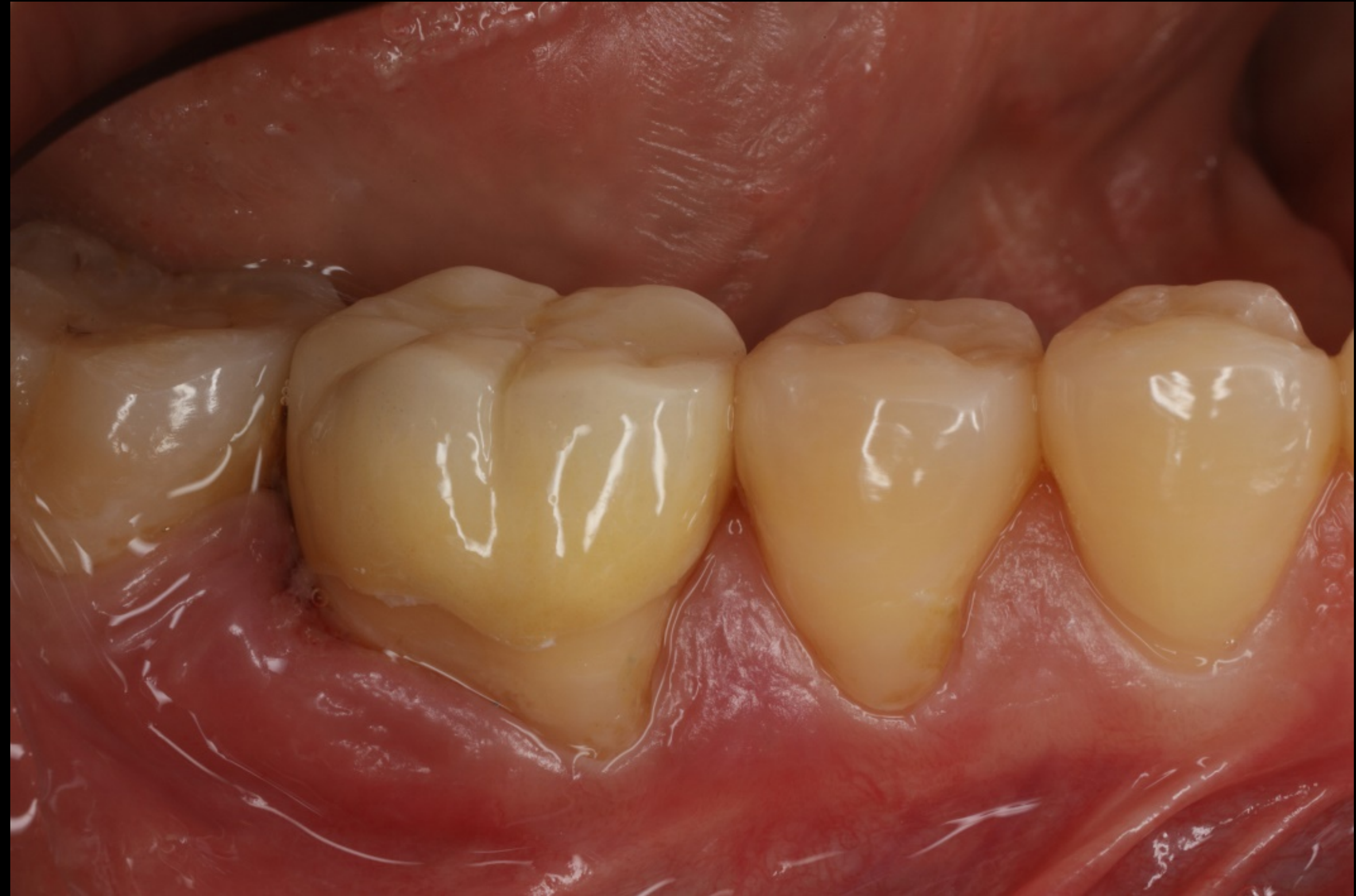
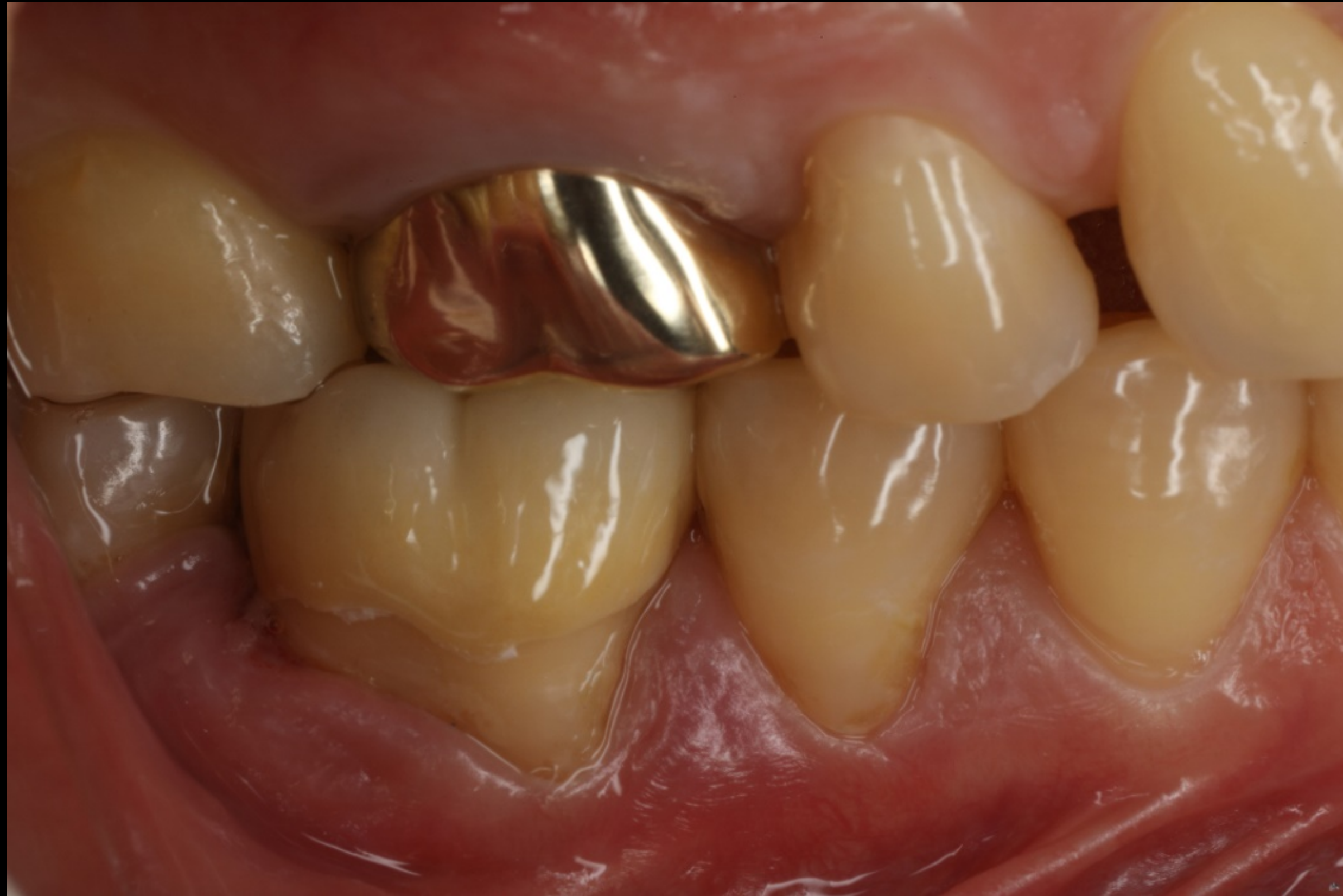
Inner – White Opaque
Cervical, Groove – A3.5
Occlusal – Light Gray

Glazing



Final Prosthesis



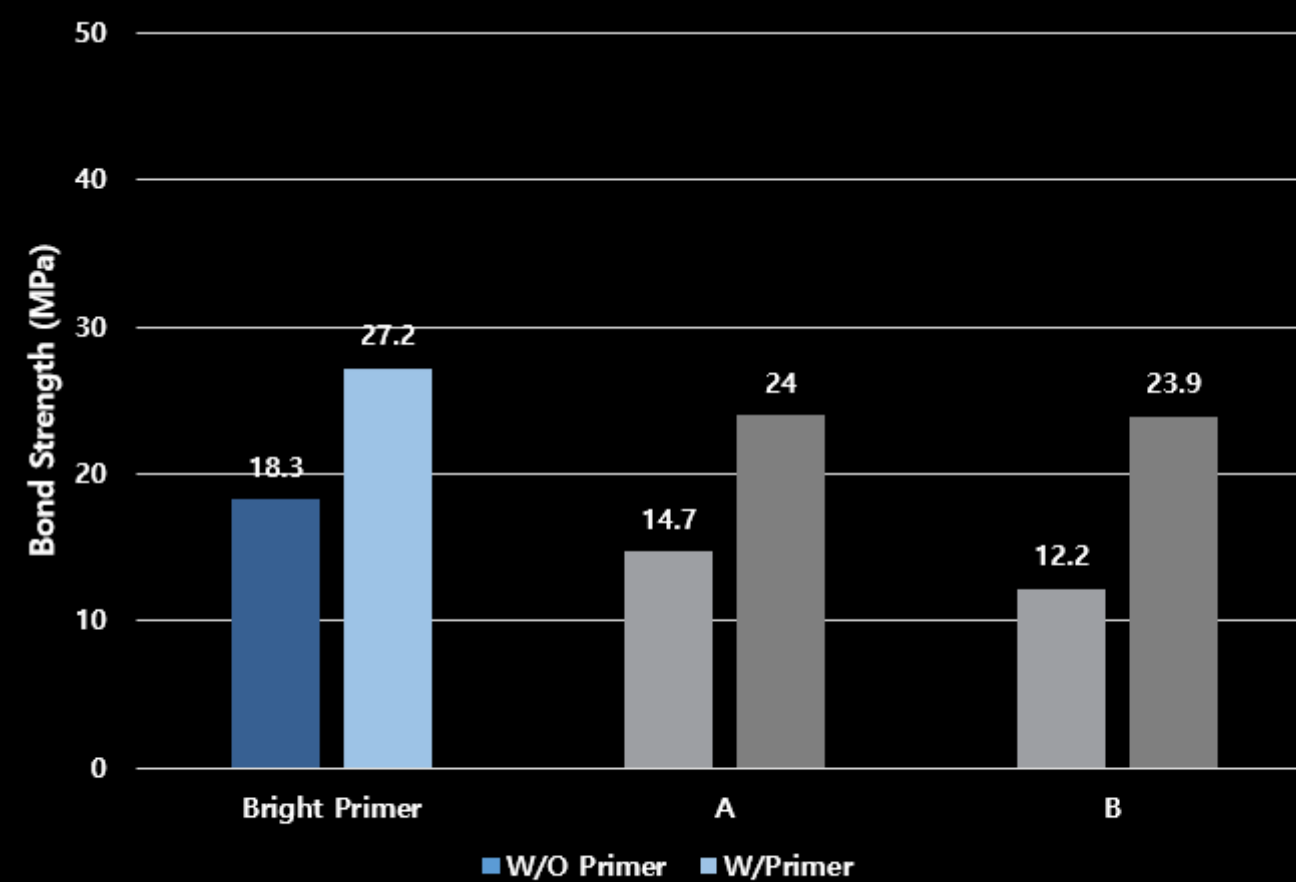
Bright Primer

- **Universal Primer containing 10-MDP**
- Improves Bond strength between cement and restorations
- Excellent bond strength to Zirconia & Metal & LS2

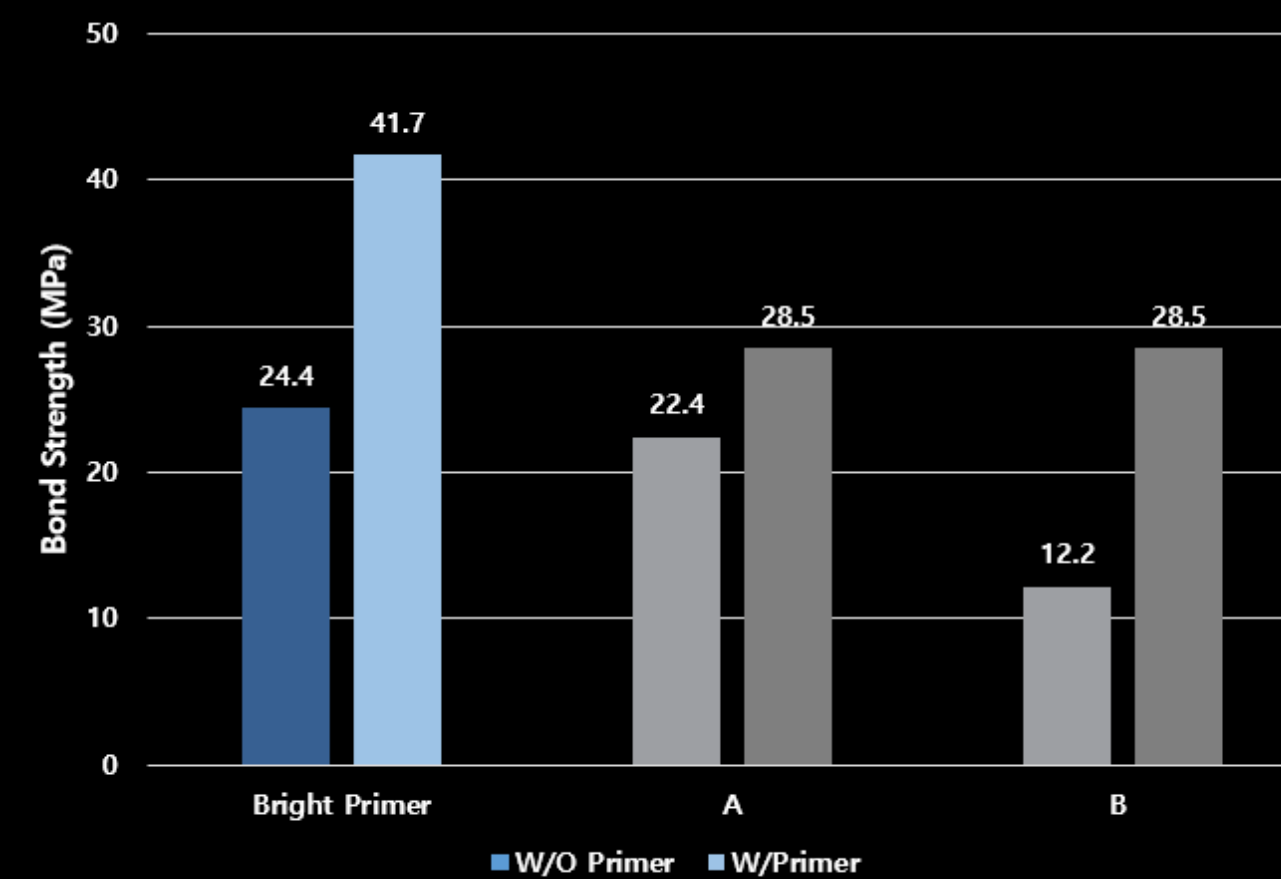


Bond Strength

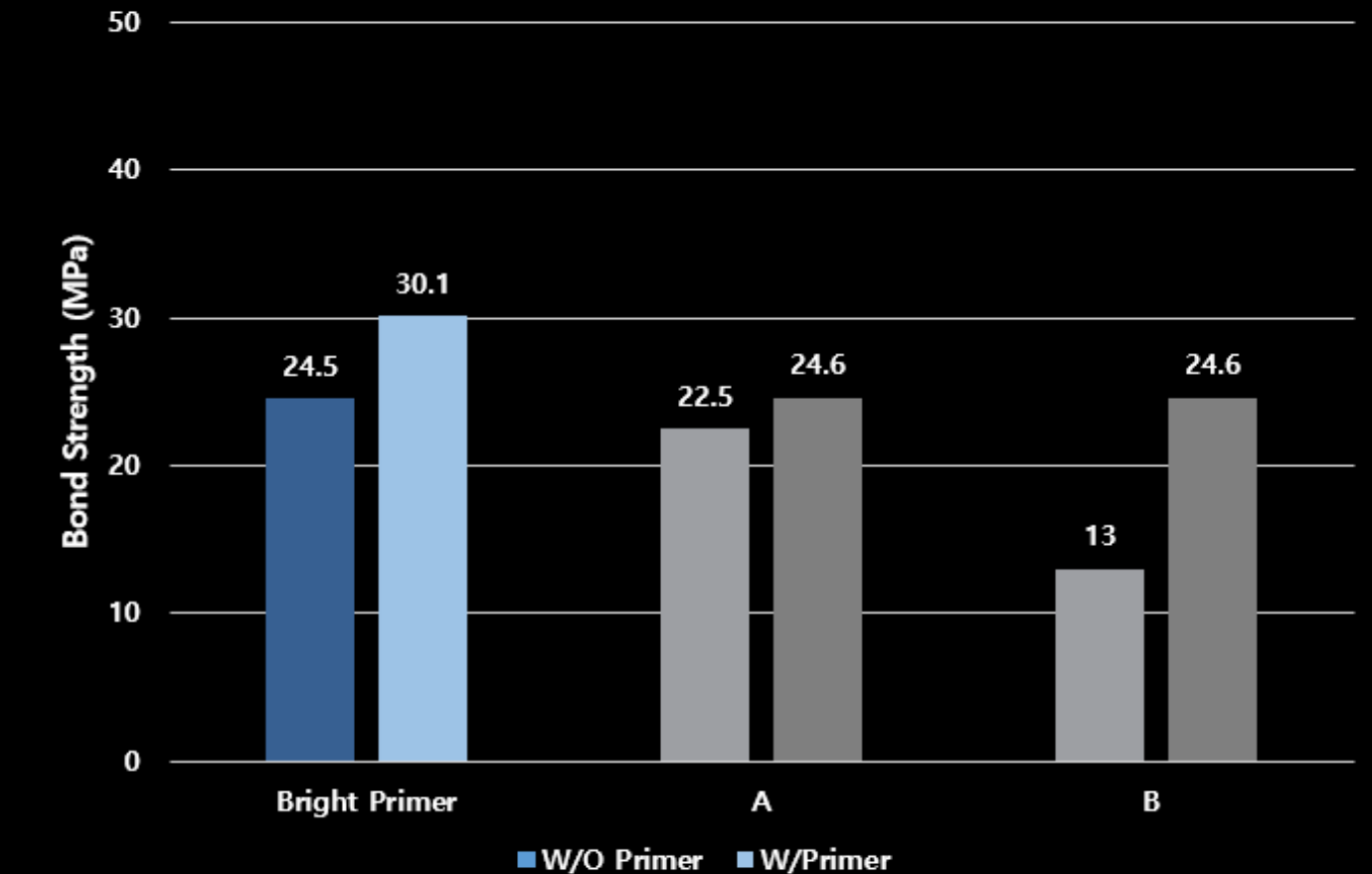
@ Zirconia



@ Metal

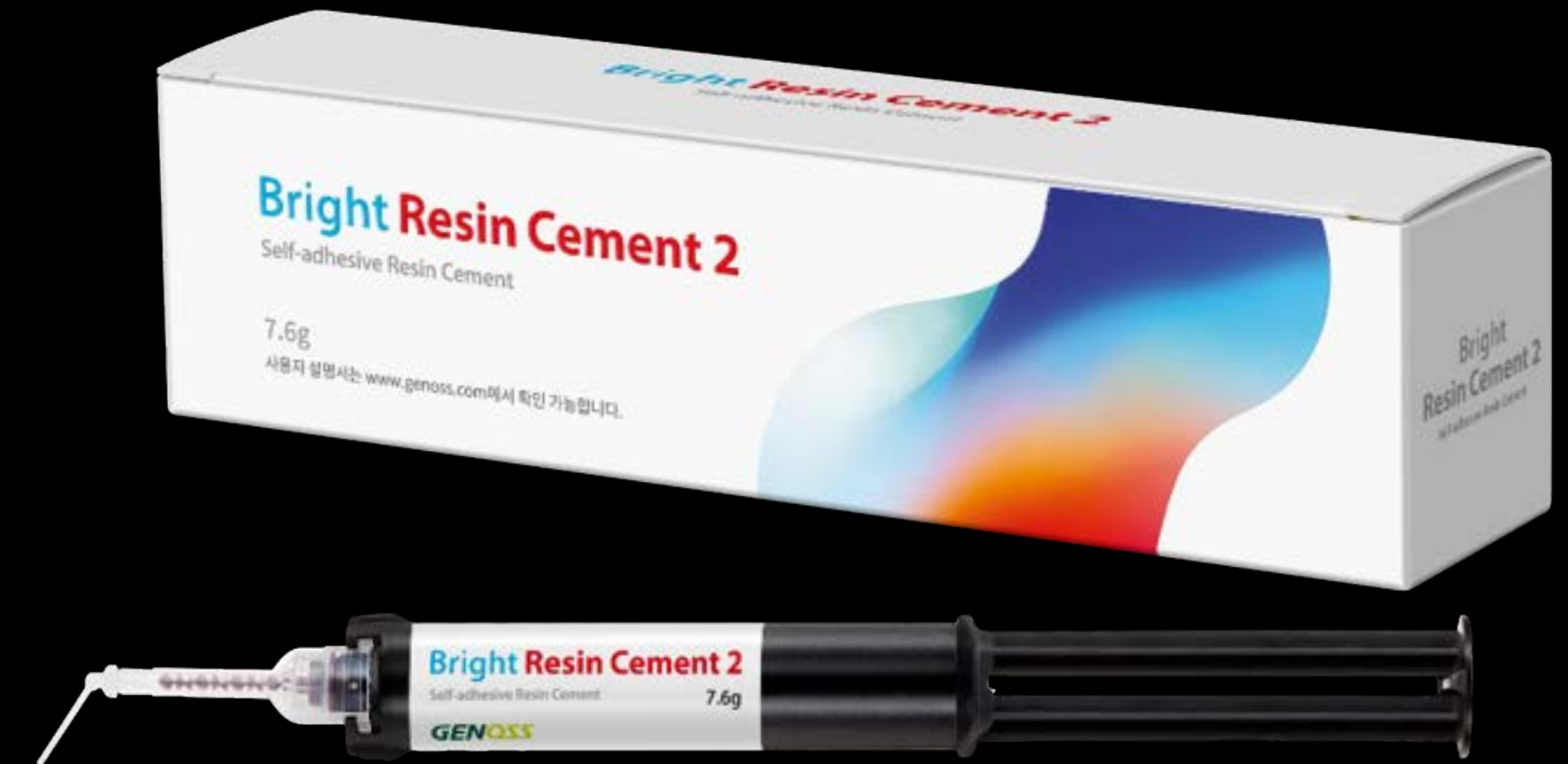

@ LS2

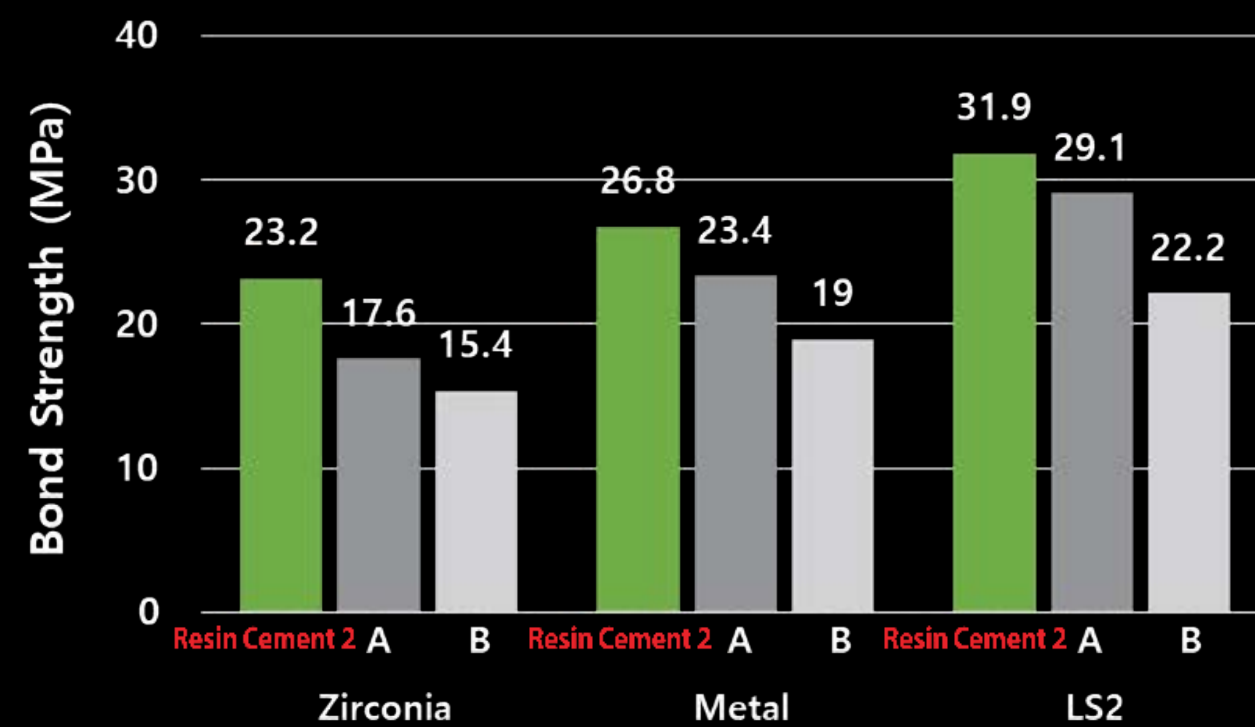


Bright Resin Cement 2

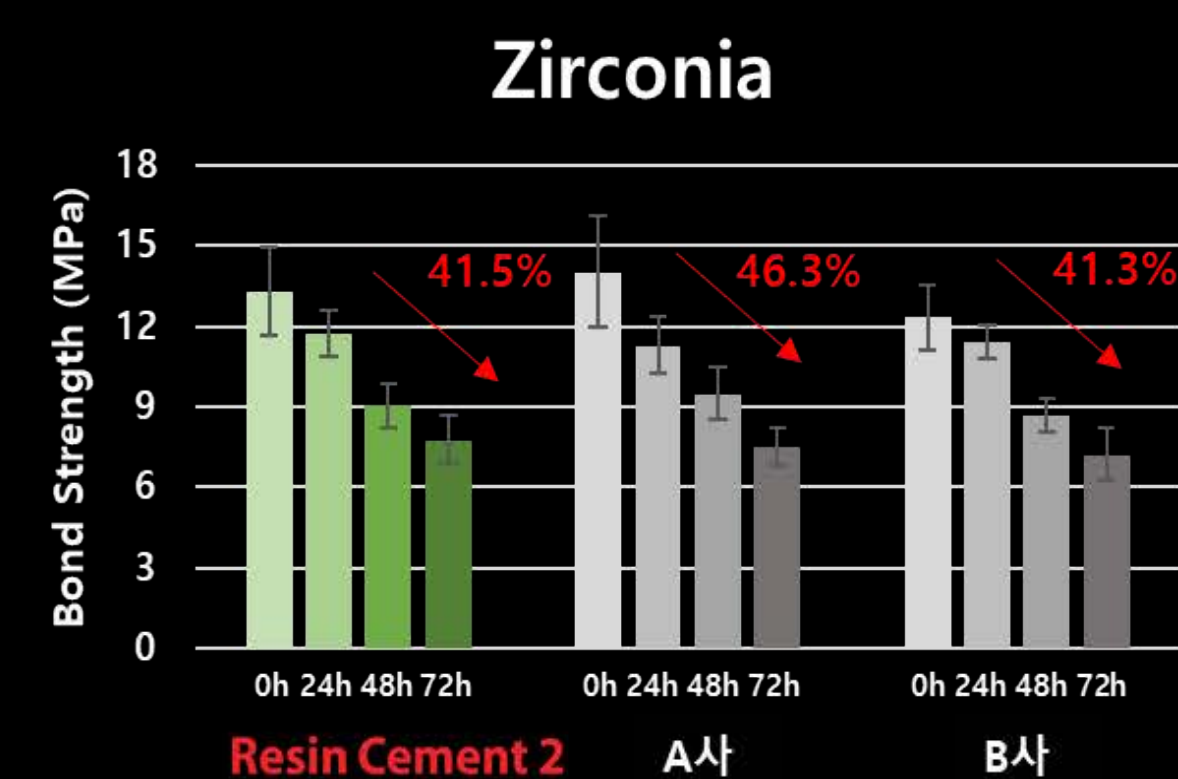
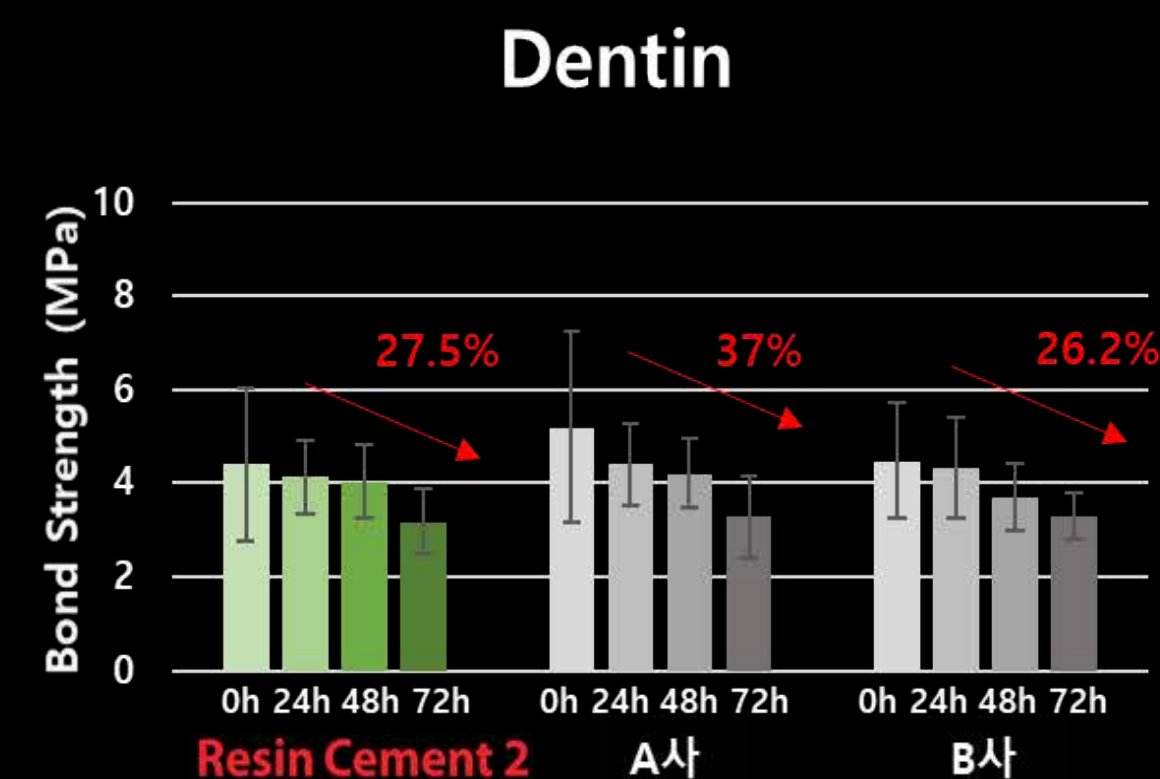
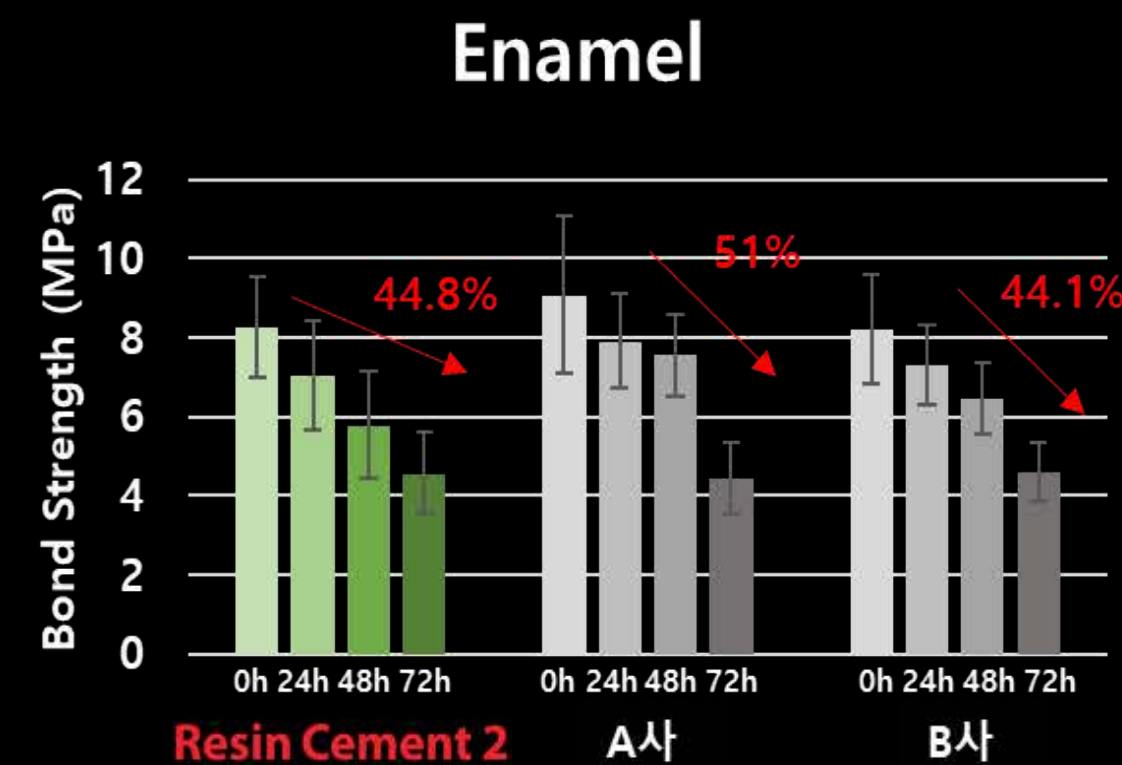
- **Strong (10-MDP) → Strong bonding to indirect restoratives**
- Stable storage stability in both refrigerated and R.T storage
- Long Working time (≥ 2 min) / Short Setting time (≤ 4 min)

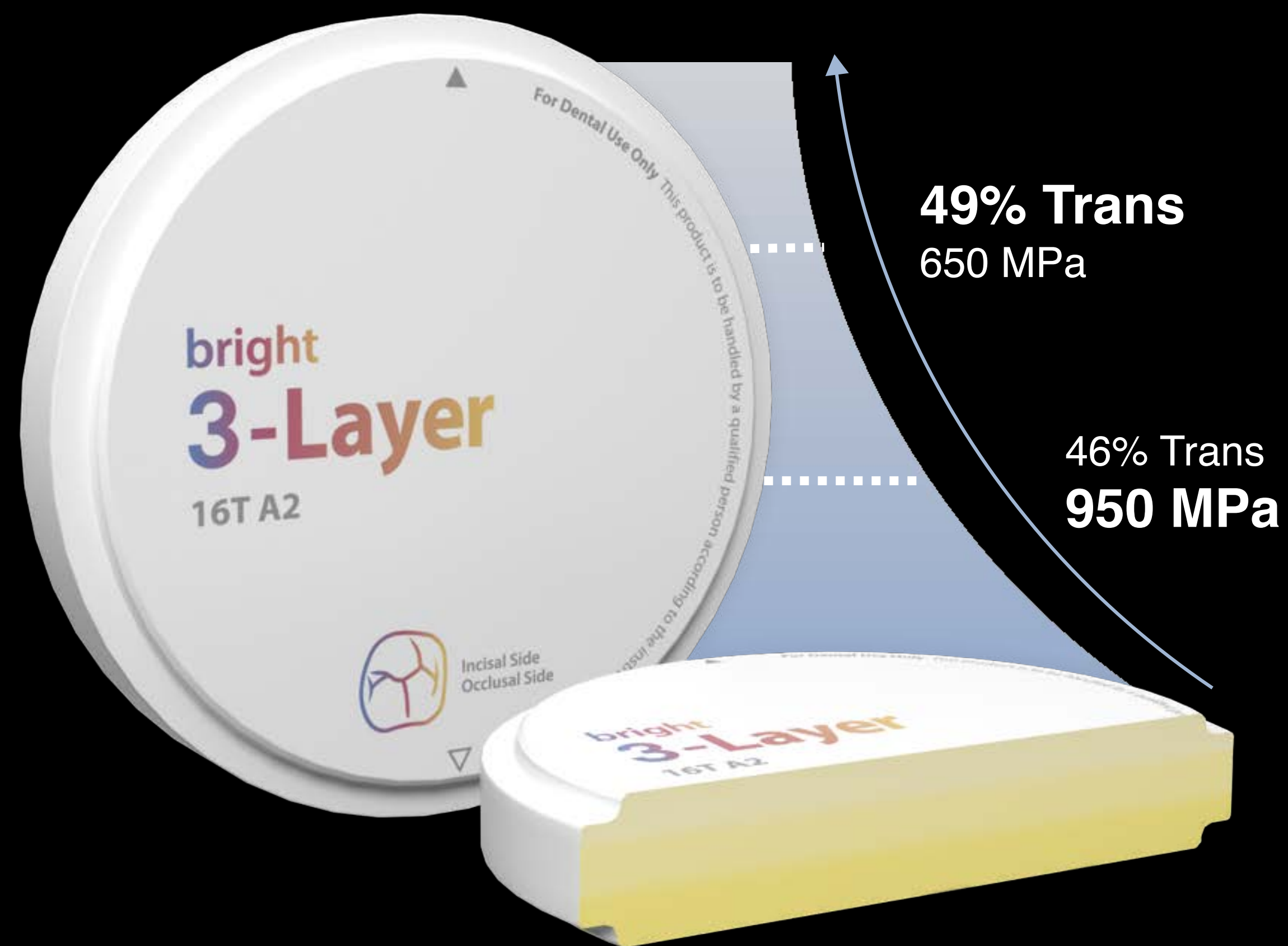


Bond Strength



Adhesion durability (72h F/U)






bright
3-Layer

NO Coloring
Staining

Dentium

3 layer Zr block



5 Y

Translucent 48
Value -0.3

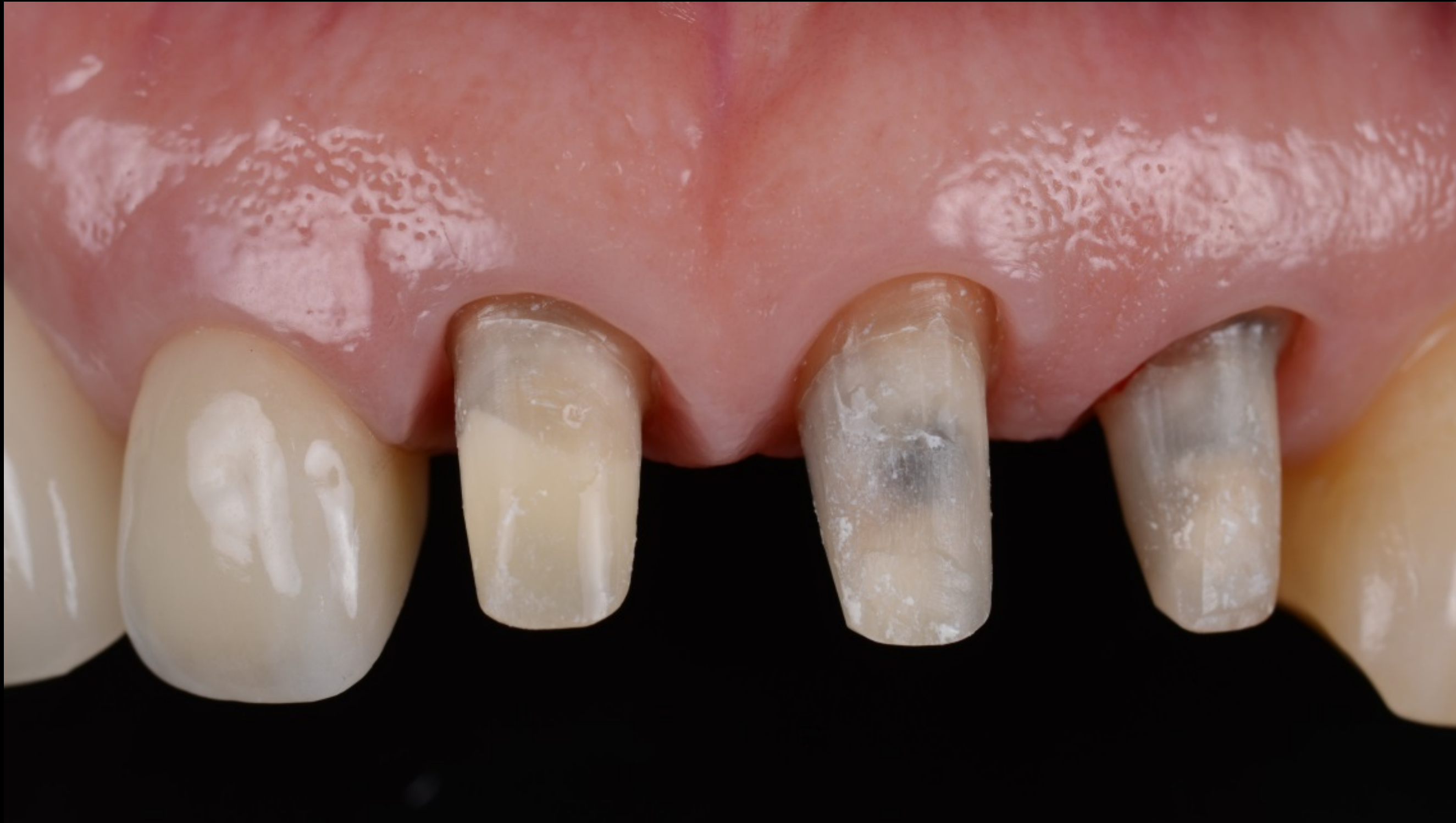5Y + 4Y

Translucent 47
Value 0

4Y

Trandlucent 46
Value +0.3

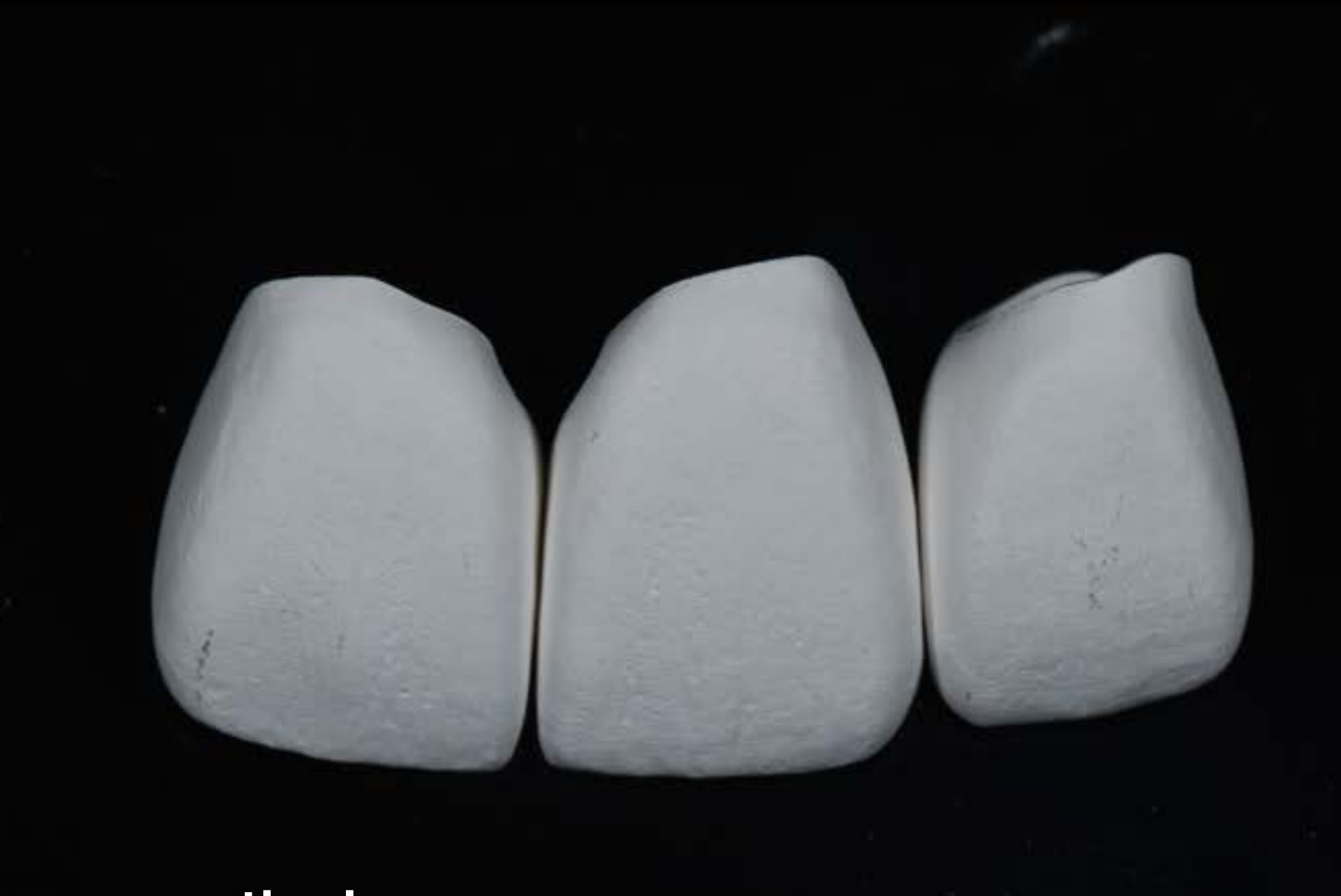Case report 1



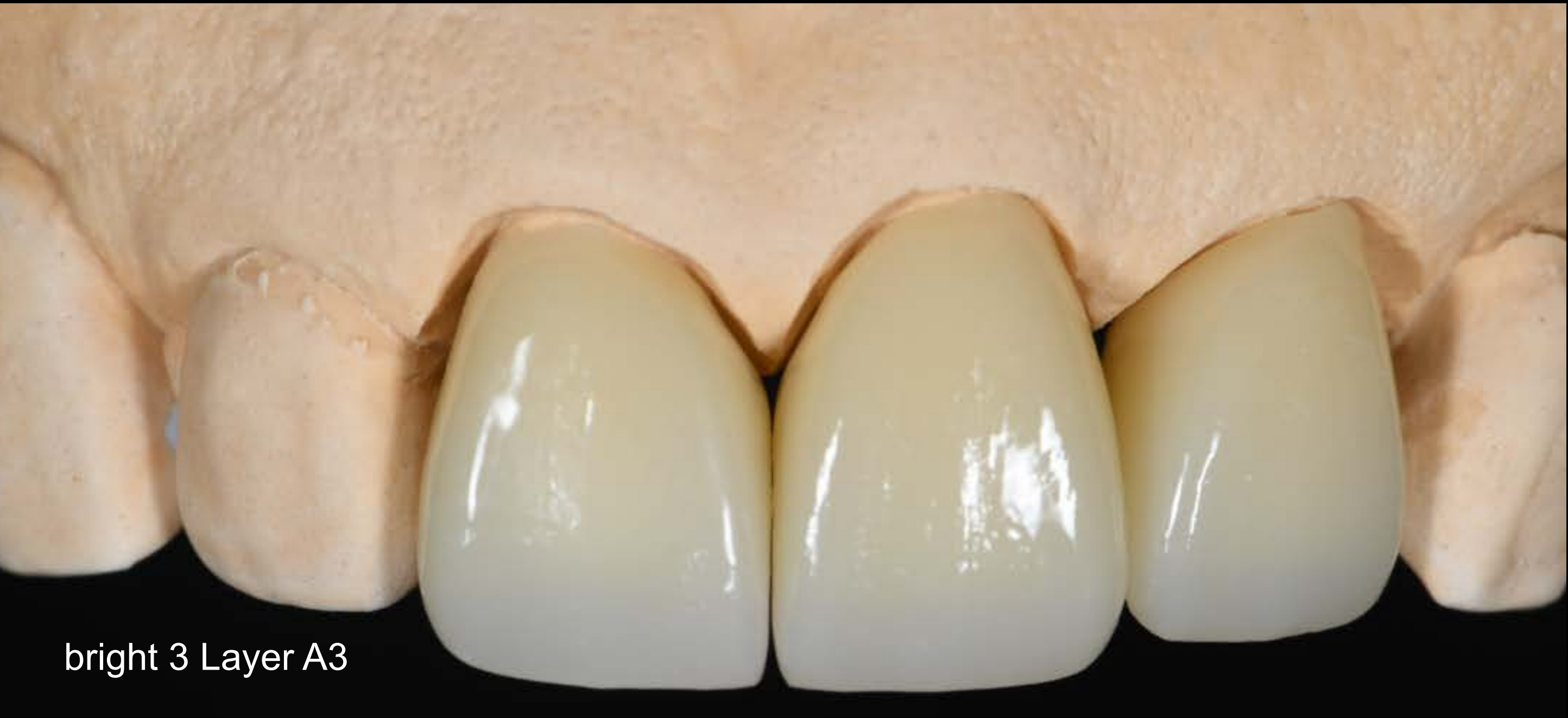- # 11, 12, 22
- Natural Teeth
- bright 3 Layer Block
- Shade A3

Natural teeth prosthesis _ upper Anterior

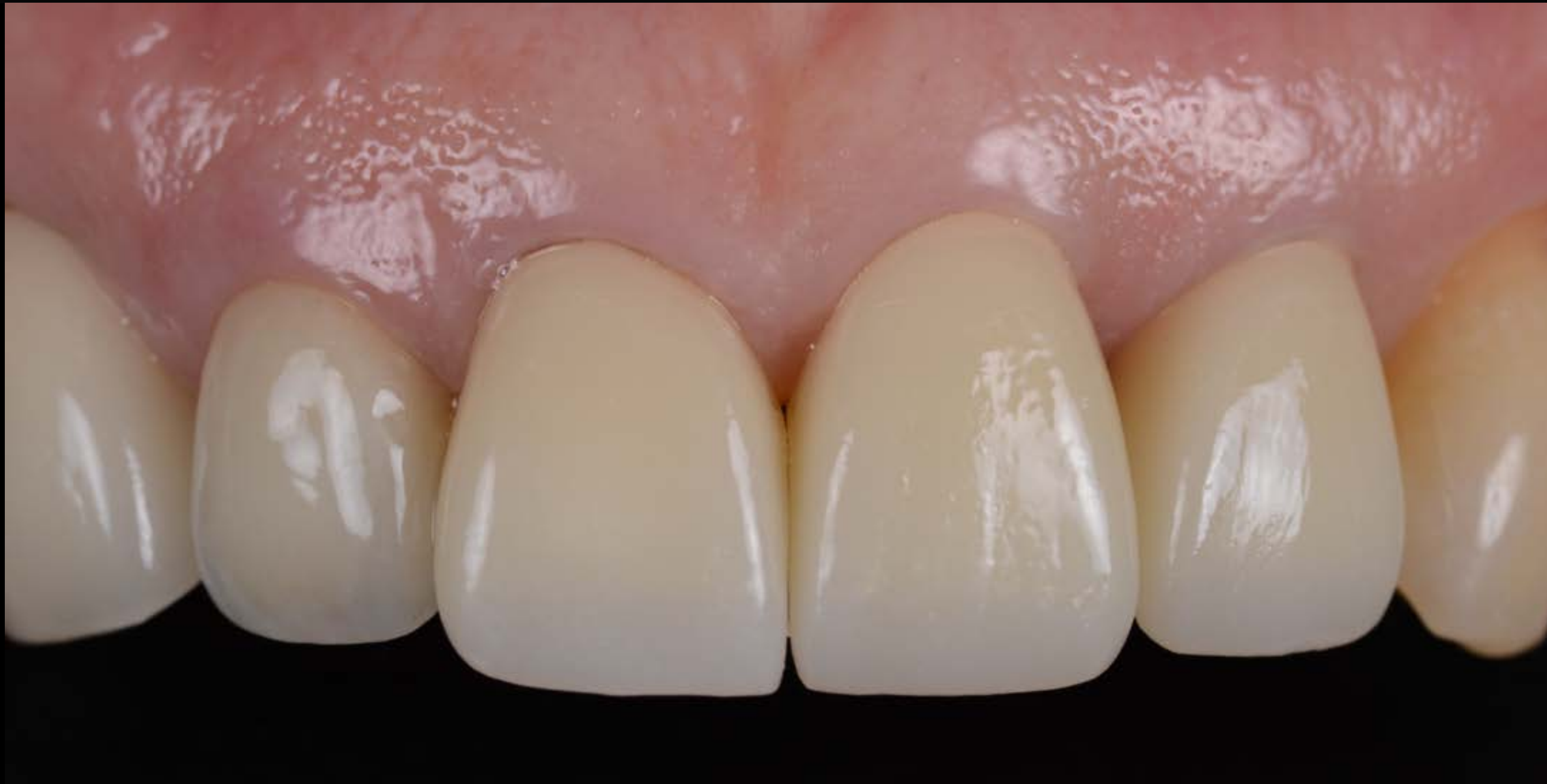Final prosthesis



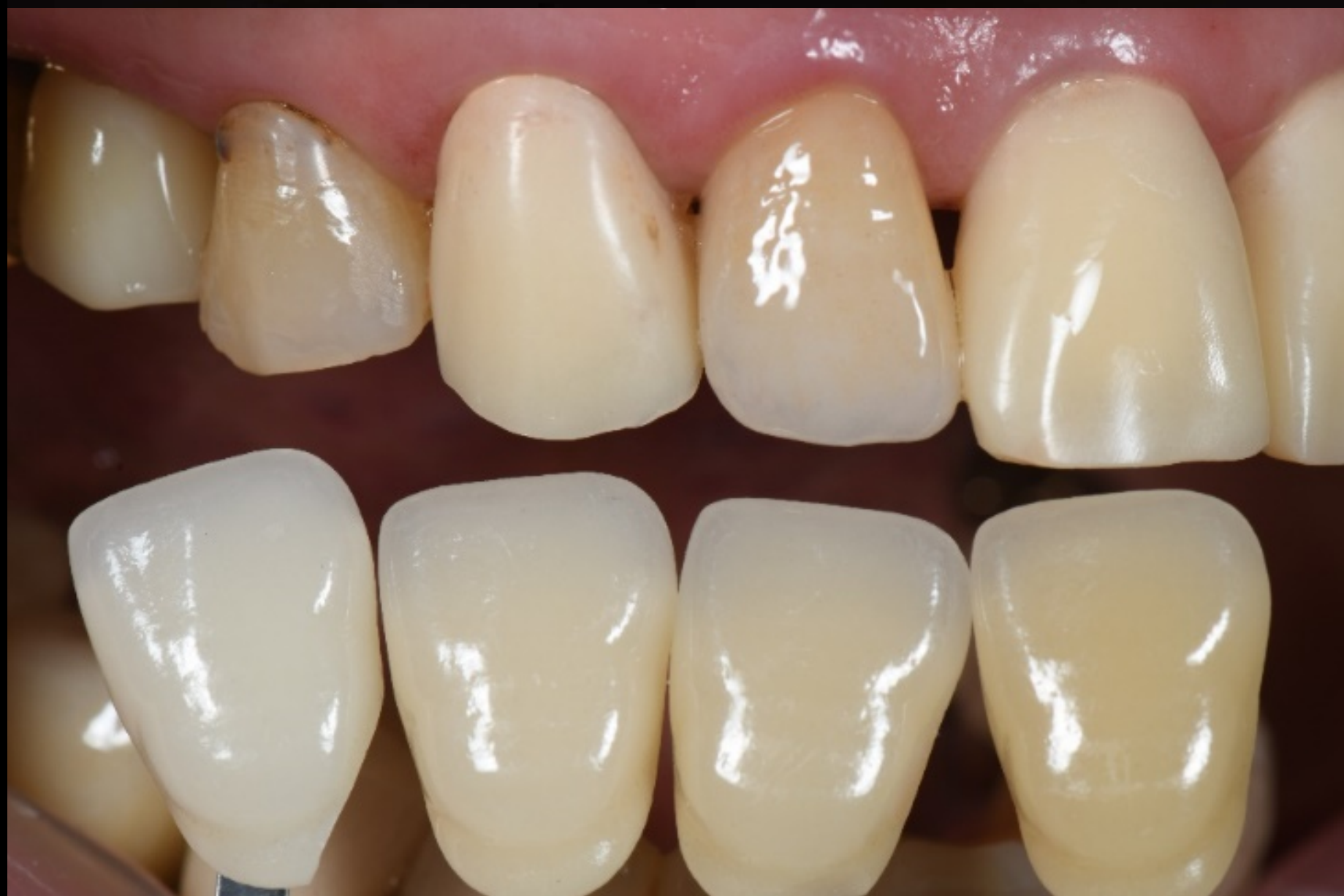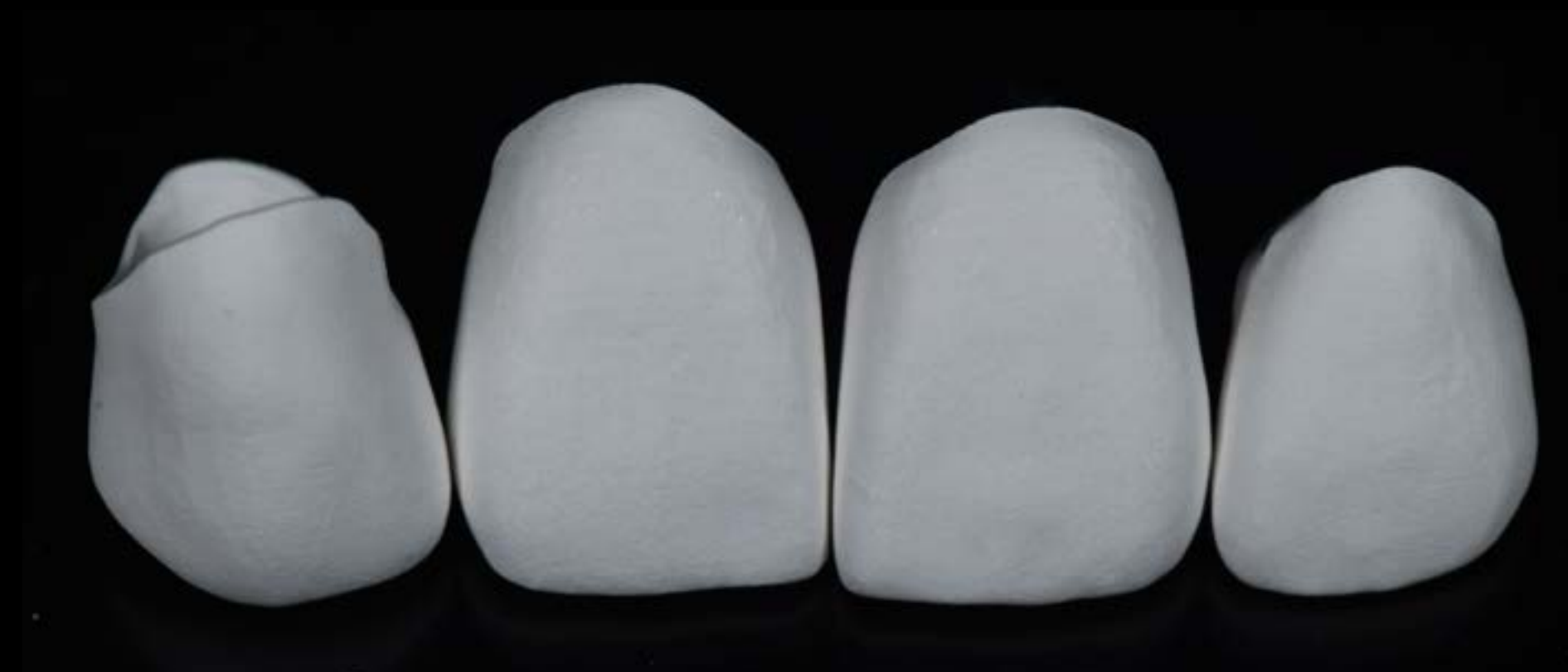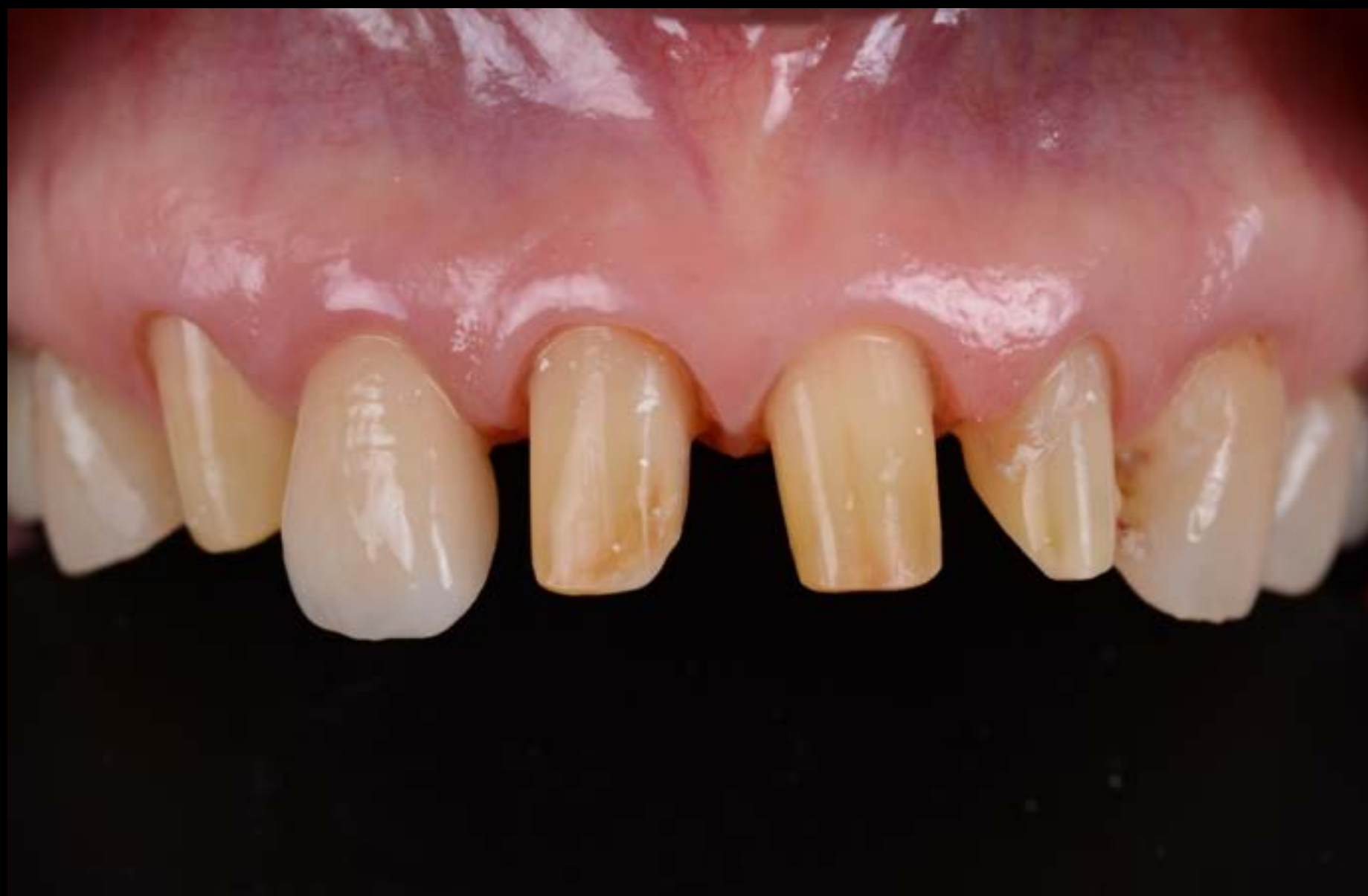내면 – White opaque



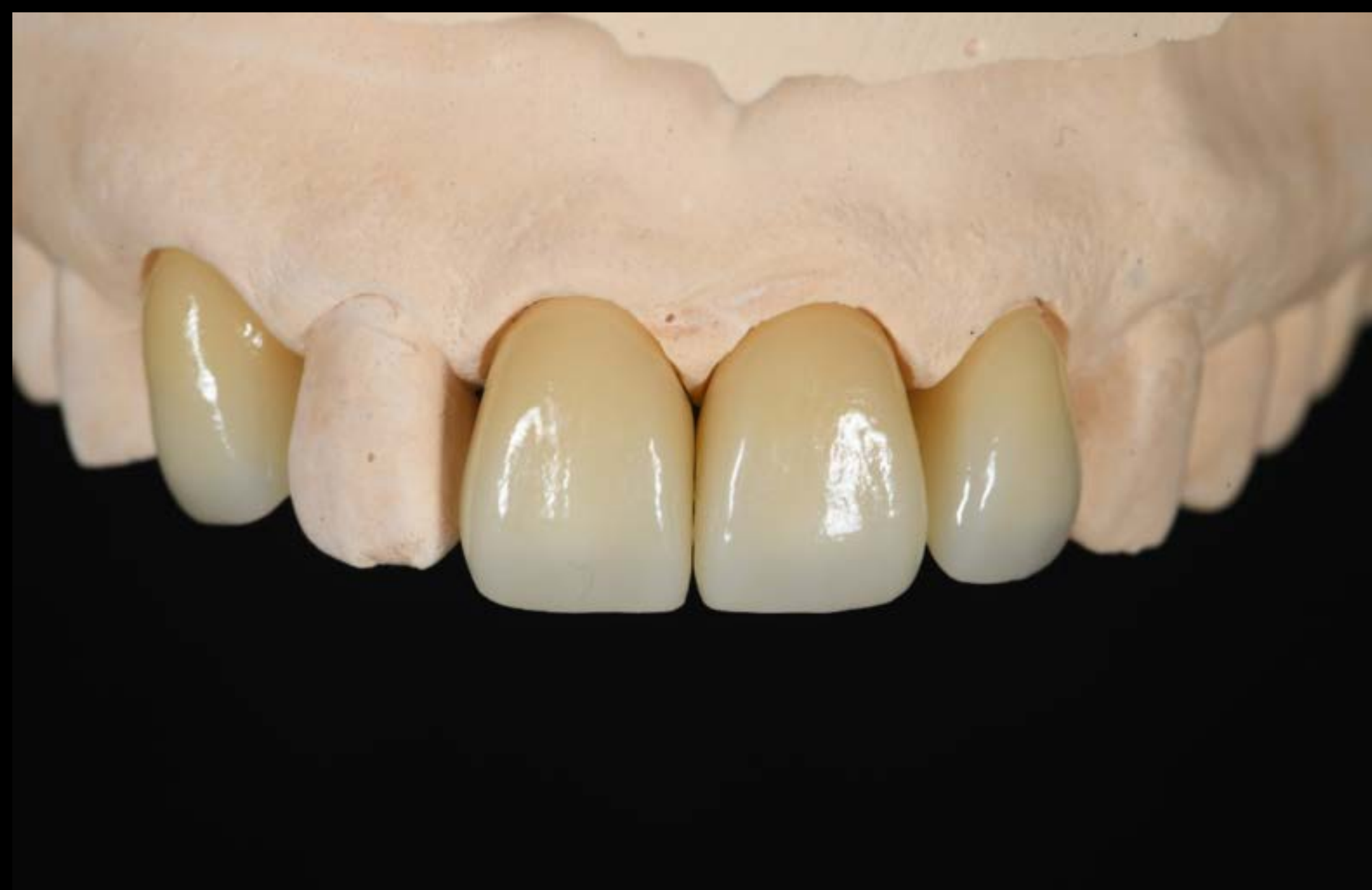bright 3 Layer A3



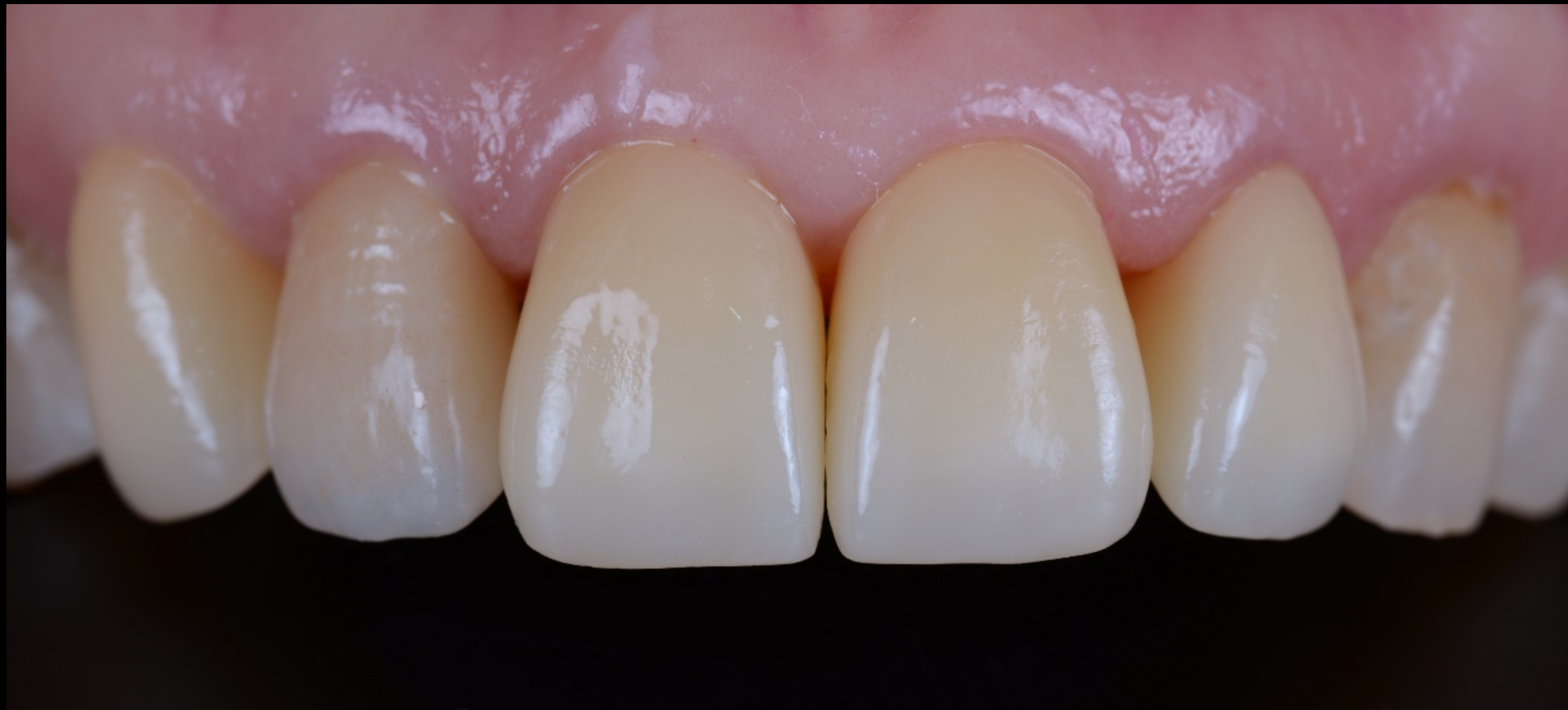Natural tooth Case_2



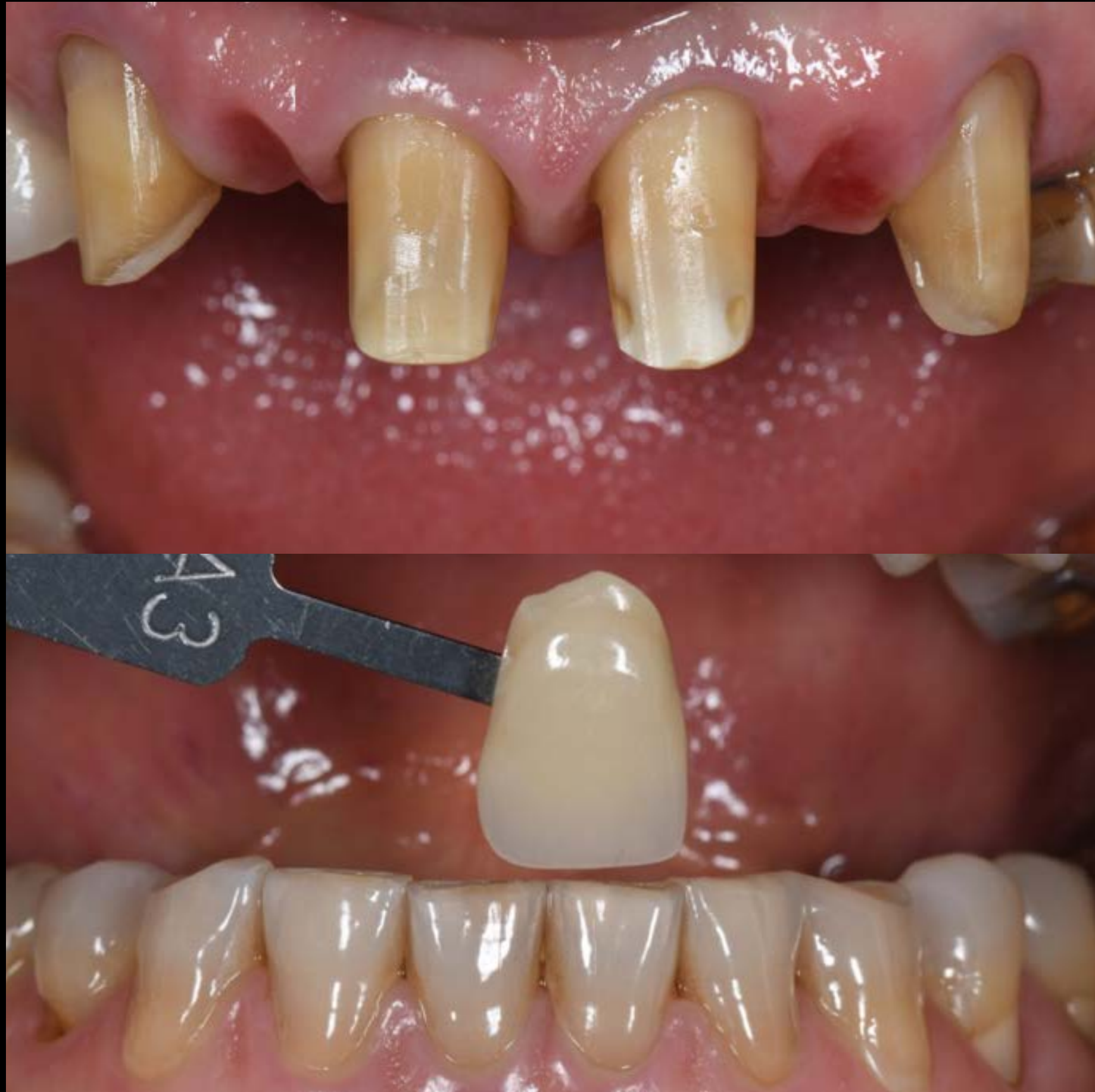Shade Taking : A3



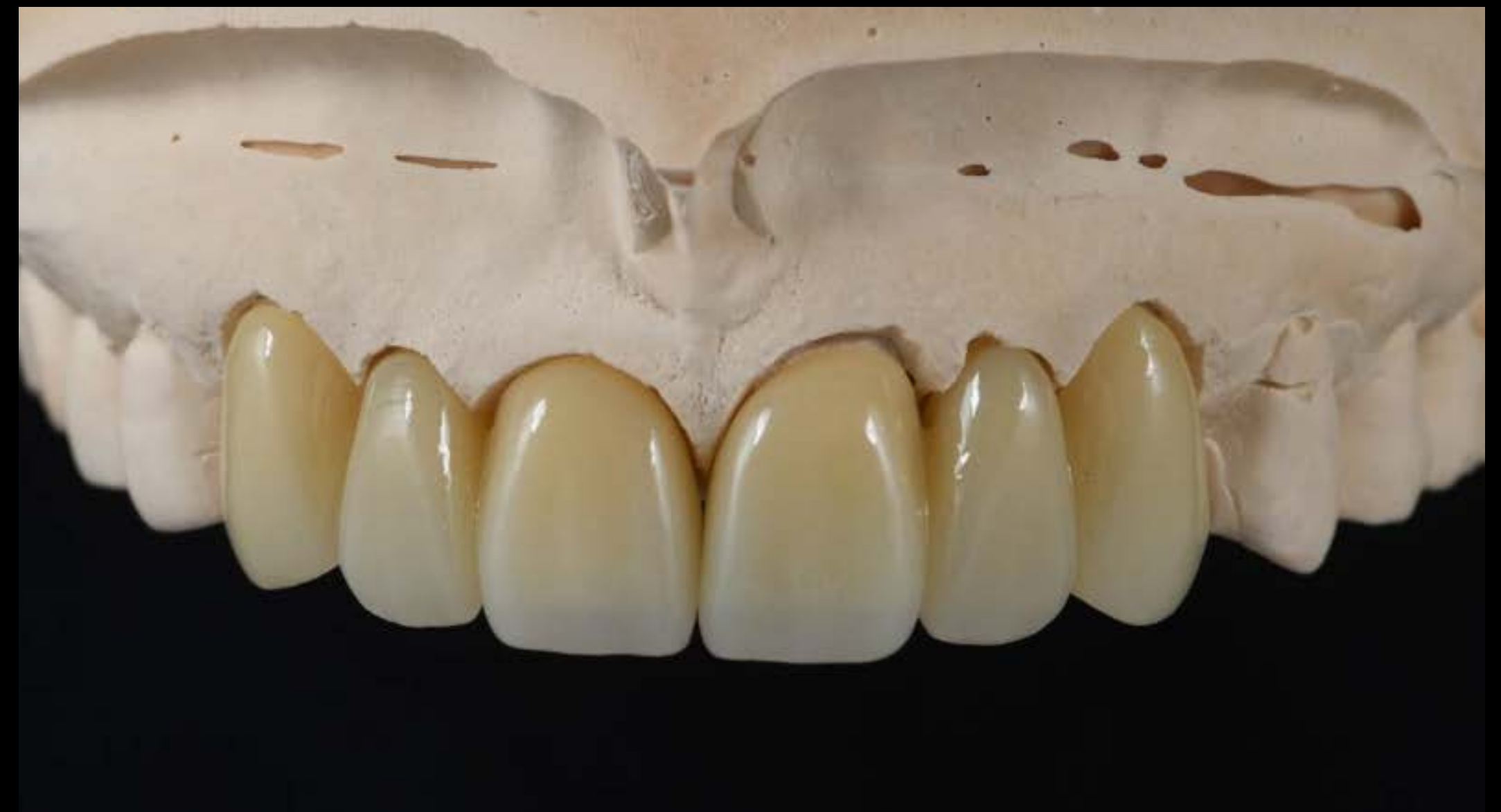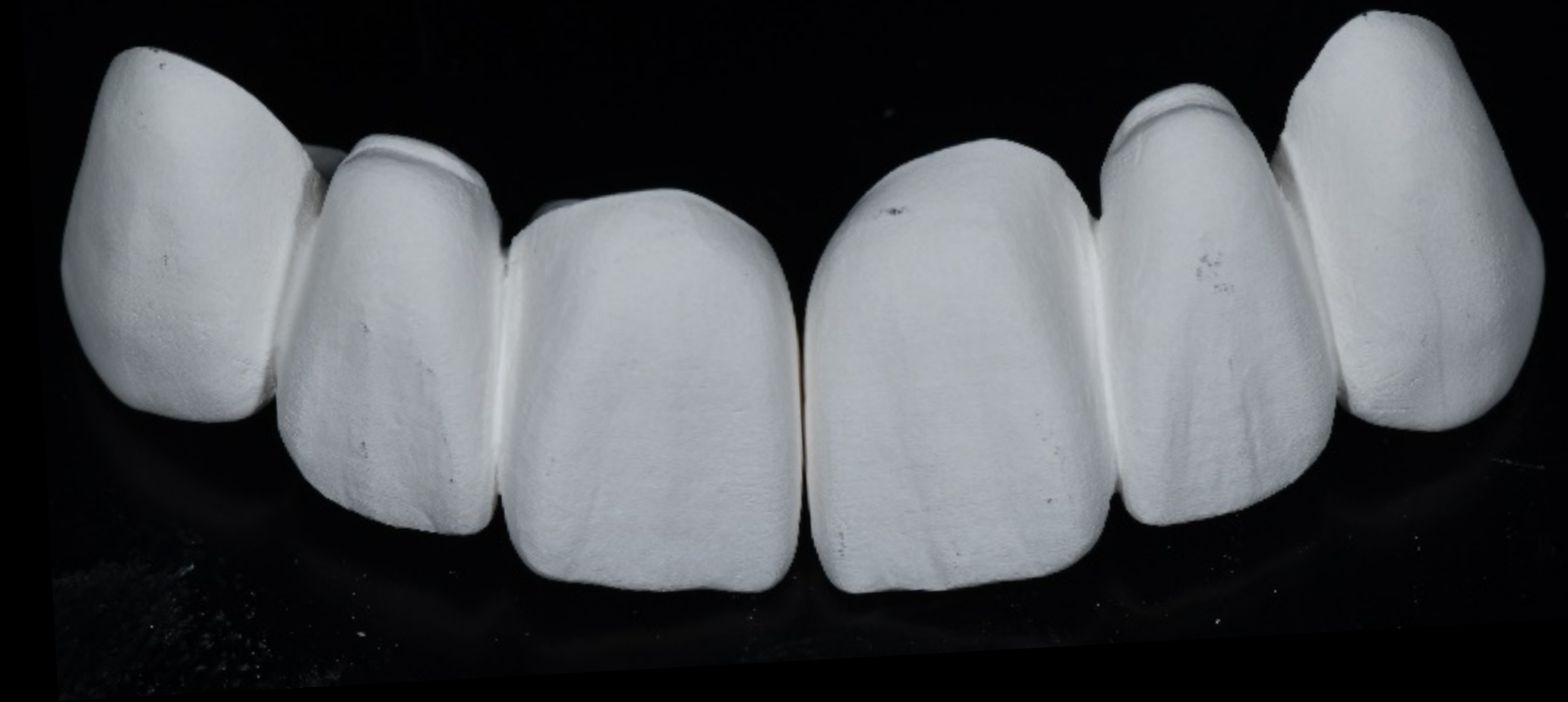Natural tooth Case_2



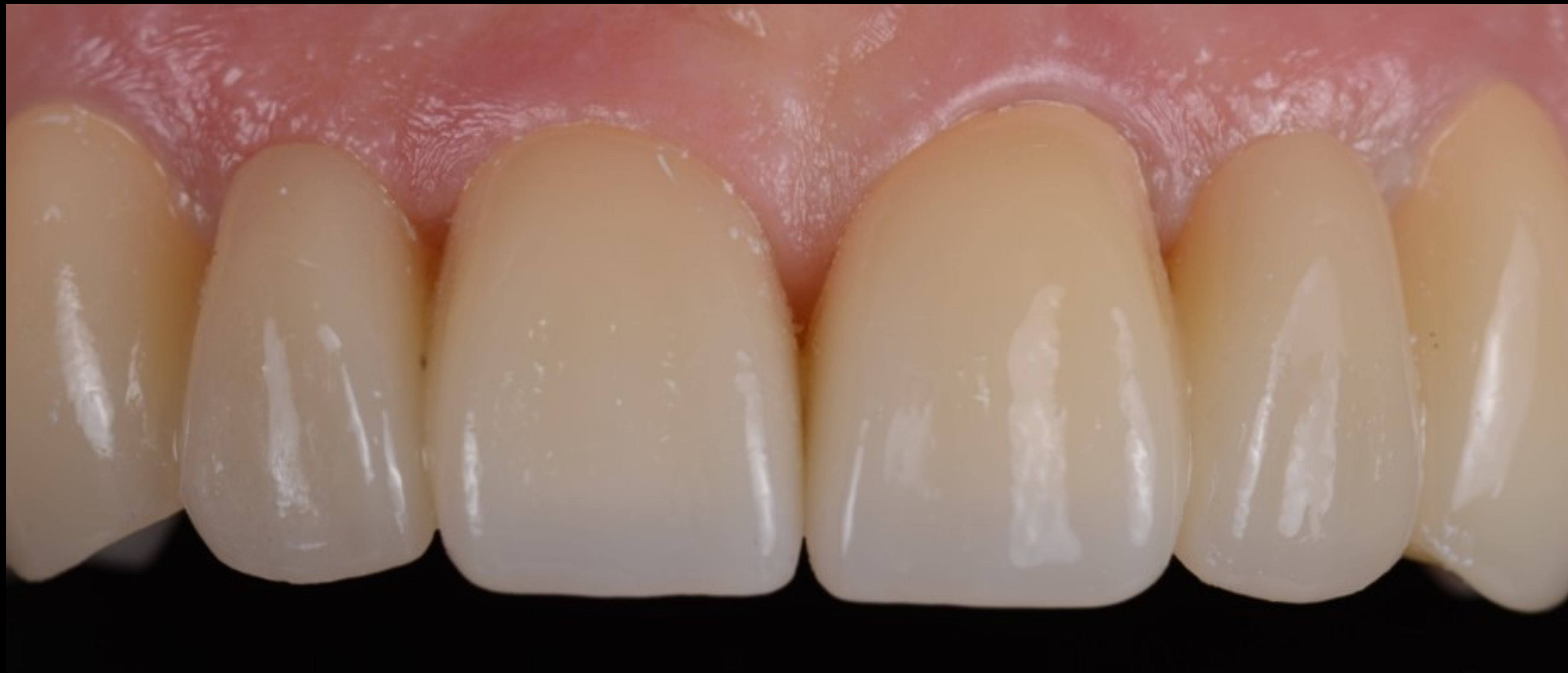Natural tooth Case_3



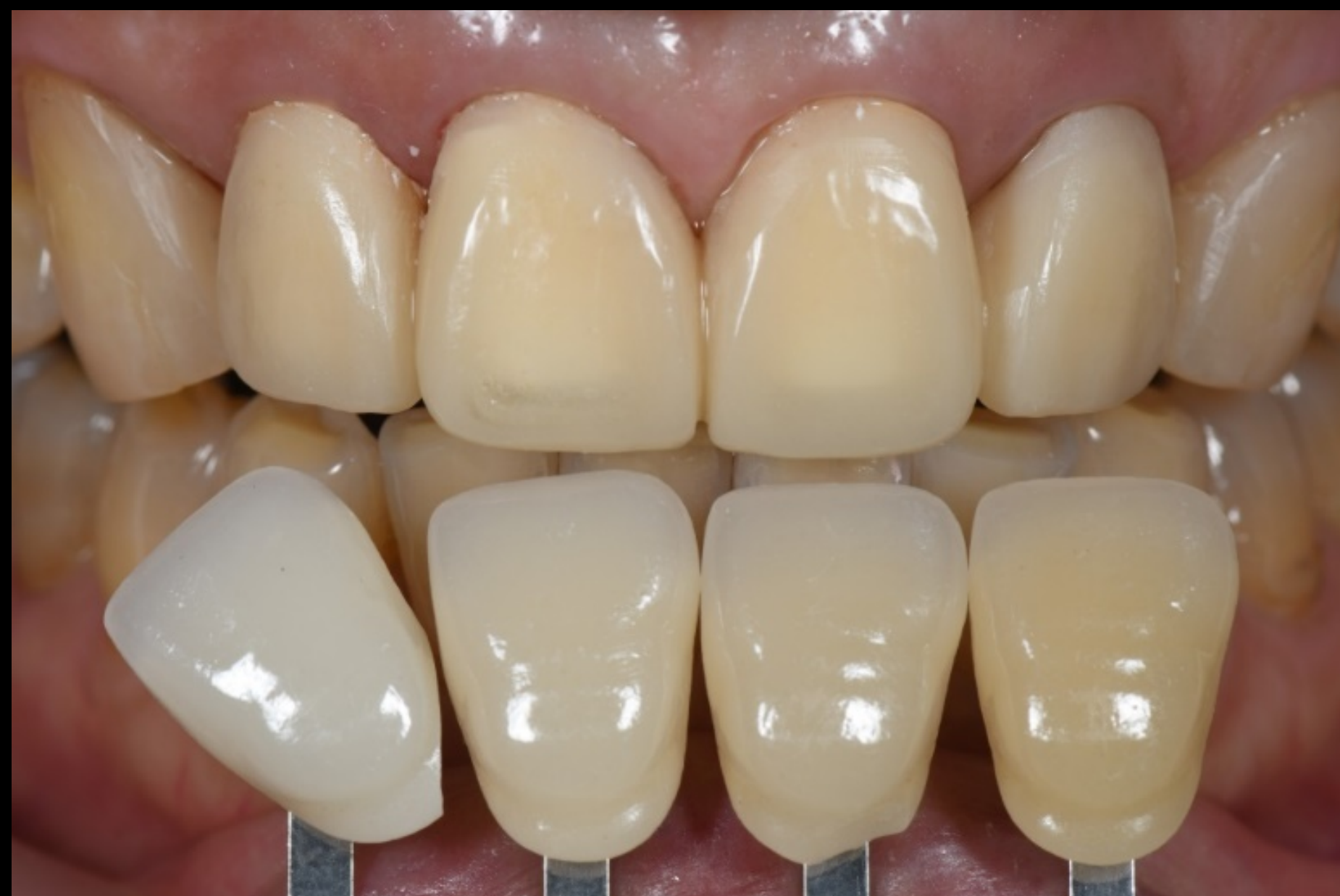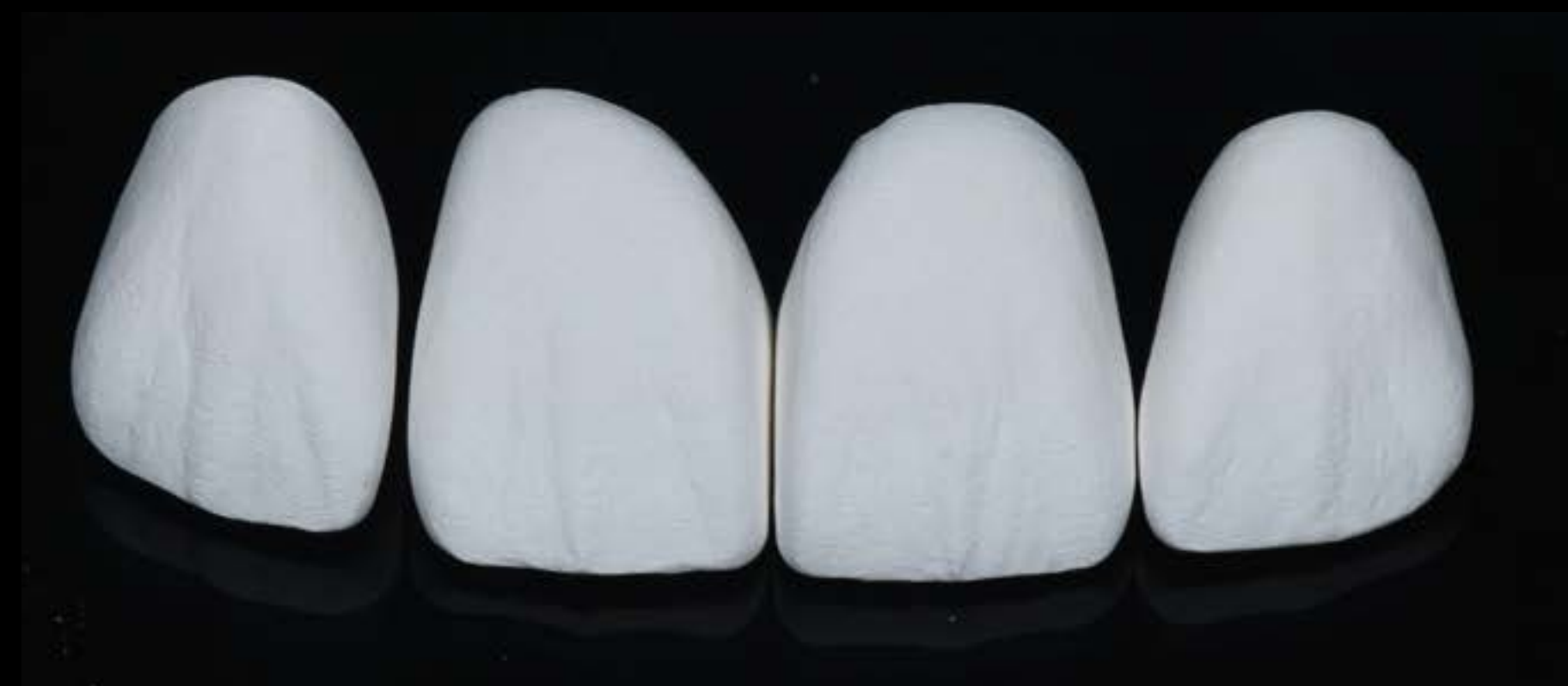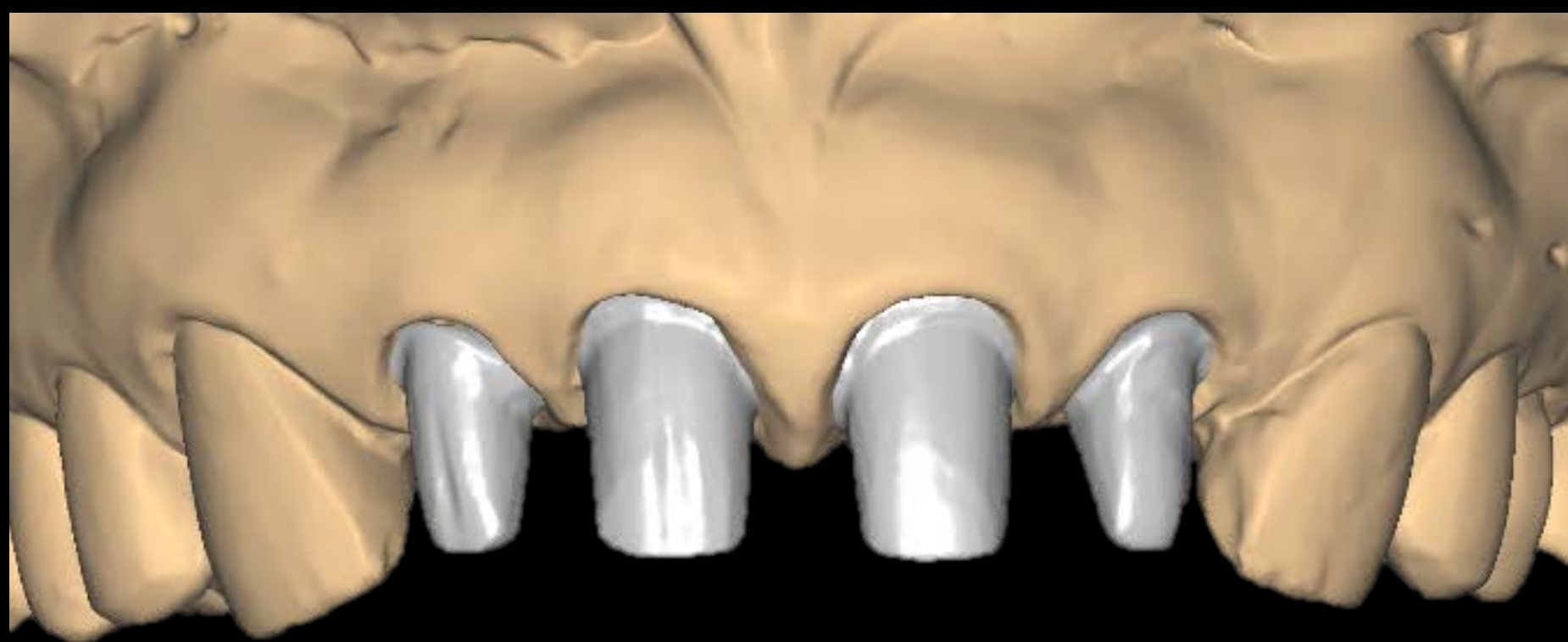
Shade Taking : A3



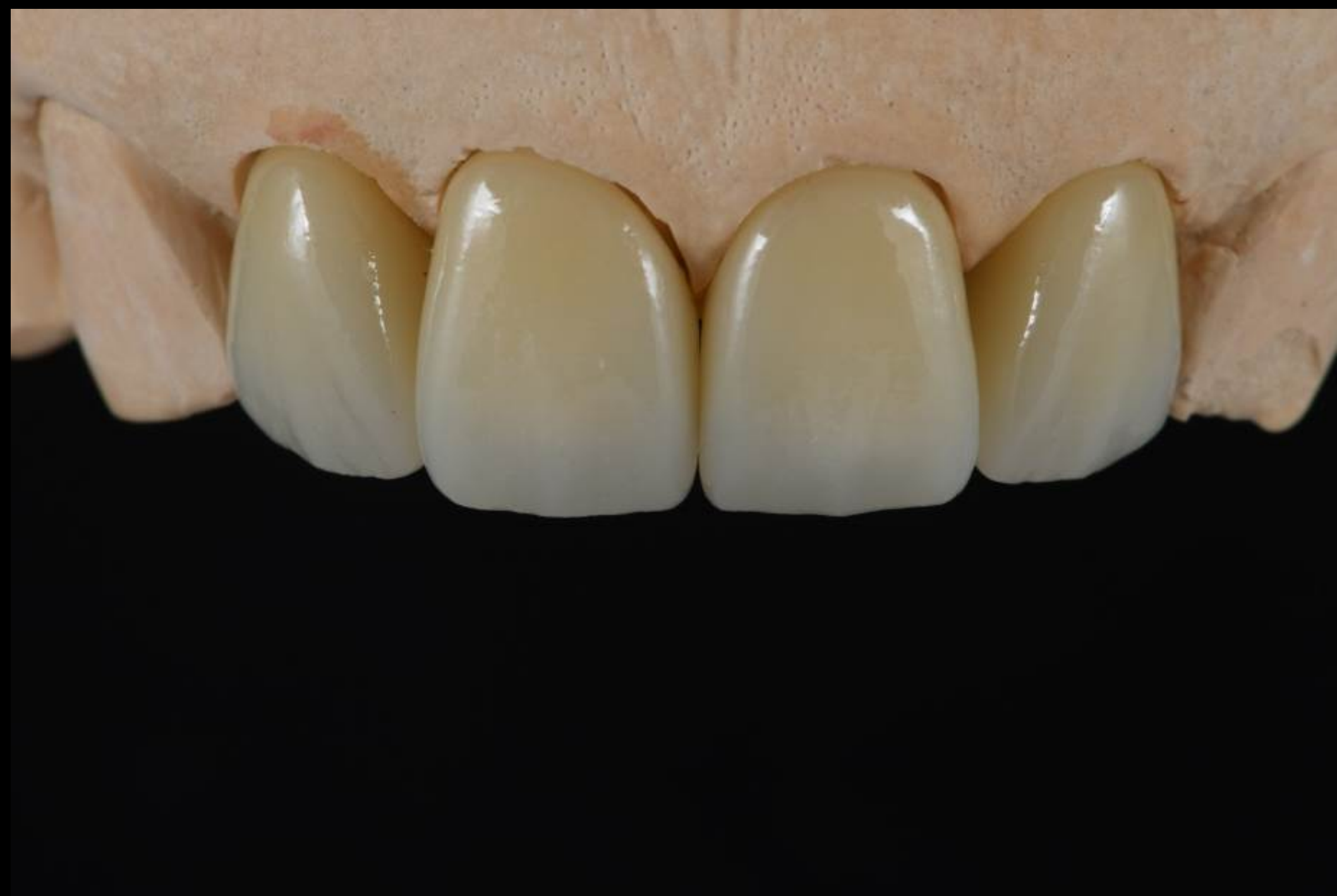Natural tooth Case_3



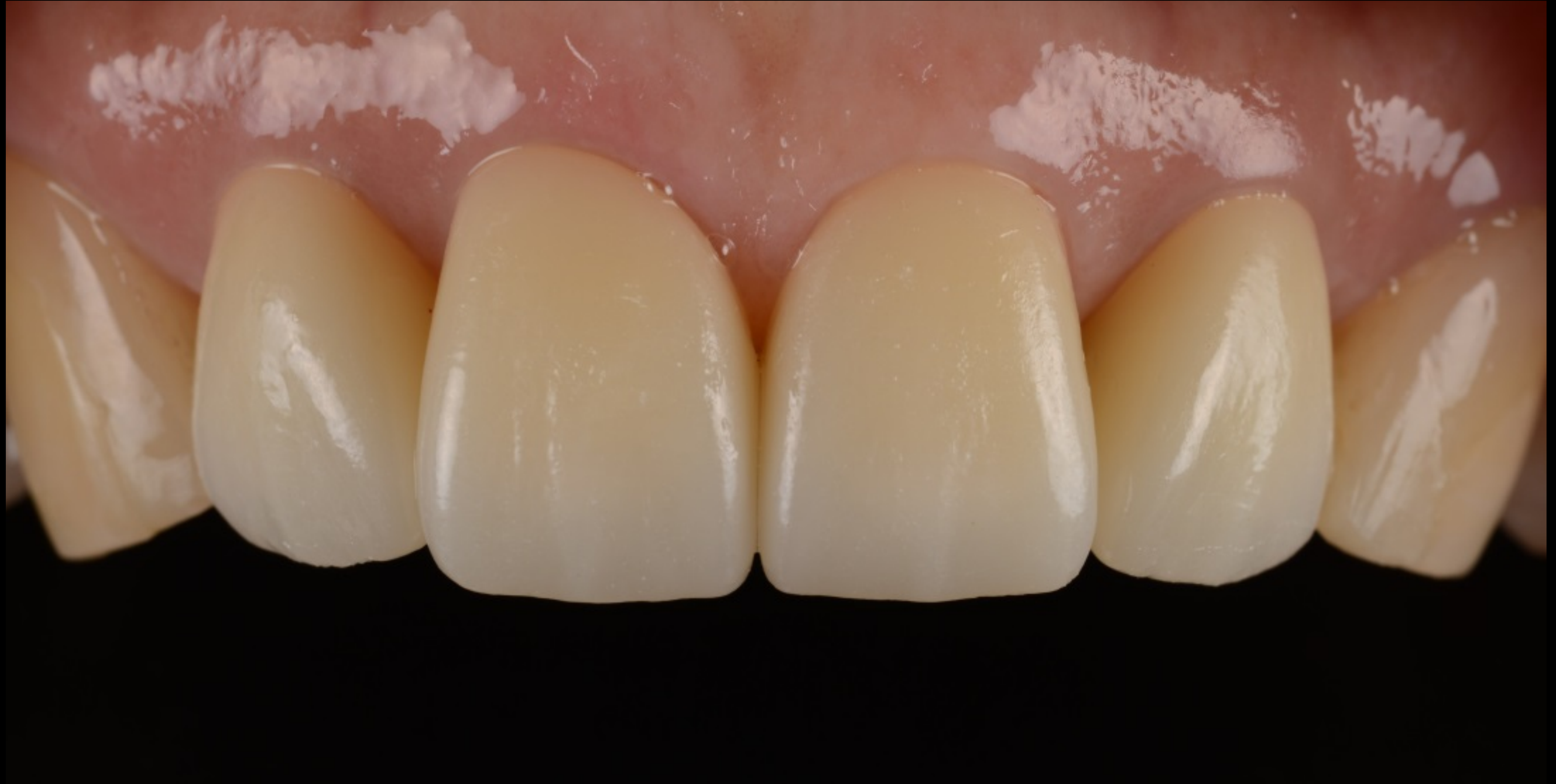Natural tooth Case_4



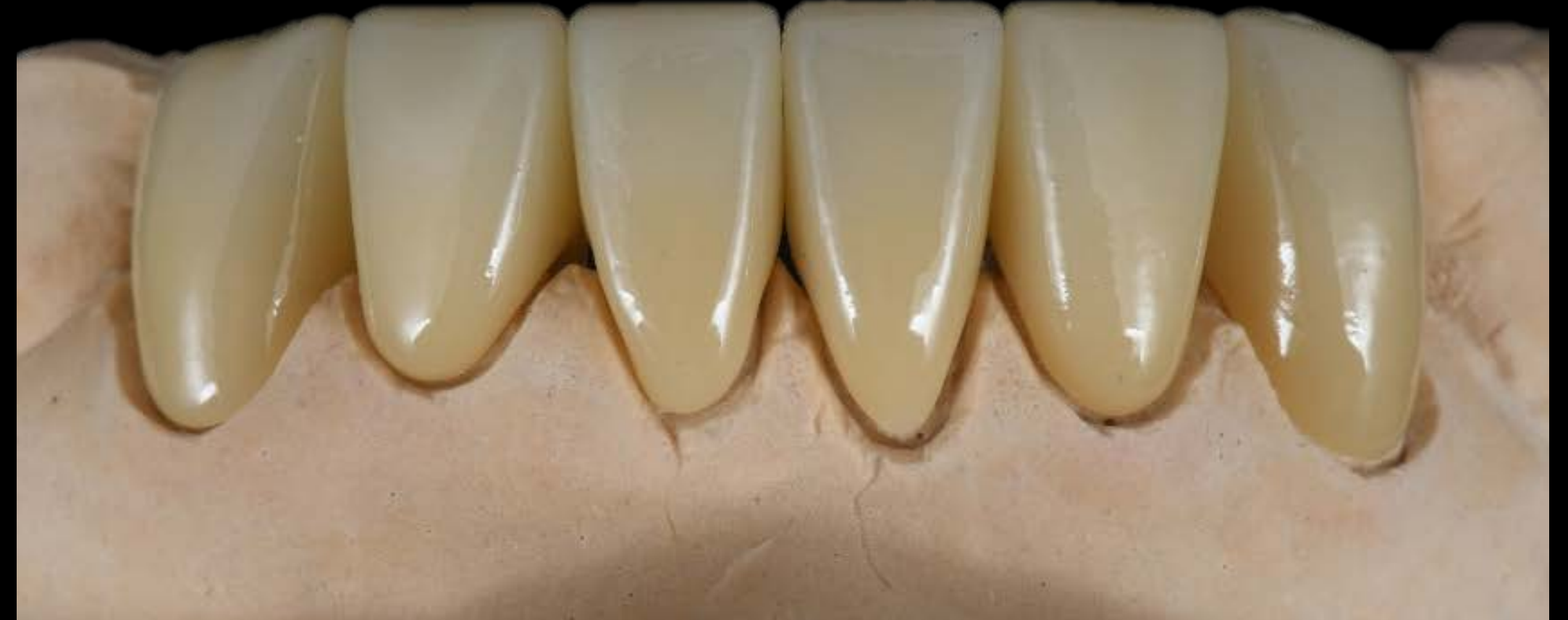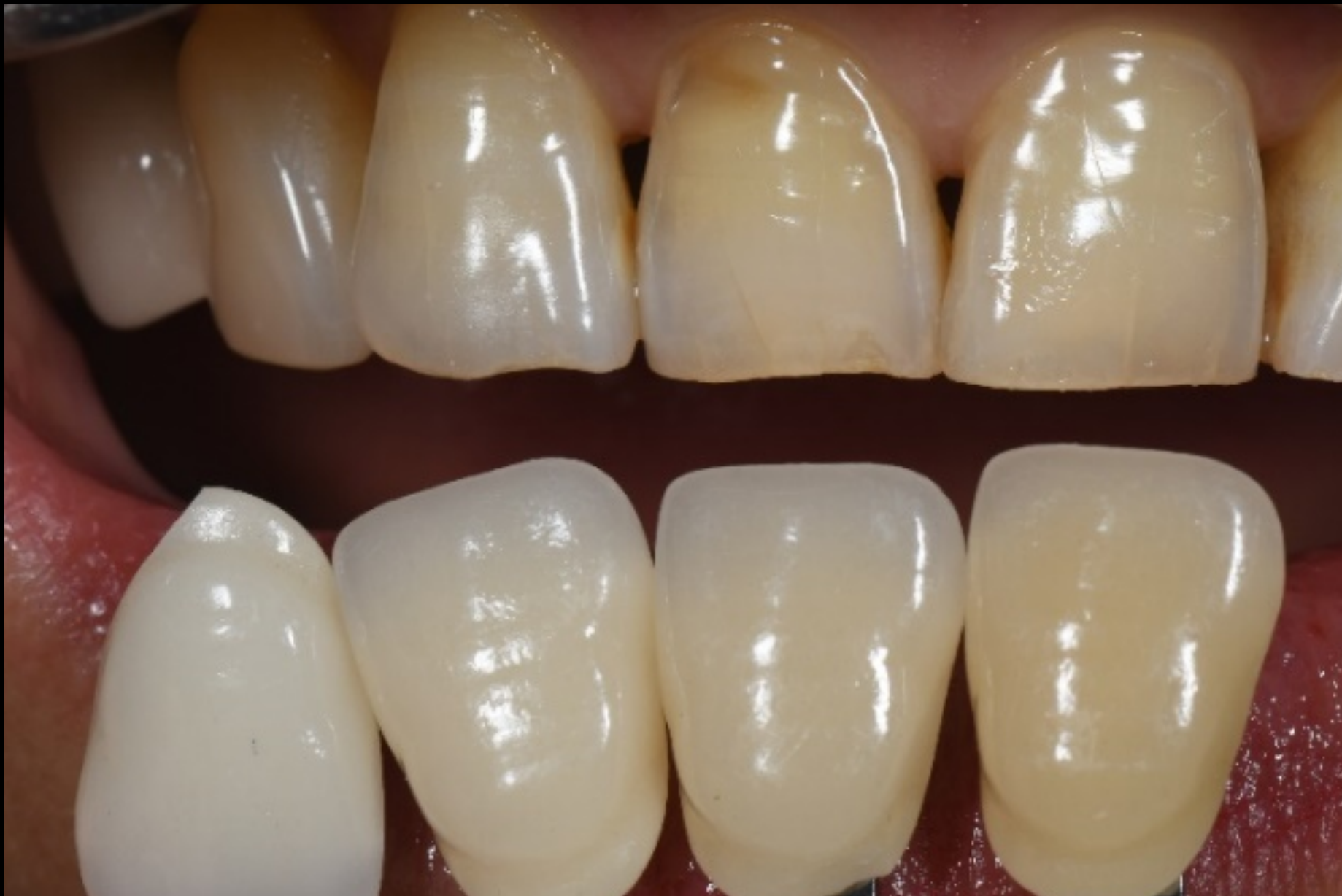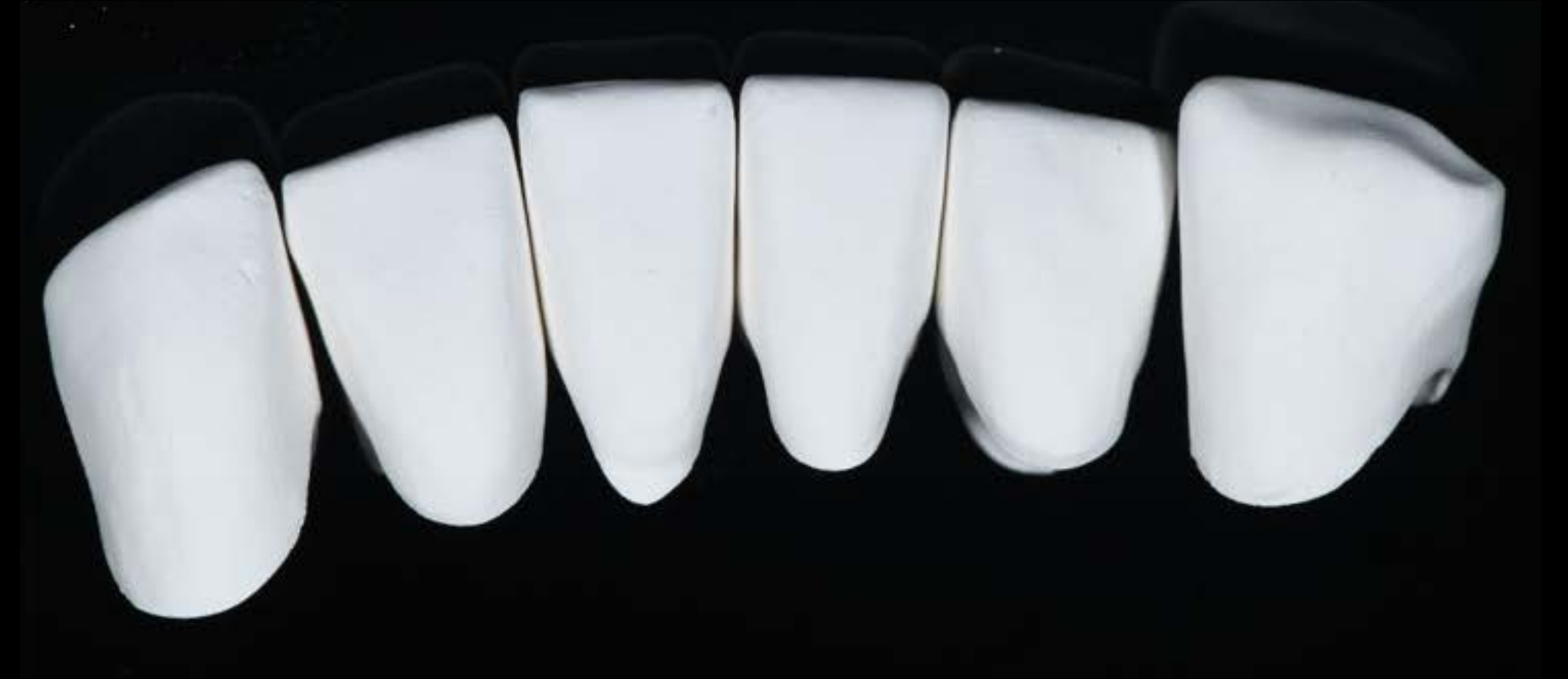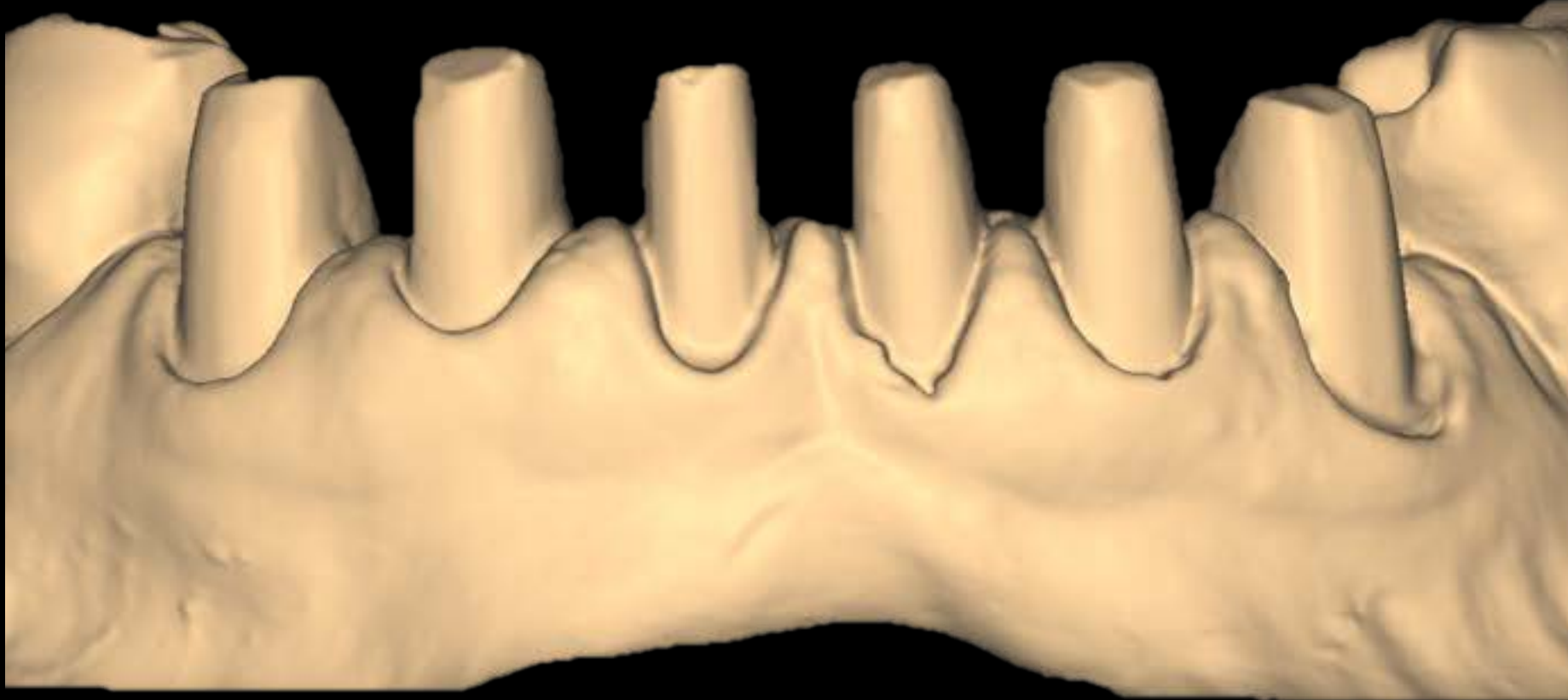Shade Taking : A3



Natural tooth Case_4

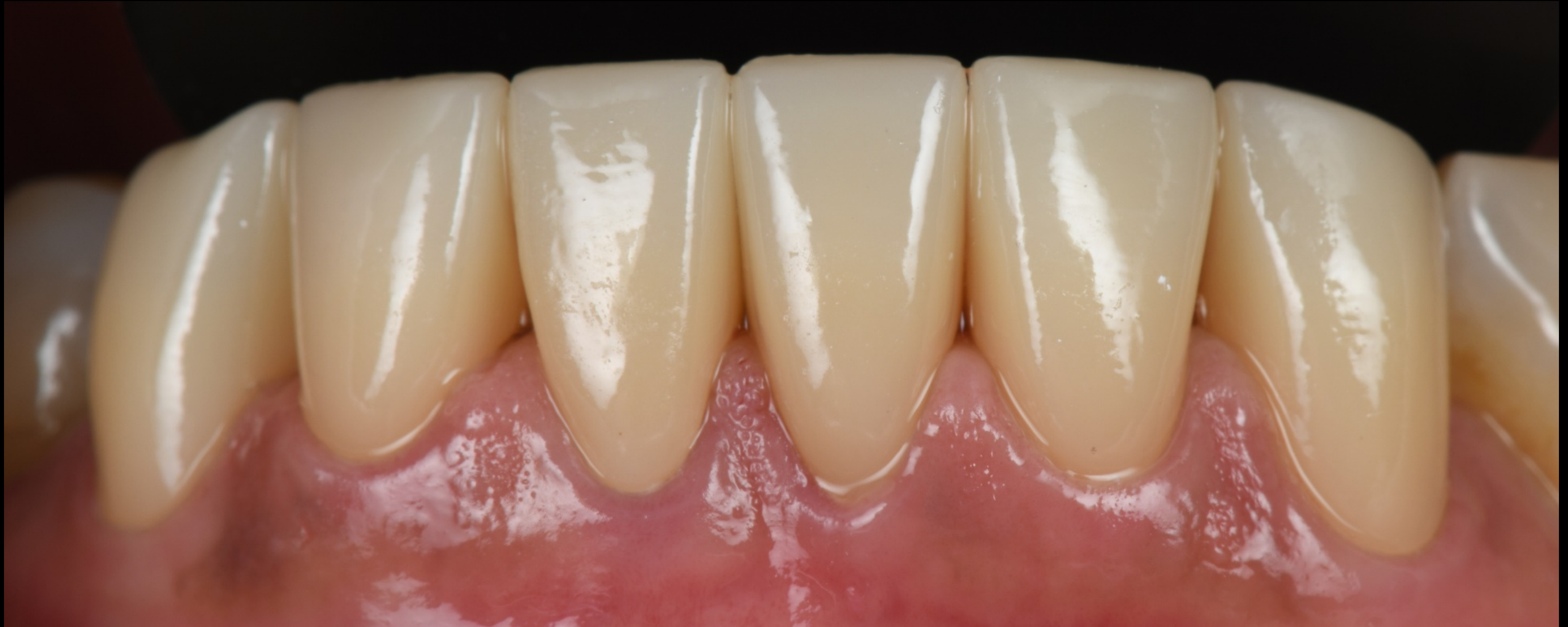

Natural tooth Case_5

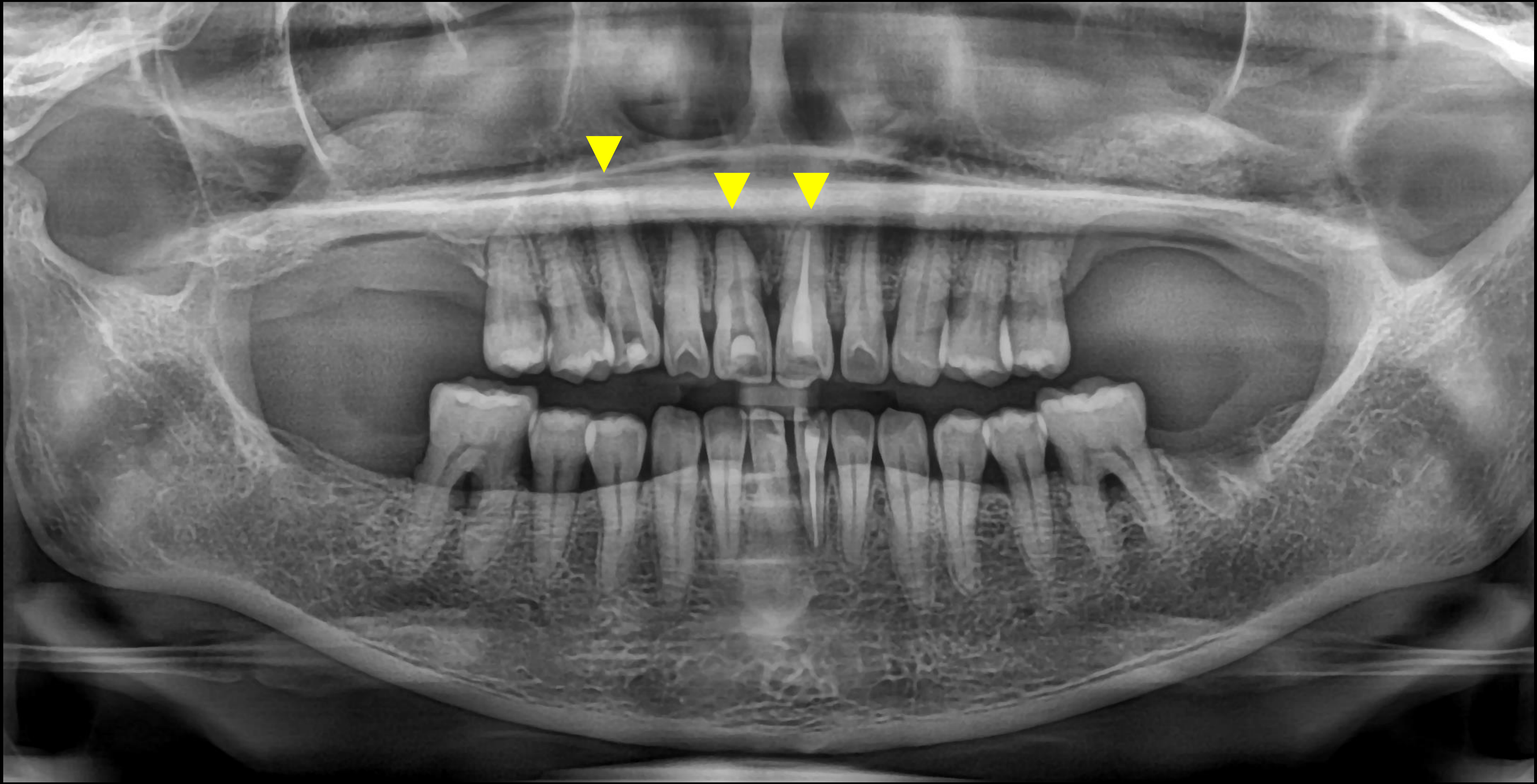


Shade Taking : A3.5

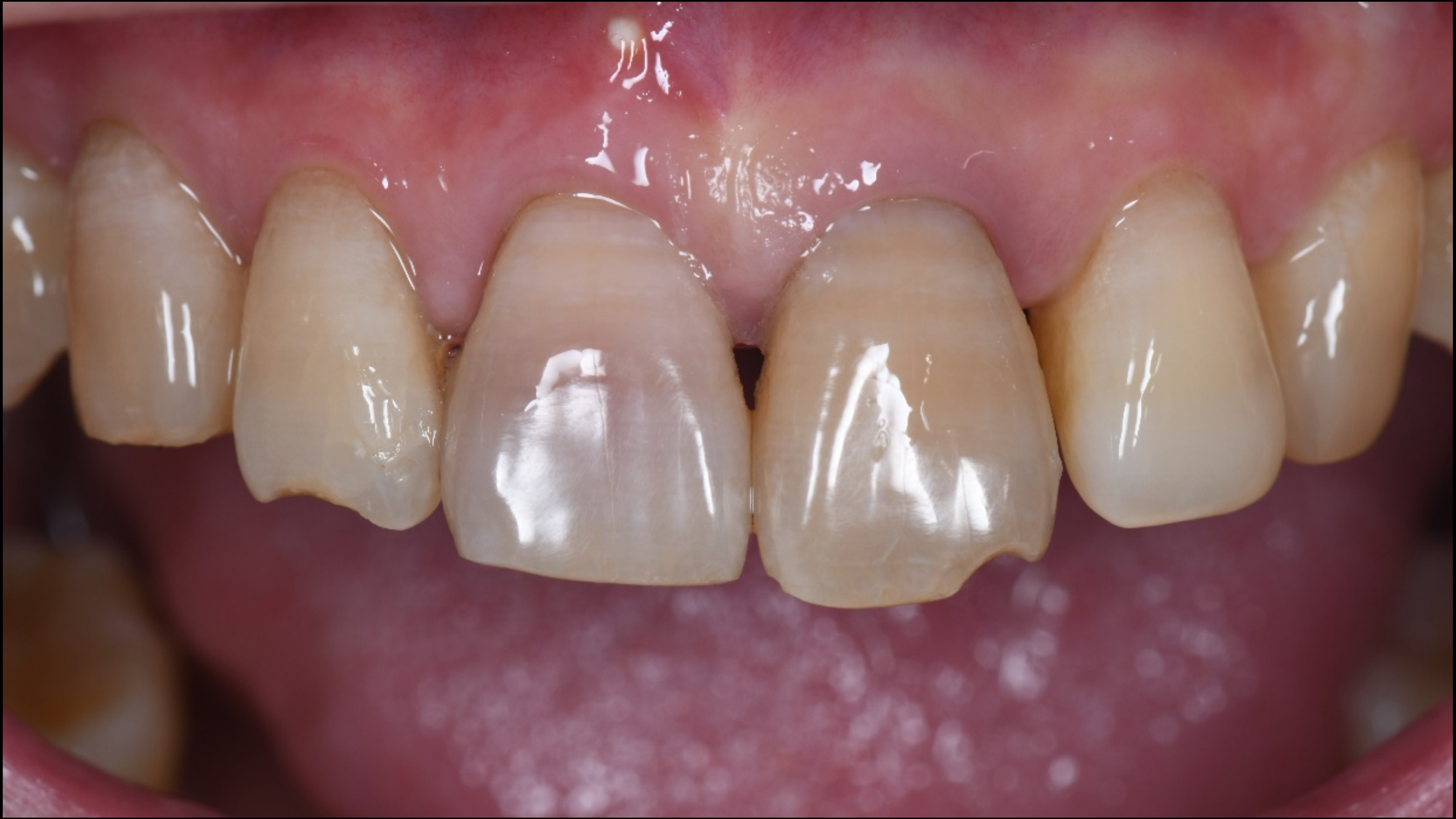Natural tooth Case_5



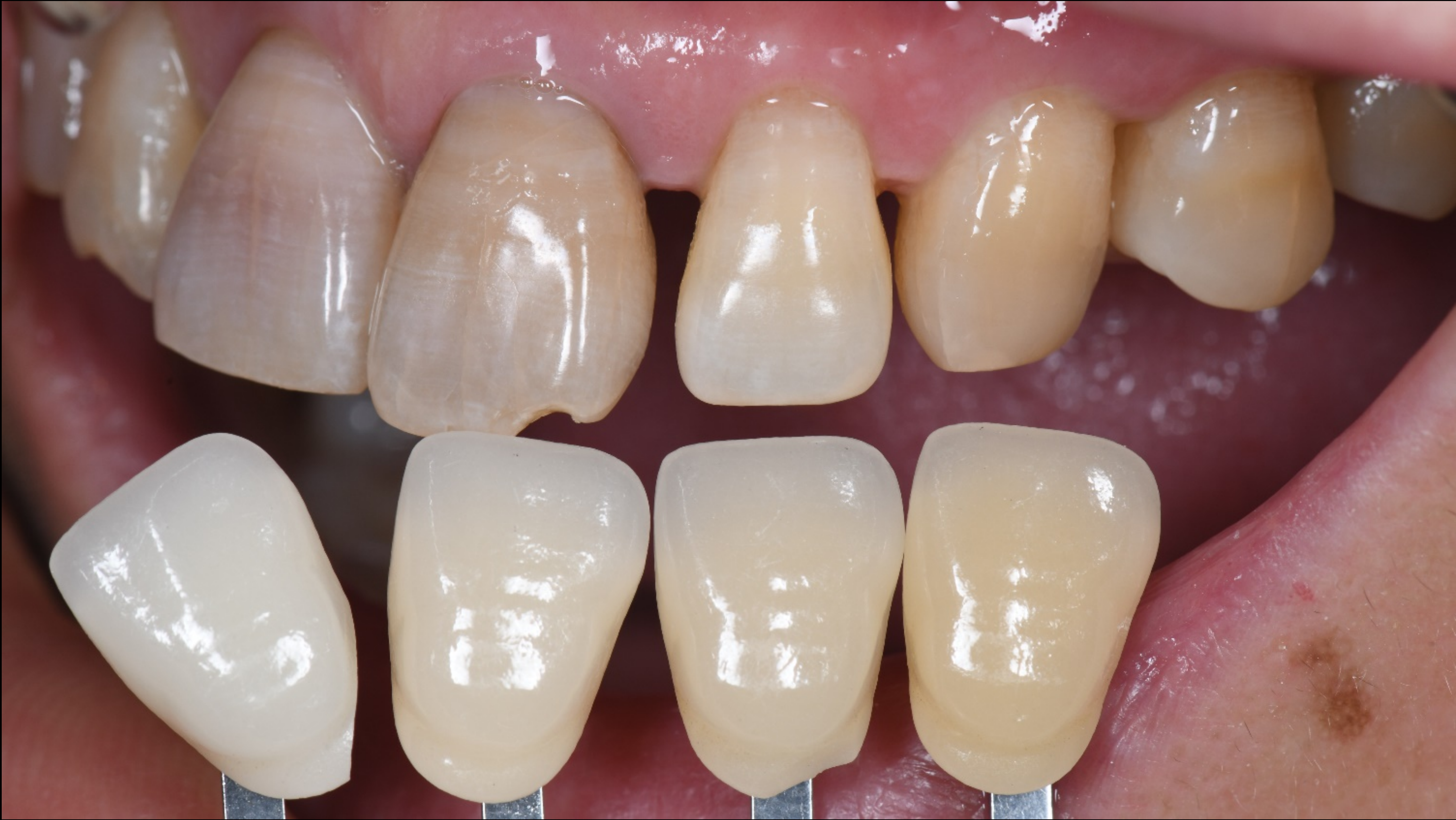Oral exam (2023-09-06)



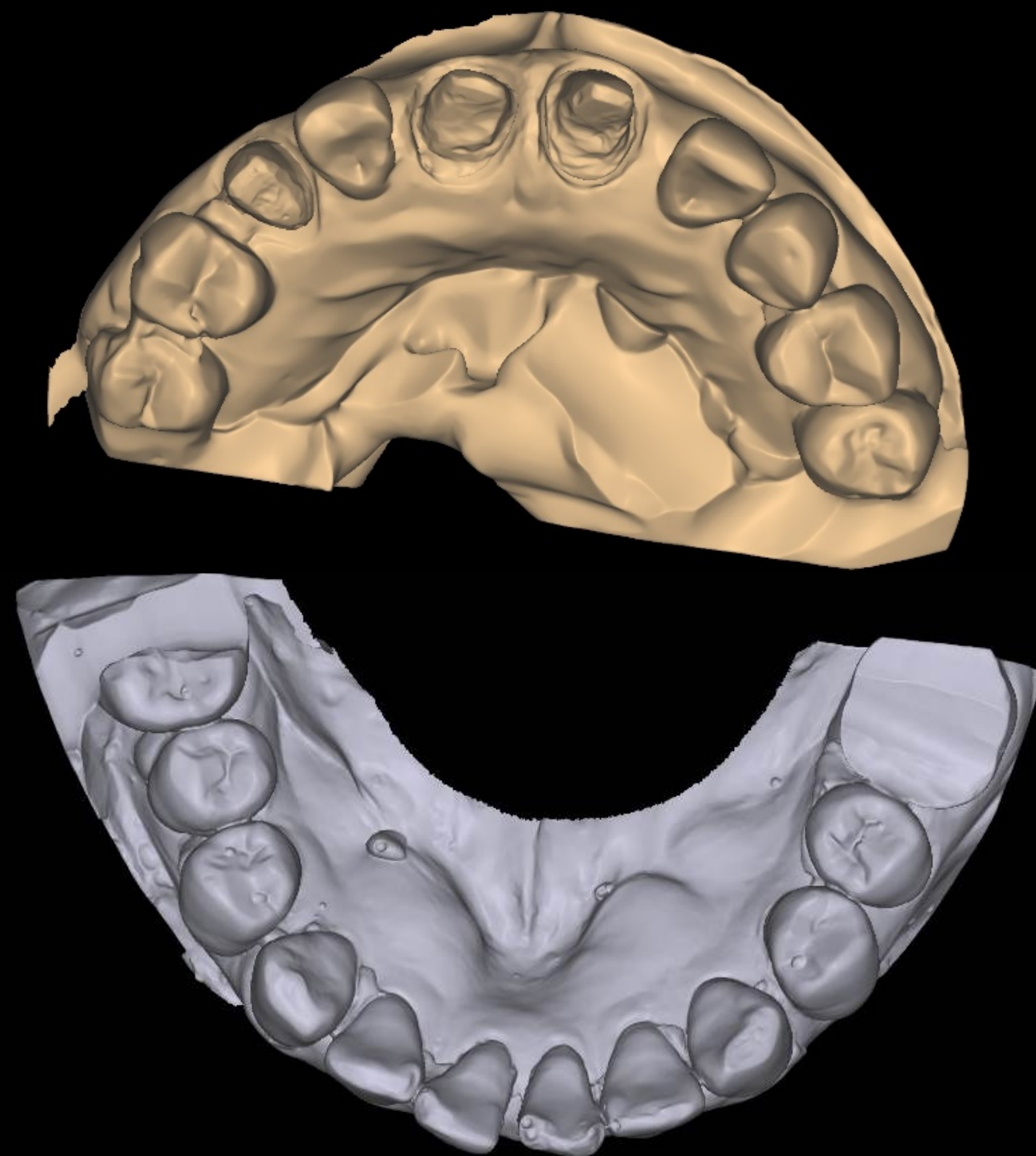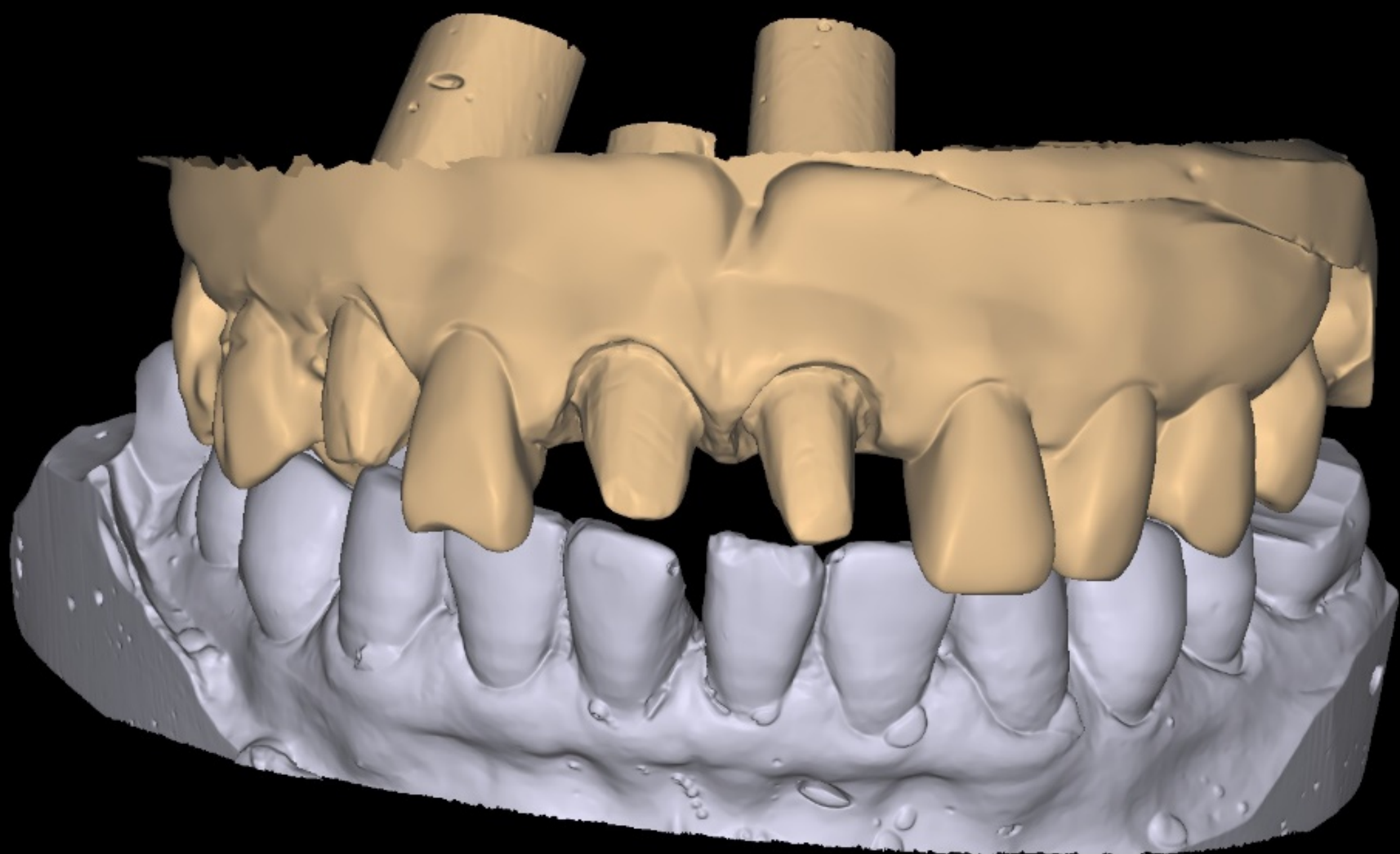
Pre-op (2023-09-06)



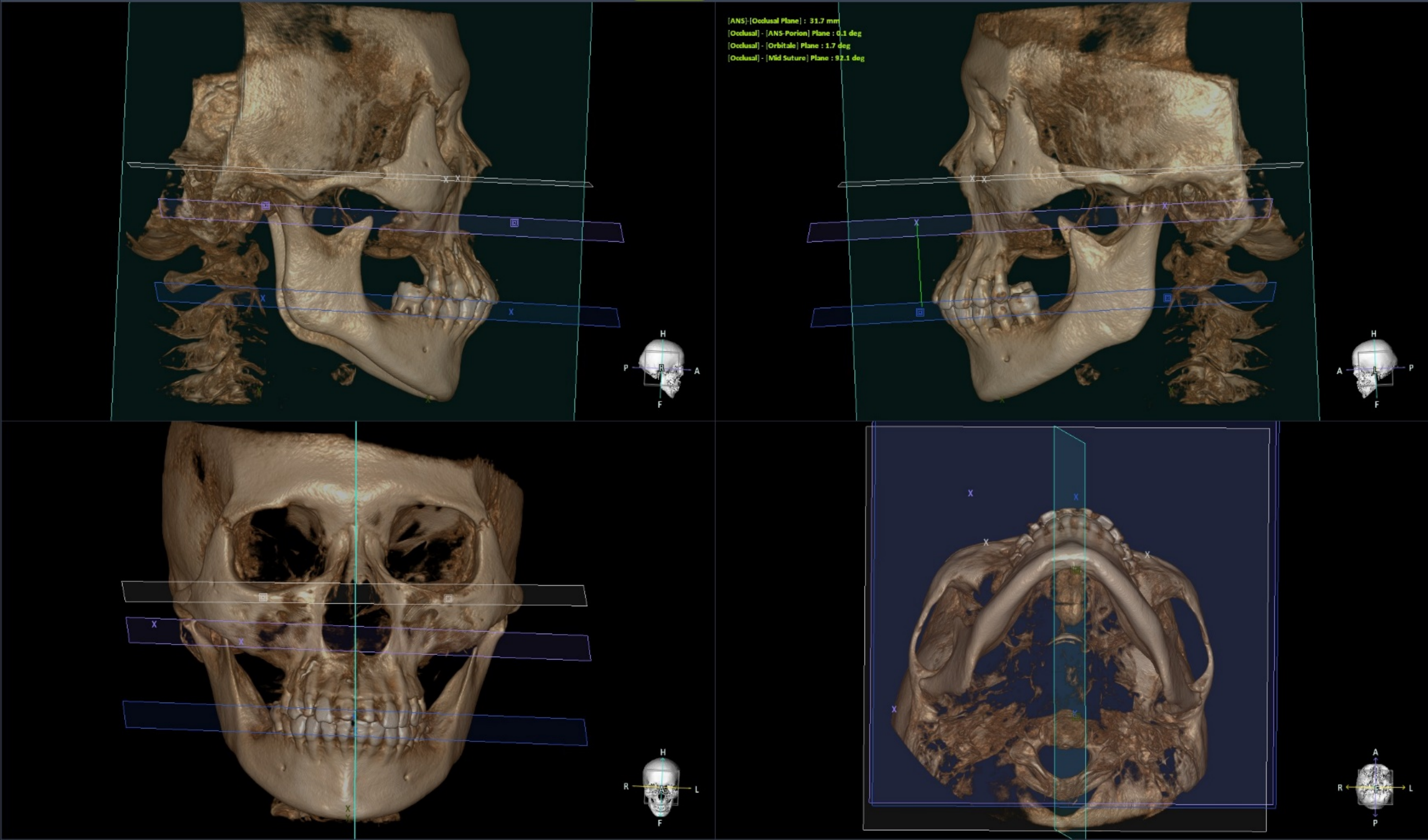
Shade taking (2023-09-06)



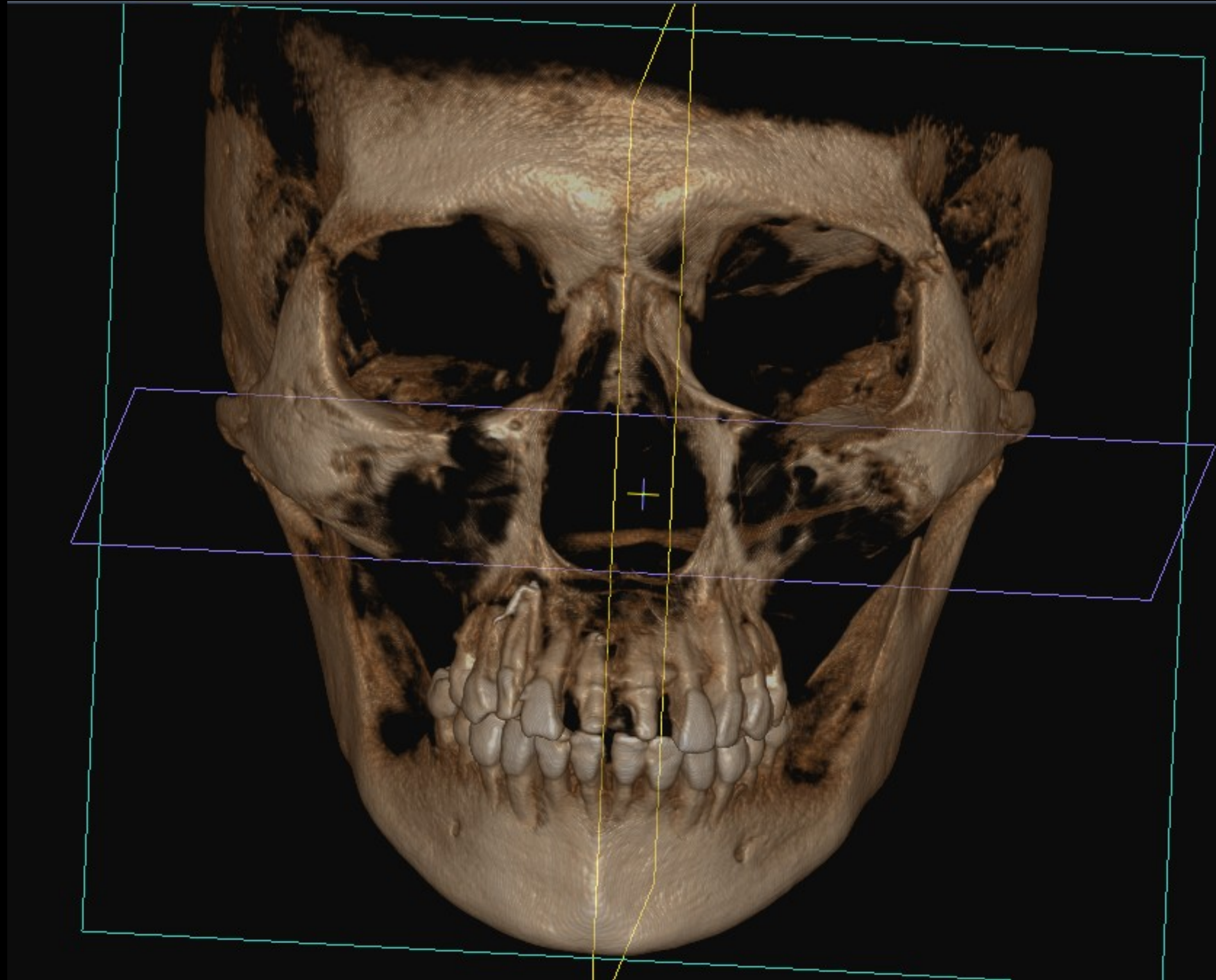
Working model (bite tray impression scan)



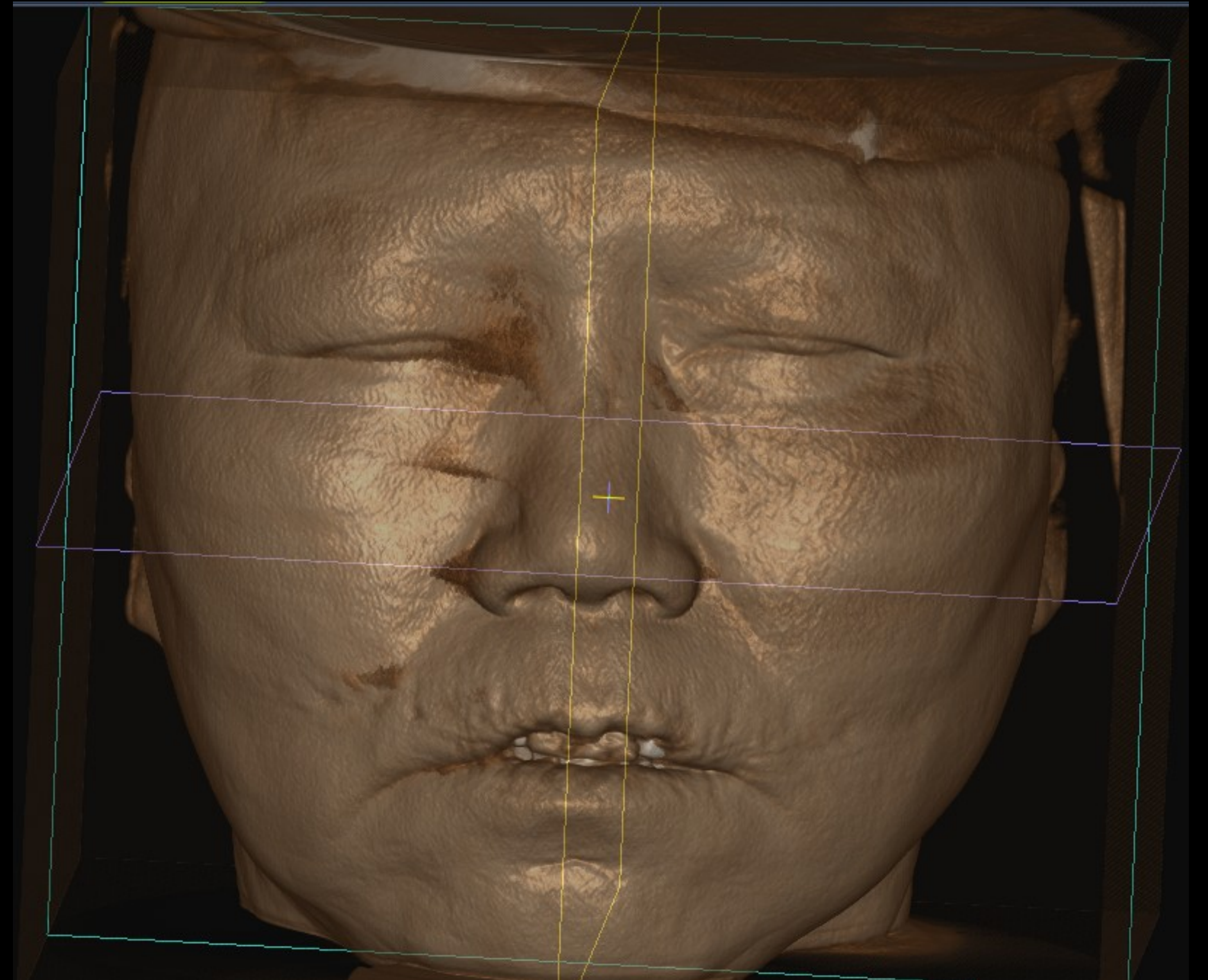
AI Occlusal plane
(rainbow 3D viewer)



CT STL export (rainbow 3D Viewer)

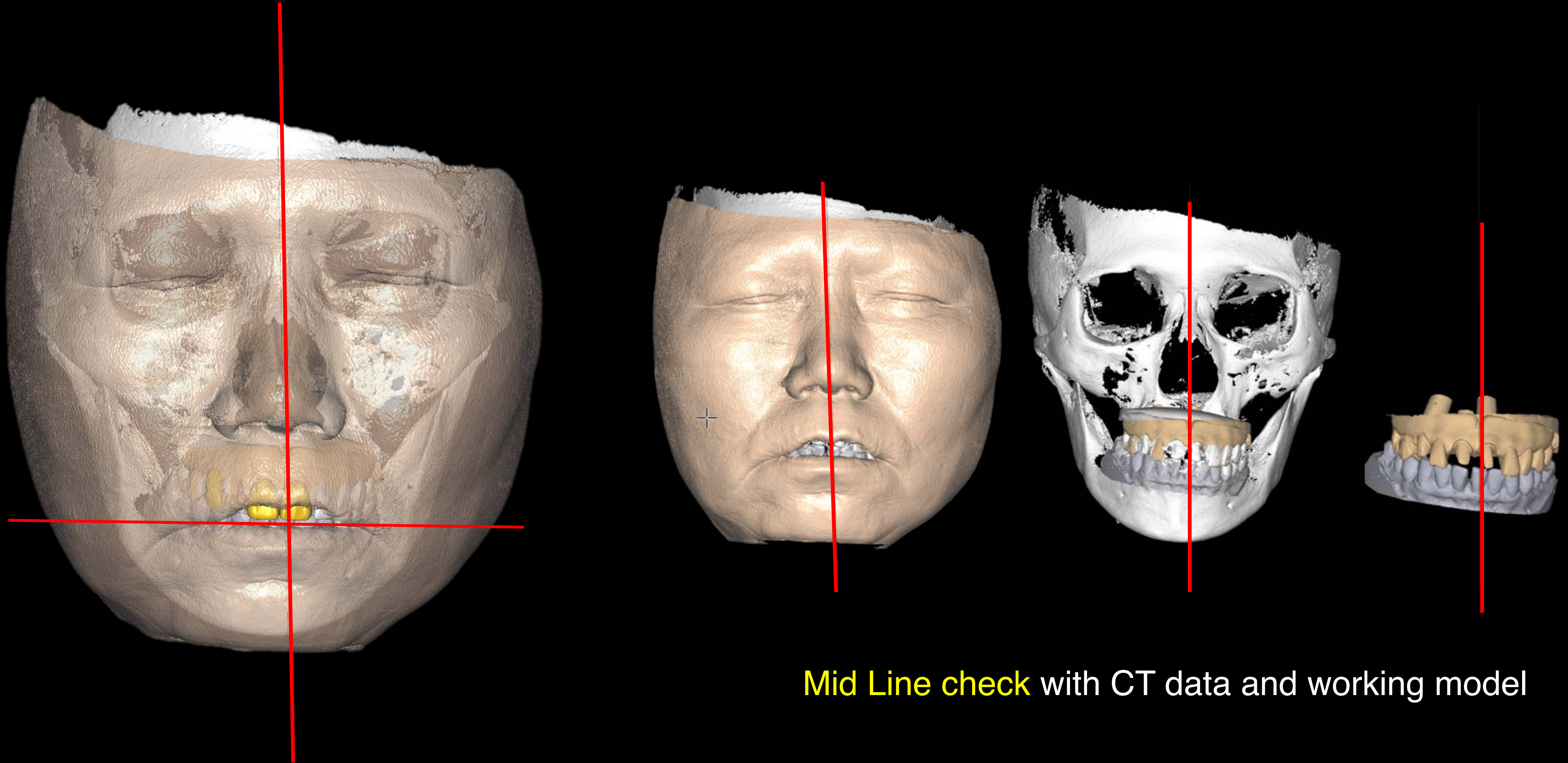


Hard tissue



Soft tissue

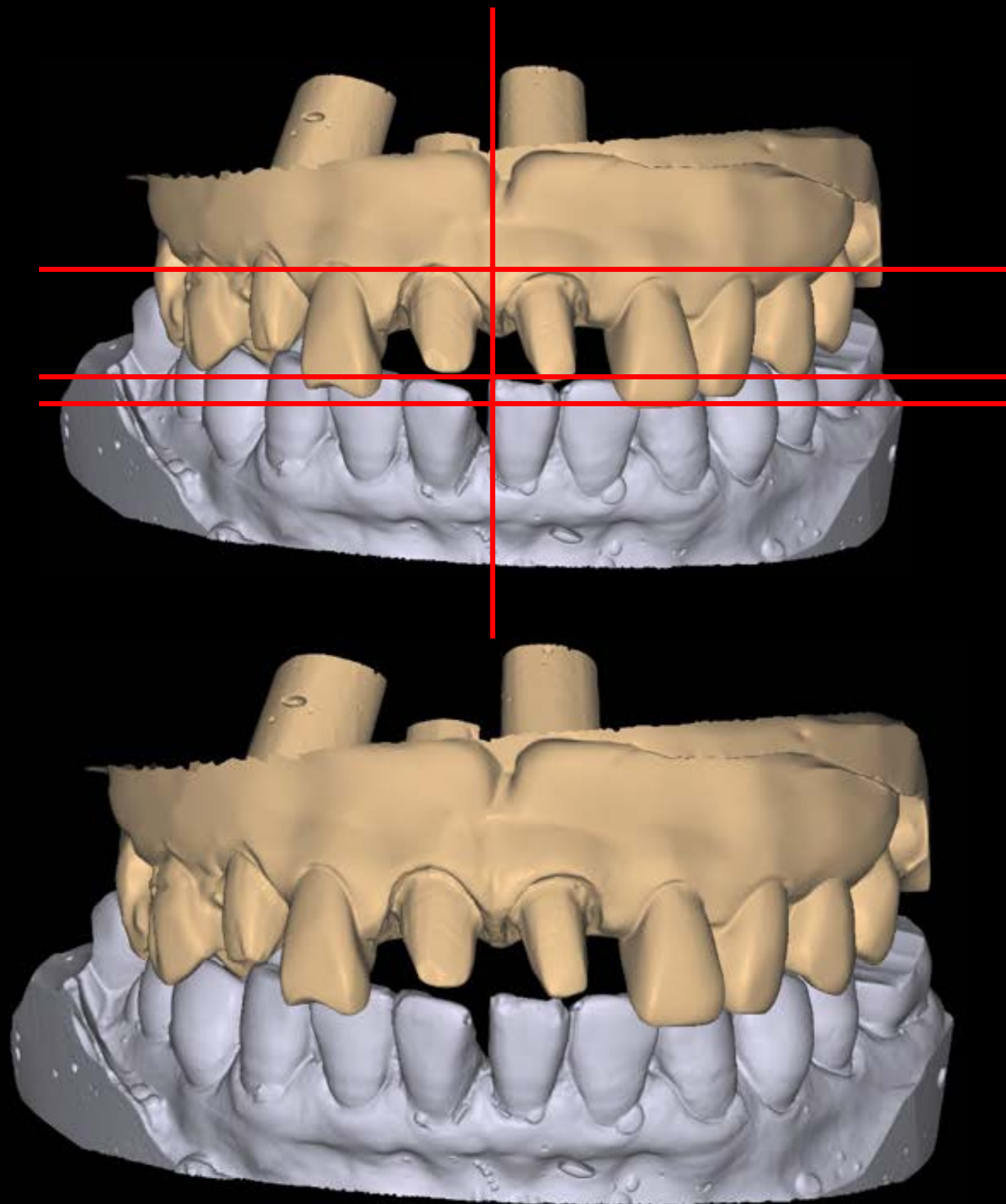
All data stitching
(CT STL + Plane + working model)



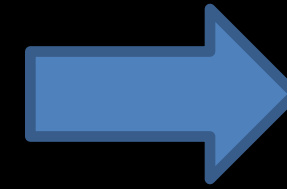
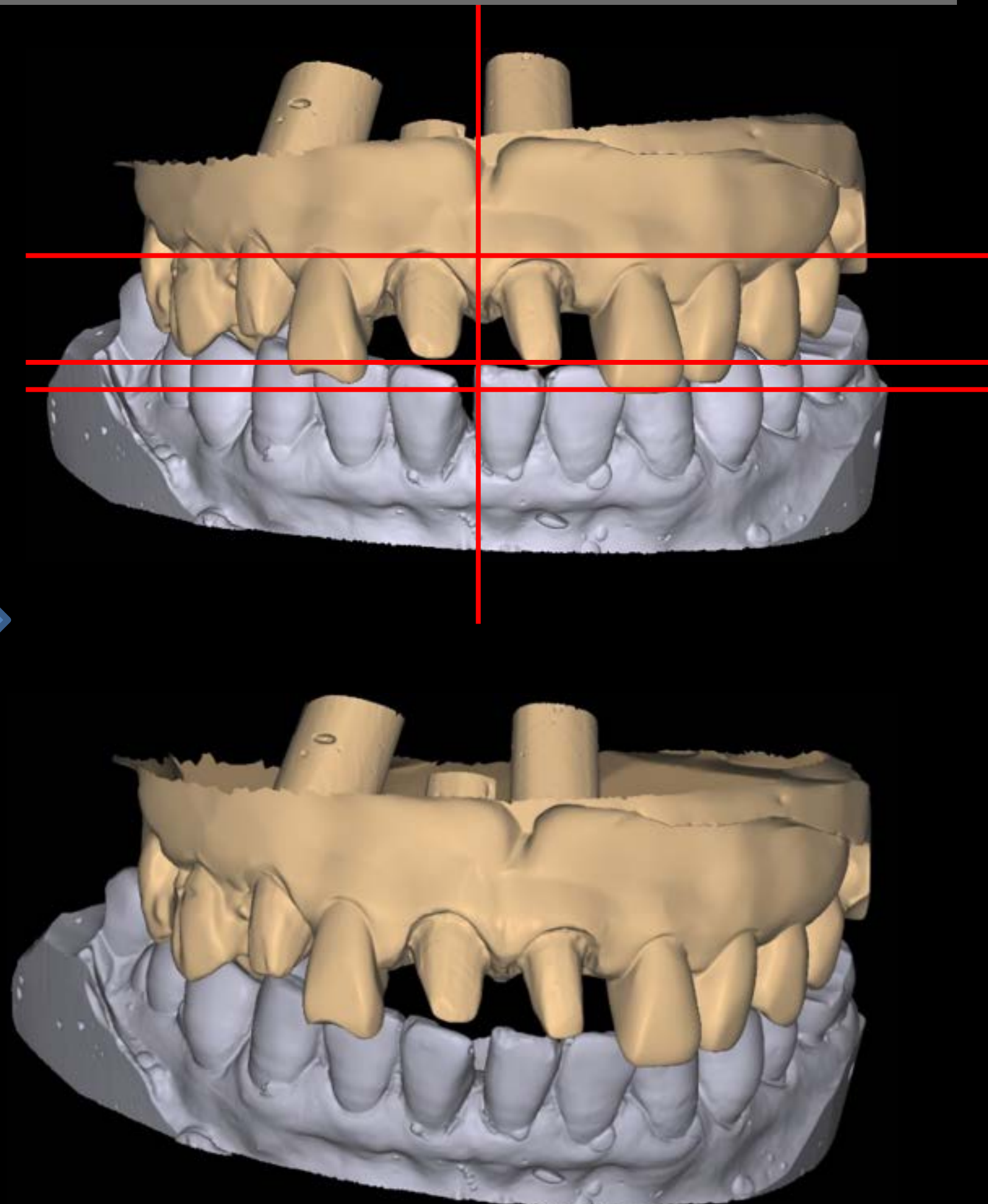
Mid Line check with CT data and working model

Tooth Axis & Mid line check

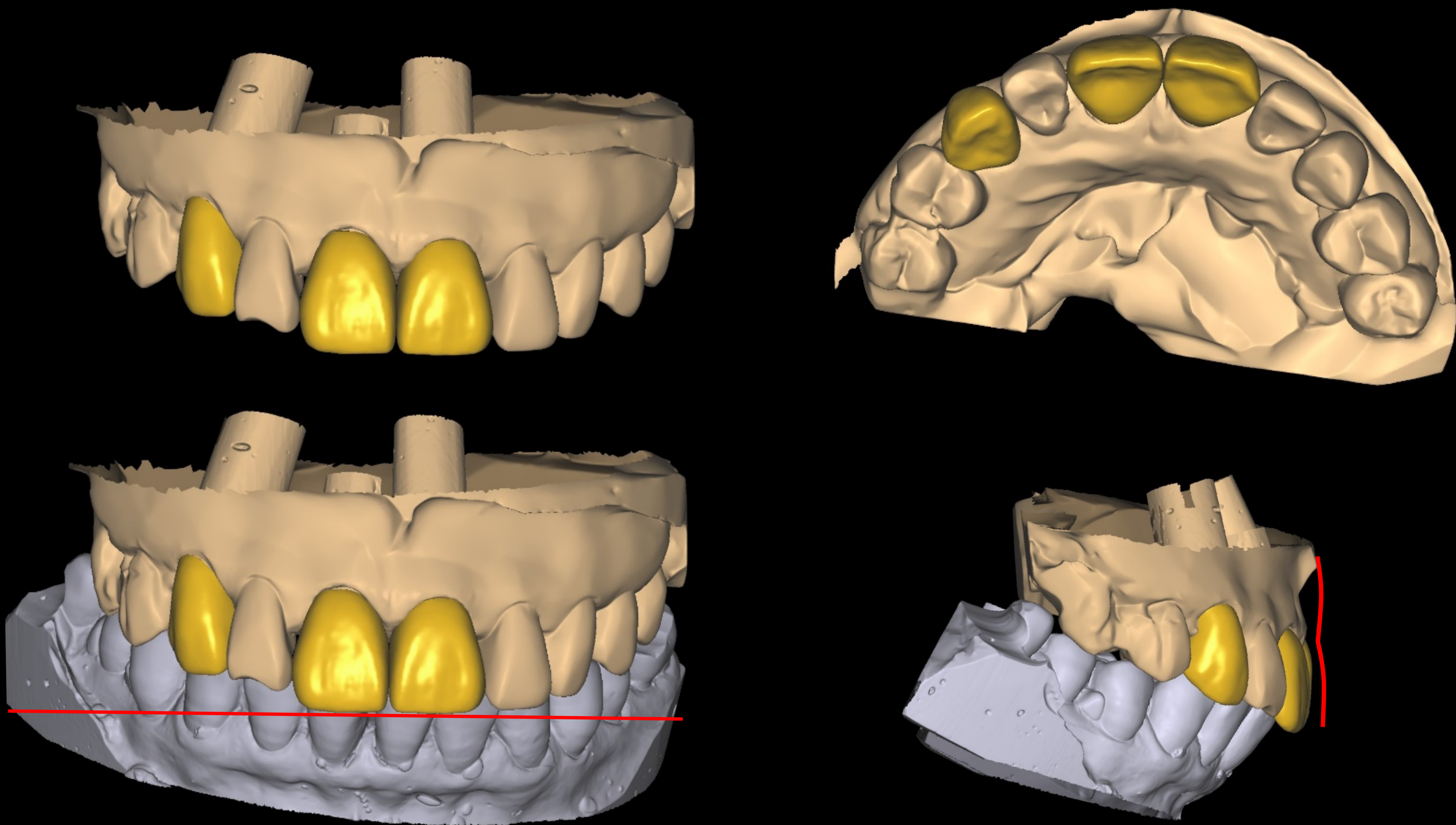
Tooth Axis & Mid Line check
with **only working model**



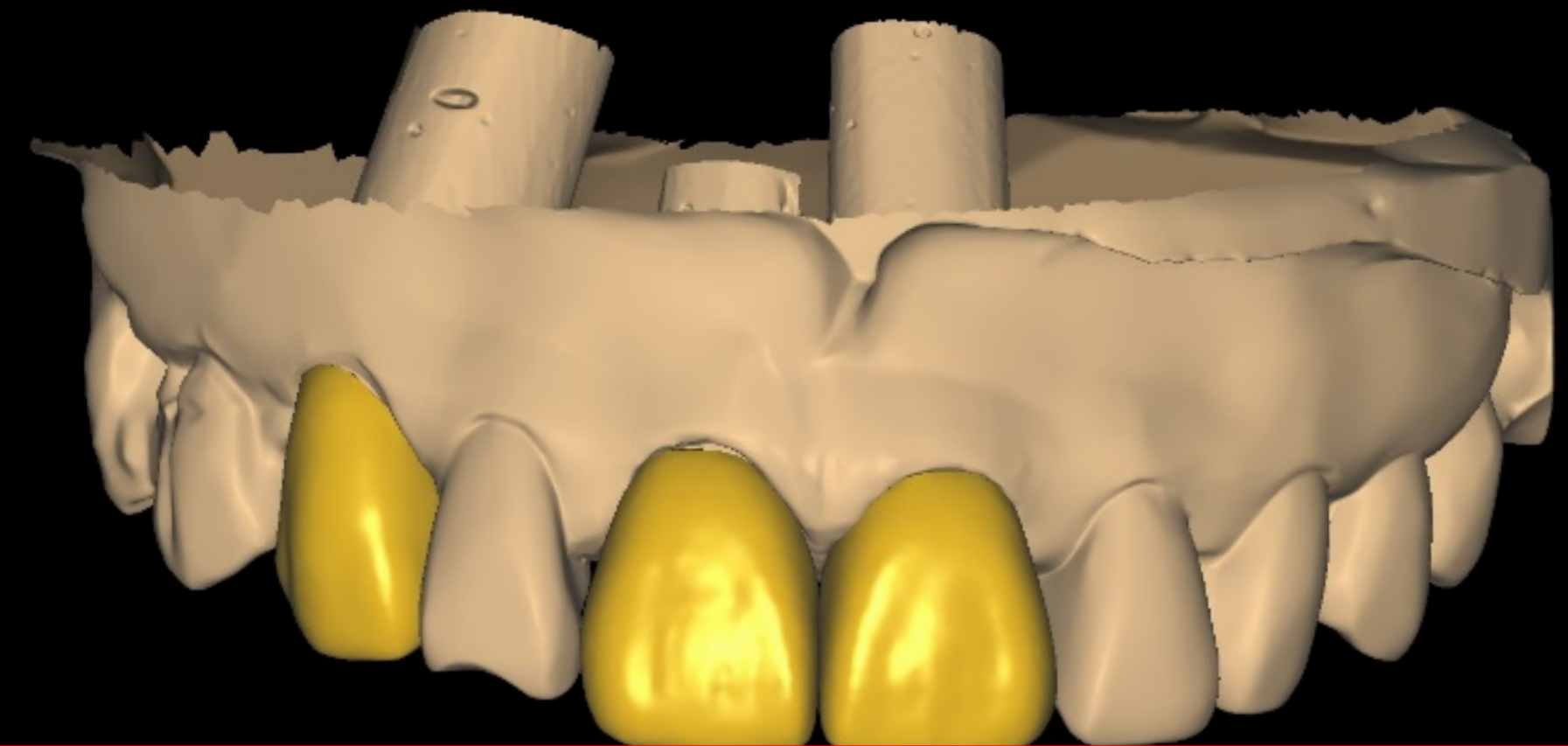
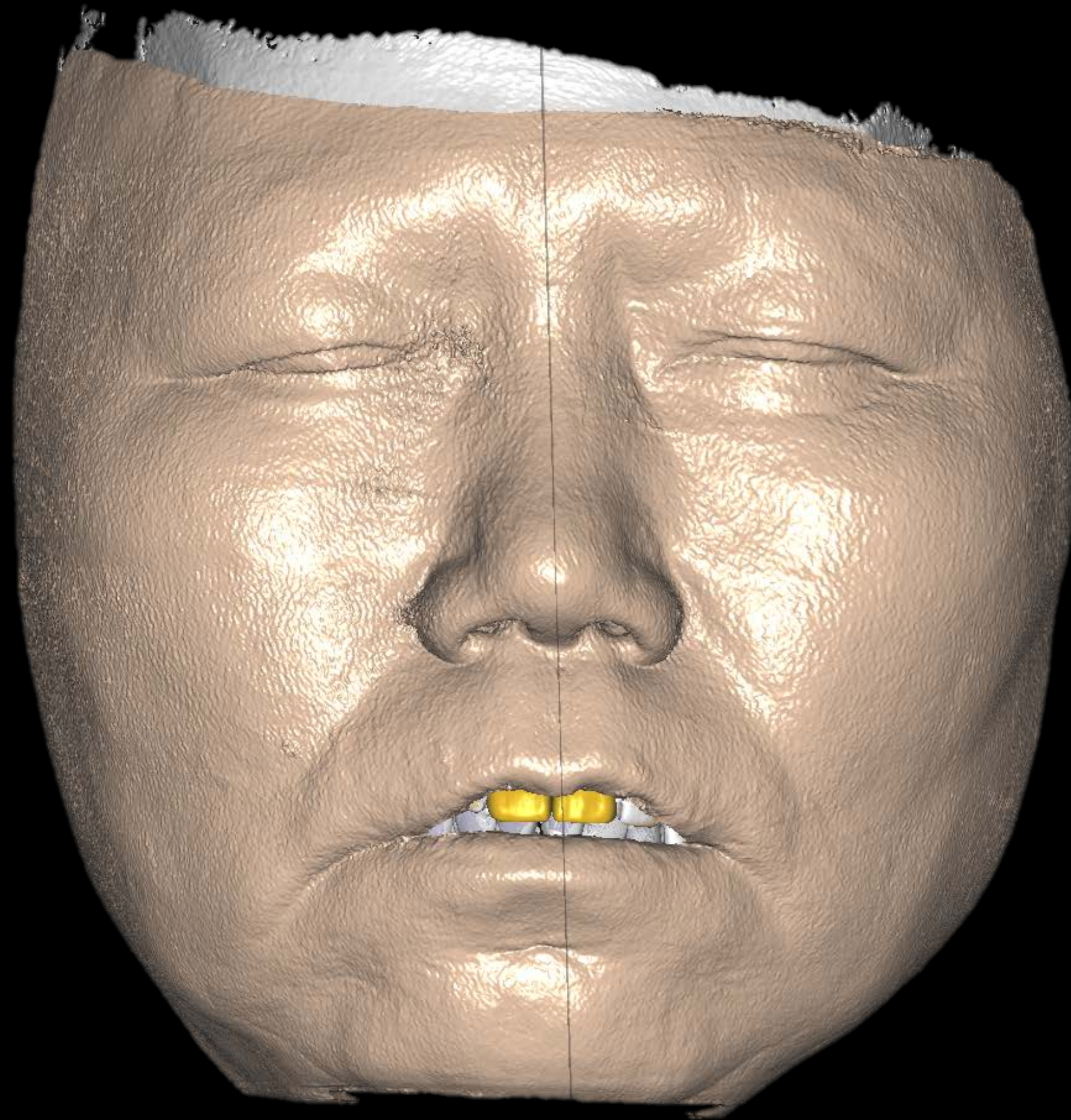
Tooth Axis & Mid Line check
with **CT & working model**



CAD (Final prosthesis)

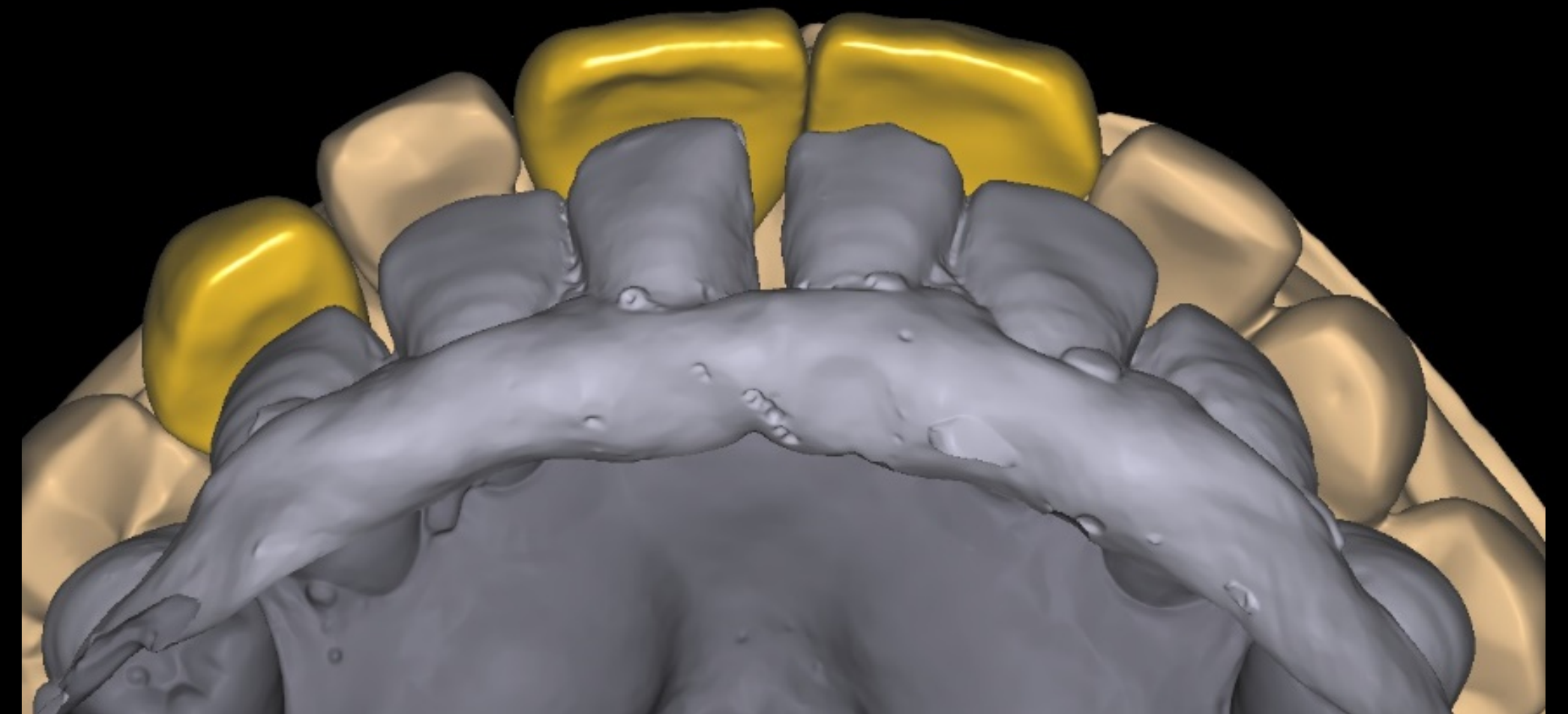
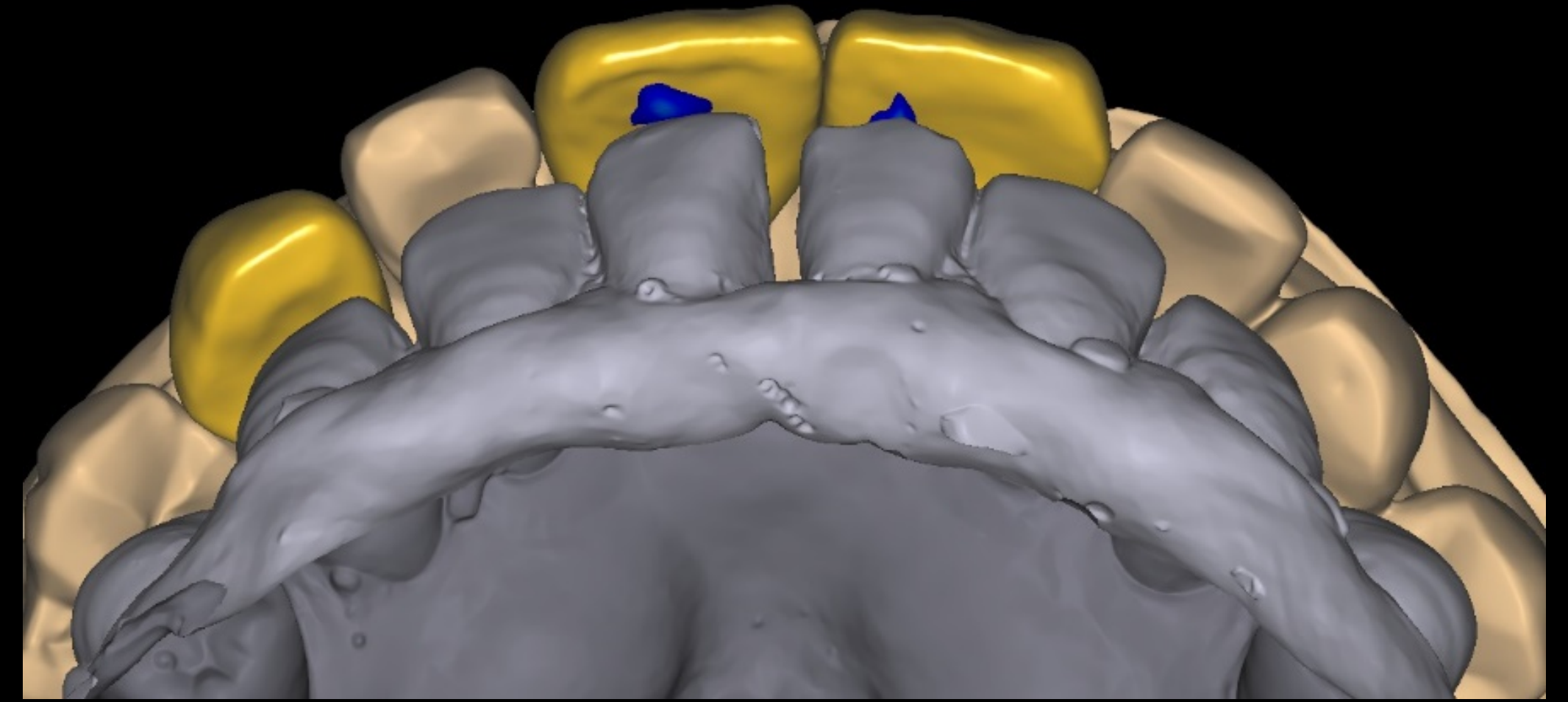
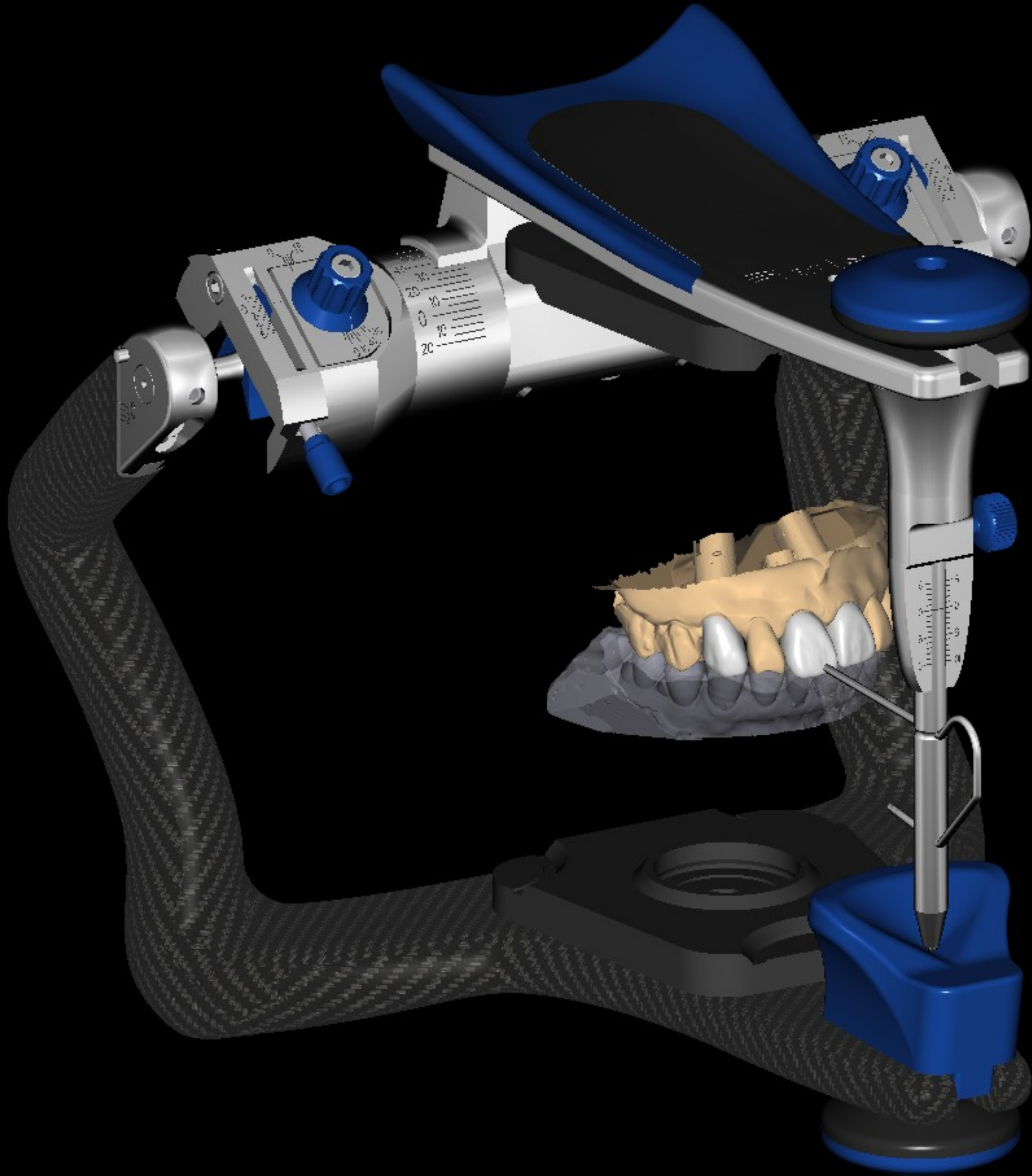


CAD (Final prosthesis)

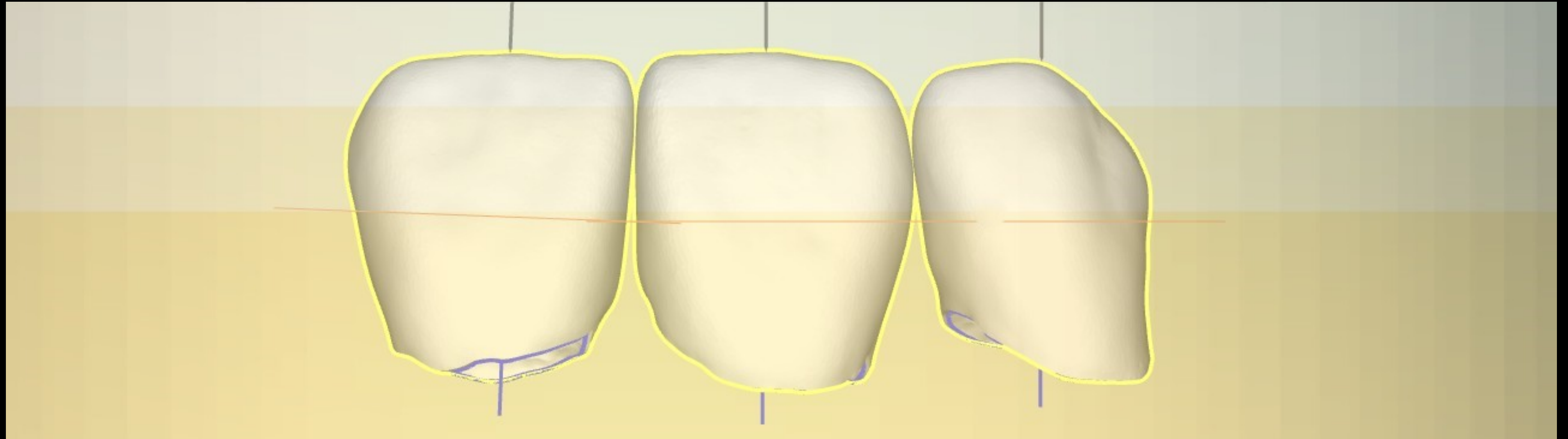


Crown length check with CT soft tissue data

CAD : Mounting with virtual articulator

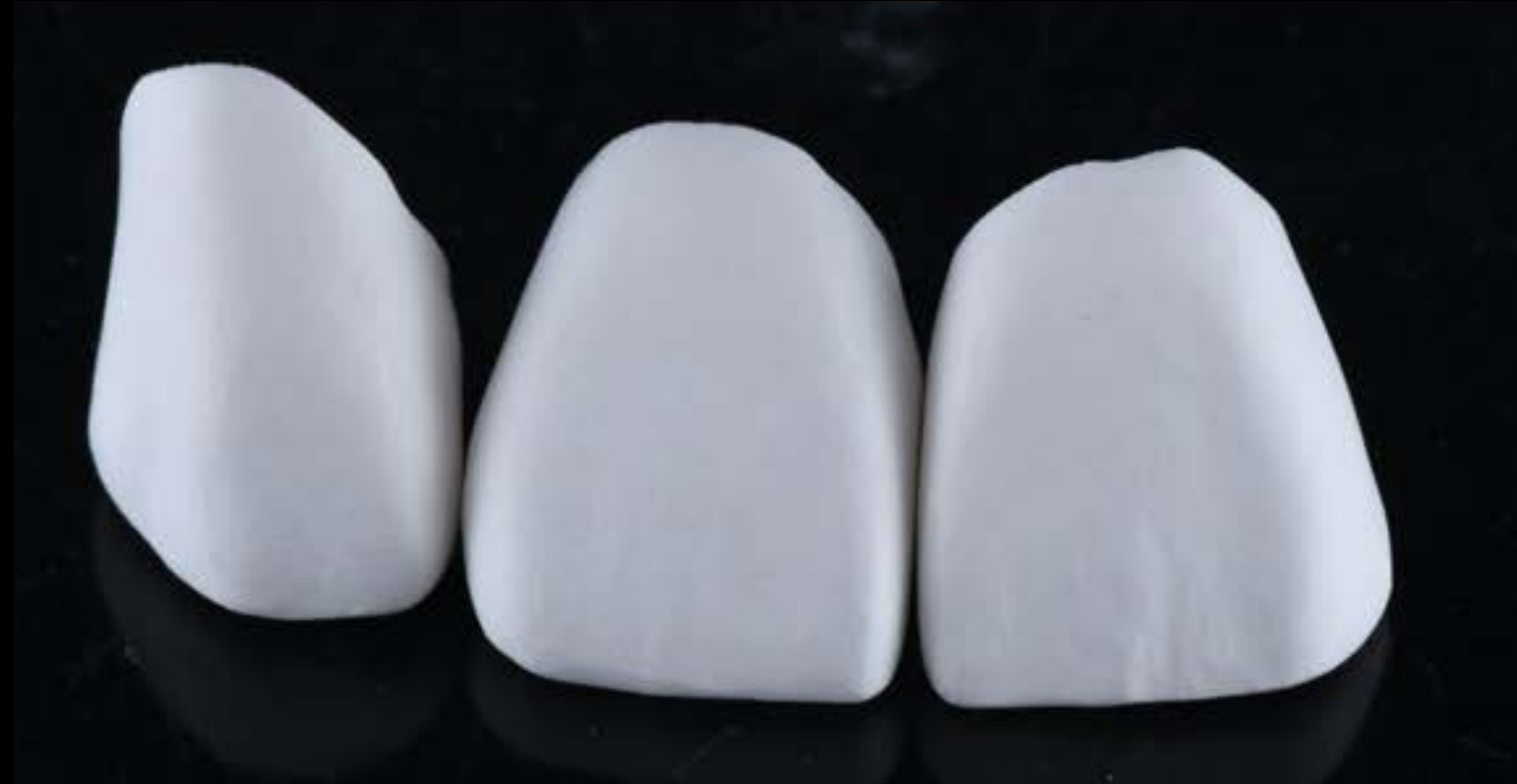

Hyper dent

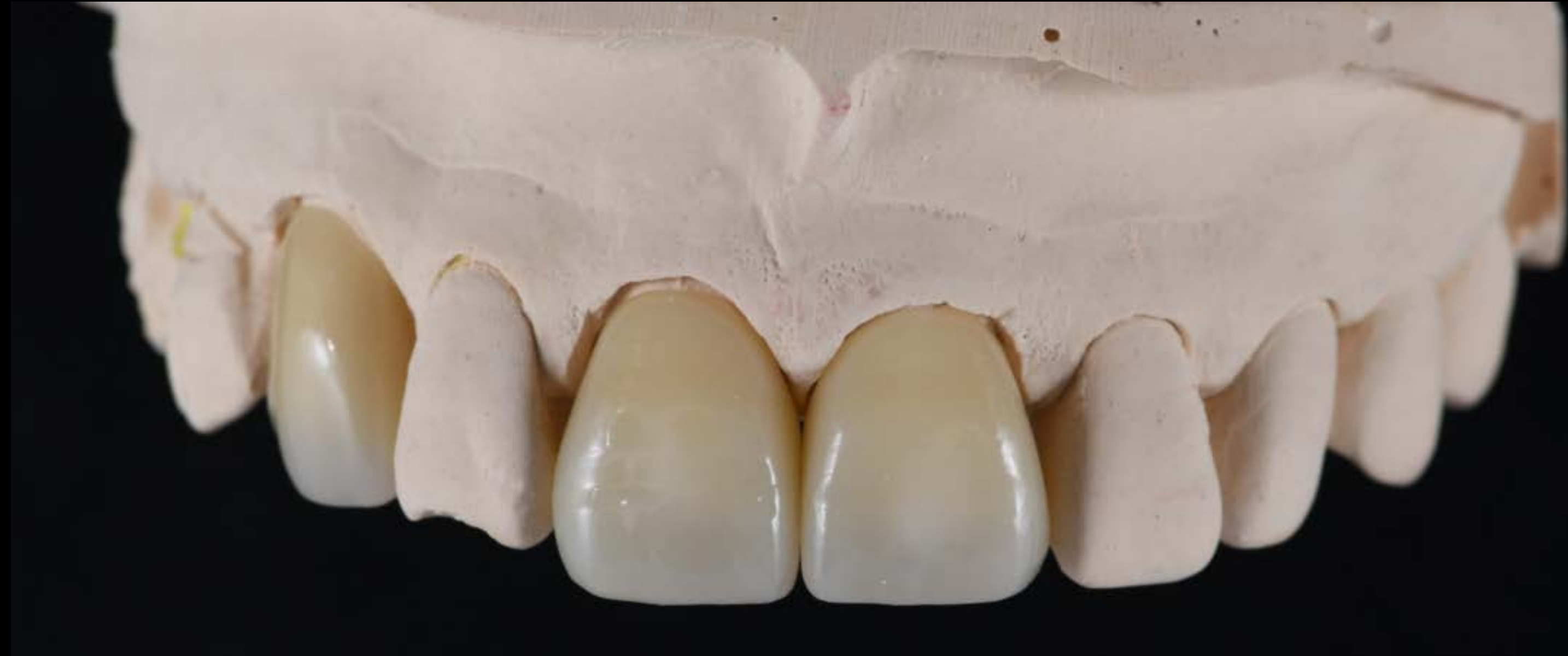

18T 3 Layer Block

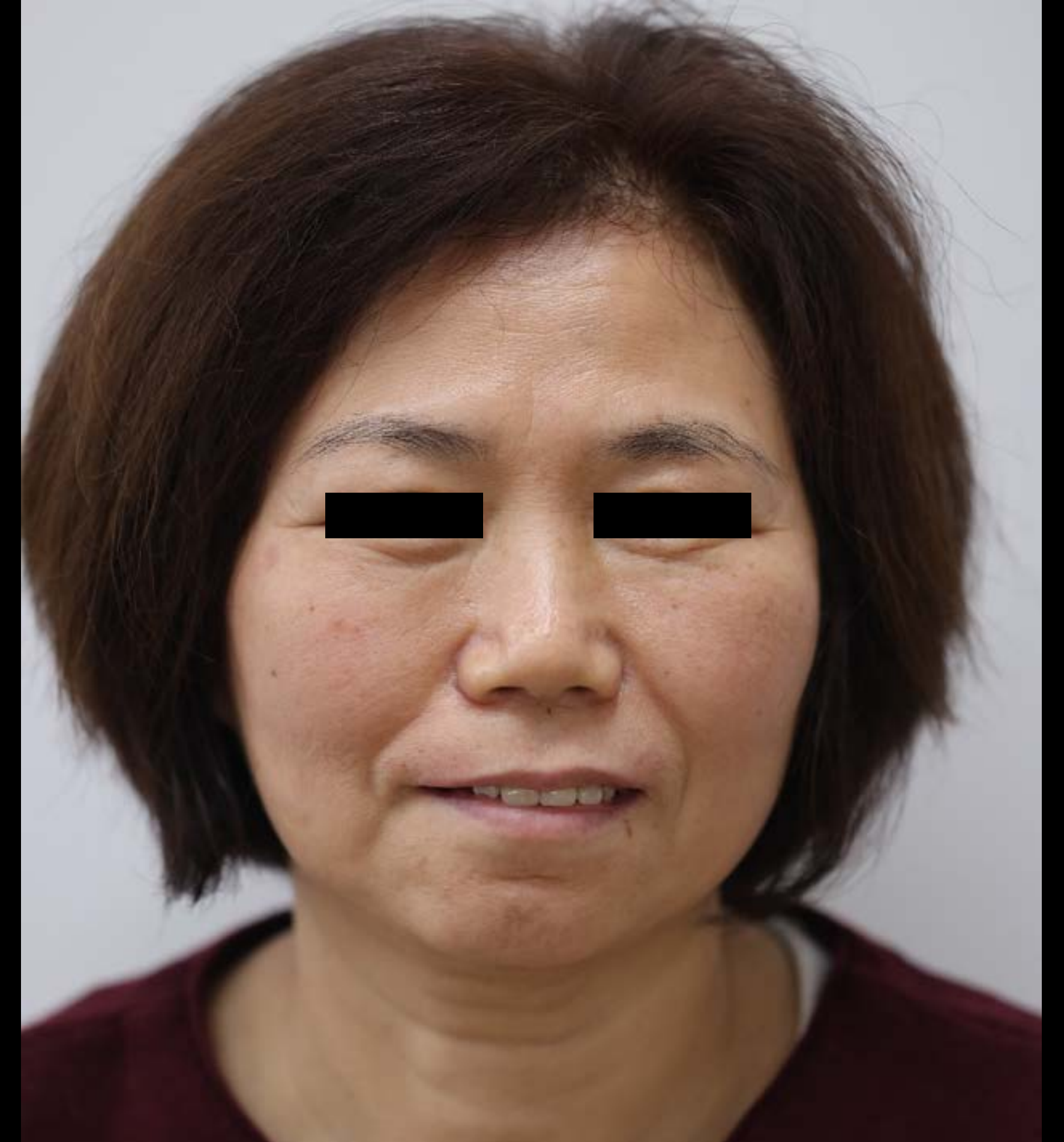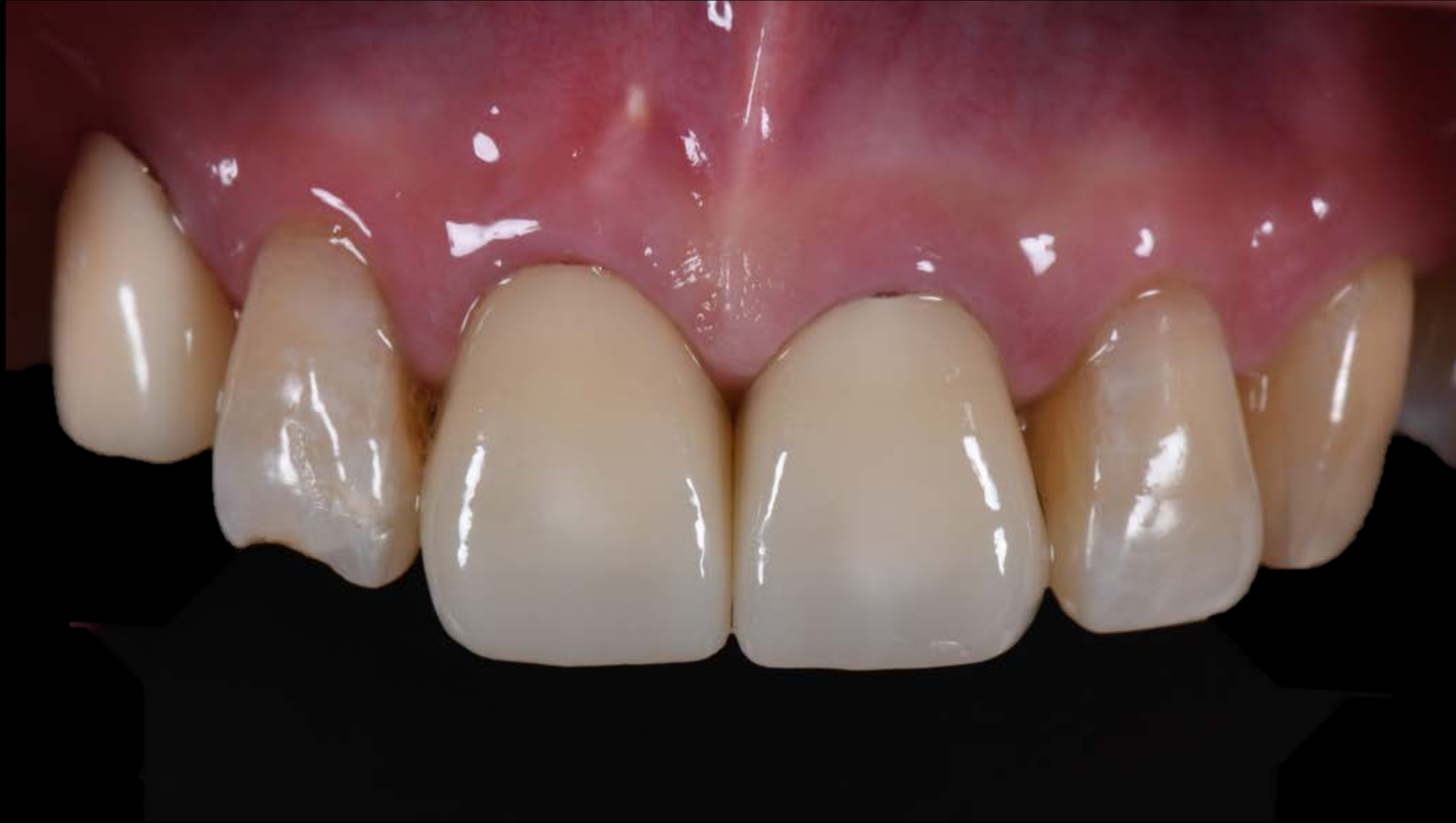Milling / Coloring / Glazing



Inner – White Opaque

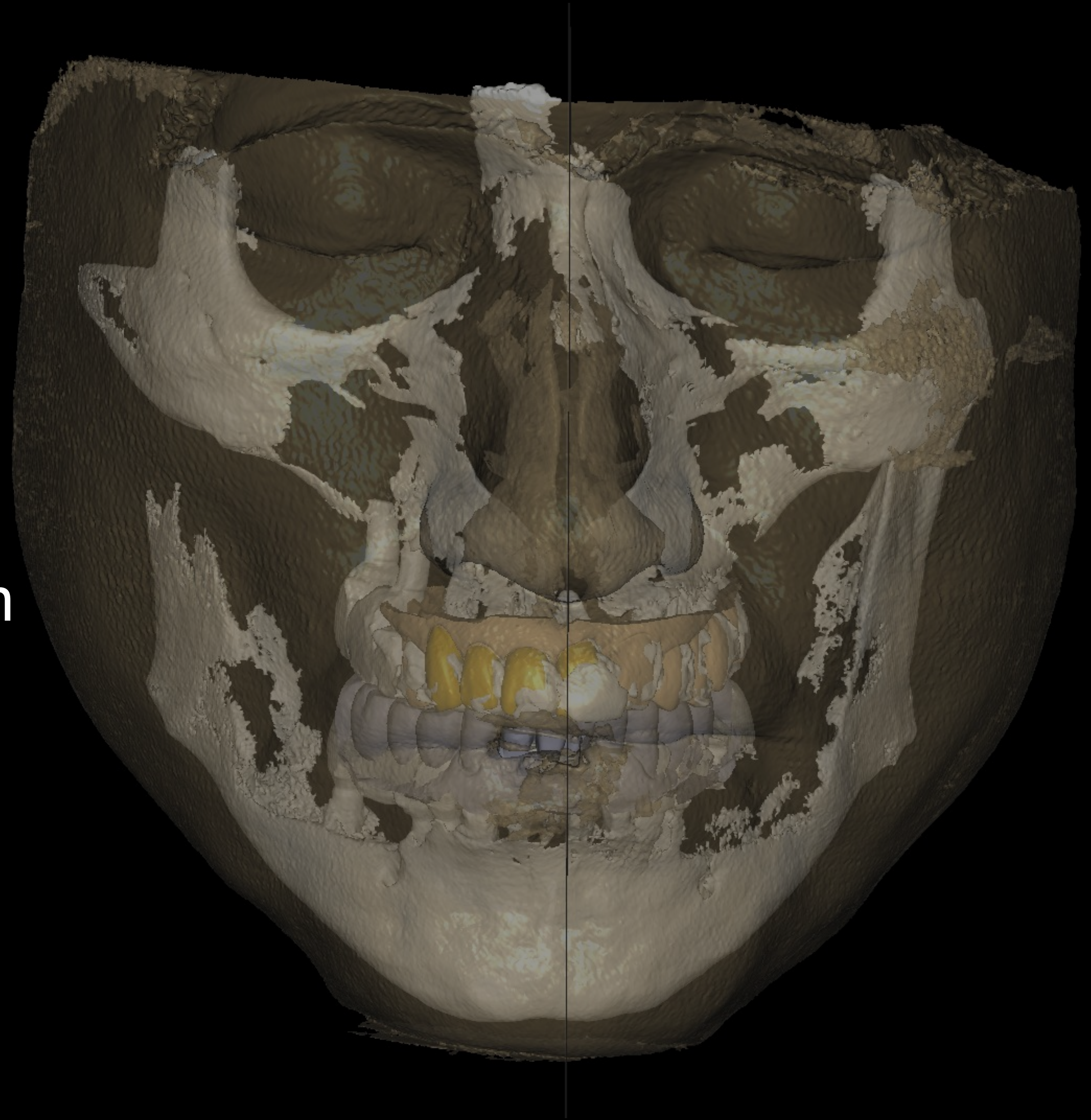

Final prosthesis

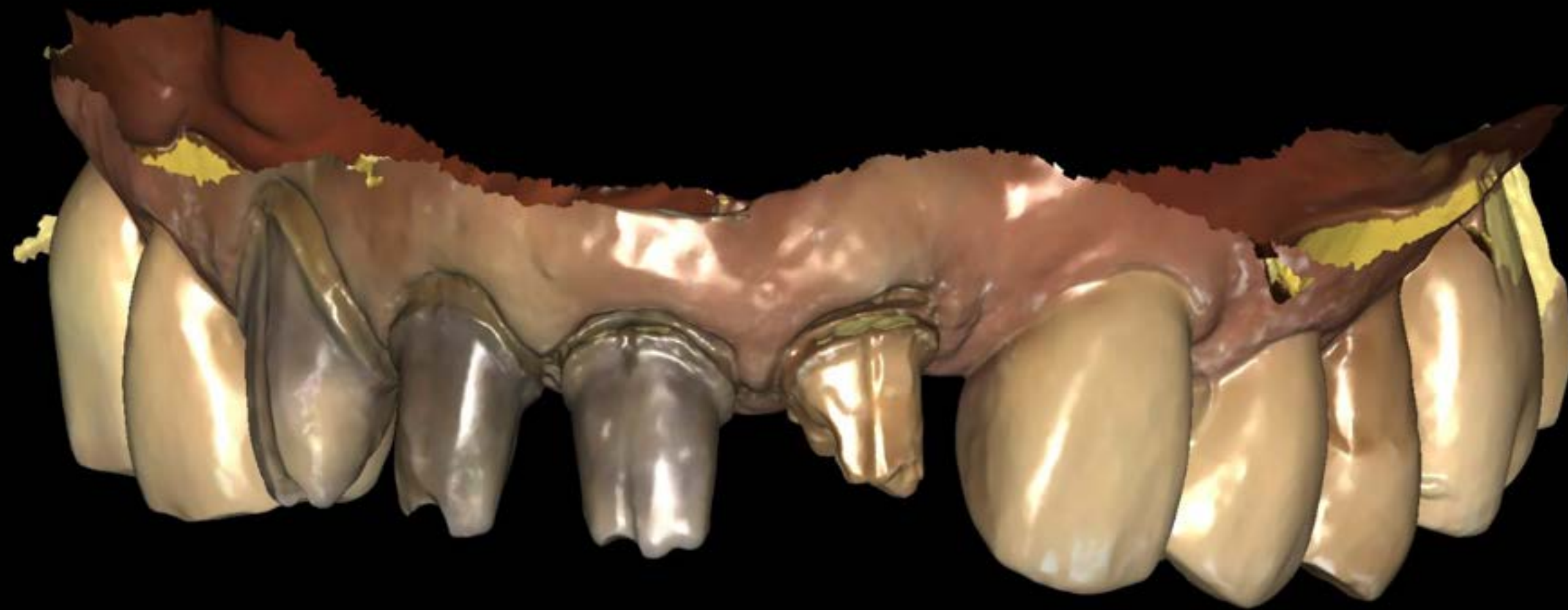


Virtual Set-up

Very effective with pts commutation
Systematized approach for tx




Case report



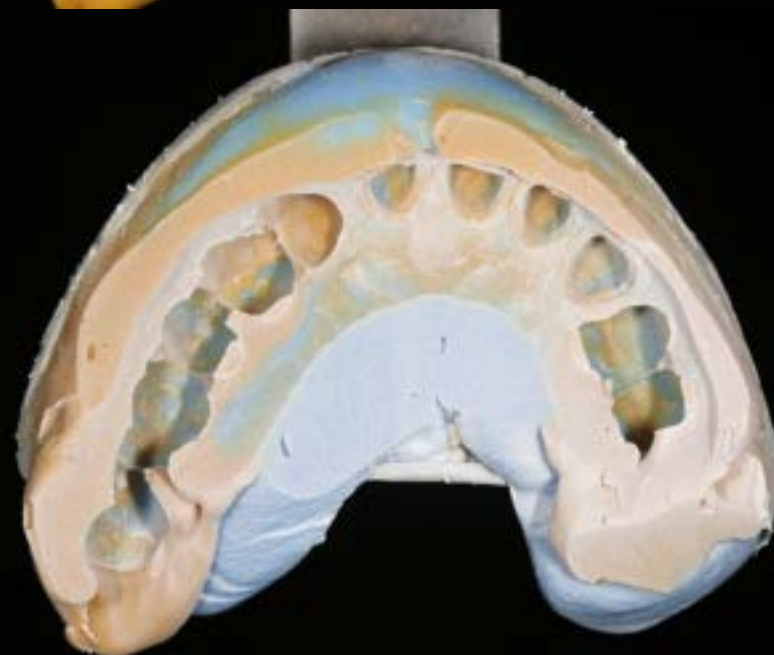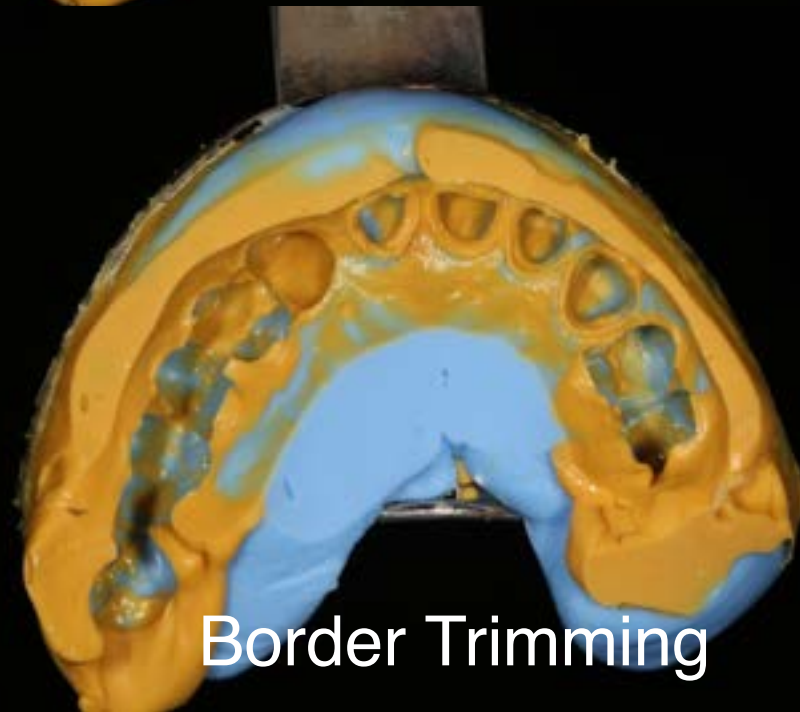
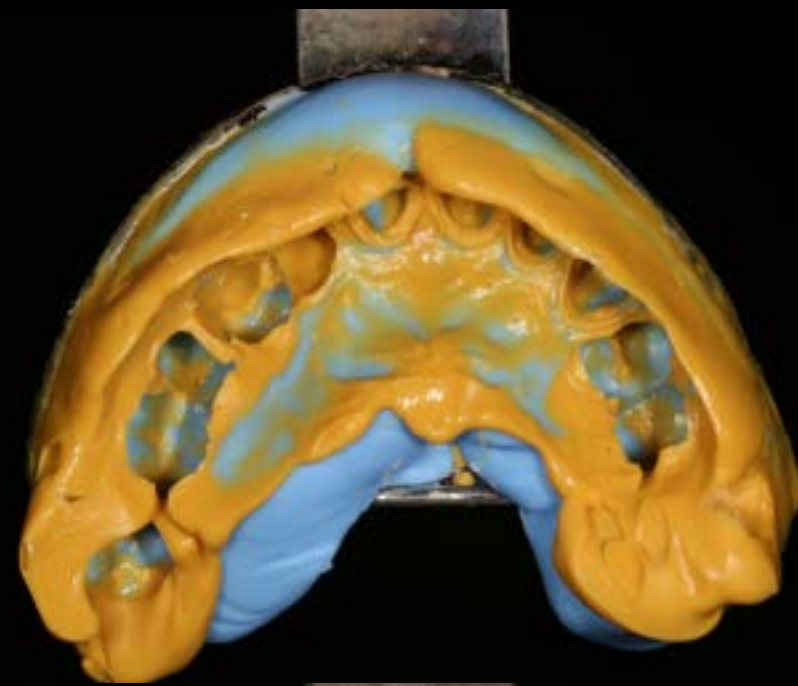
- # 13, 12, 11, 21
- Natural Teeth
- bright 3 Layer
- Shade A3

Virtual Set-up combined with facial scanner



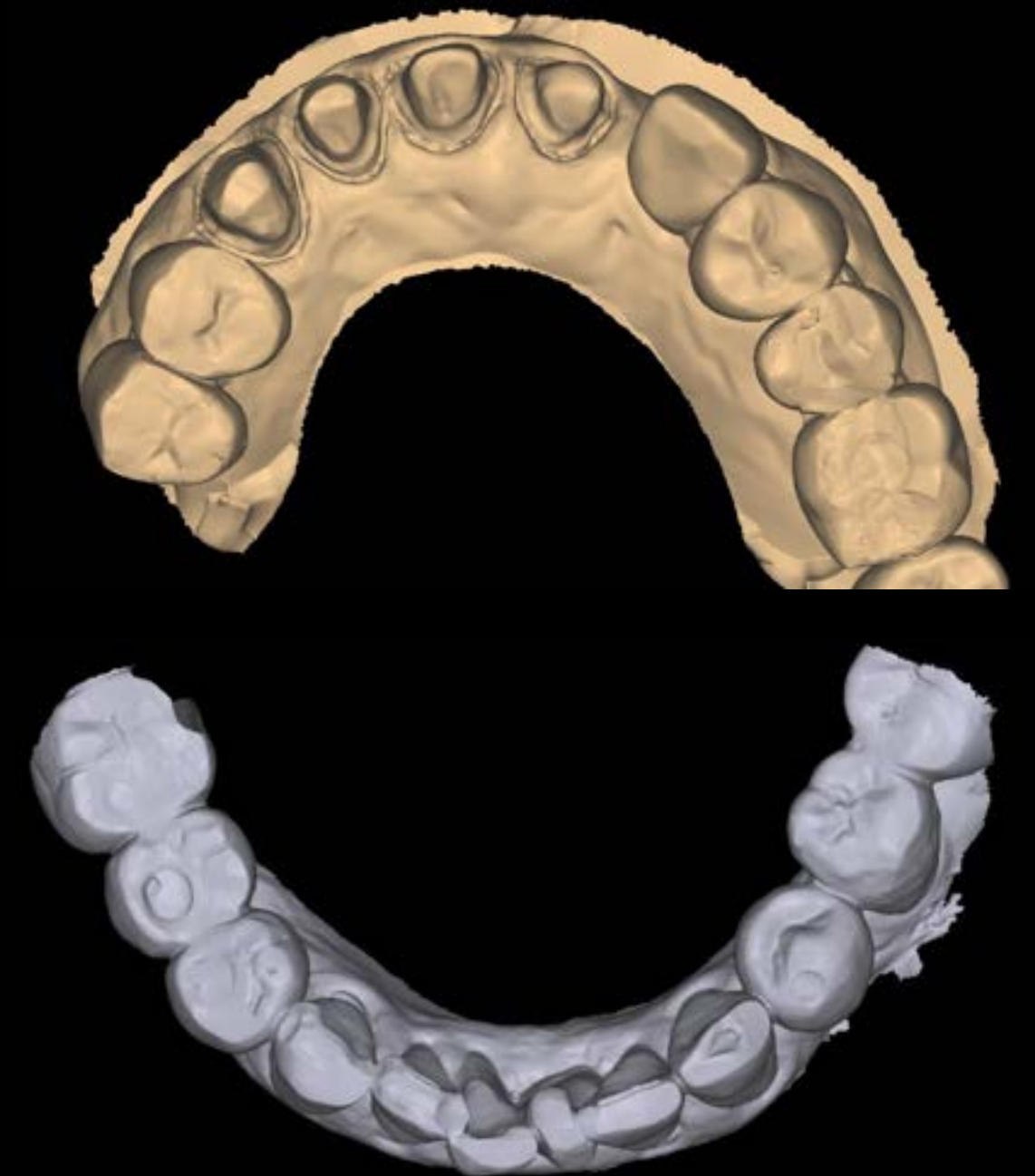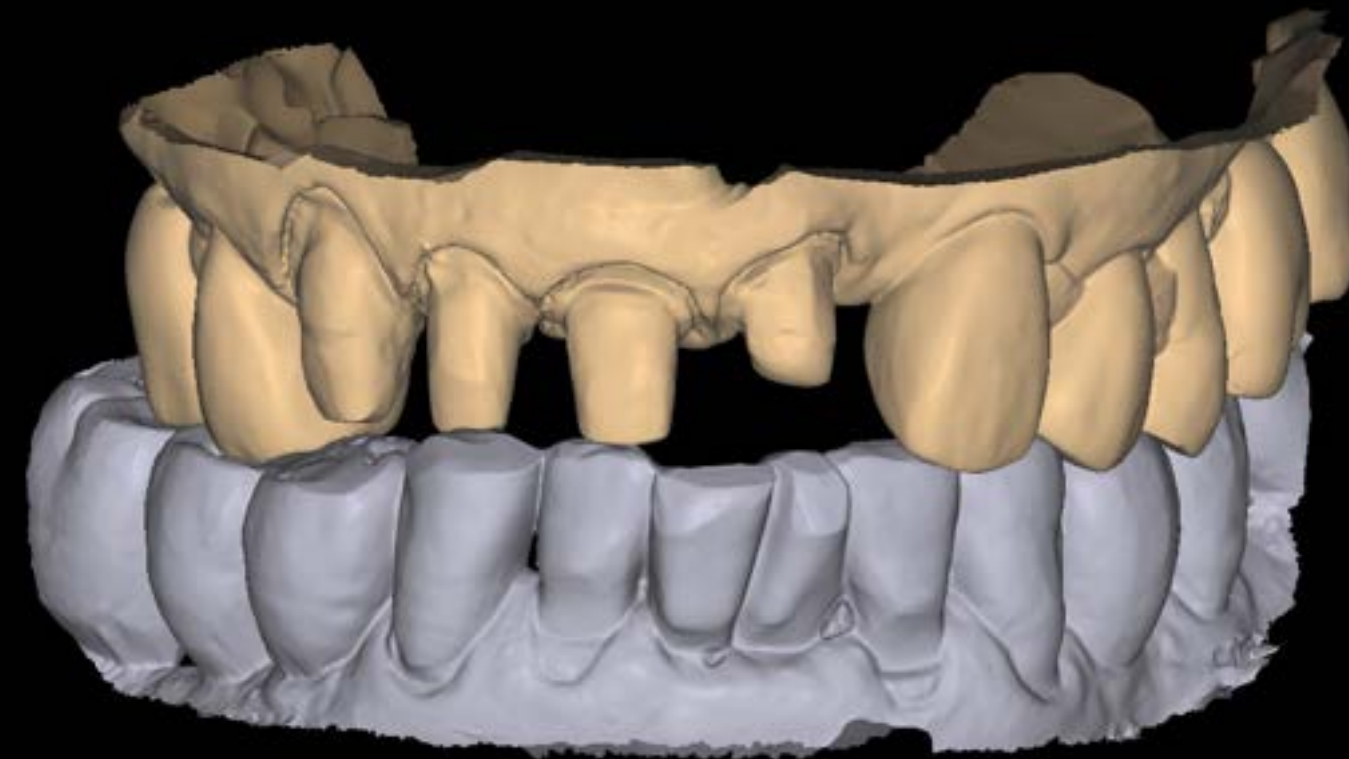

Very good with pts consulting and systemic tx

Impression scan for working model



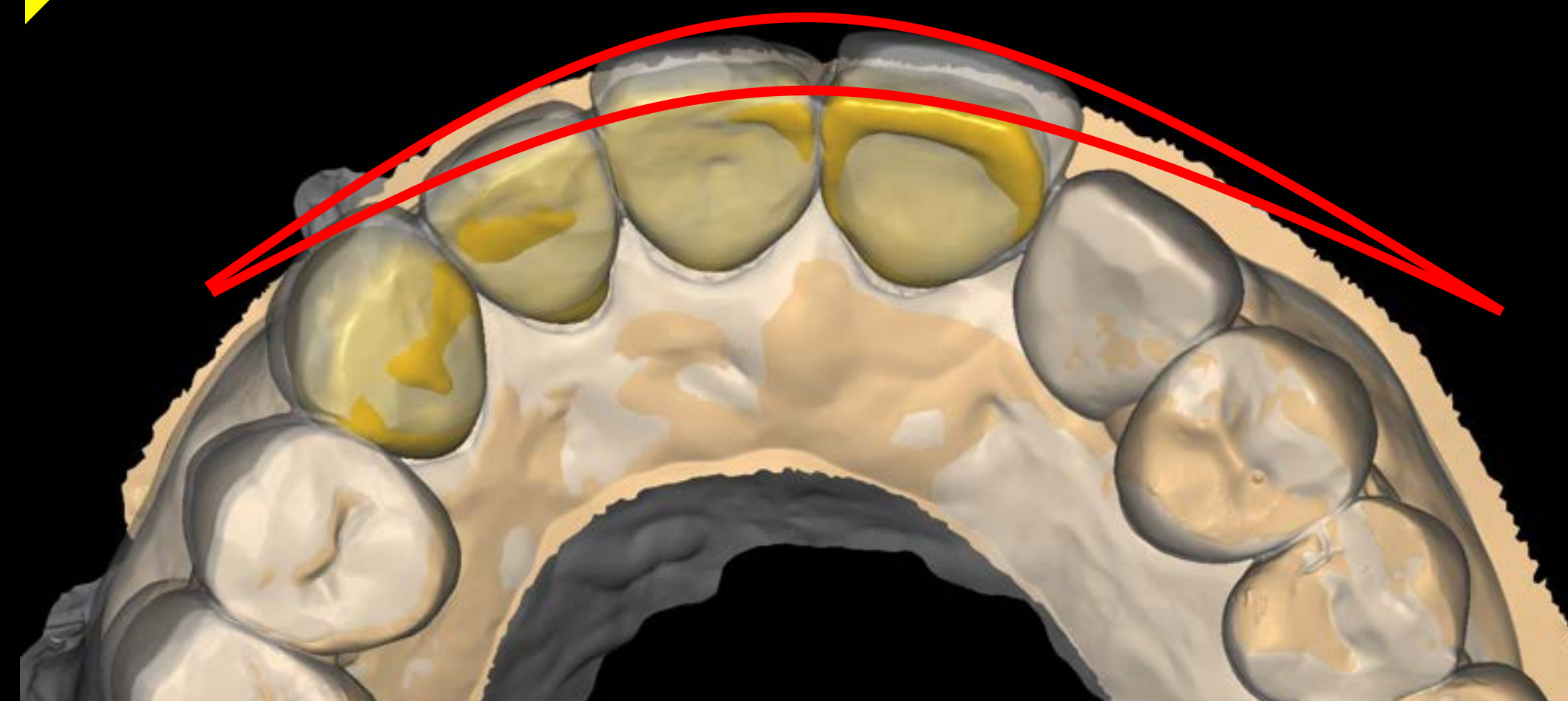
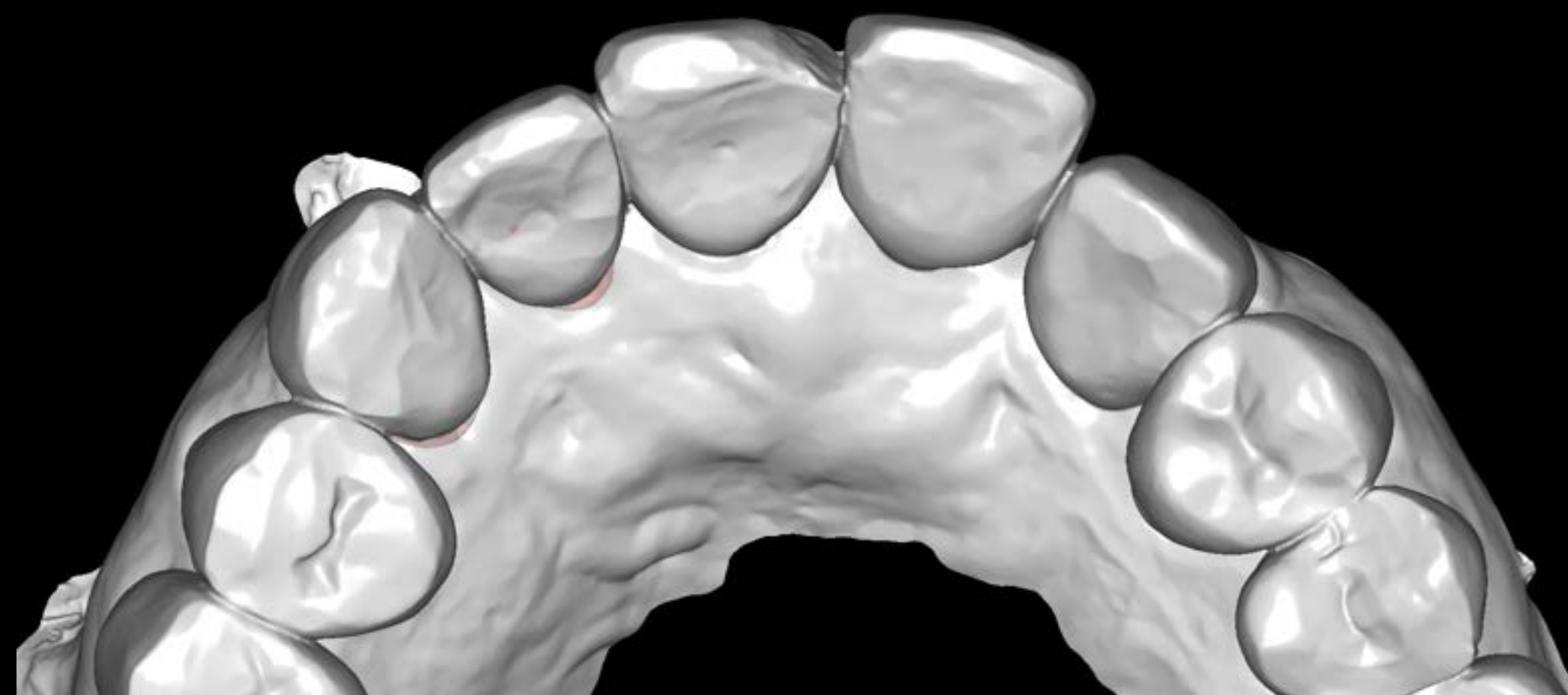

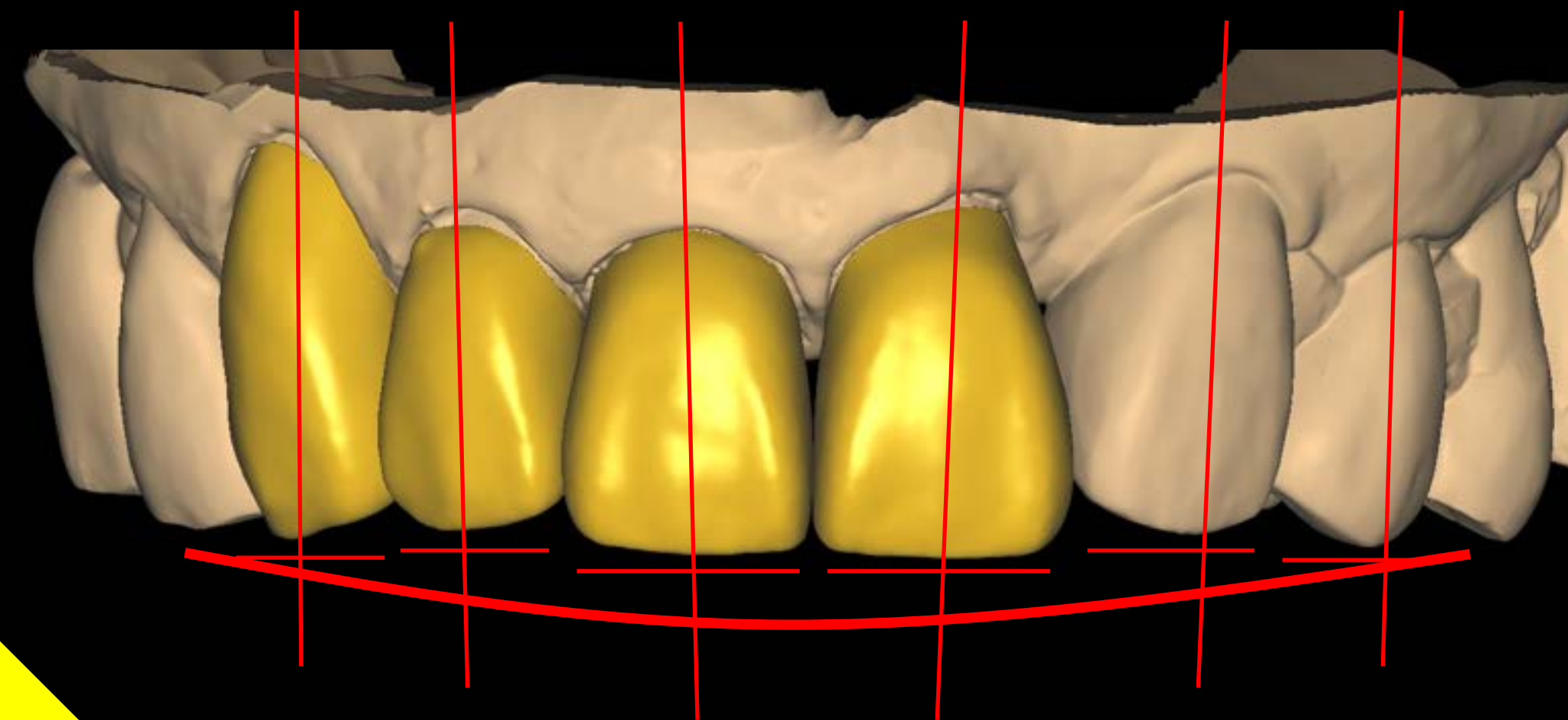
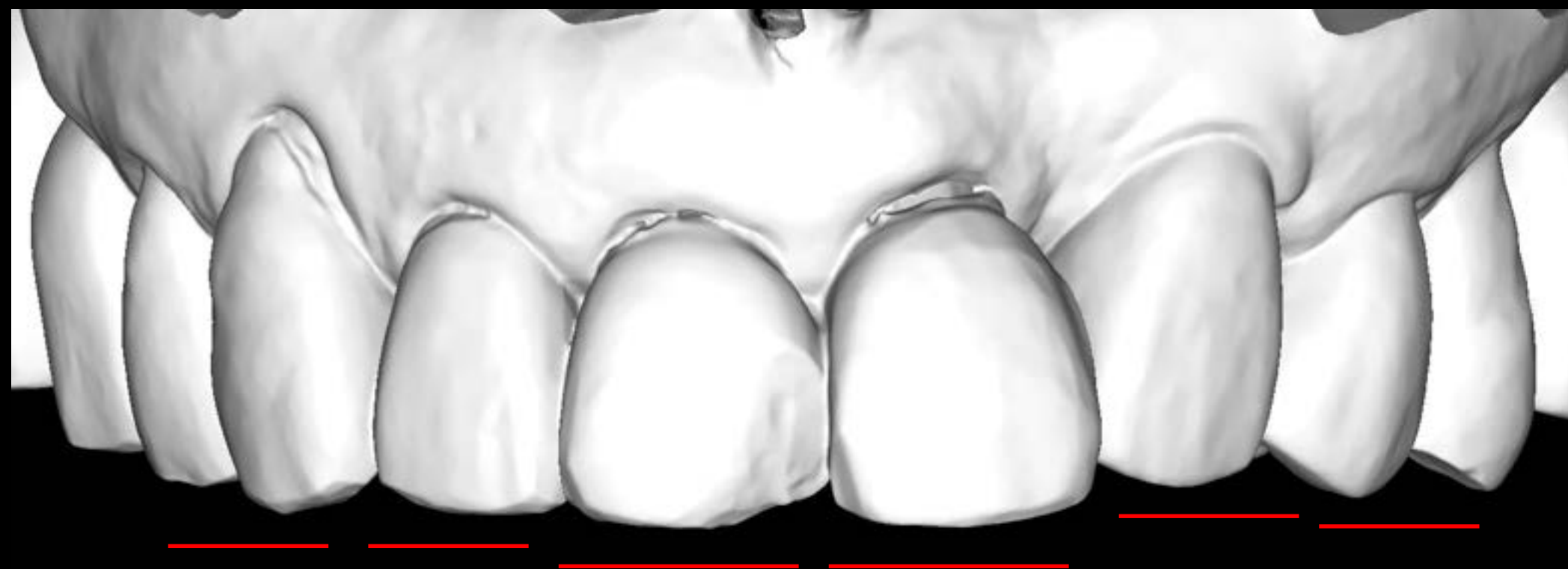
Border Trimming

Scan spray

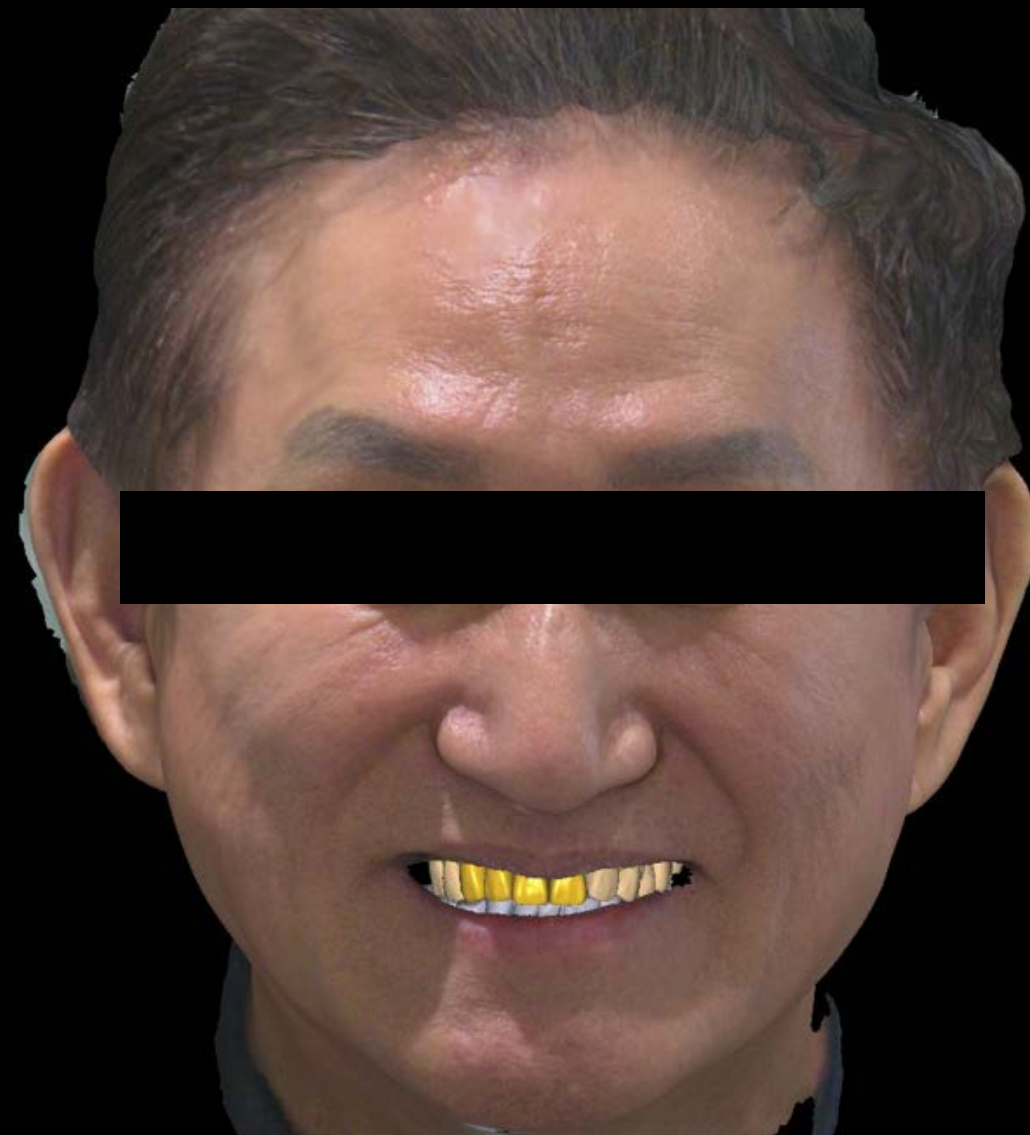

3) Virtual Set – up_case 1

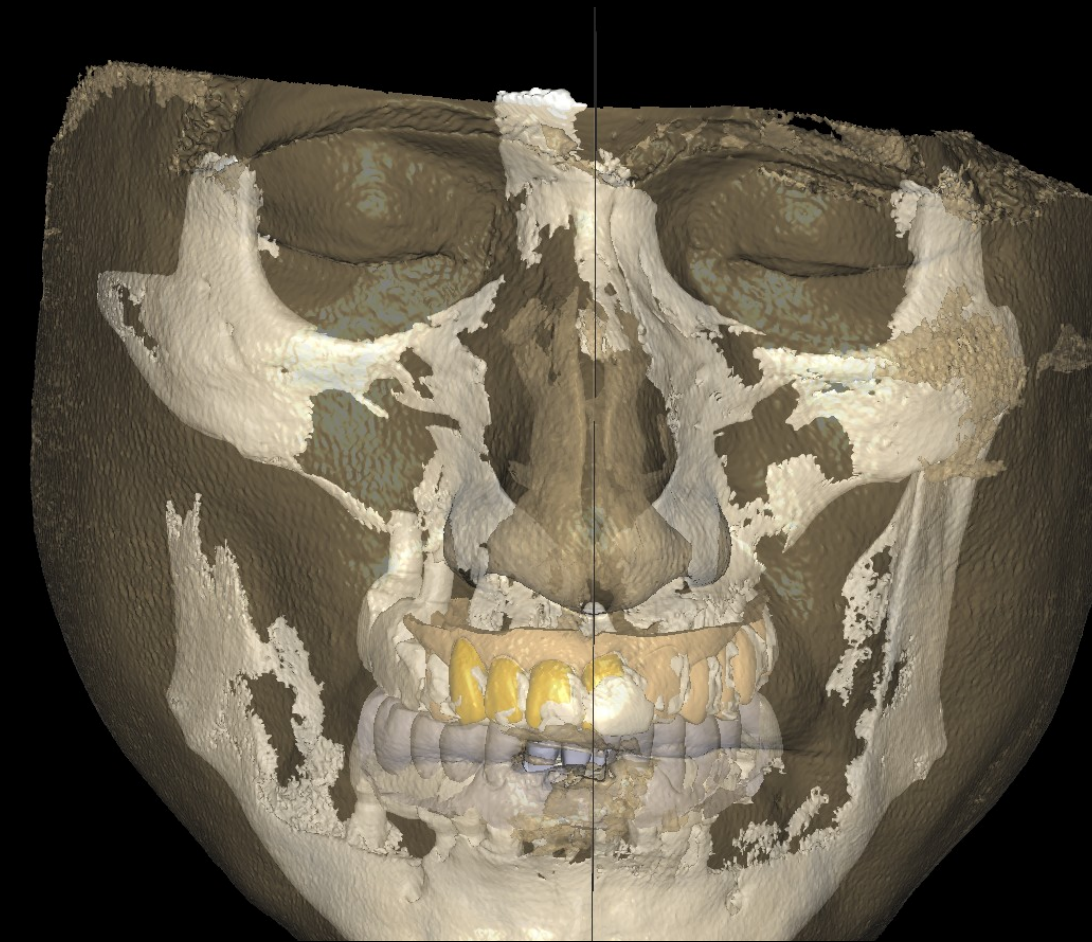Prosthesis design



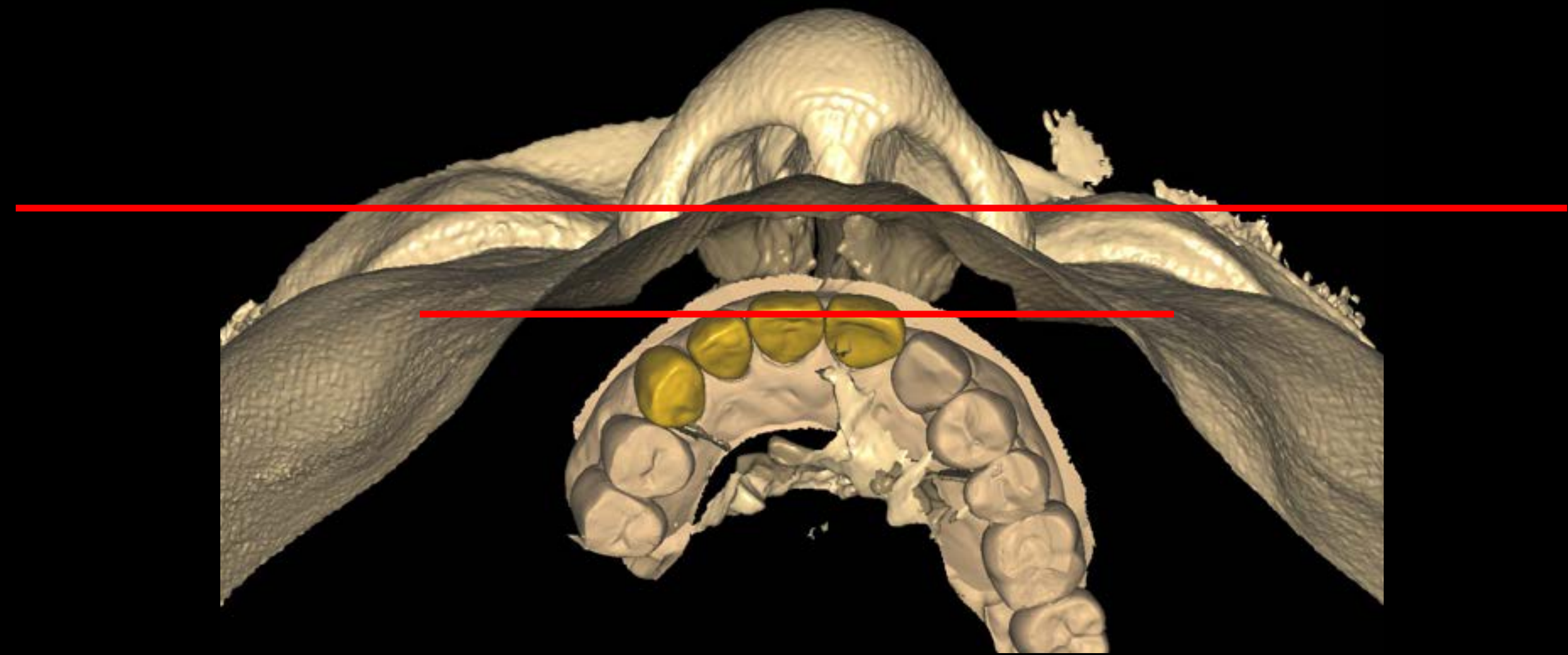
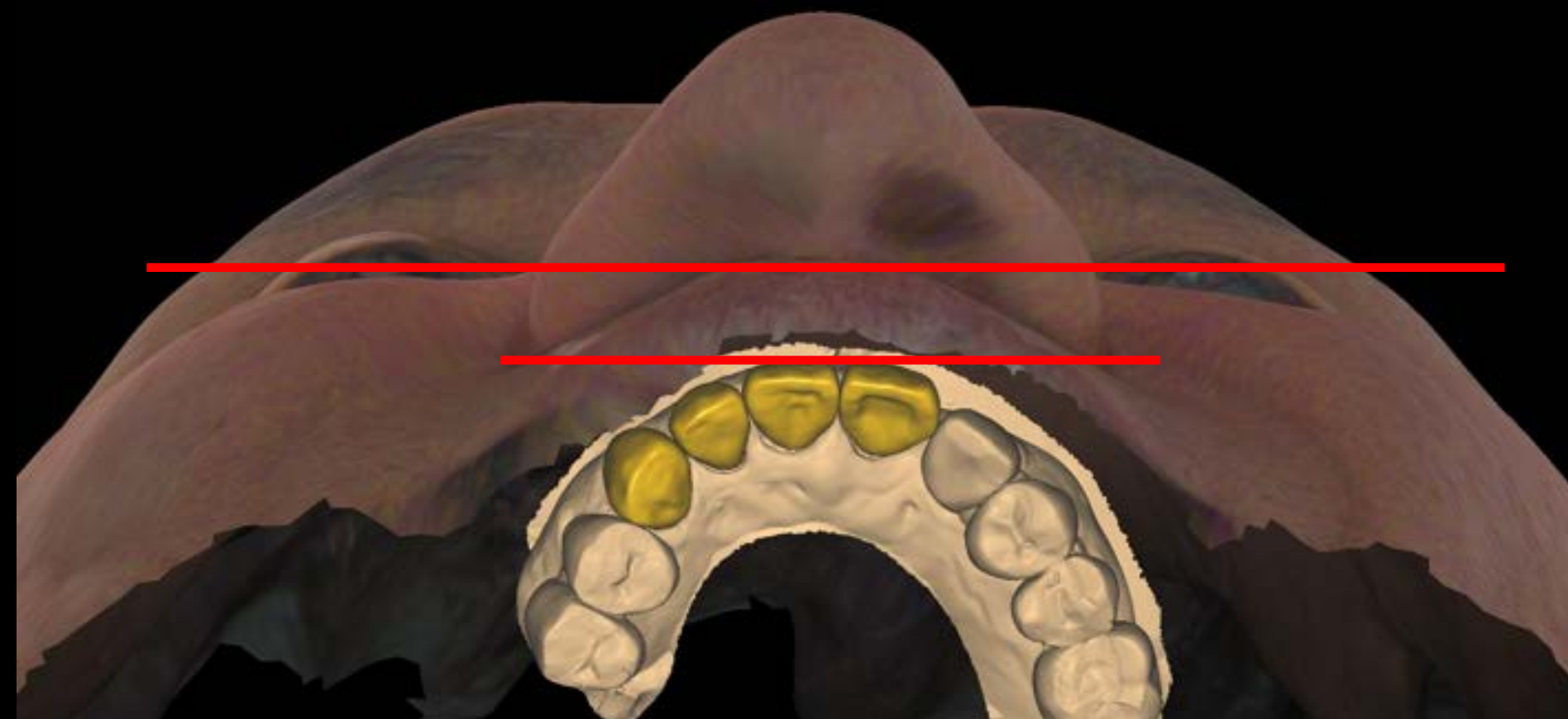
Facial scanner vs CT data application



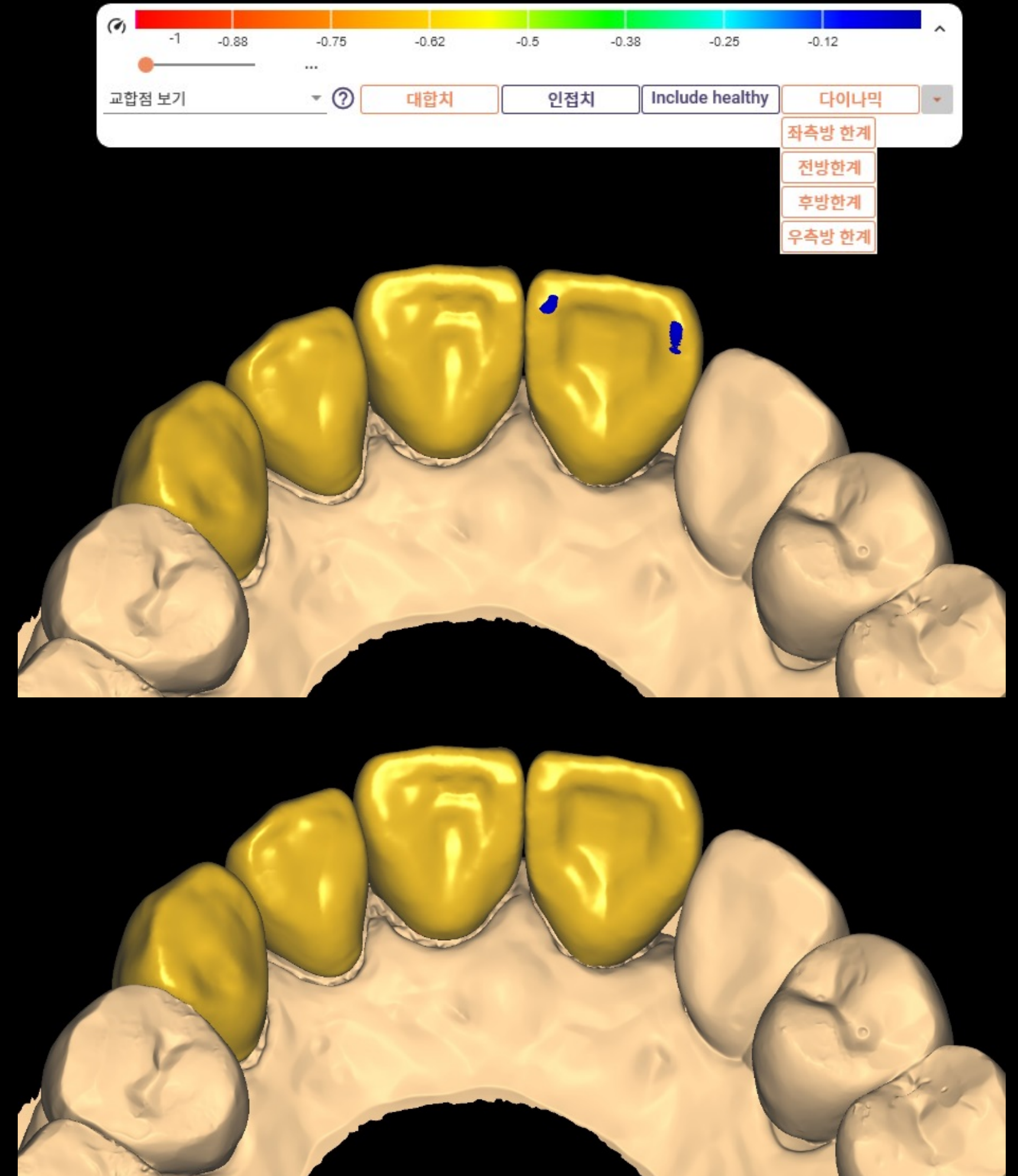
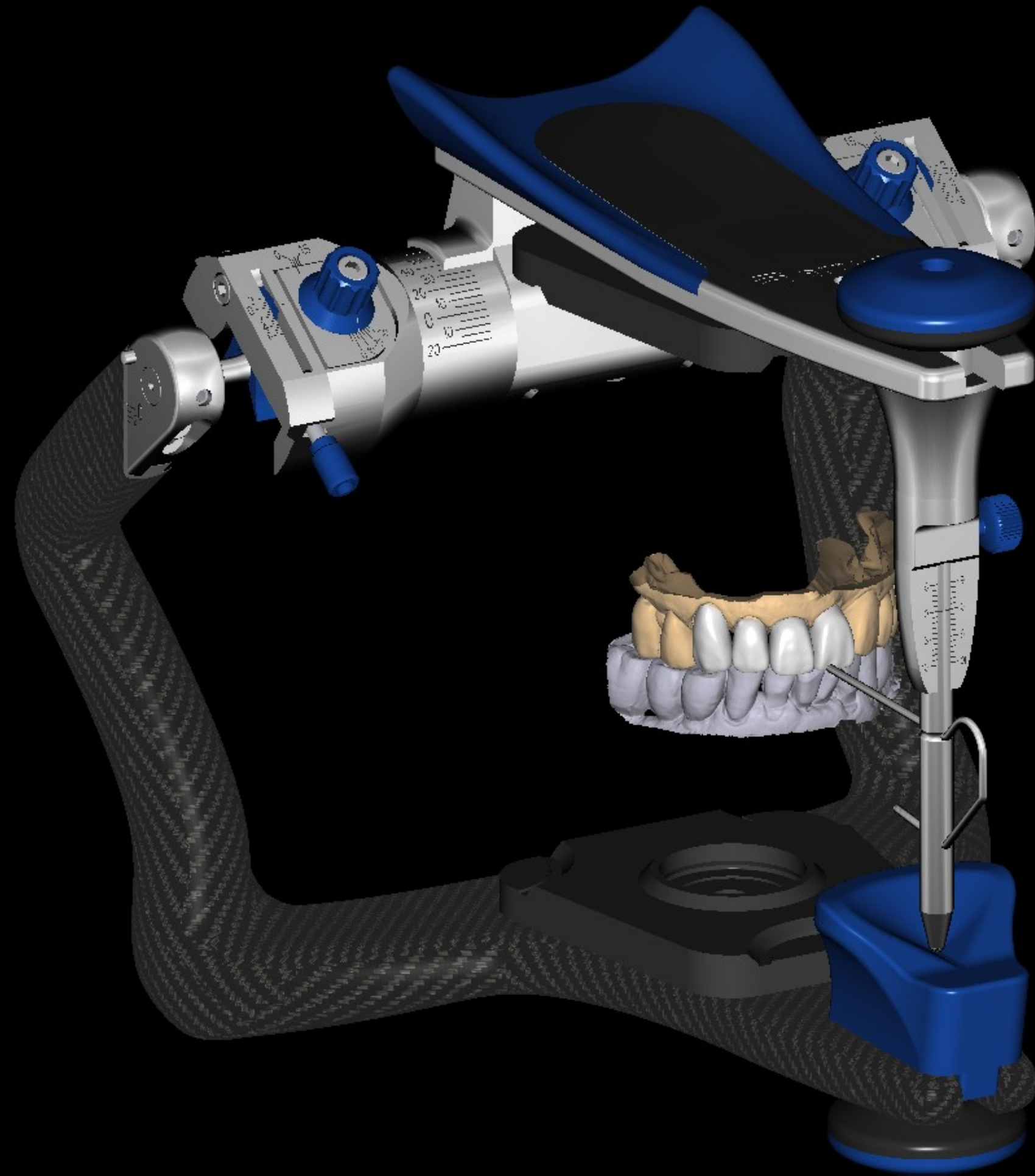
Facial scanner
Good for pts consulting



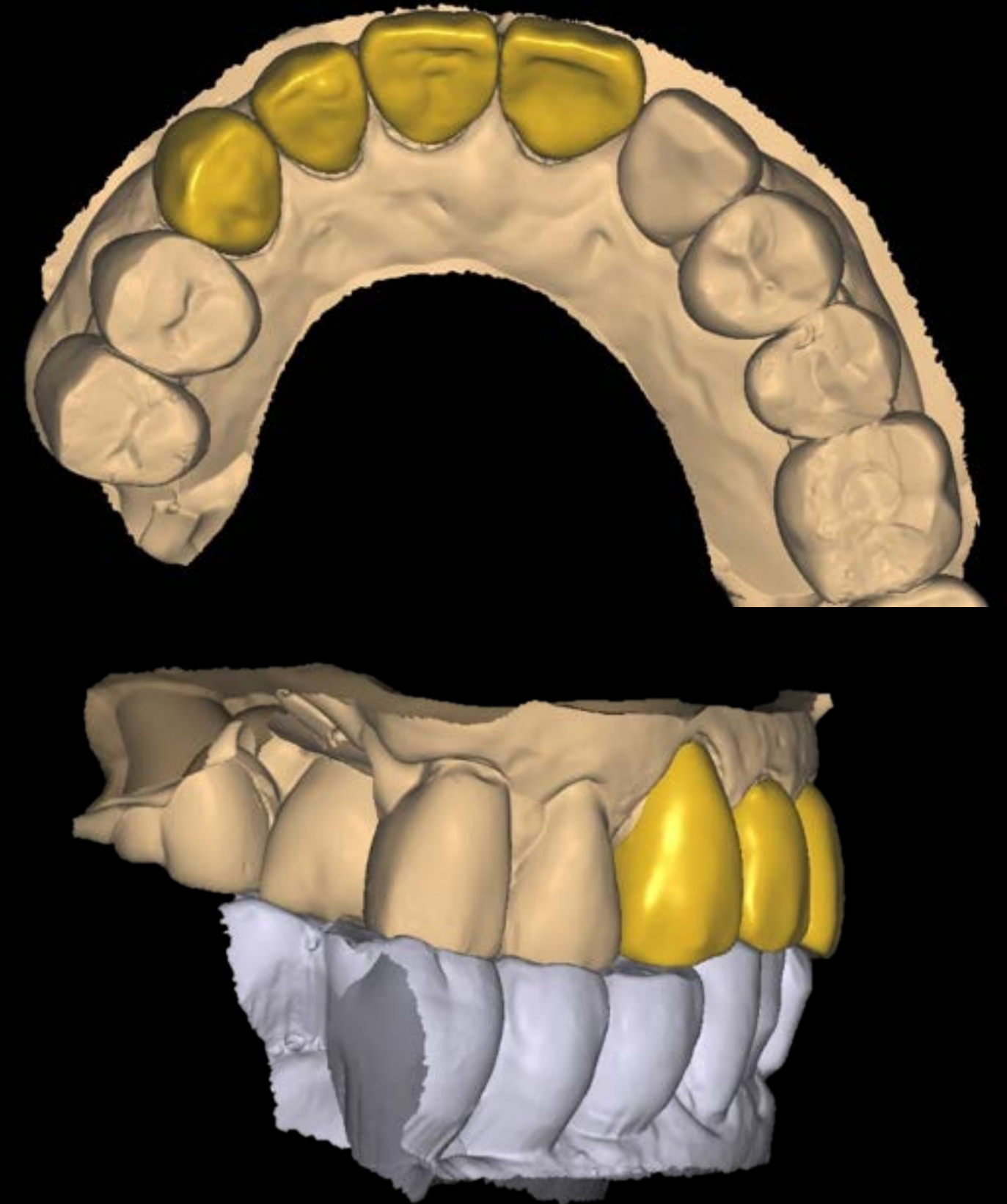
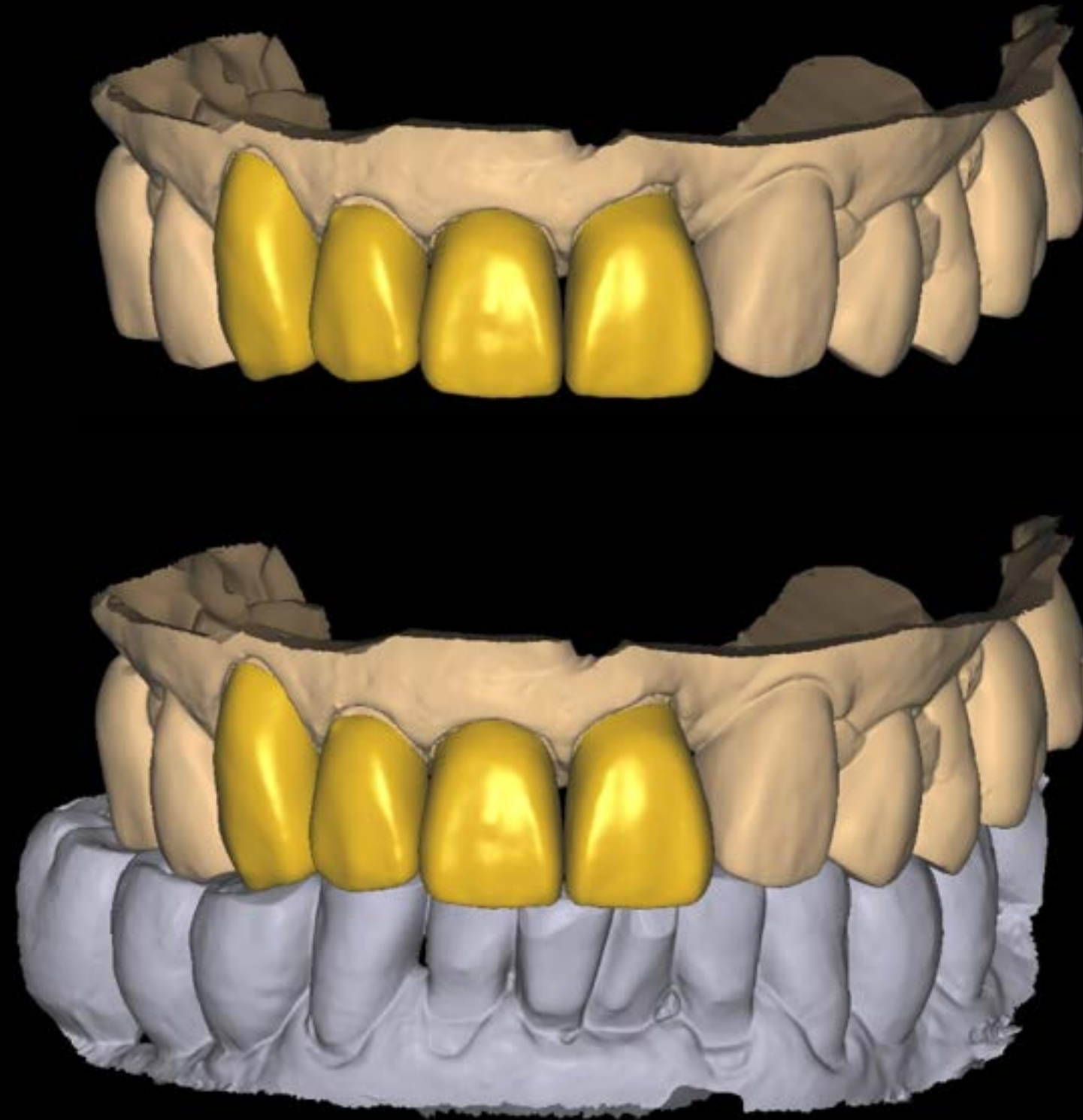
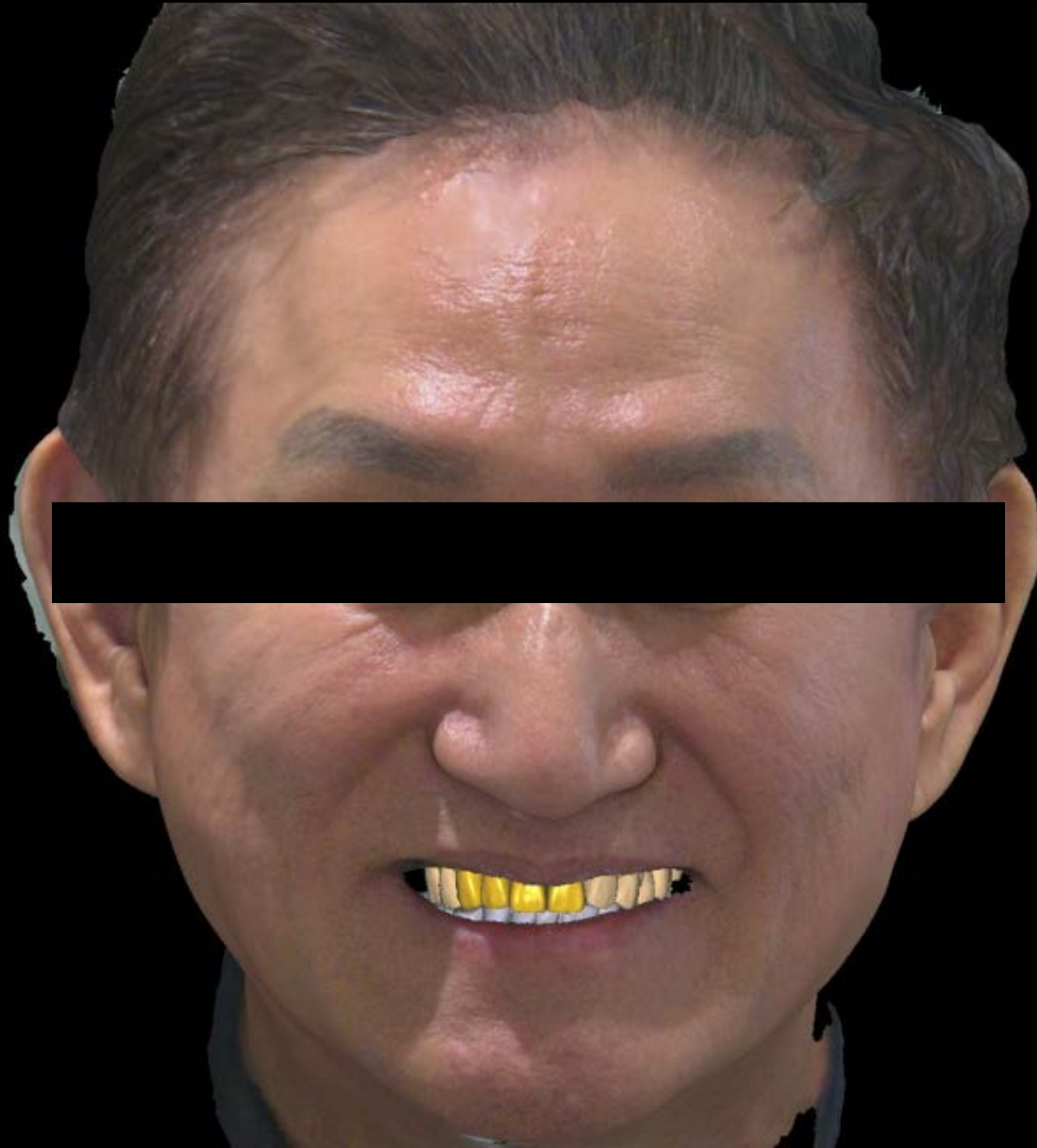CT STL
more precise for lab



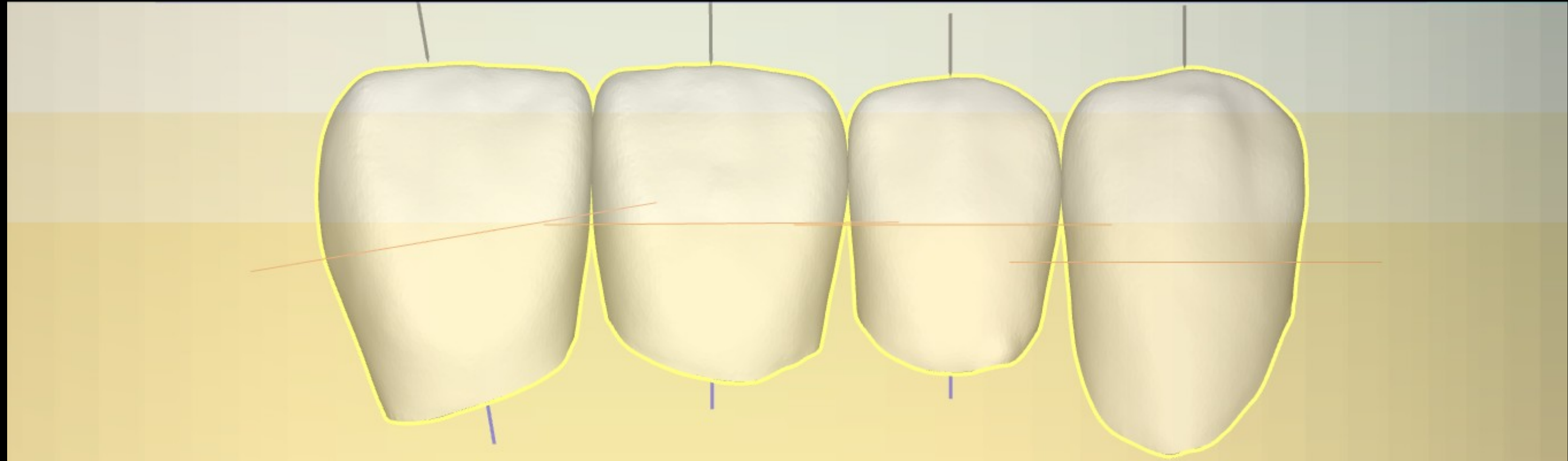
Prosthesis design



Prosthesis design

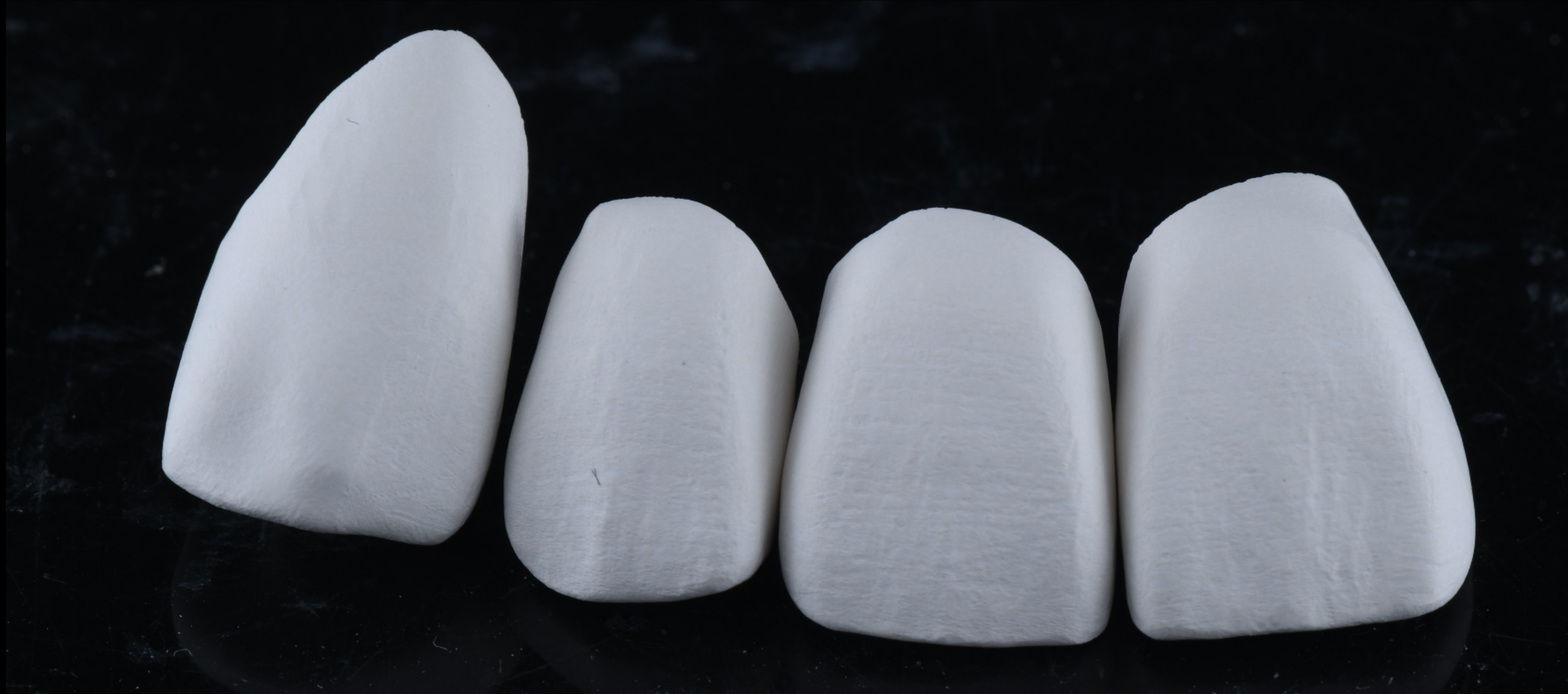

Hyper Dent



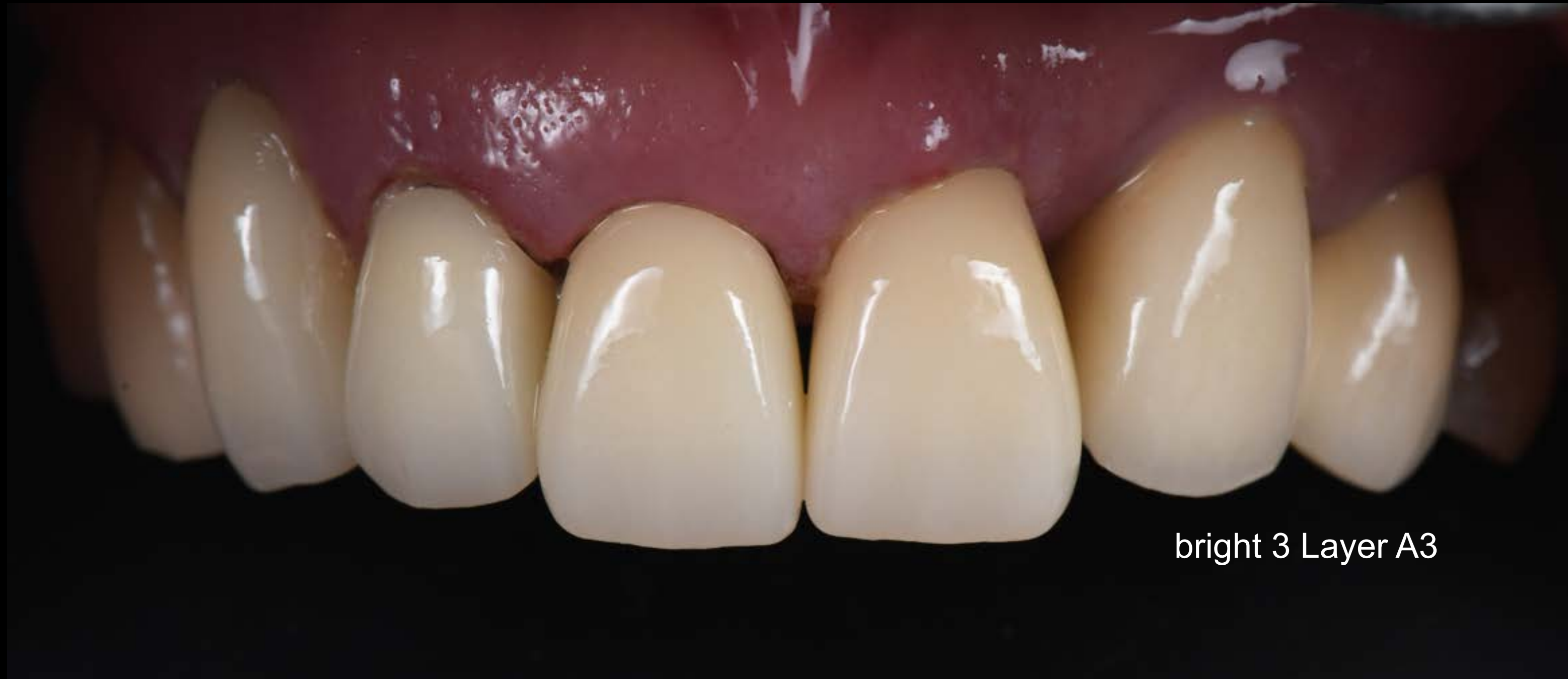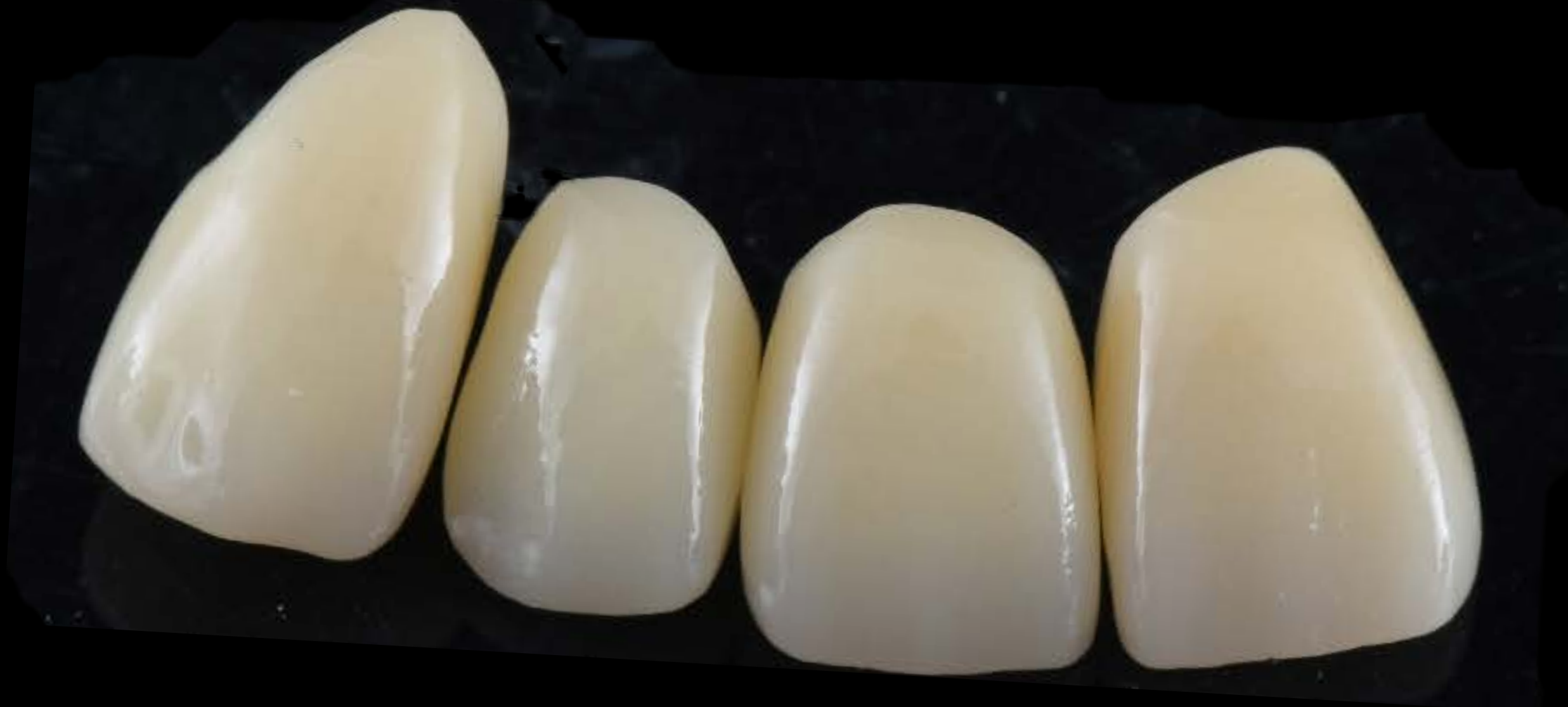A3 18T 3 Layer Block

Coloring

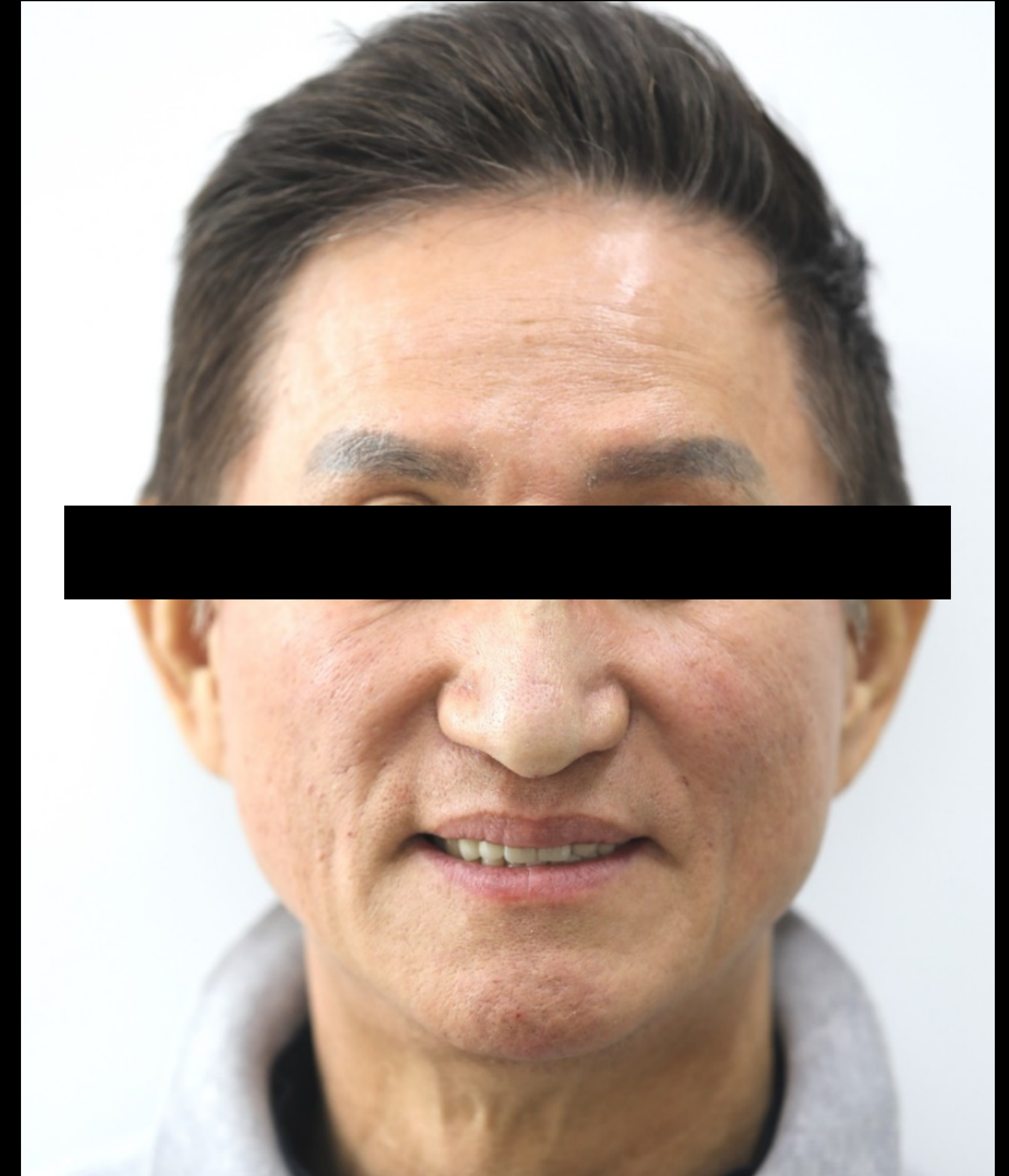

Inner – White Opaque

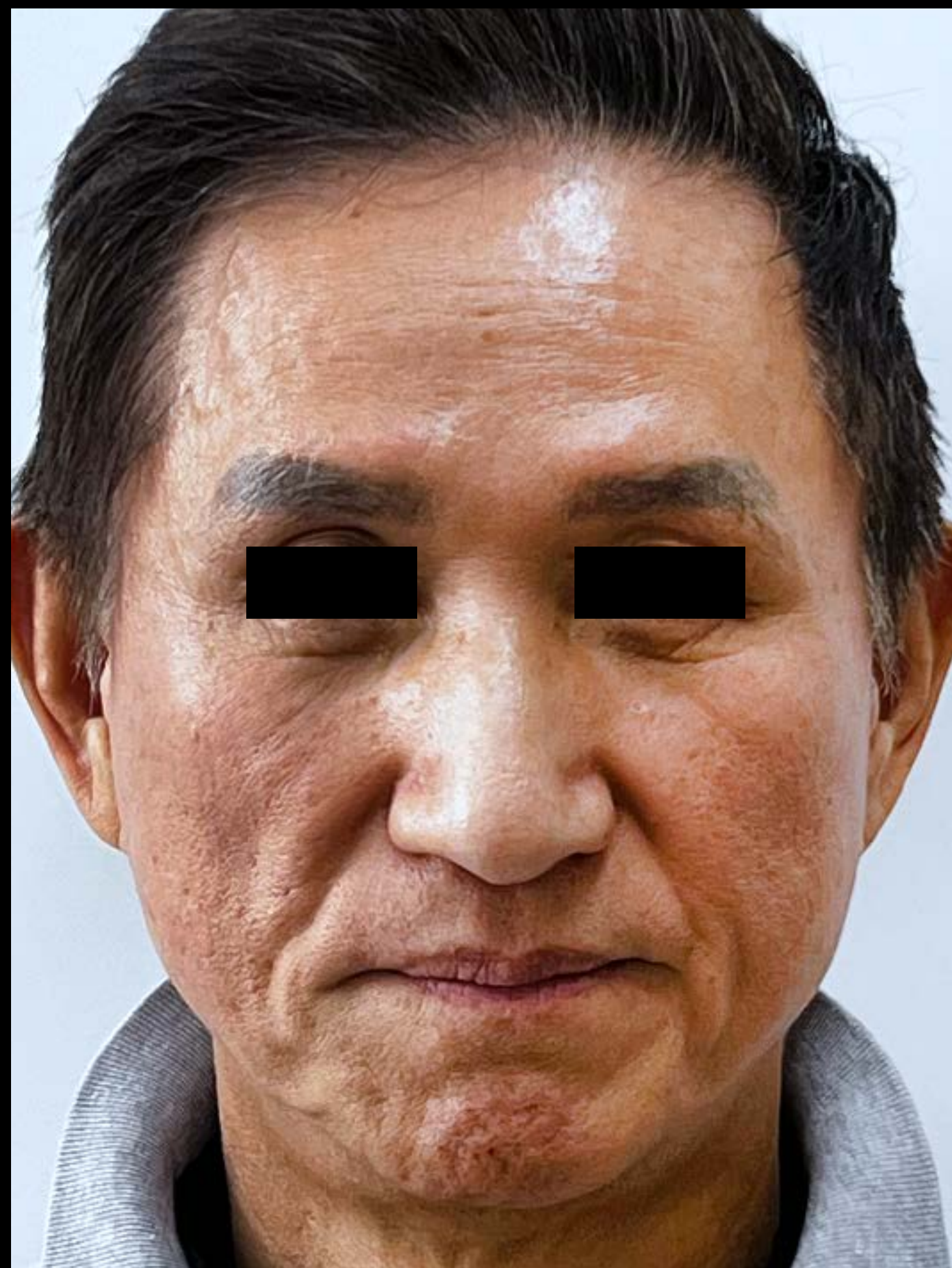
Prosthesis design



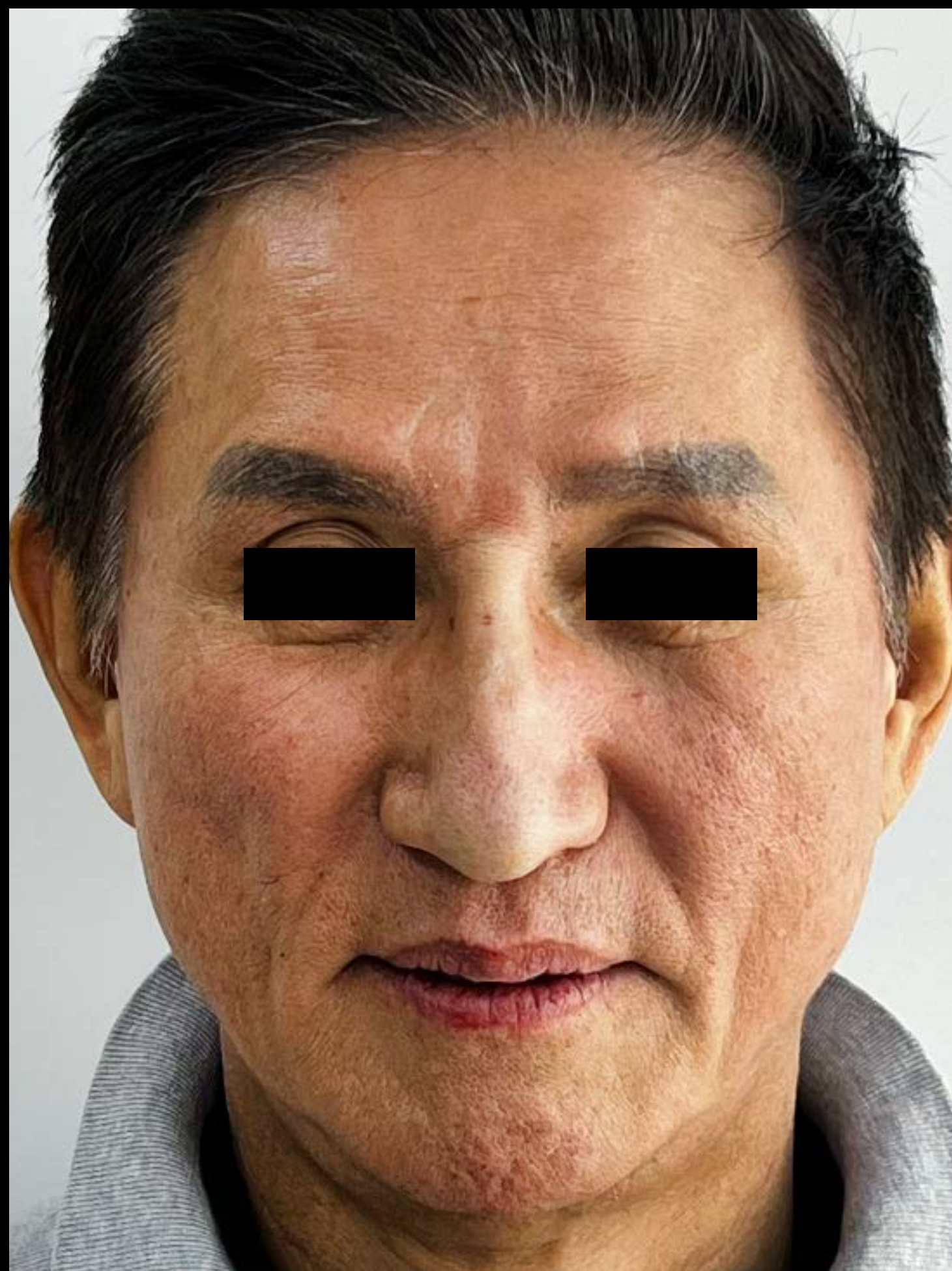bright 3 Layer A3



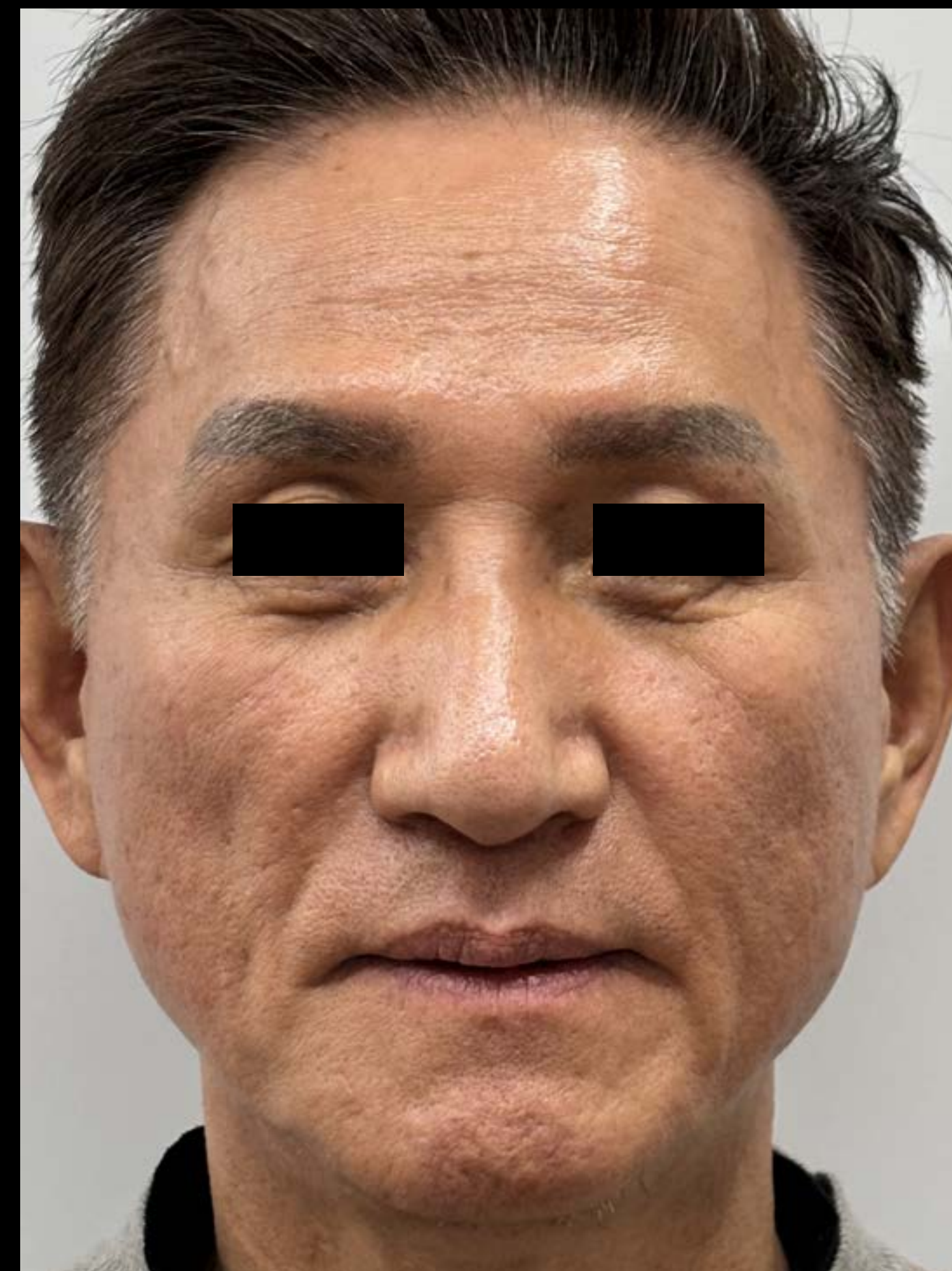
Before



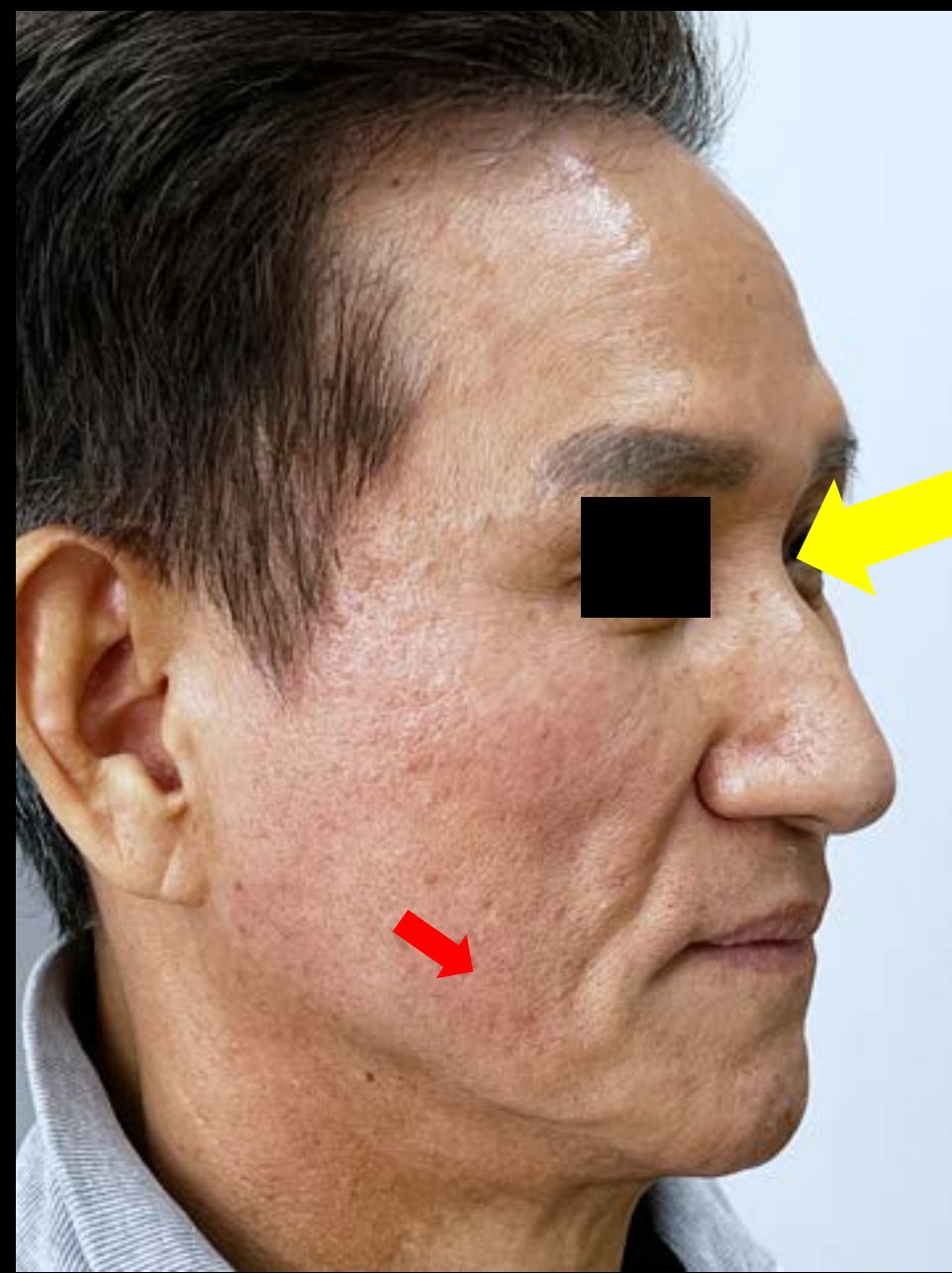
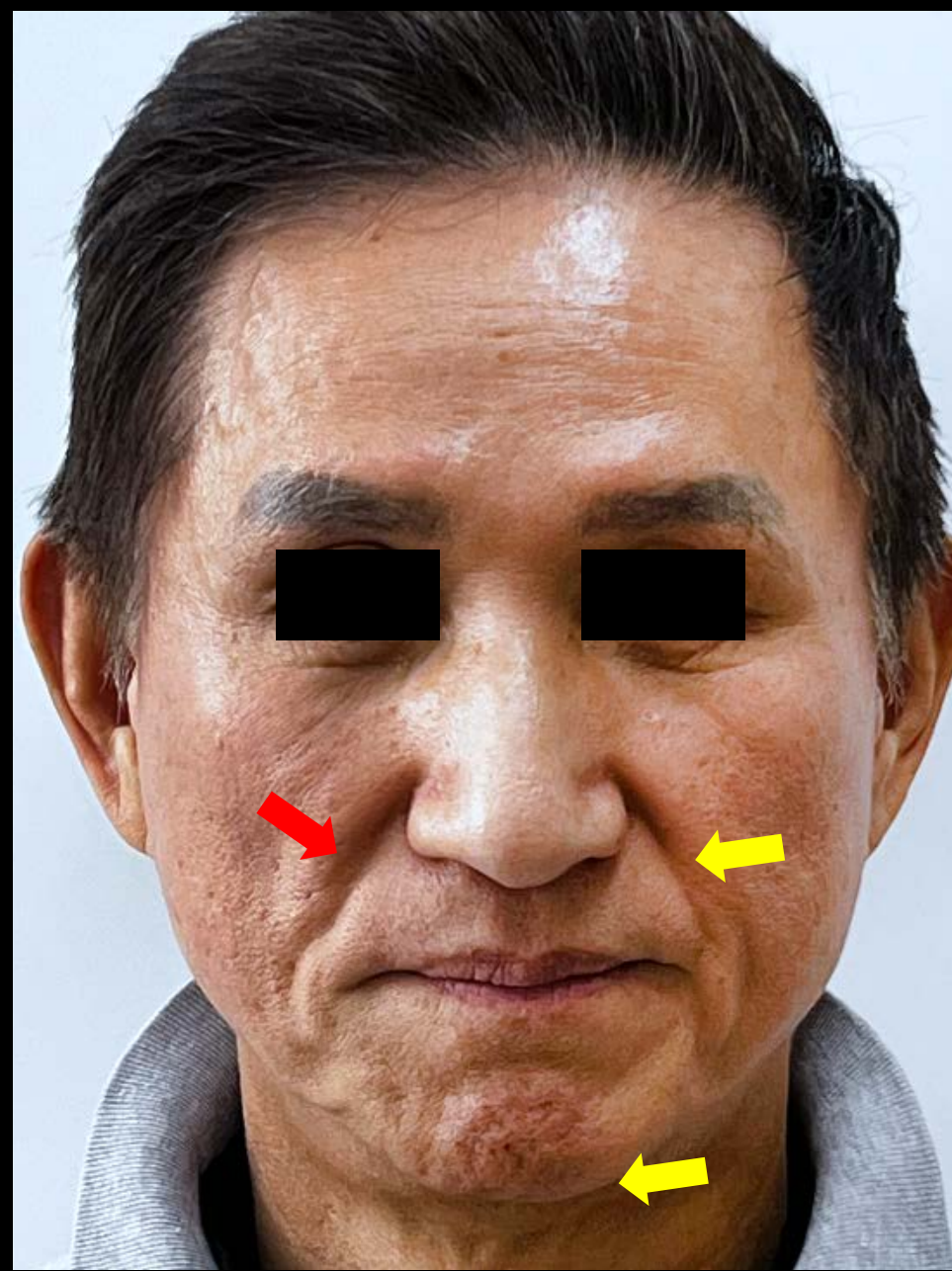
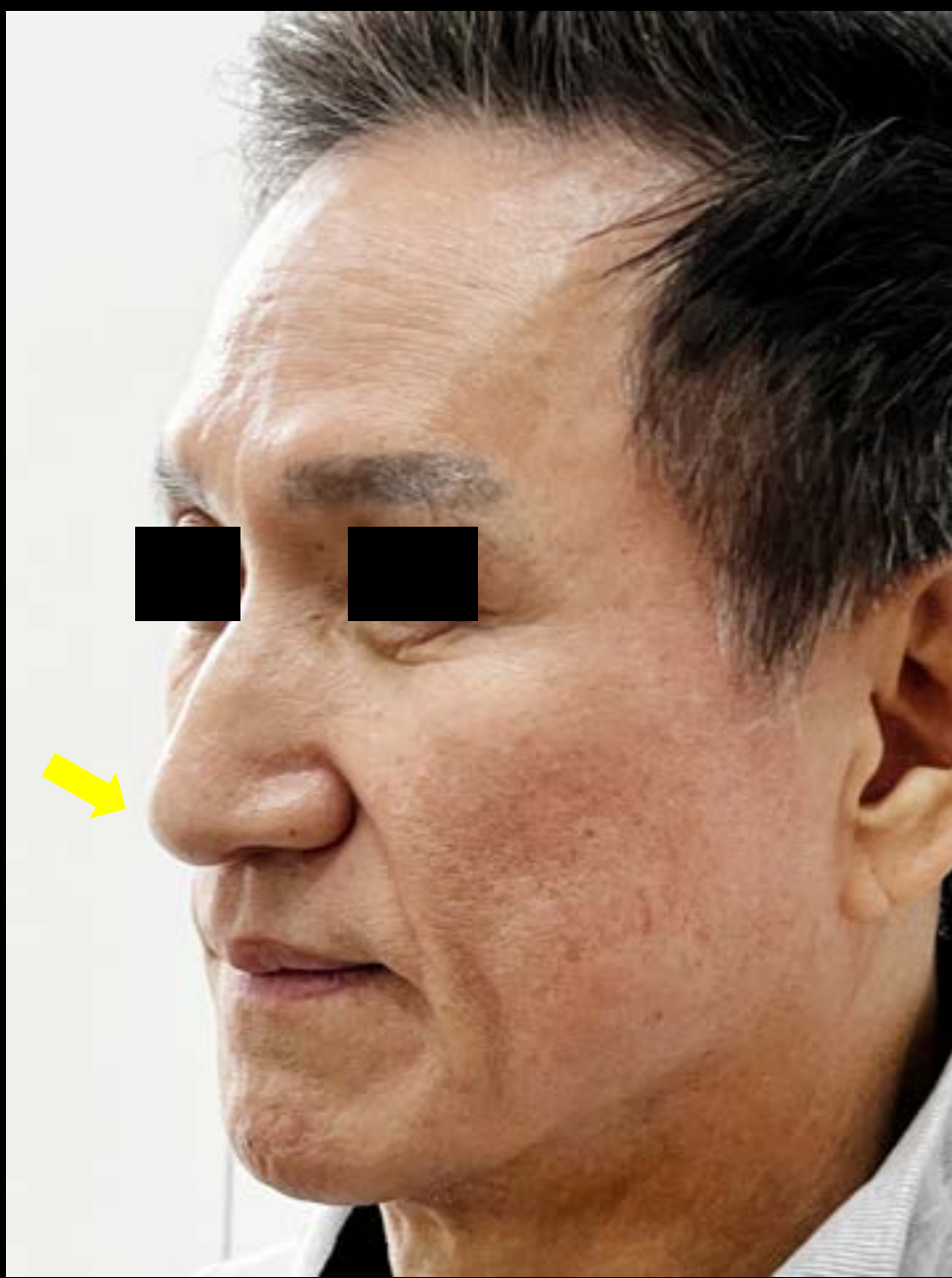
After



1 Month Later



before



application site

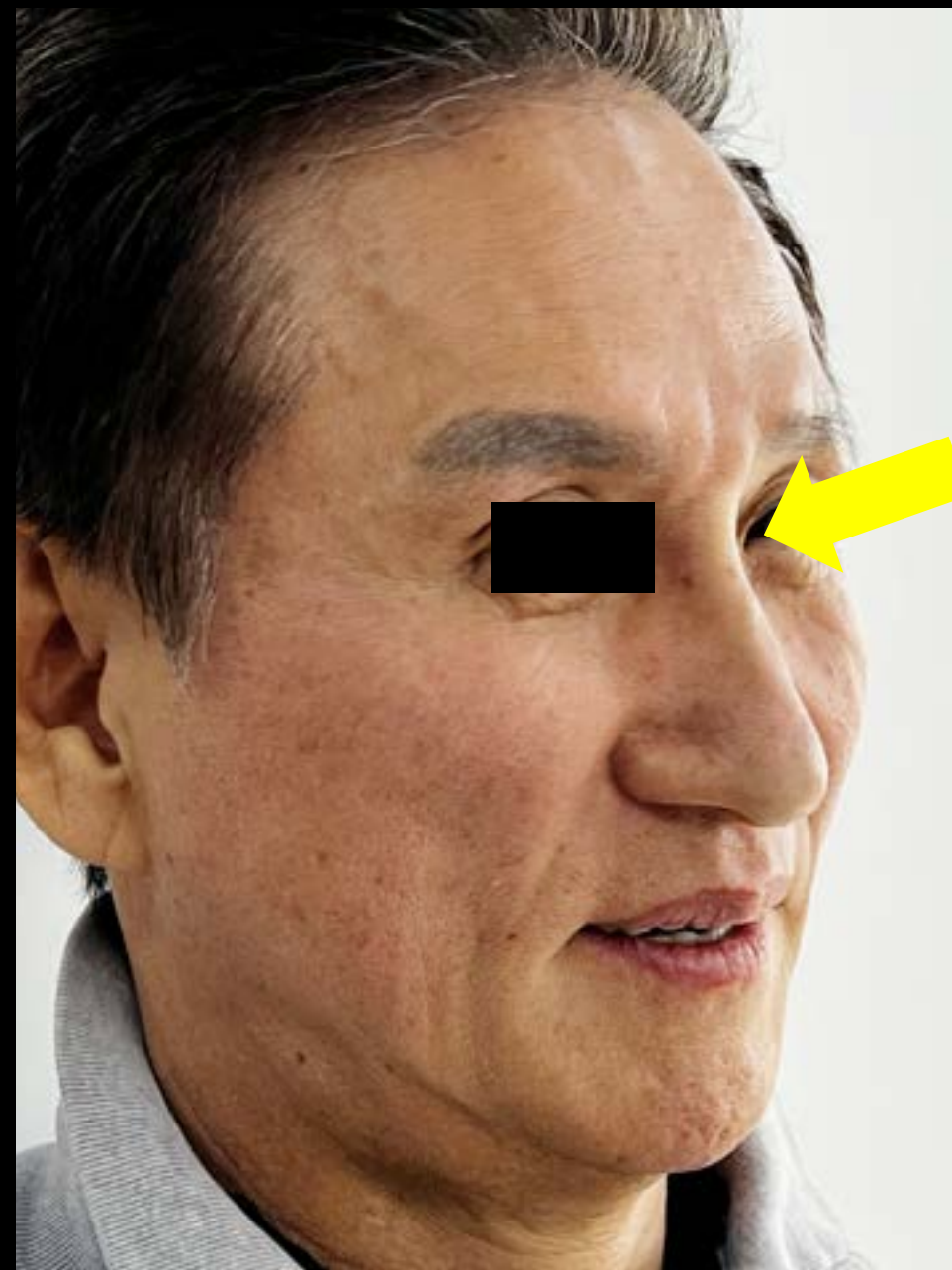
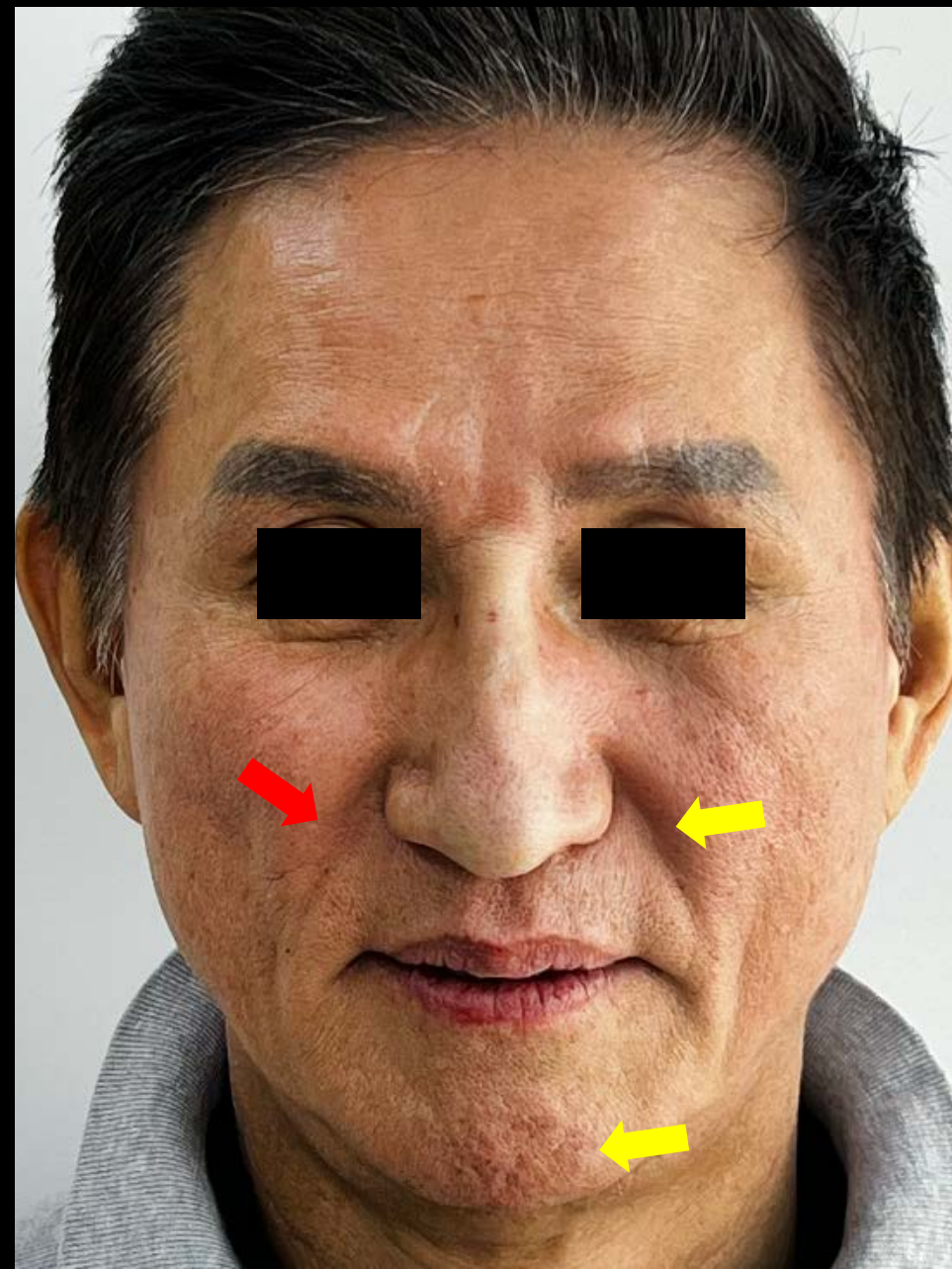
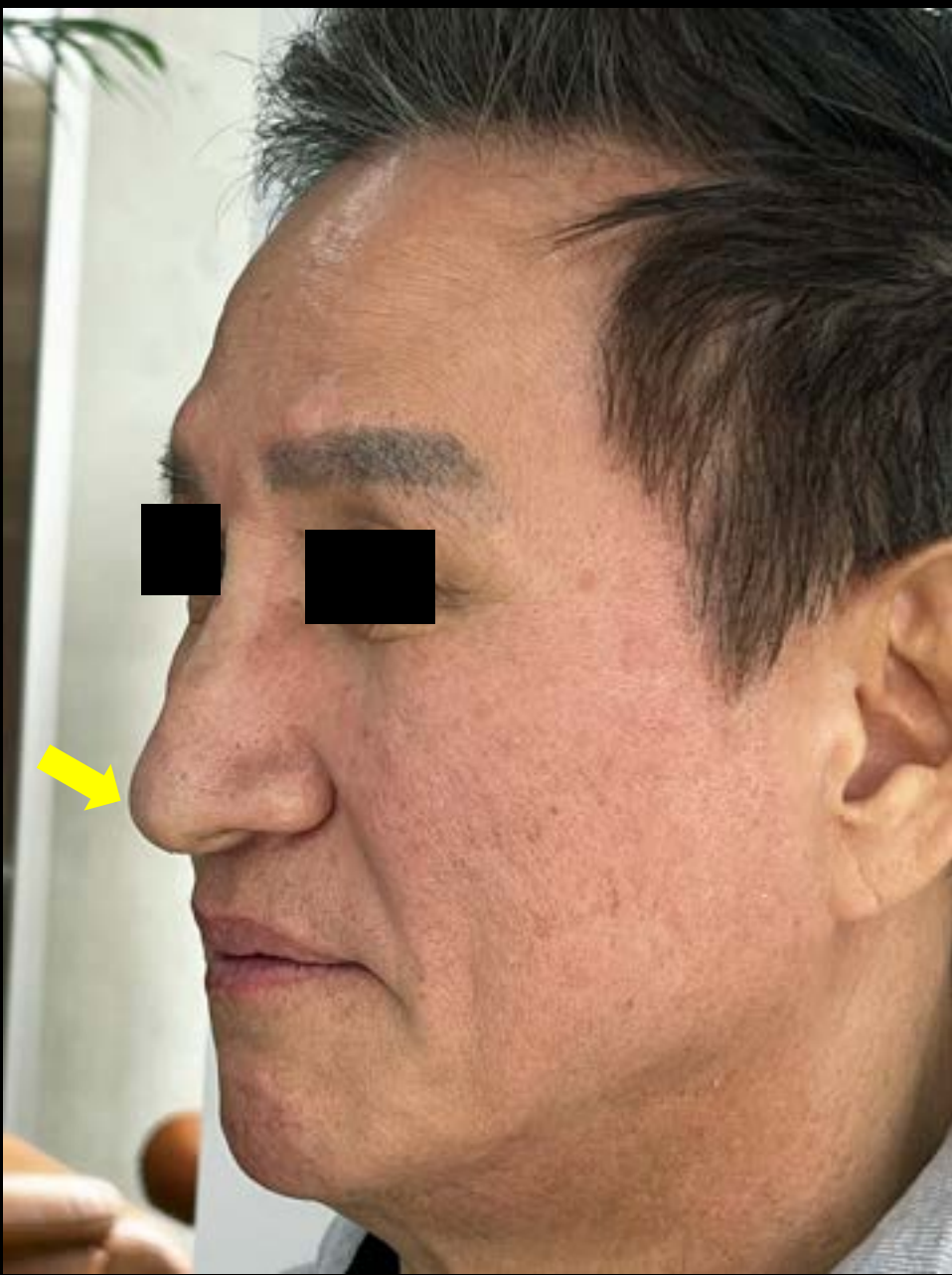High ✓

- Nose
- Nasolabial folds
- Chin

Smile ↙

- Nasolabial folds
- Marionette lines

after



High elastic hyaluronic acid filler

The way to overcome Barriers of digital

Cost for investment for facial scanner and CT

Inaccuracy with IOS

Knowledge of material development

Too much information and too less total education

No turn key suggestion with practices

Contents

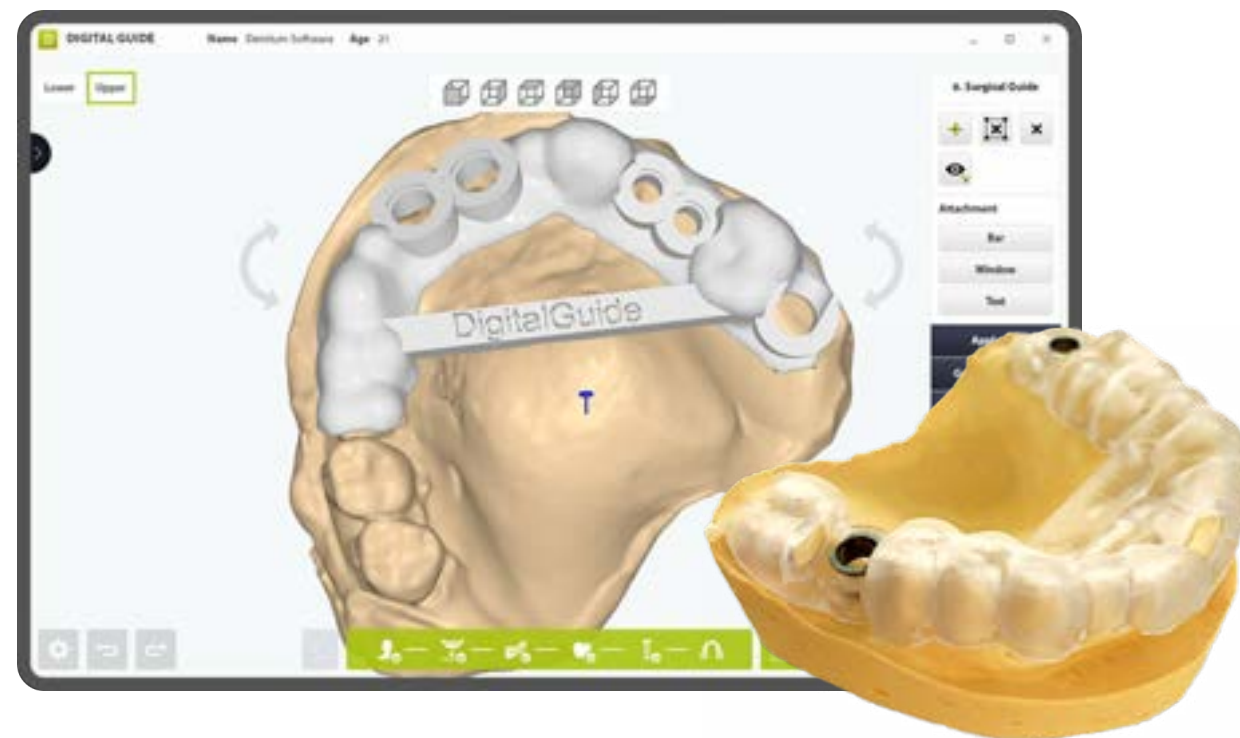
BTS

Diverse applications of CT viewers

Zirconia block

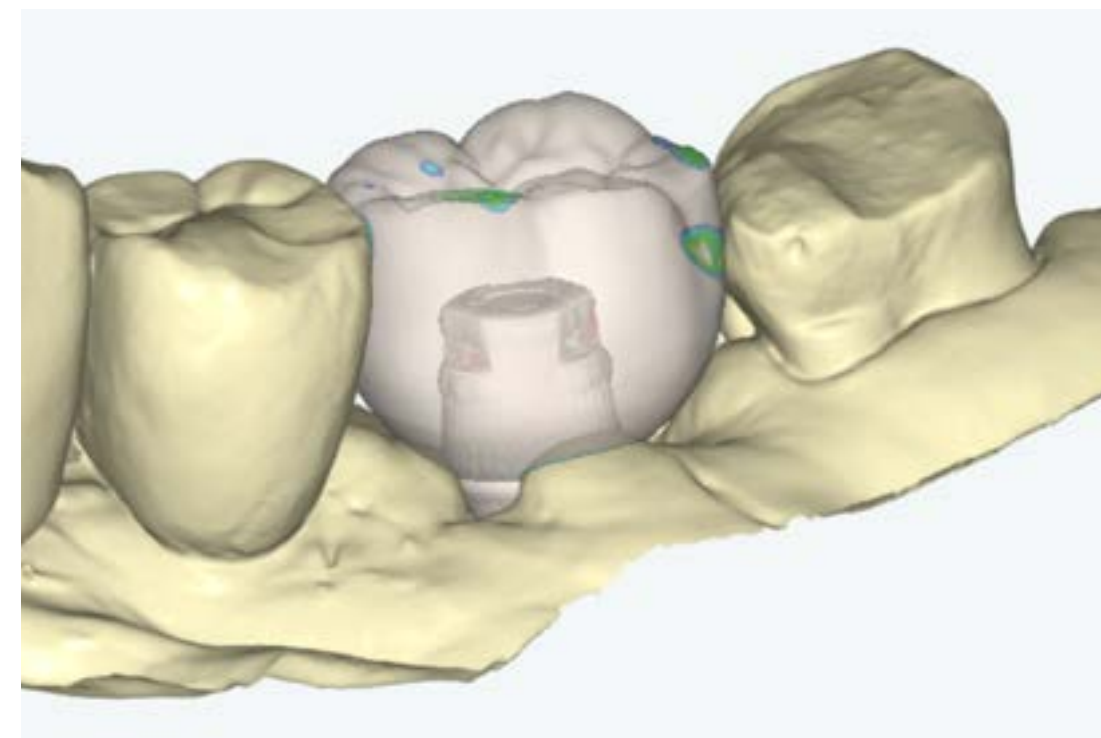
Auxiliary

Surgical
Guide



+

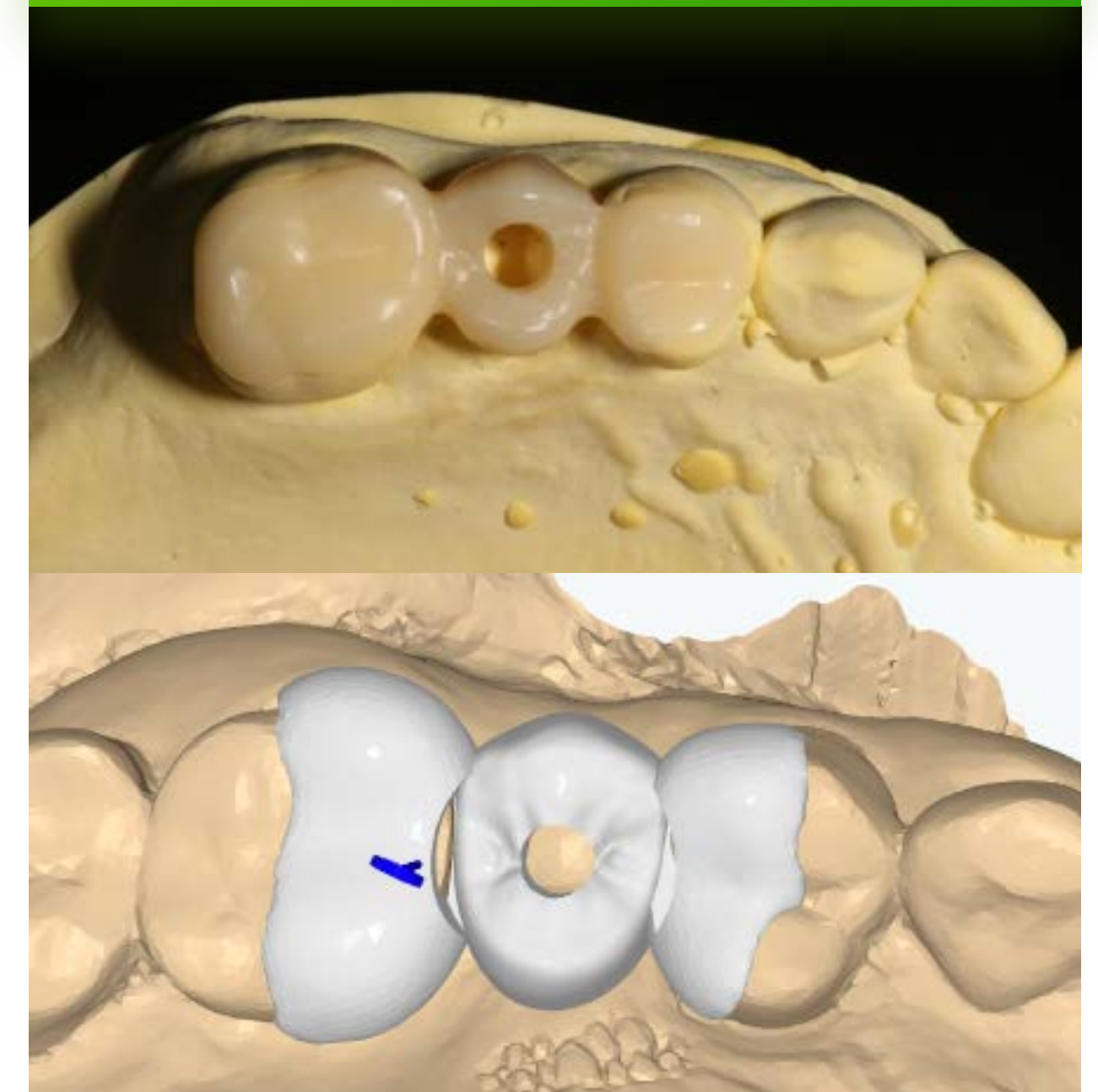
Crown



>

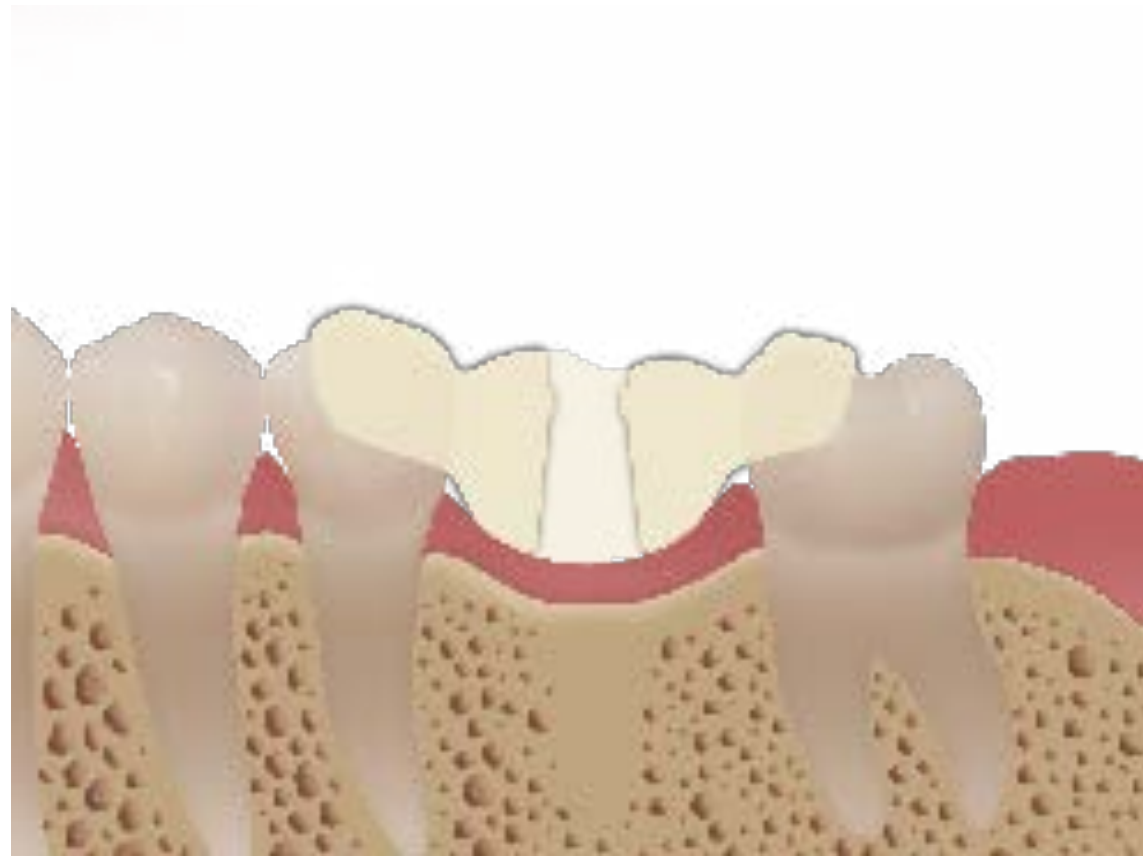Crown Guide

Top-down design
Minimalism

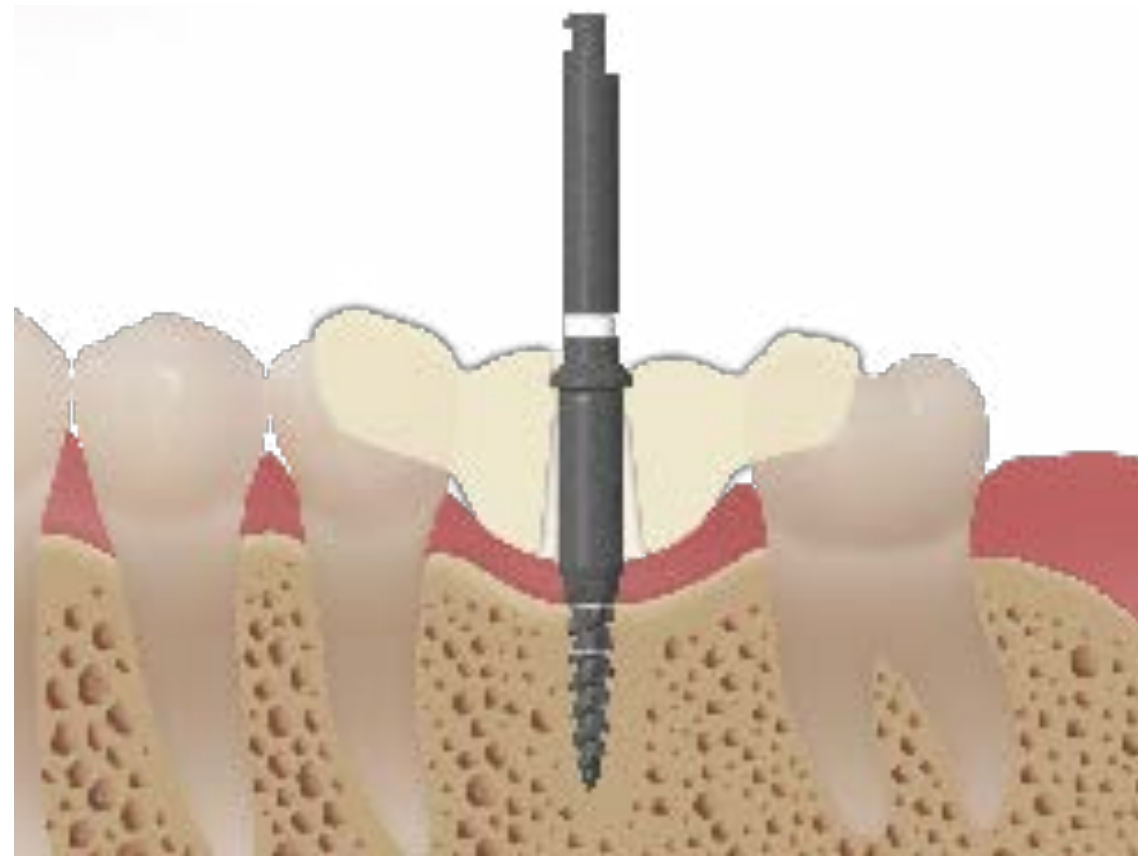
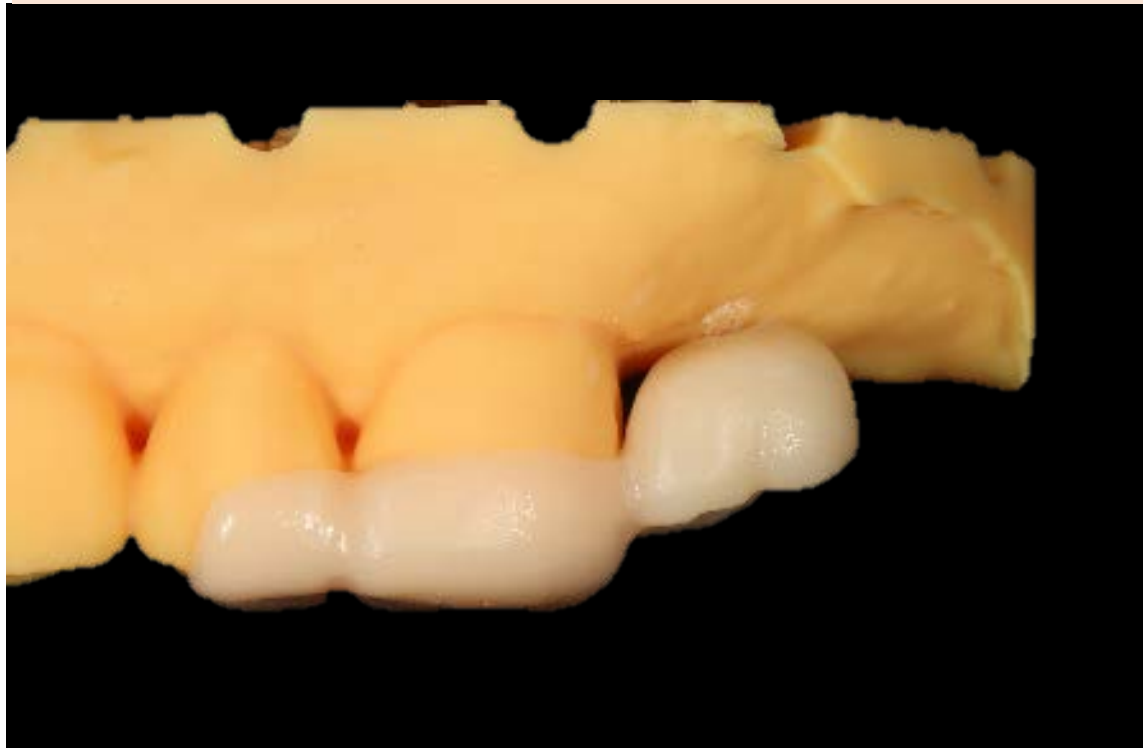
Digital Minimalism : **Crown guide**

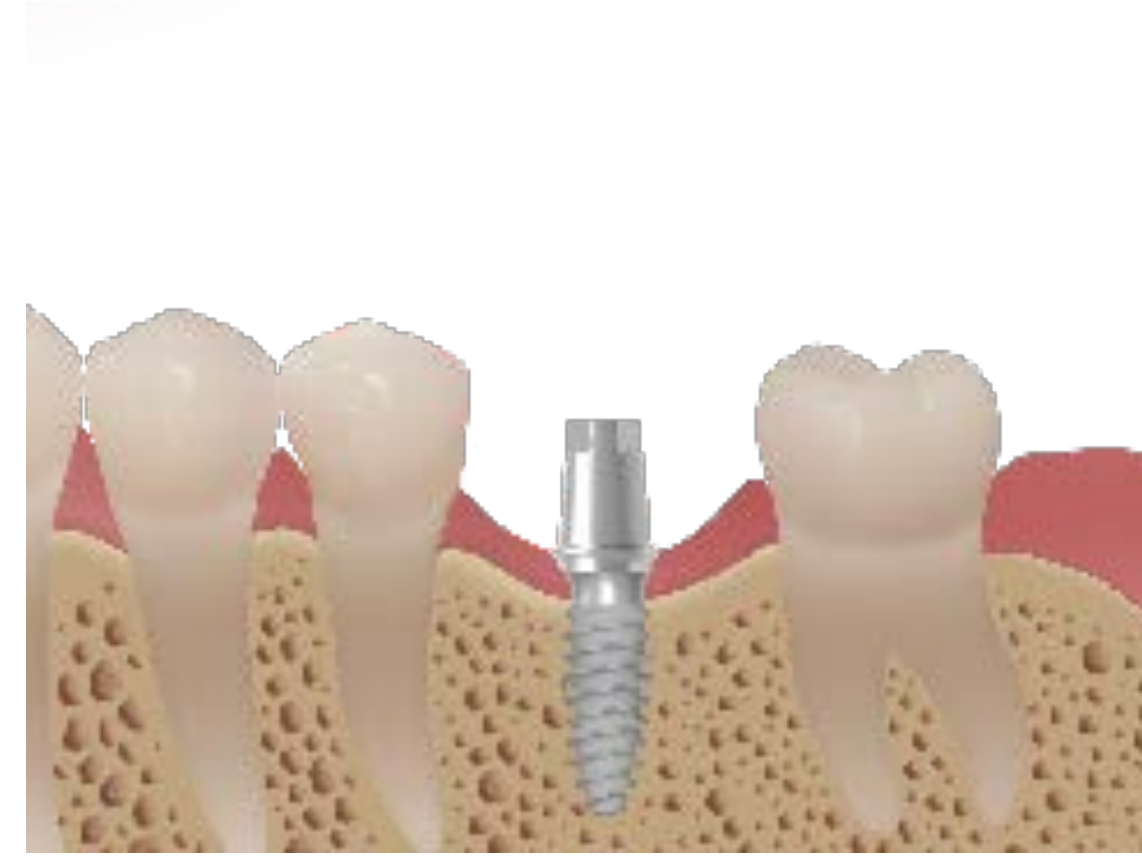
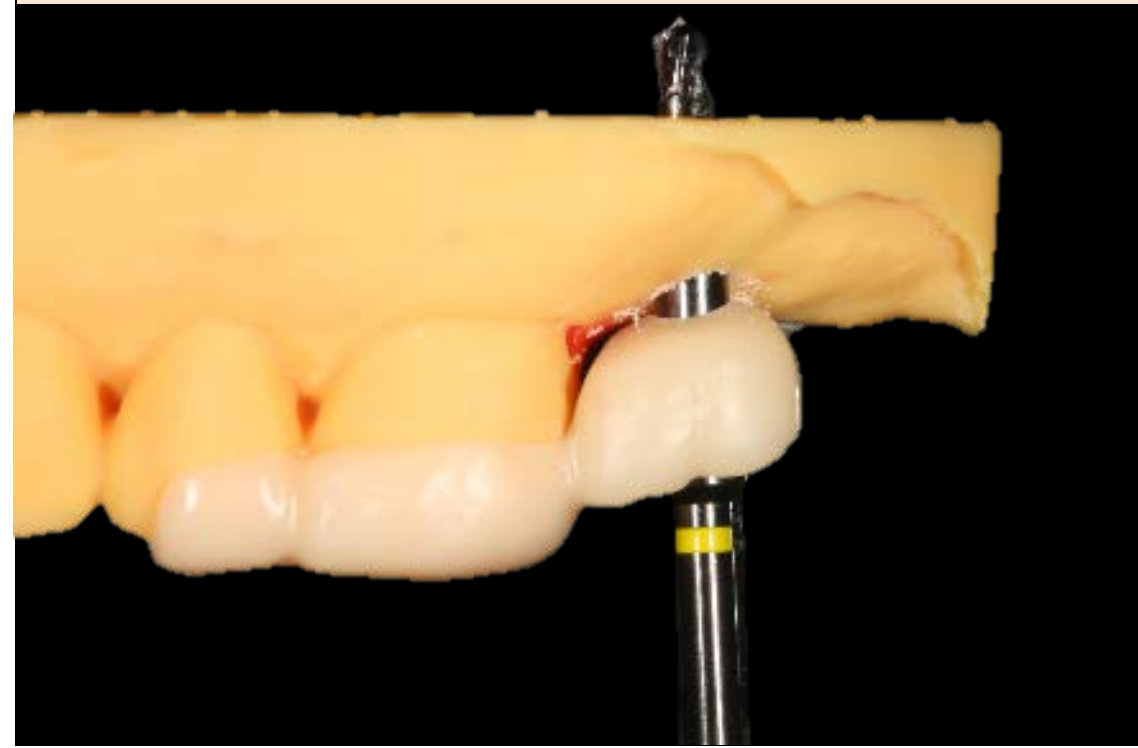
무엇을! 어떻게!



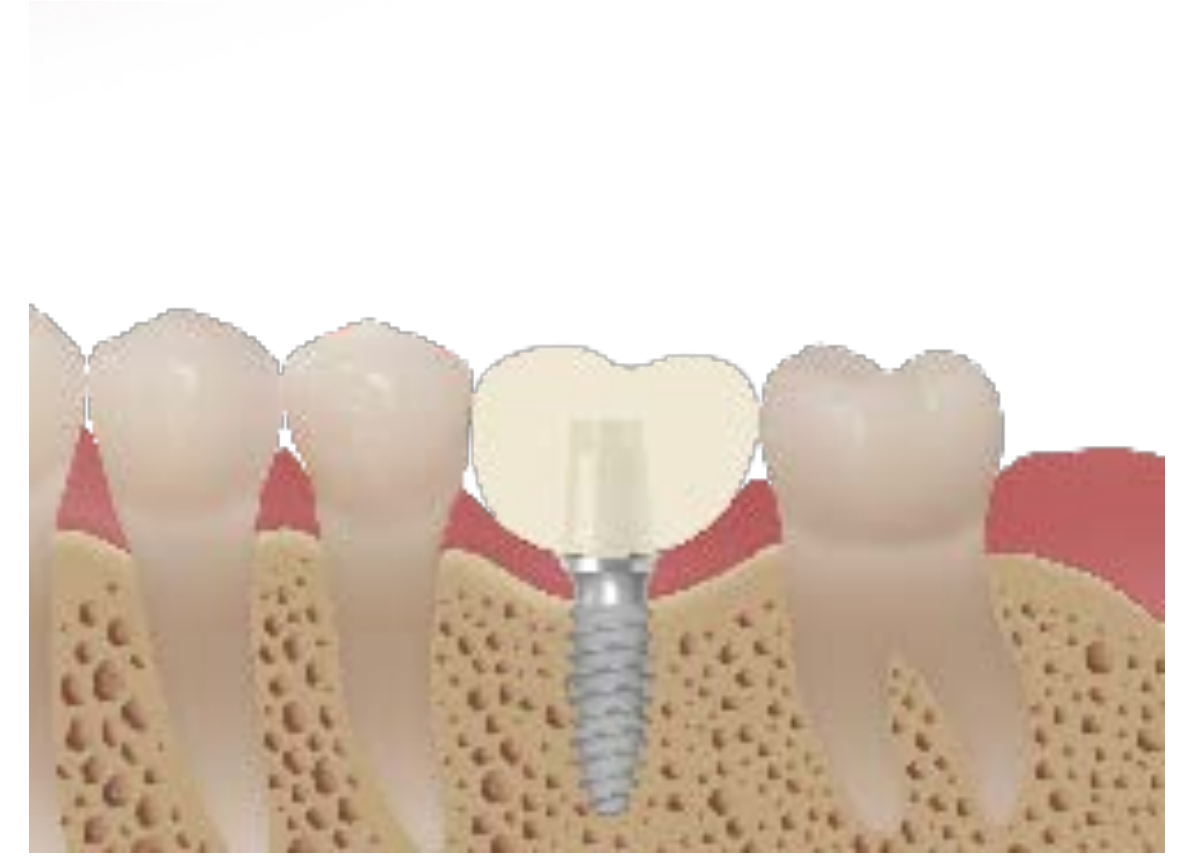
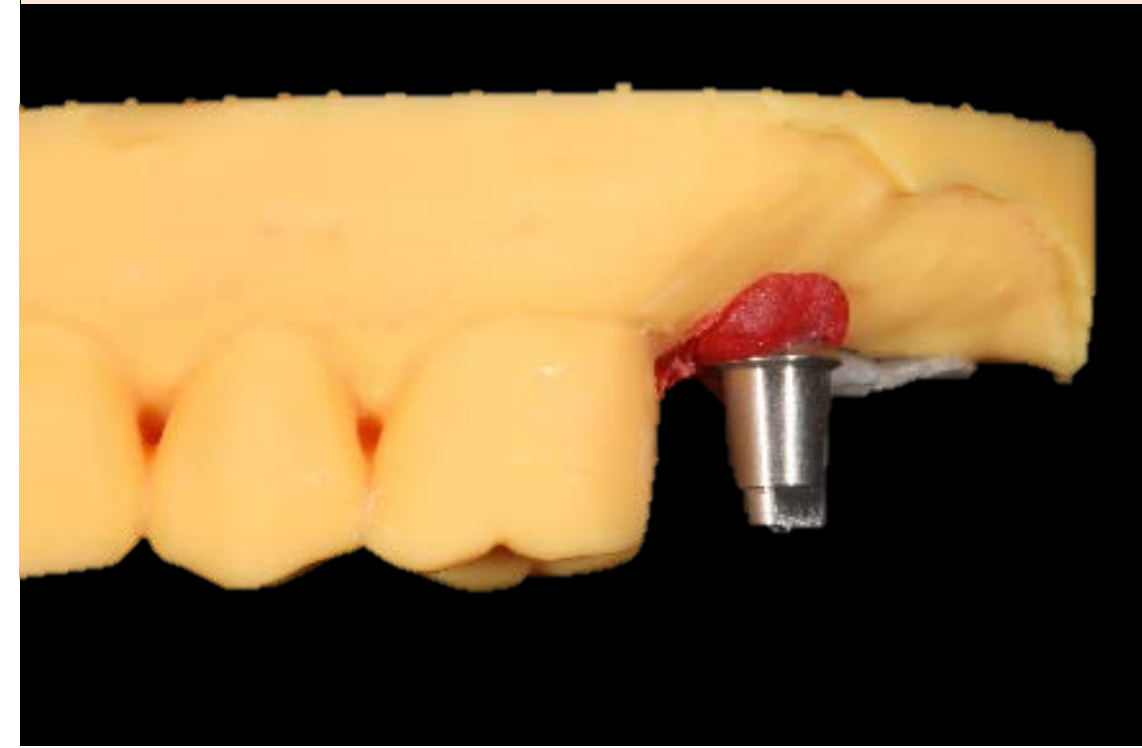
adaptation



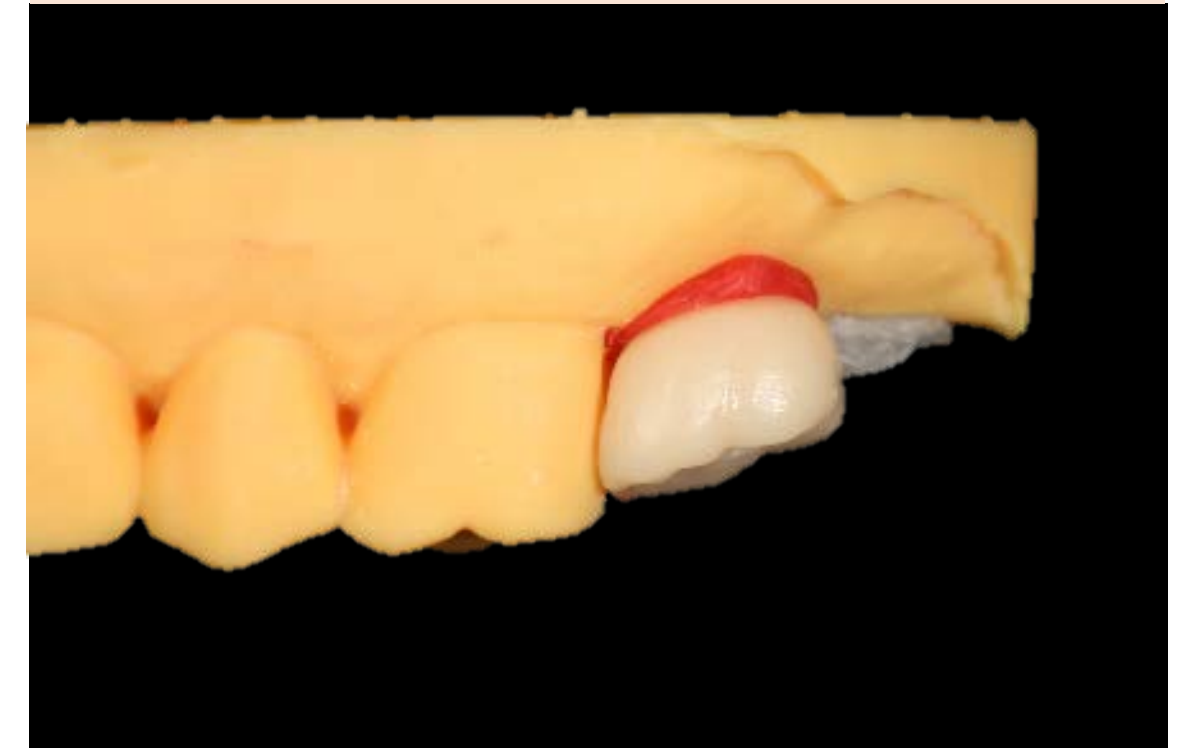drilling



implantation



delivery

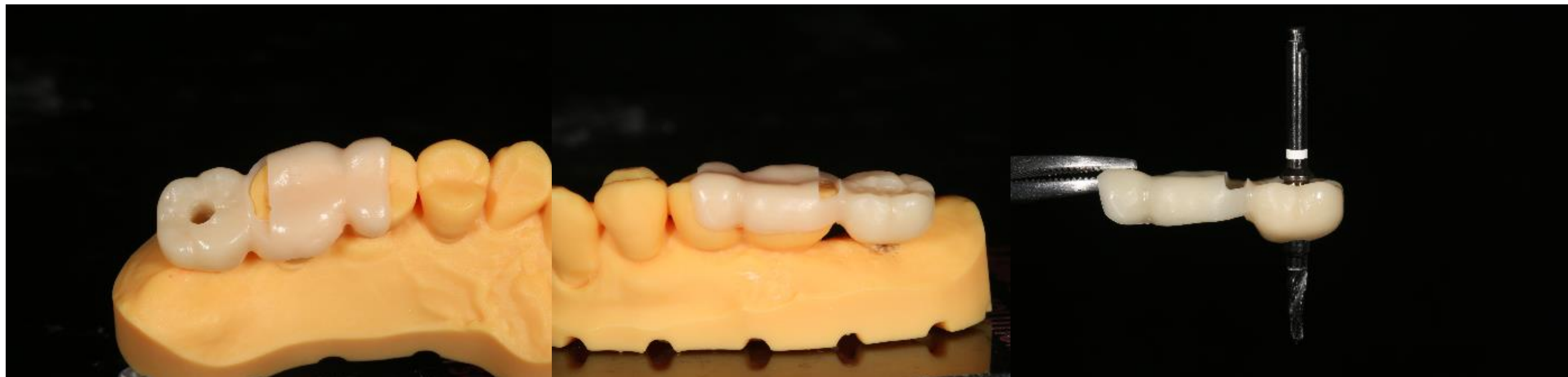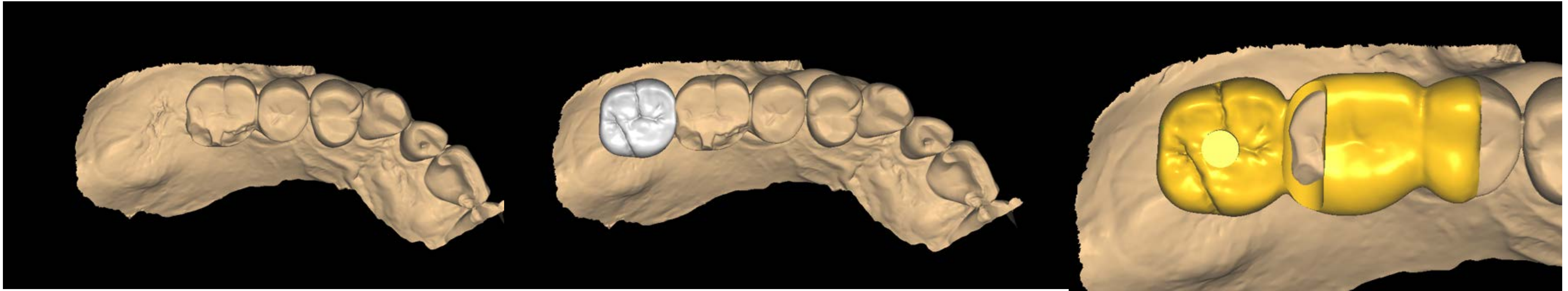


Digital Minimalism : **Crown guide**

무엇을! 어떻게!

Case 2_#17

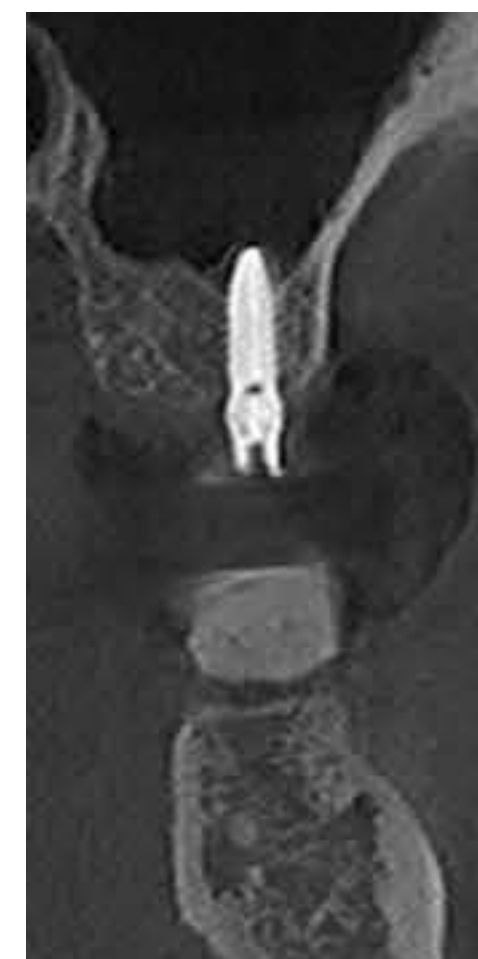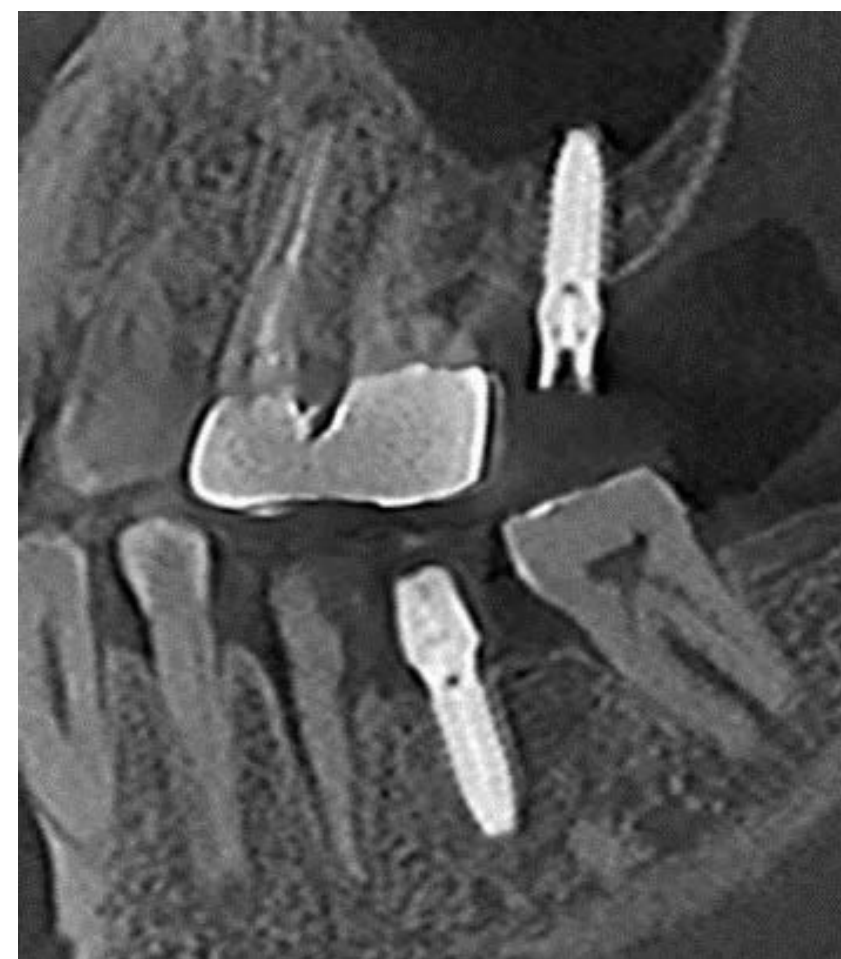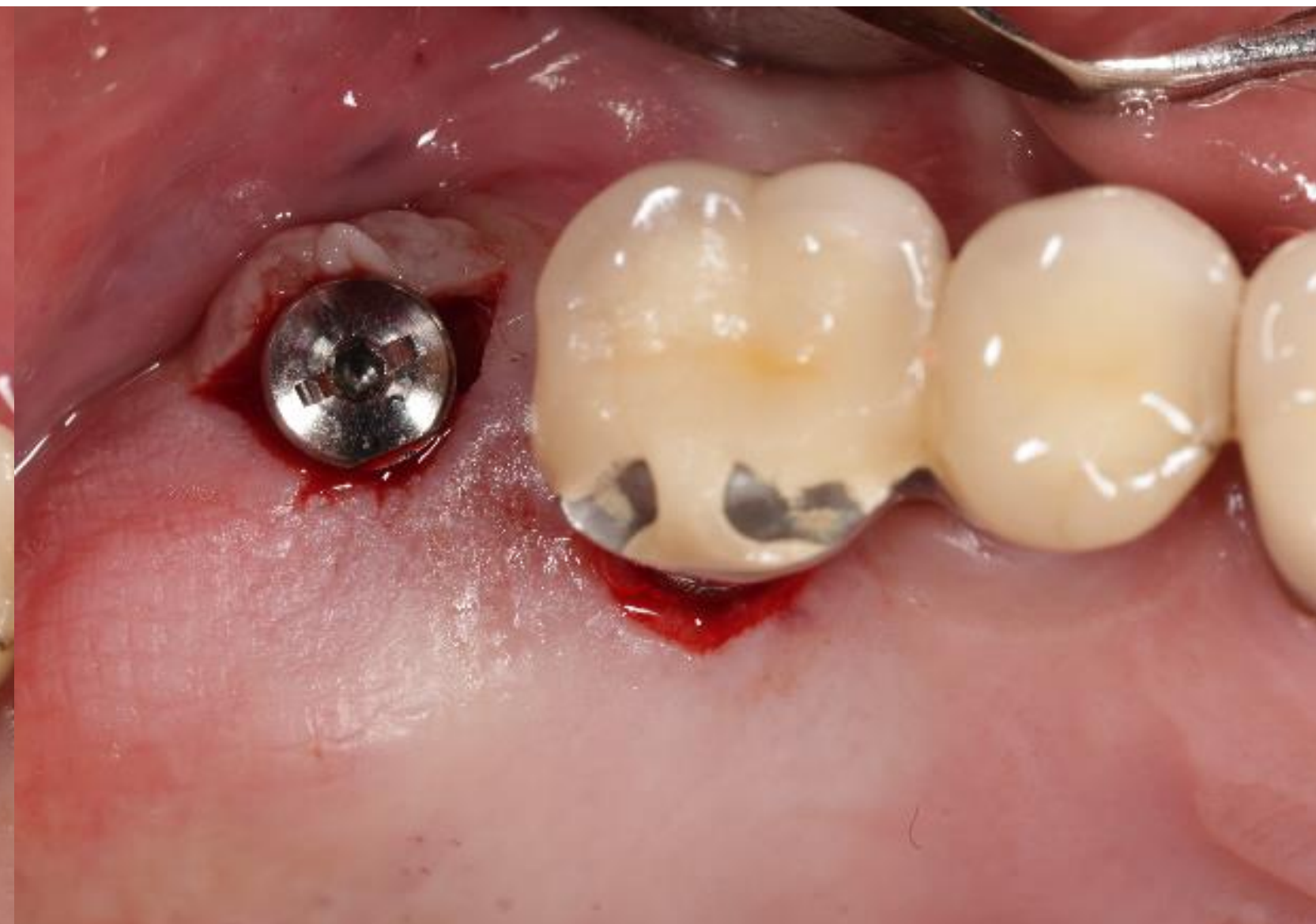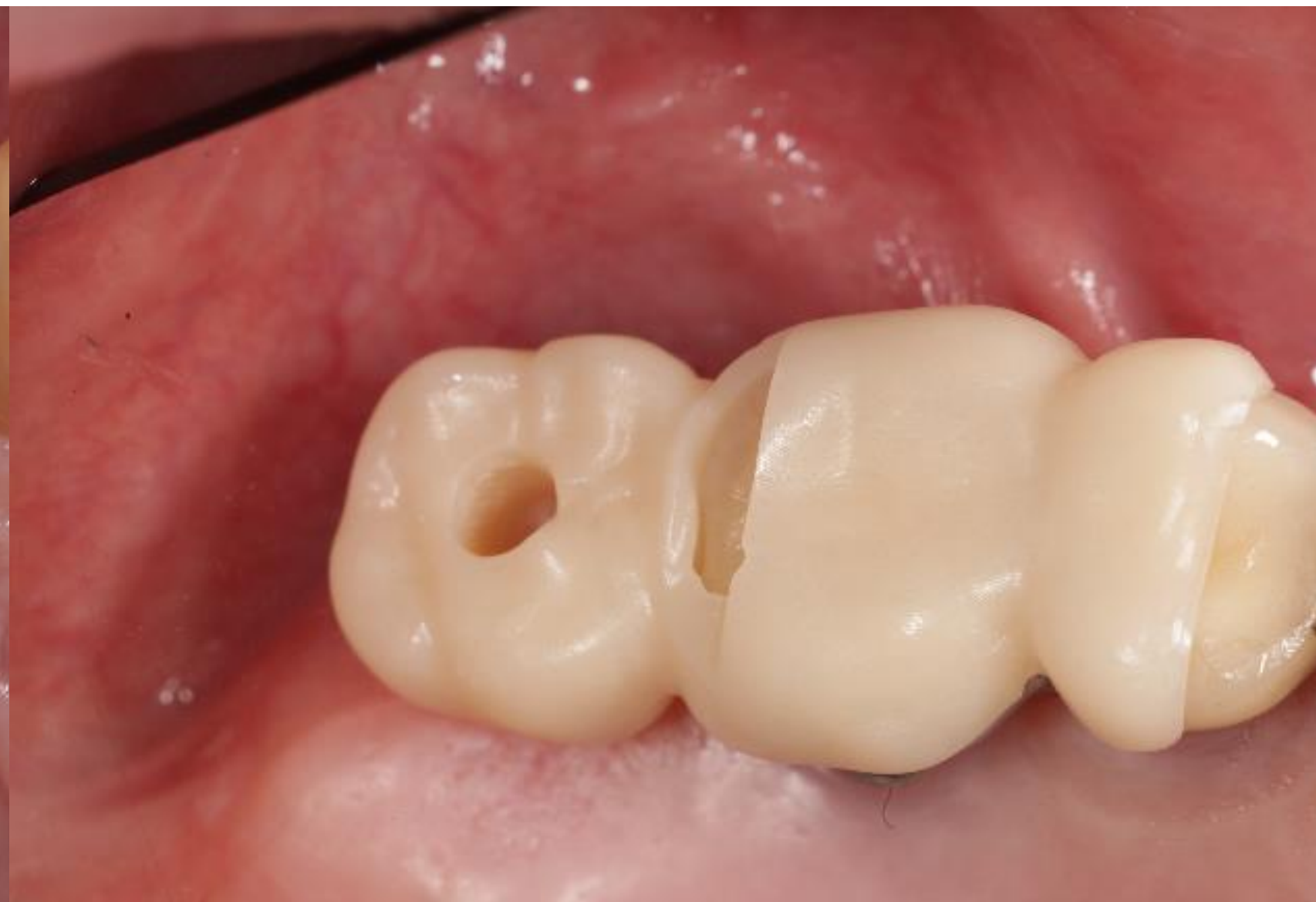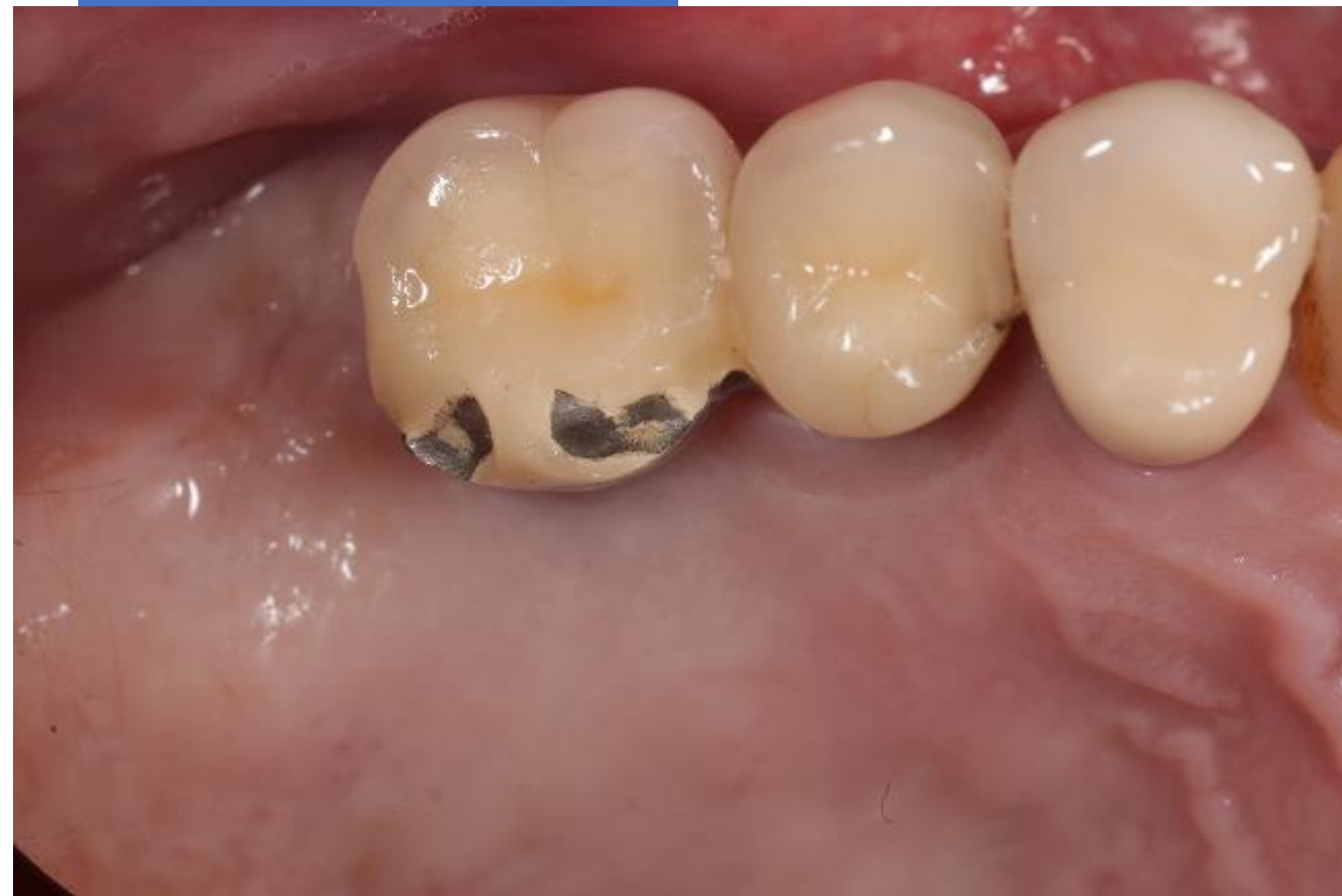제작과정



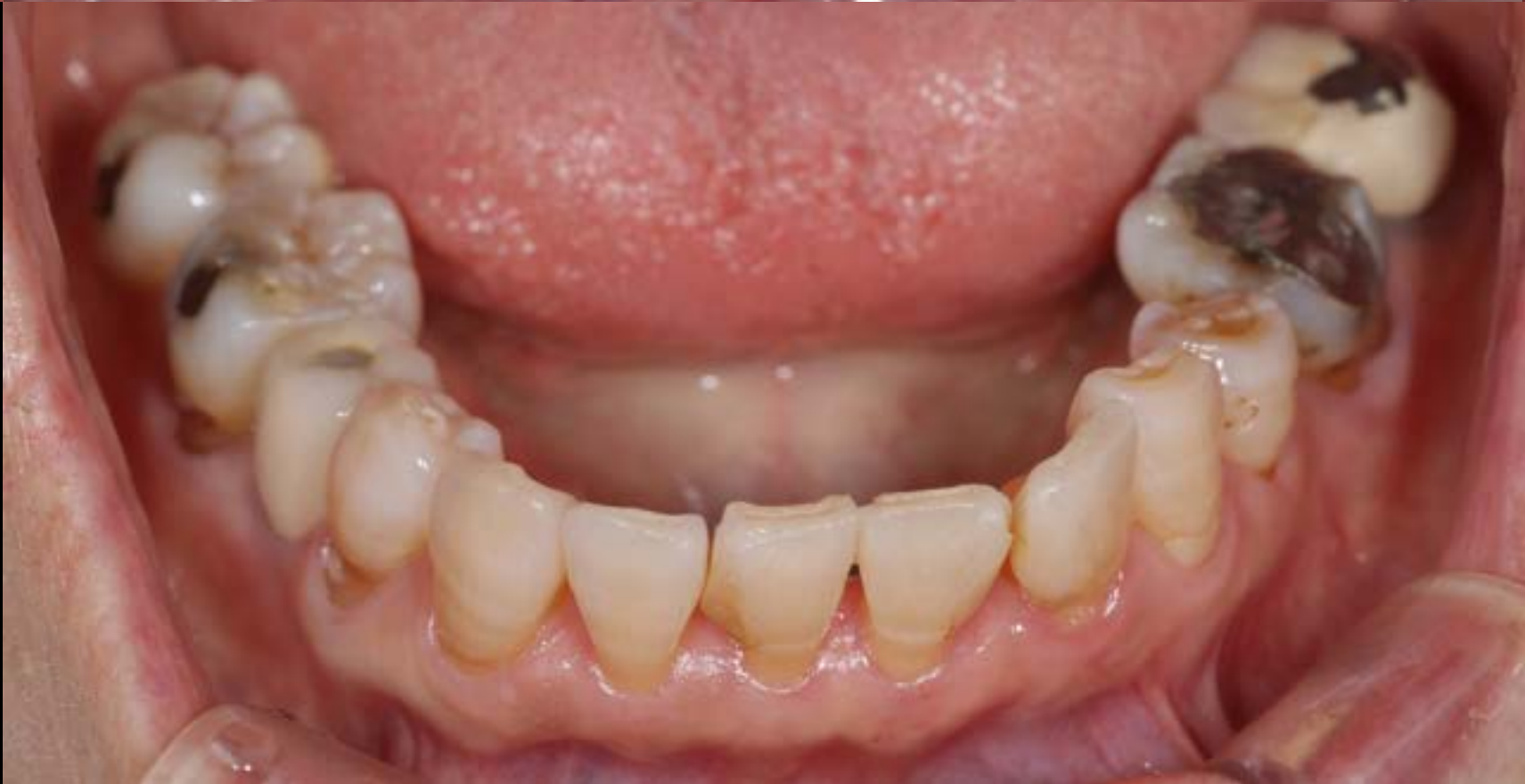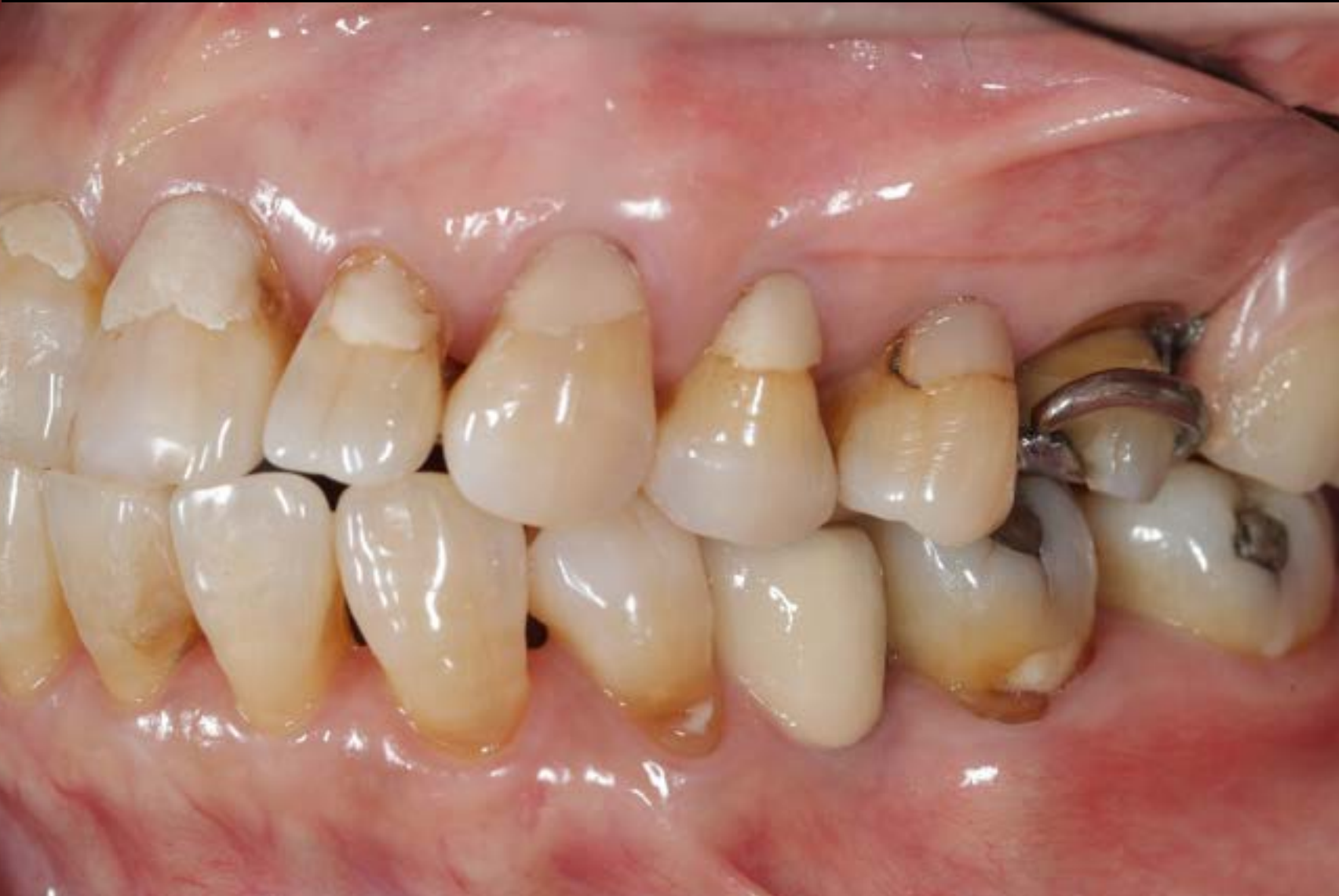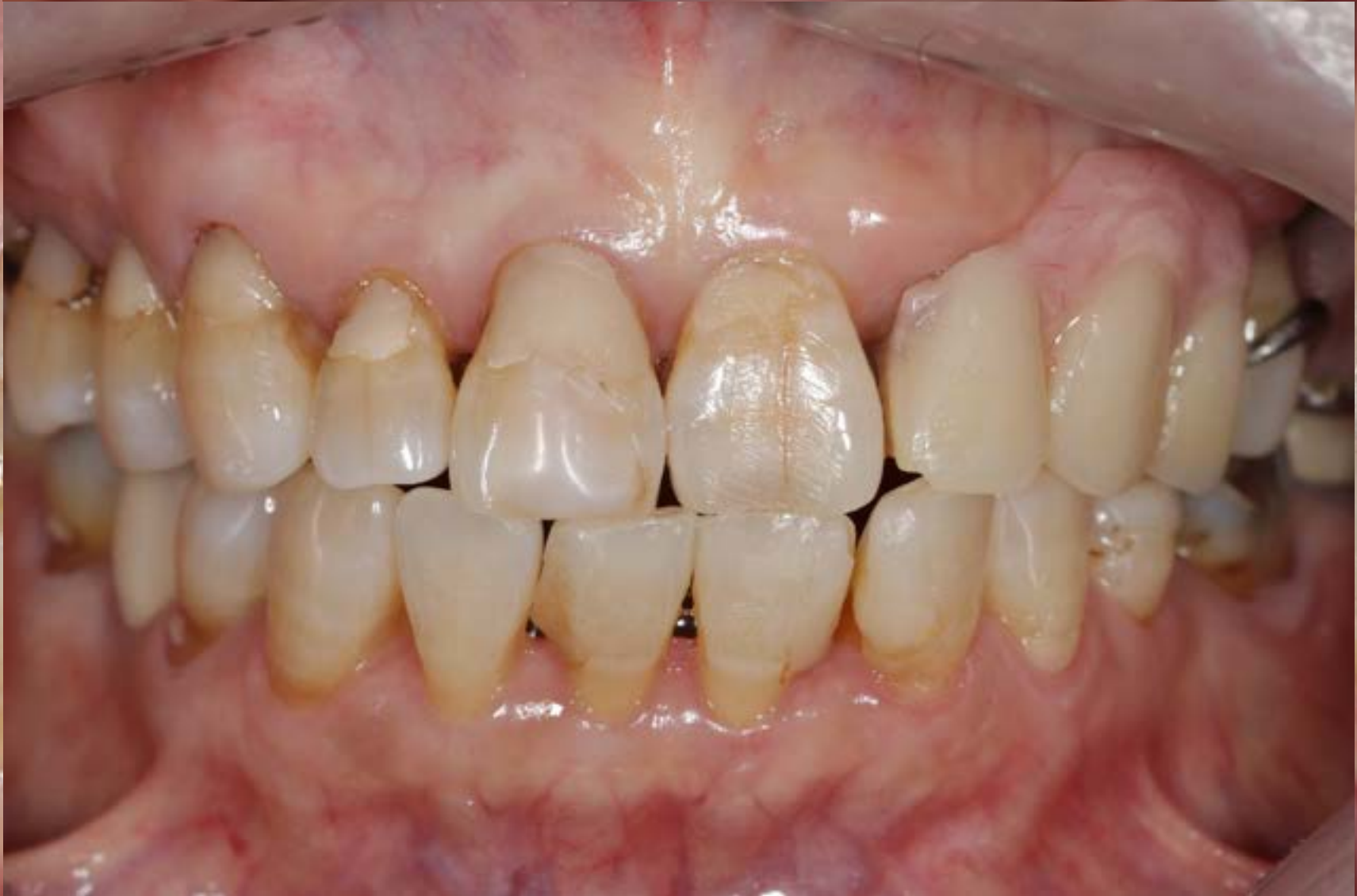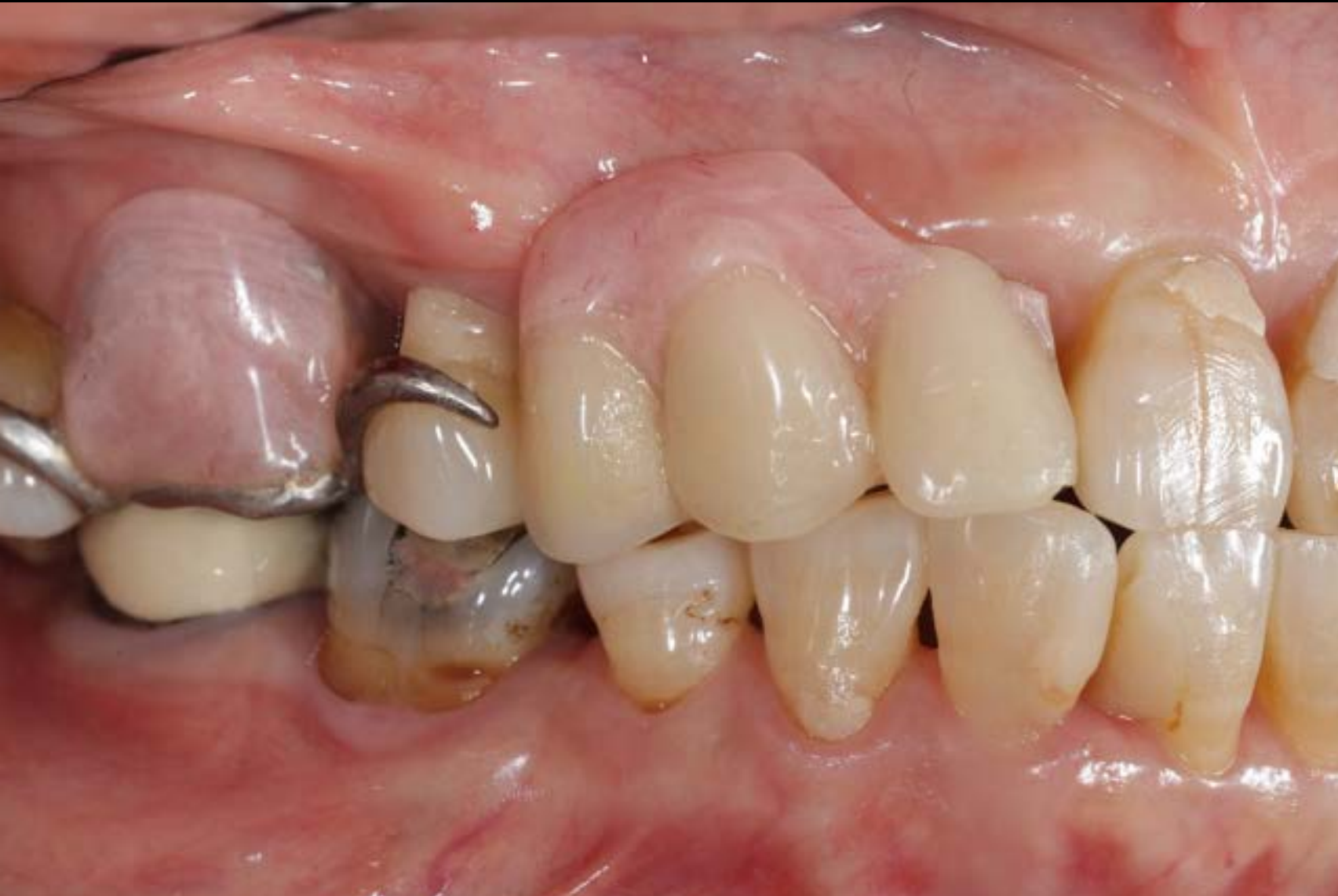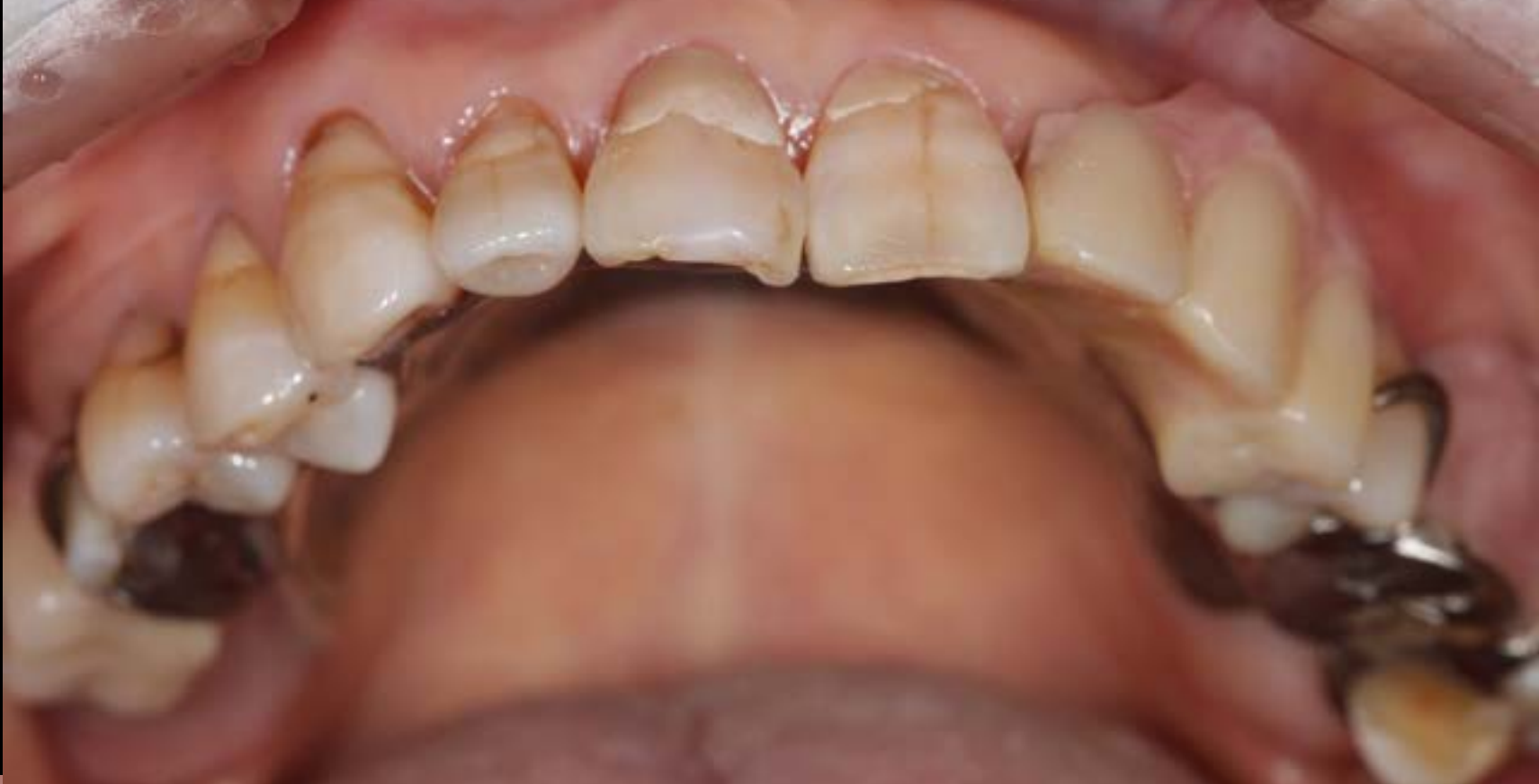Digital Minimalism : Crown guide

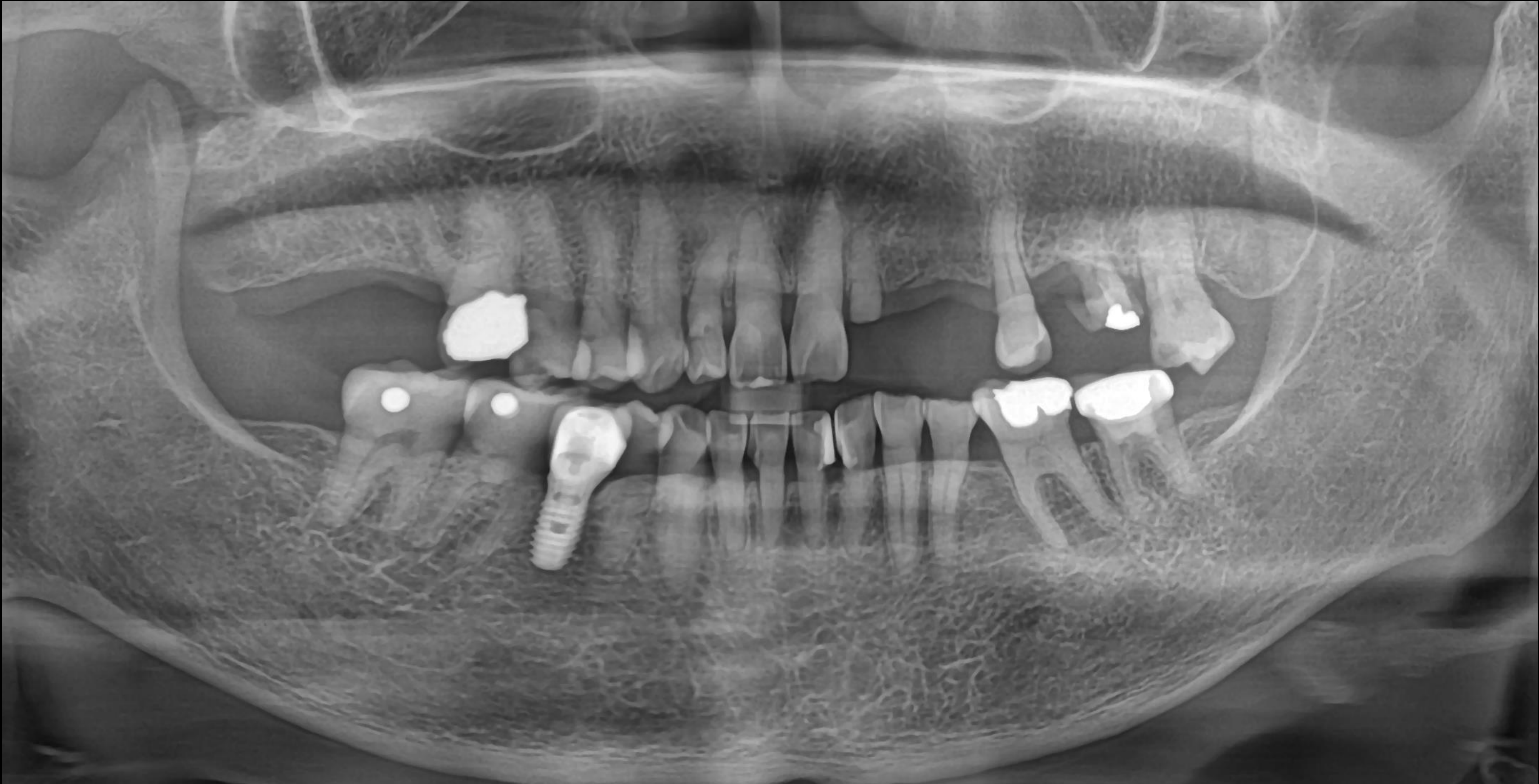무엇을! 어떻게!

Case 2_#17

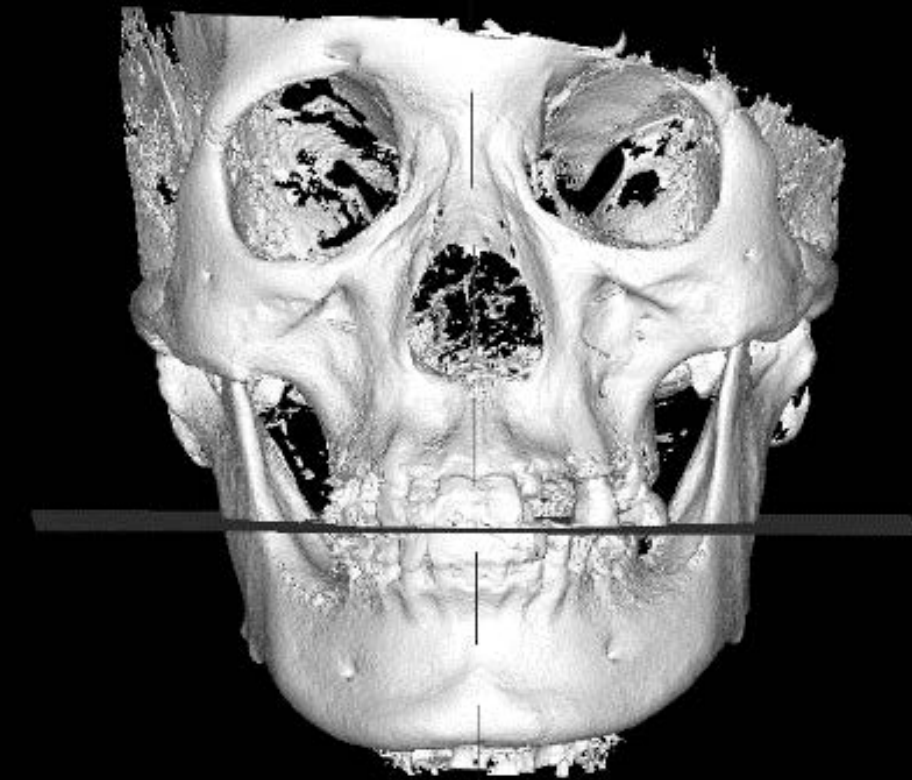
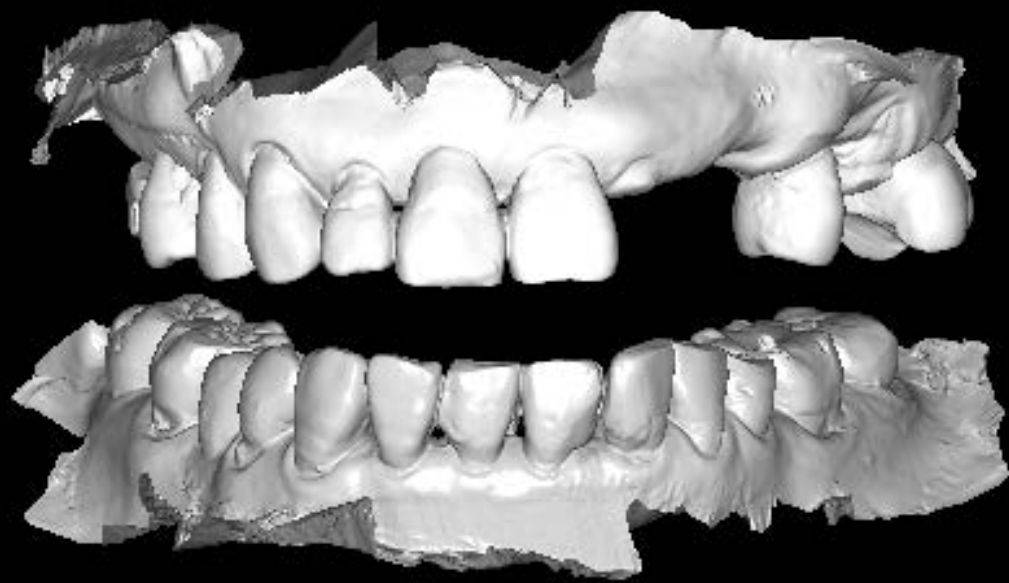

Pre-op(2024-03-06)

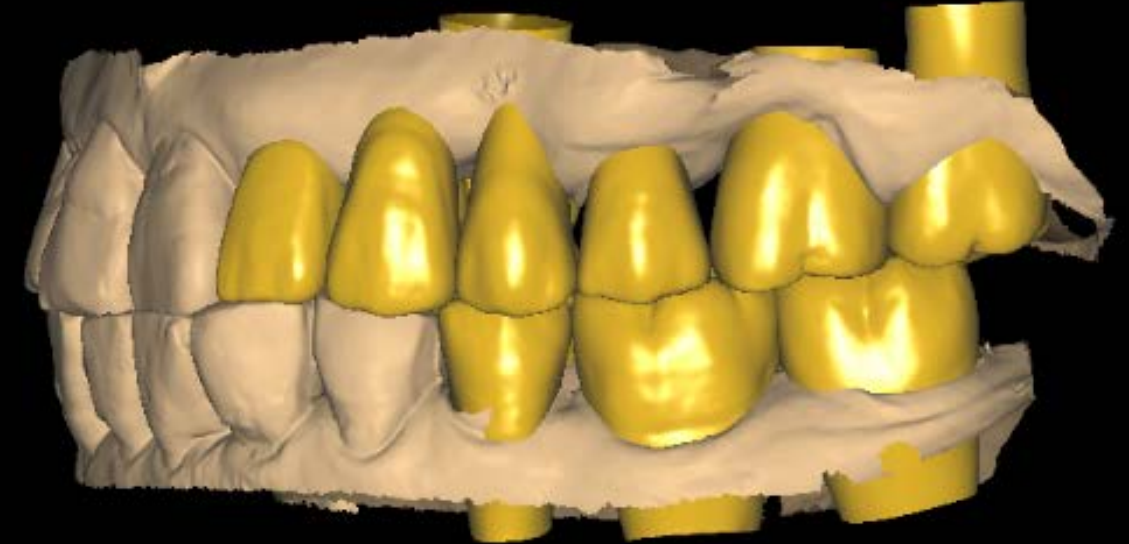
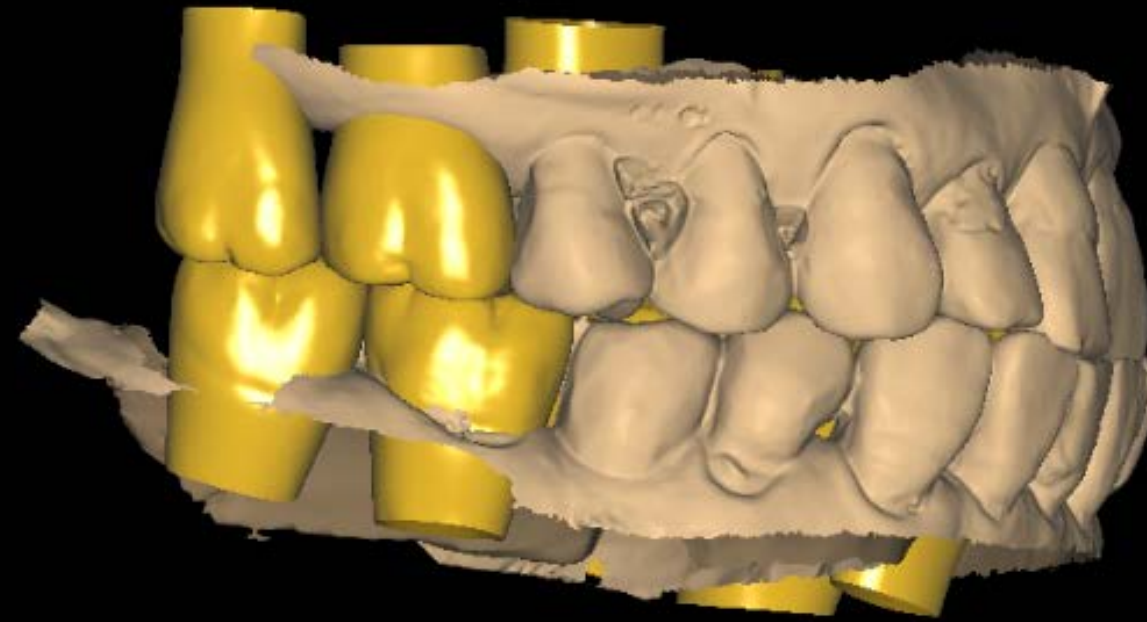
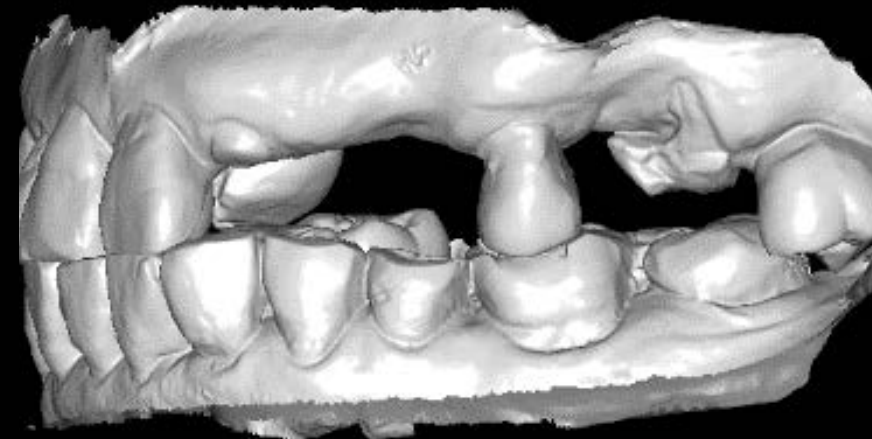
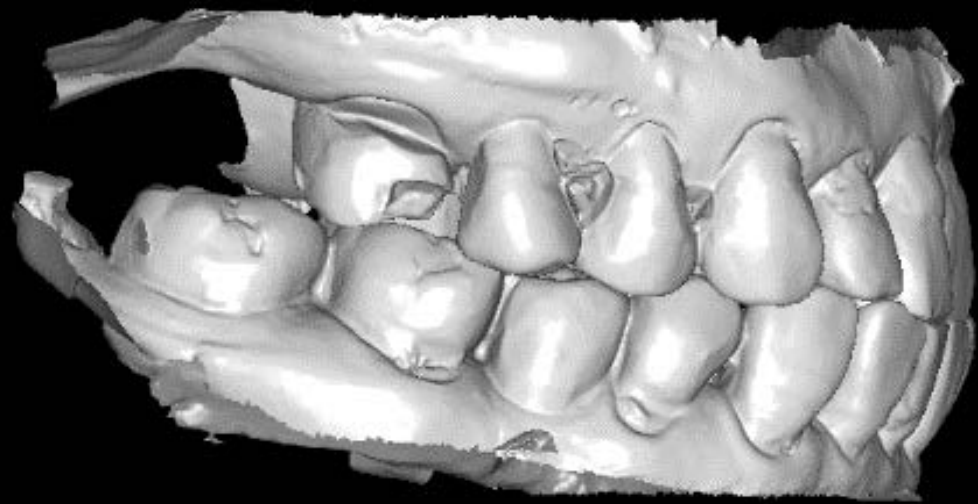
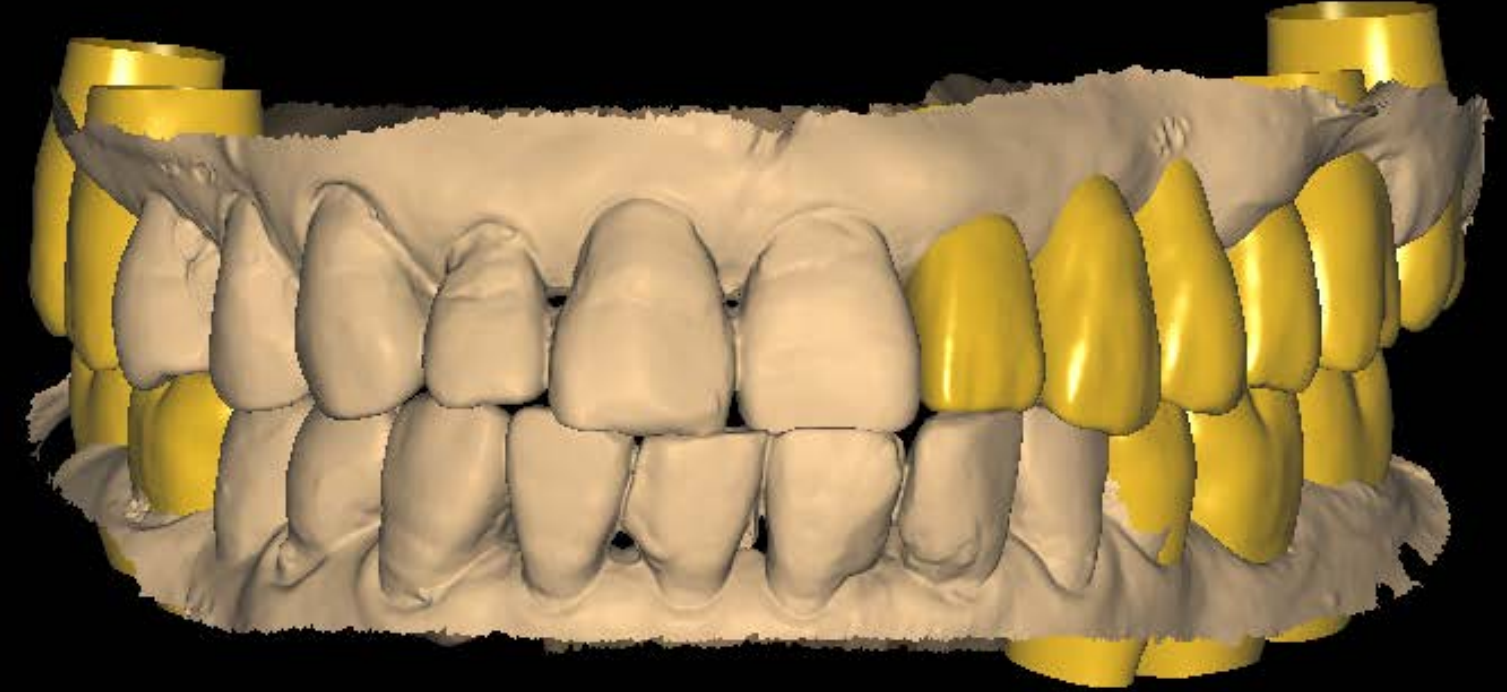
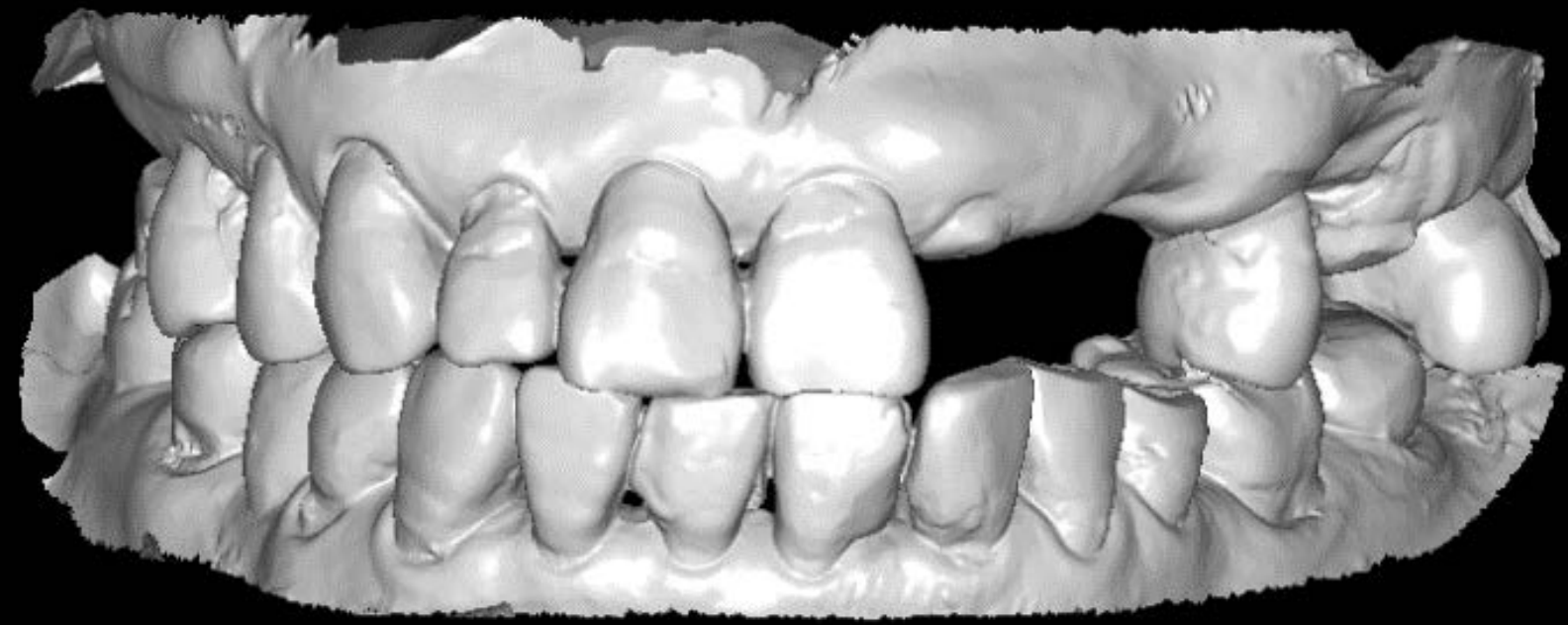


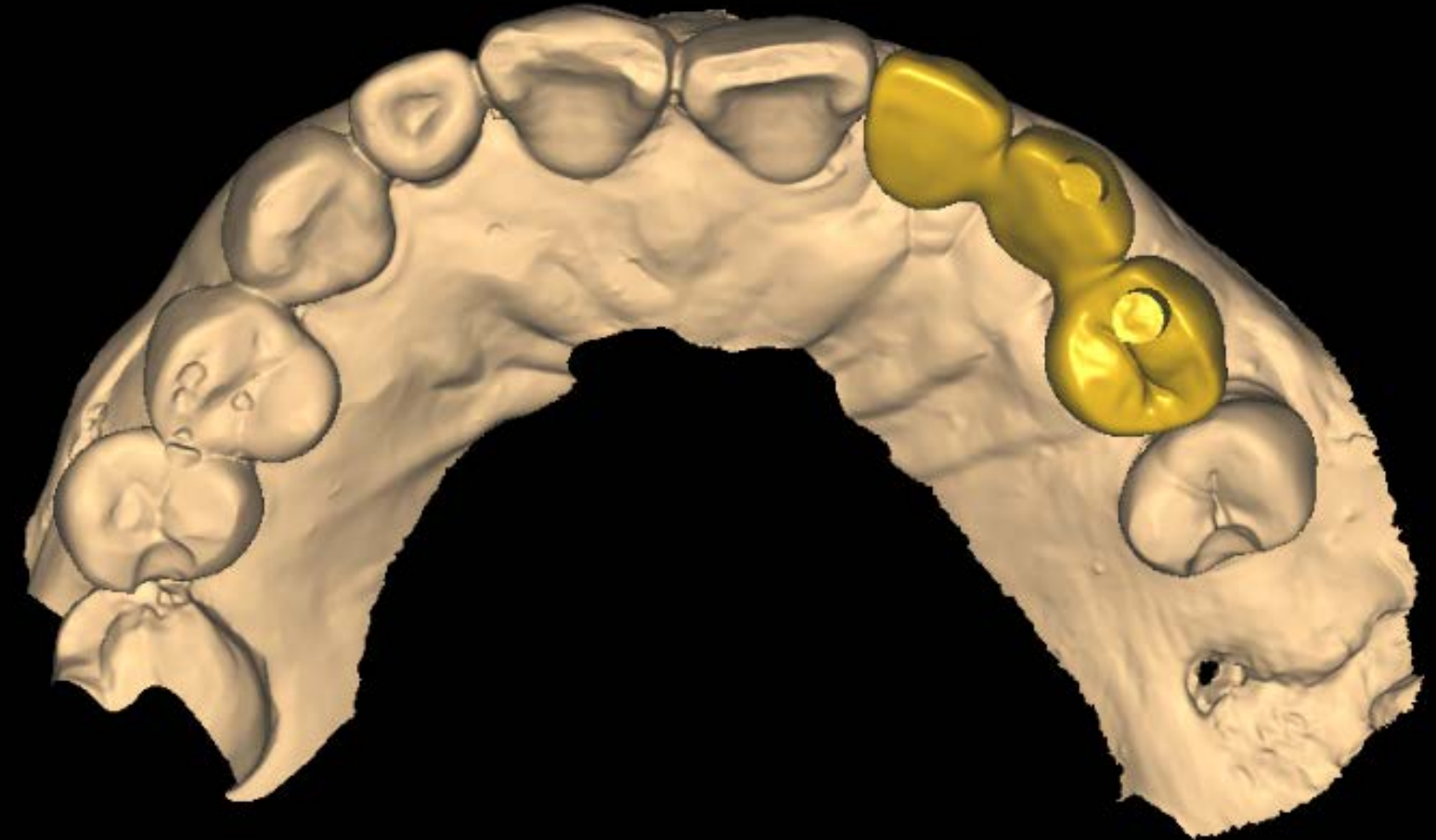
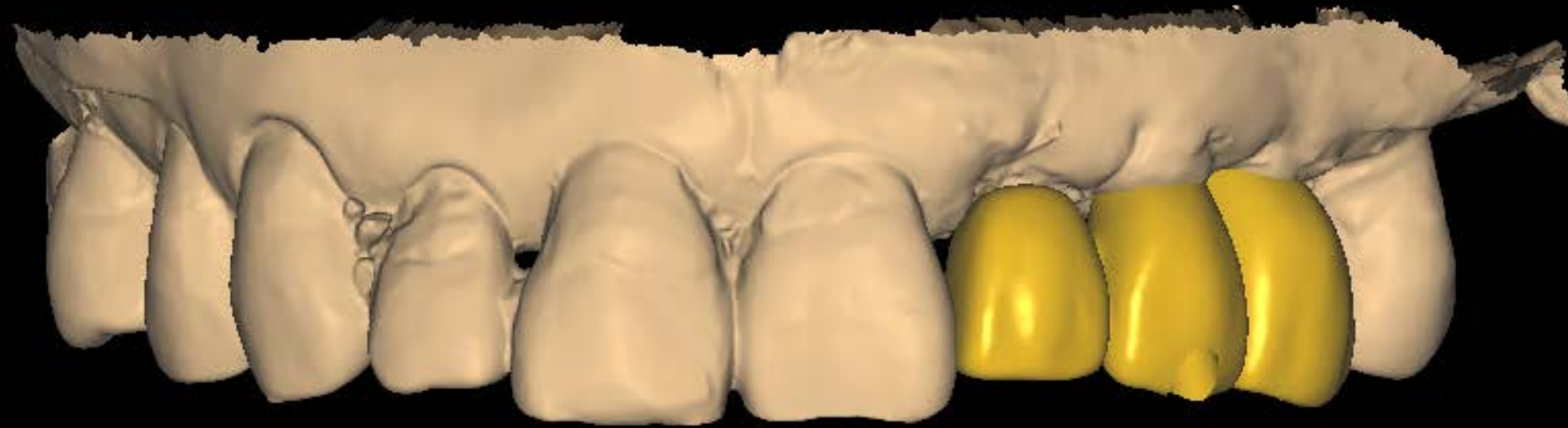
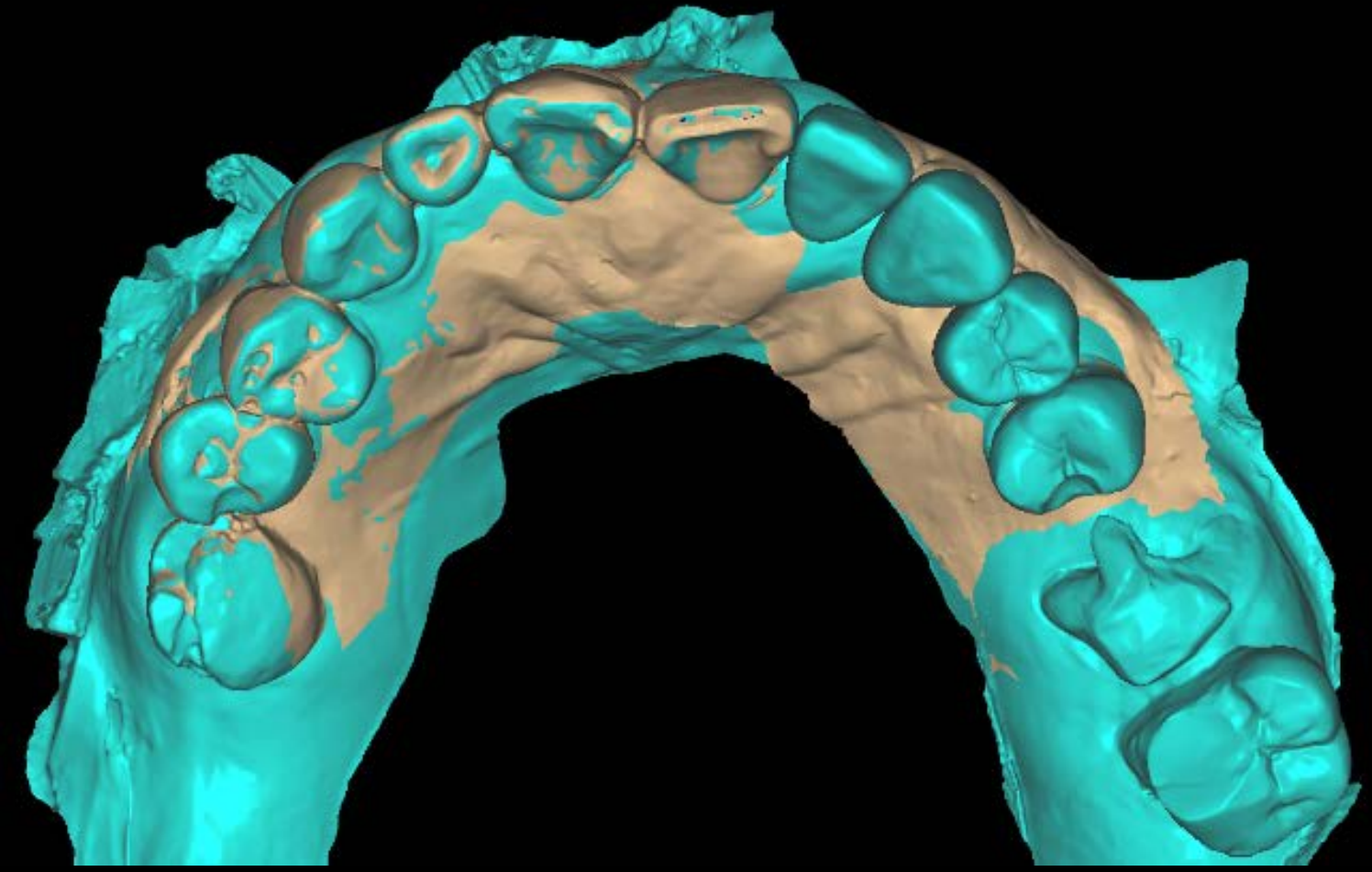
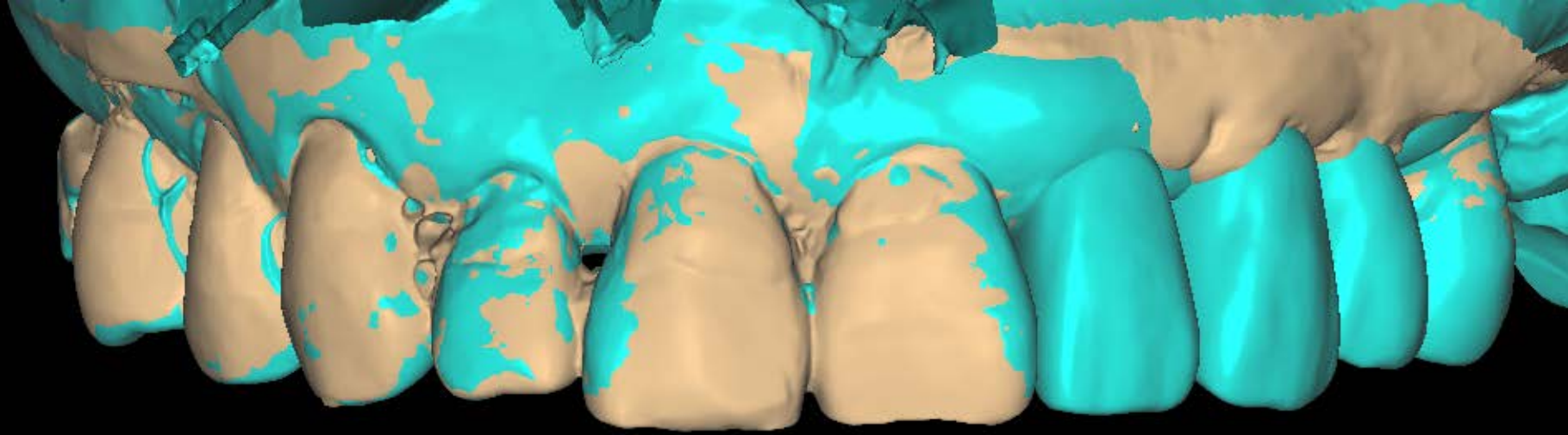
Virtual Set up



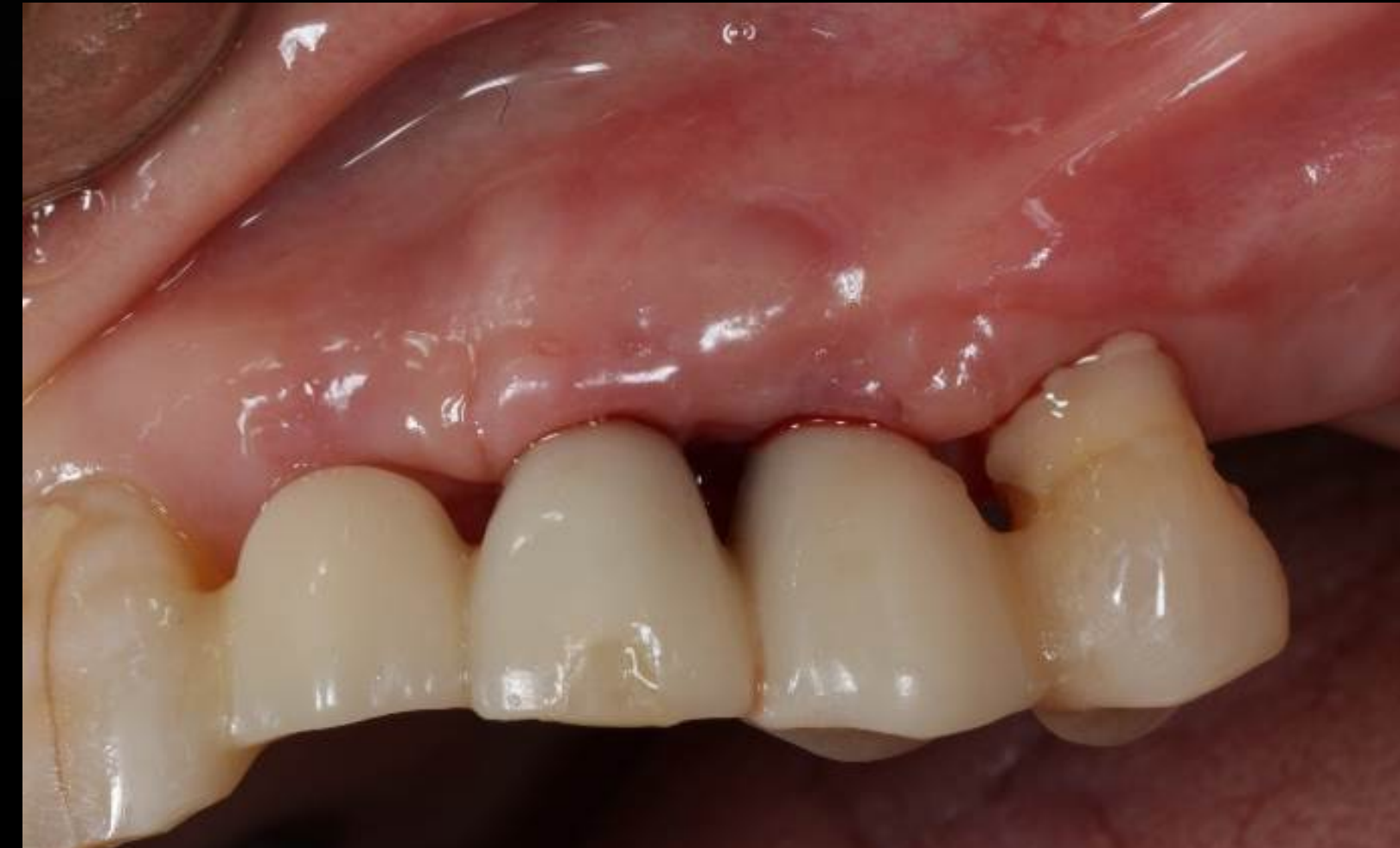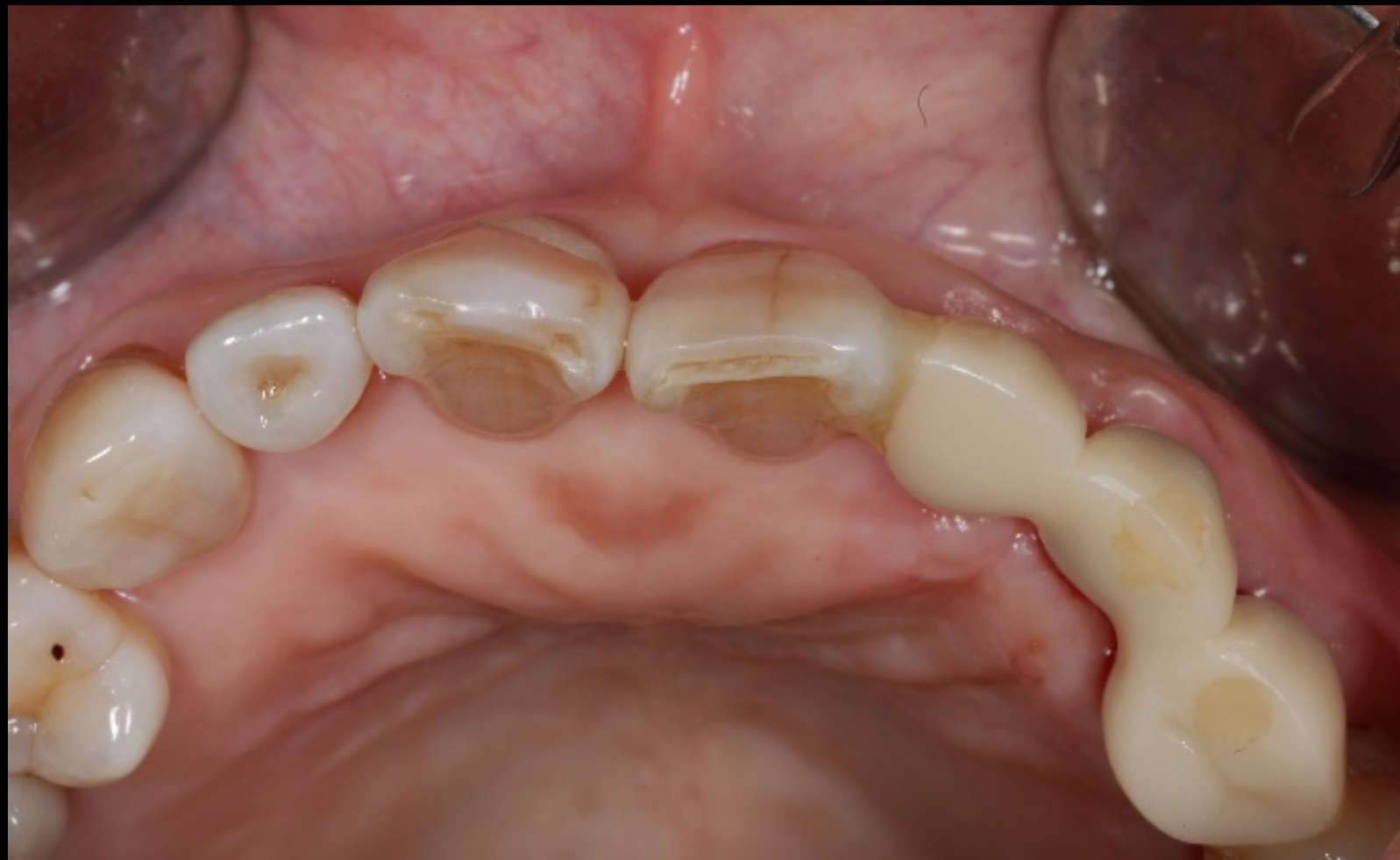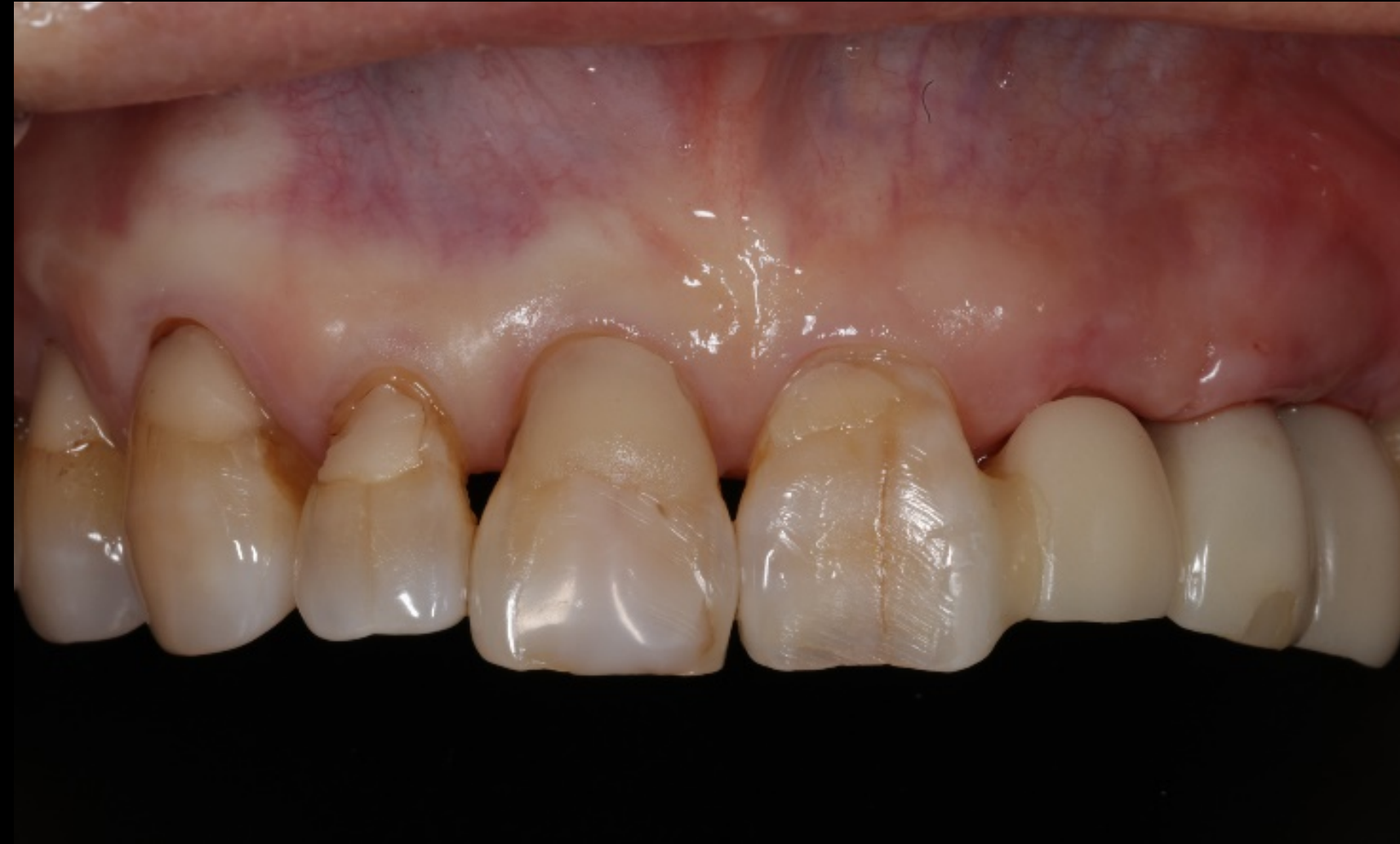Virtual Set up



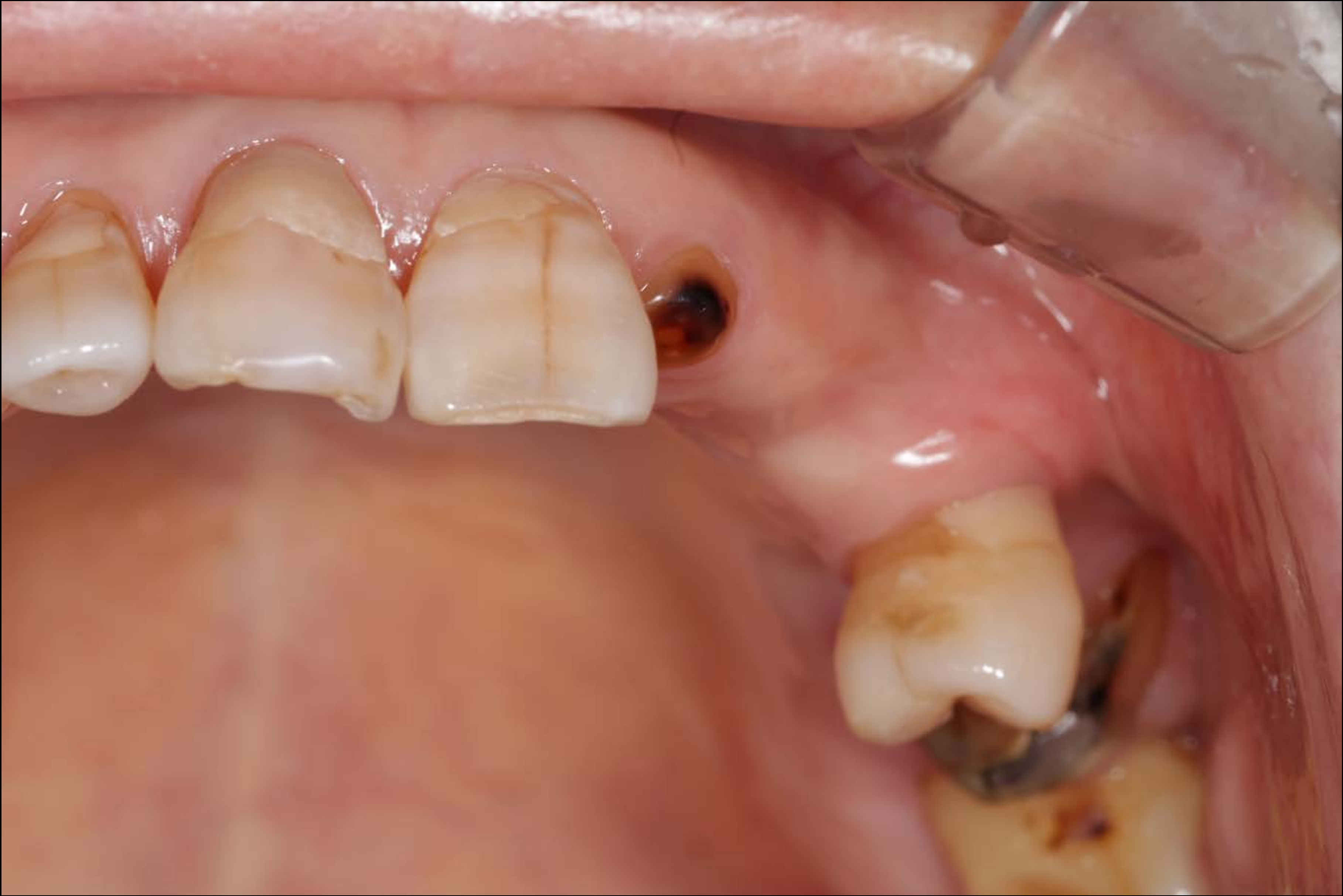Cad Design

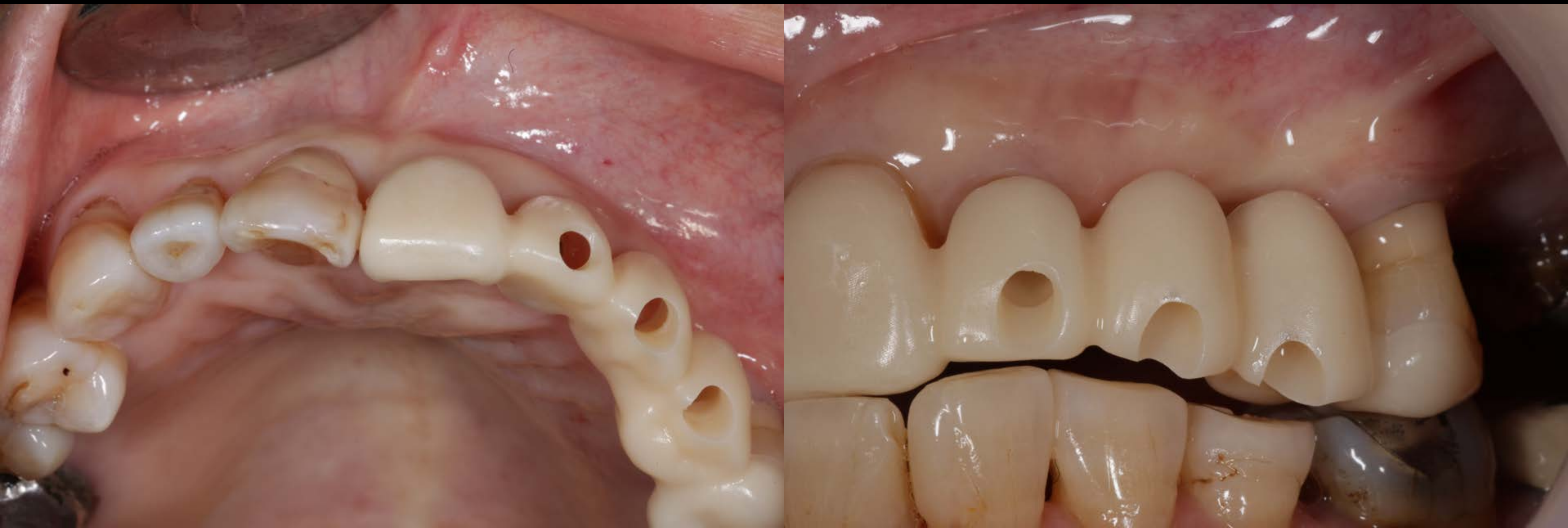


Final Prosthesis

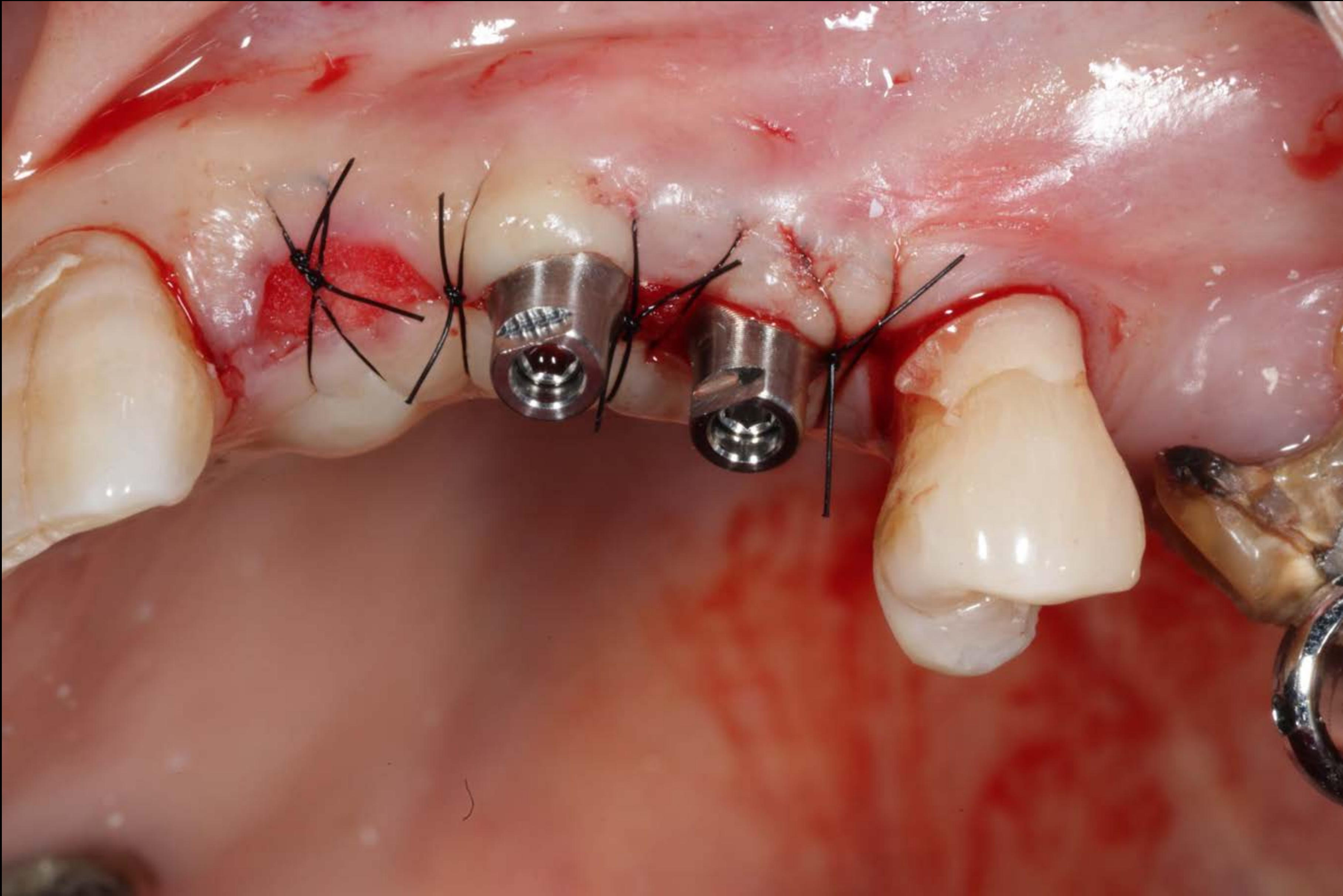


Pre-op(2024-03-06)

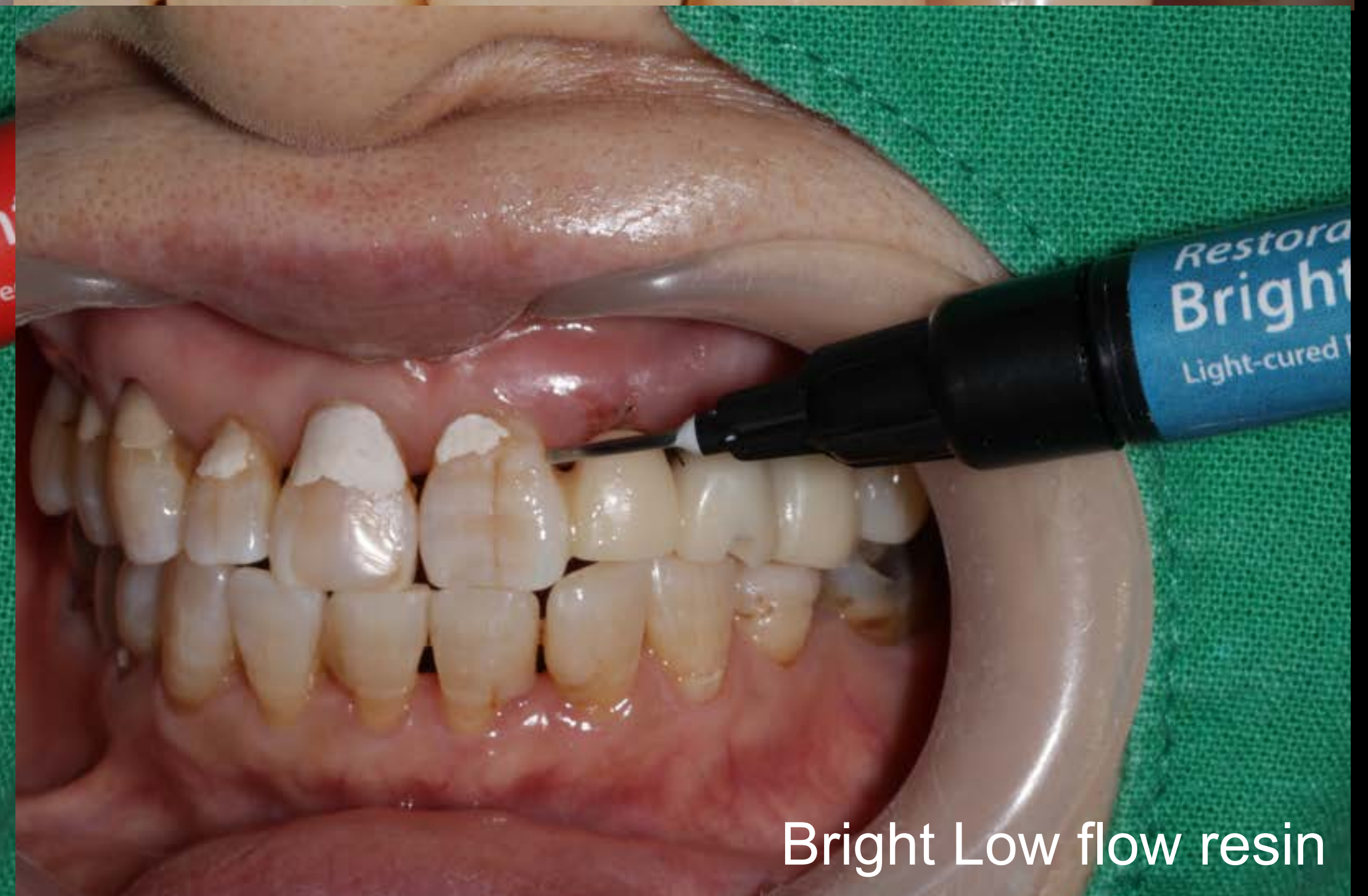
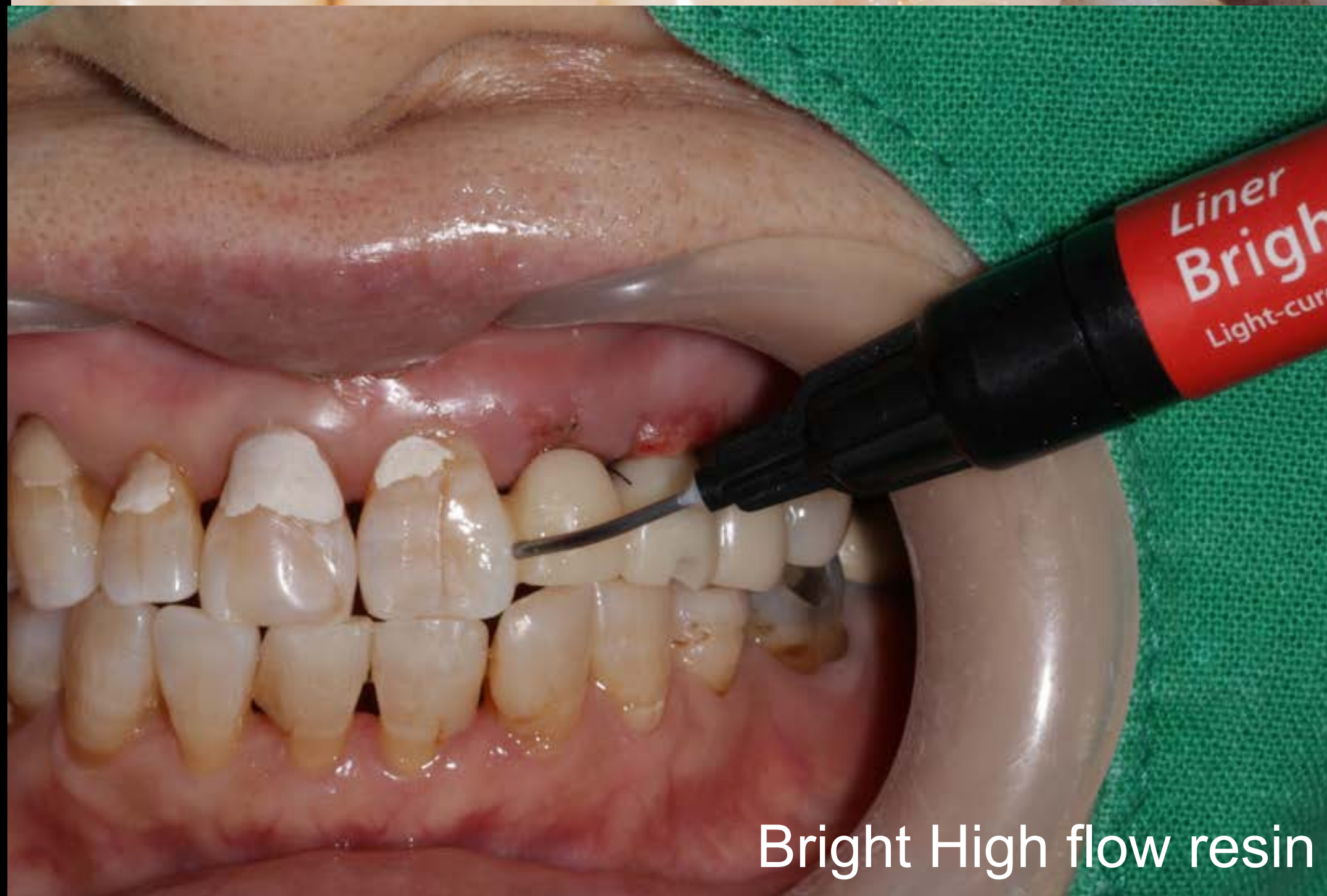
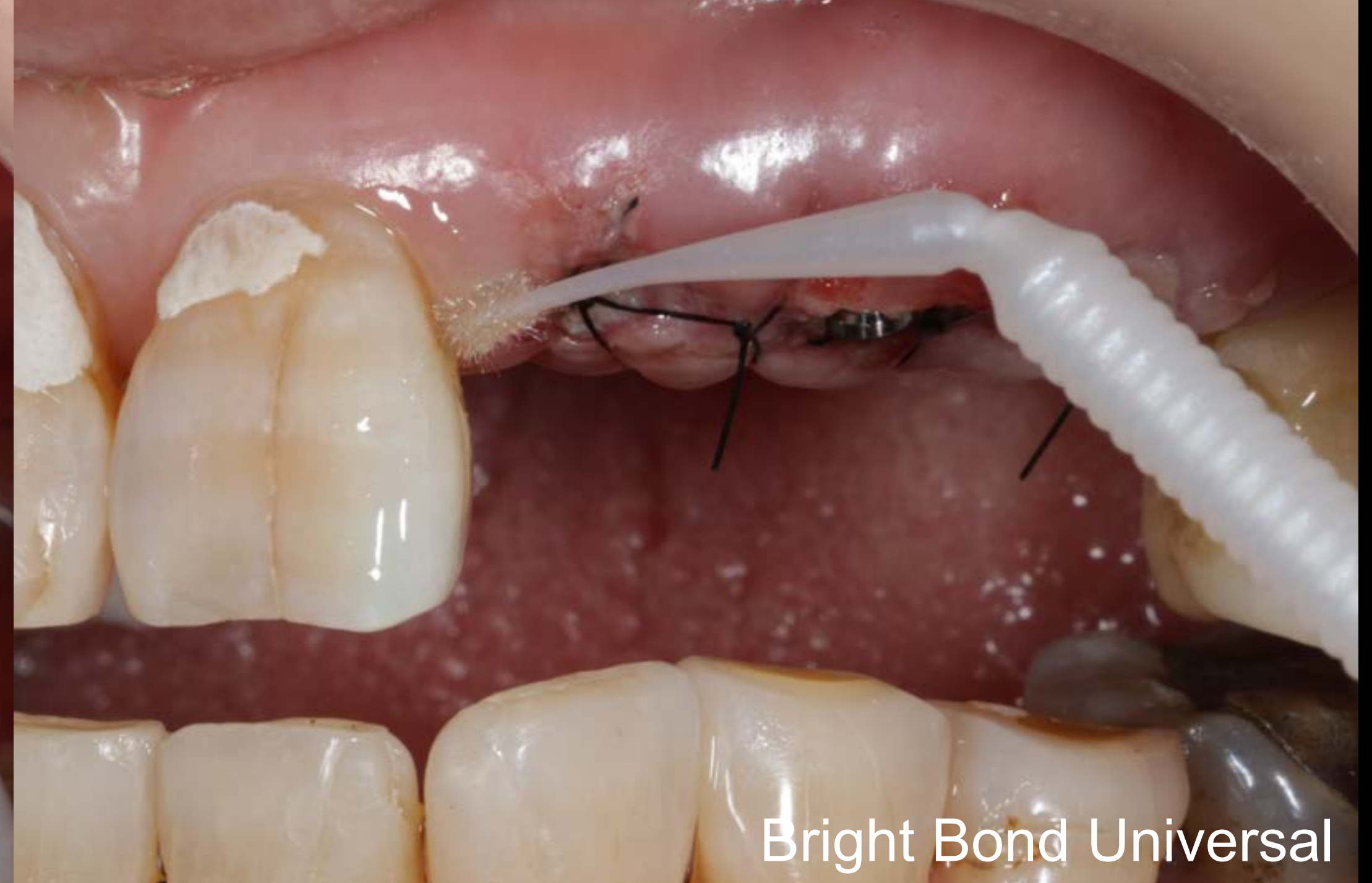
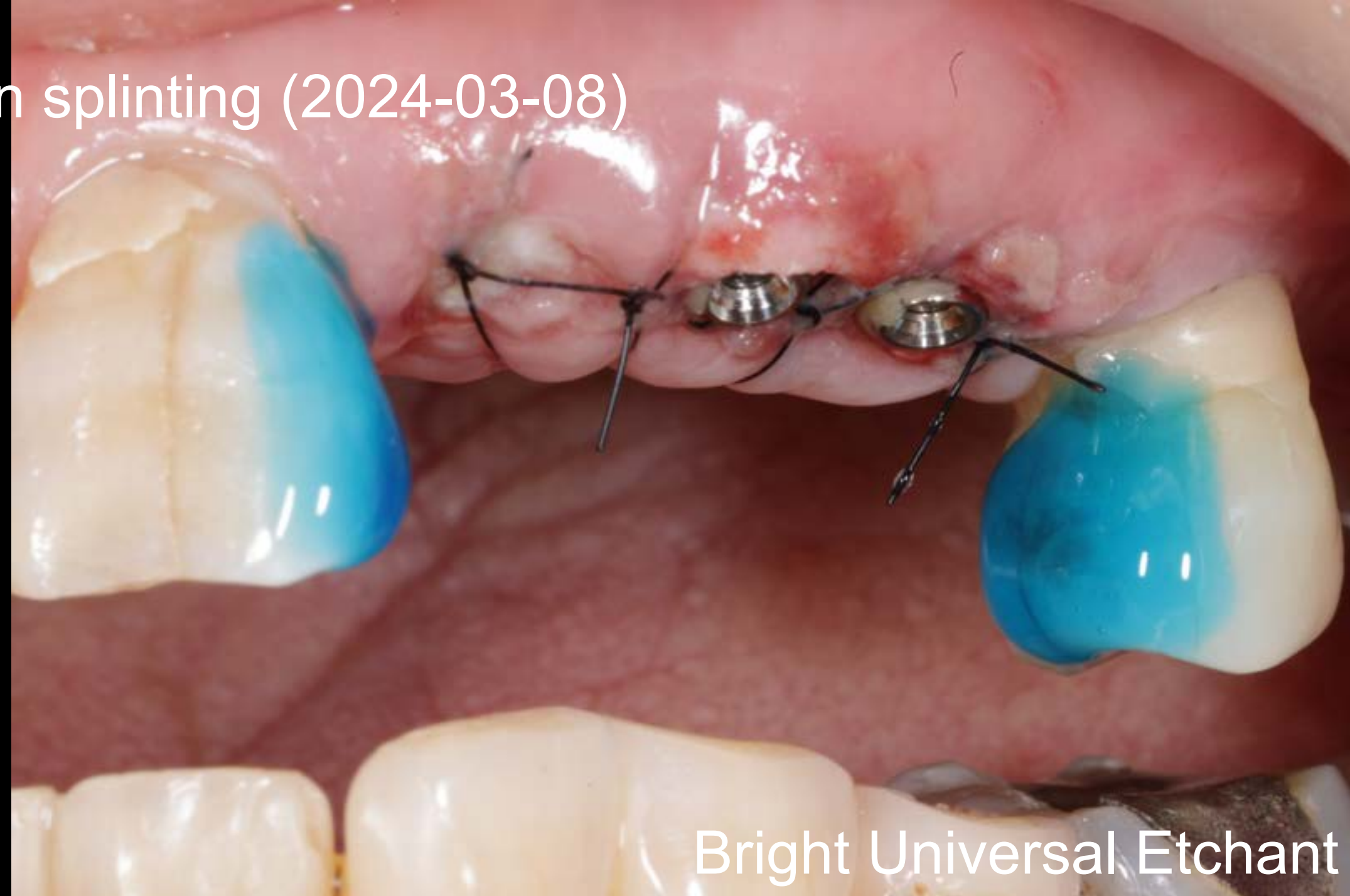
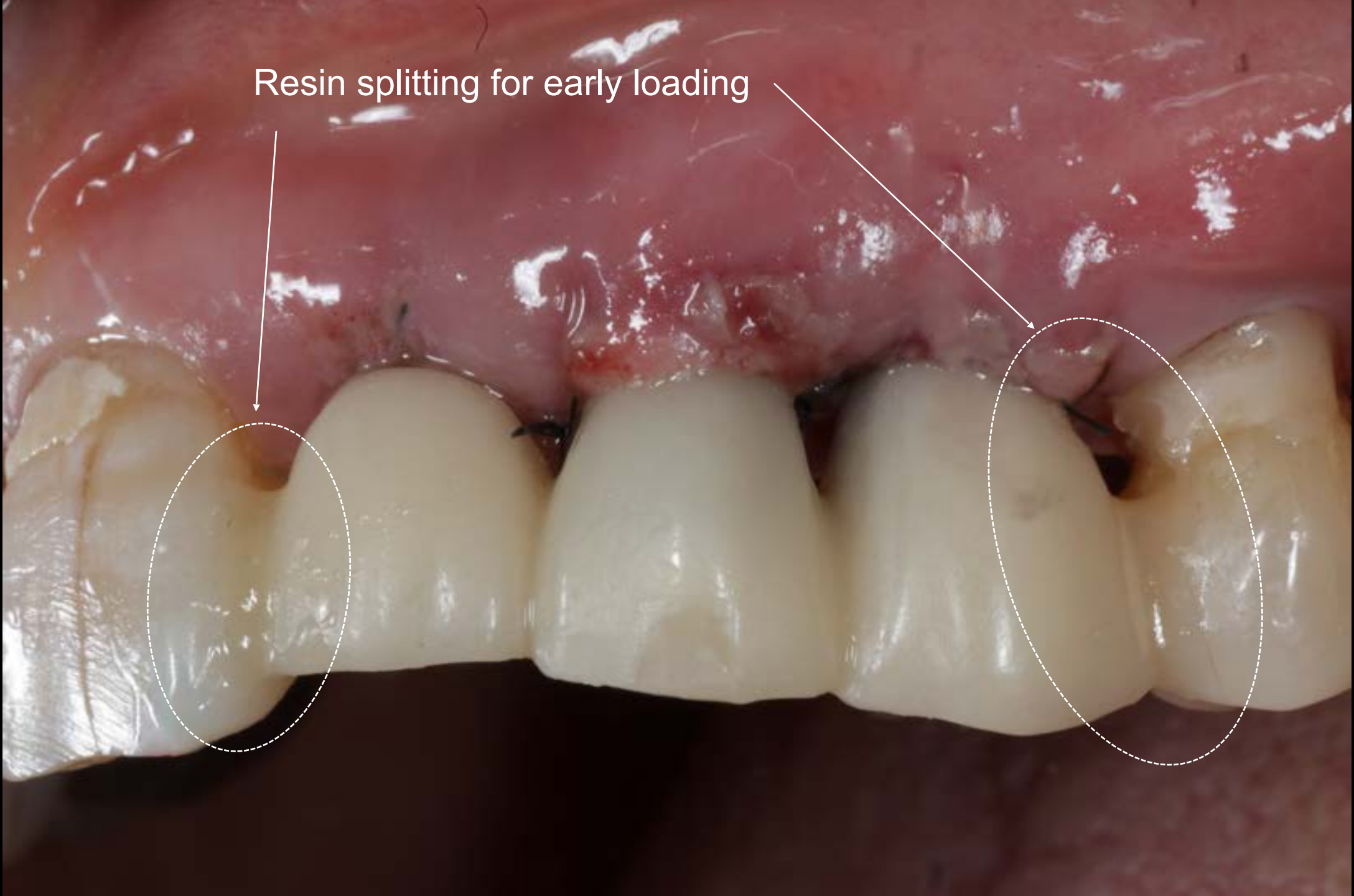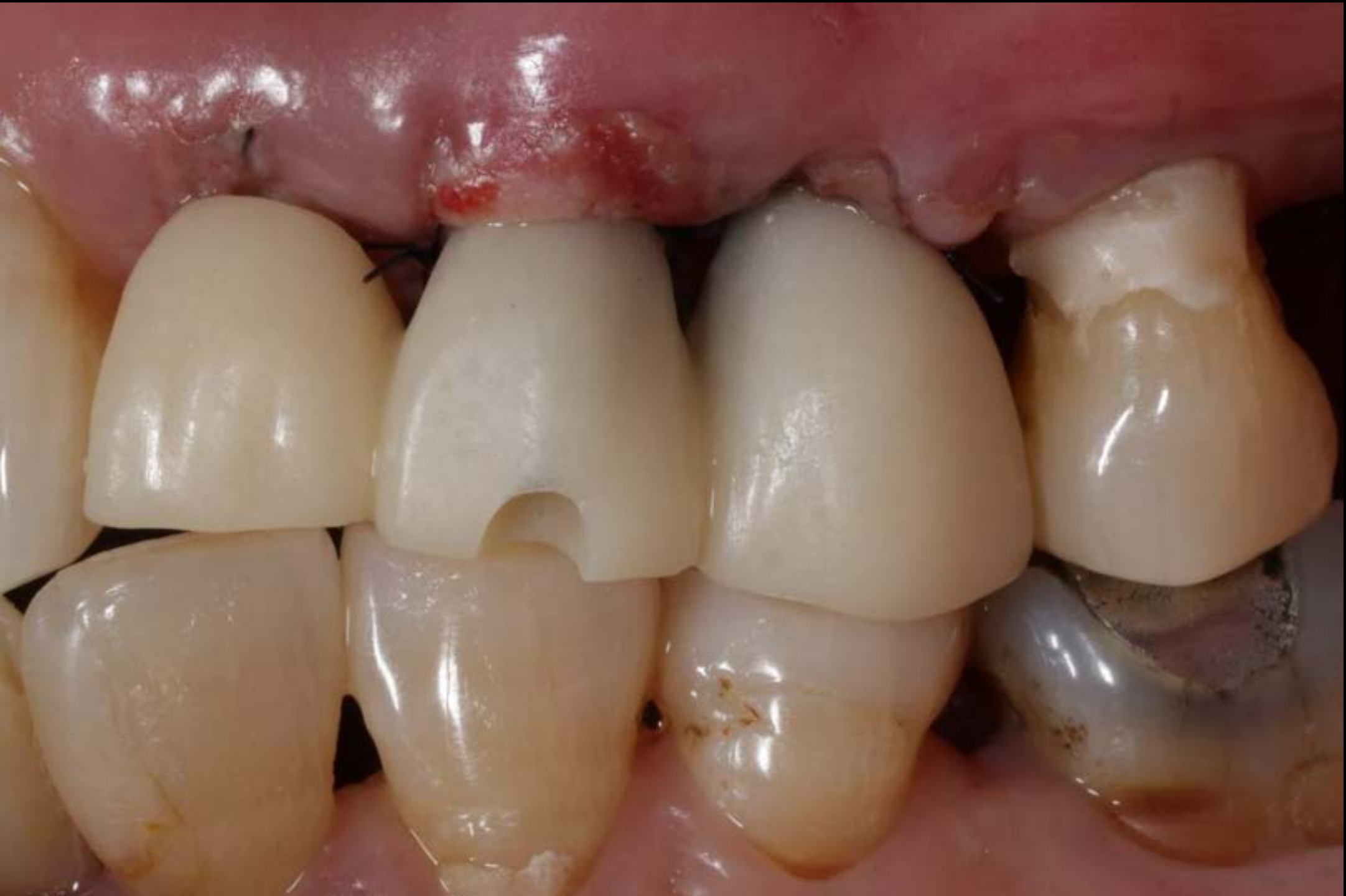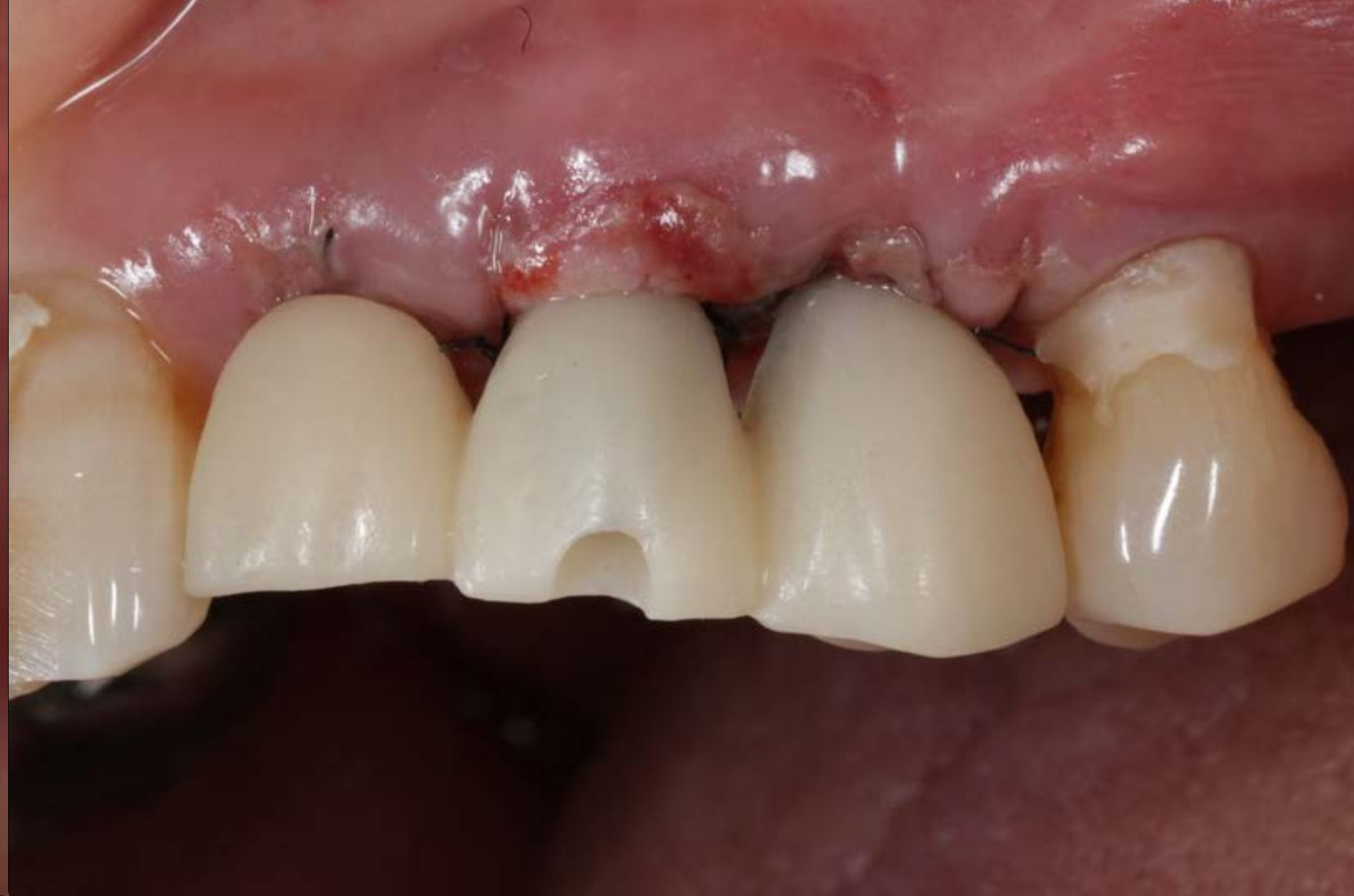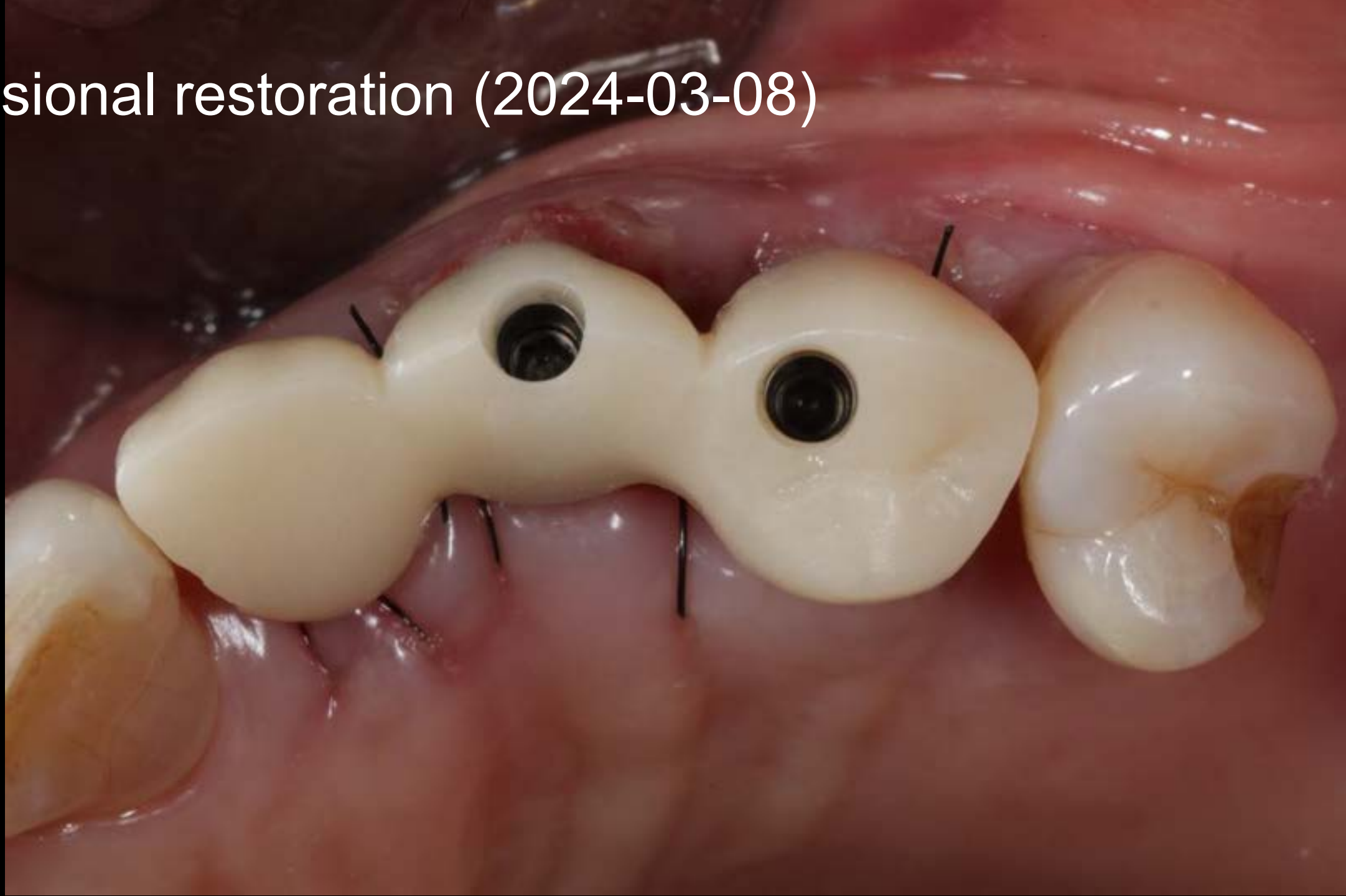Post-op (2024-03-06)



Resin splinting (2024-03-08)



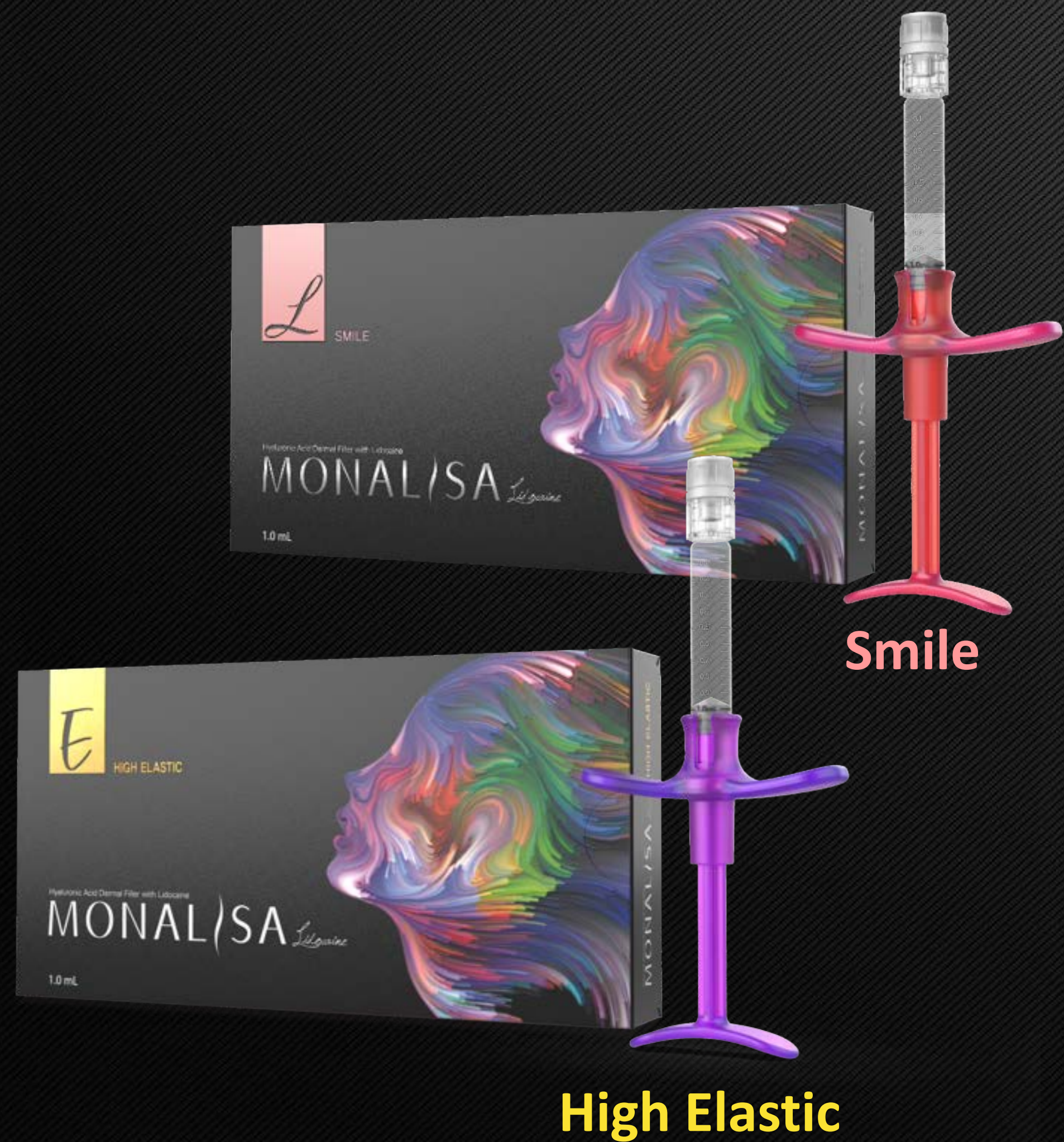Provisional restoration (2024-03-08)



MONALISA Lidocaine

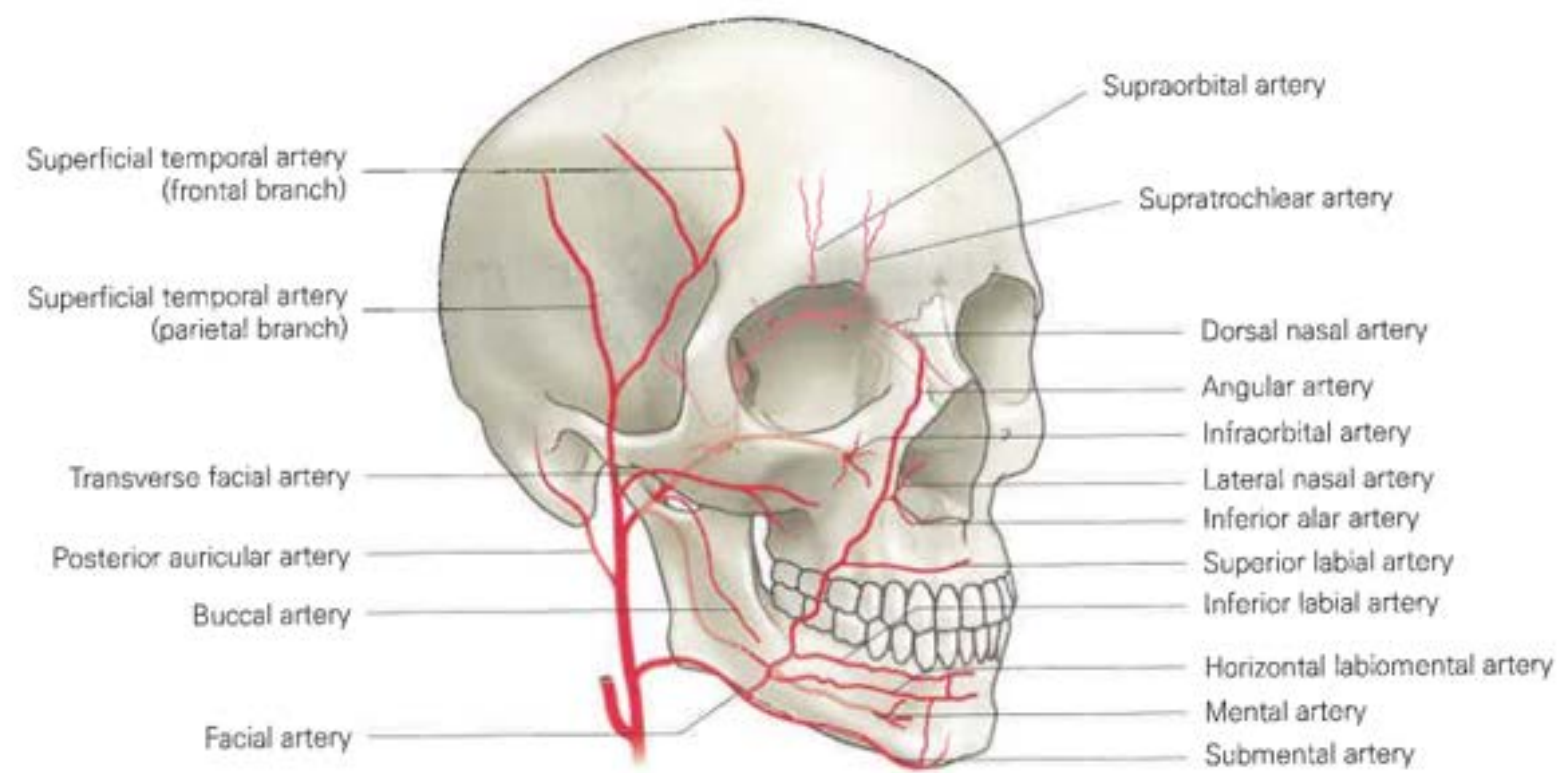
Hyaluronic Acid Dermal Filler with Lidocaine

MONALISA

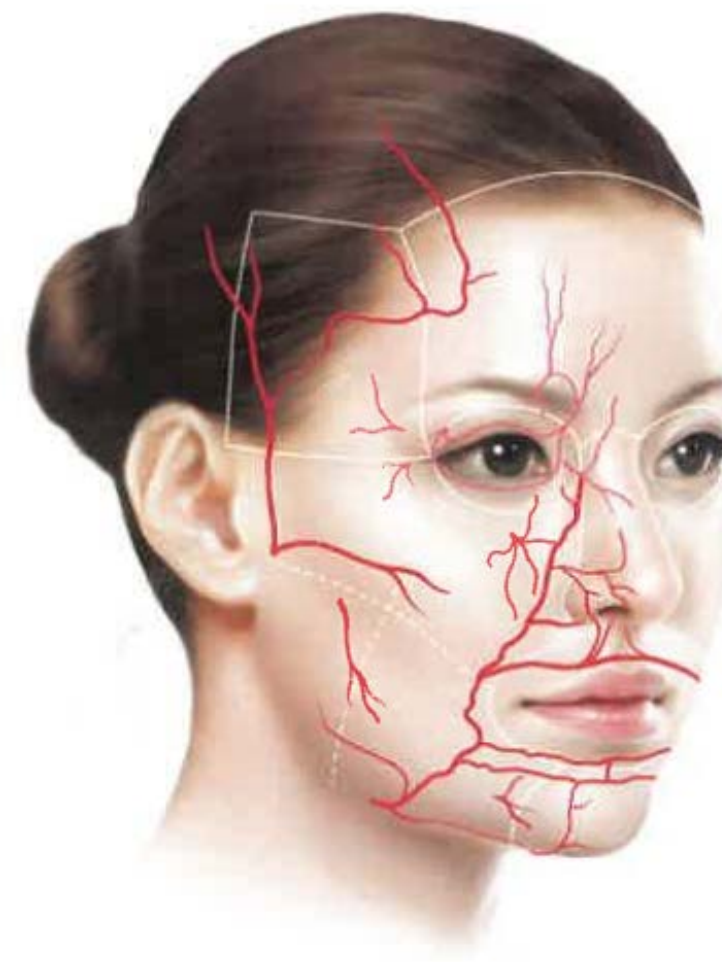


Product	SMILE		HIGH ELASTIC
Form	No impurities, transparent and colorless gel		
Components	Cross-linked hyaluronic acid, 0.3% Lidocaine		
HA Concentration	24 mg/mL		
Particle Size	400 μm		900 μm
Volume	1.0 mL		
Application	Superficial dermis / Middle layer of subcutis		Deep to very deep layer of subcutis
Needle size	27 GTW*		25 GTW*
Storage Temperature	2 ~ 25 °C		

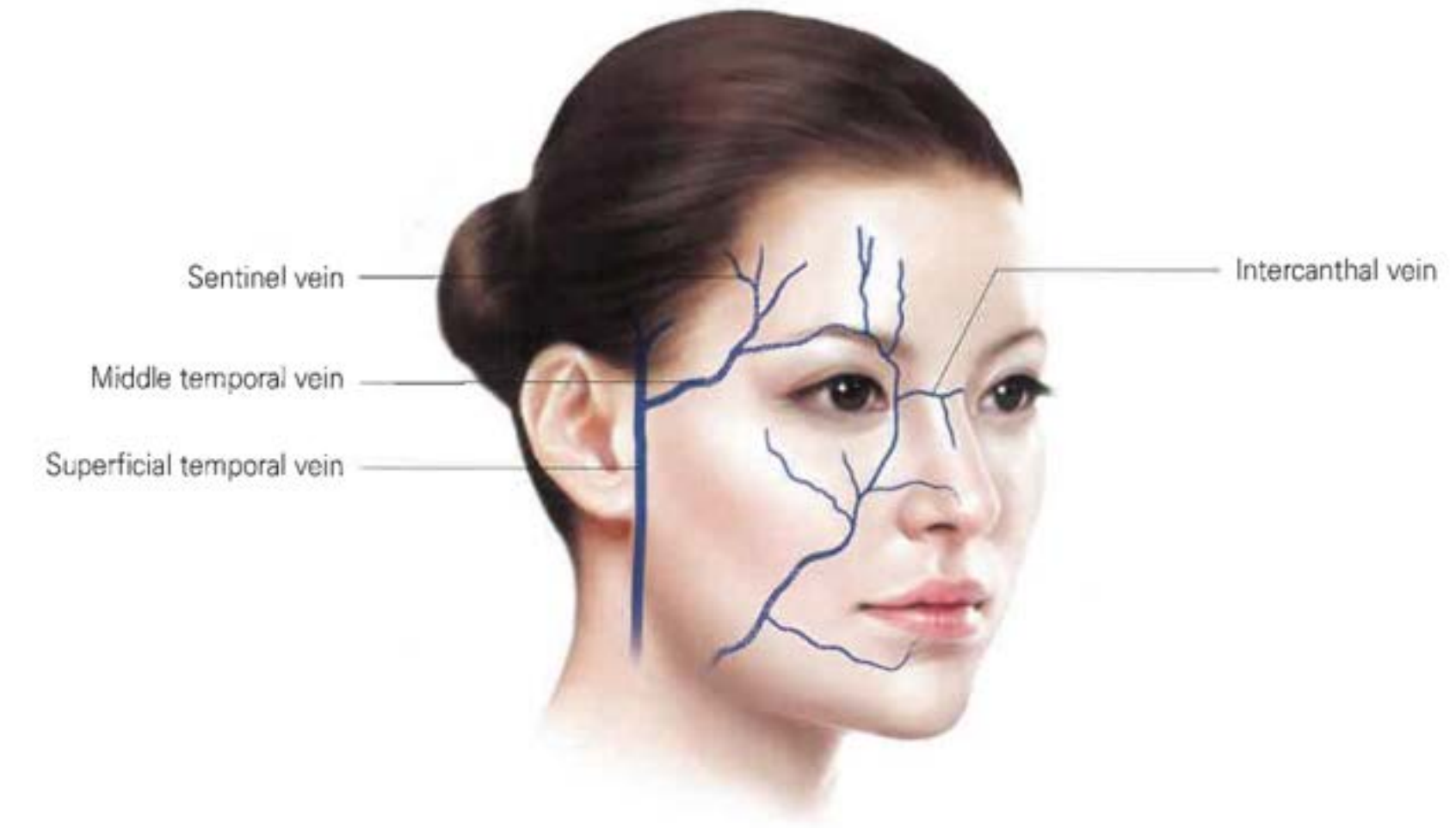
* TW : Thin wall



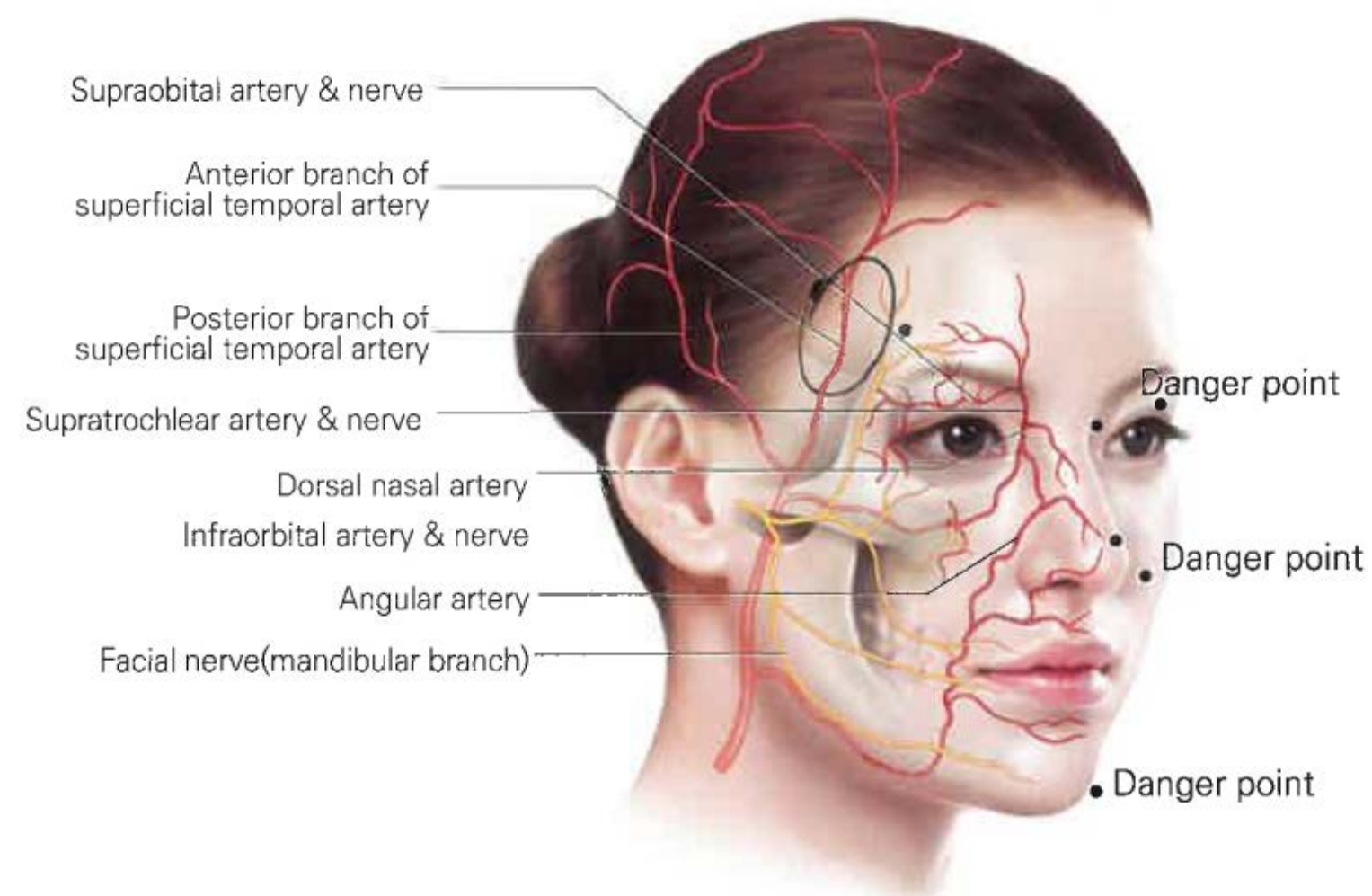
▲ Arterial branches of face



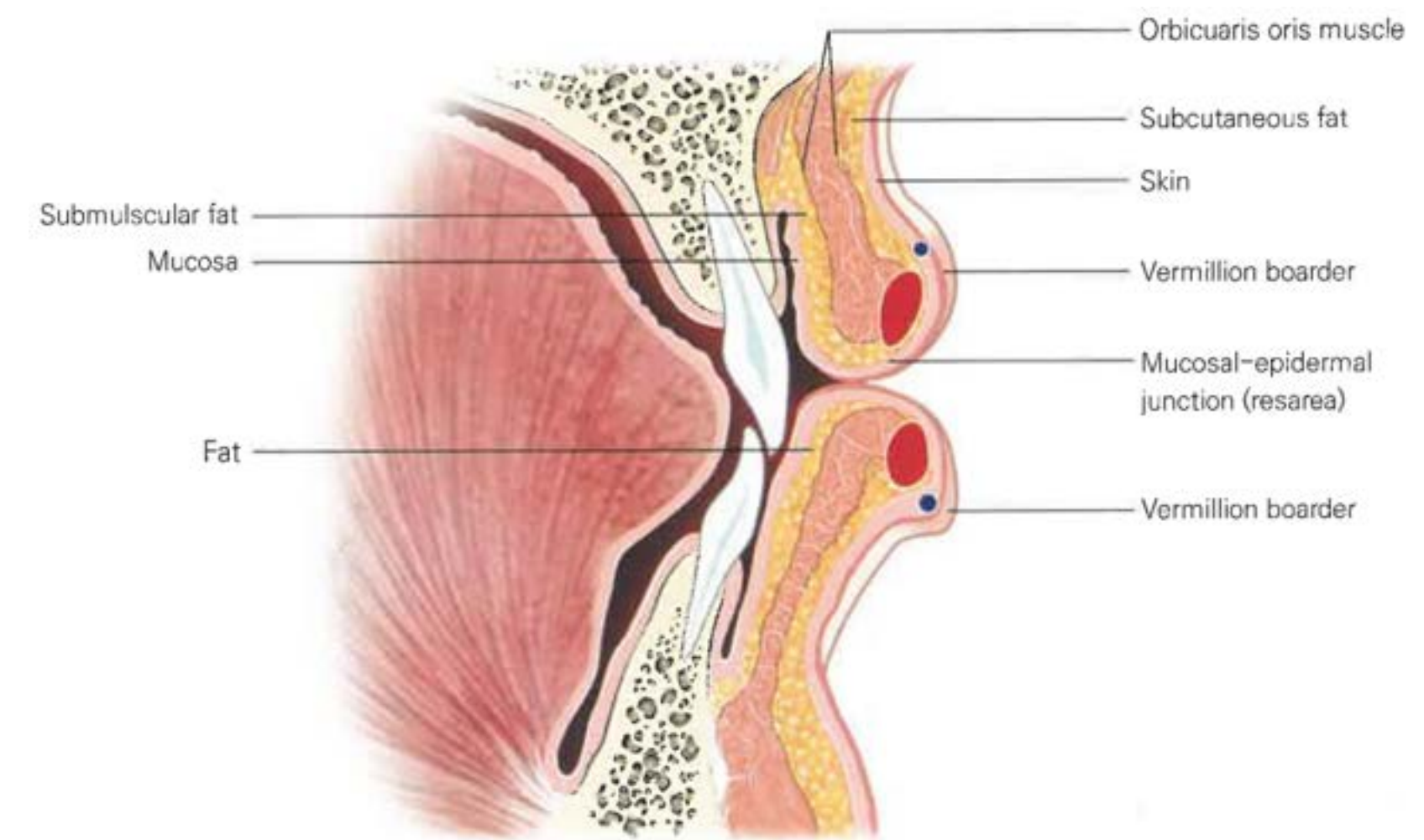
▲ Arteries supplying facial regions



▲ Veins of face



▲ The blood supply of lateral forehead area



▲ Sagittal section of the lip

Safe filler

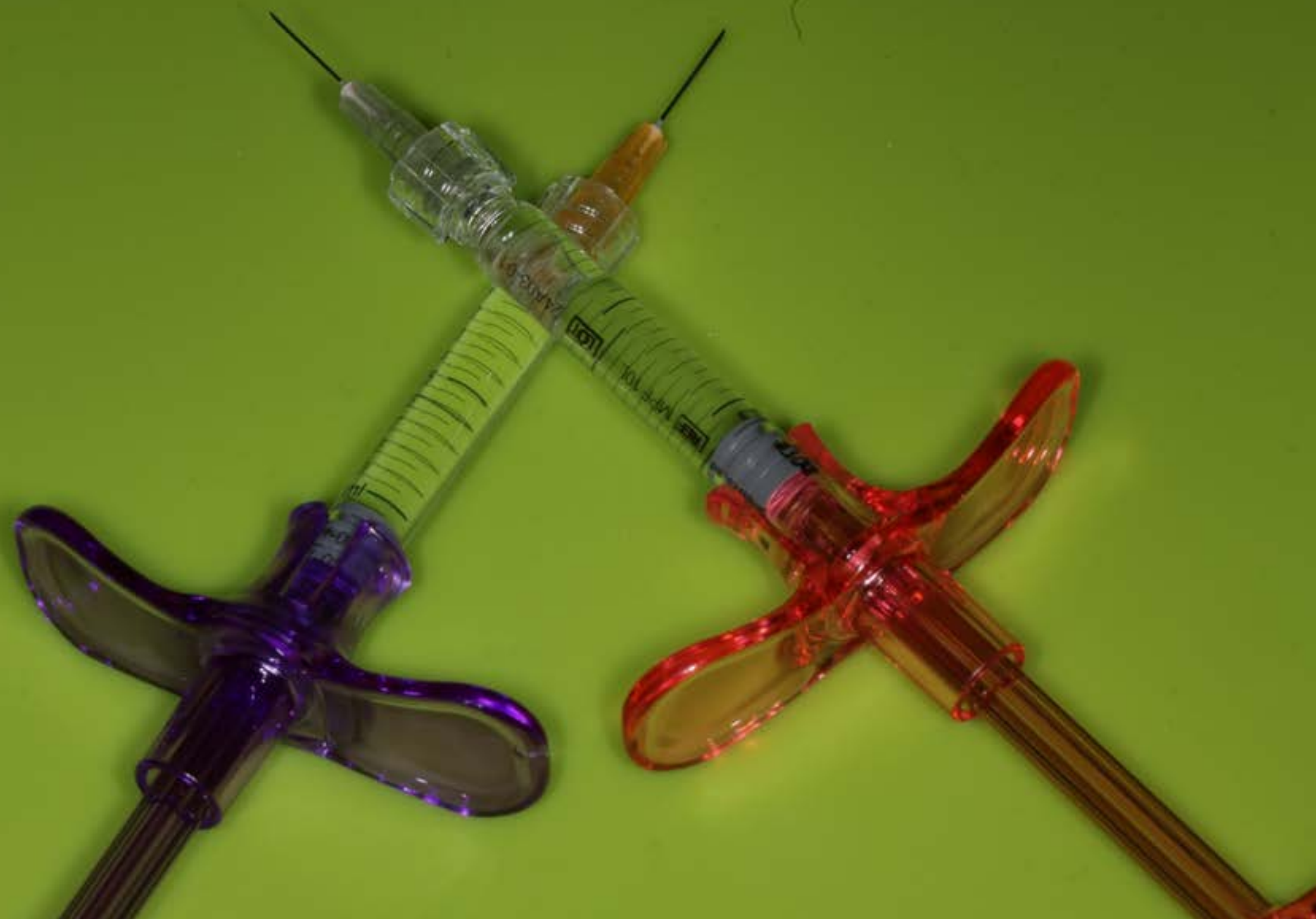Natural image filler injection

Mutilayer

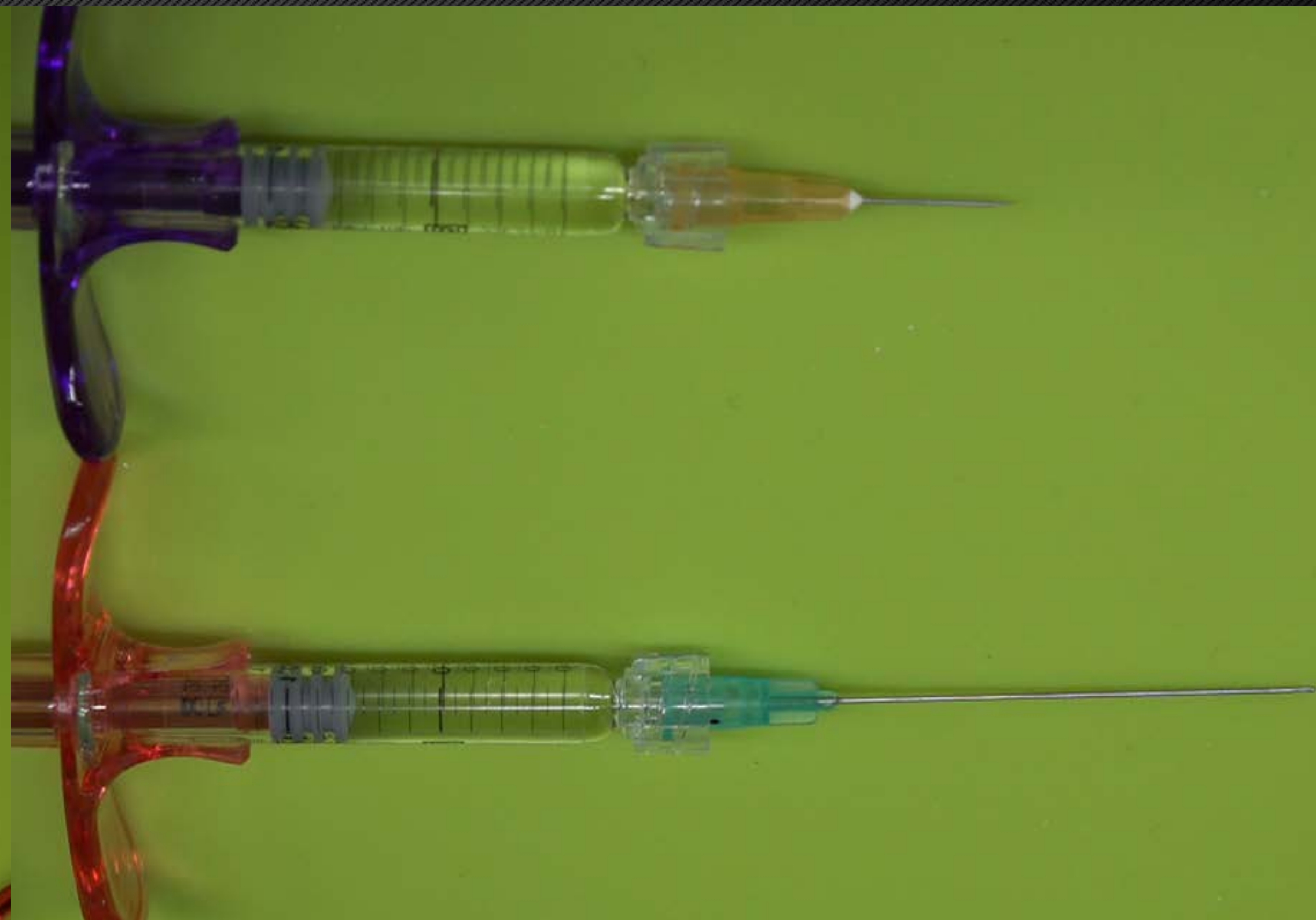- bone contact
- just below the dermis

Hyaluronic Acid Dermal Filler with Lidocaine

MONALISA

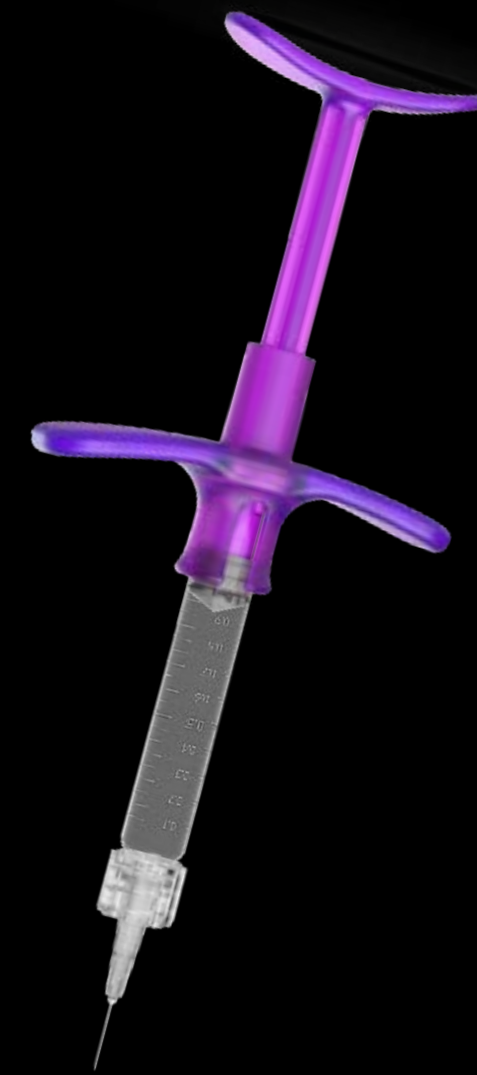
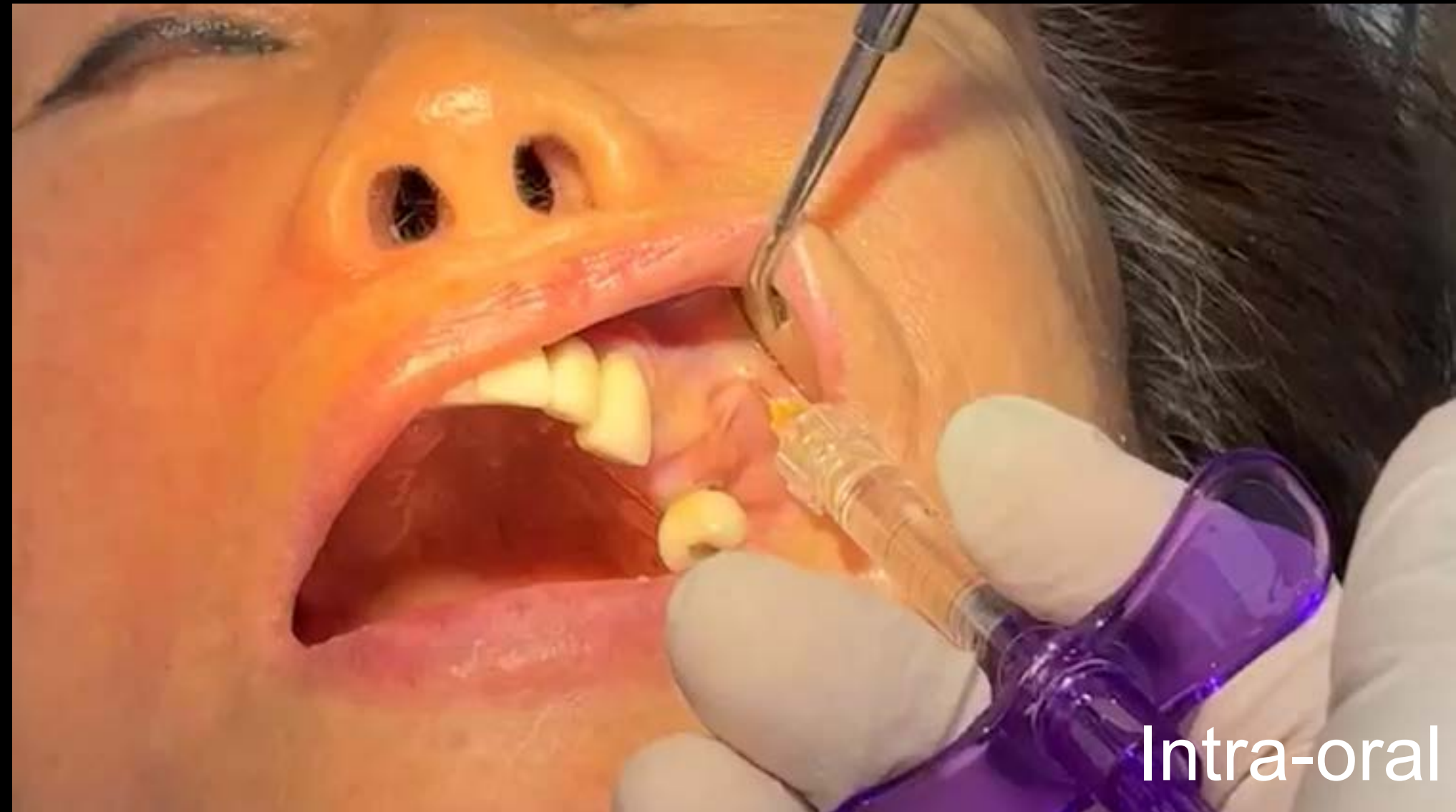
25G Needle



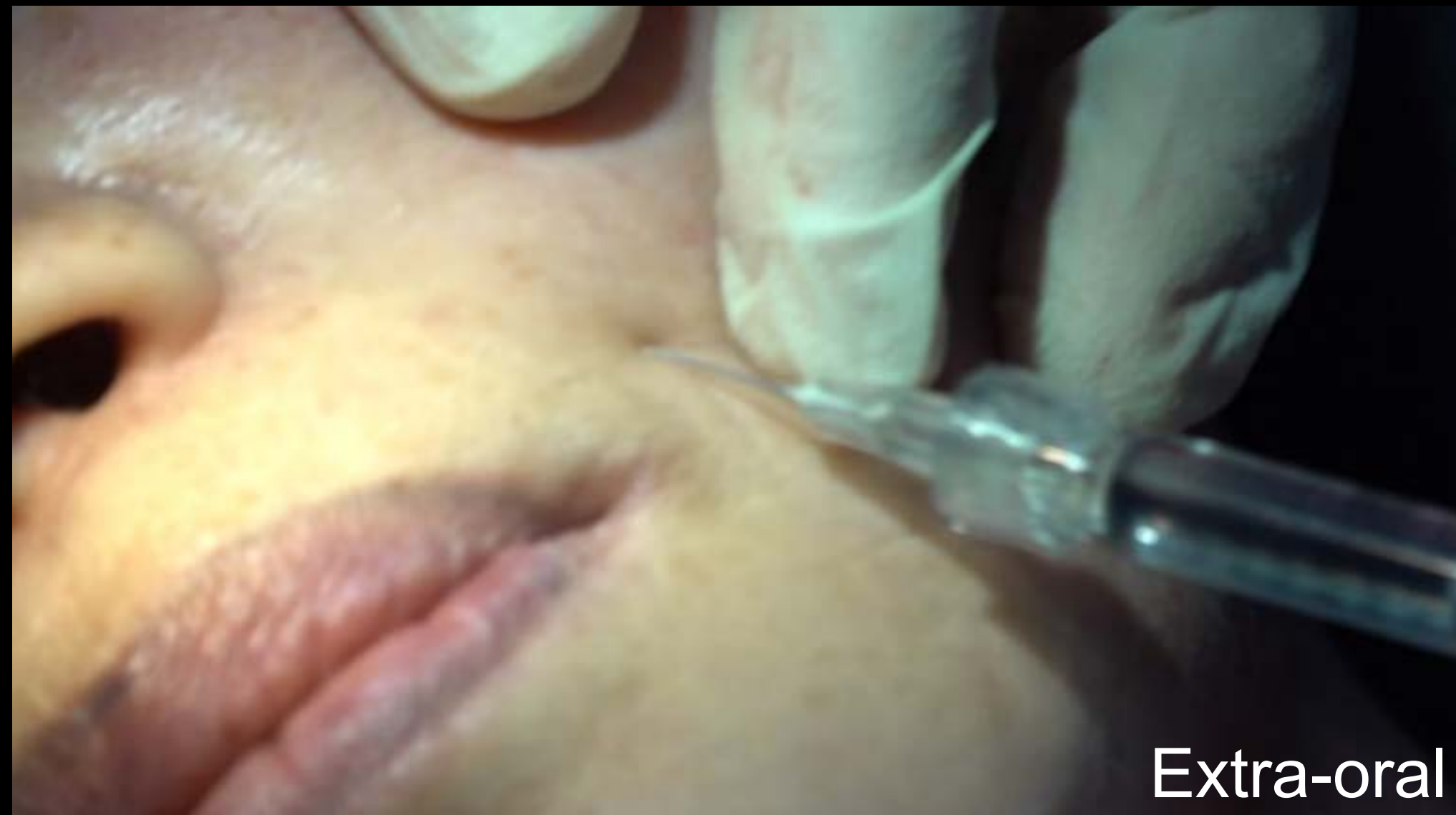25G Needle / 23G Cannula

Application site



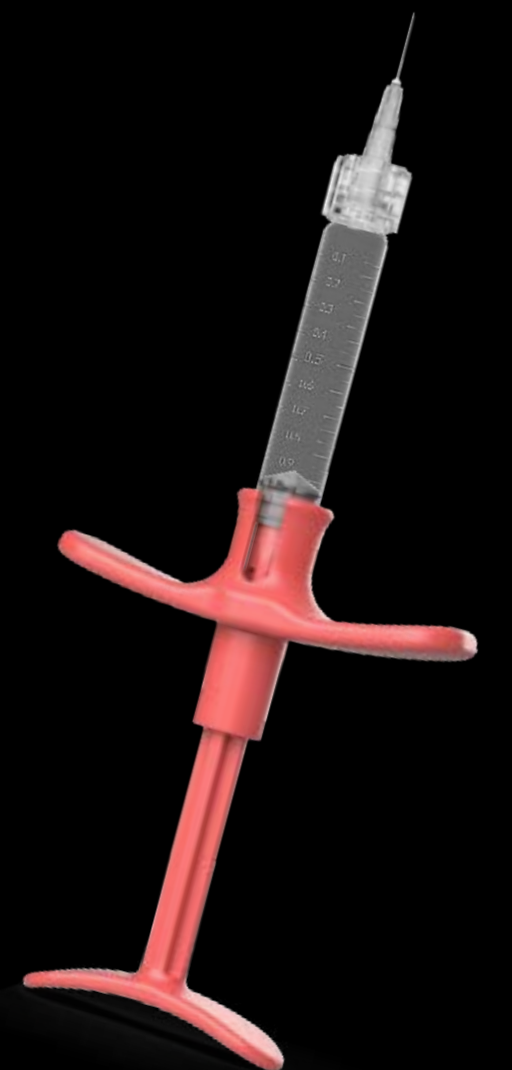Bone contact touch (Deep fatty layer)

- Long-lasting
- Deep wrinkle improvement



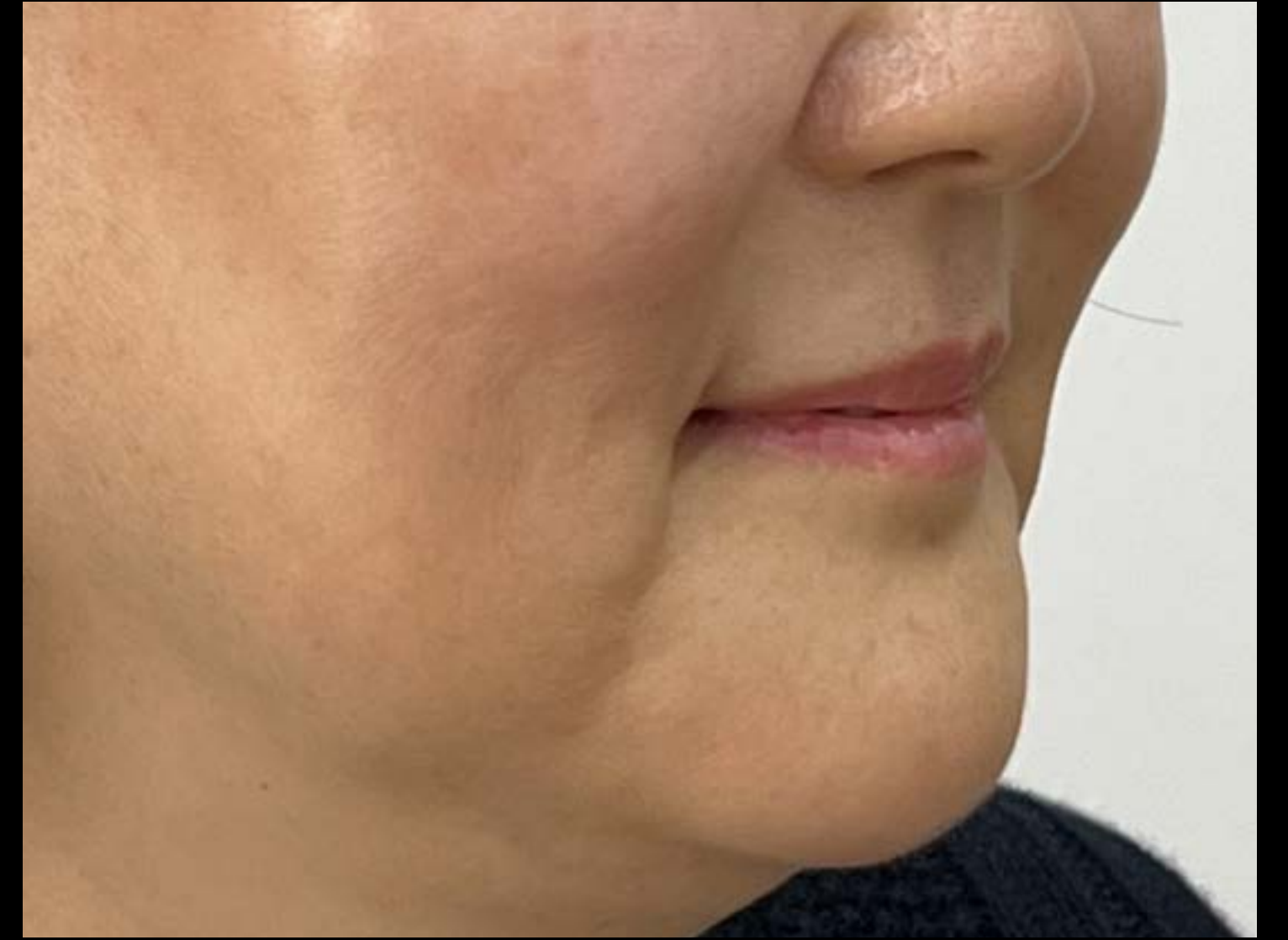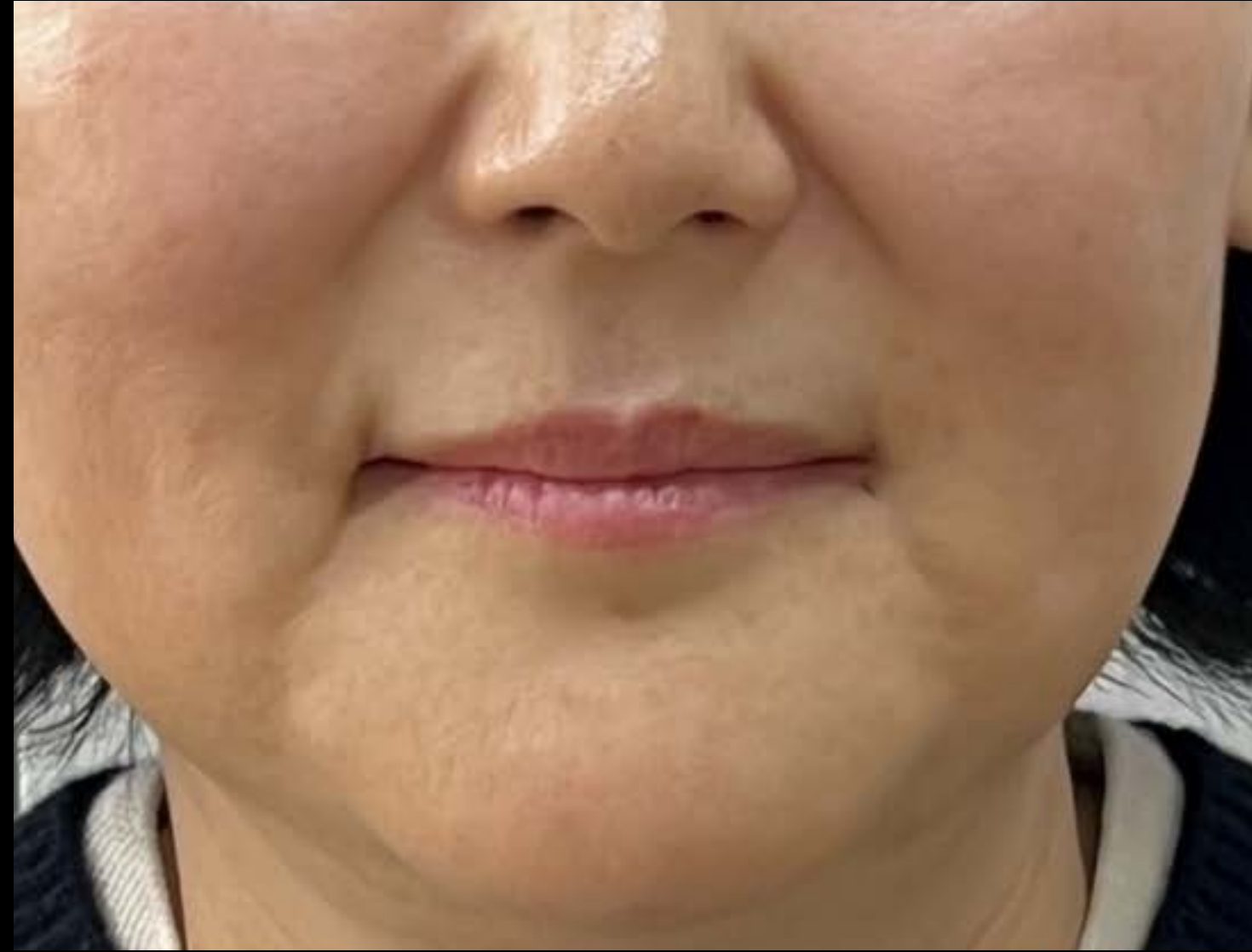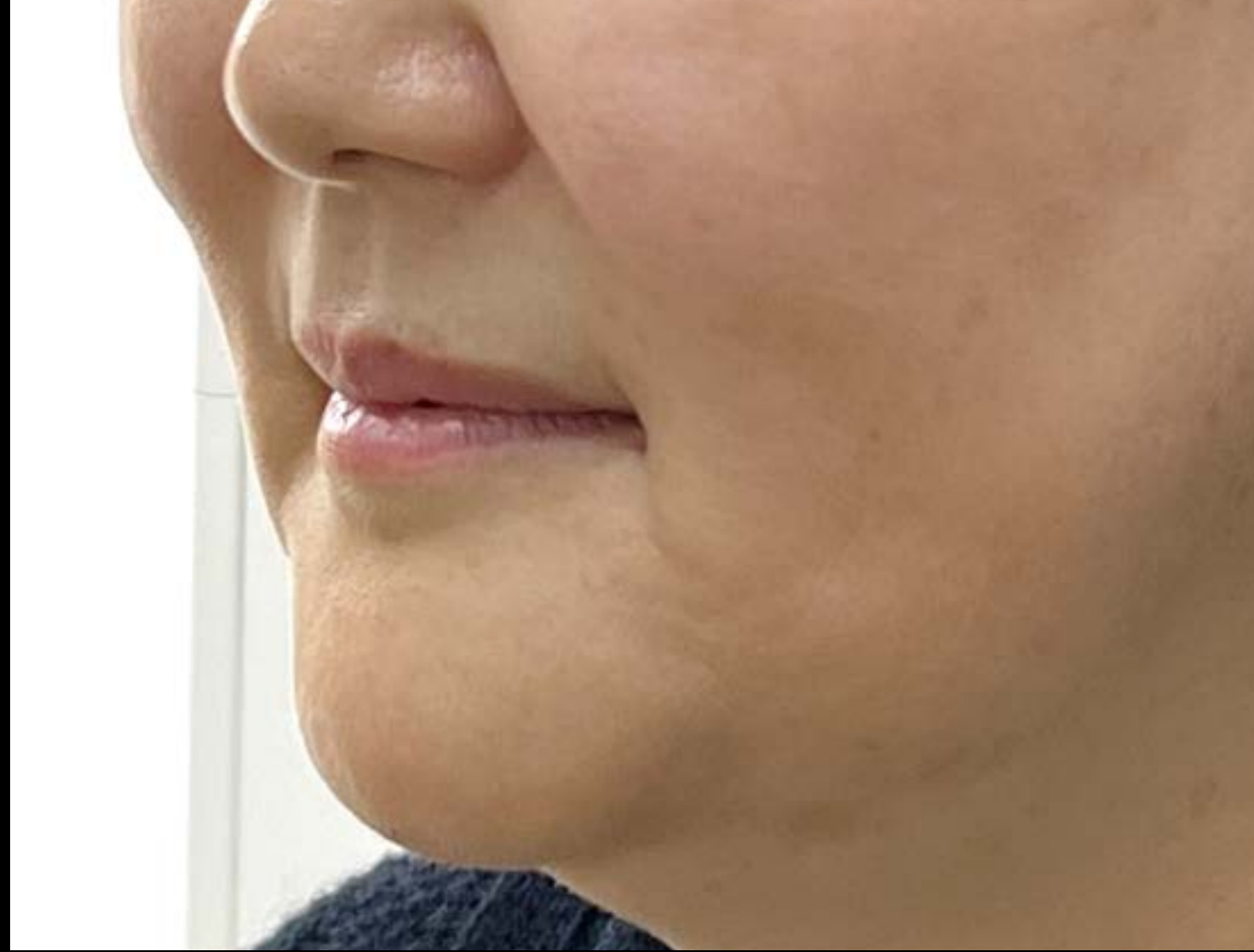Superficial skin (Superficial fatty layer)

- maintain a natural and smooth appearance
- low invasiveness

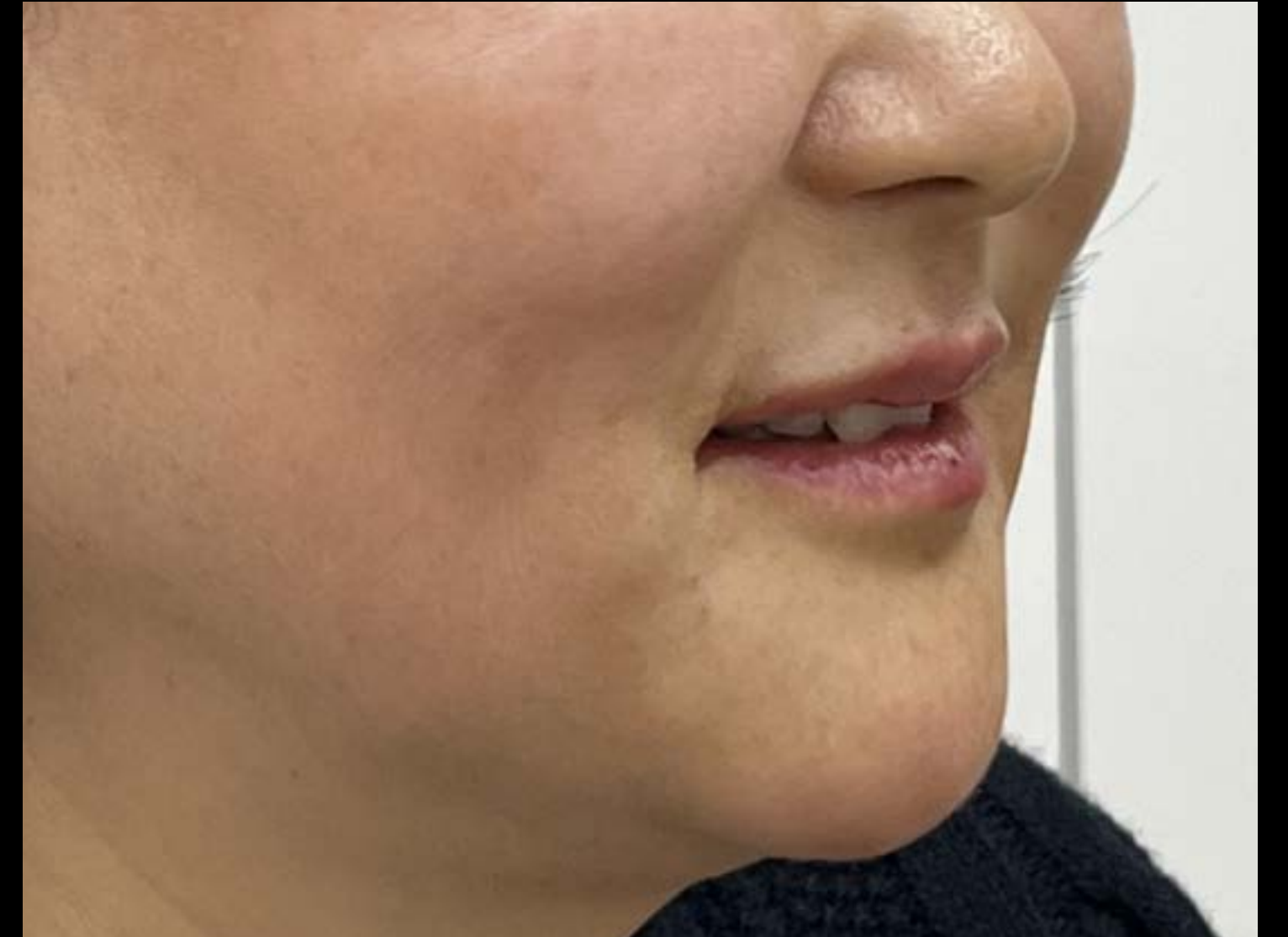
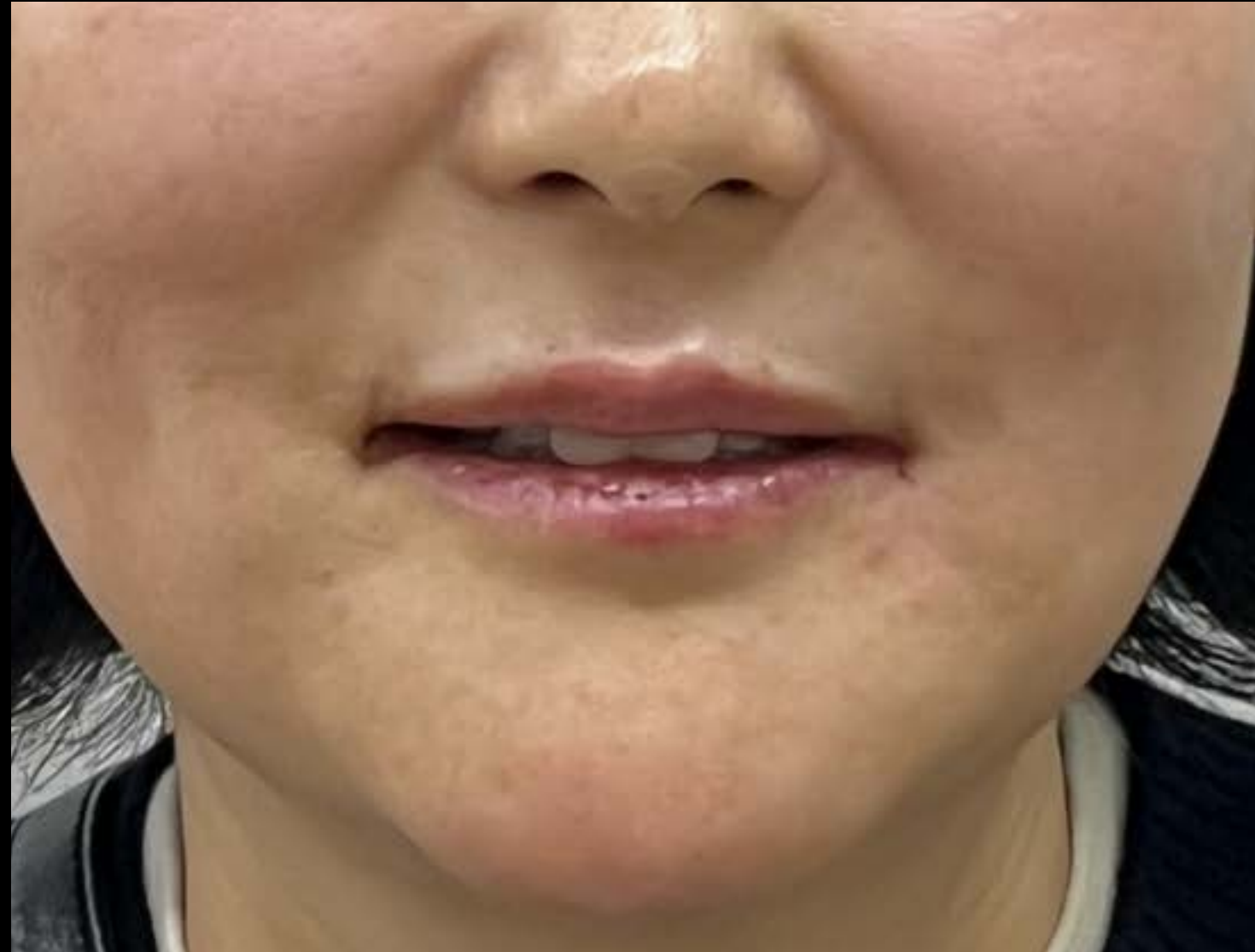
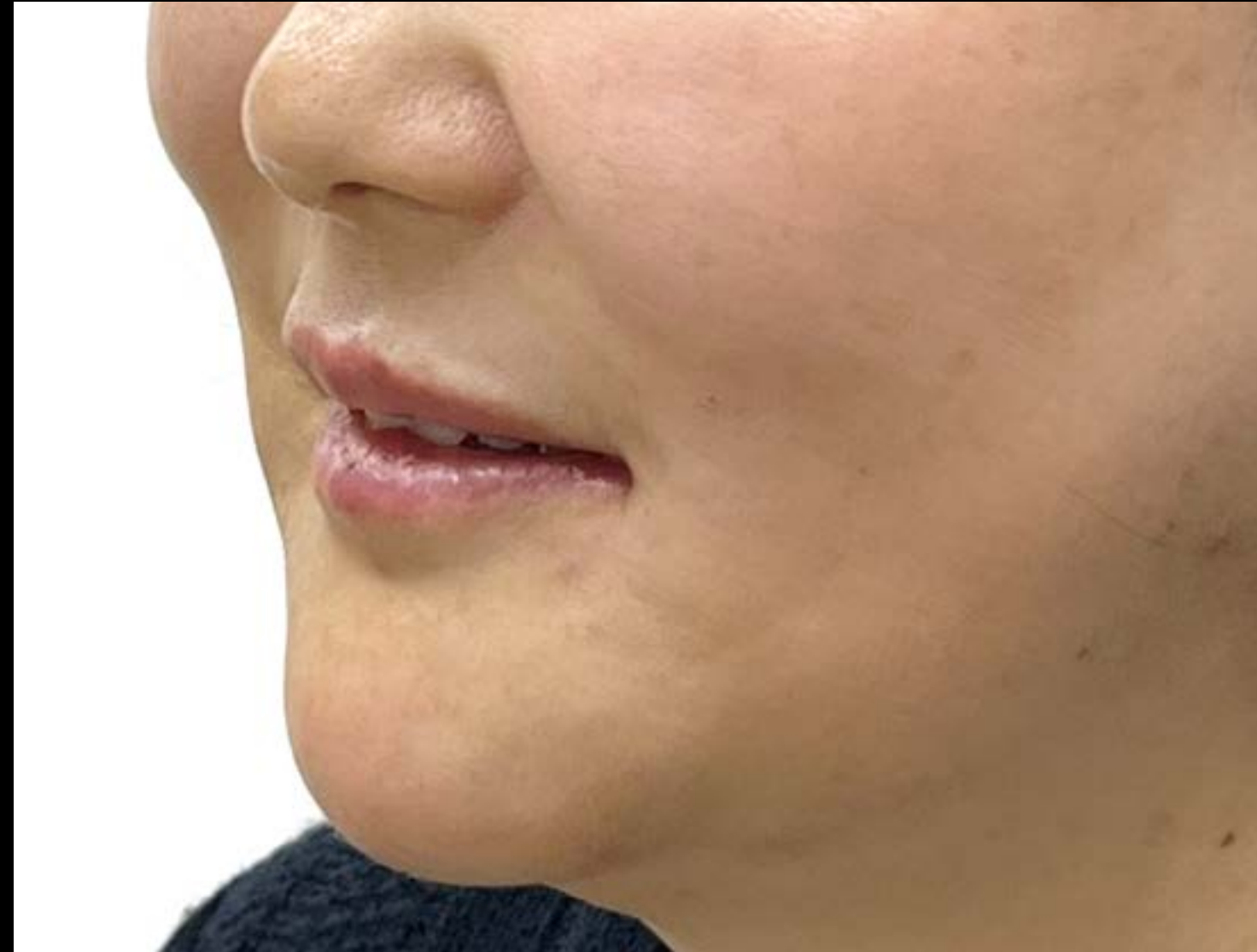Clinical case : Nasolabial folds & Marionette Line & Lip

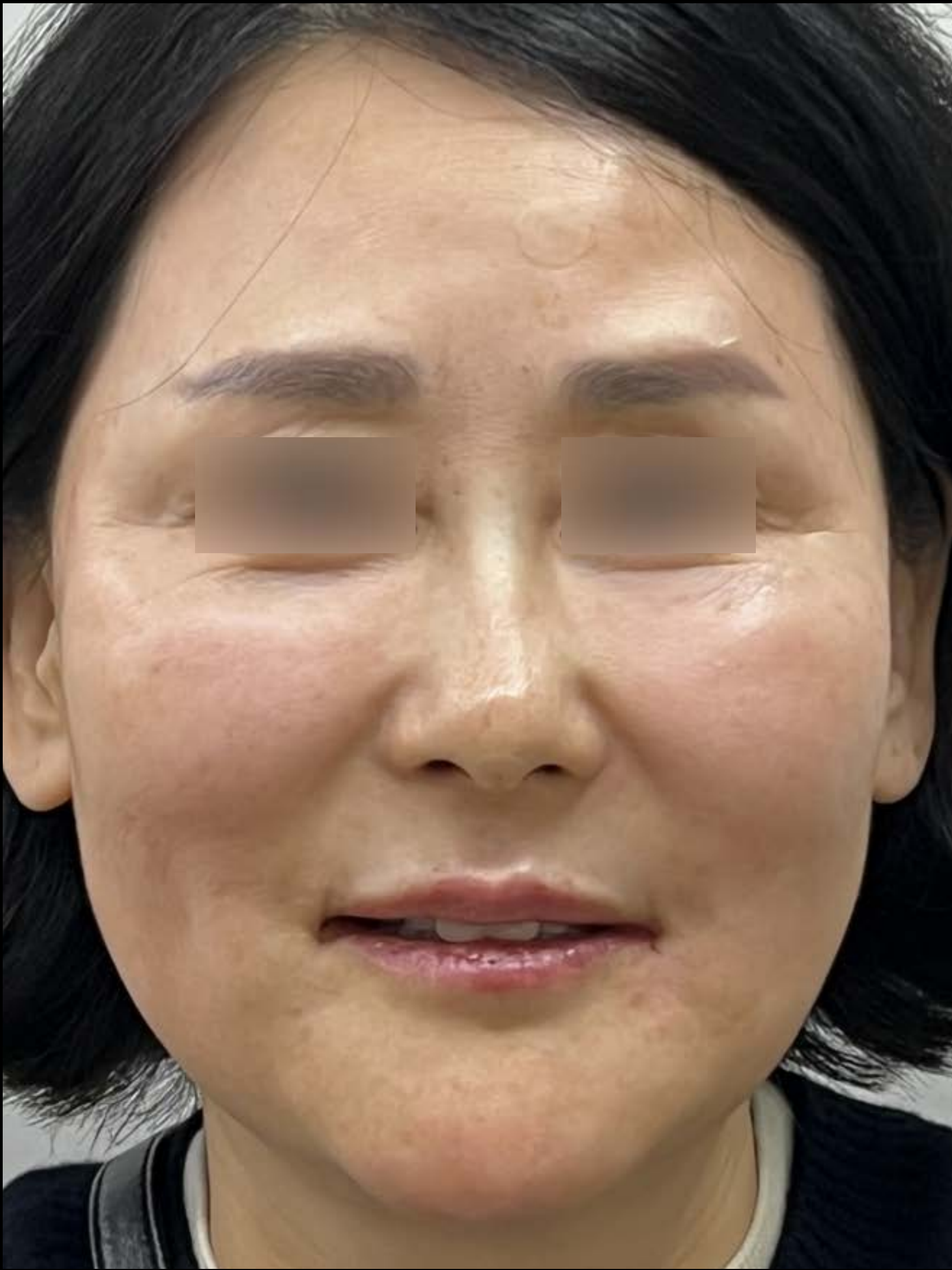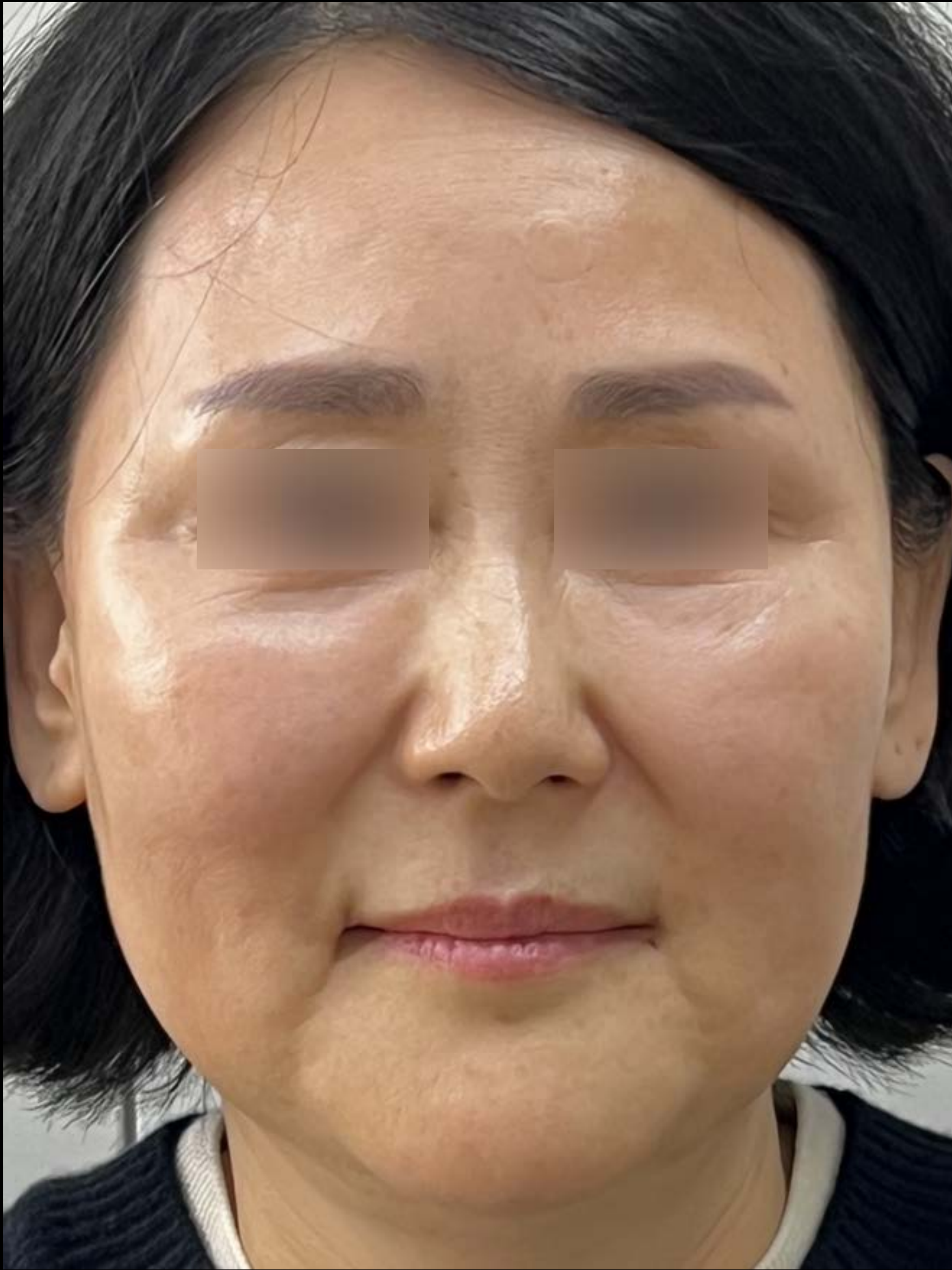Before



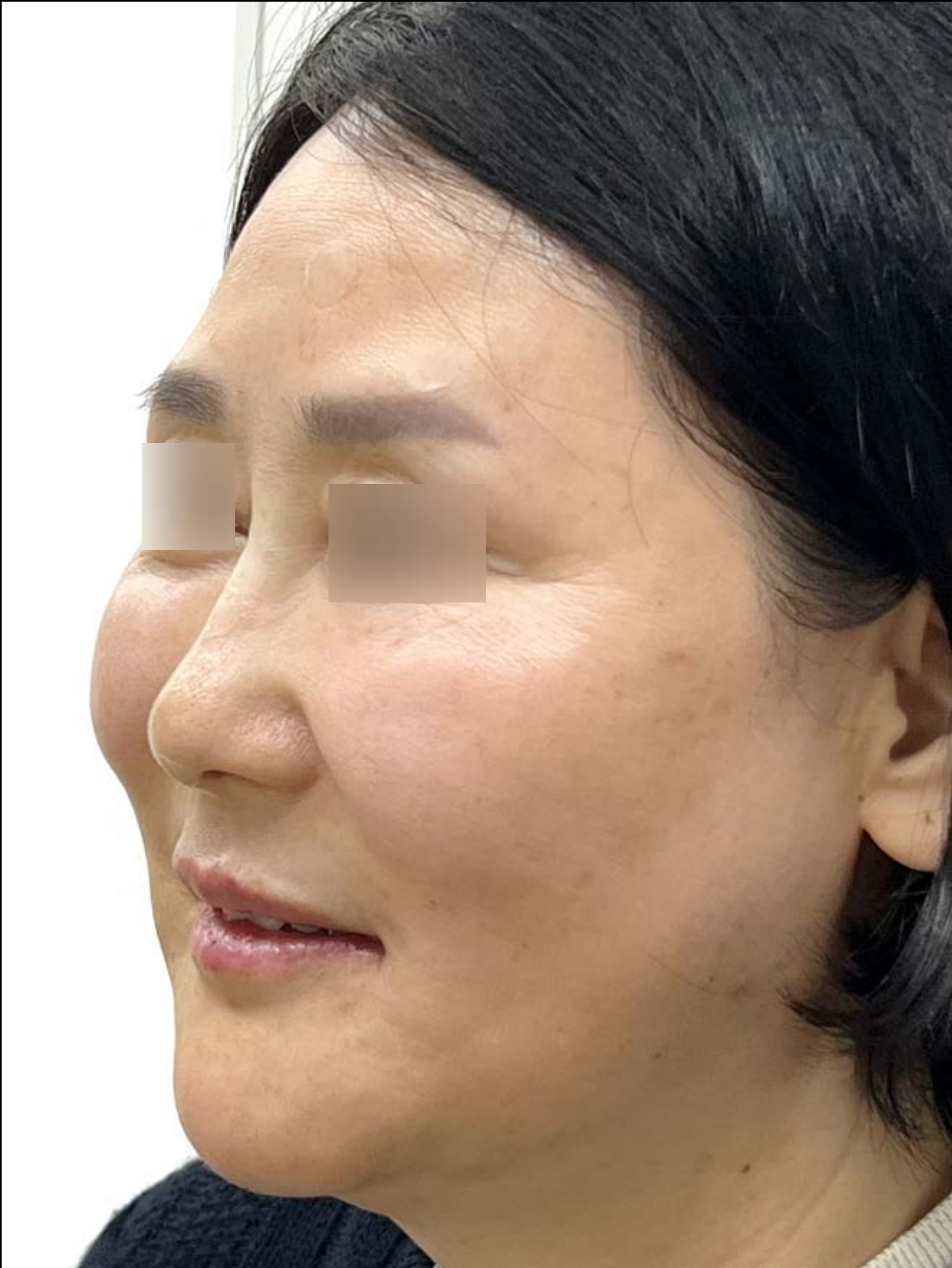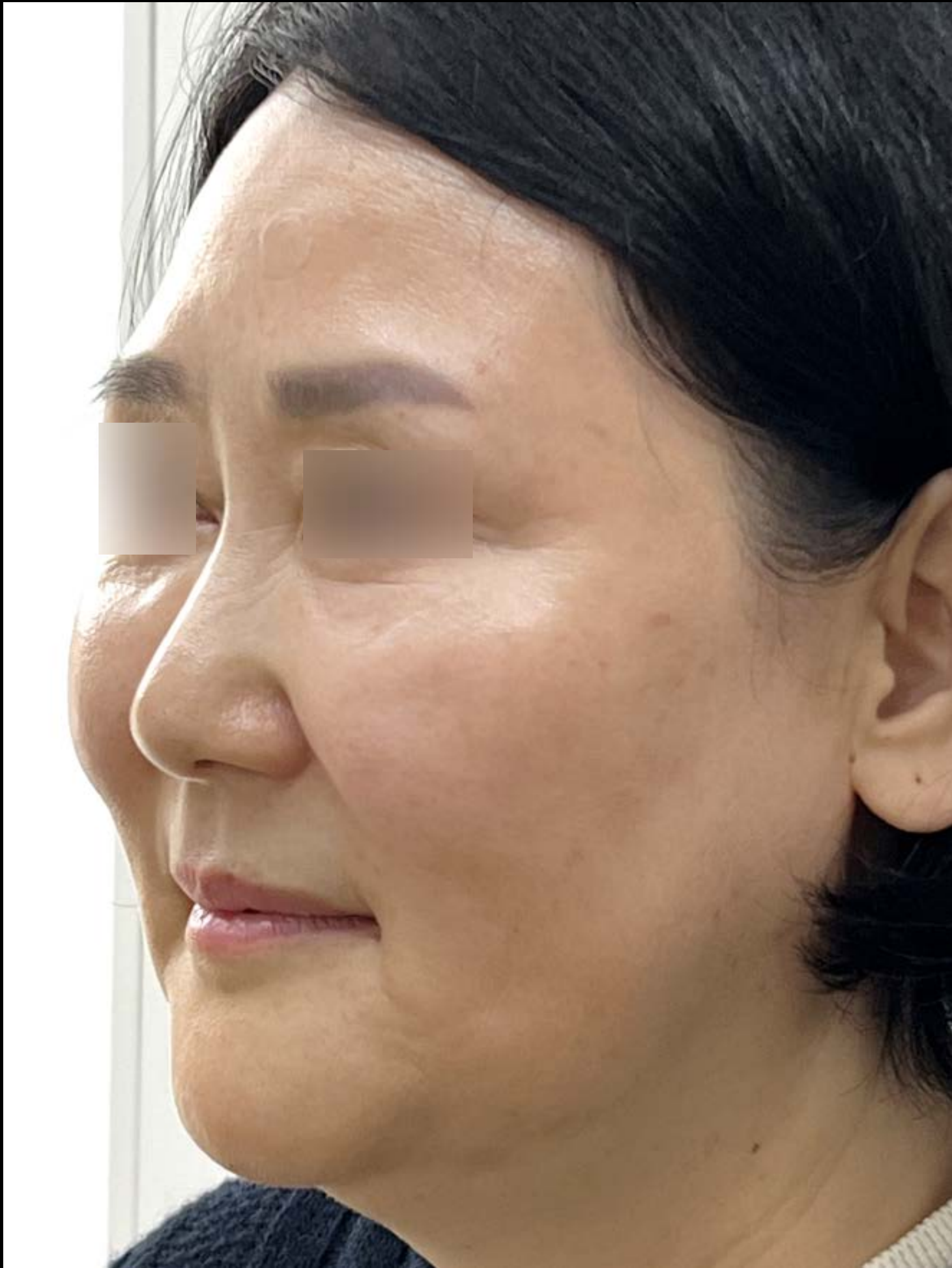After



Before & After



Before & After



Appreciate
For attending doctors
and staffs for helping