

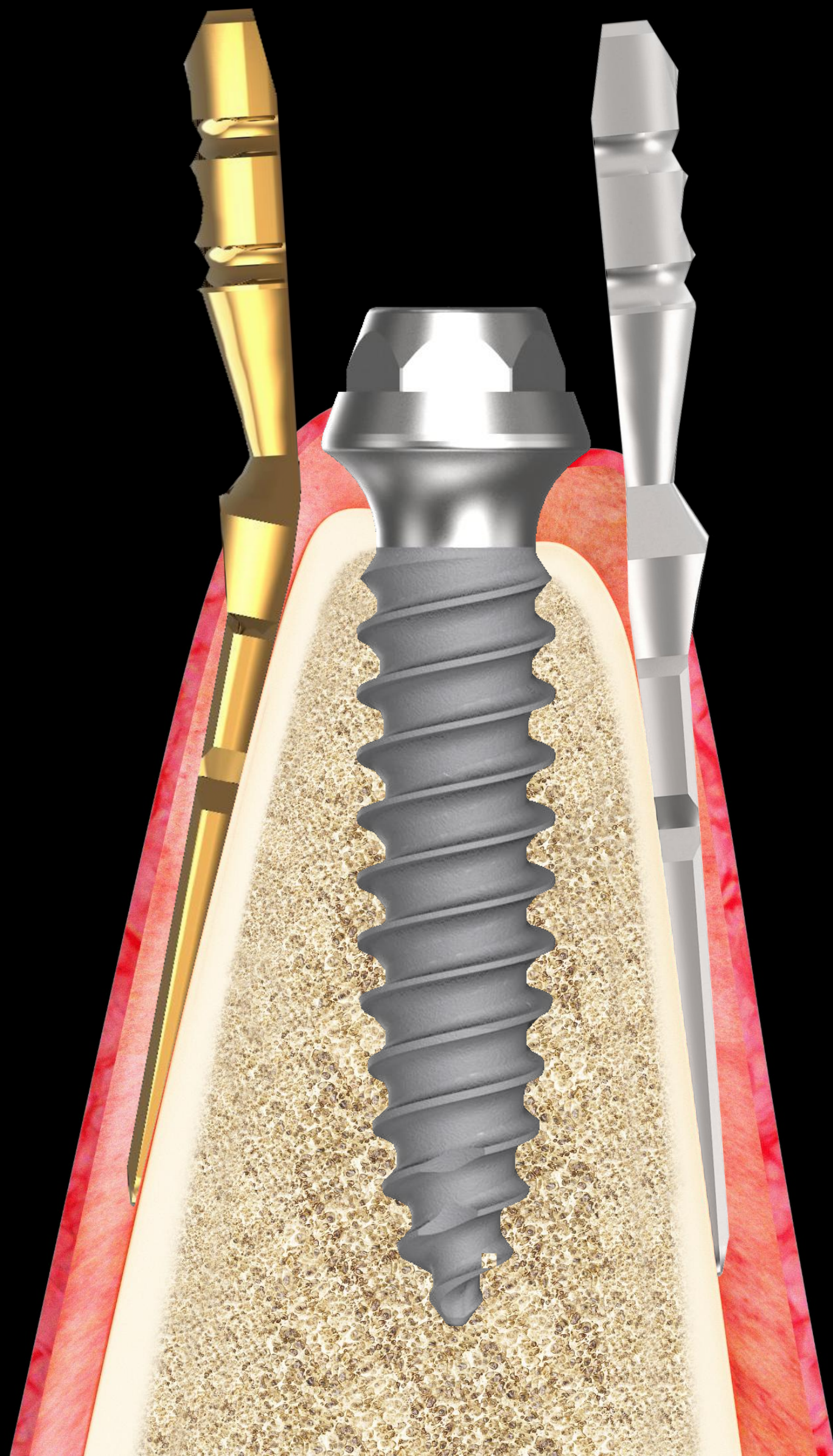
Implant in a next? - **minimalism**

Optimal results with the least amount of

Surgical intervention - simplicity

Material use - efficiency

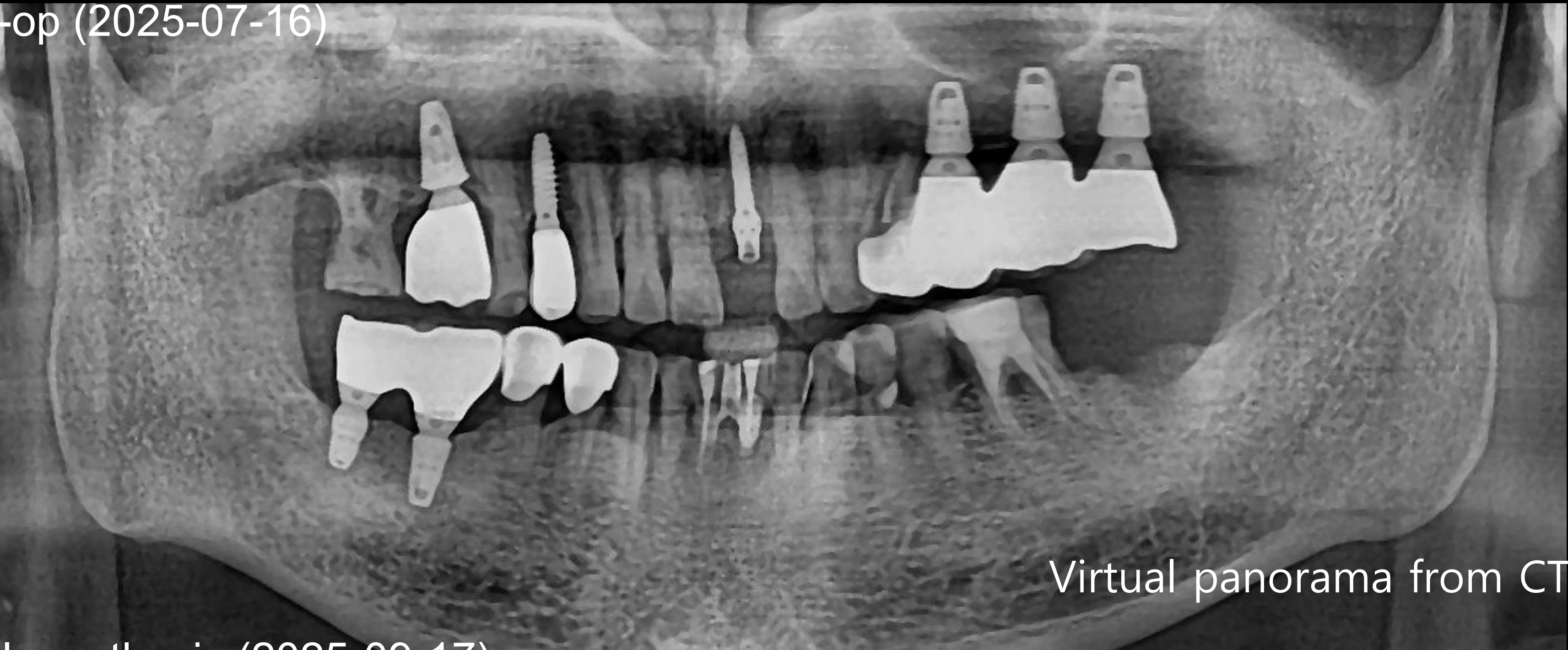Patient comfort



Dr Sungmin Chung periodontist Ph.D

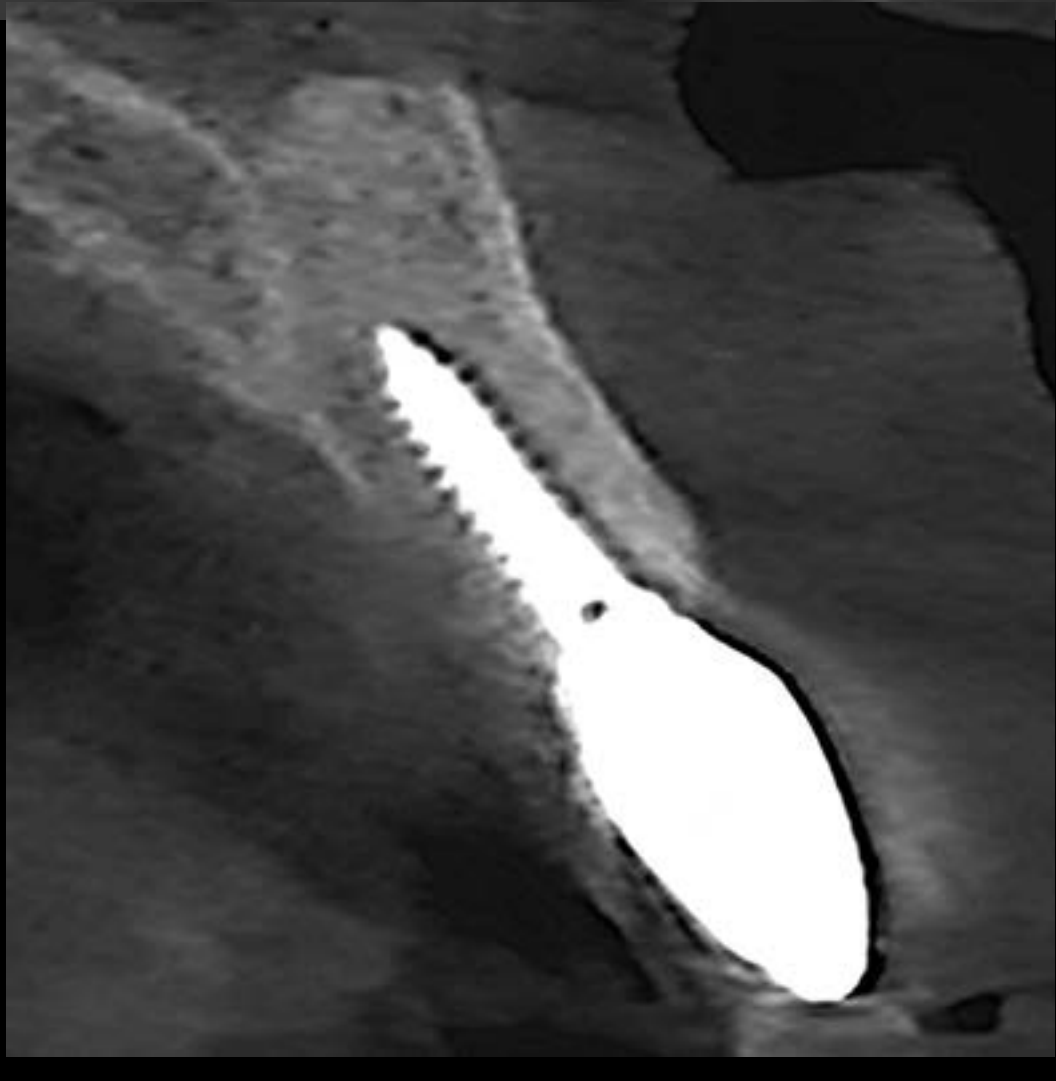
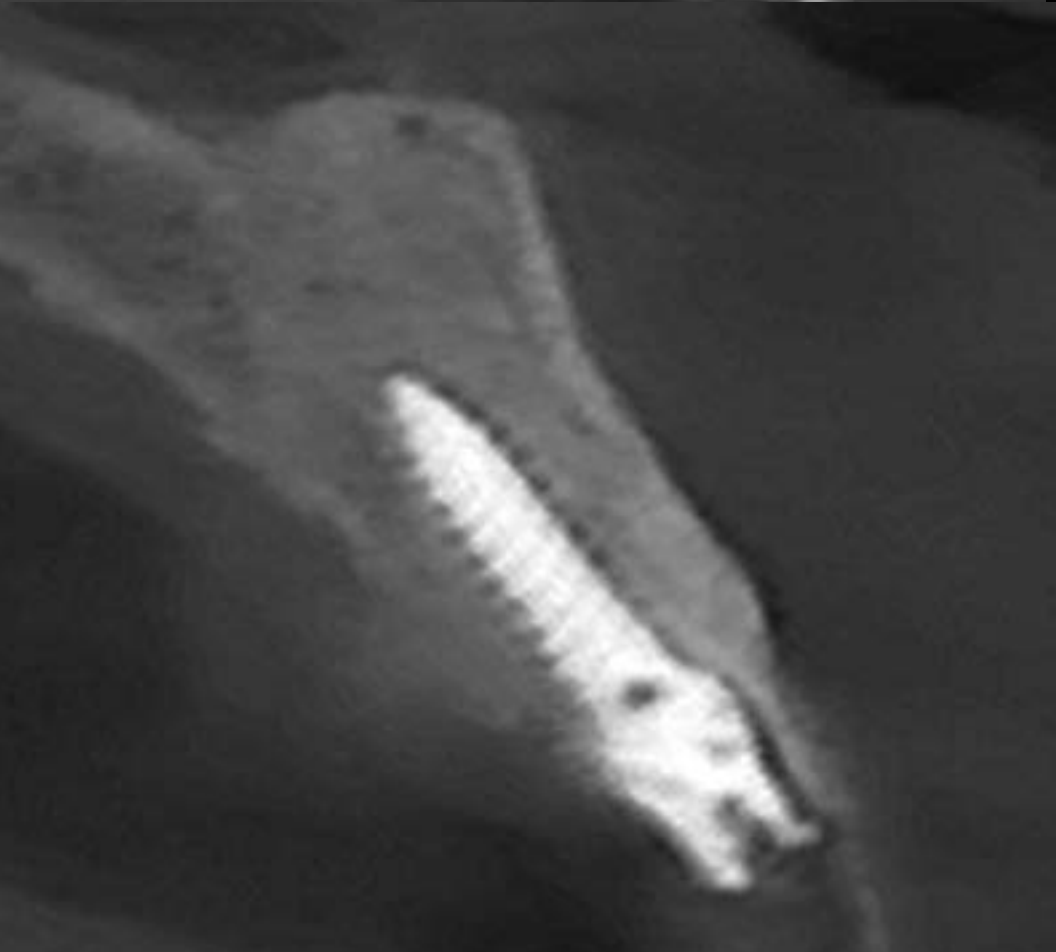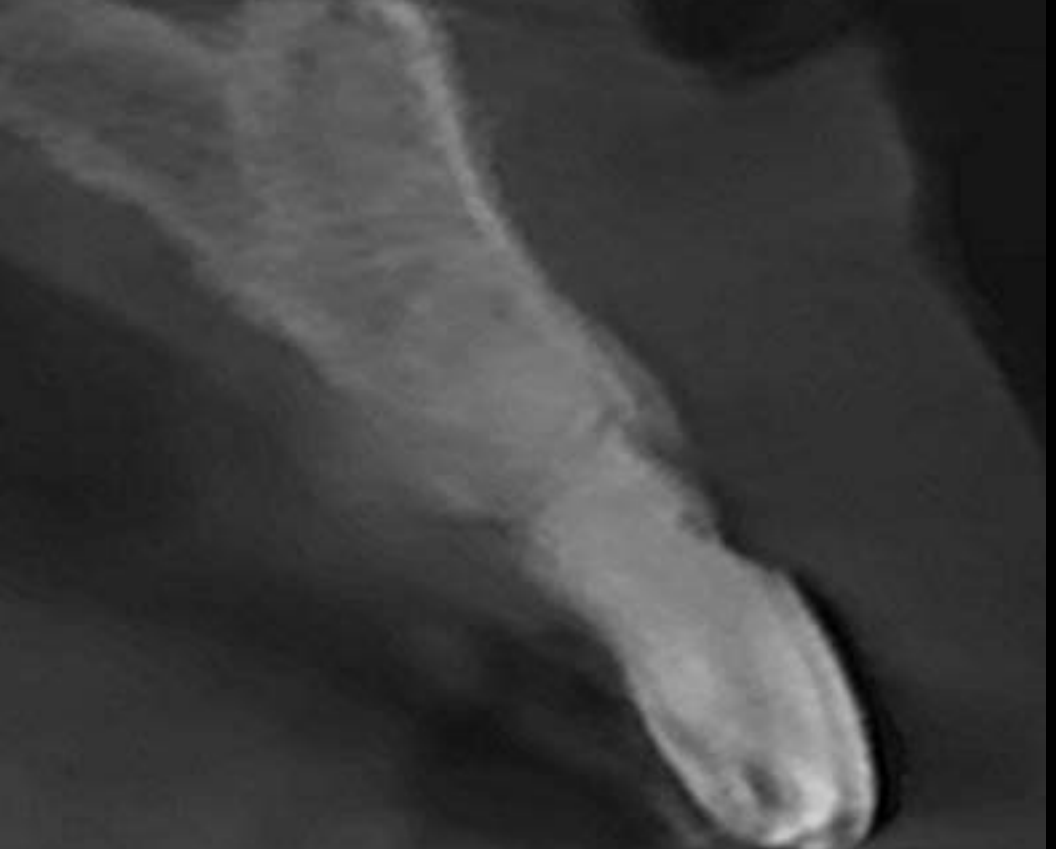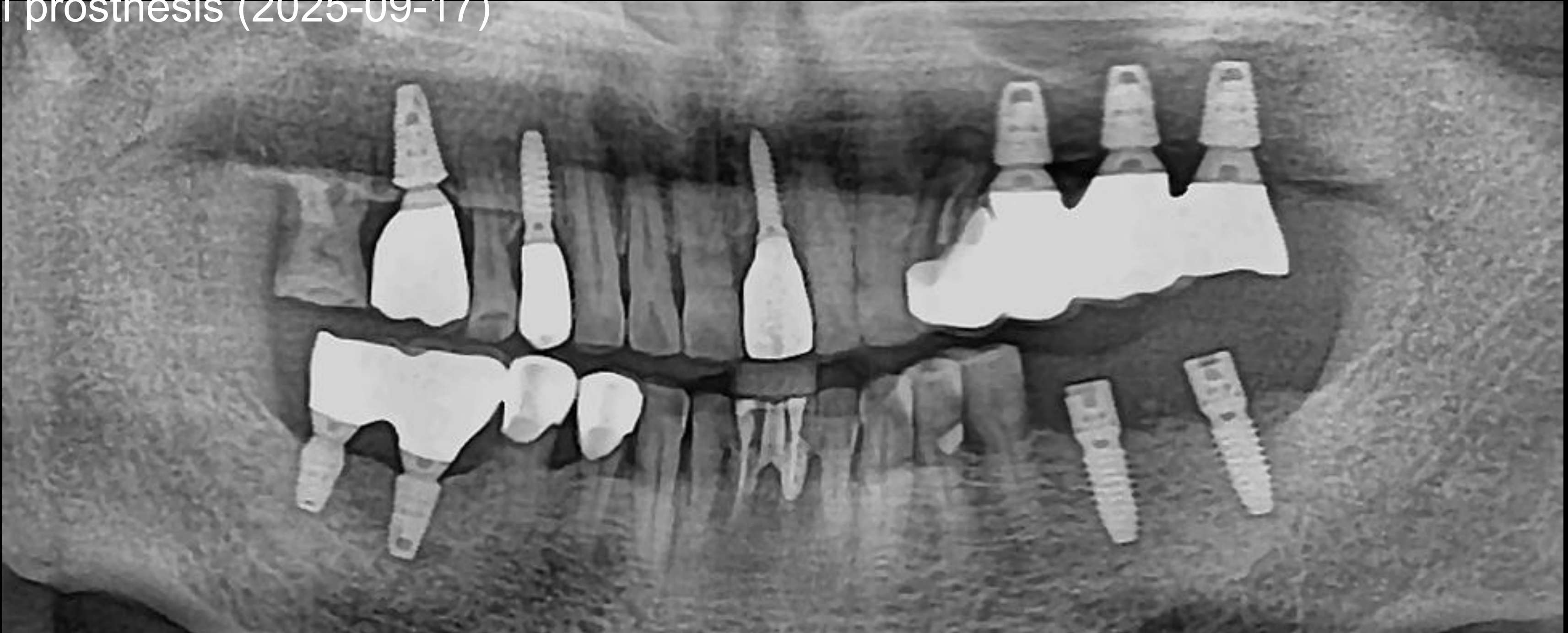Founder of Genesis and Dentium

Post-op (2025-07-16)

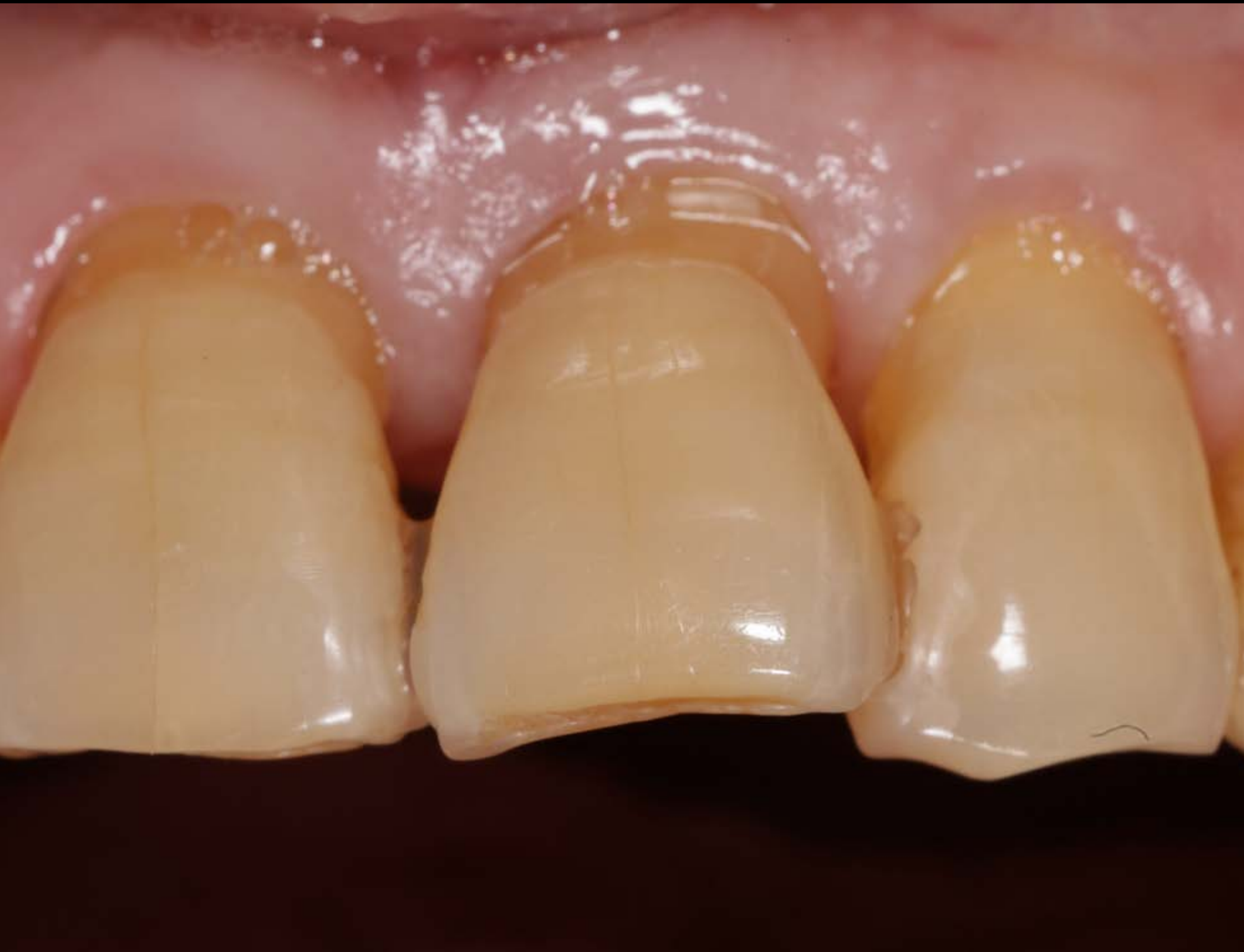

Virtual panorama from CT

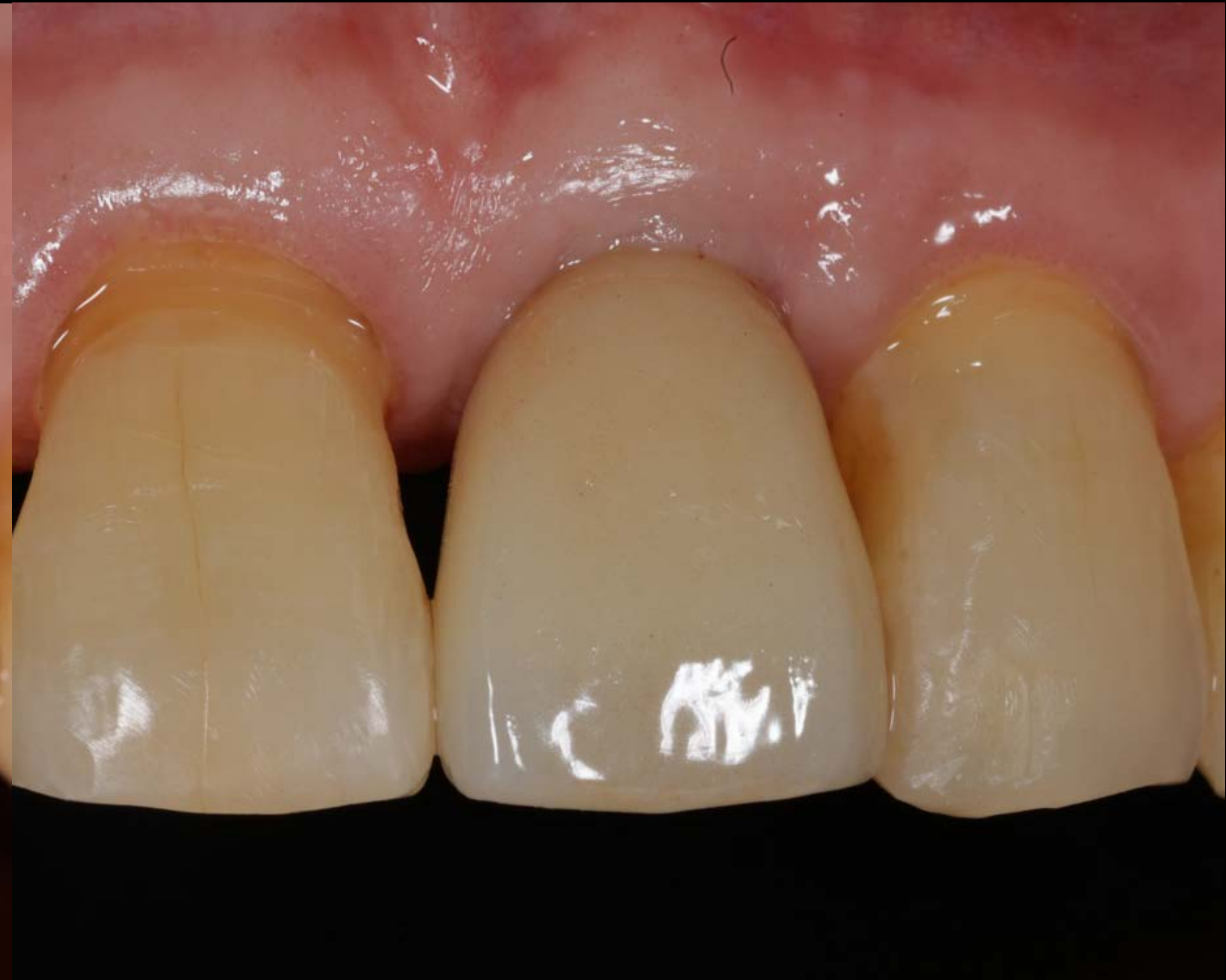Final prosthesis (2025-09-17)



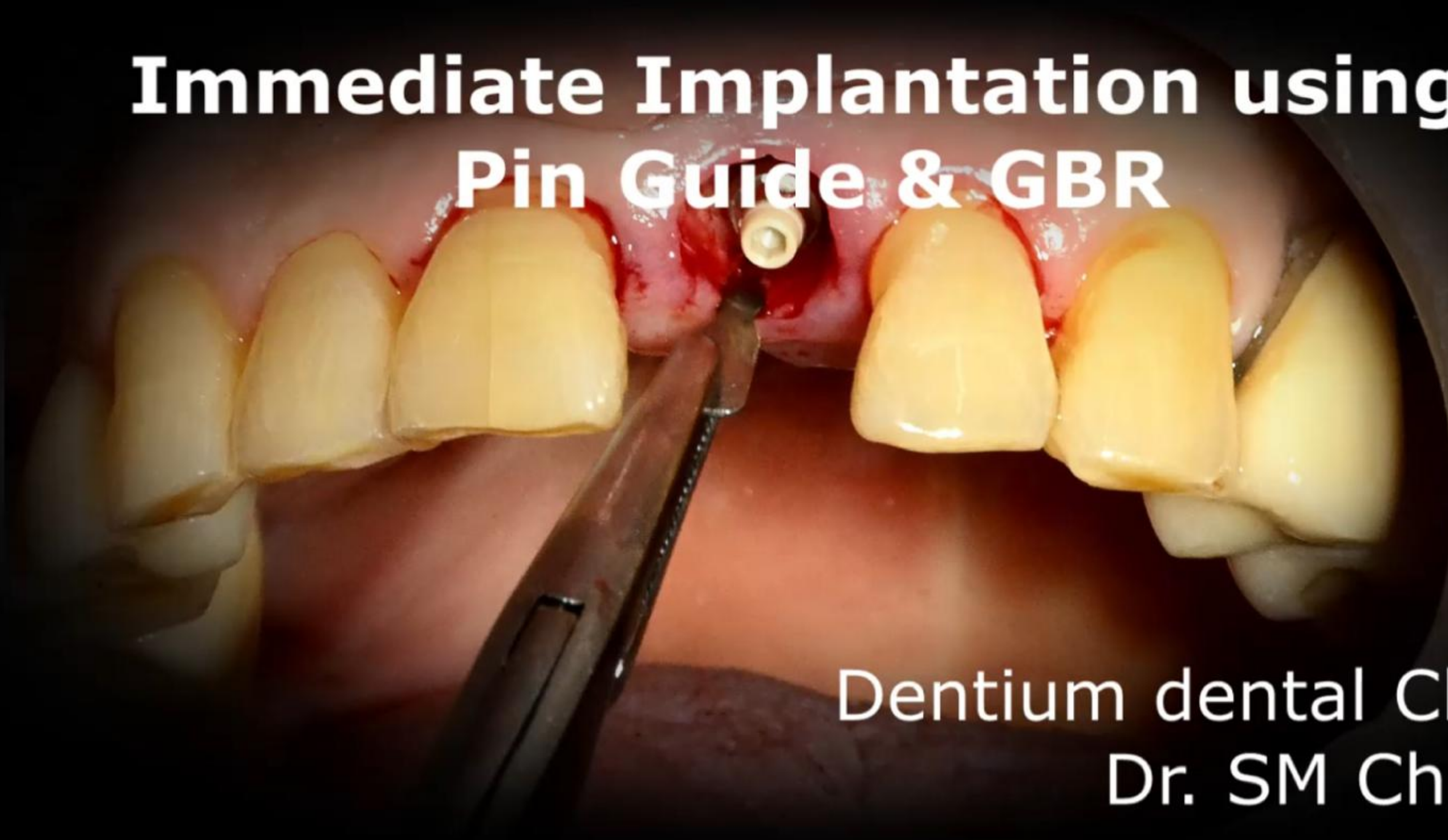Pre-op (2025-07-16)



Final prosthesis (2025-09-17)



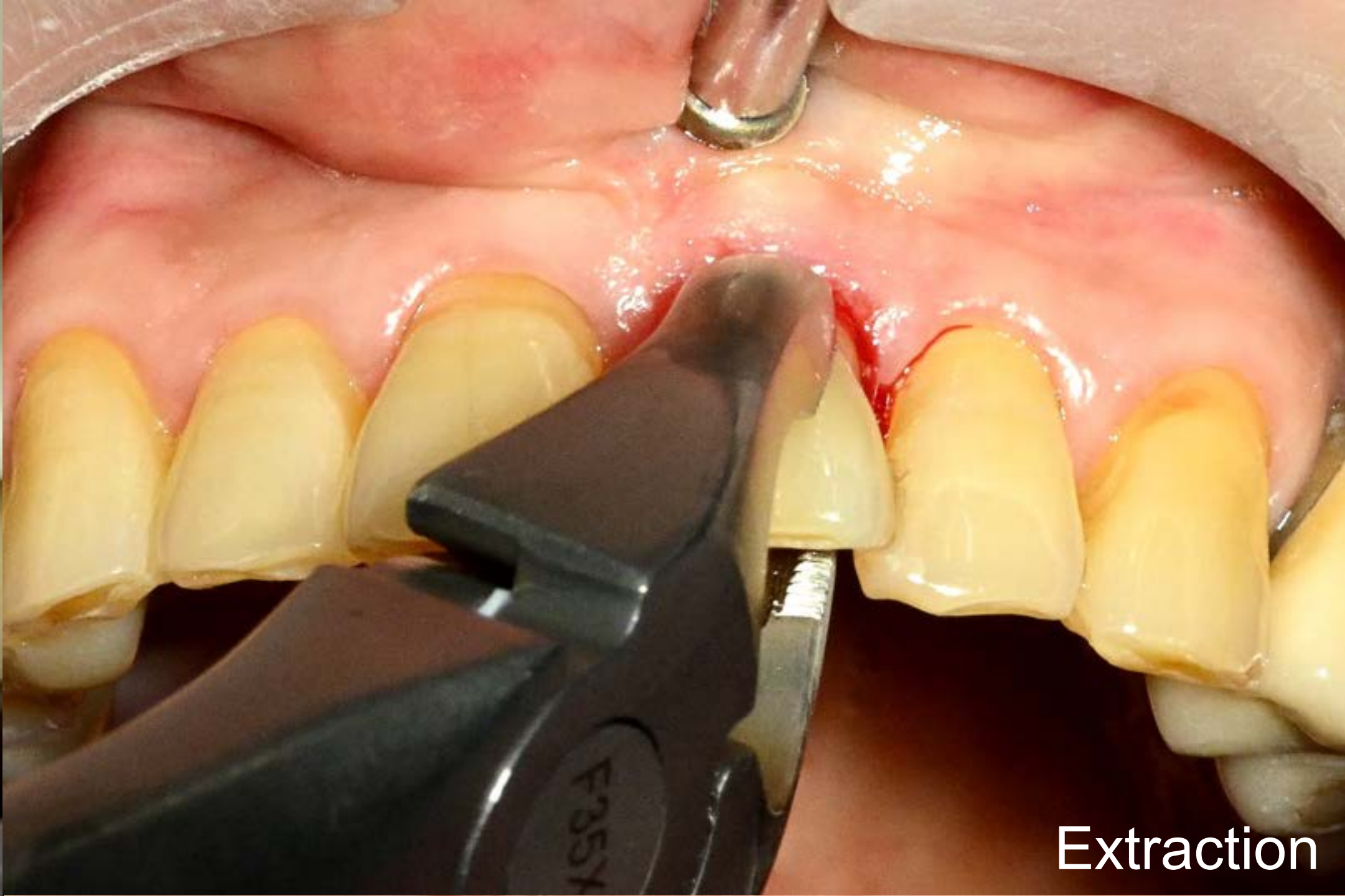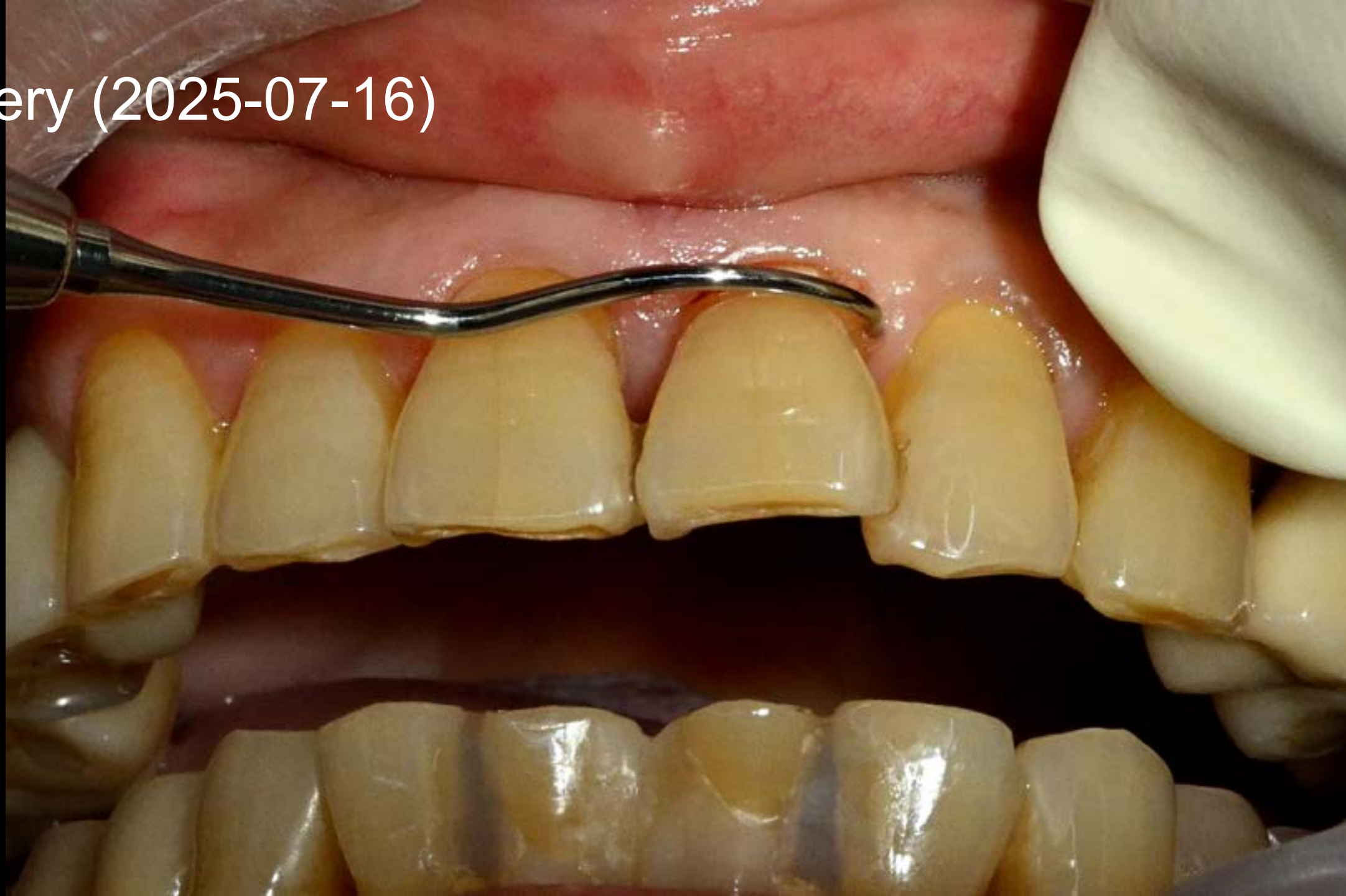Immediate Implantation using Pin Guide & GBR



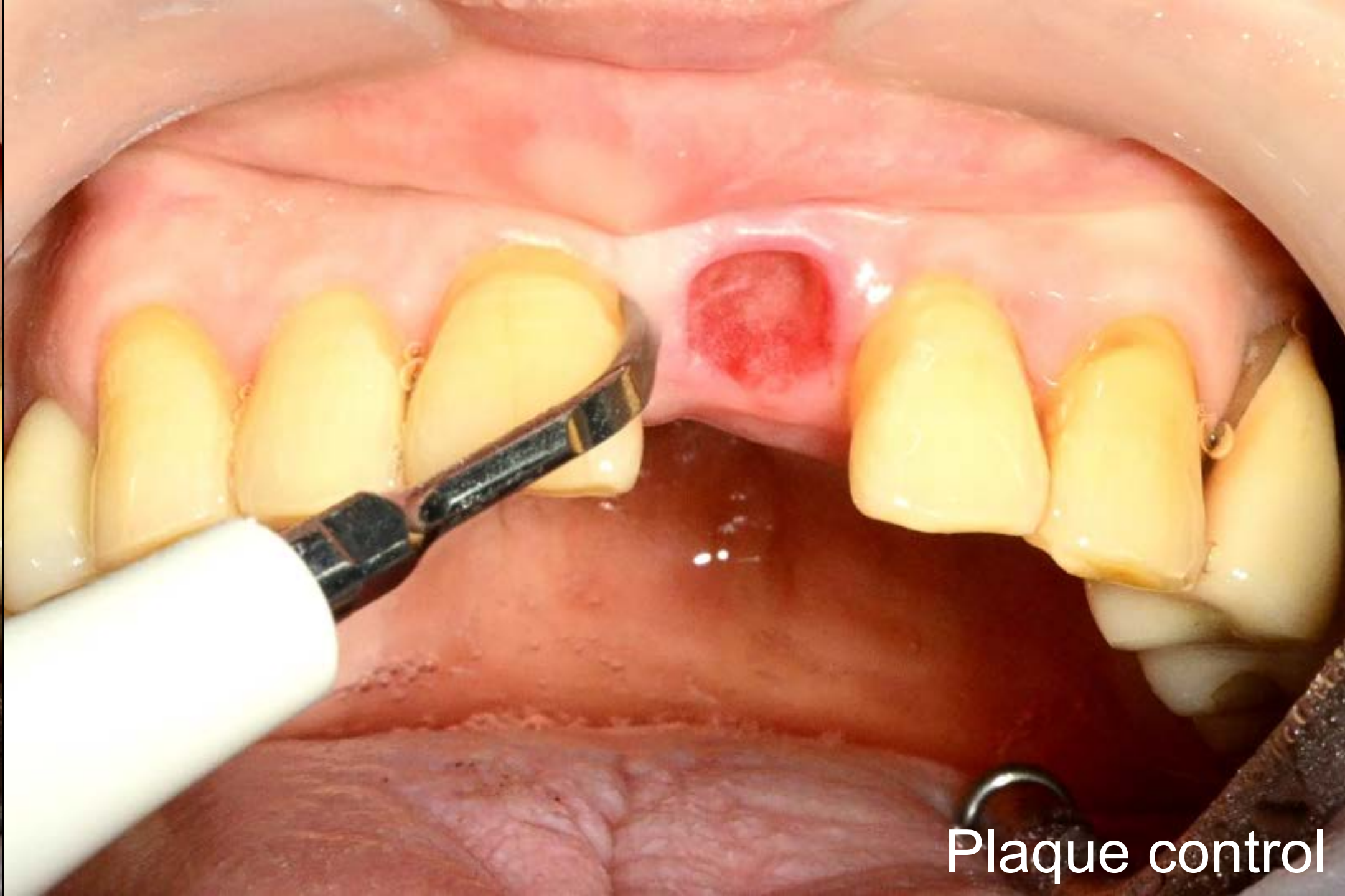
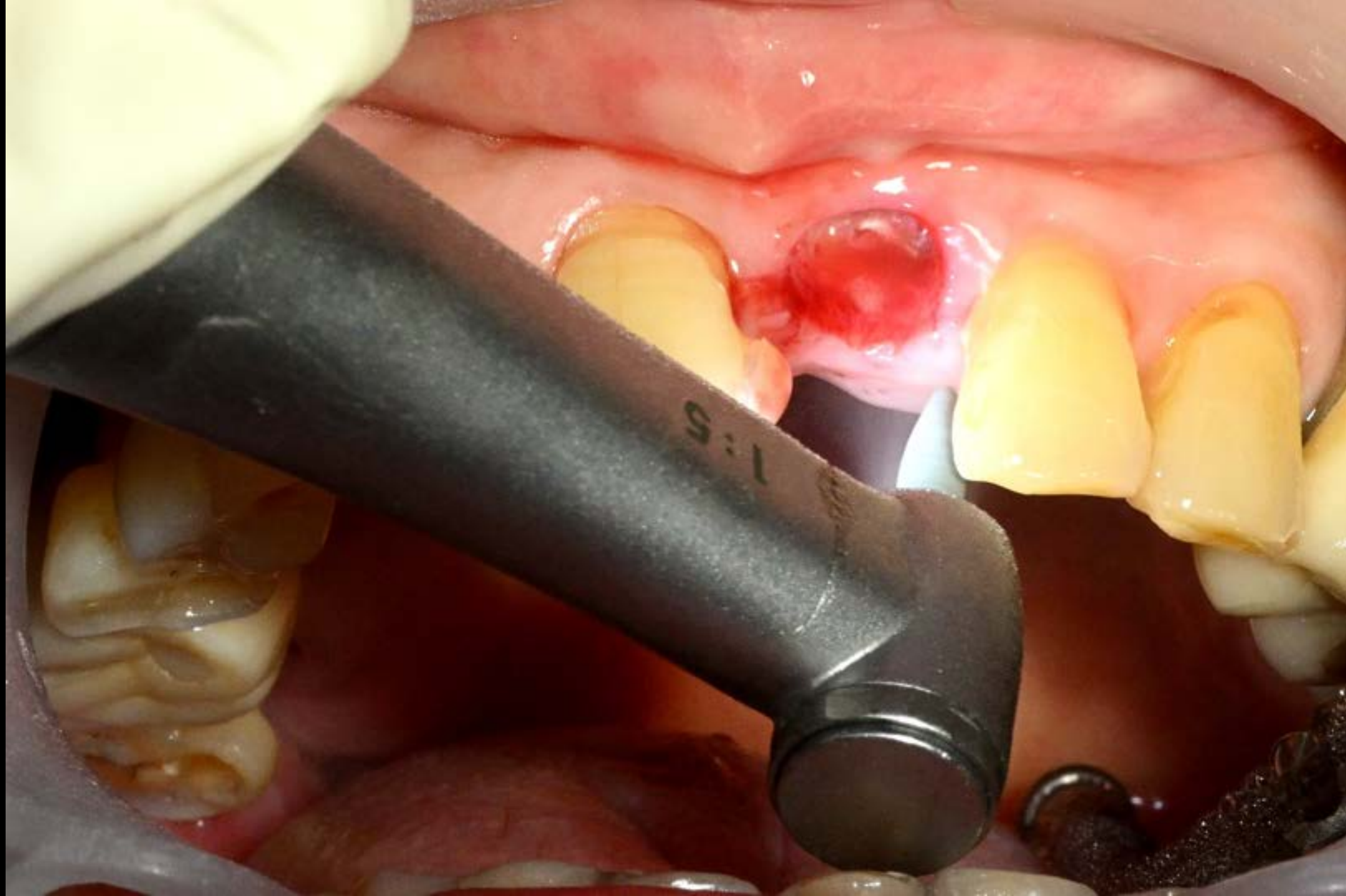Dentium dental Clinic
Dr. SM Chung

**** 4p Surgery VOD 1**

Surgery (2025-07-16)

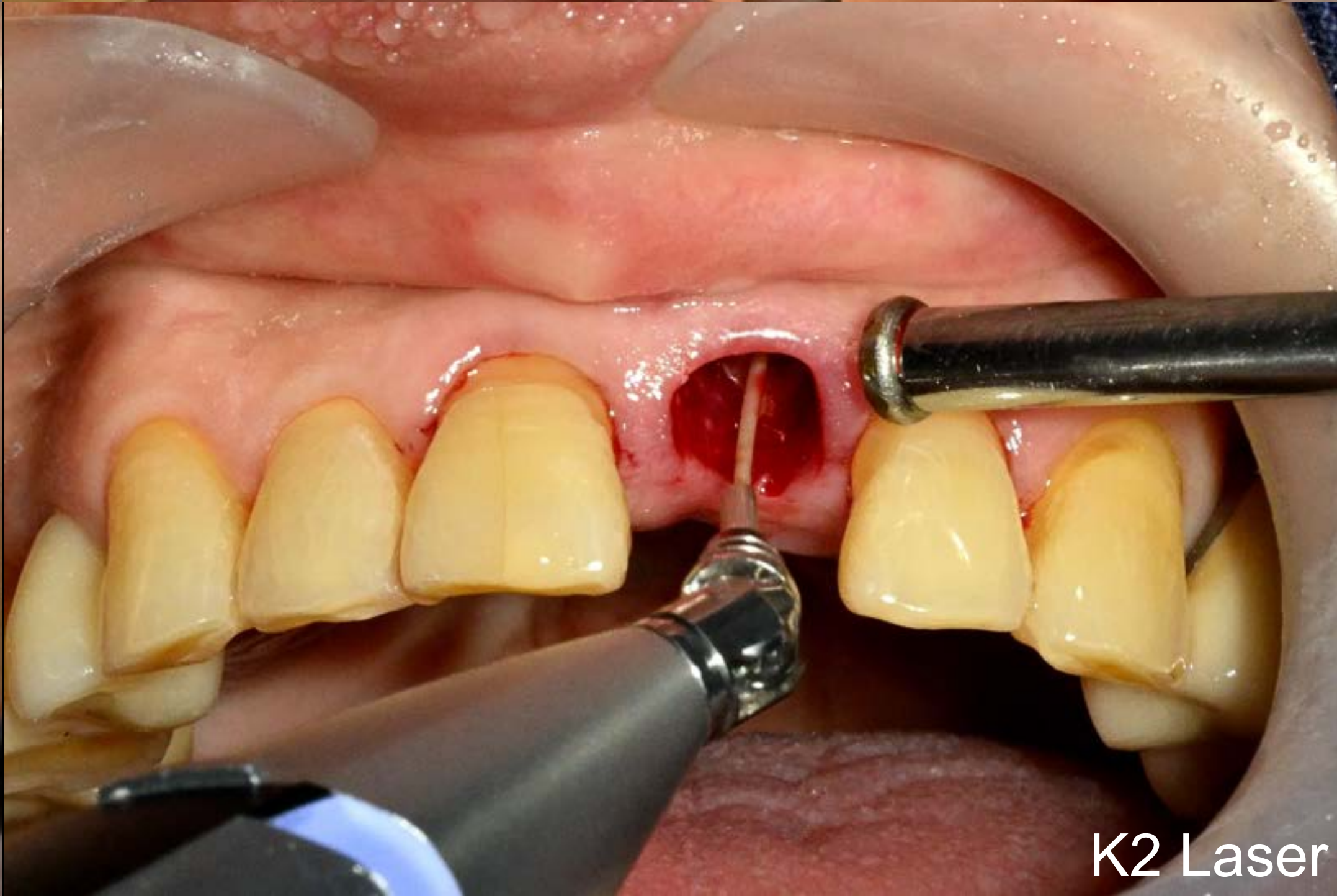
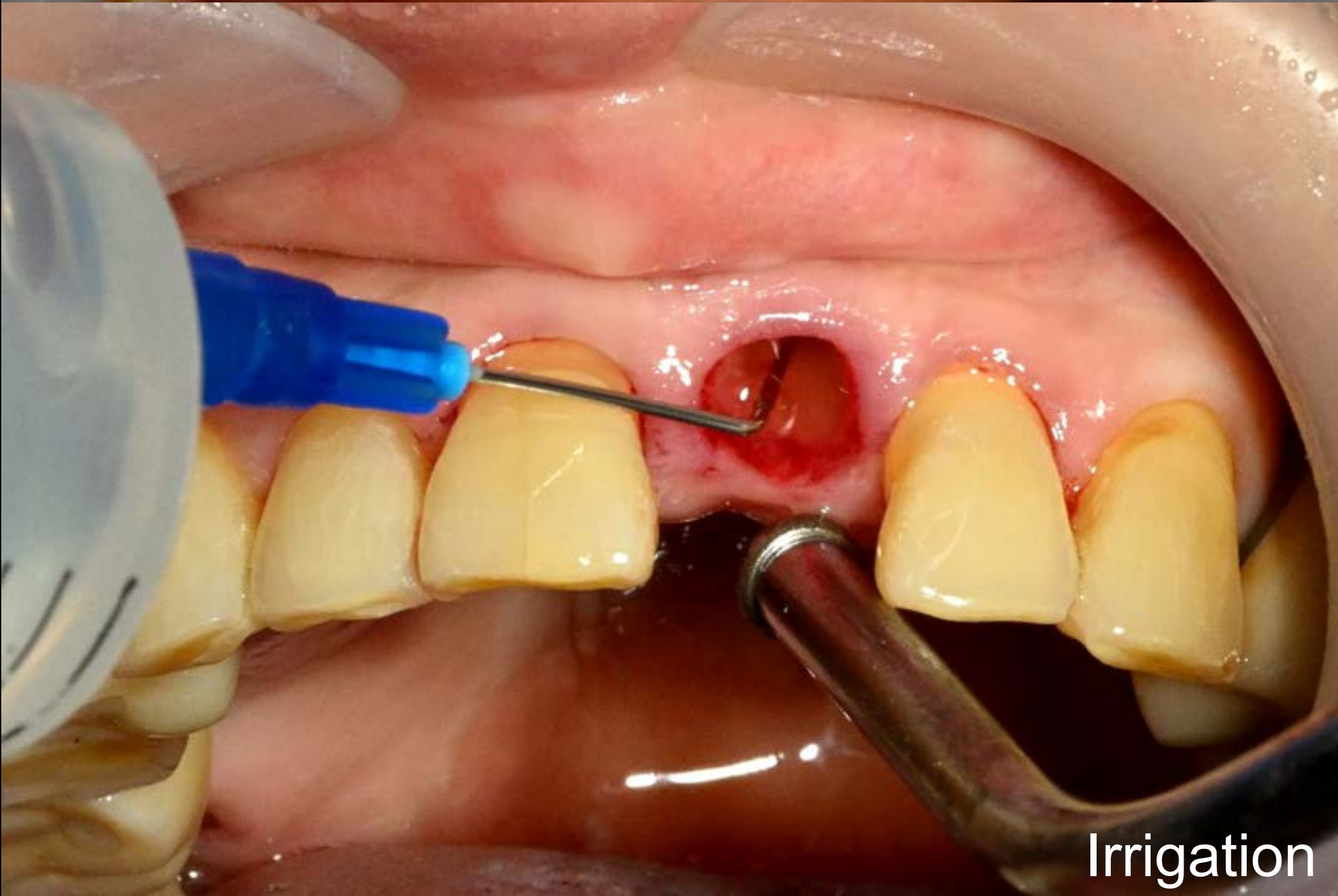
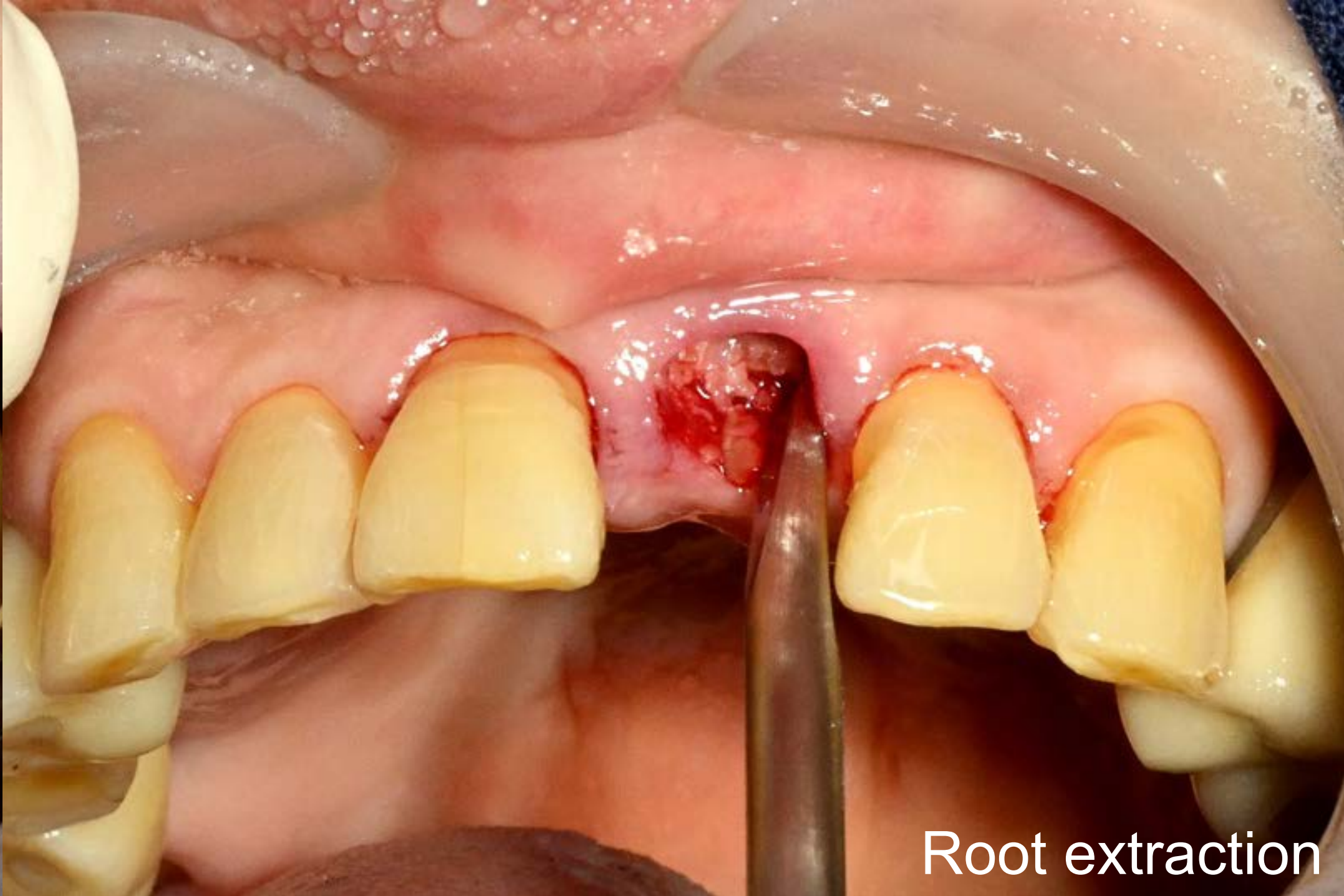
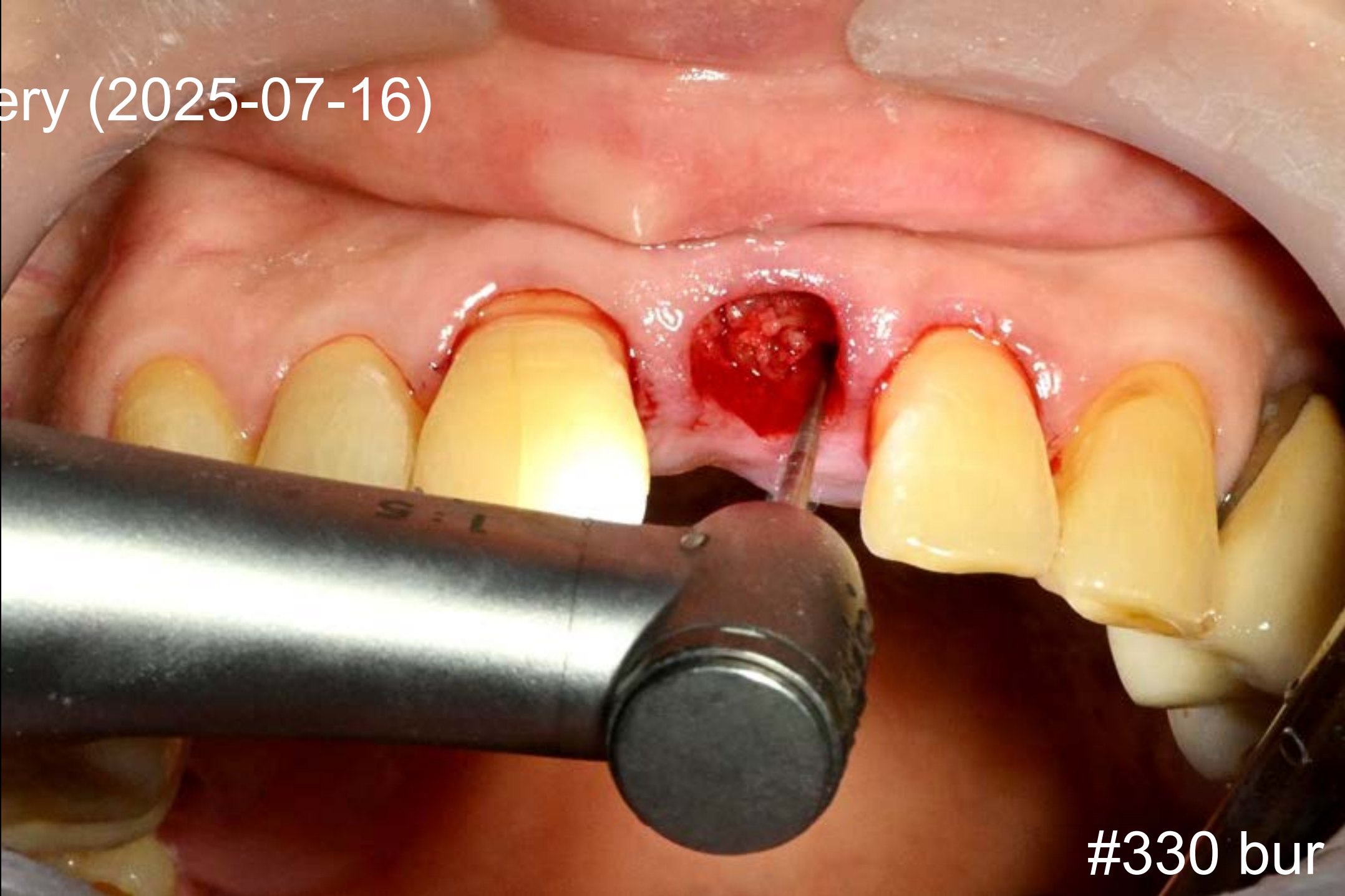


Extraction

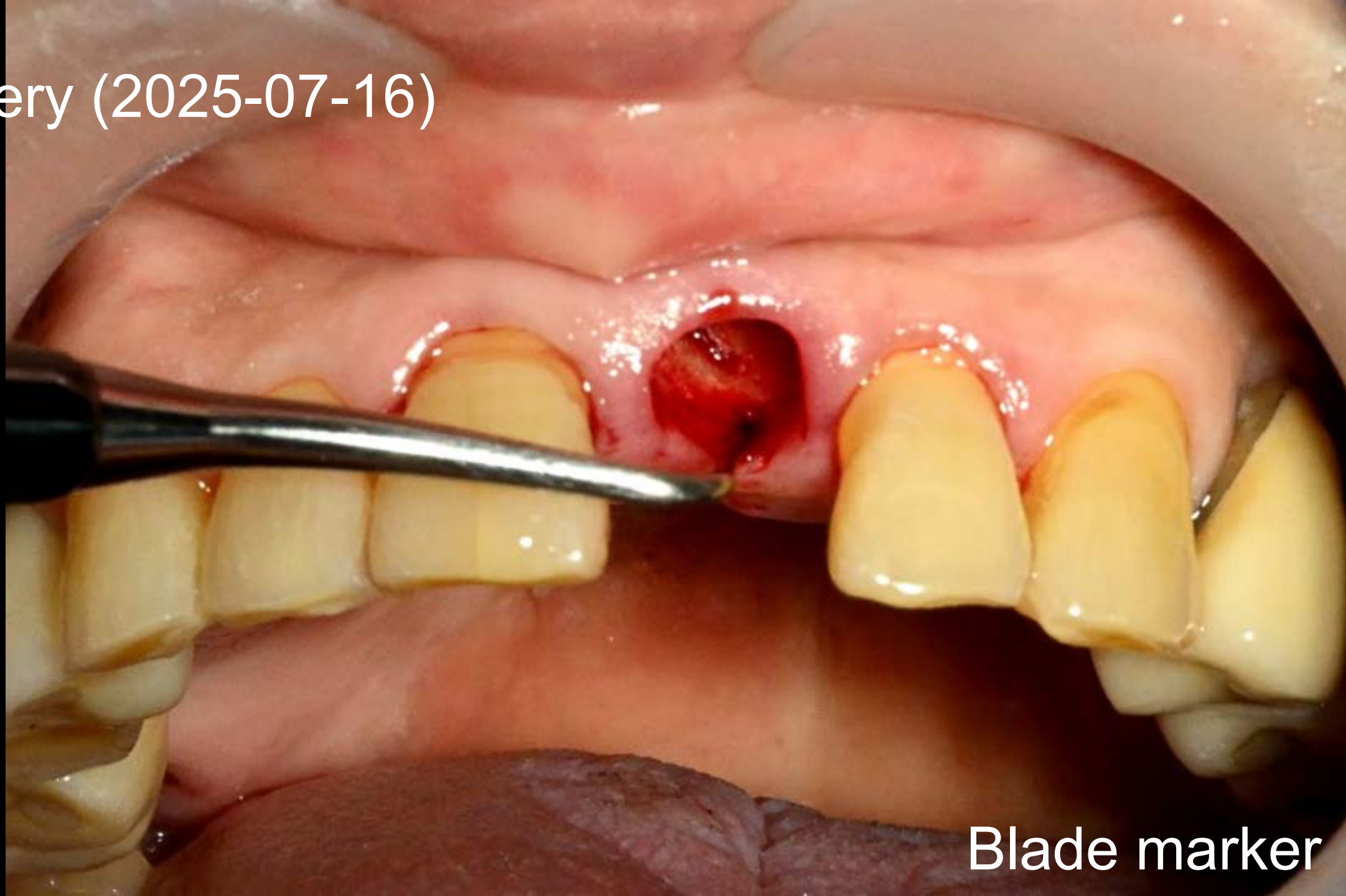


Plaque control

Surgery (2025-07-16)



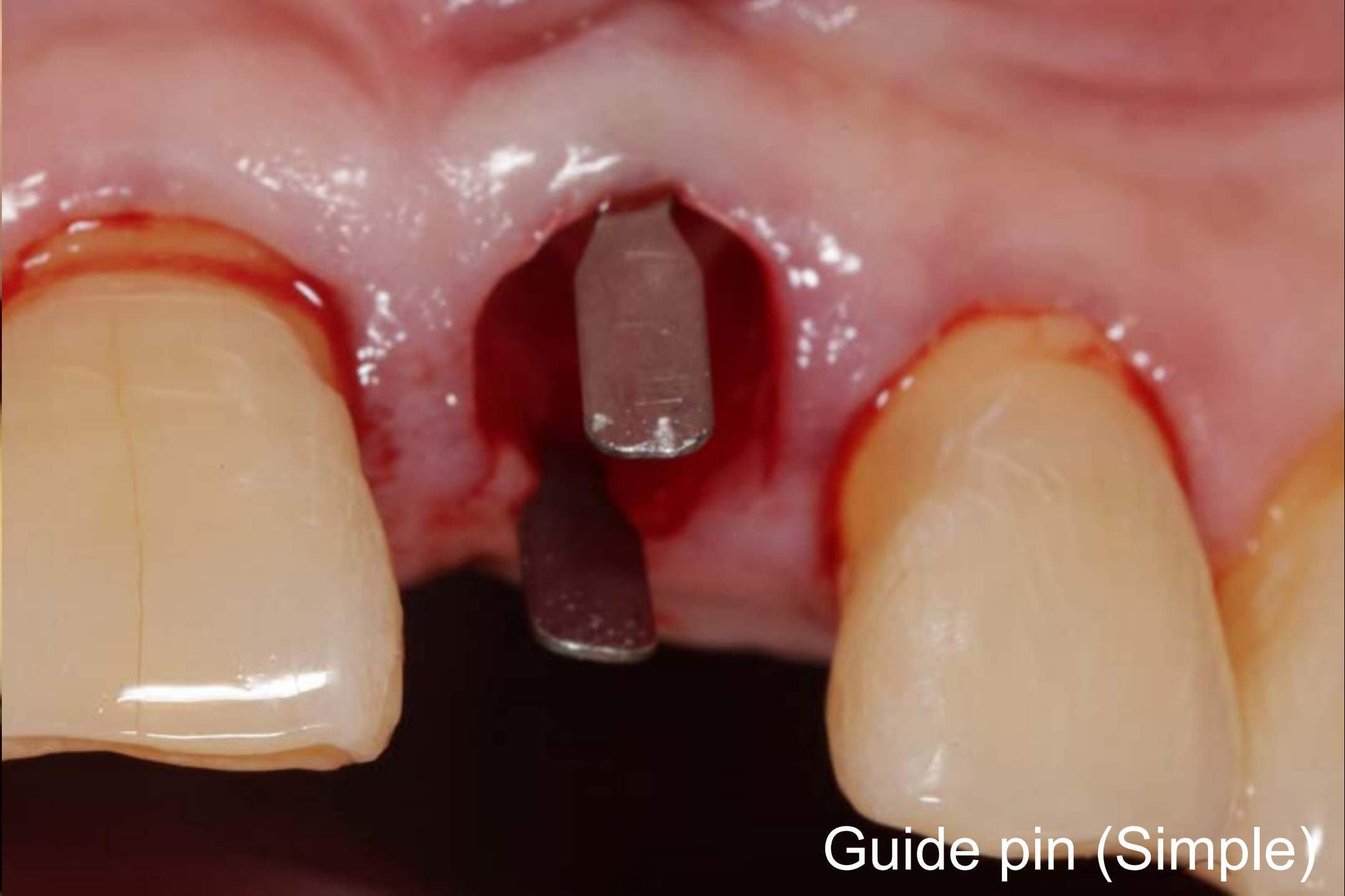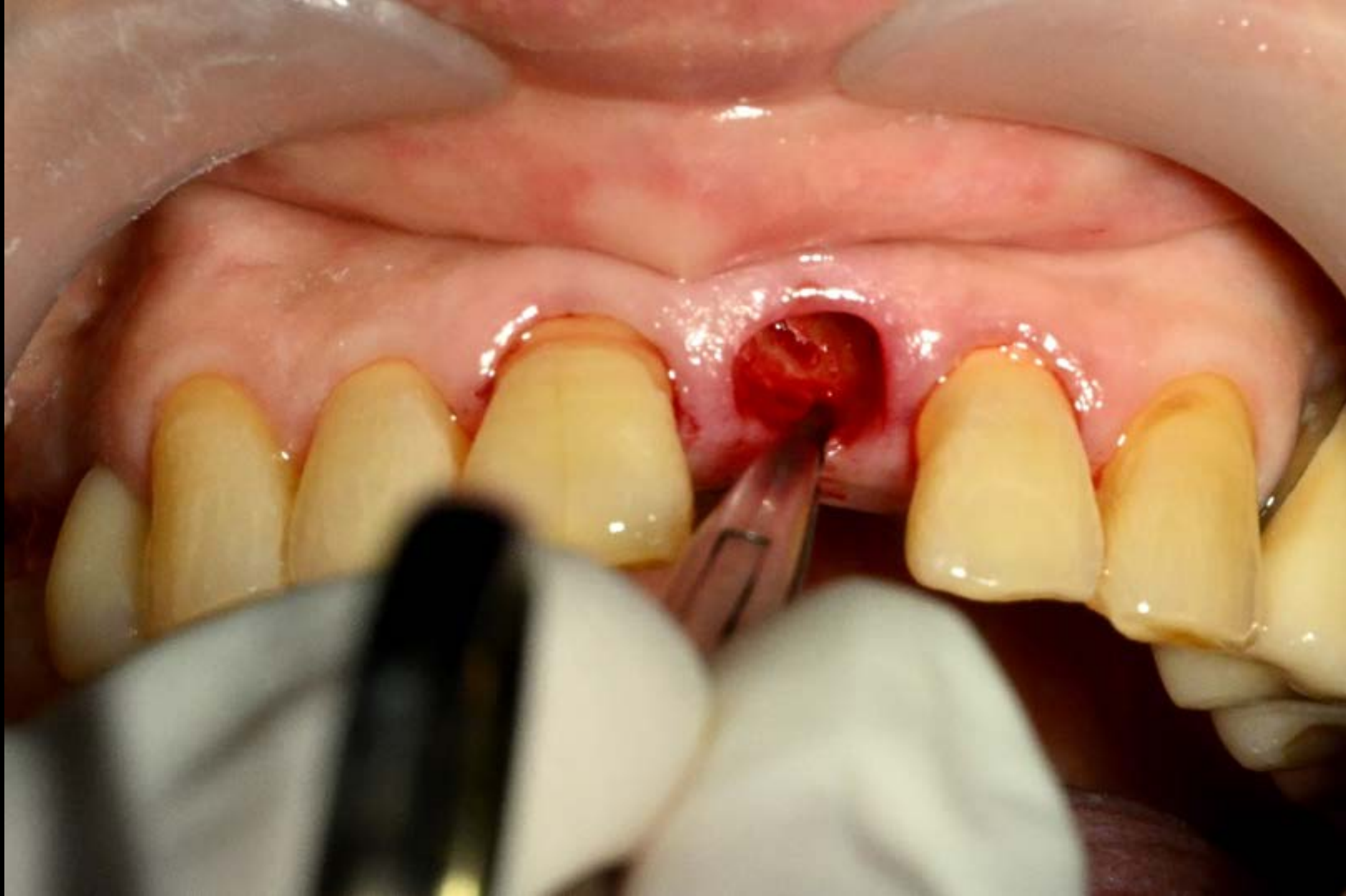
Surgery (2025-07-16)



Blade marker

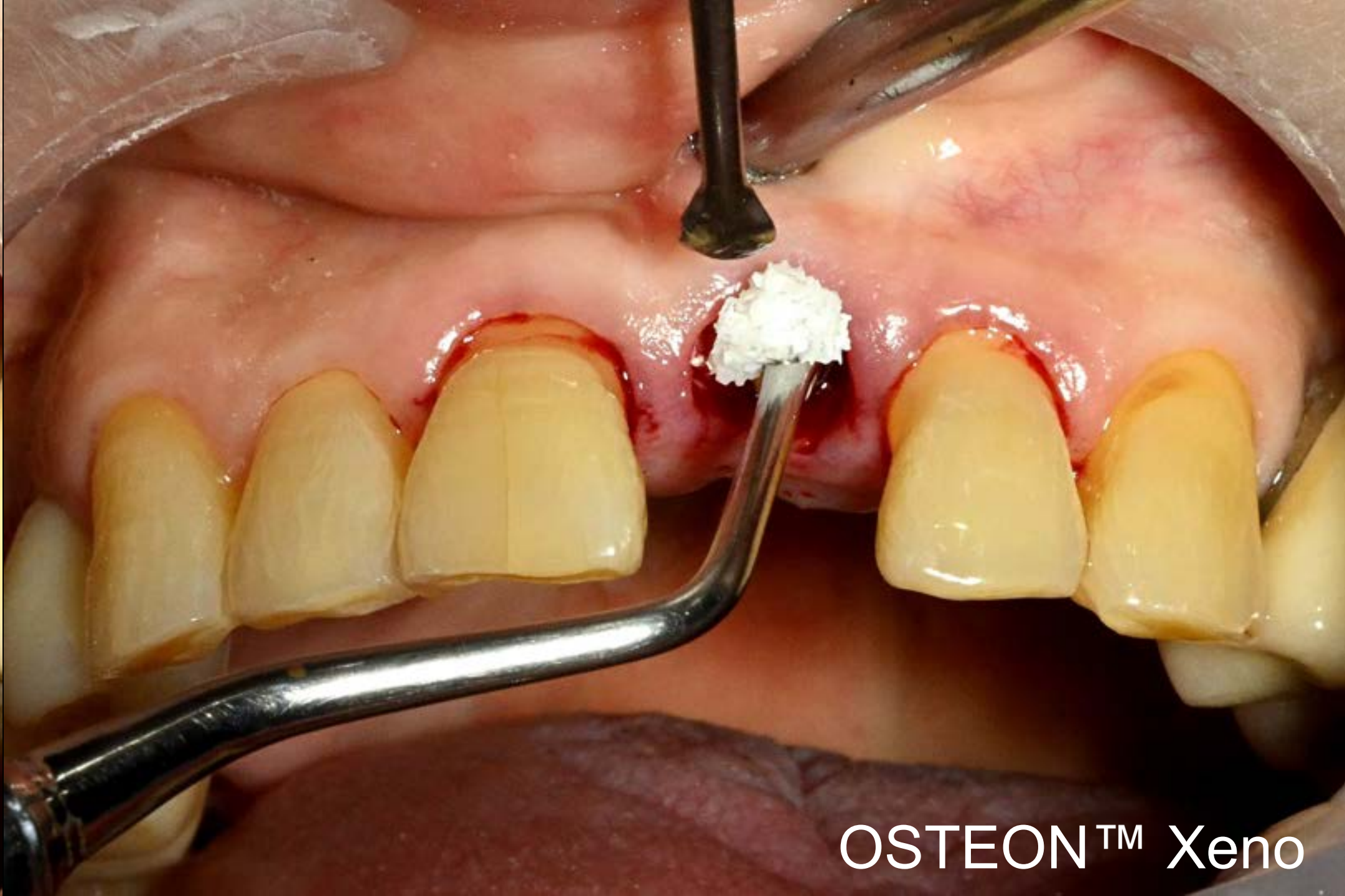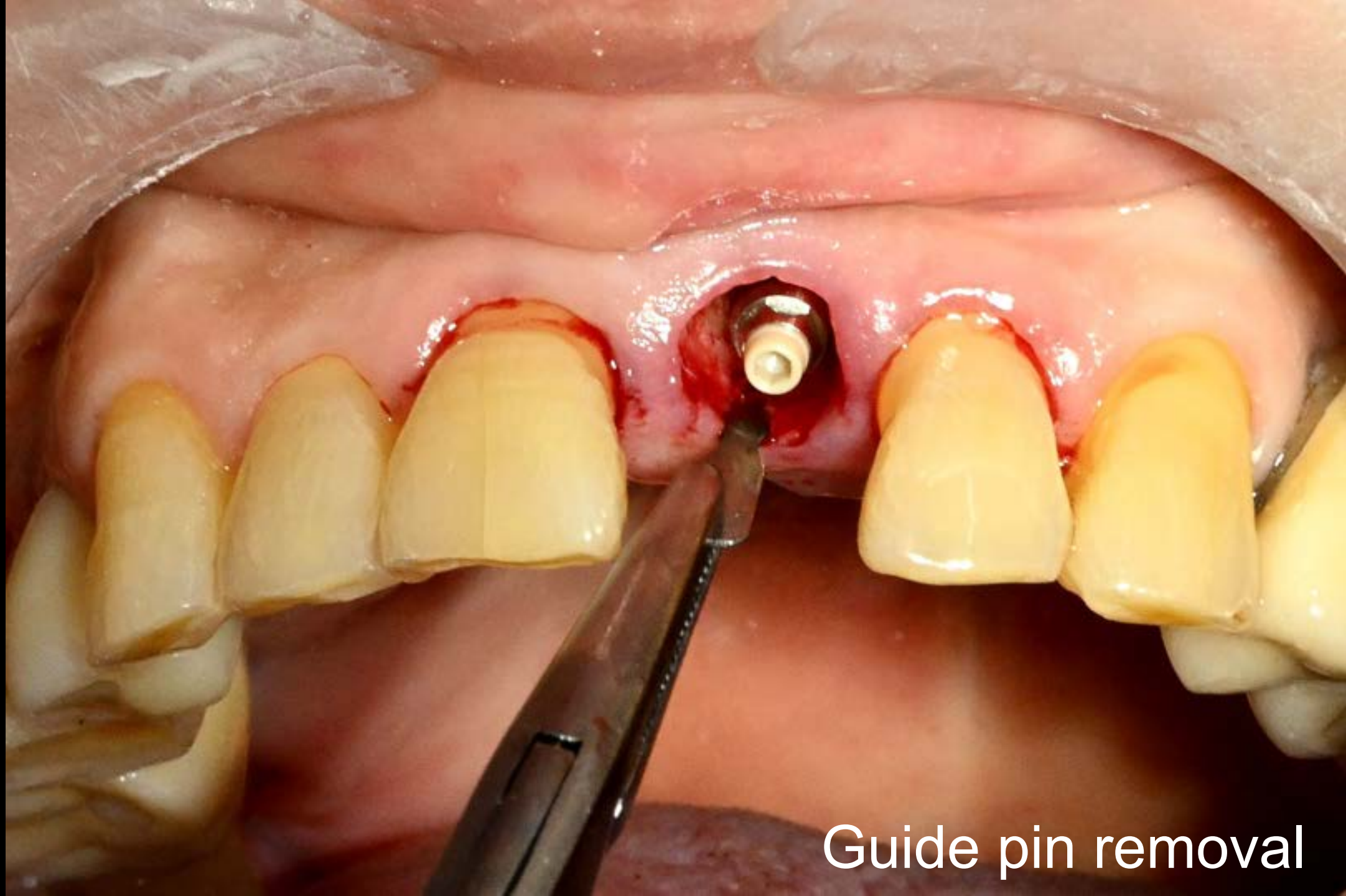
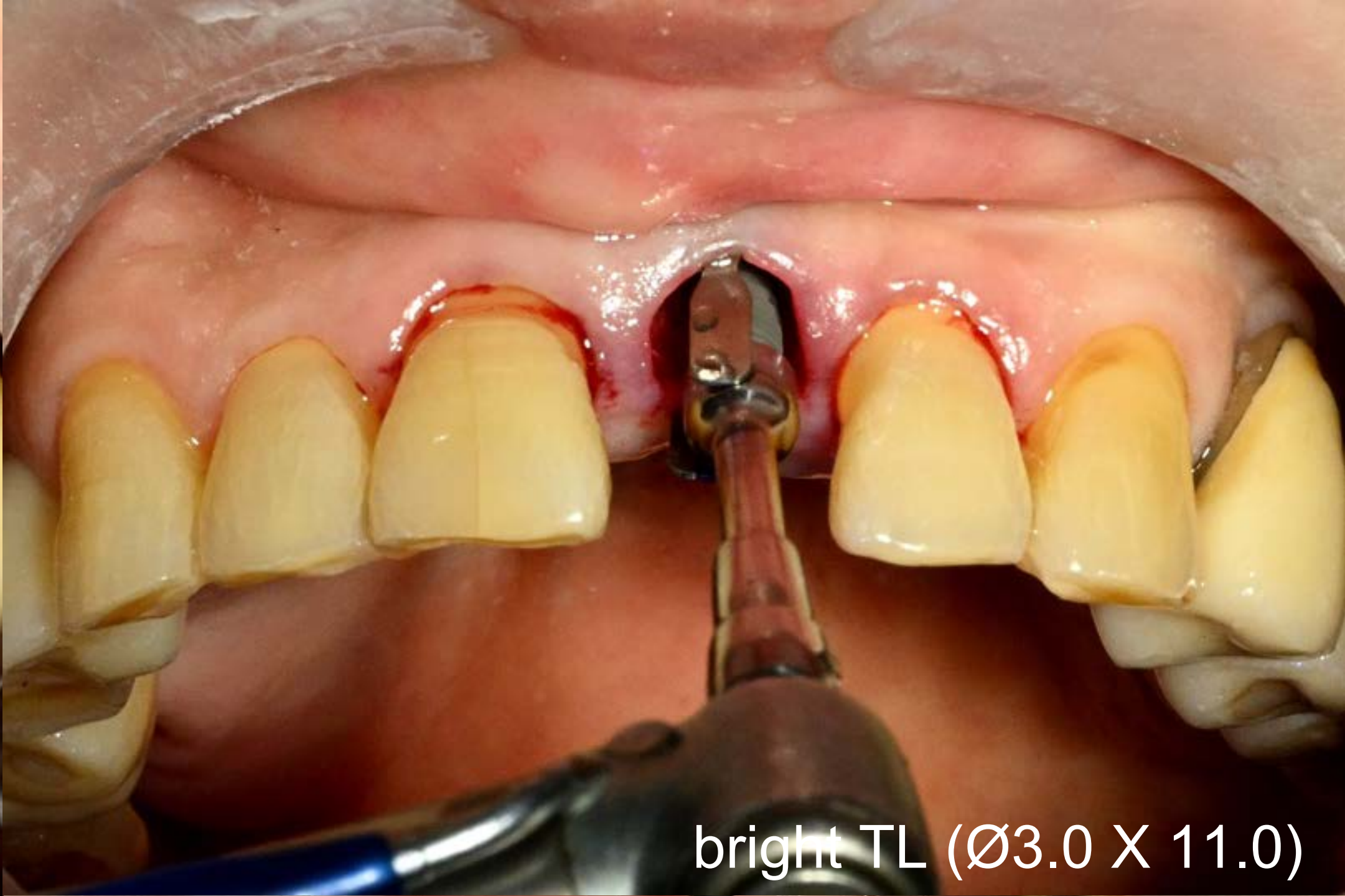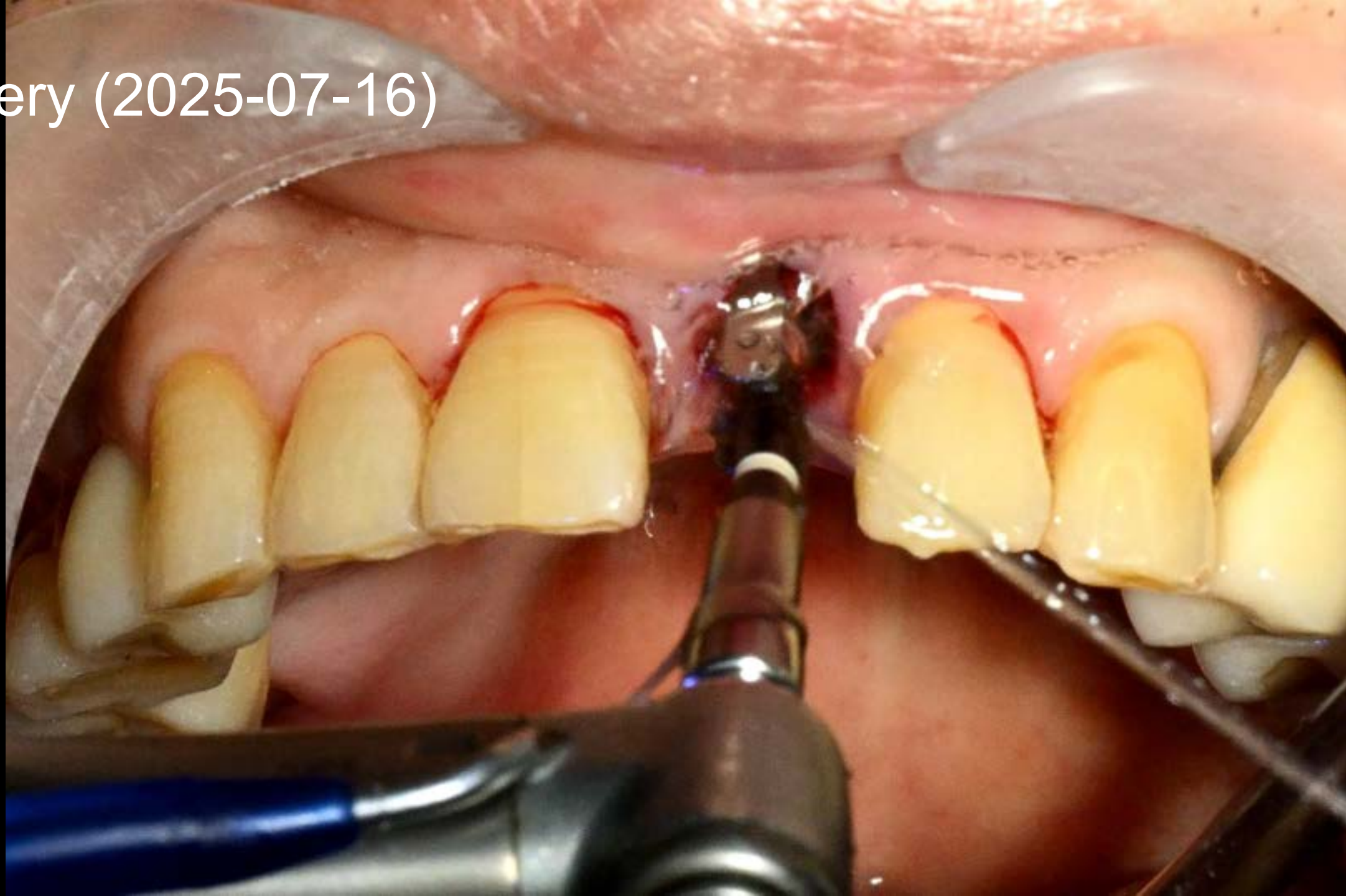


Guide Pin (Simple) with needle holder



Guide pin (Simple)

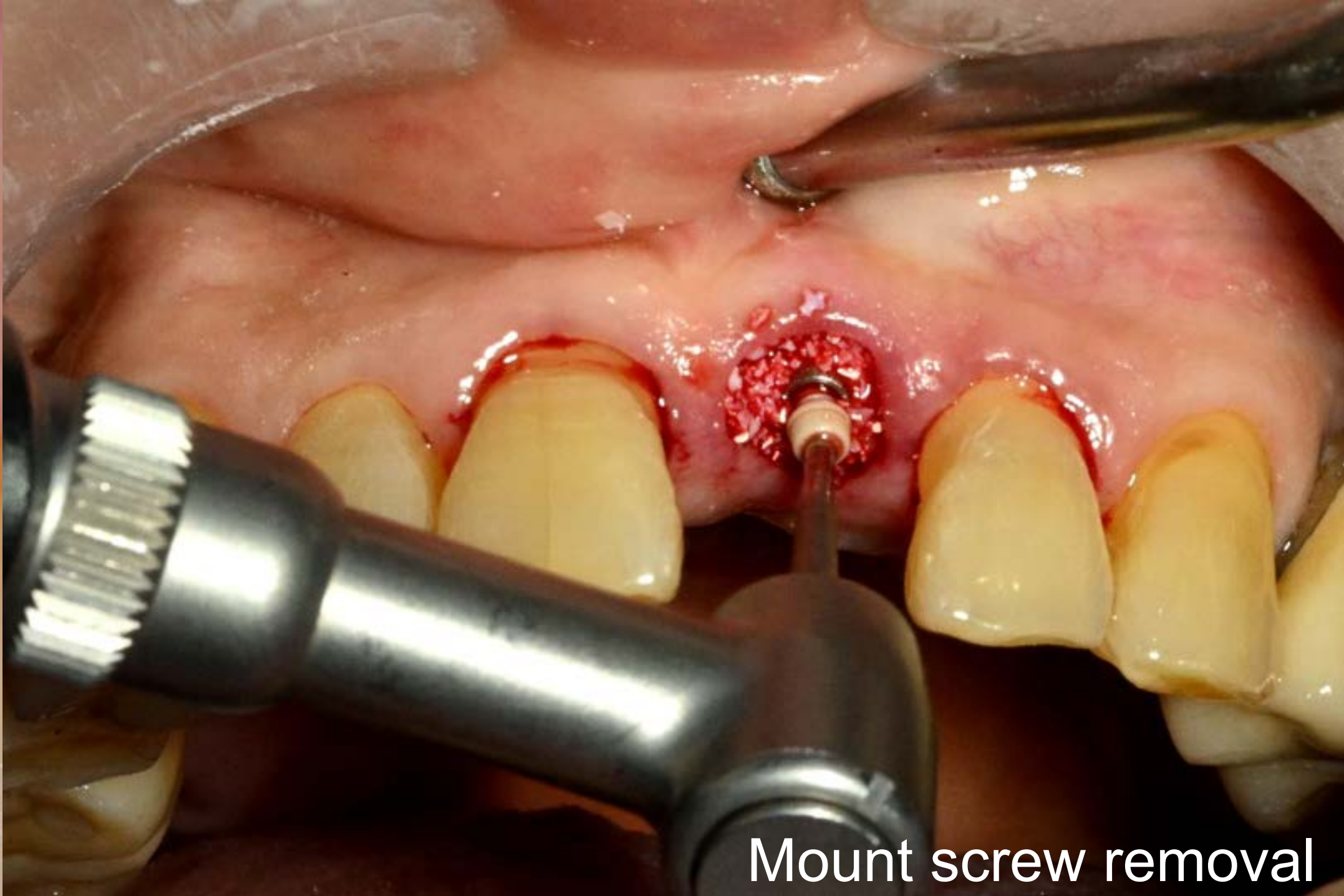
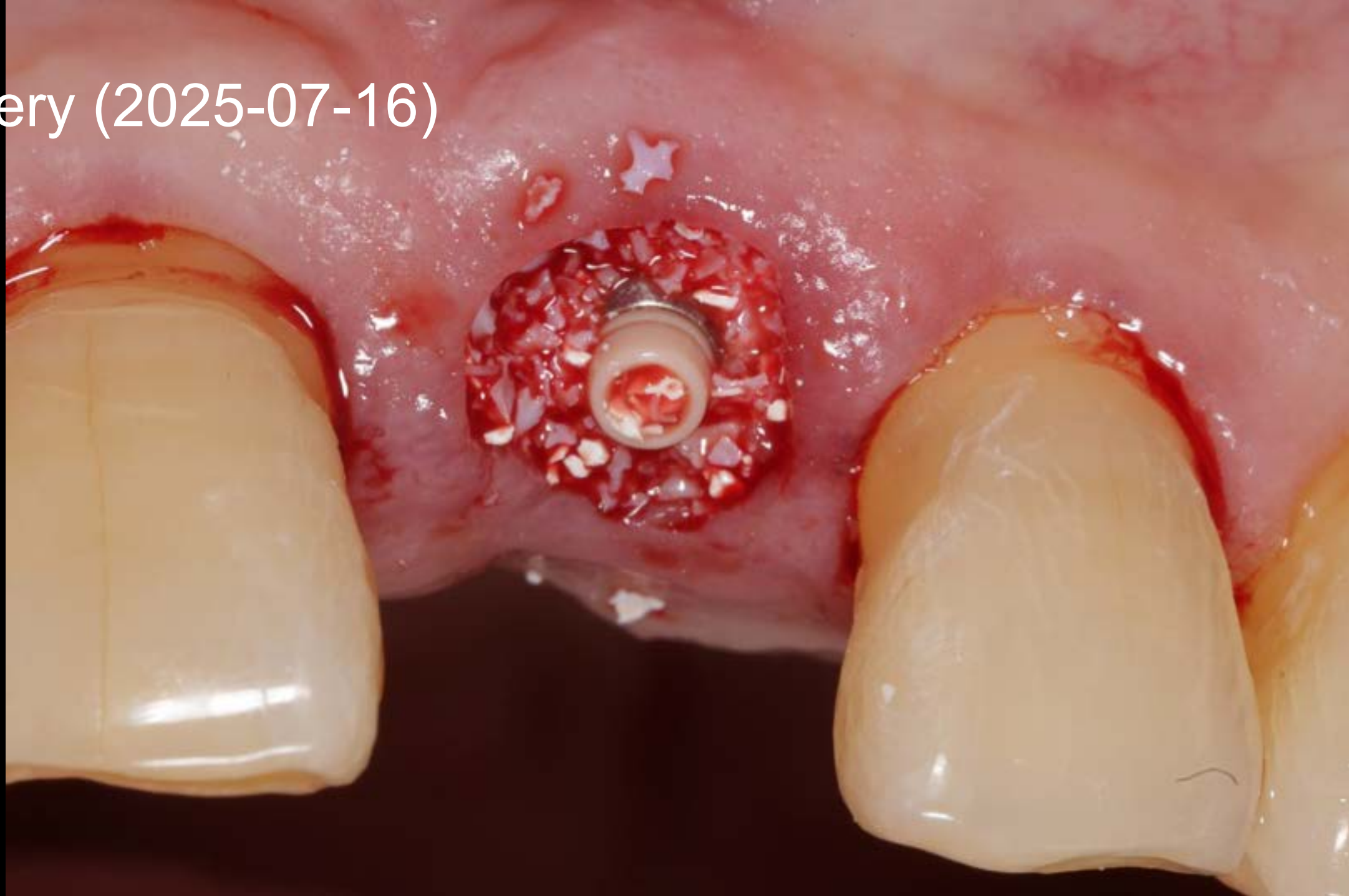Surgery (2025-07-16)



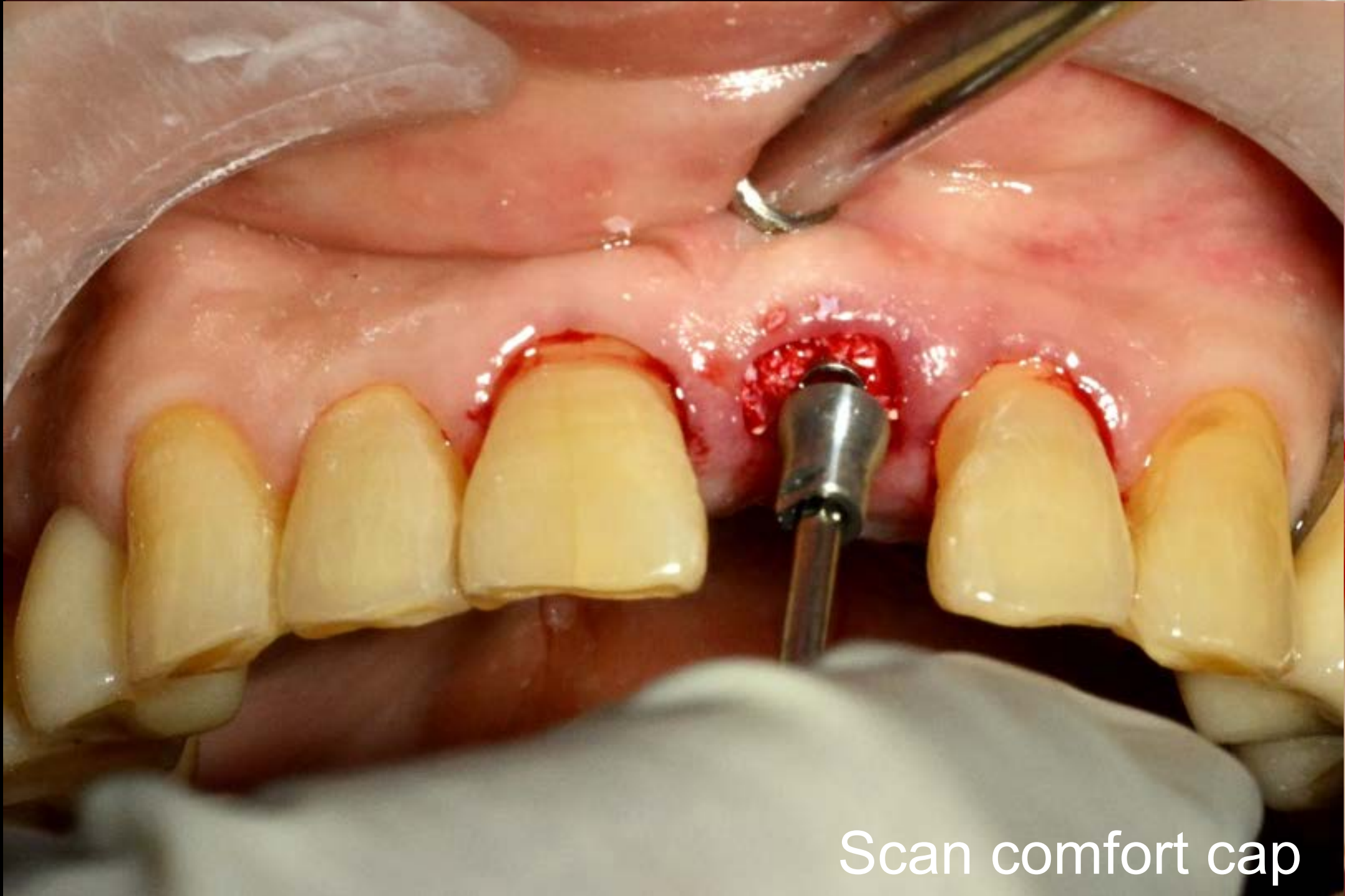
Guide pin removal

OSTEON™ Xeno

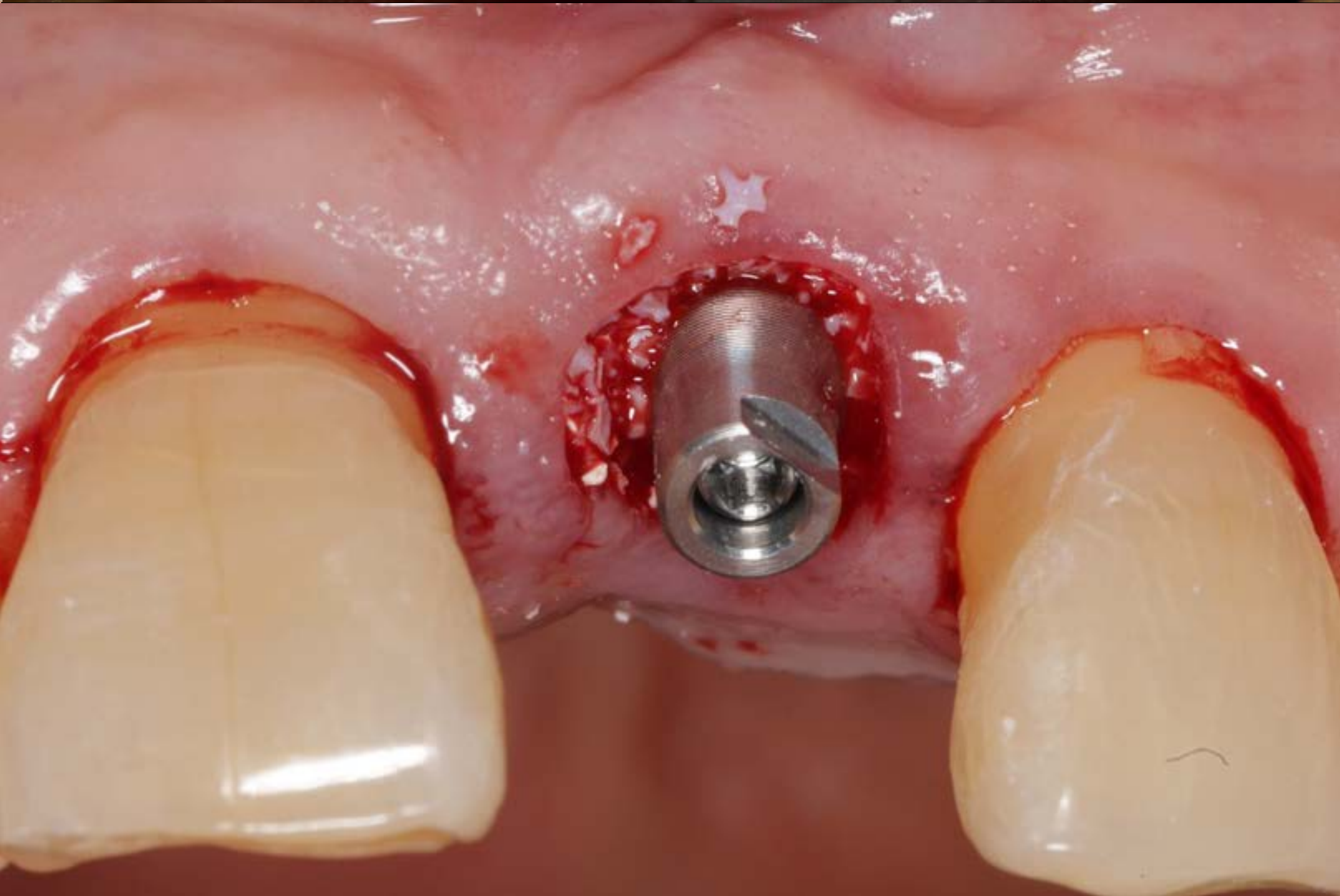Surgery (2025-07-16)



Mount screw removal

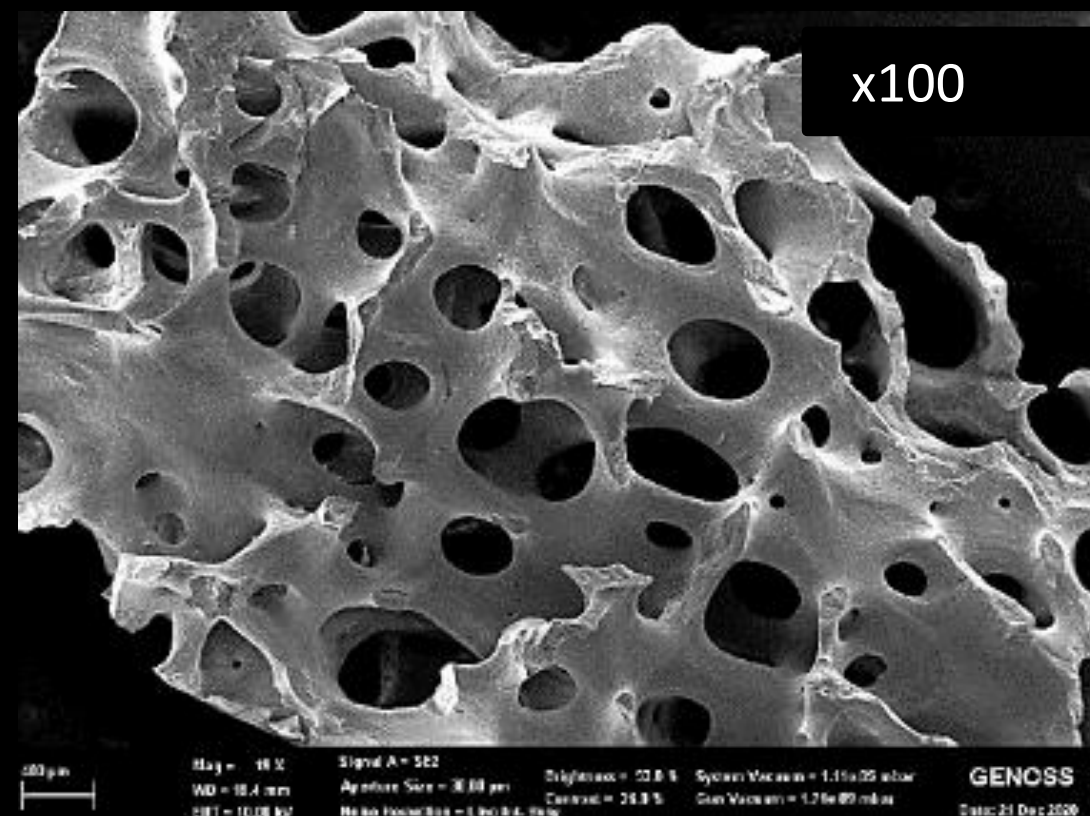


Scan comfort cap




OSTEON™ Xeno

- Osteoconductive **natural bovine bone** substitute (similar to human bone)
- Highly interconnected macro/micro-pores
- Excellent Osteoconductivity
- **Easy handling and excellent wettability**
- Complete removal of organic substances
- Type: vial, block



Macropores

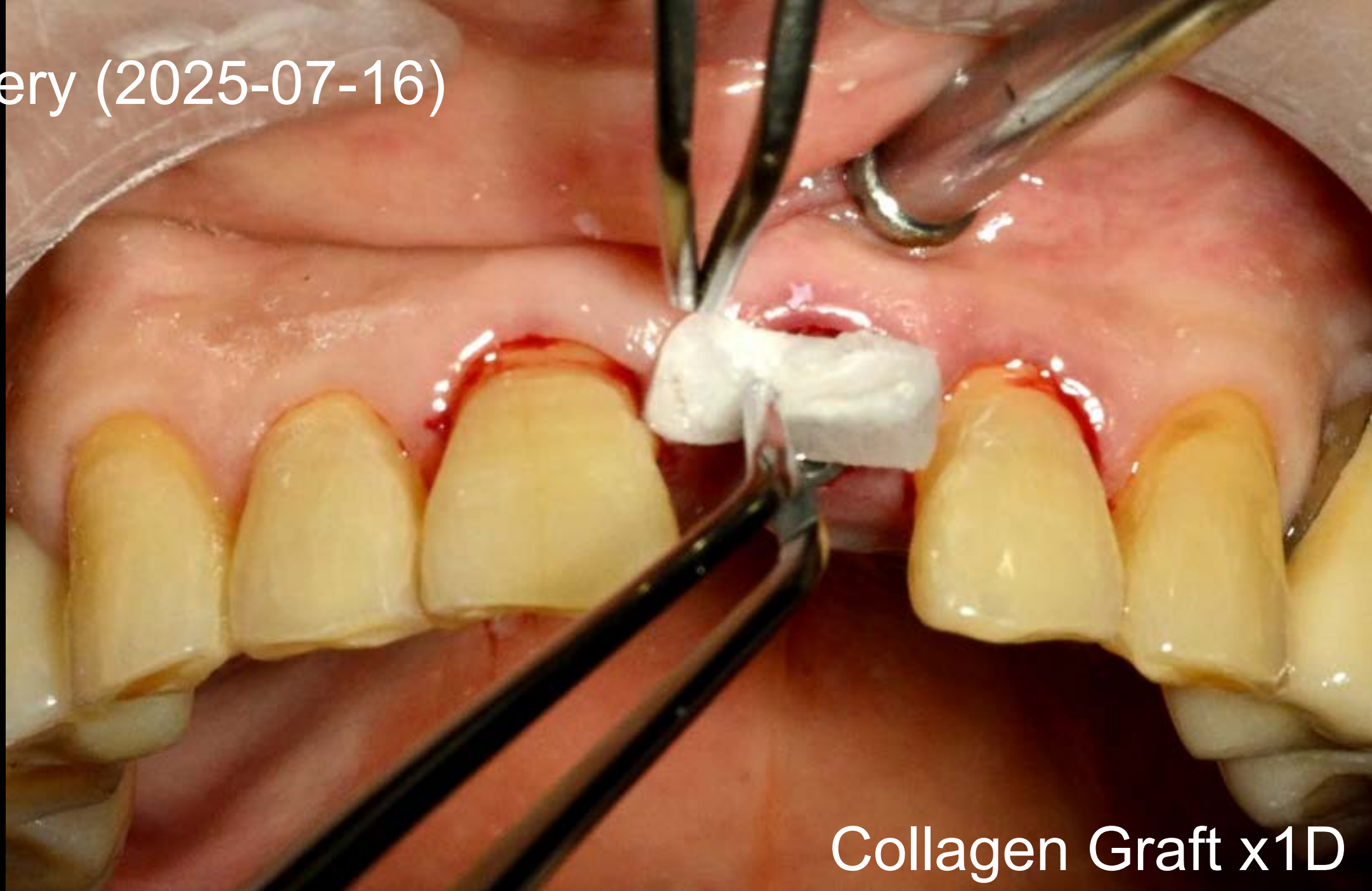


Micropores

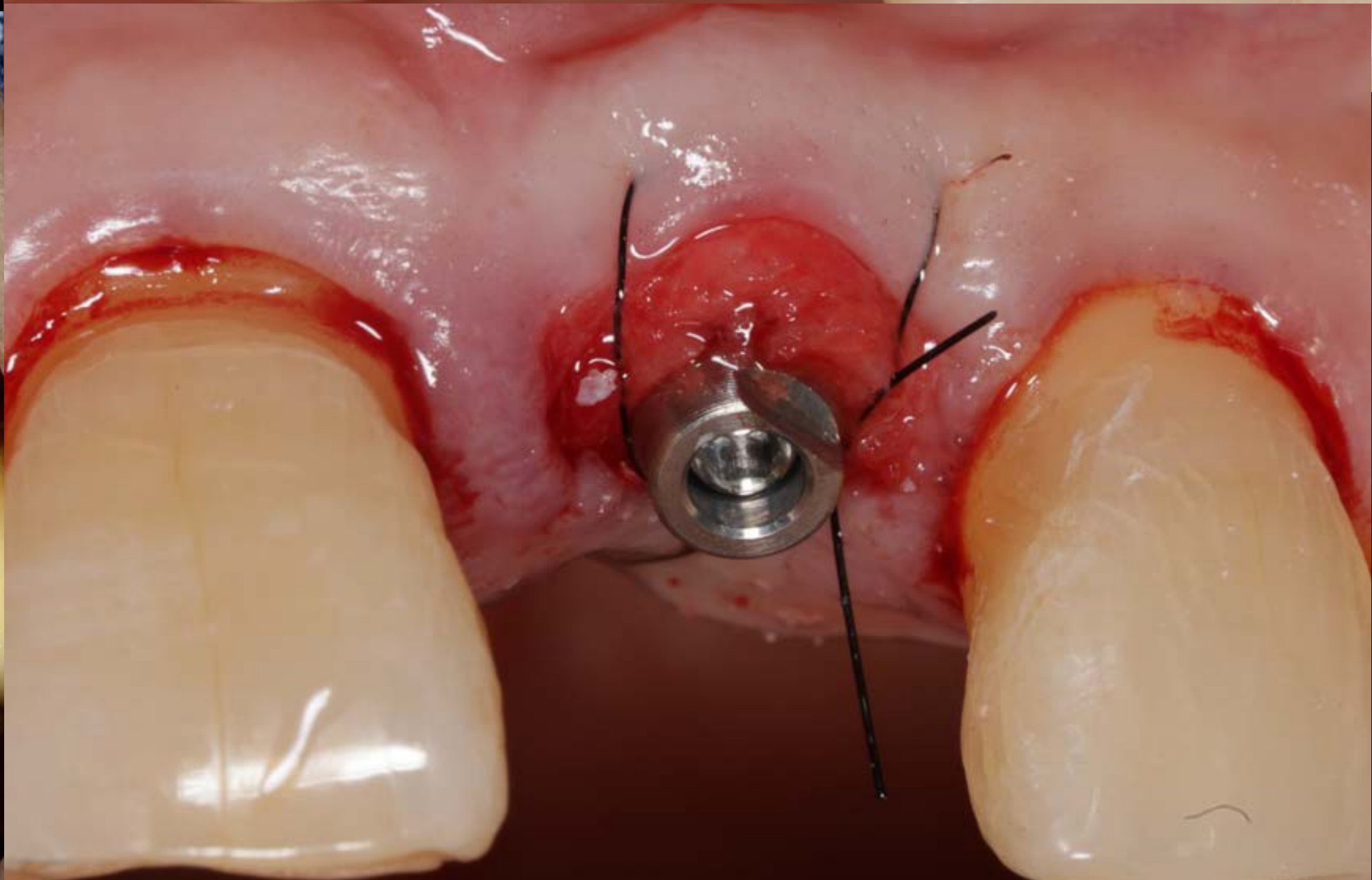
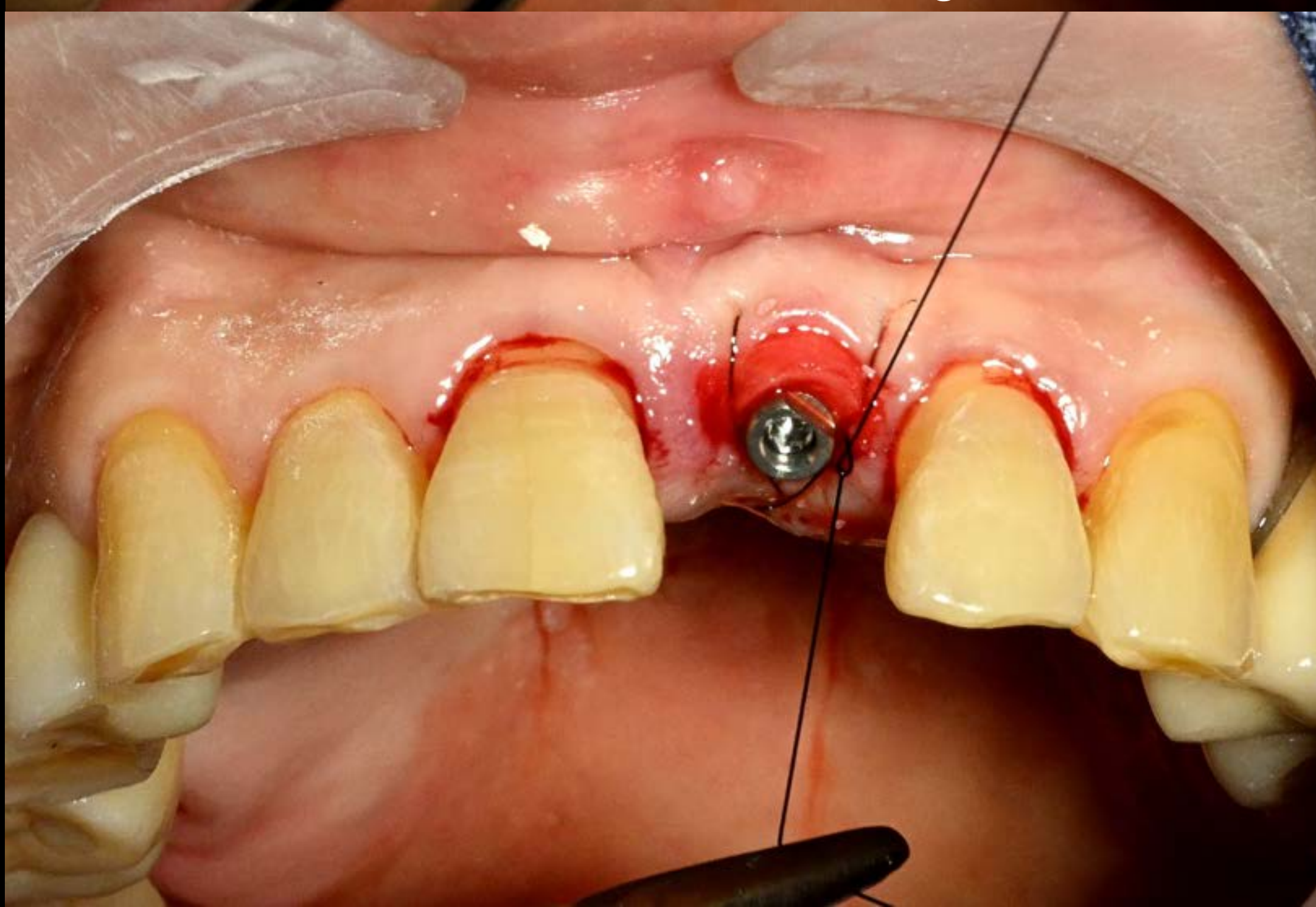
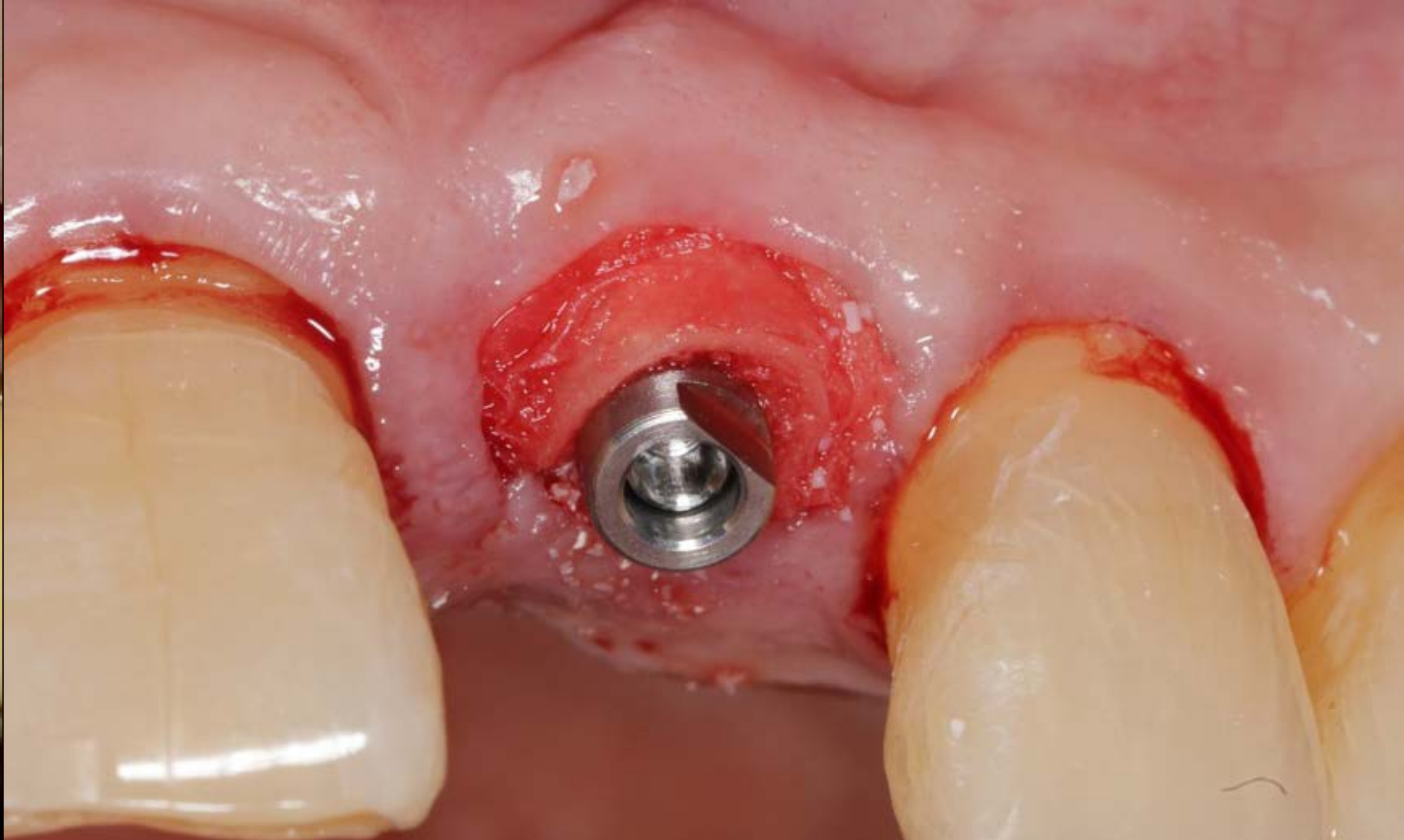

Particle size: 0.2-1.0mm

Surgery (2025-07-16)

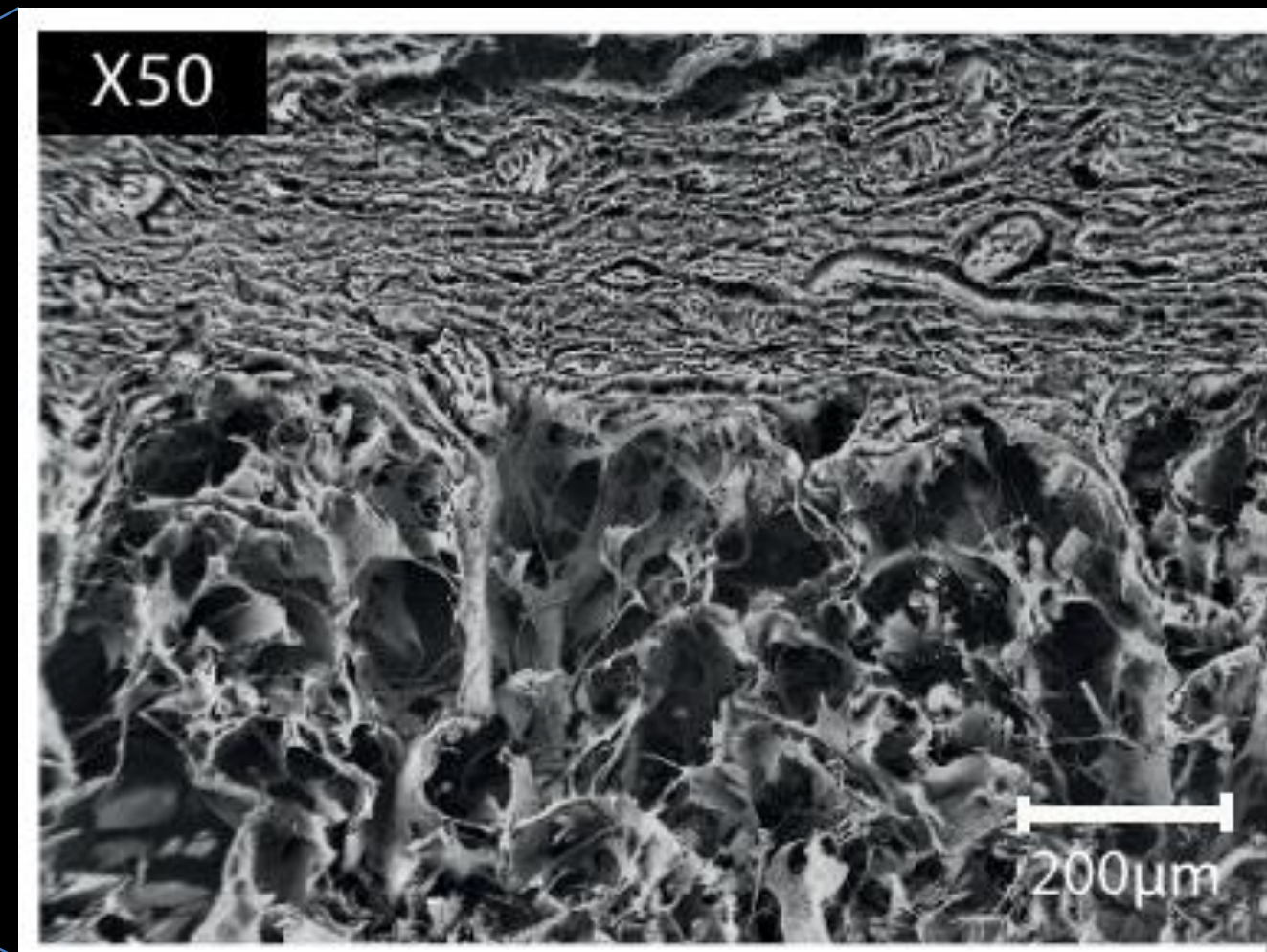




Collagen Graft x1D



Collagen Graft **x1D**

- **Absorbable Matrix**
- Highly pure Type I Collagen (from porcine tendon)
- **Bilayer structure: Dense & porous layers**
- **Fast soft tissue healing** by epithelialization
(absorbed within 1 months)
- Applications: Ridge Preservation, Keratinized tissue augmentation, Root coverage, FGG alternative, etc.




Top
(Dense)

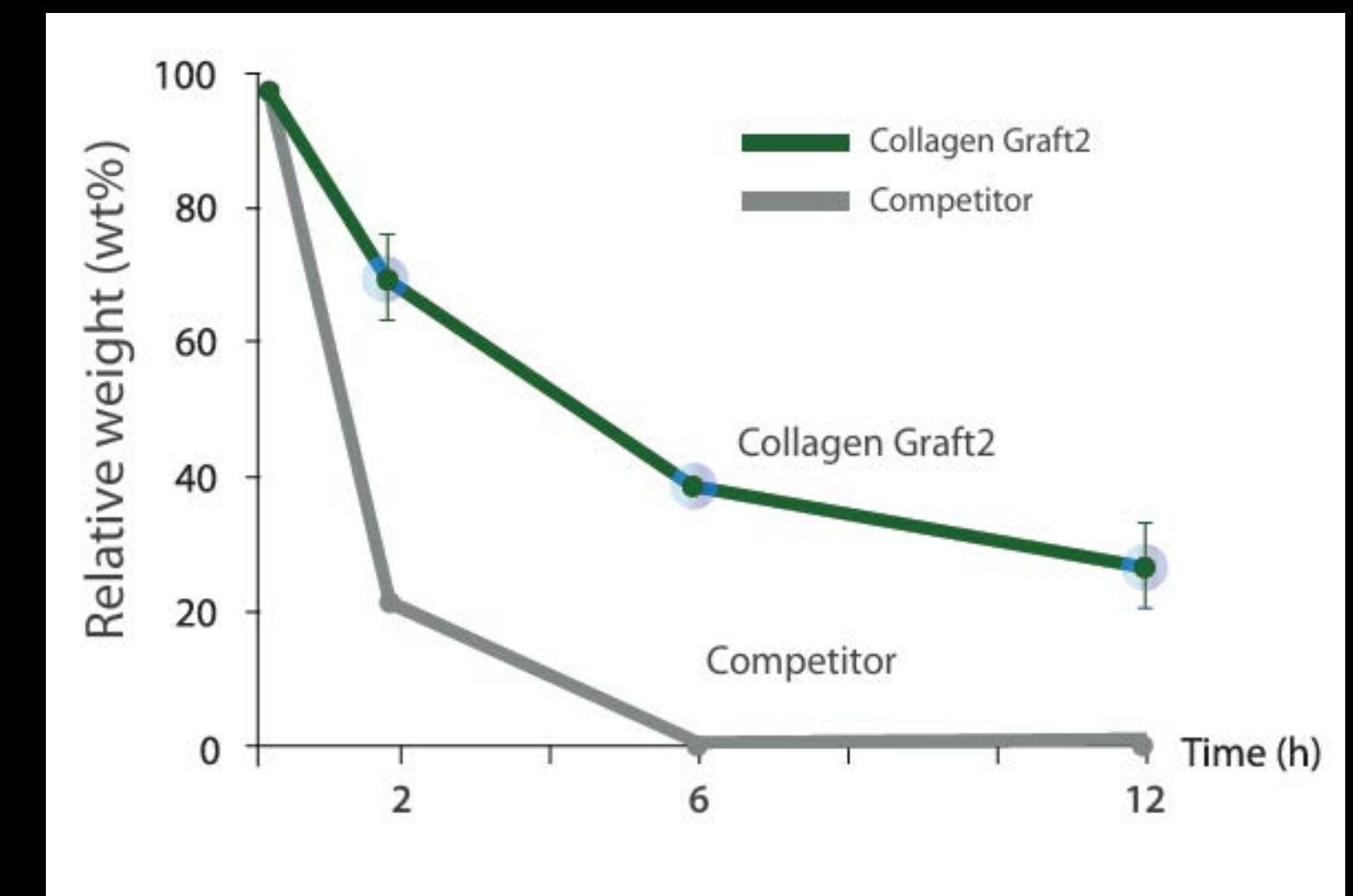
Bottom
(Porous)

Soft tissue substitute: Collagen graft

- ✓ Absorbable Matrix
- ✓ Highly pure Type I Collagen (from porcine tendon)
- ✓ Bilayer structure: Dense & porous layers
- ✓ Fast soft tissue healing by epithelization (absorbed within 1 months)
- ✓ Applications: Ridge Preservation, Keratinized tissue augmentation, Root coverage, FGJ alternative, etc.



Microstructure

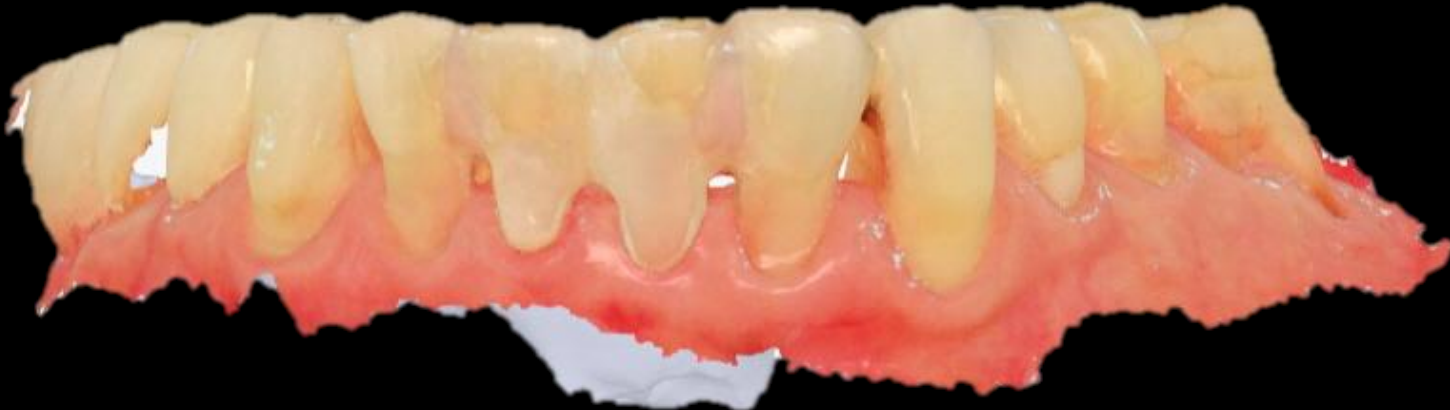
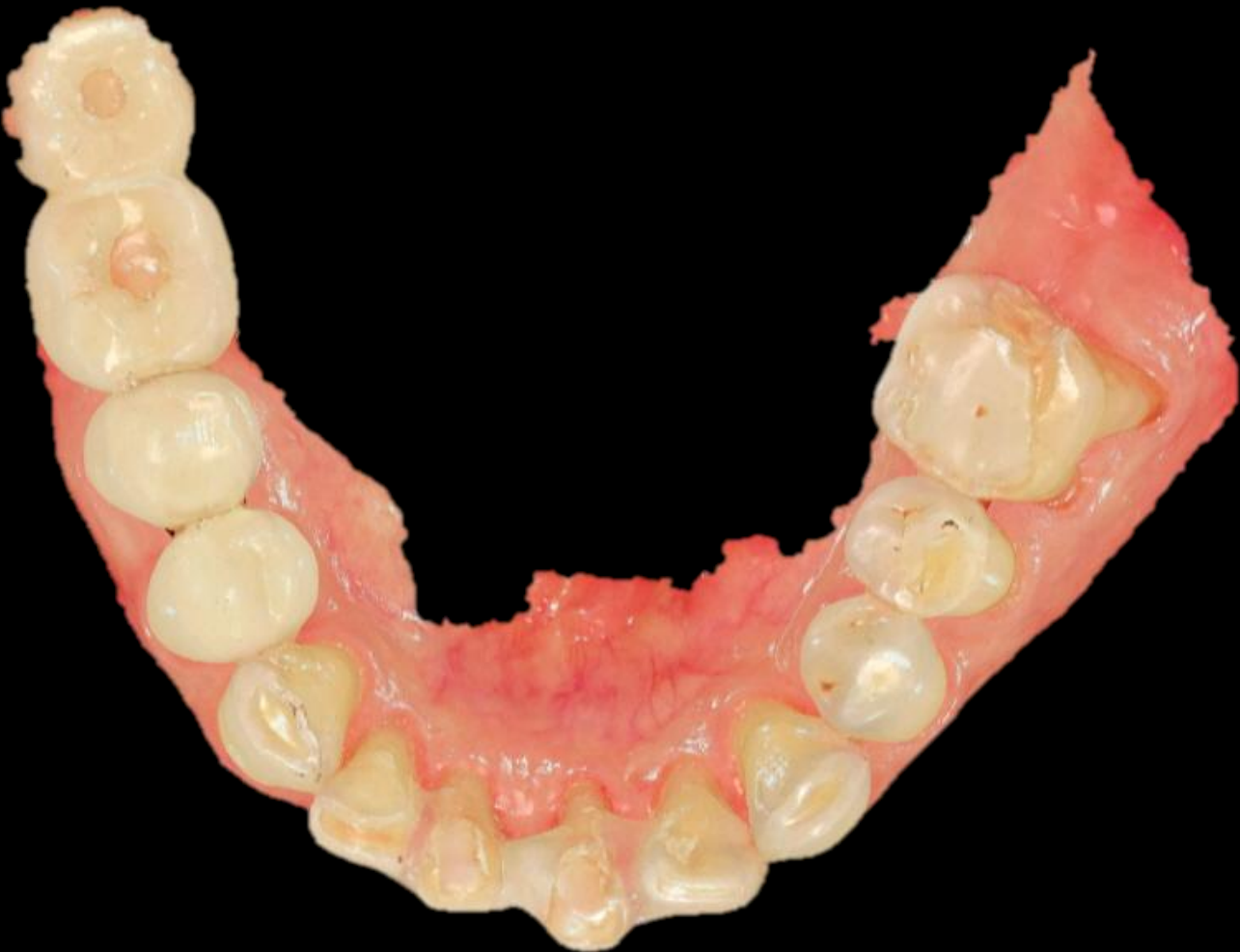
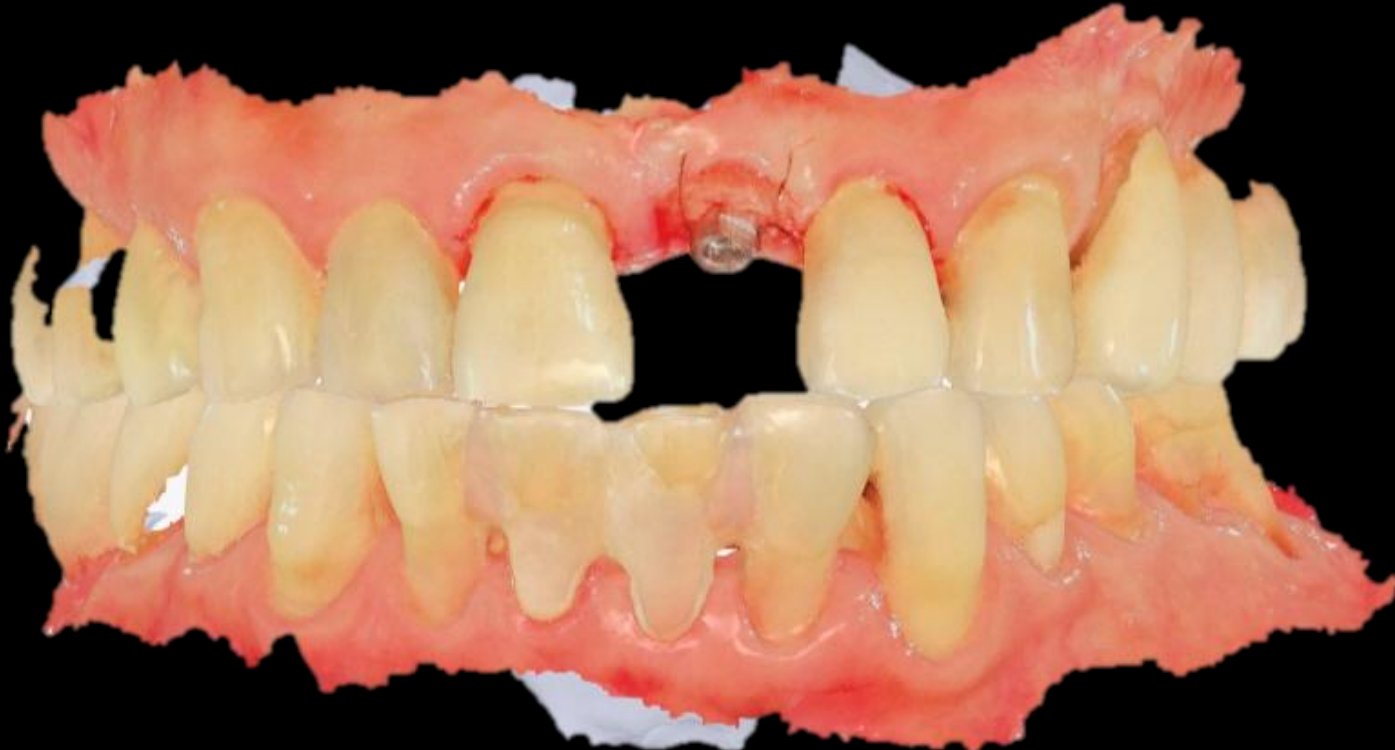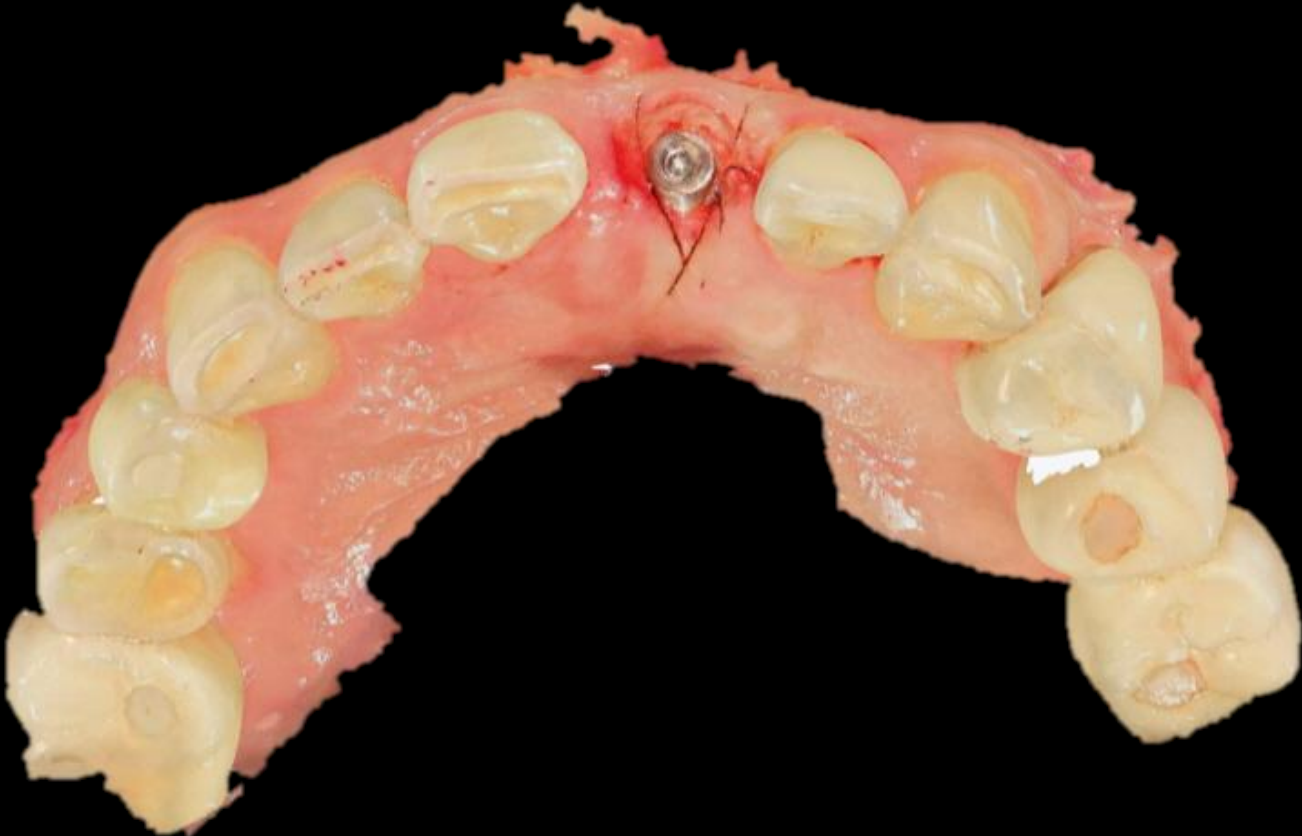In vitro Degradation

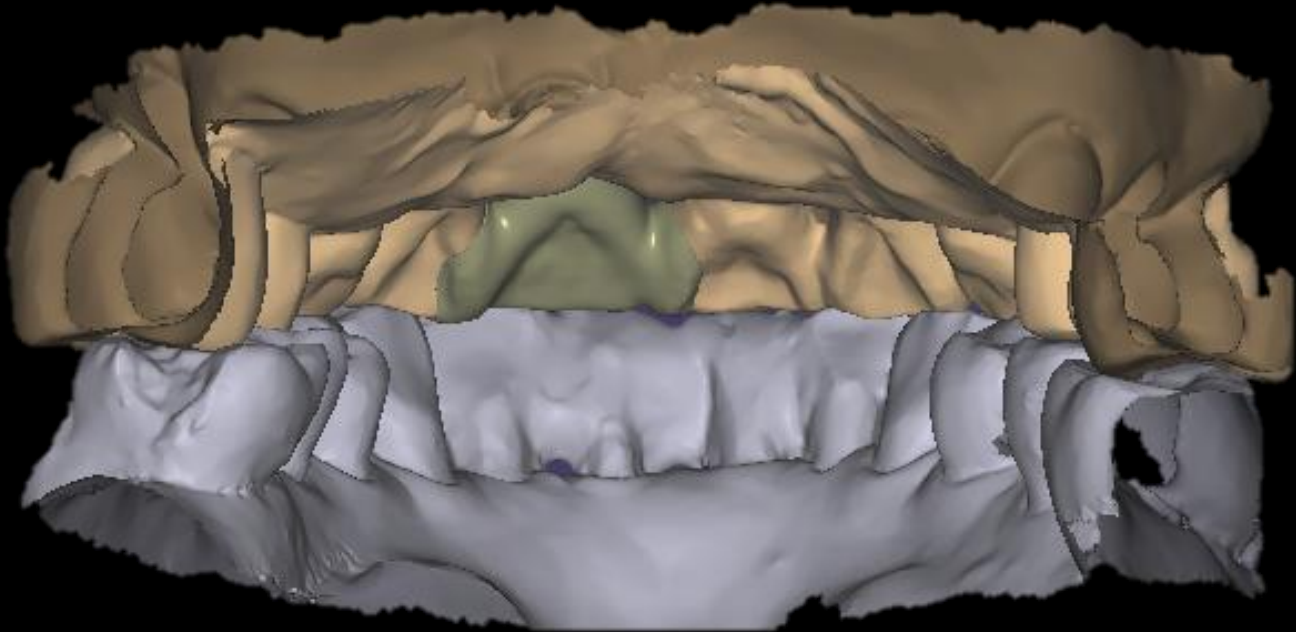
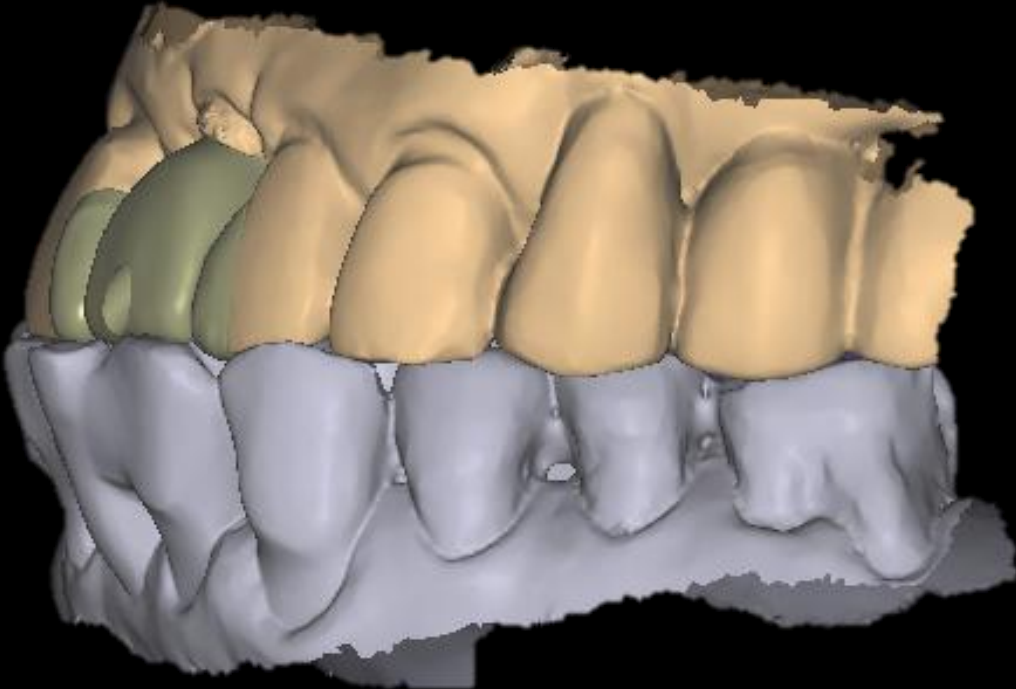
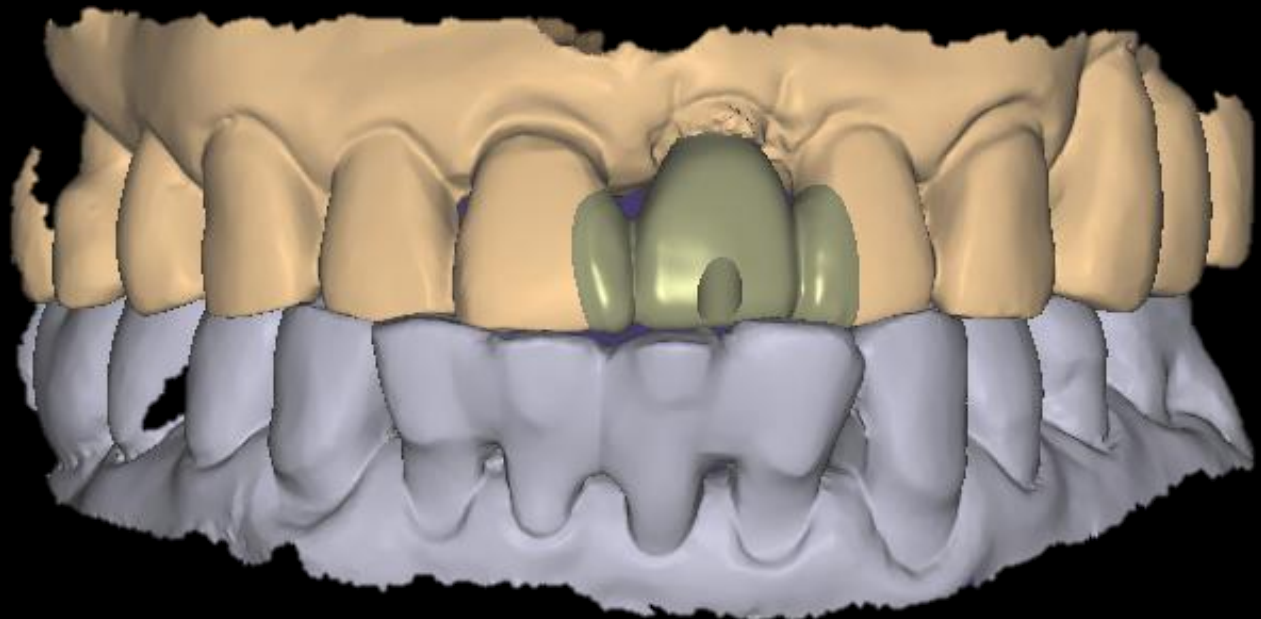
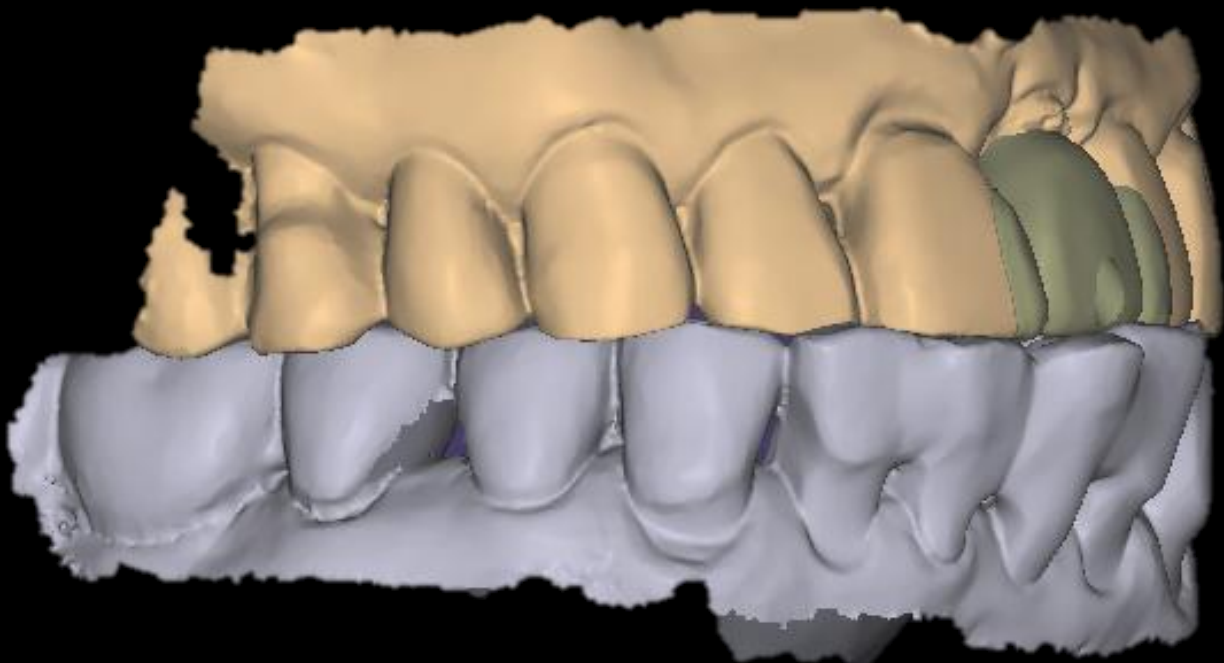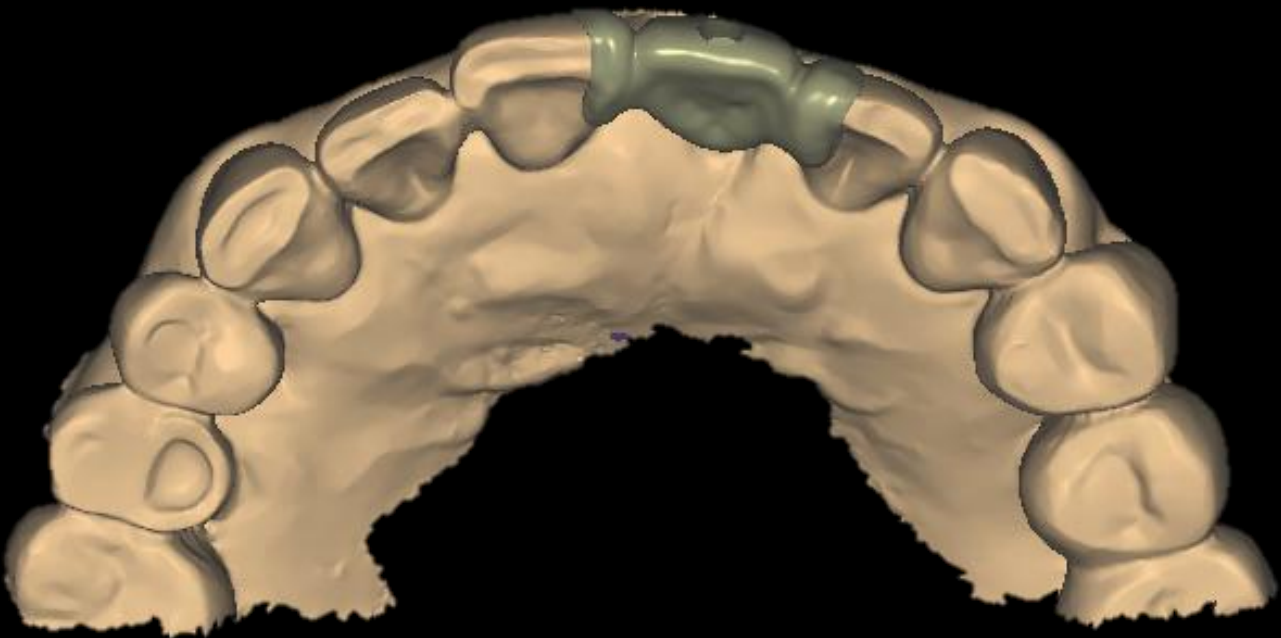
Gap filling between fixture and labial bone is with bone graft

Between healing abutment and labial gingiva is with collagen graft

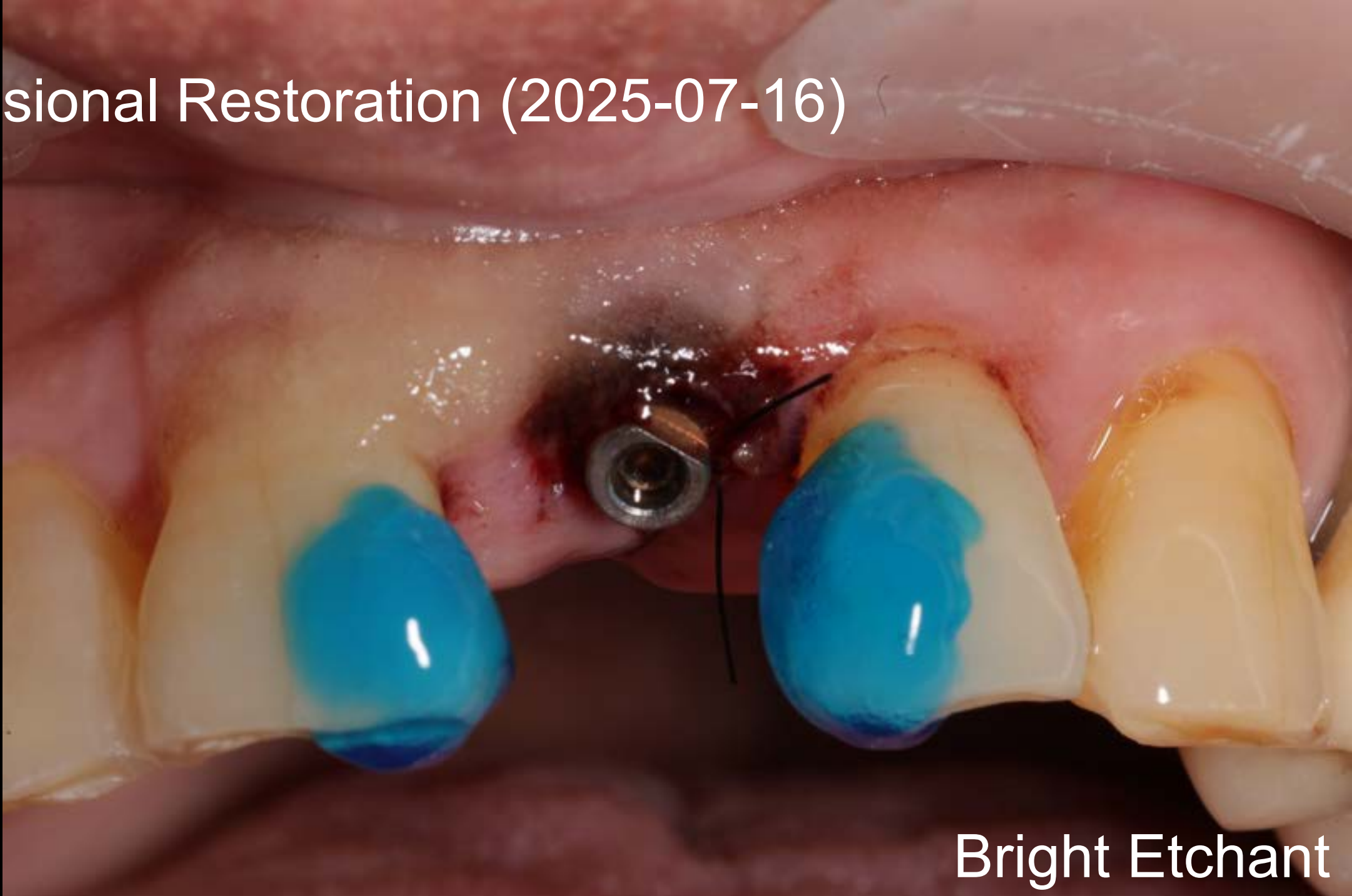
Intra Oral Scan



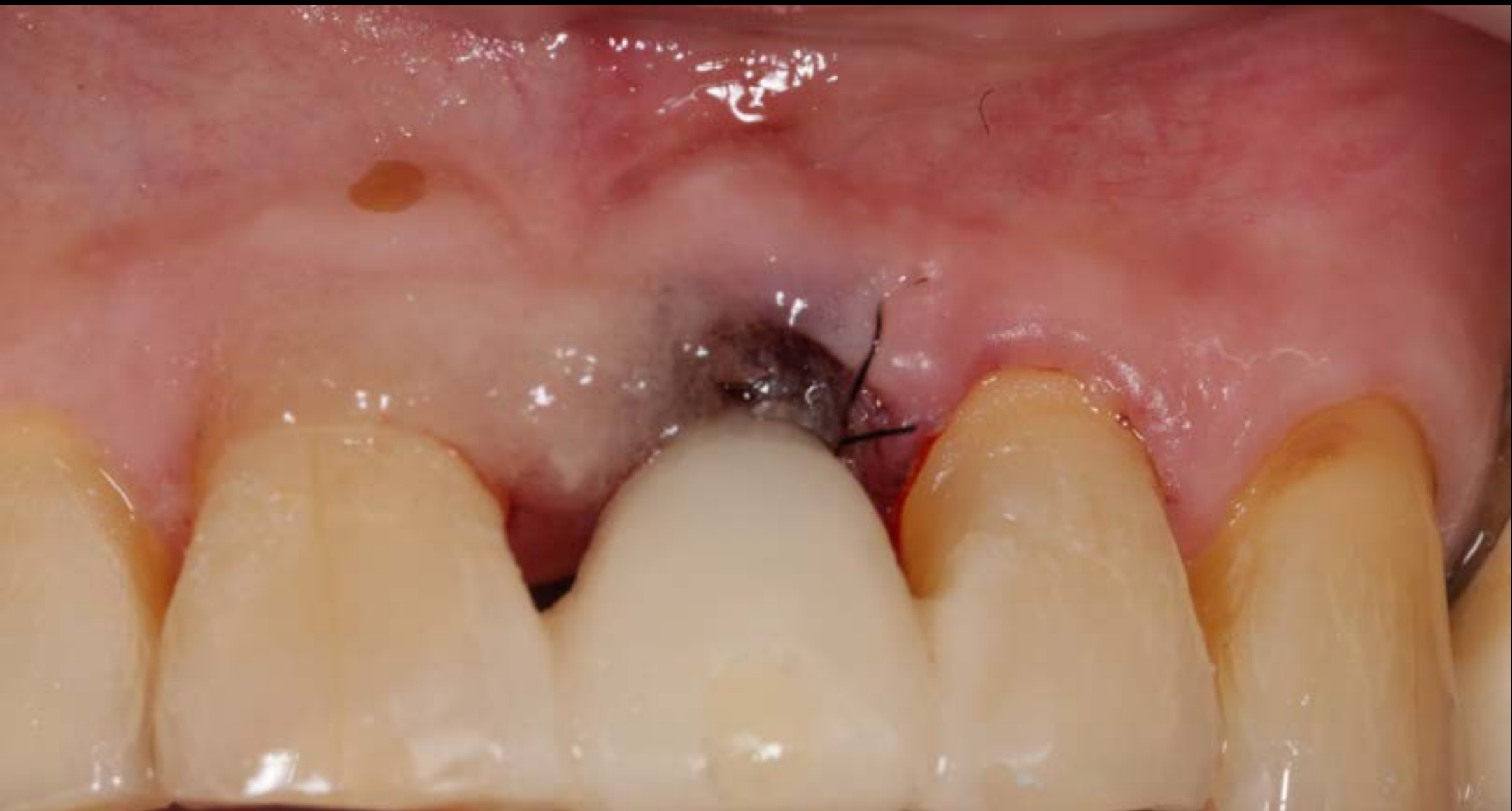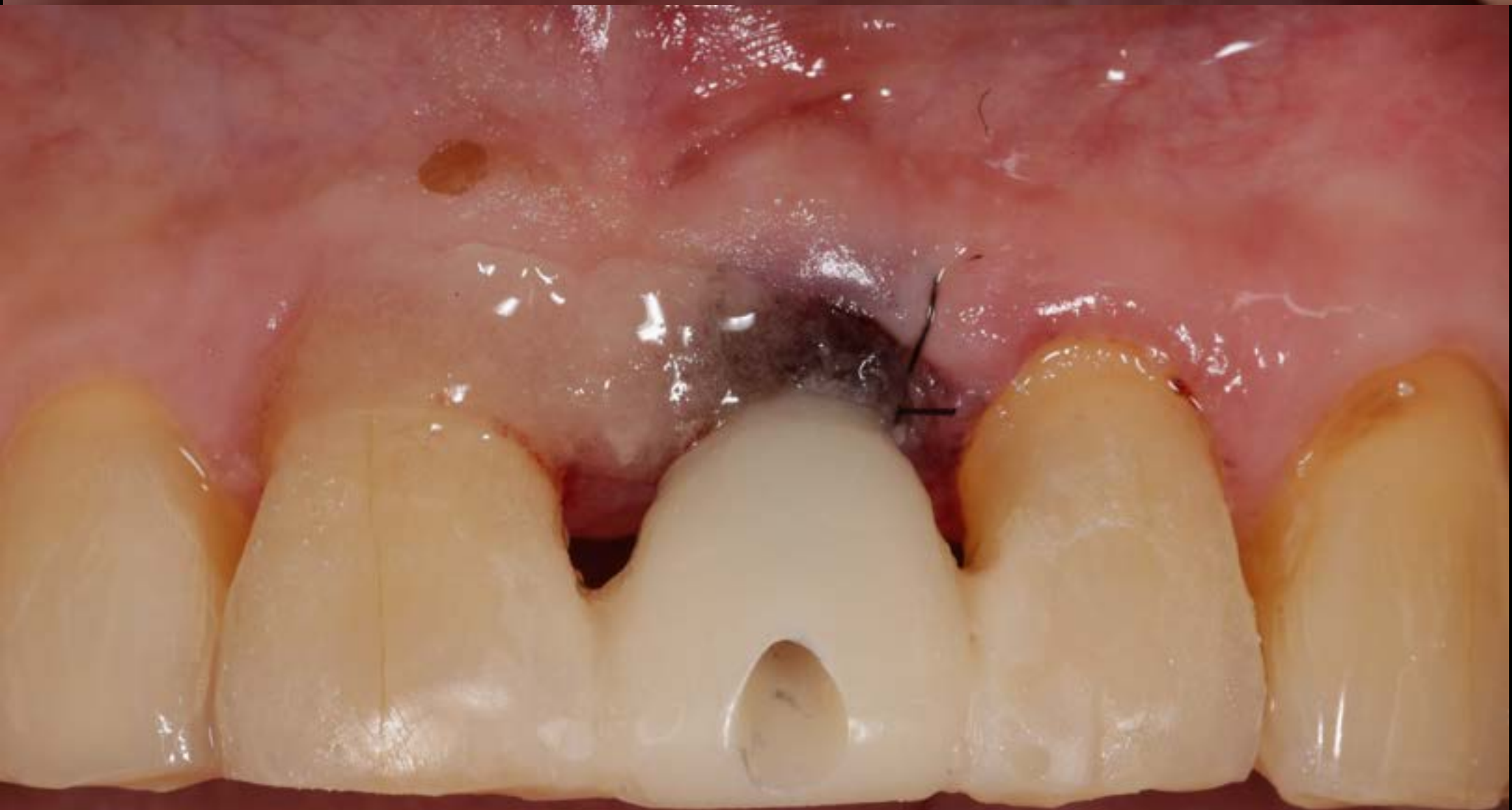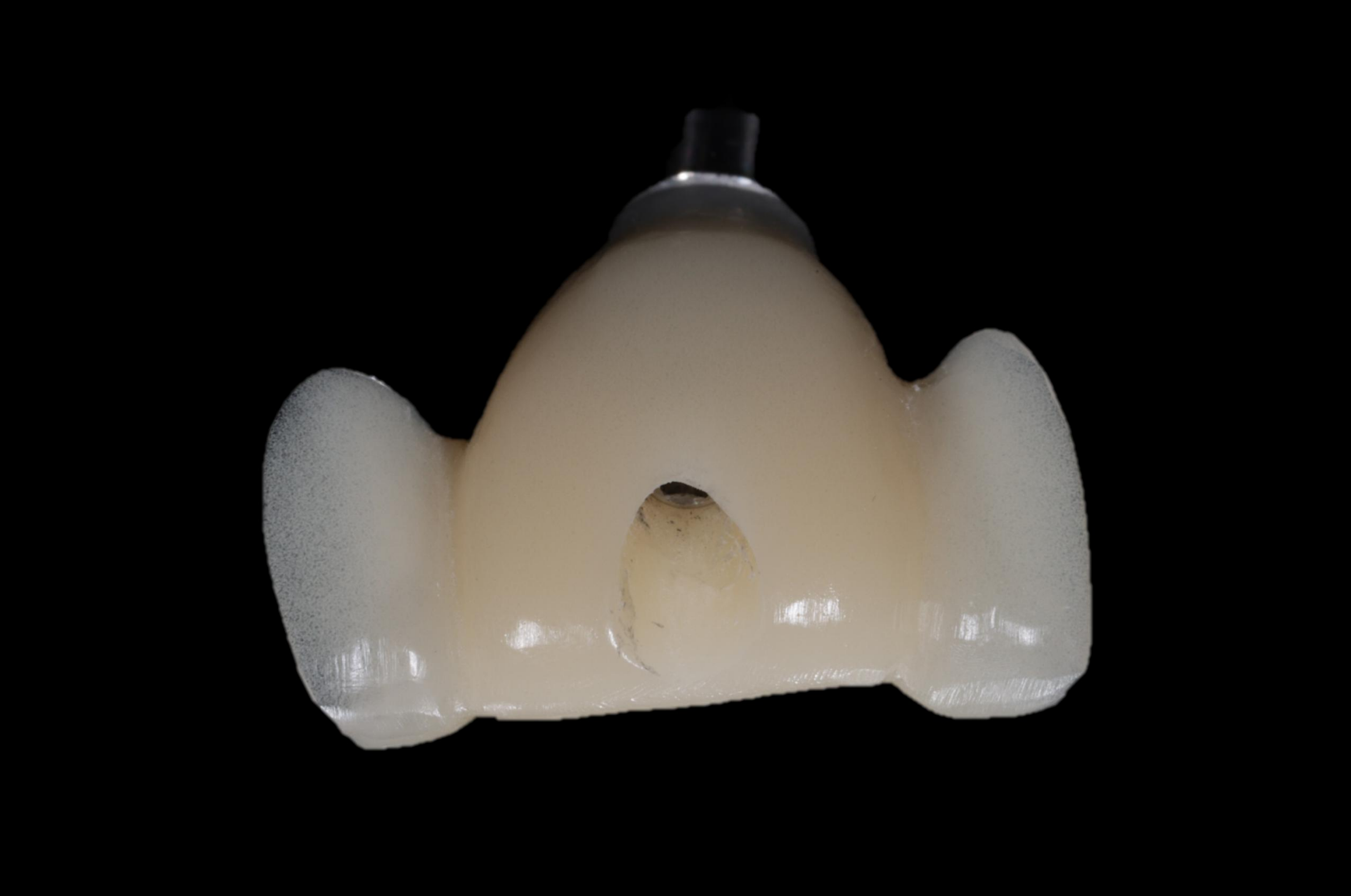CAD (Temporary)



Provisional Restoration (2025-07-16)



Bright Etchant

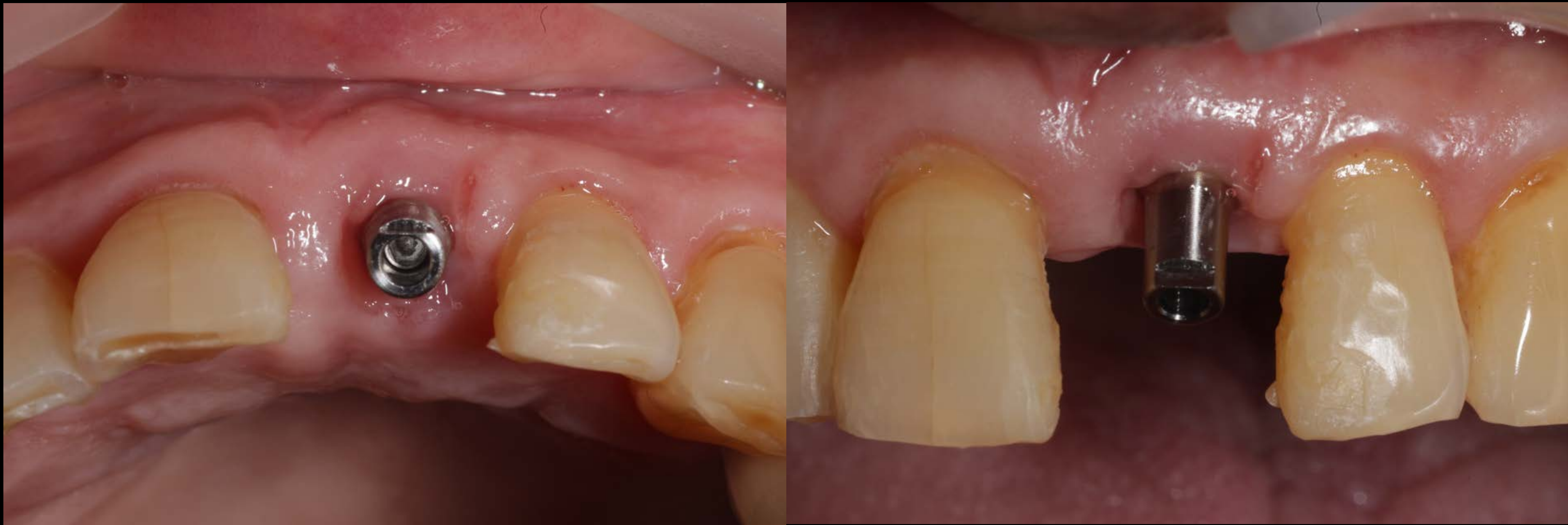

HRF

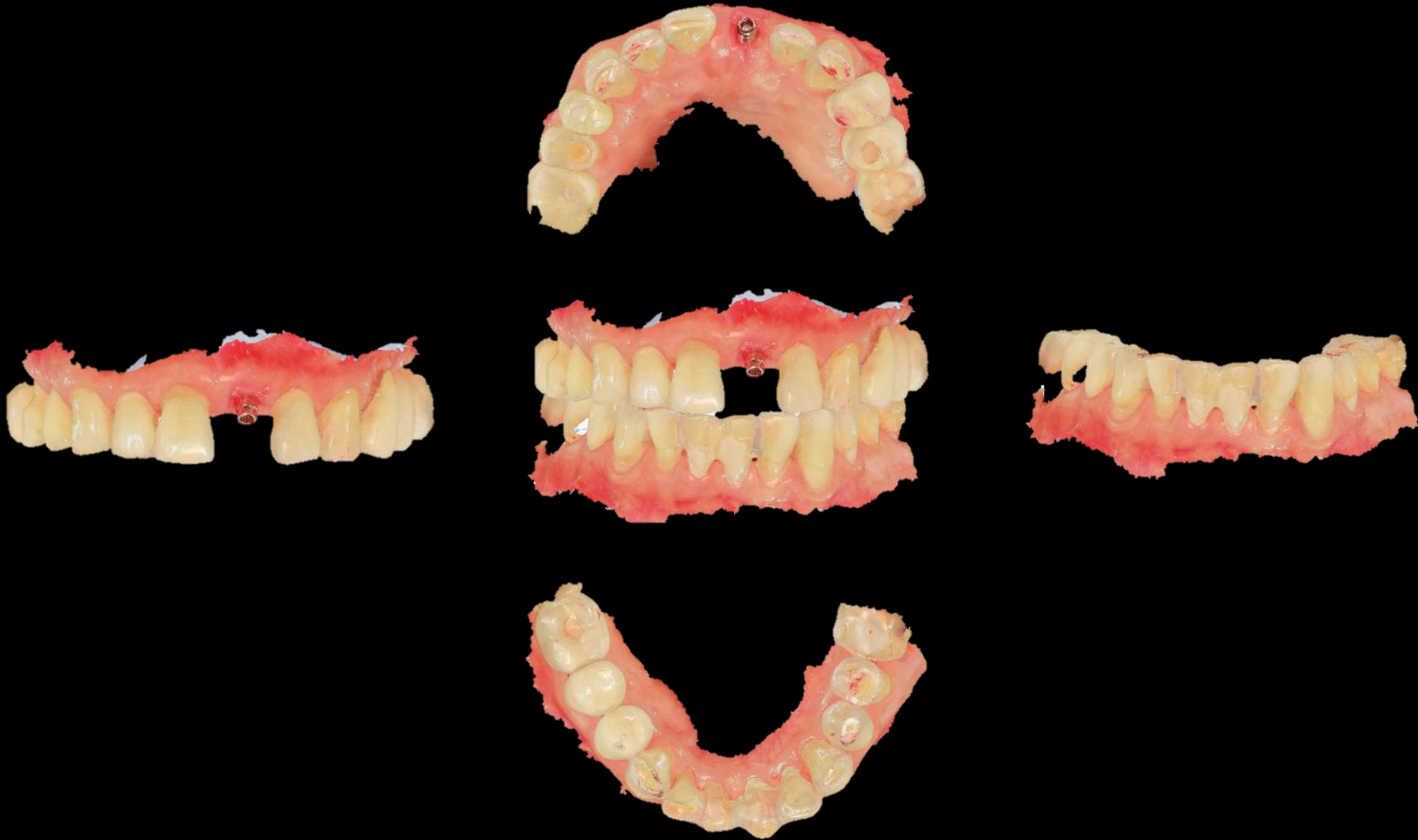
Immediate loading with temporary is required for esthetics

But occlusal force must be spreader with adjacent natural teeth

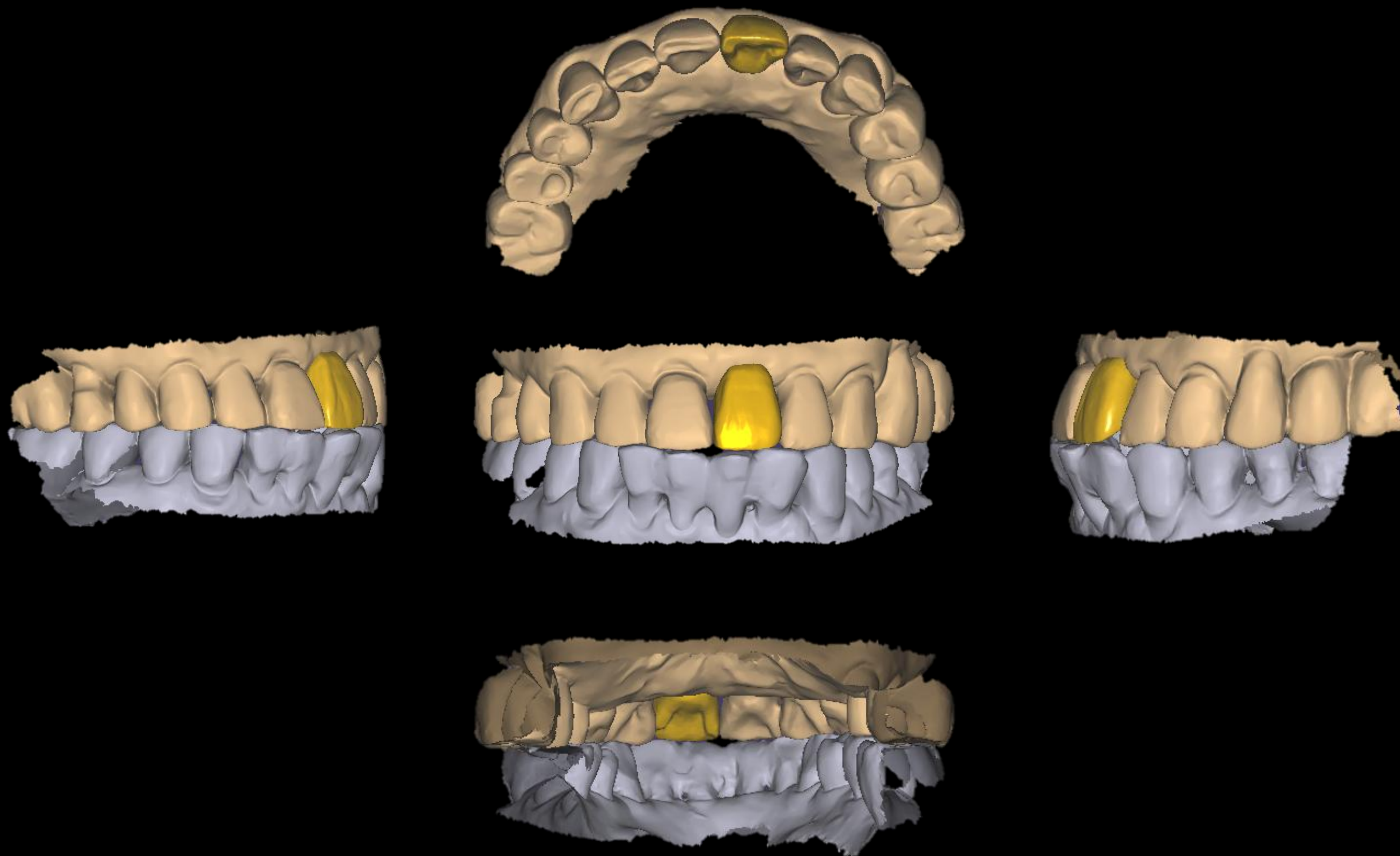
Healing : 1 month (2025-08-13)



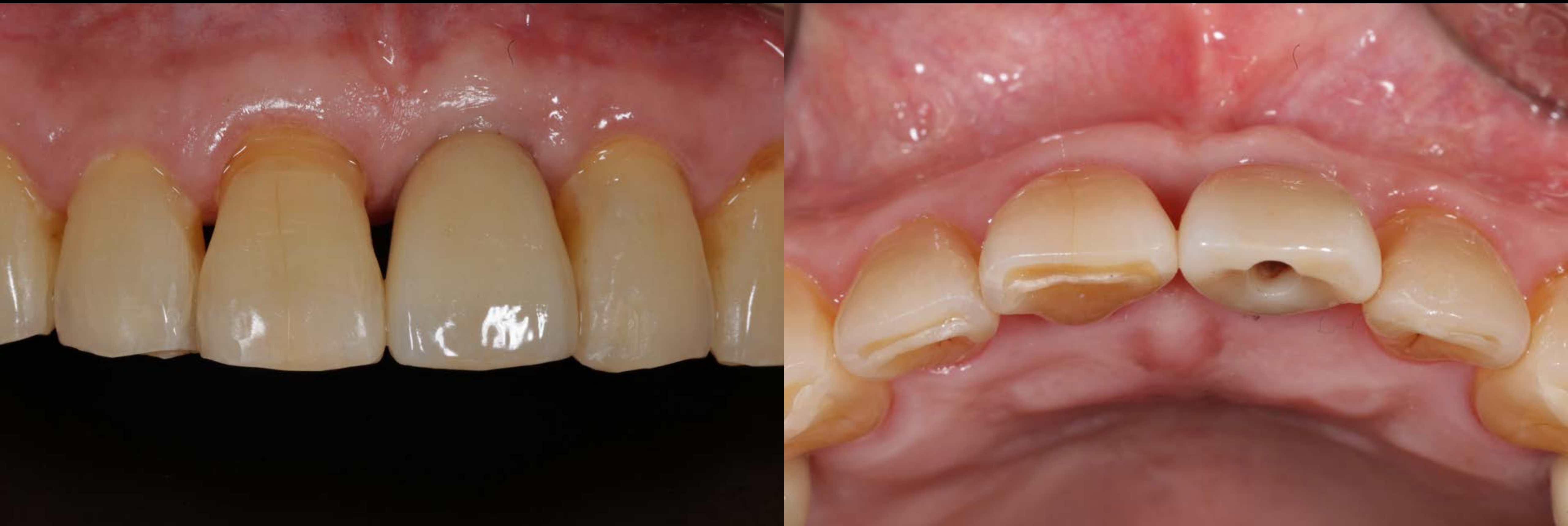Intra Oral Scan



CAD (Final prosthesis)



Final prosthesis (2025-09-17)



Narrow diameter is very effective in ant thin bone

After healing, very simple contour augmentation

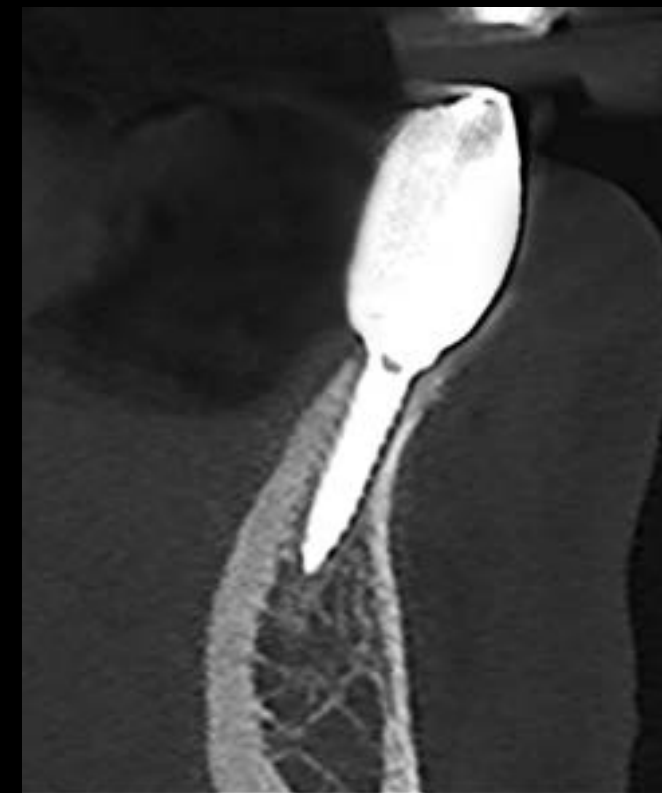

- highly sintered bone is good for labial augmentation to reduce resorption

Thin labial bone to fixture can be maintained thin fixture

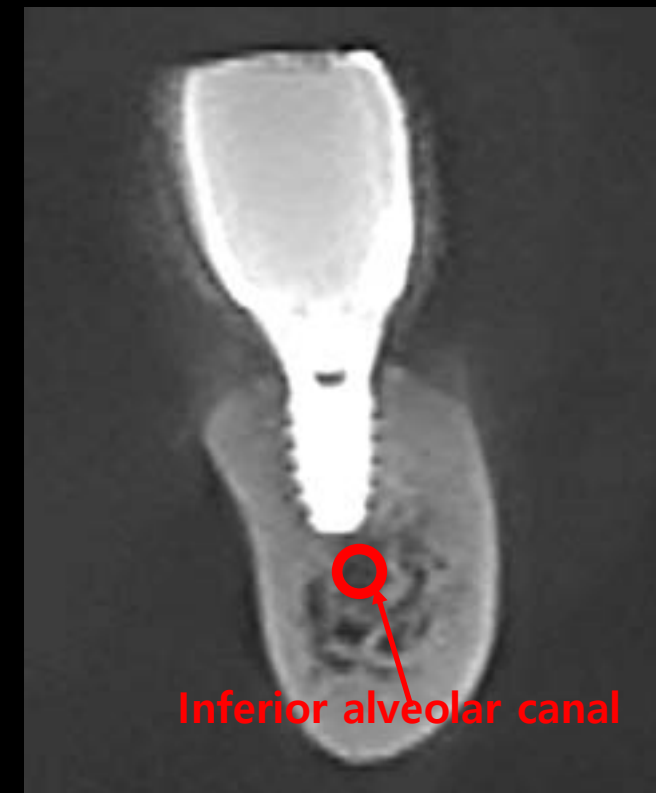
- **the ideal labial bone** from fixture is different with fixture diameter

ex) **over 4mm - 2mm, 3.5mm - 1.5mm, less 3mm - 1mm**

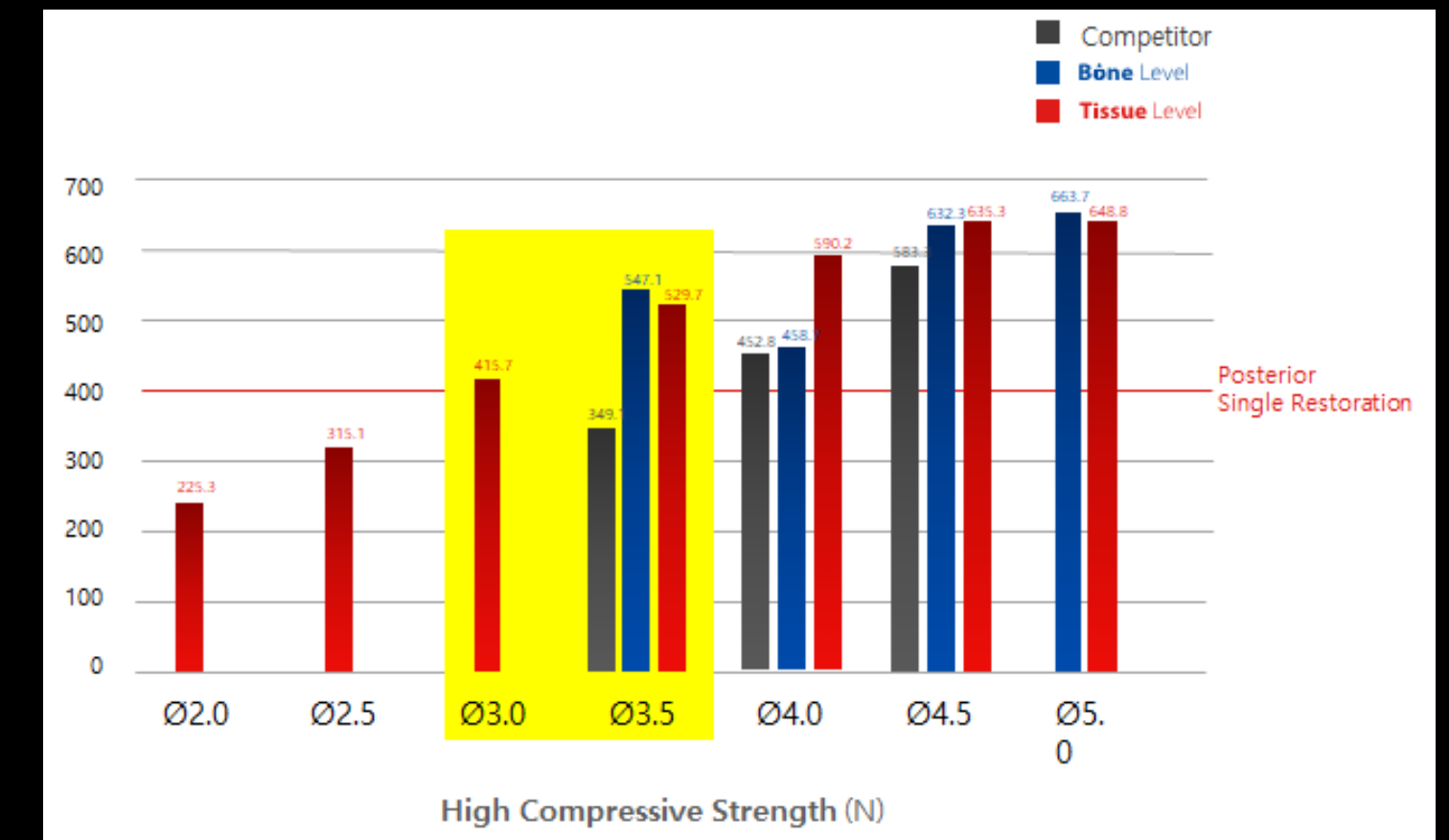
Short and Narrow, but Strong : bright Implant



#42 (bright TL 2.5 X 11.0)



#47 (bright TL 4.0 X 7.0)



Advantages of Short & Narrow Implants

✓ Applicable in limited bone conditions

Can be placed in areas with reduced bone height or width without the need for extensive grafting.

✓ Minimally invasive surgery

Requires less drilling in both depth and diameter, resulting in simpler procedures, less bleeding, reduced discomfort, and faster healing.

✓ Avoidance of anatomical structures

Allows safe placement near critical areas such as the maxillary sinus or the mandibular nerve.

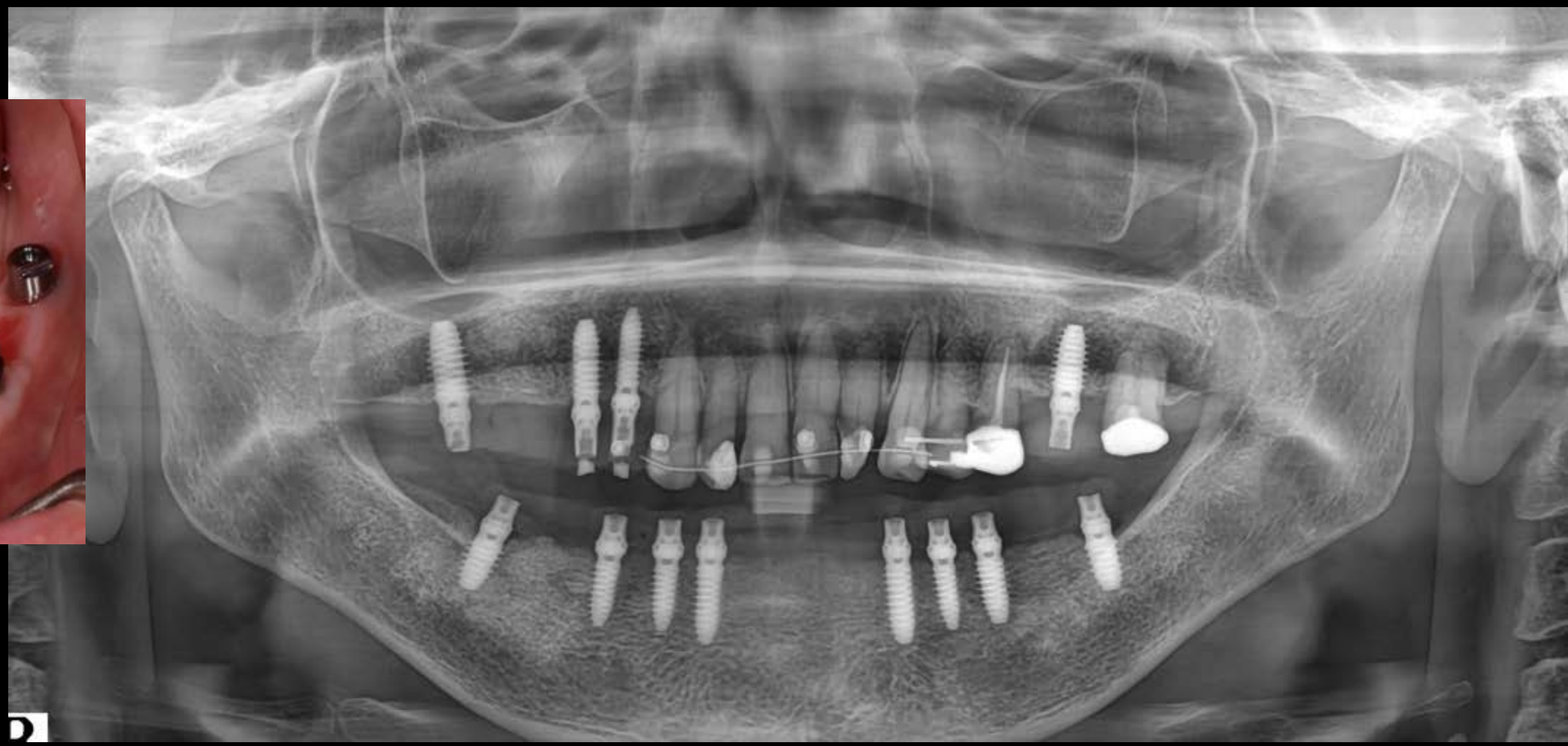
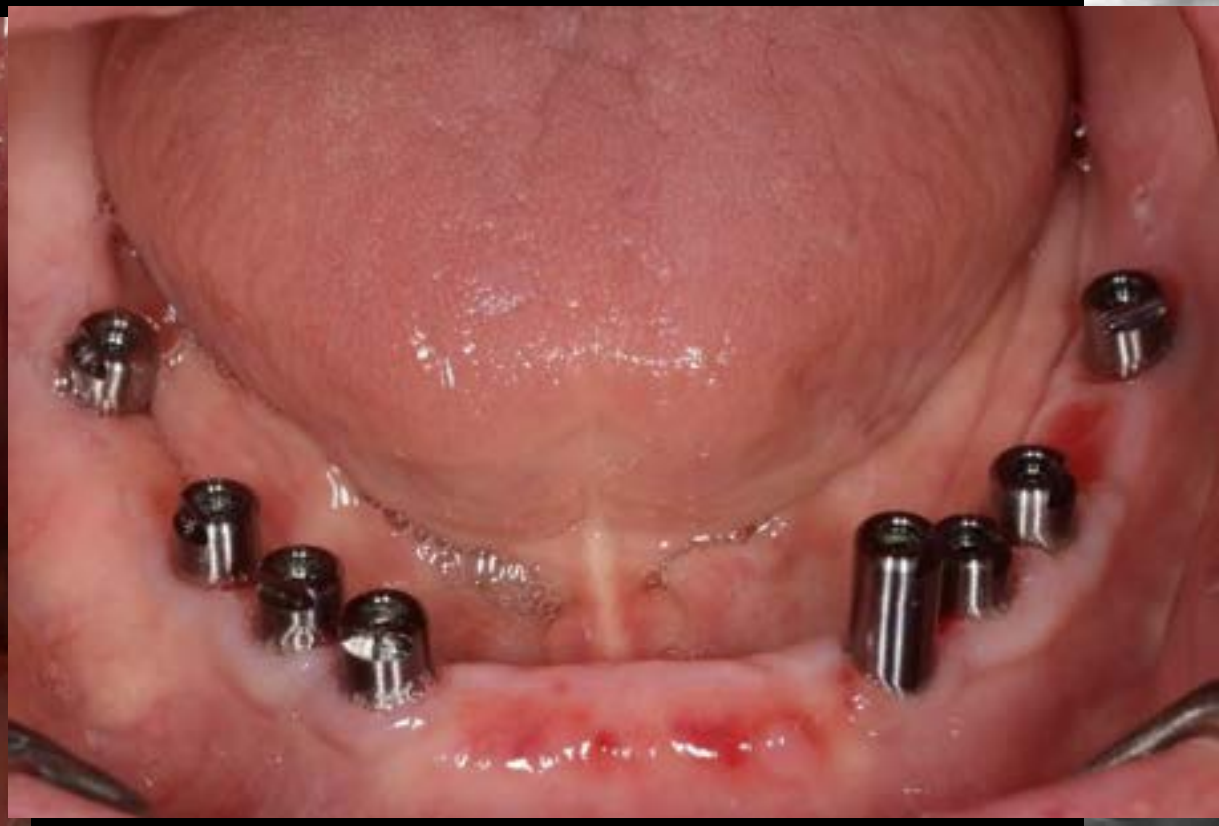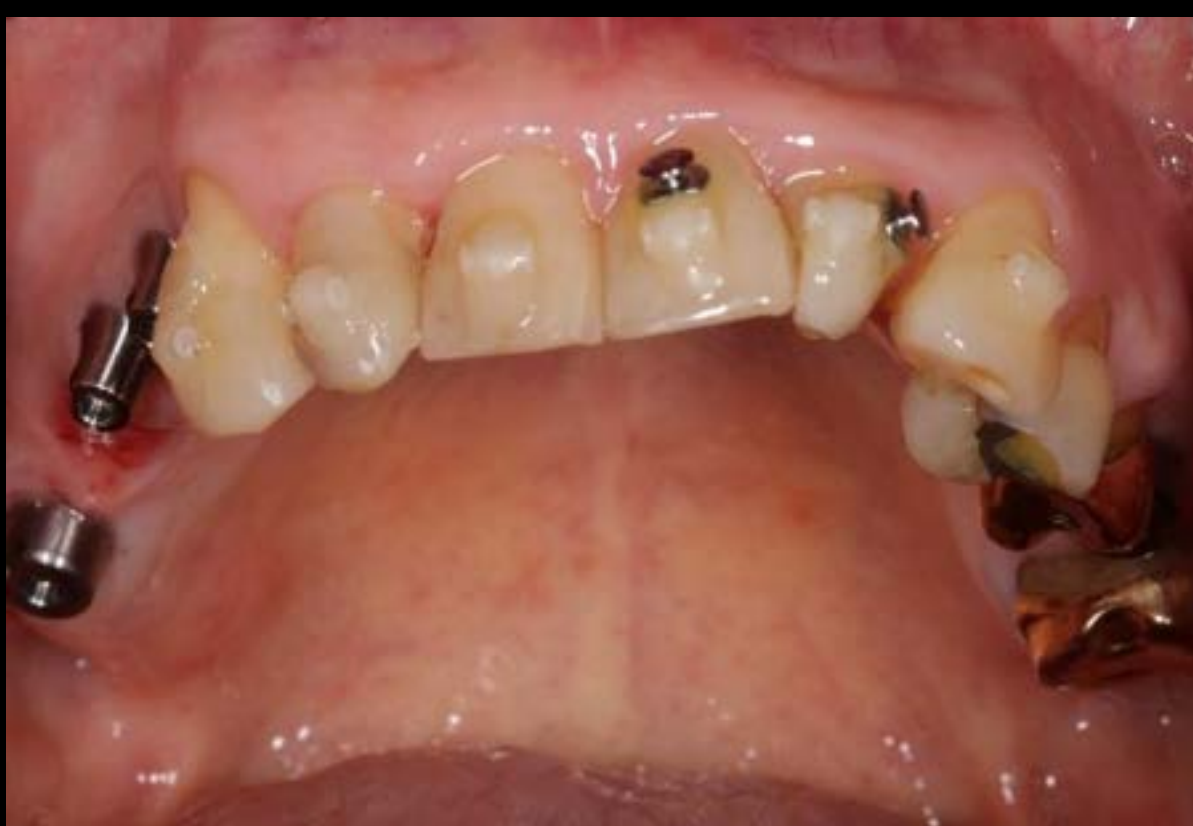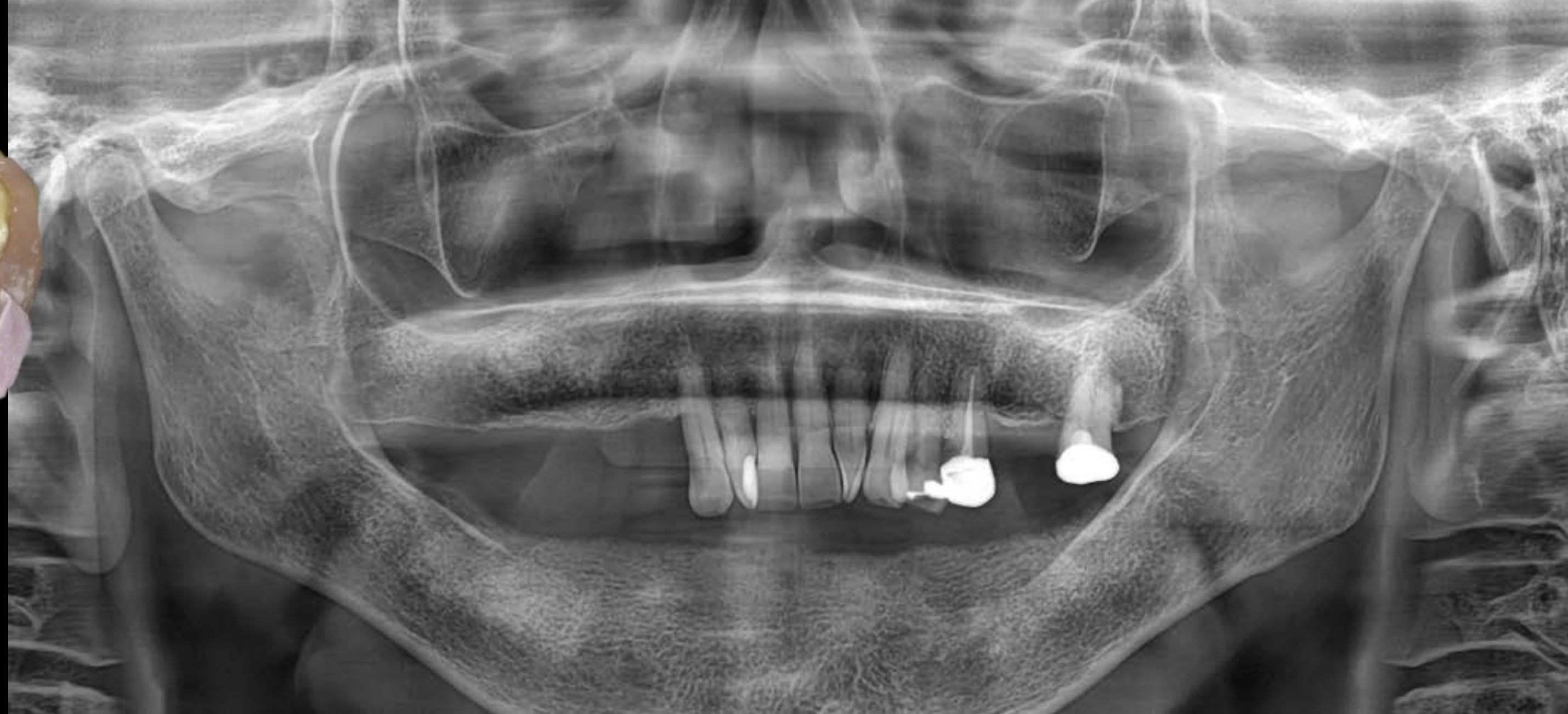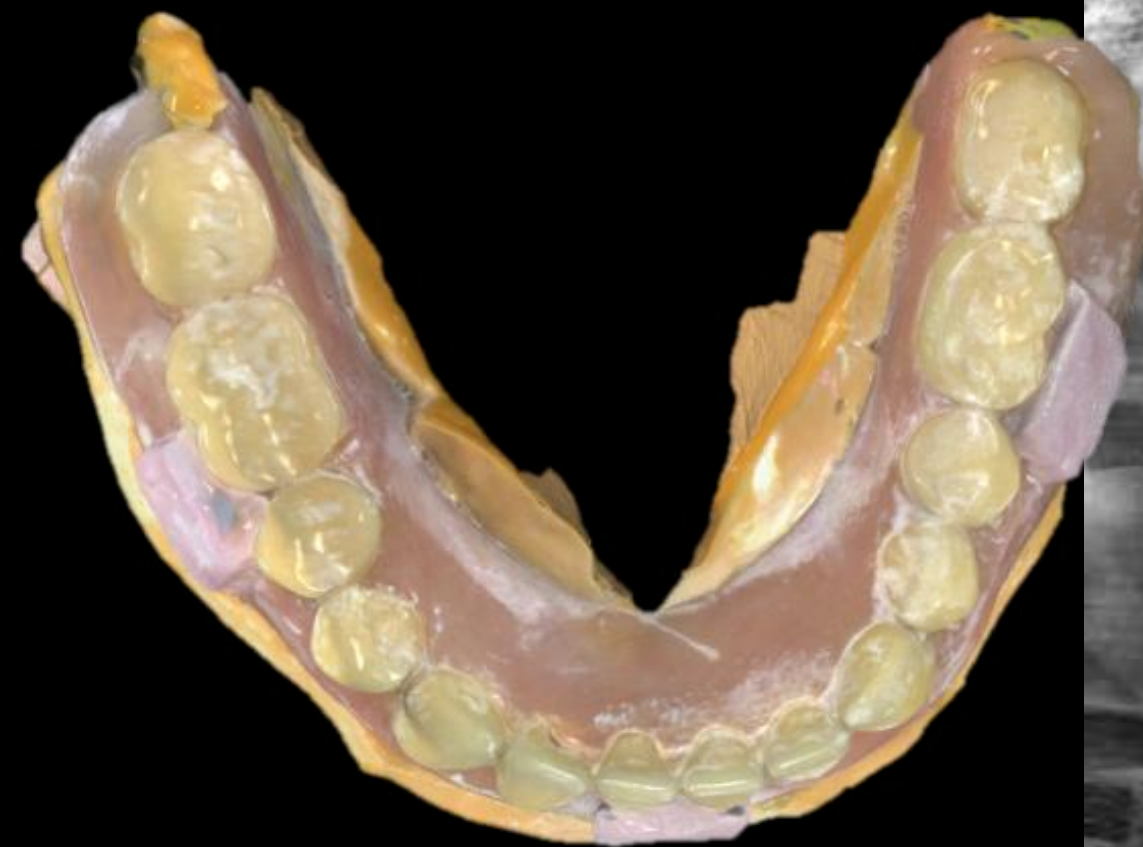
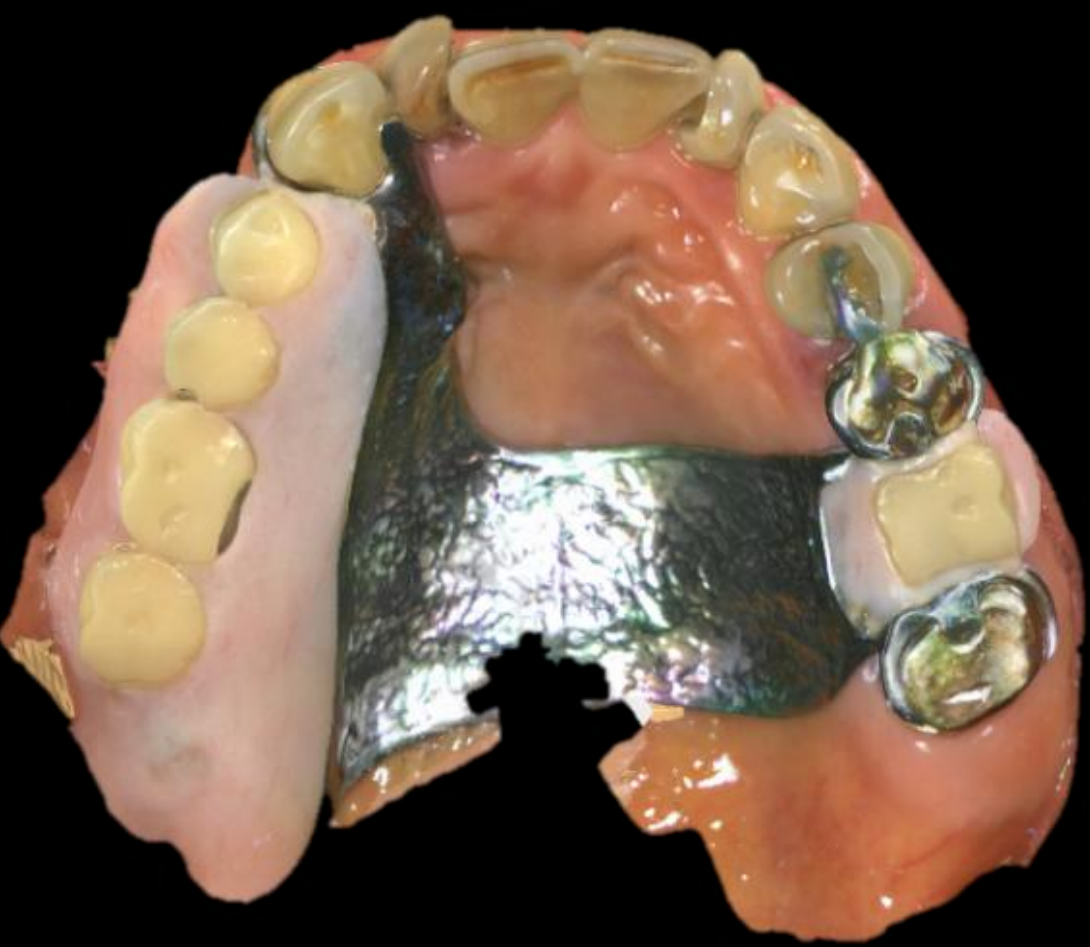✓ Preservation of surrounding bone and soft tissue

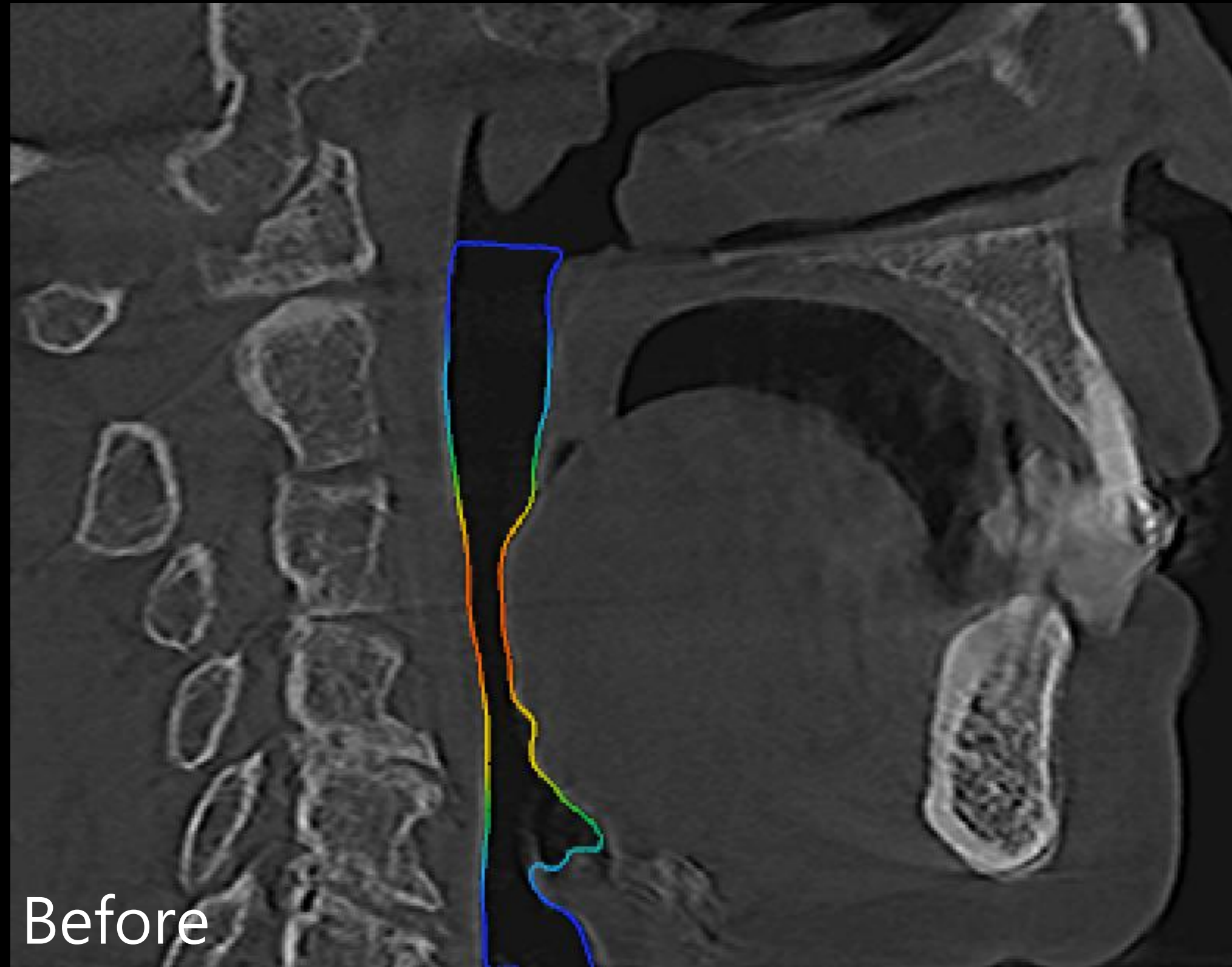Maintains more of the natural bone and tissue, which supports long-term stability and esthetics.

✓ Enhanced stability through optimized fixture design

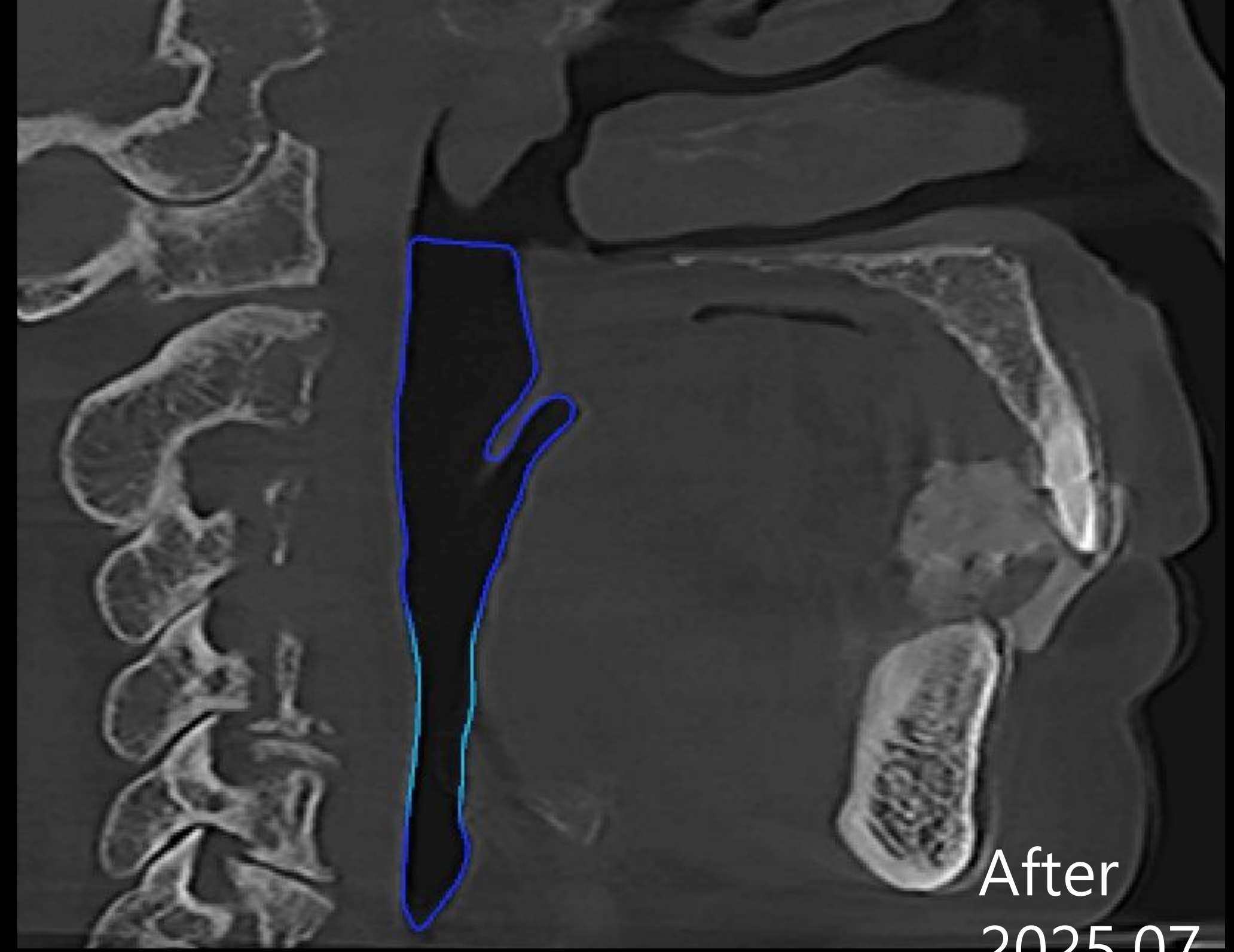
bright TL Implant feature an external connection that provides reliable stability, while bright BL Implant utilize a deep connection for a secure fit.

Both types share double and aggressive threads, long cutting edges, and a dome-shaped body, ensuring strong primary stability and predictable long-term outcomes.

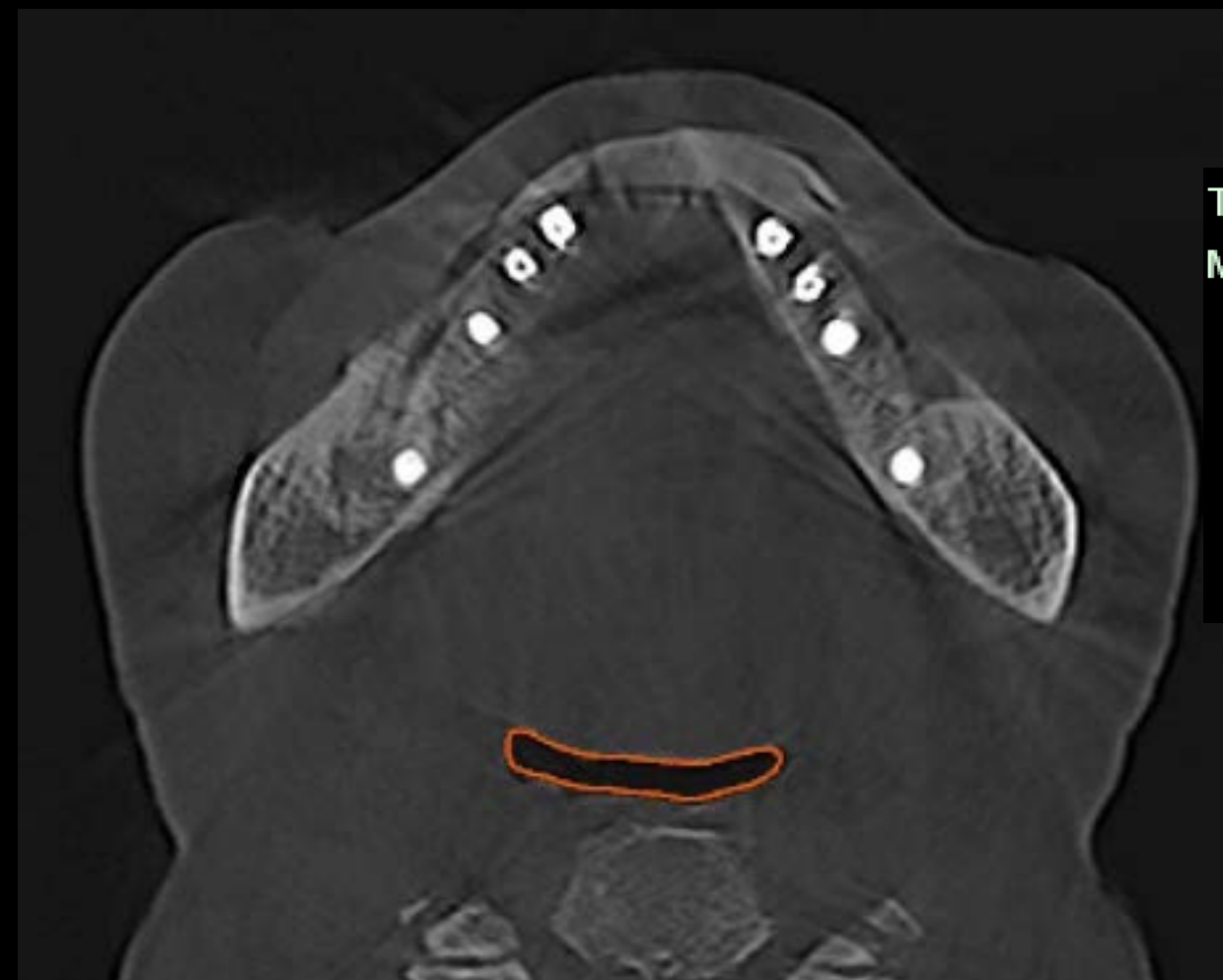



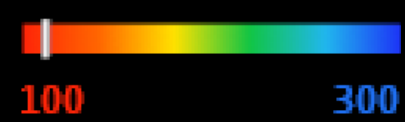Before
2024.03



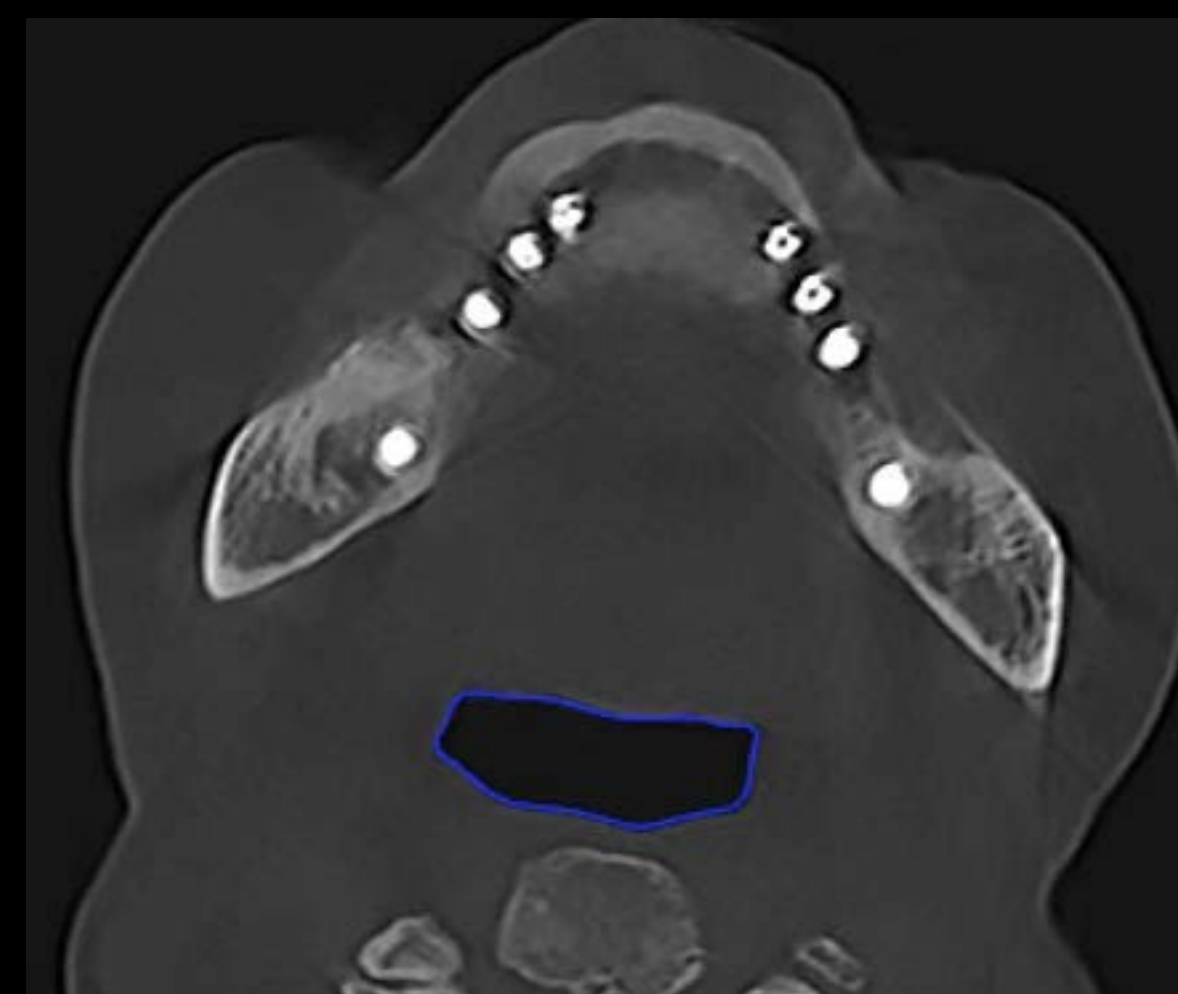
After
2025.07
(VD 3mm)



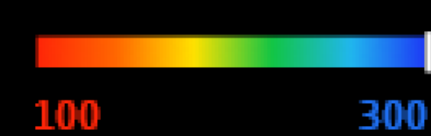
Total Volume : 16.29 cc
Min Area : 109.60 mm2
Area : 111.72 mm2
AP : 7.00 mm
LR : 28.20 mm



111.72

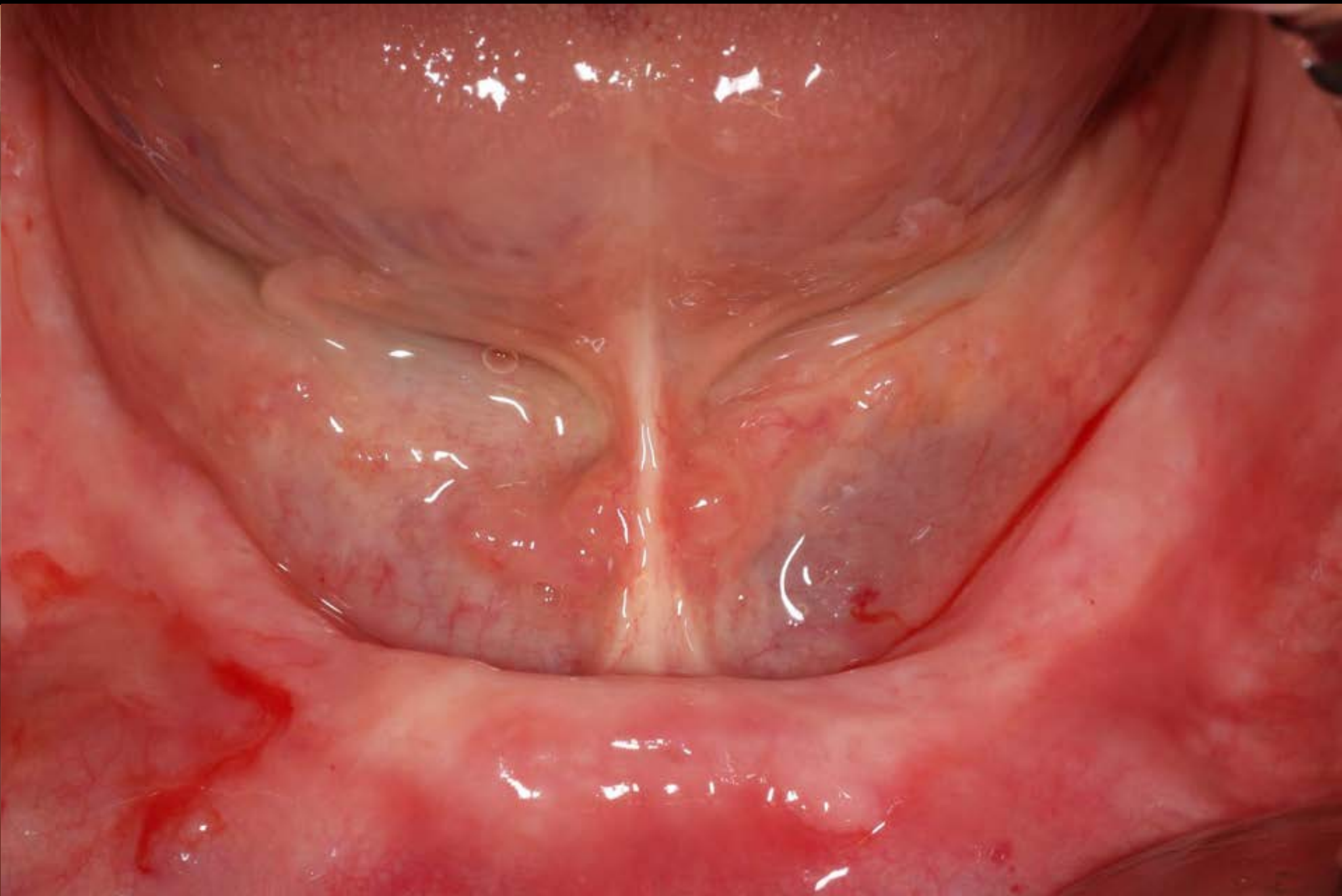
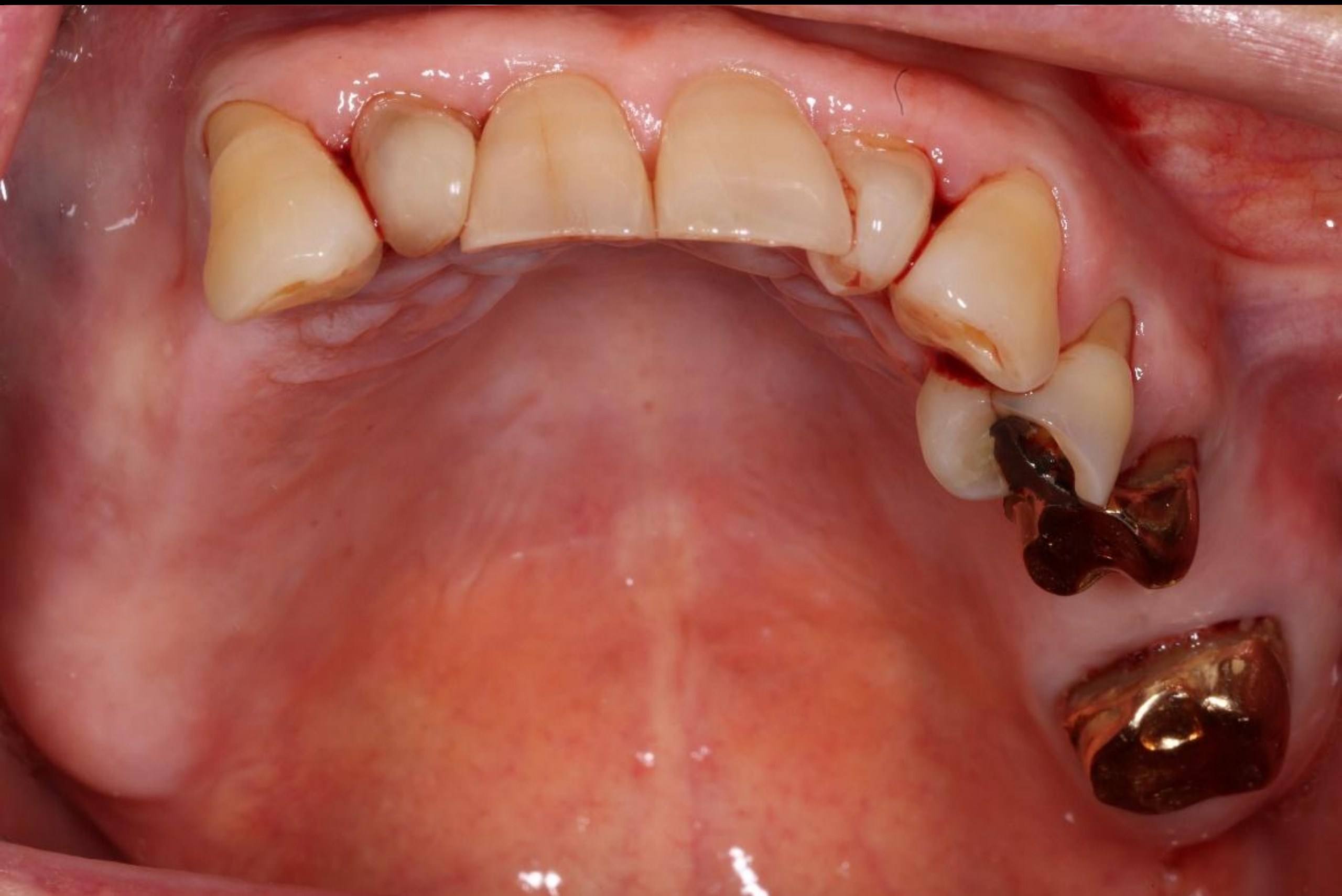
Total Volume : 24.07 cc
Min Area : 240.92 mm2
Area : 330.24 mm2
AP : 13.80 mm
LR : 32.60 mm

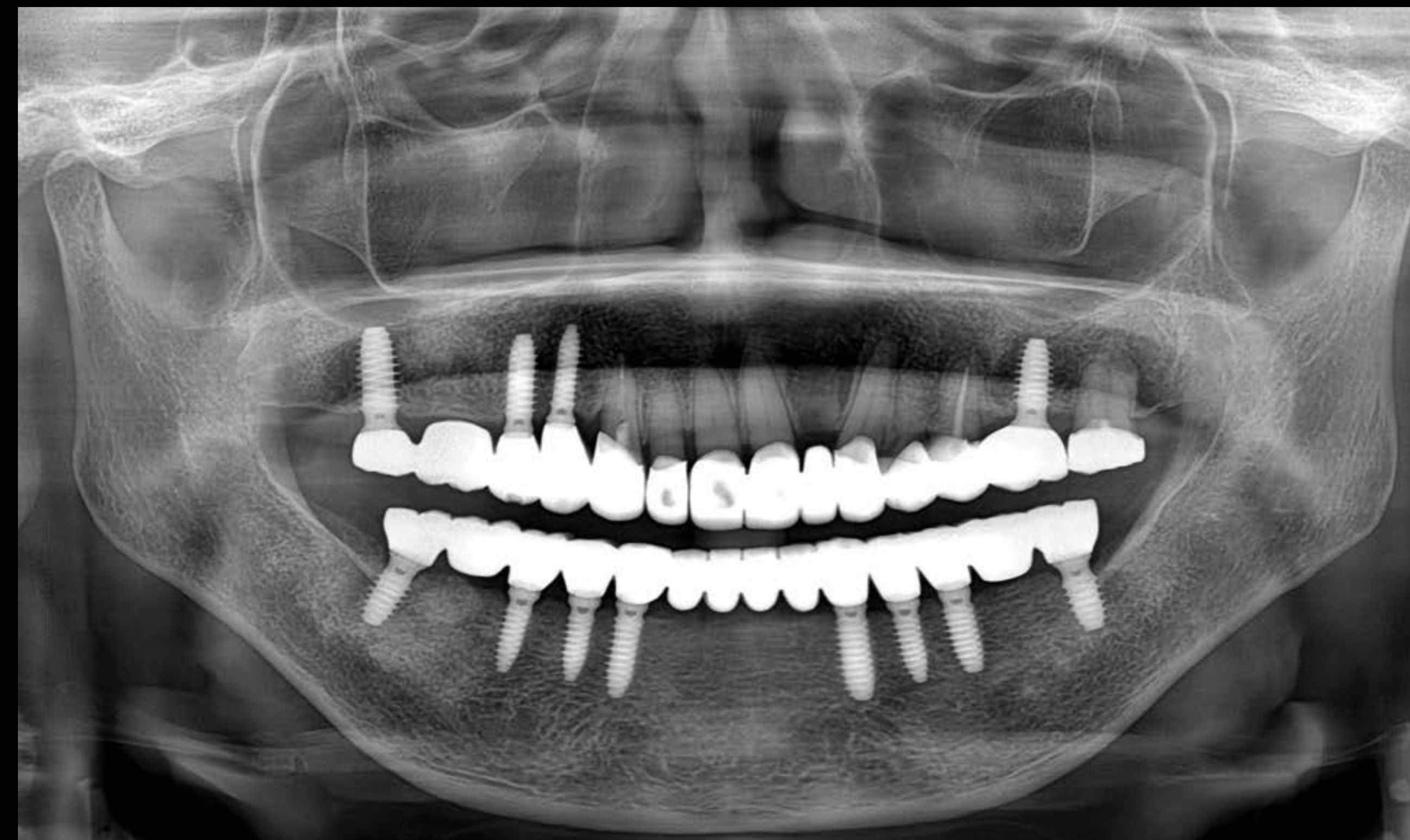
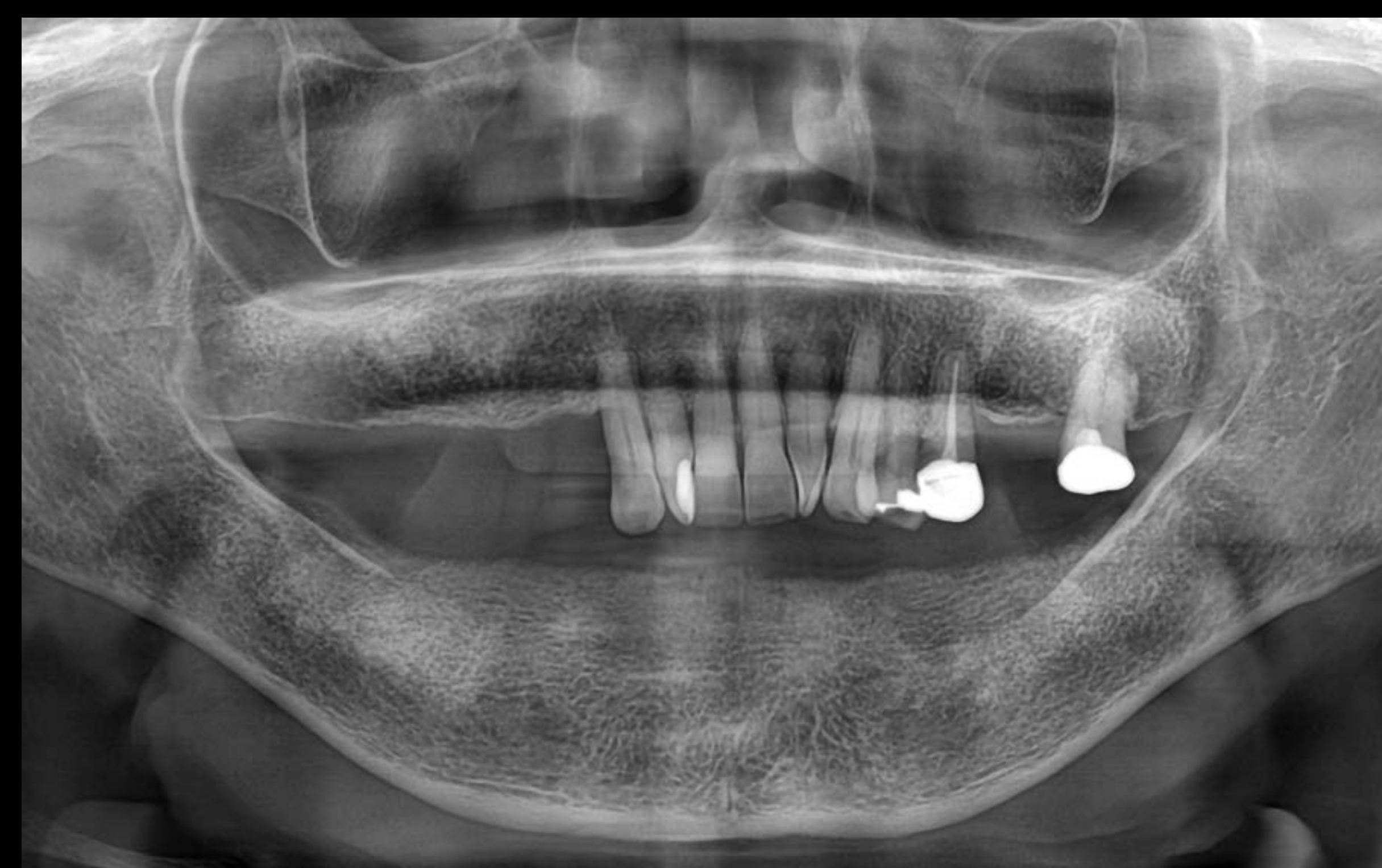
330.24

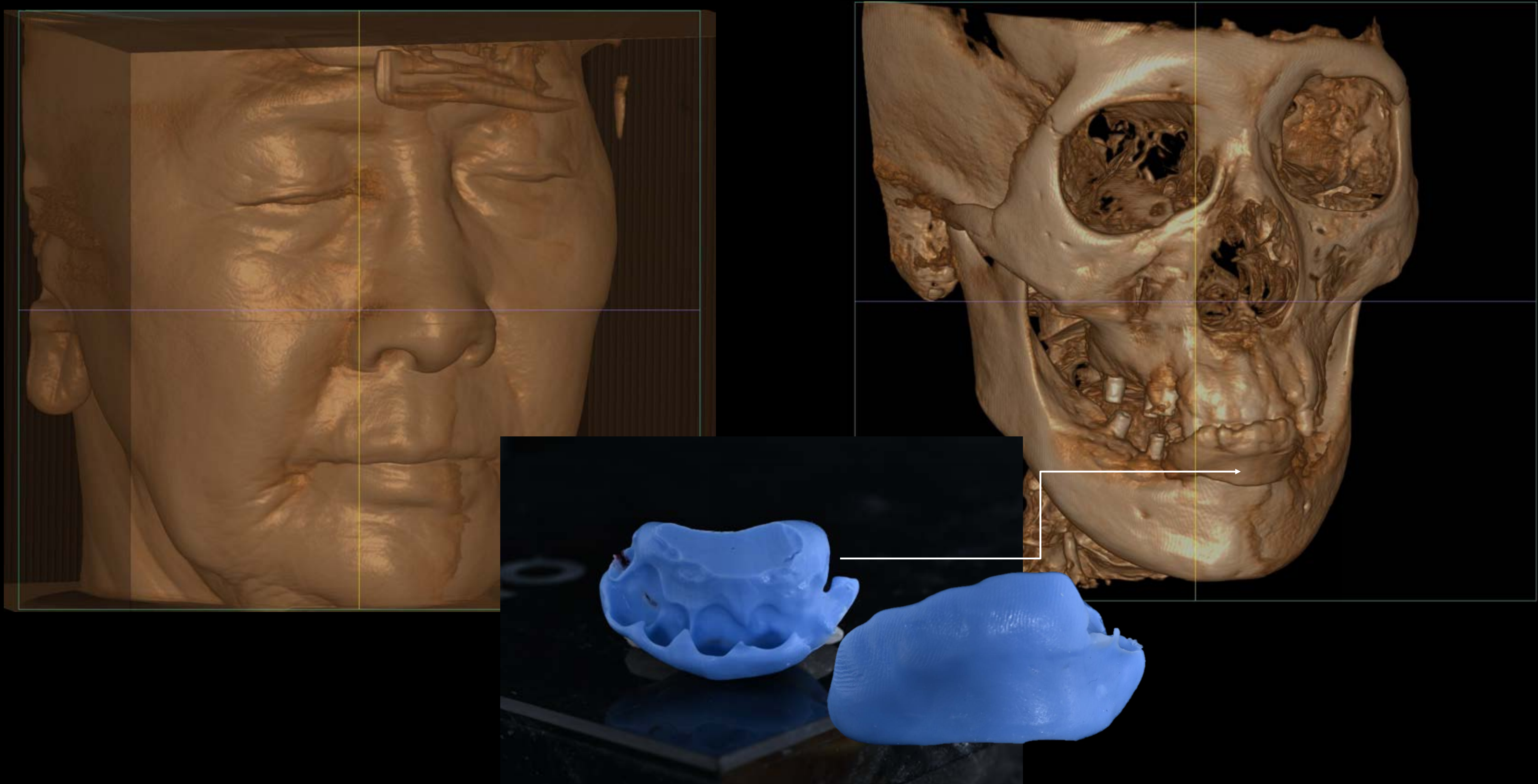
Pre-op (2022-02-06)



bright Implant

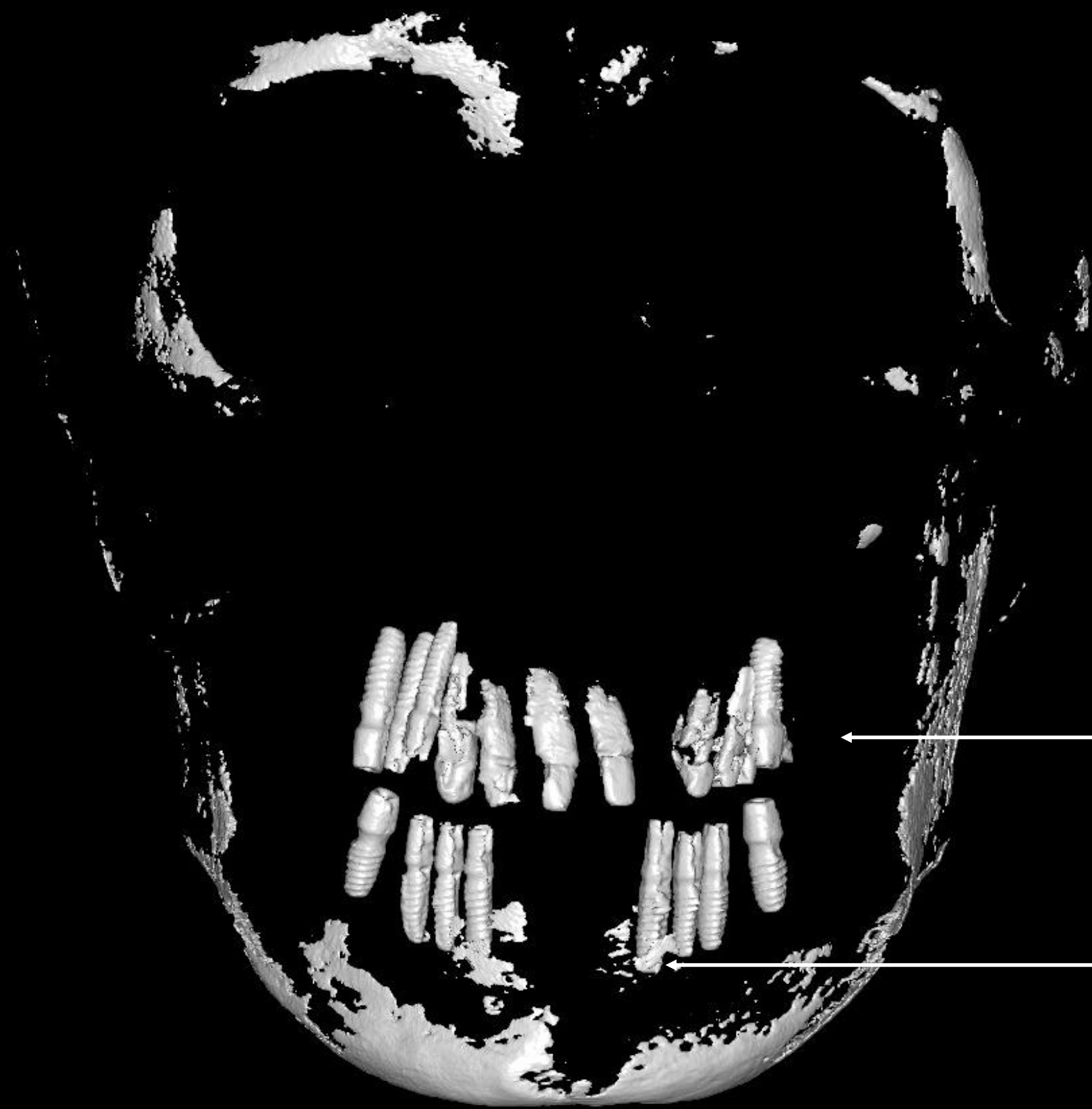


Putty index

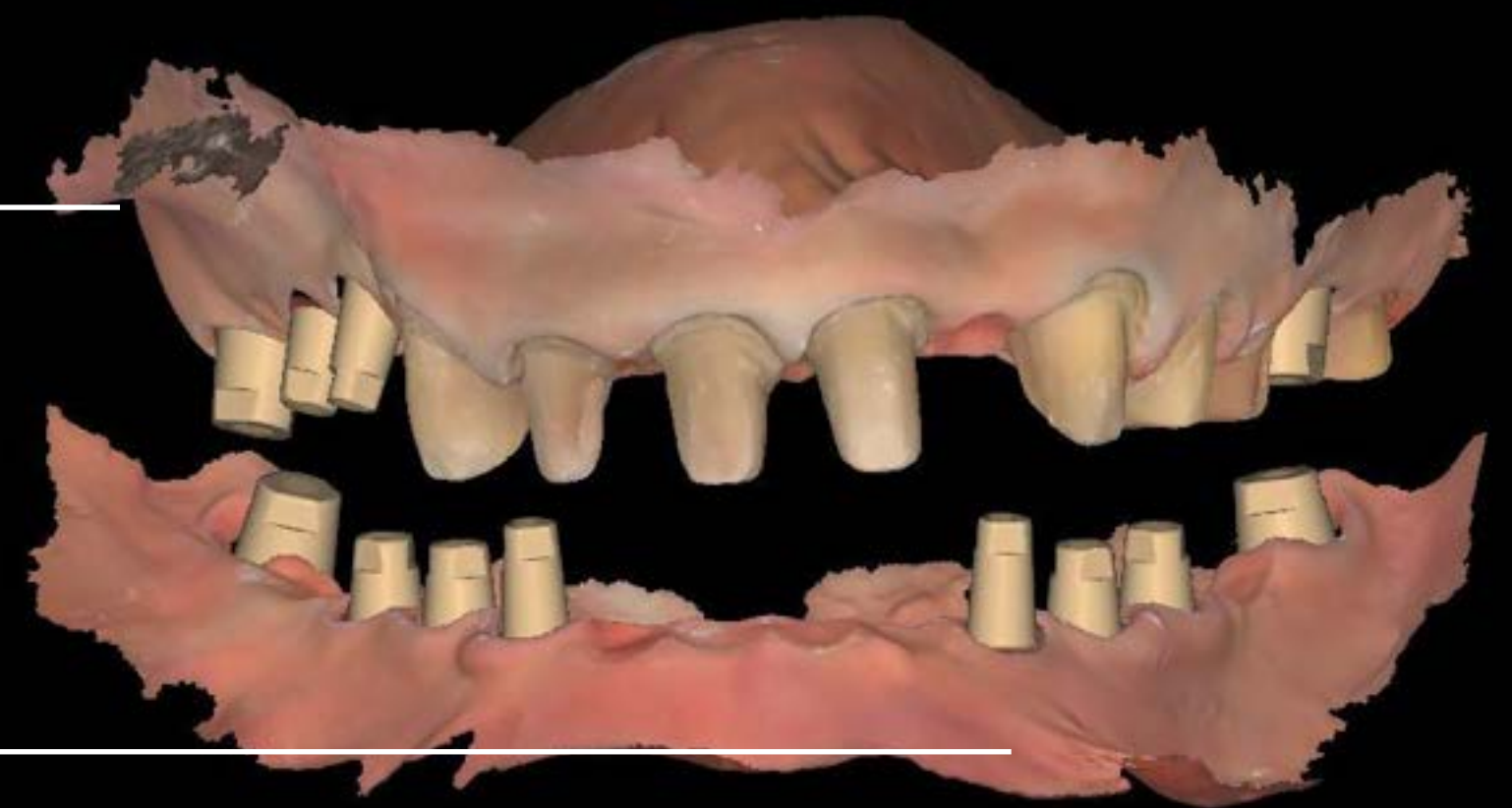


Final CT was taken using a putty index to capture the occlusal relationship of the provisional teeth while the patient was adapting to the increased vertical dimension (VD) for the fabrication of the final prosthesis

CT Check Bite

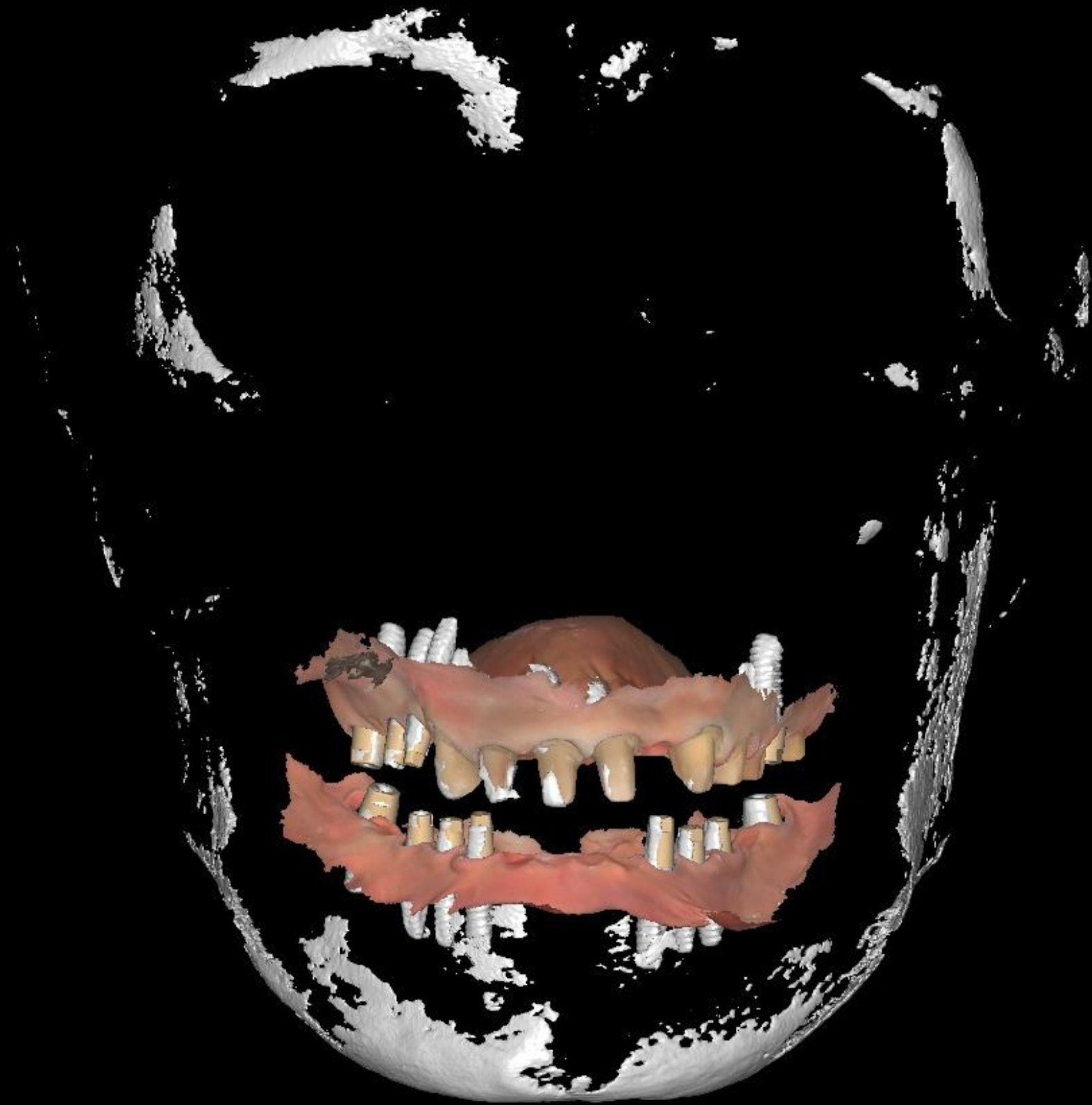


CT Check bite



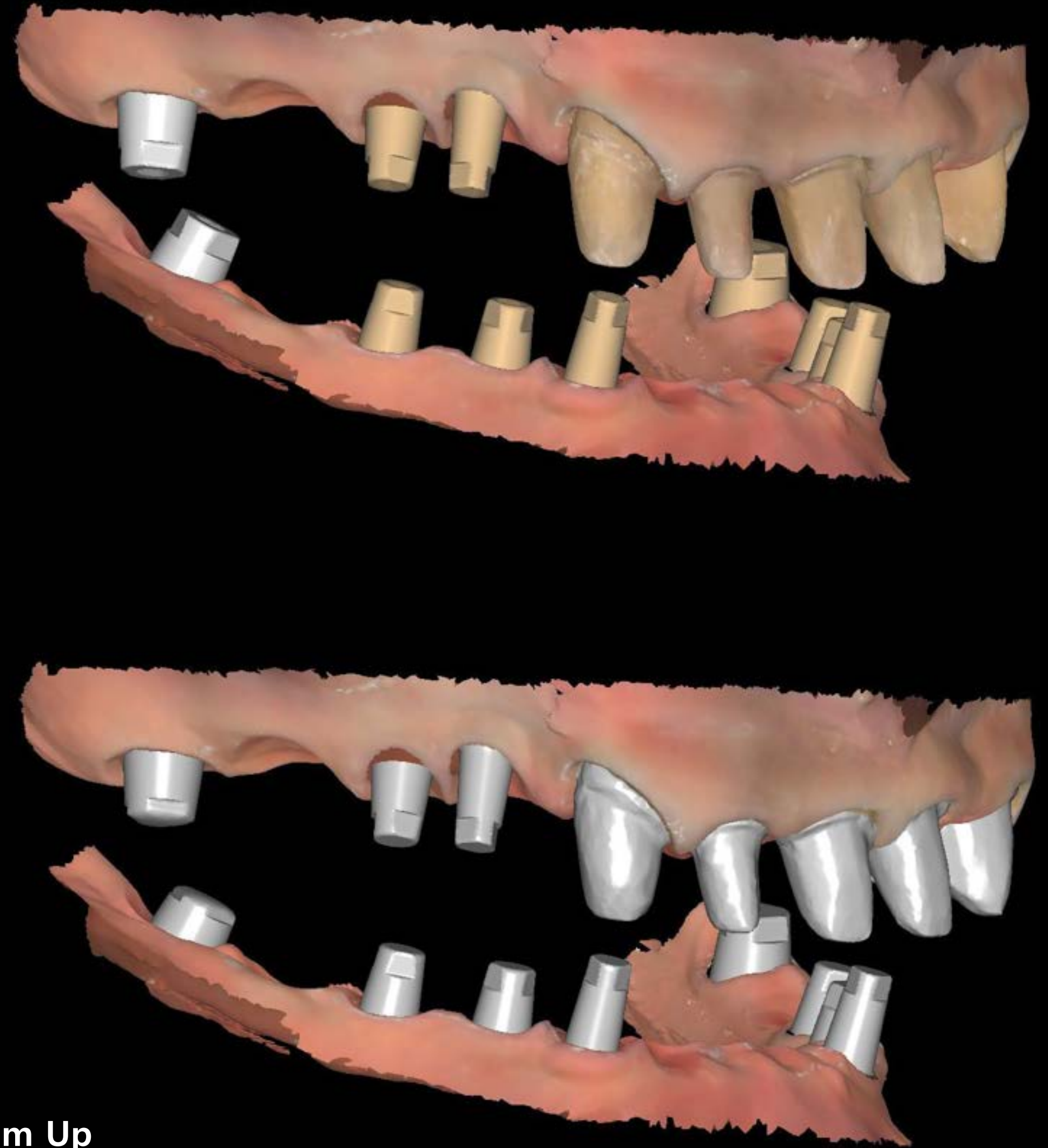
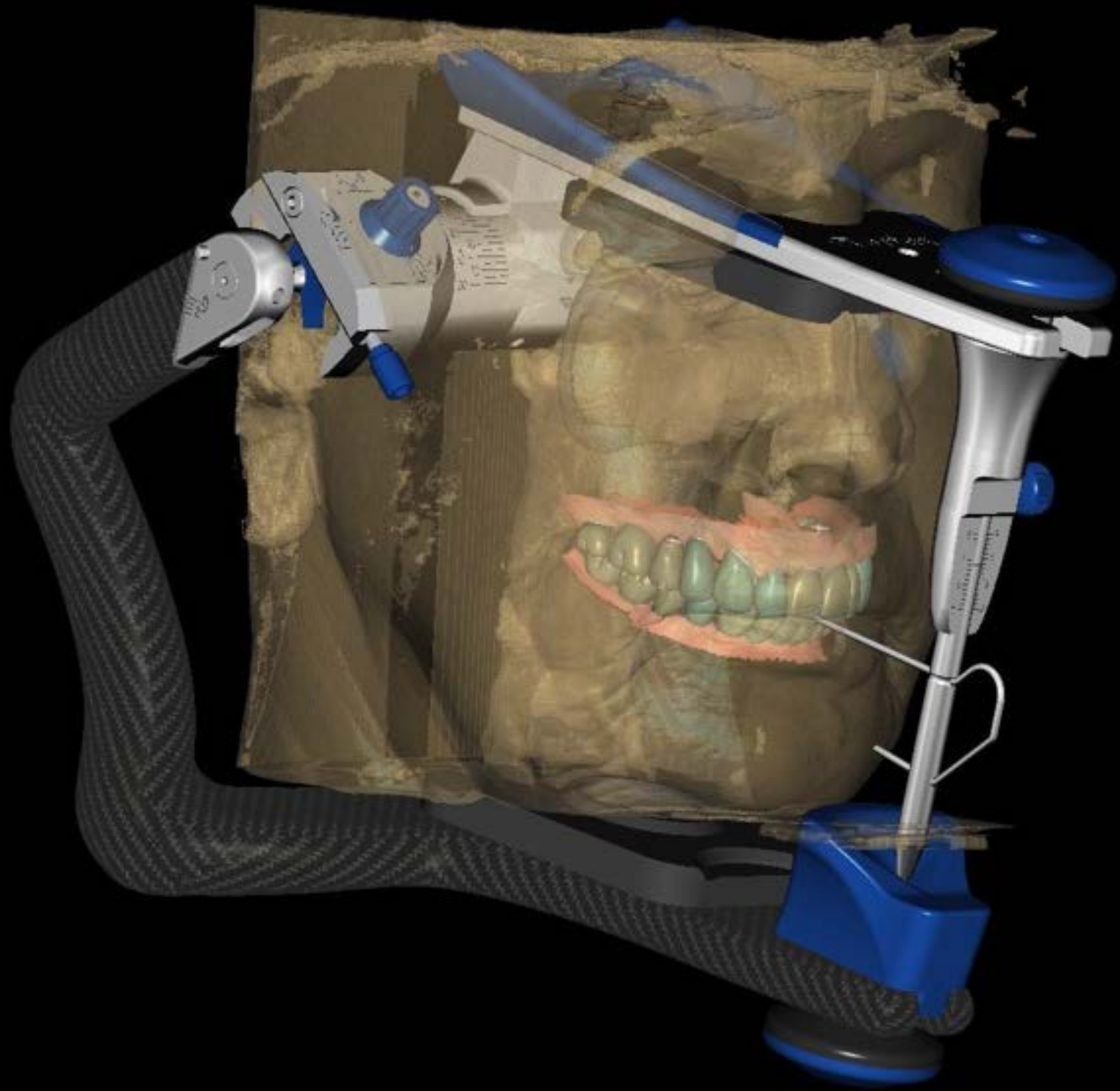
Shining 3D Aoral 3 Wireless data

CT Check Bite

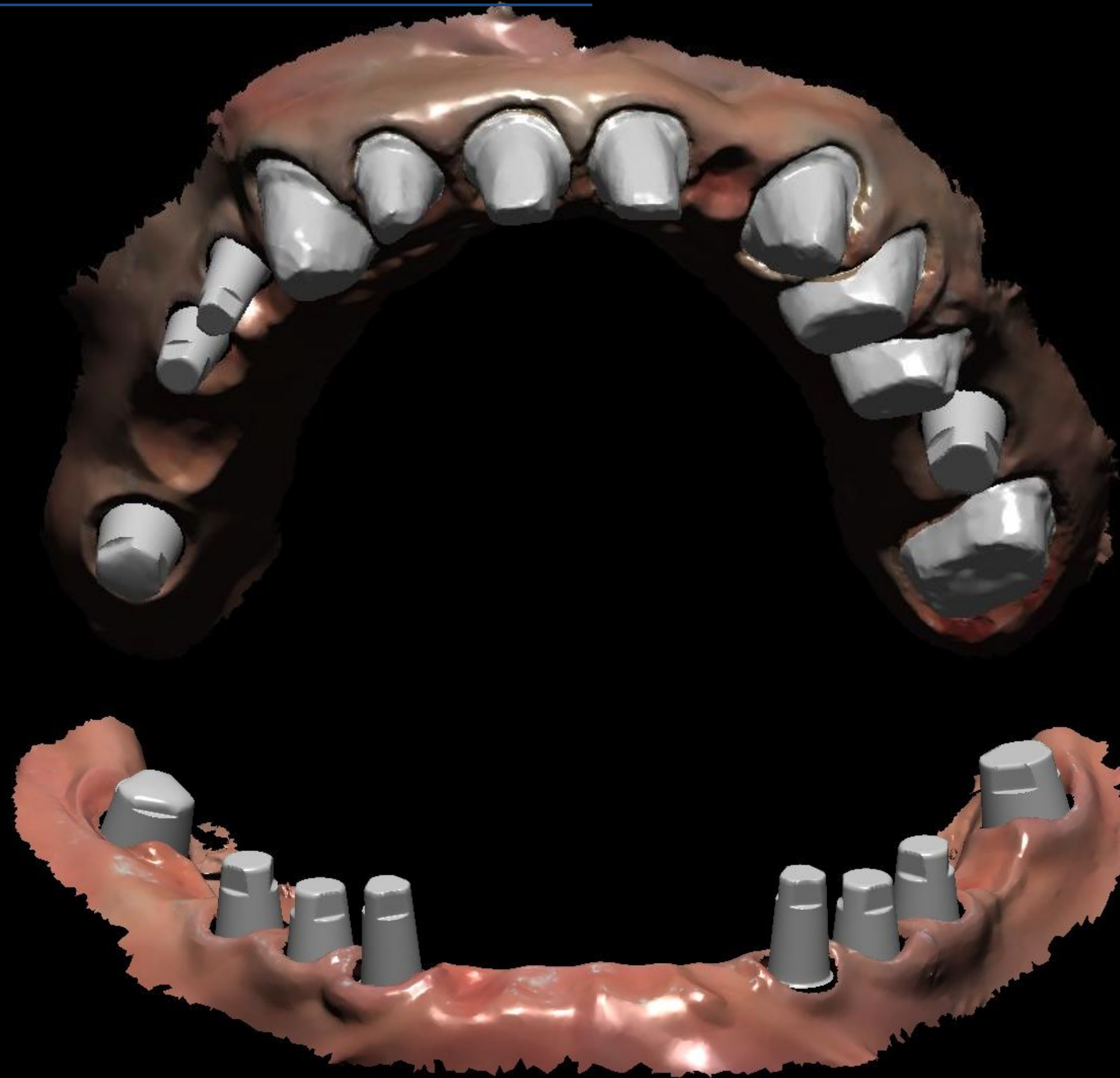

CT Check bite + los scan data

Cad Design

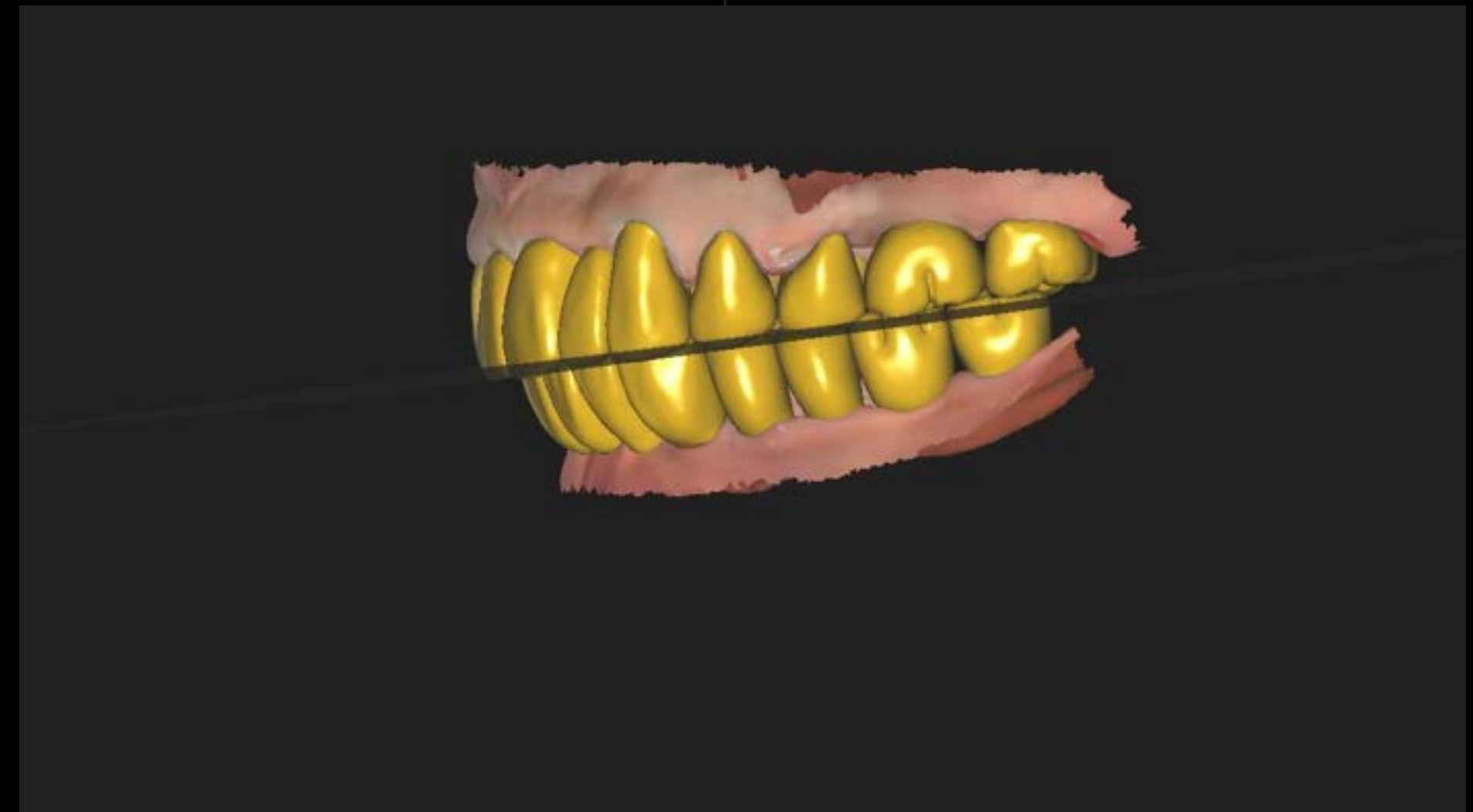
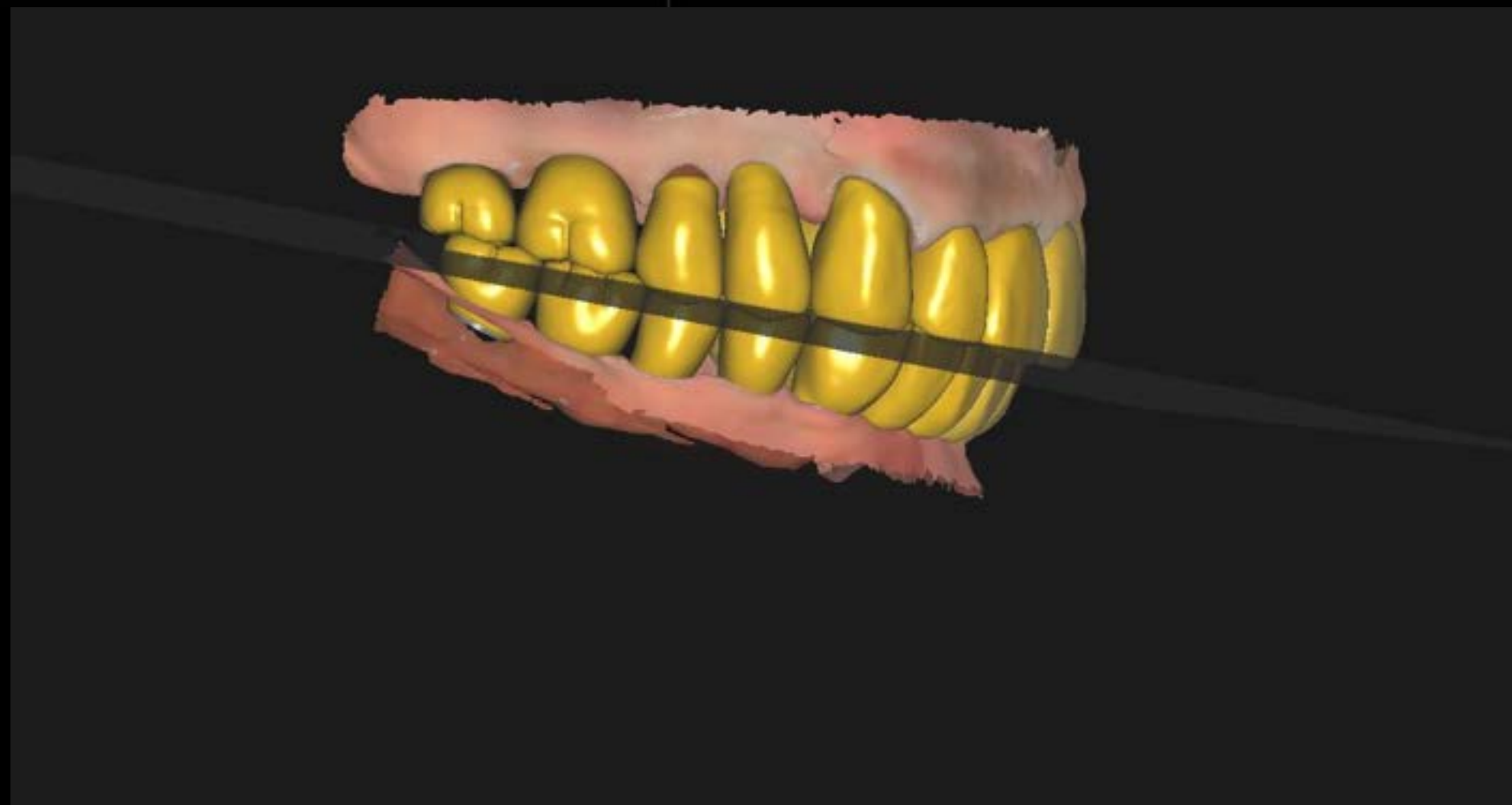
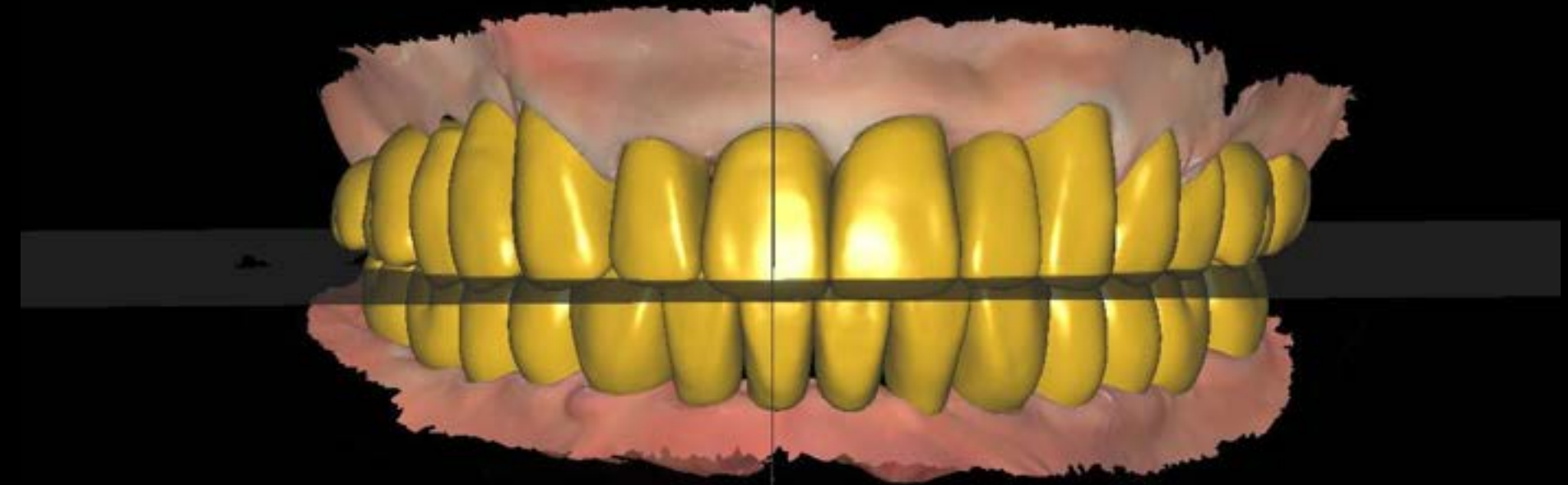
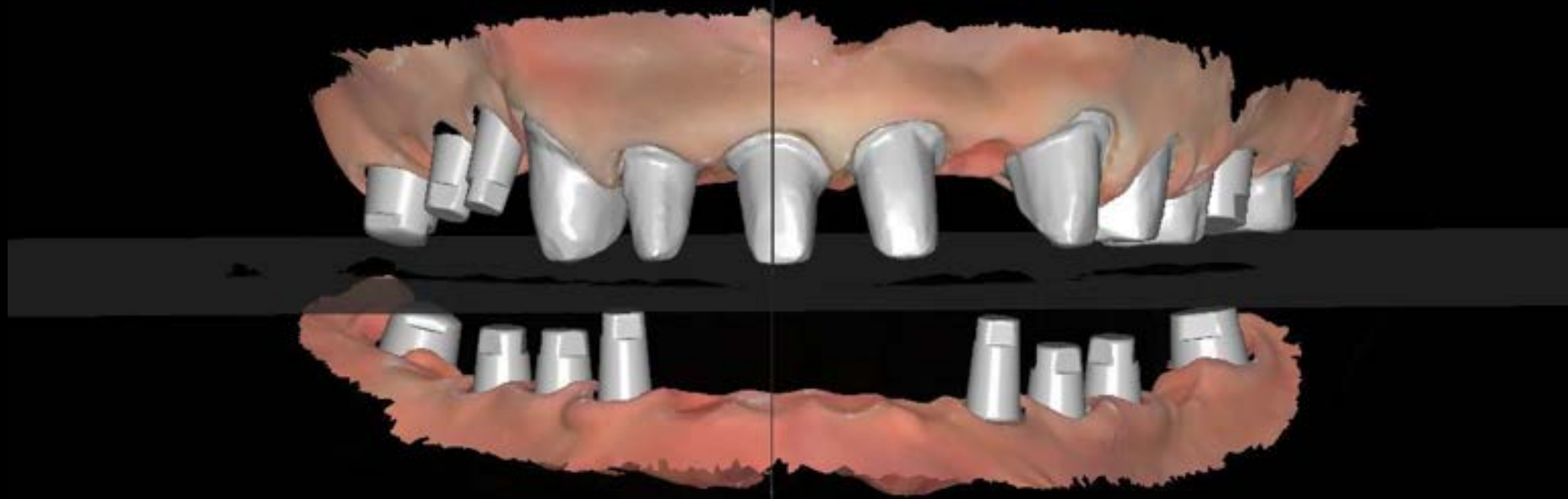

Final Design VD 1mm Up

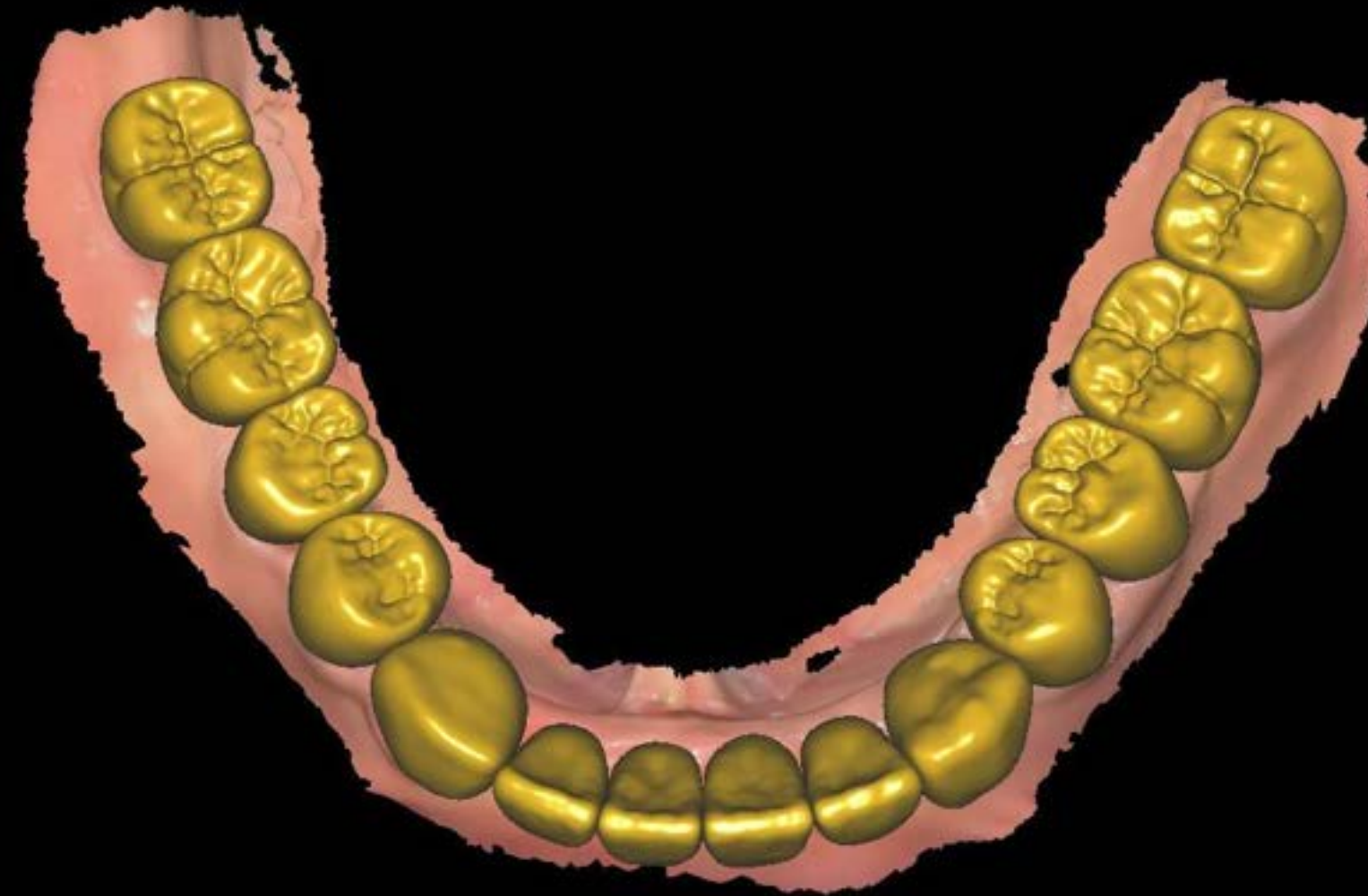
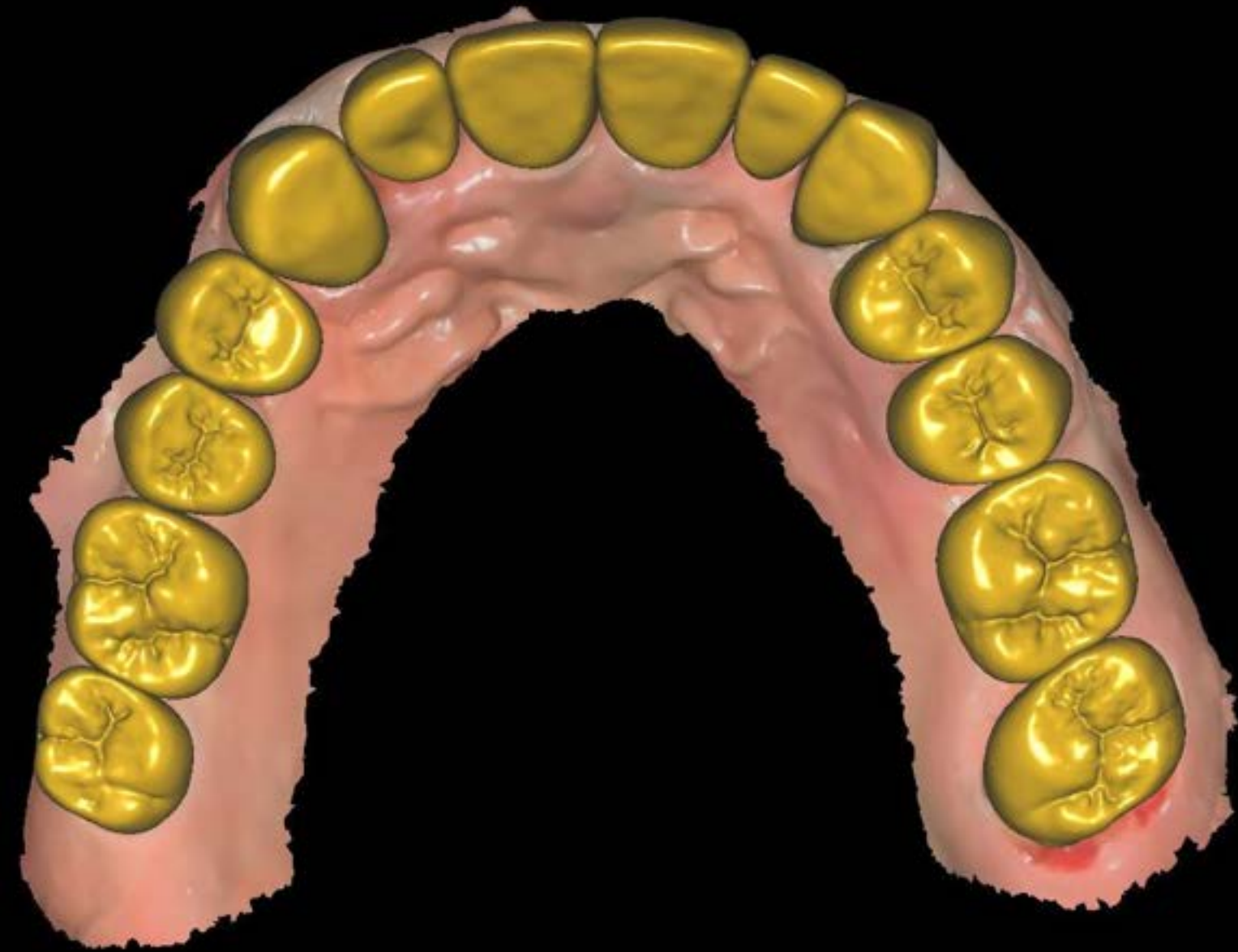
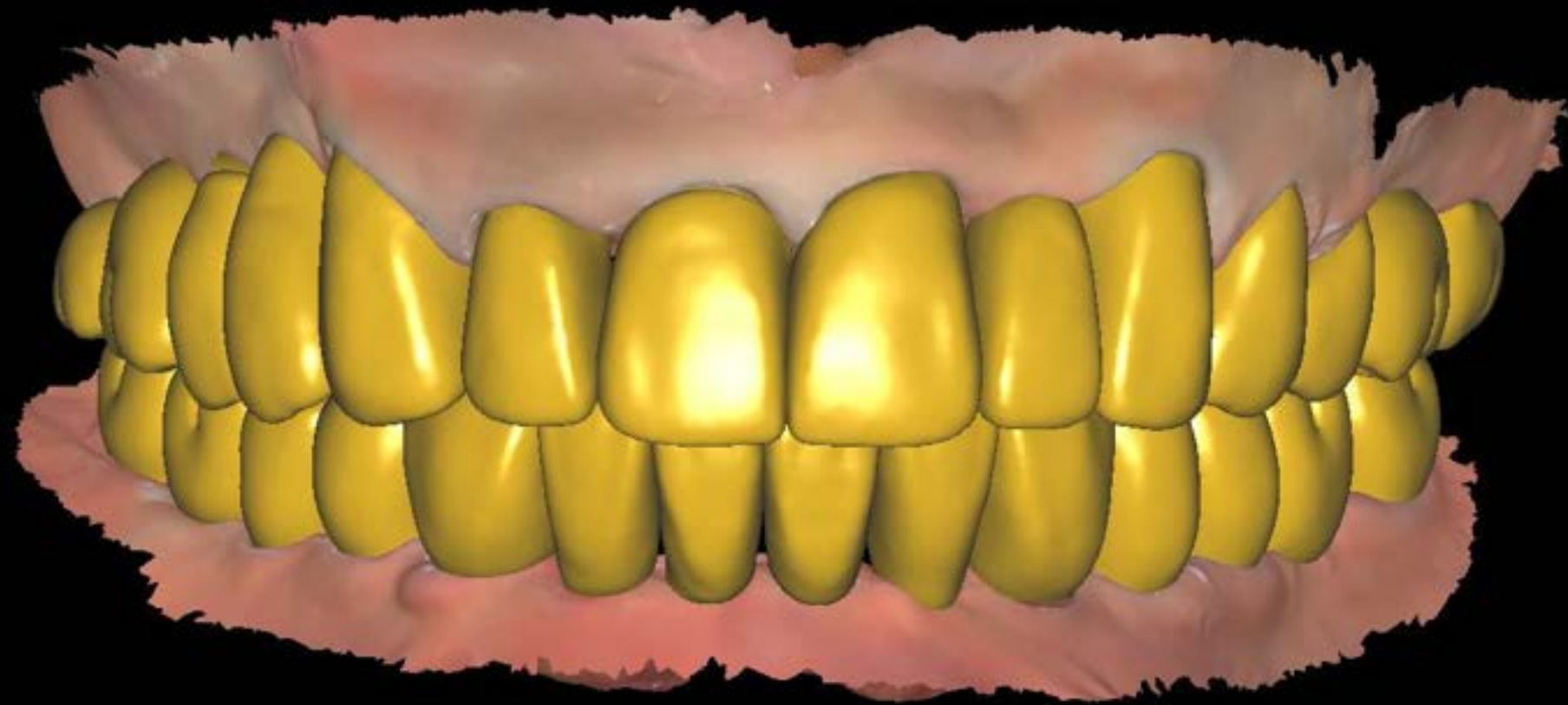
All bright Digital abutment & Ti base abutment

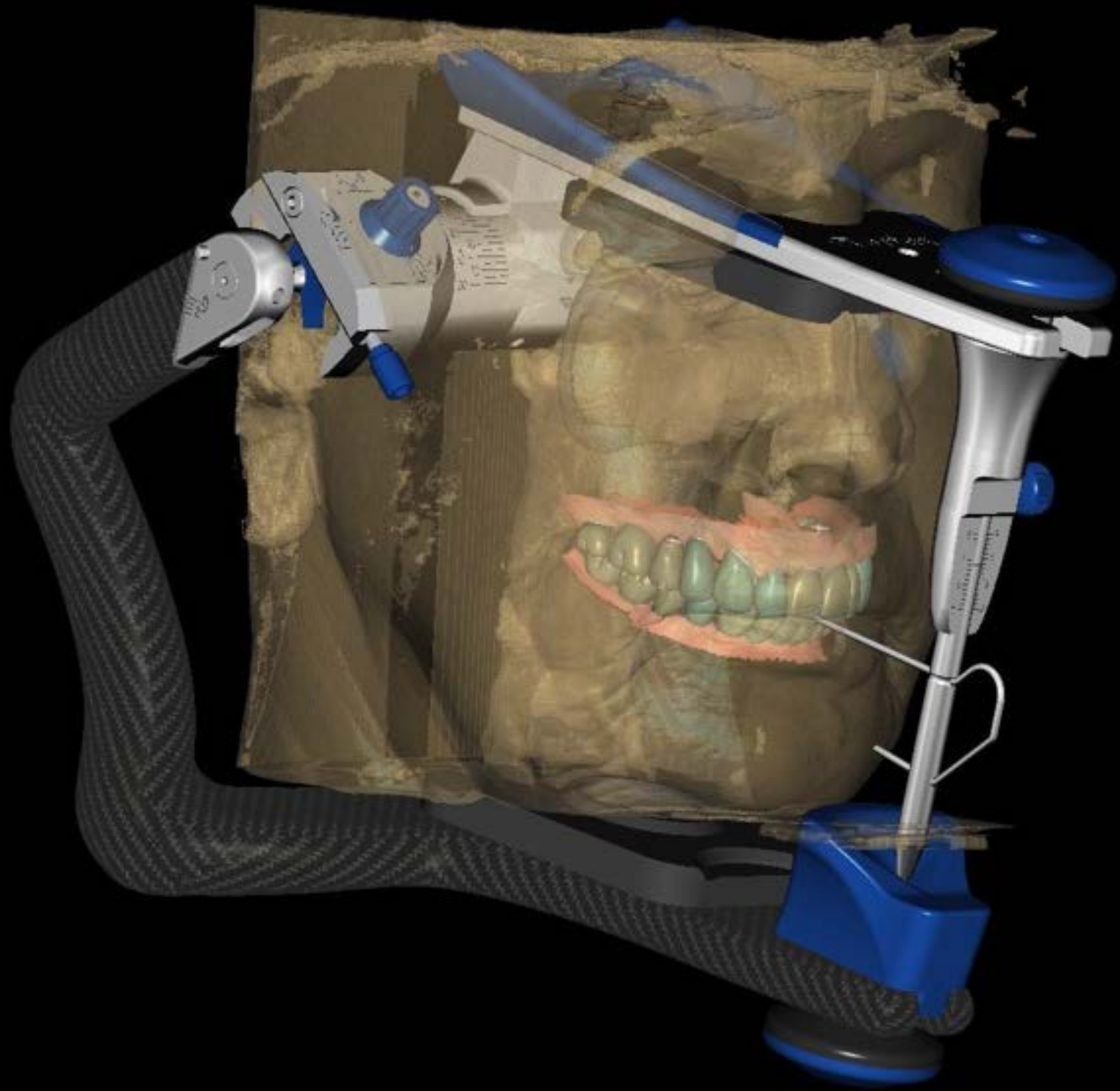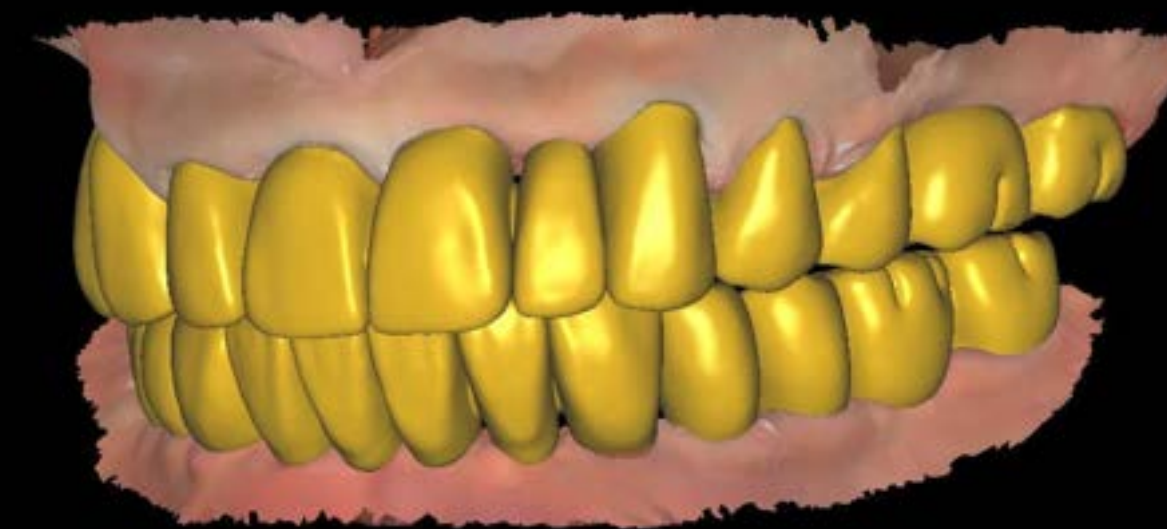
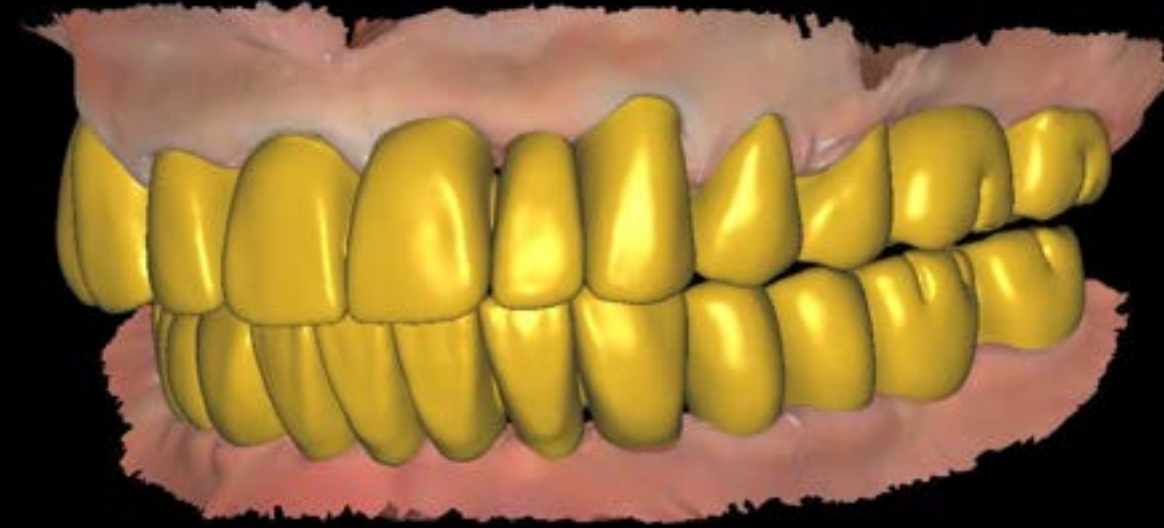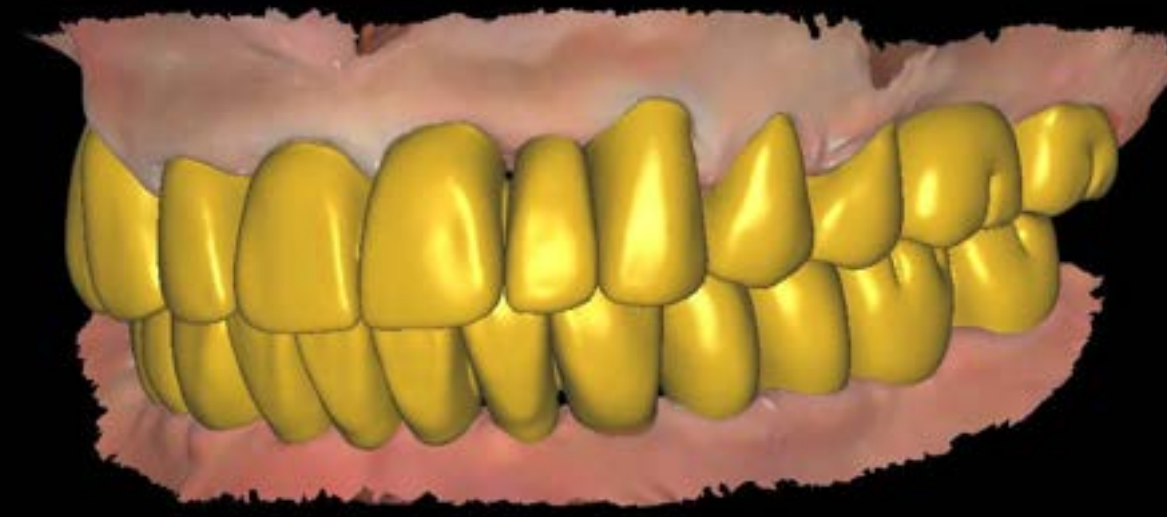Cad Design



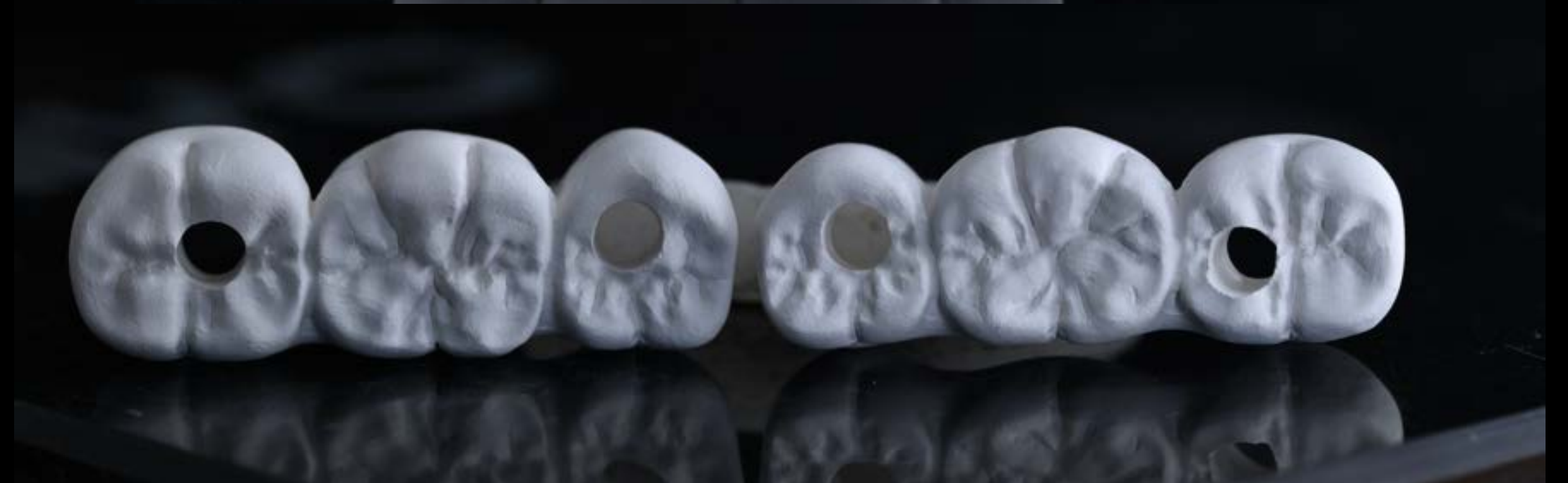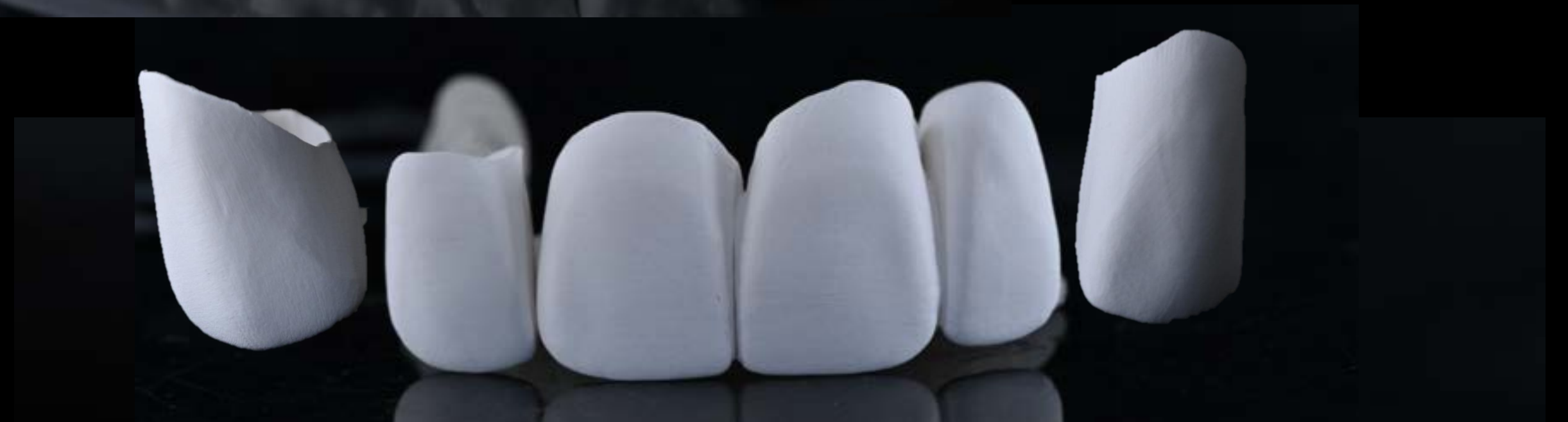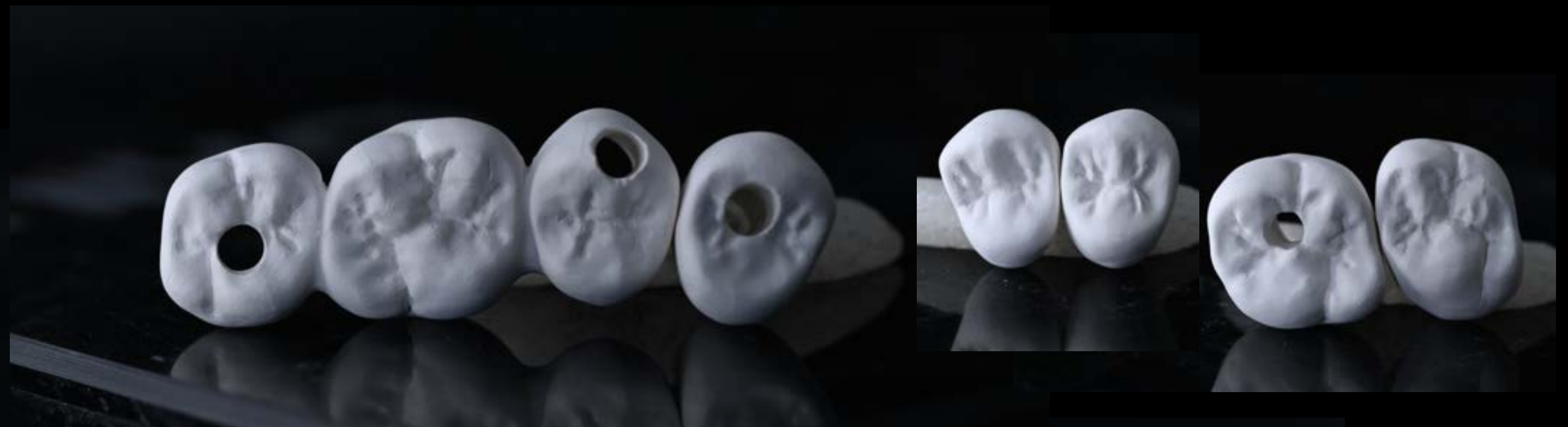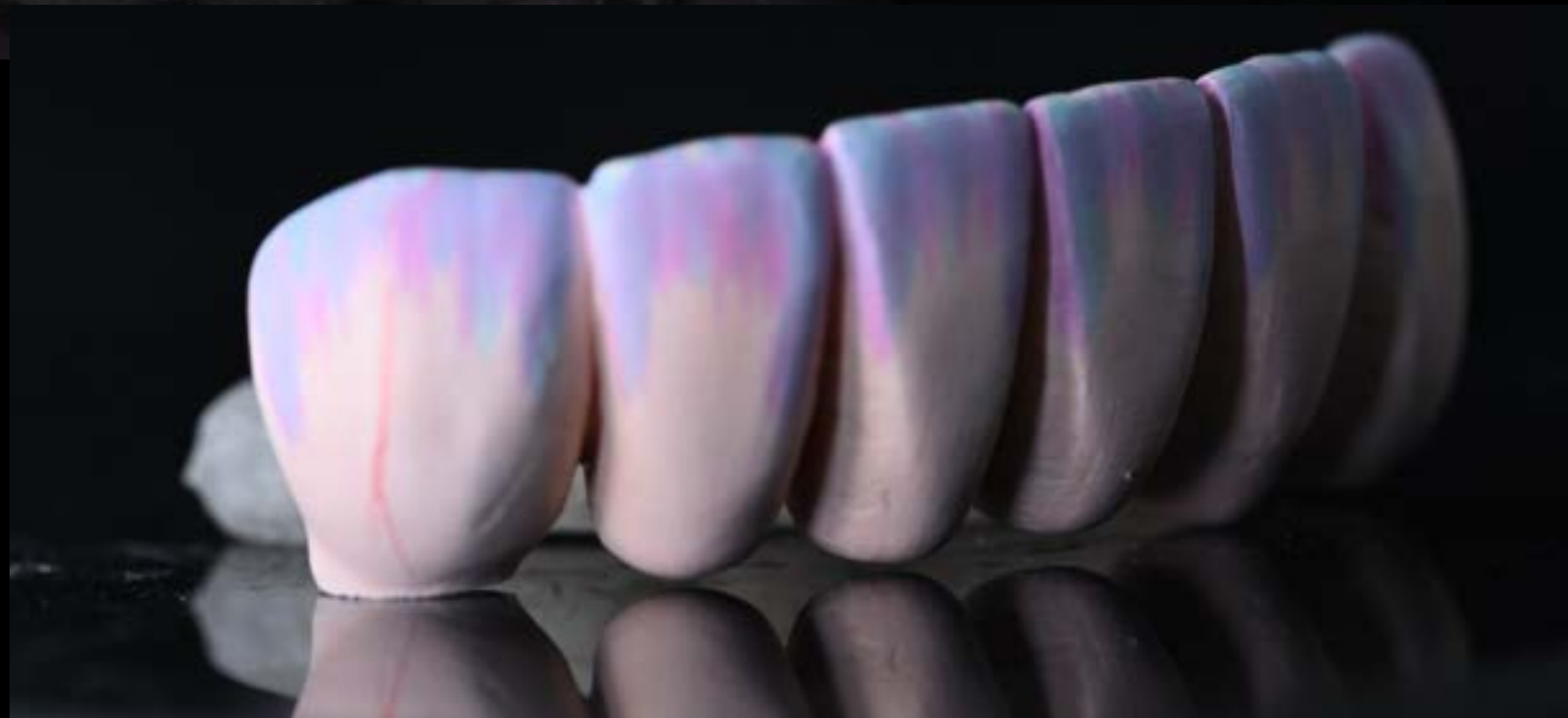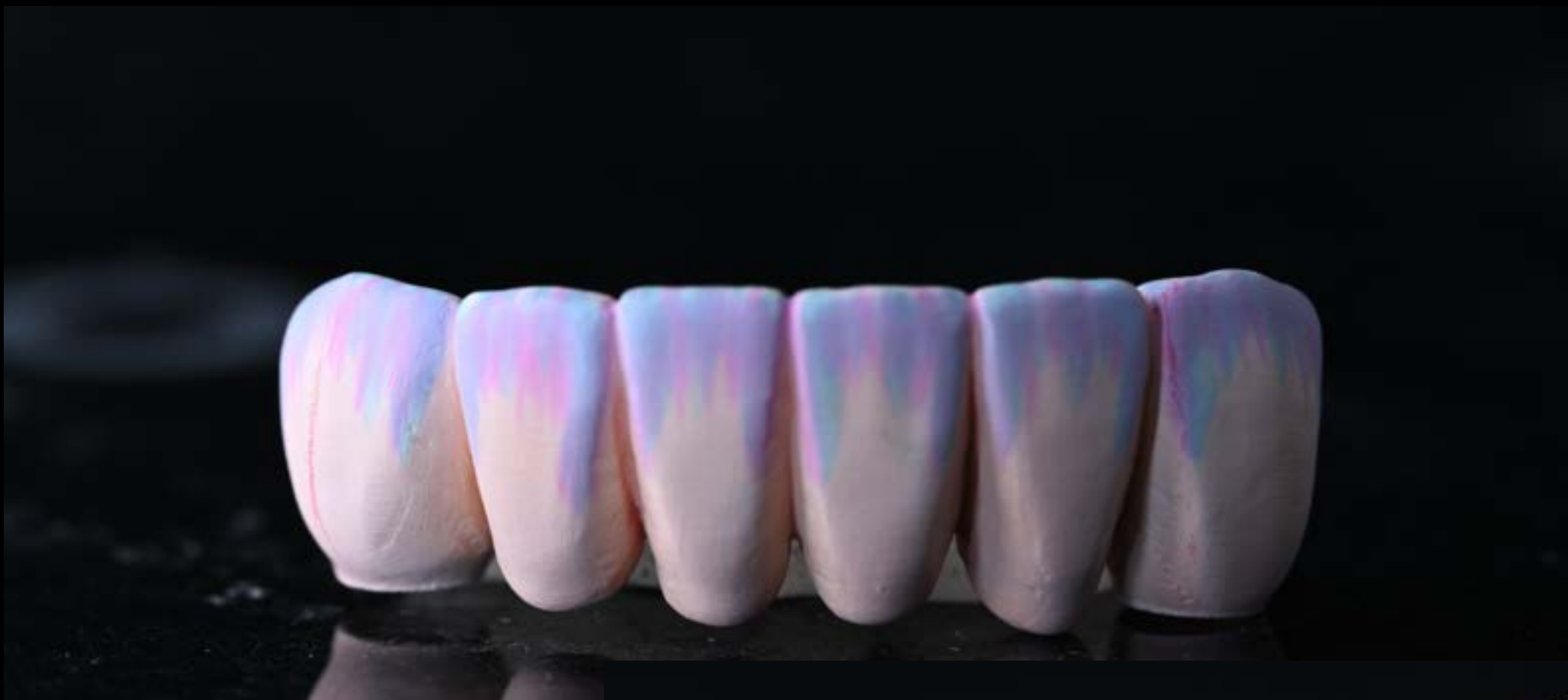Cad Design



Virtual Articulator



Zirconia Block

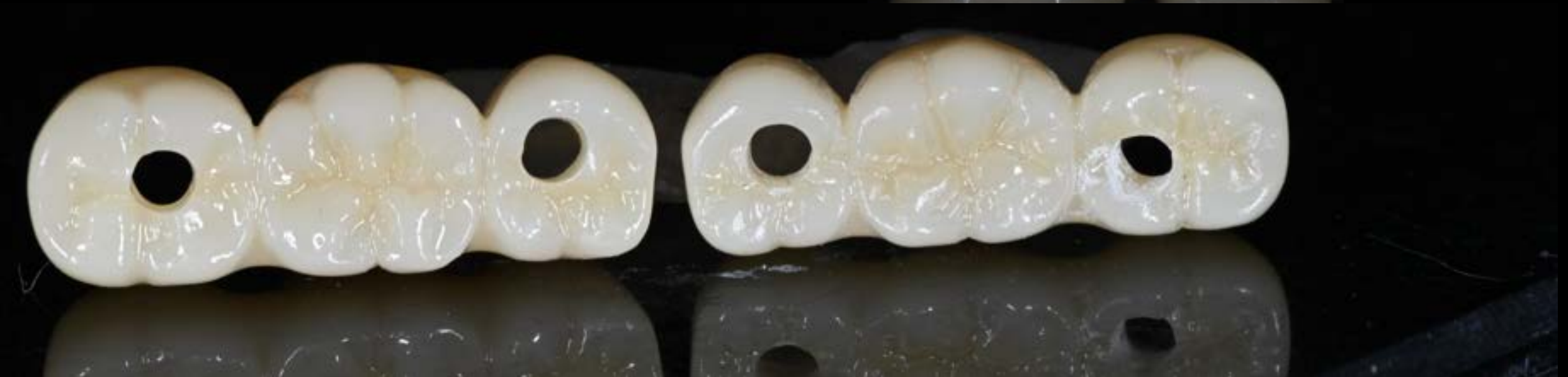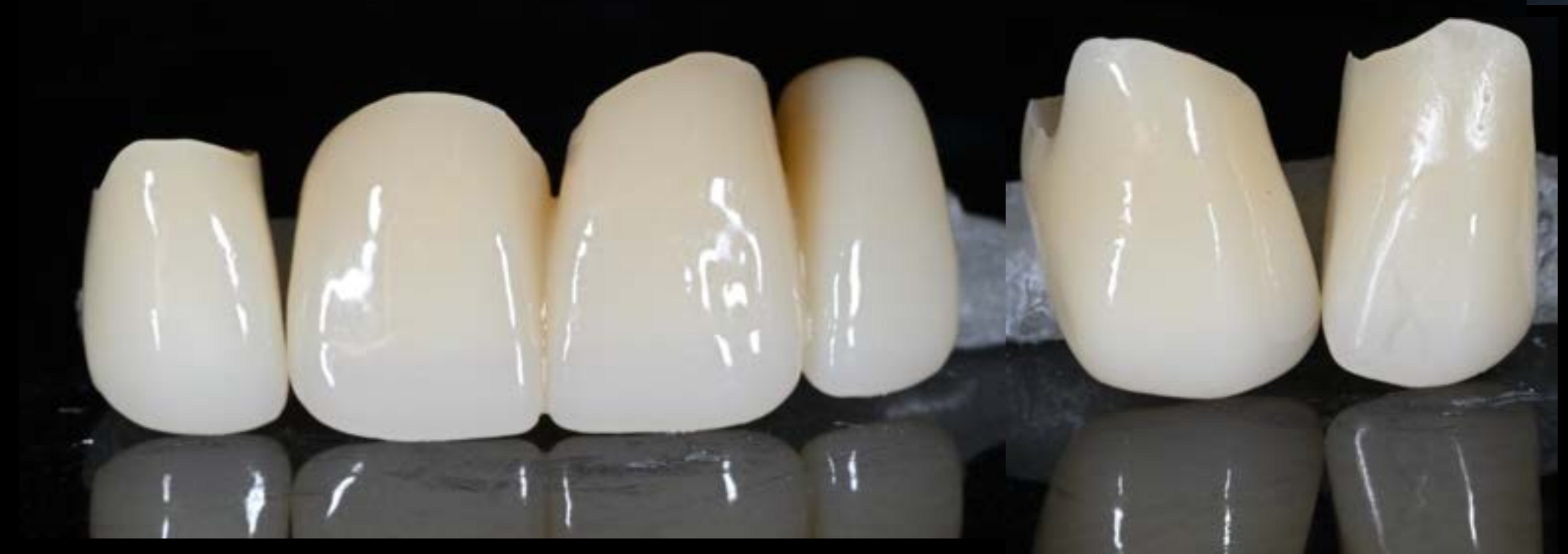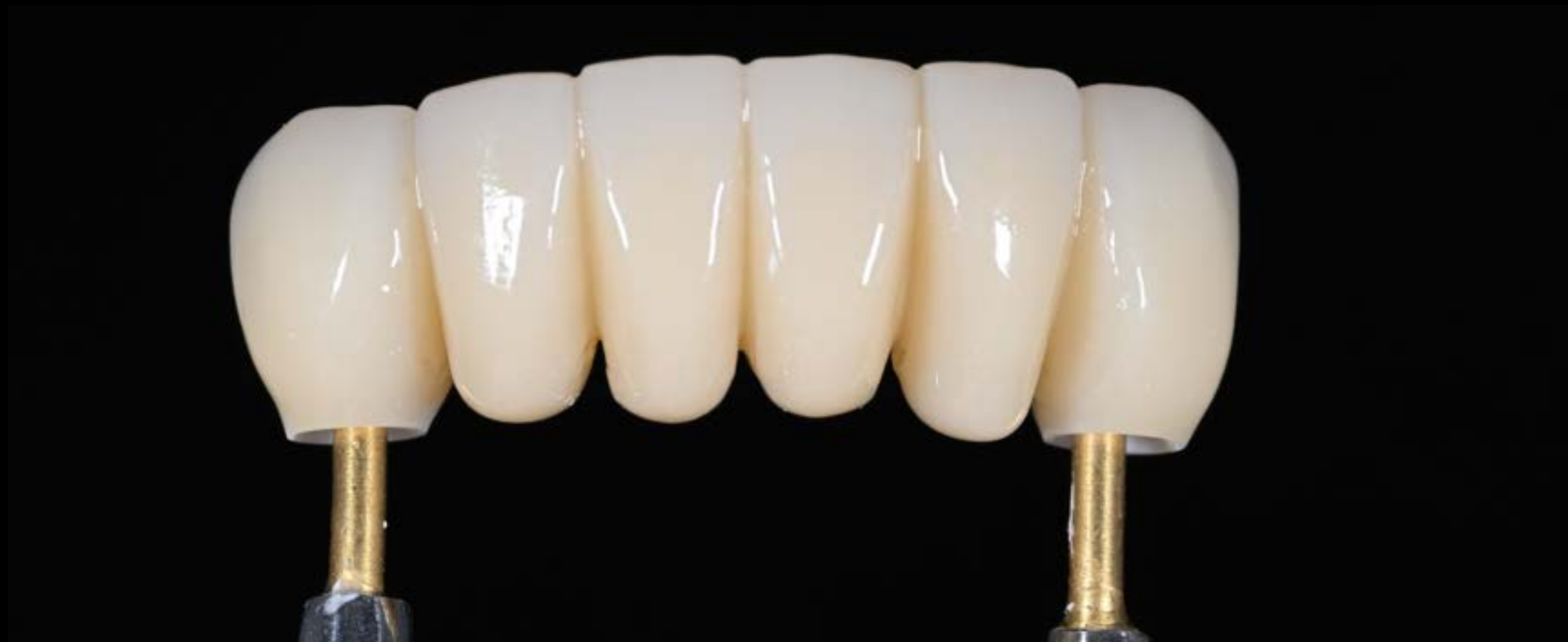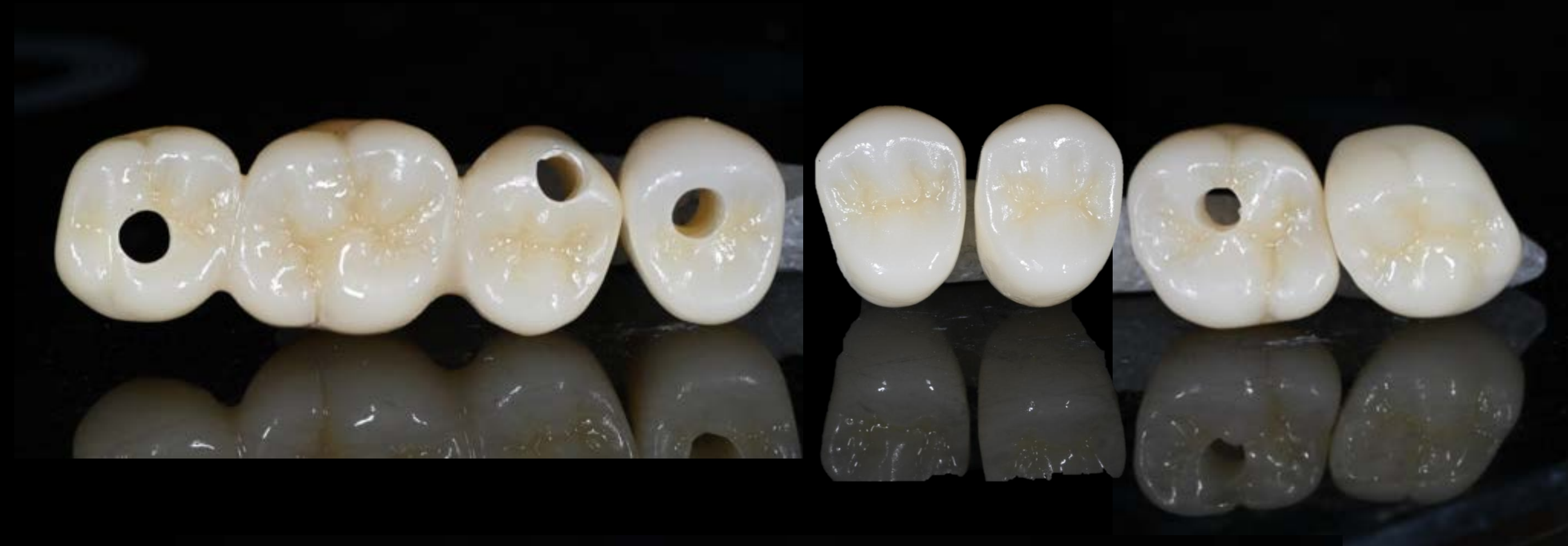


rainbow™
Shine-T

Maximum Strength
Natural Aesthetic

bright 3-Layer
No coloring & Stain

Zirconia Block

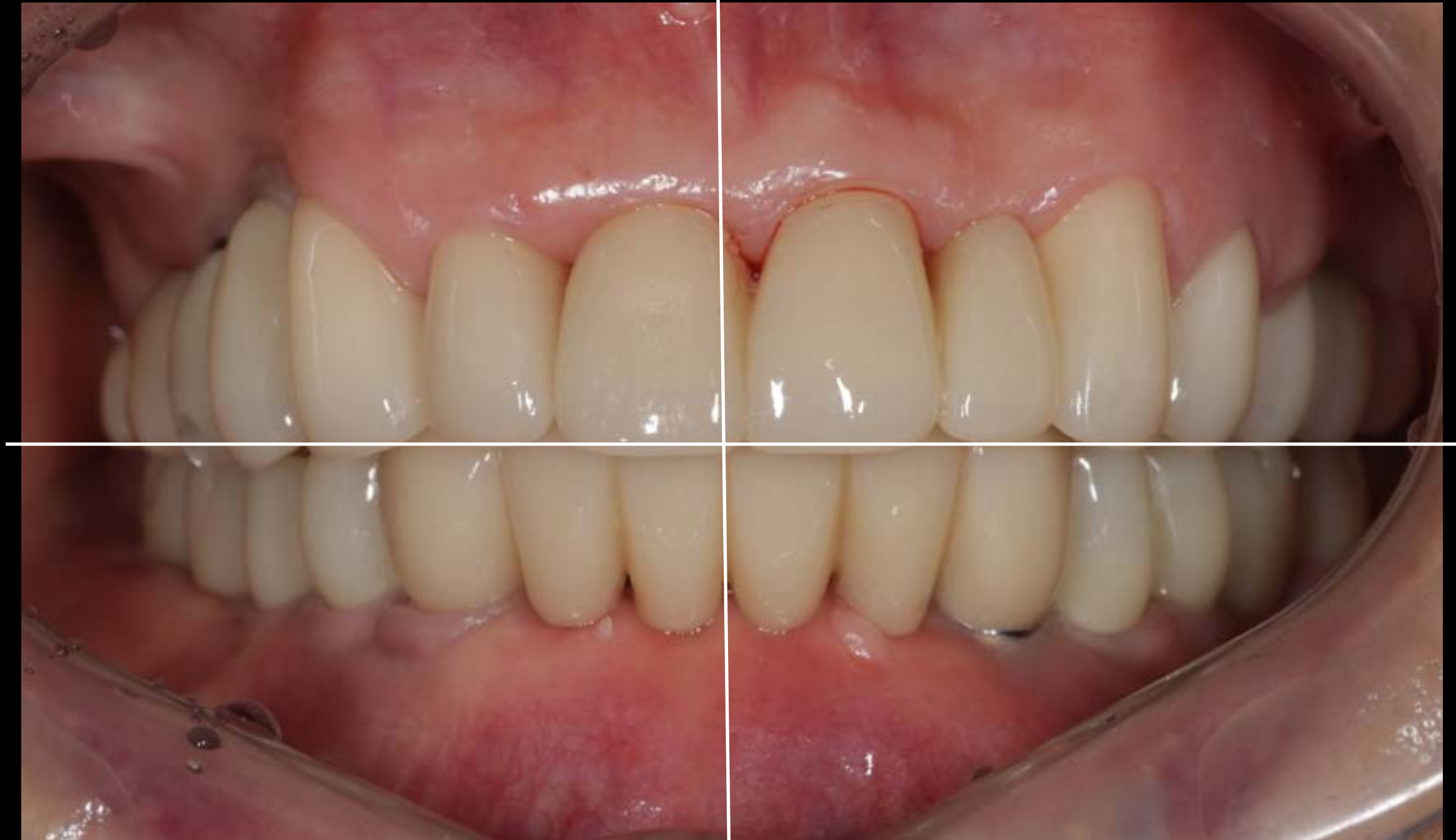
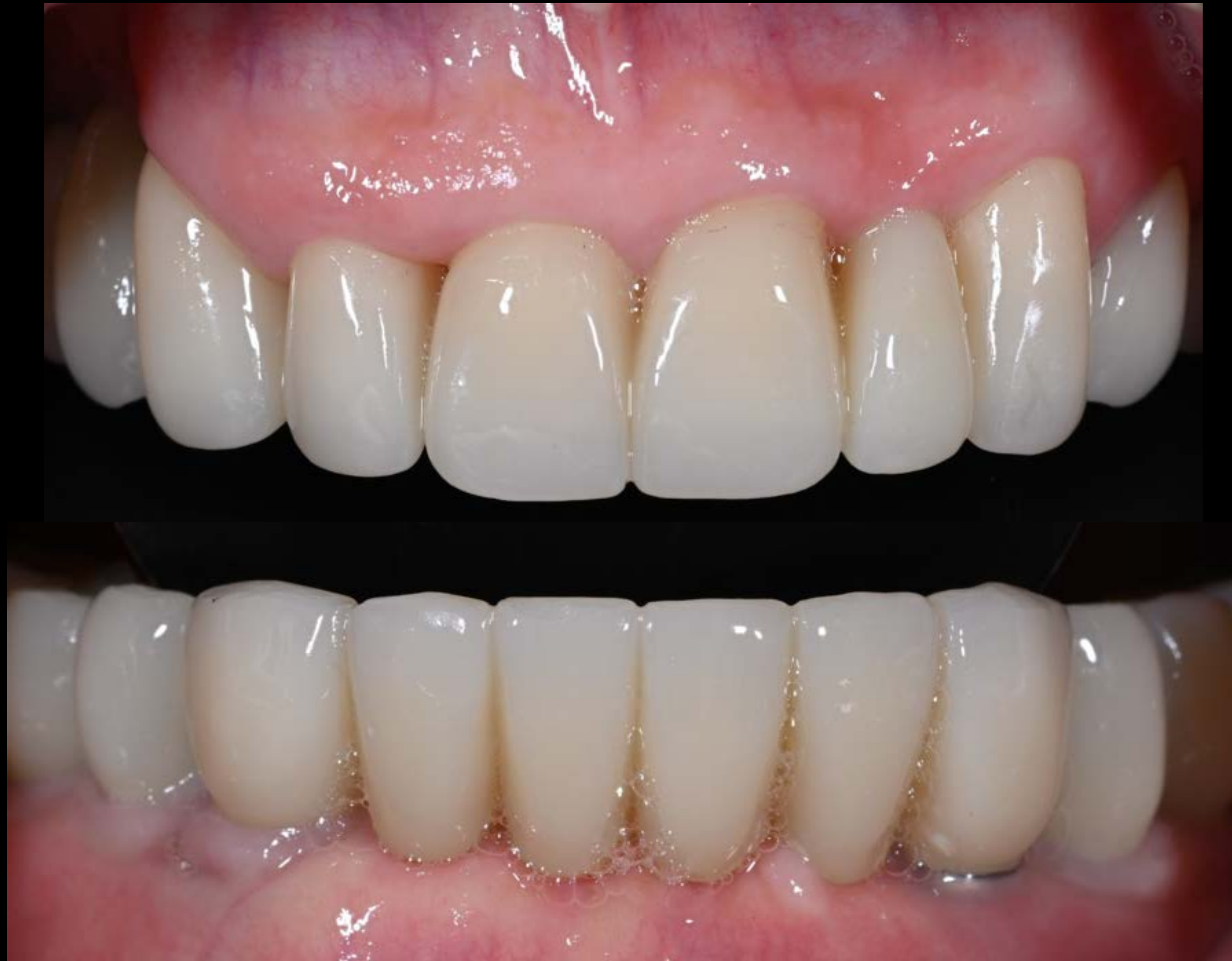
rainbow[™]
Shine-T

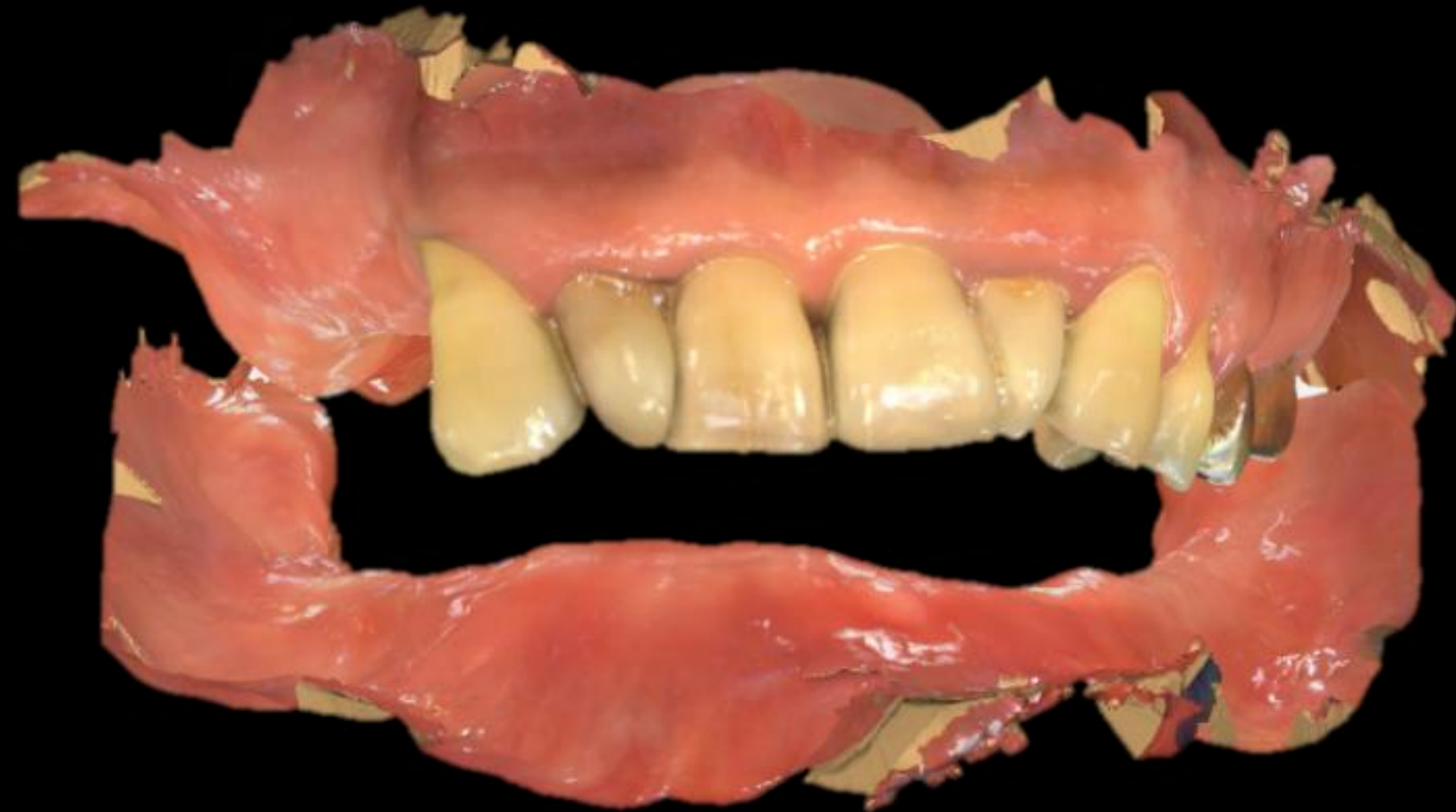✓ **Maximum Strength**
✓ **Natural Aesthetic**

bright 3-Layer
No coloring & Stain

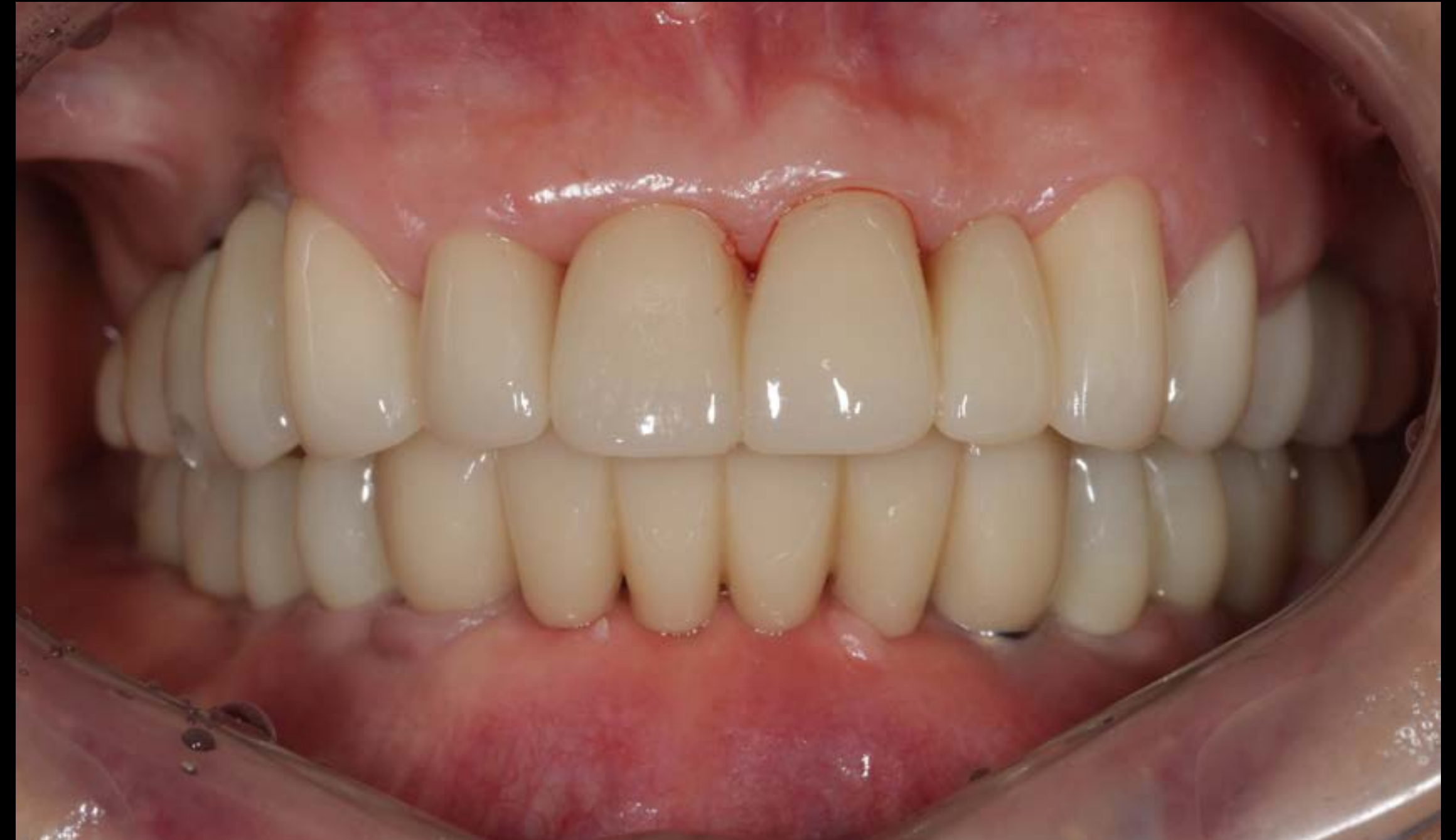Final Prosthesis



Final Prosthesis

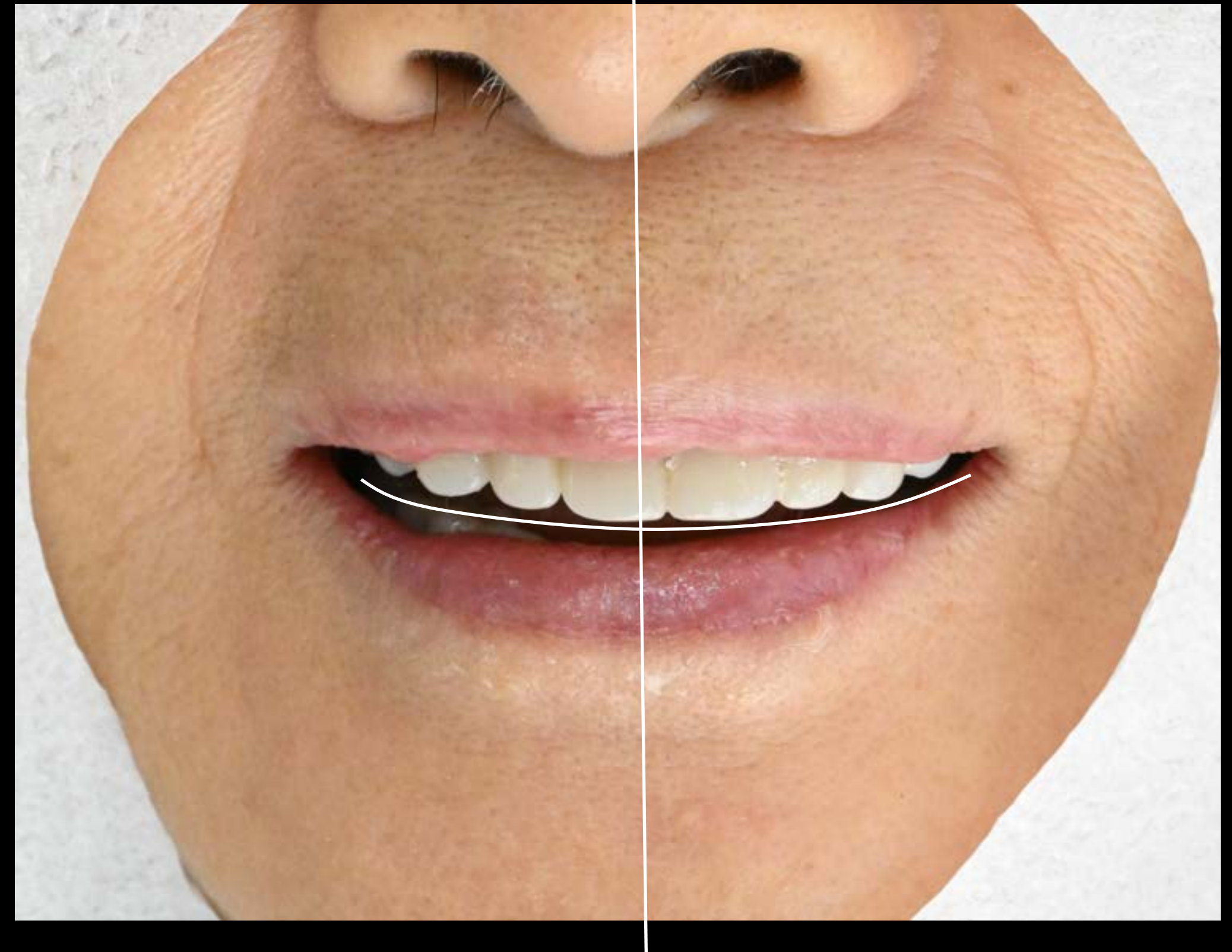

Before



After

Final Prosthesis



Hyaluronic Acid Dermal Filler with Lidocaine

MONALISA

Longterm! volume up!

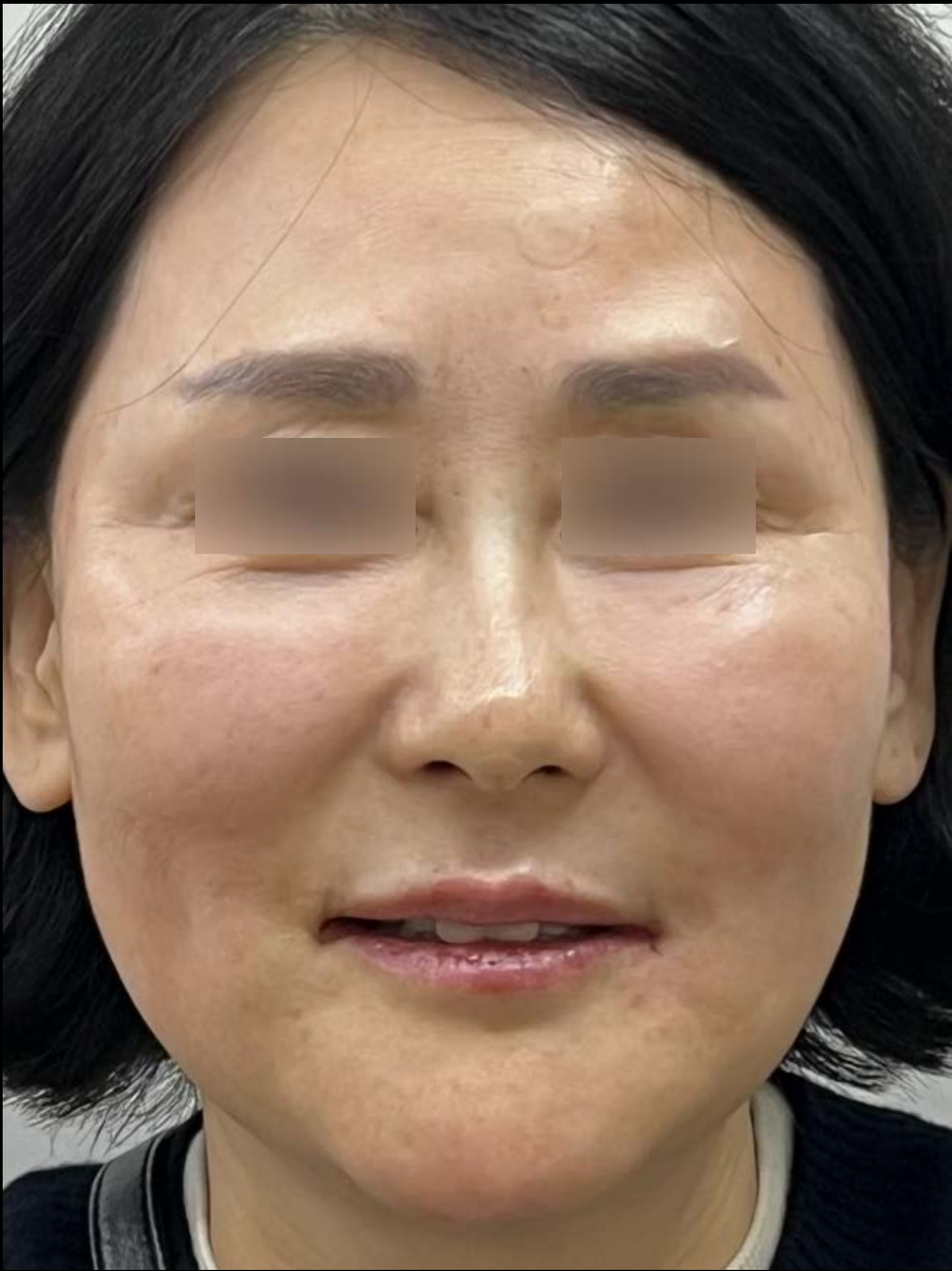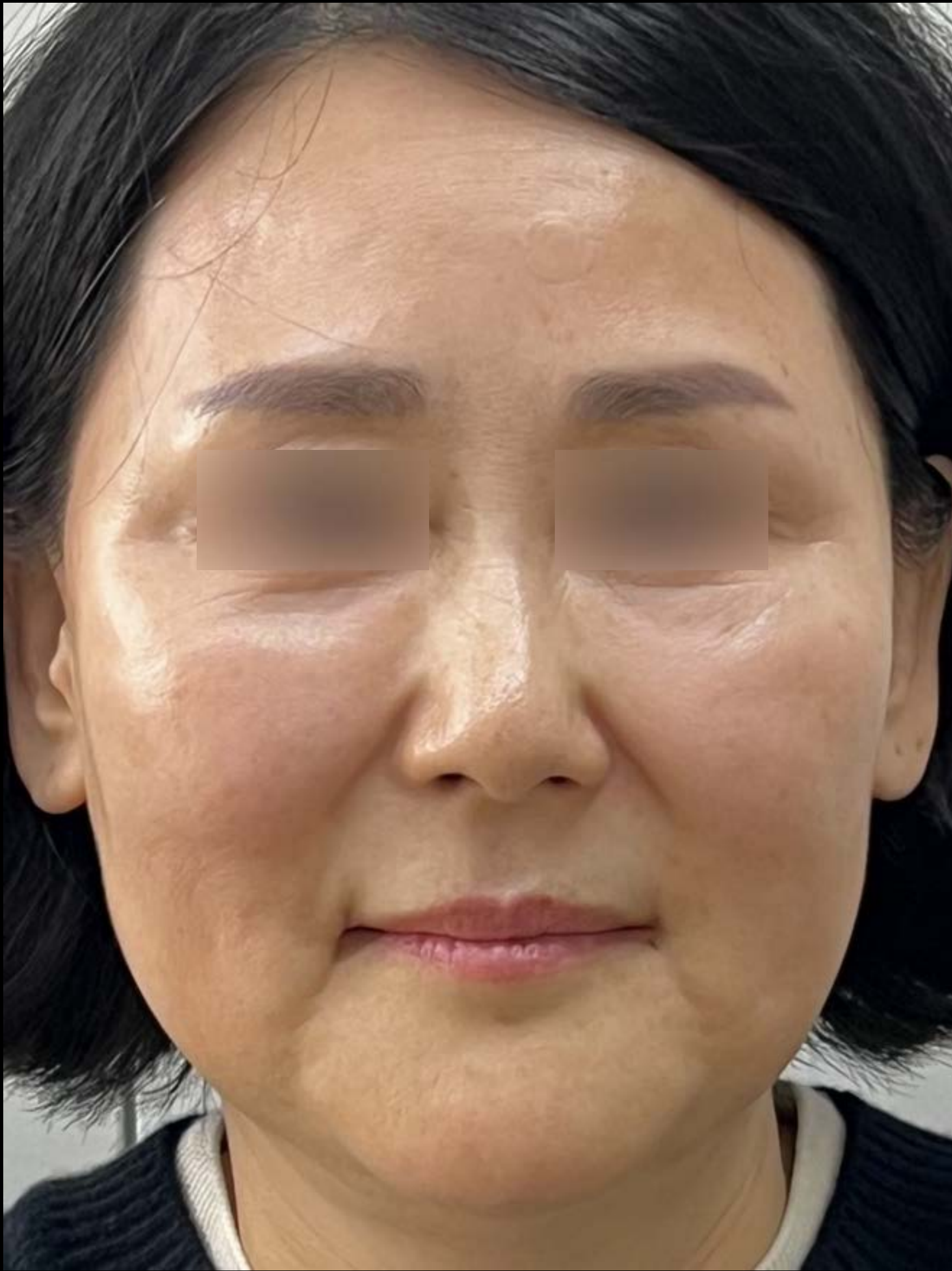Dentium dental Clinic
SM Chung



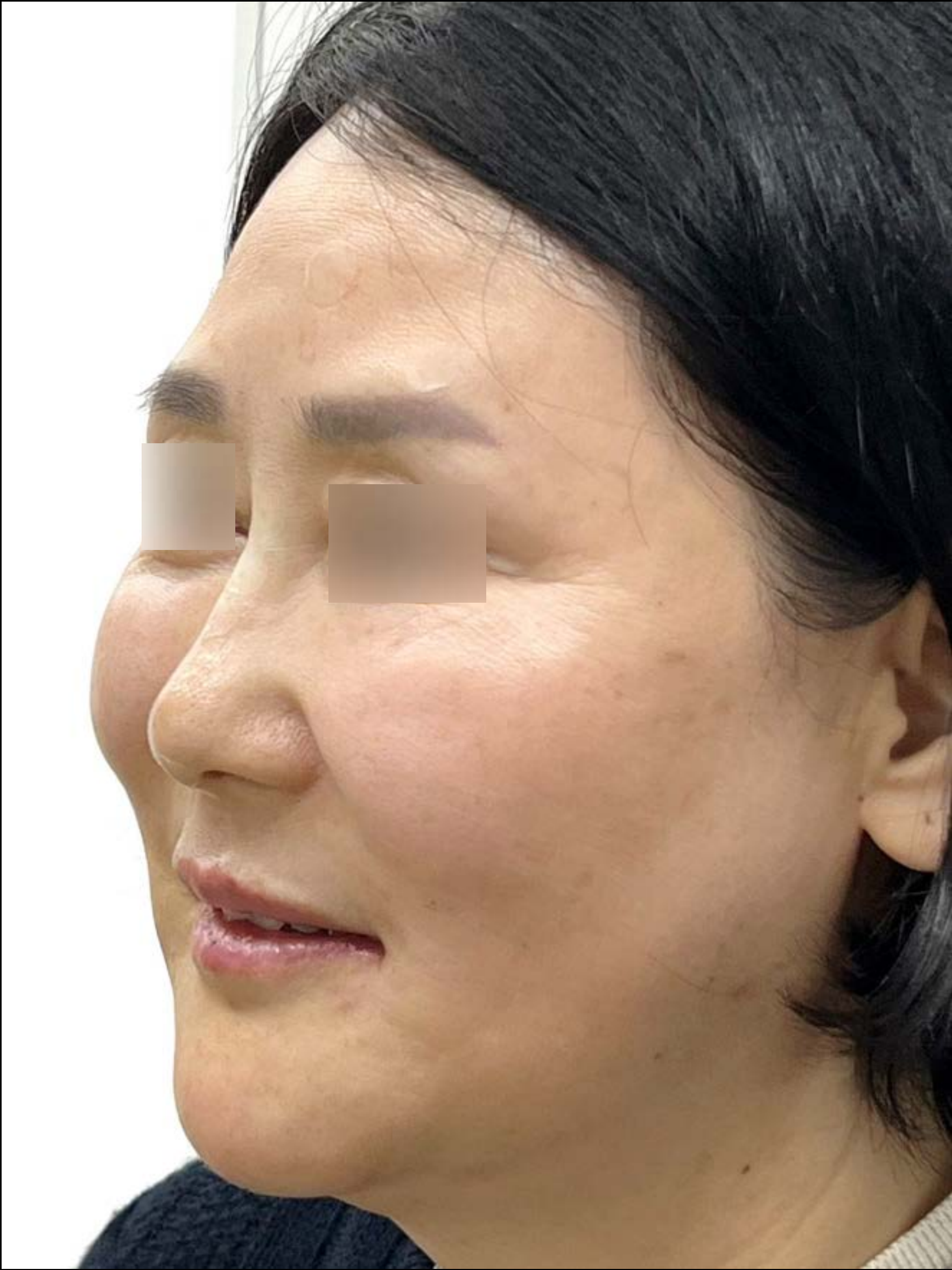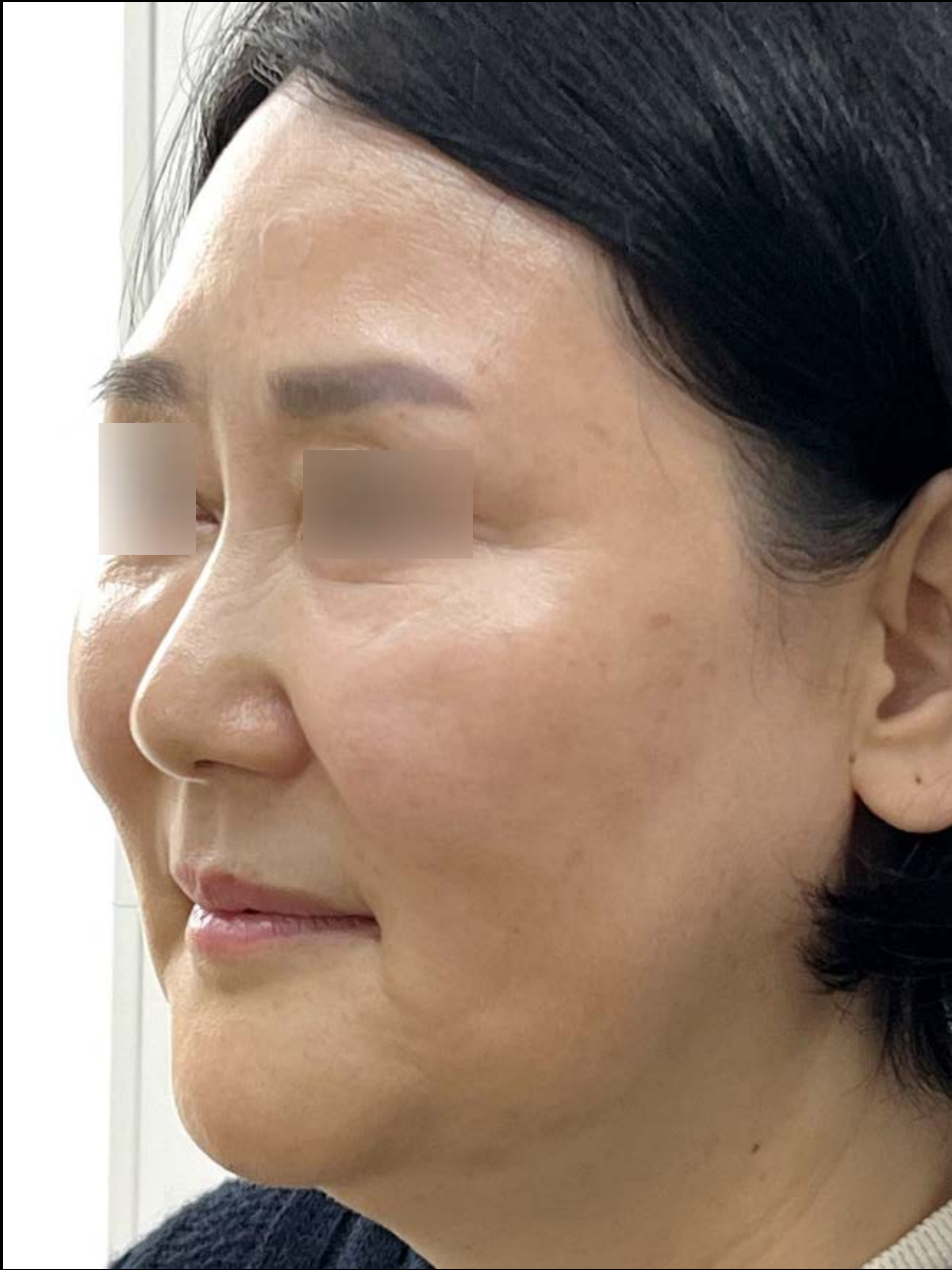*Long term
Stability*

**** 42p Filler VOD 1**

Before & After

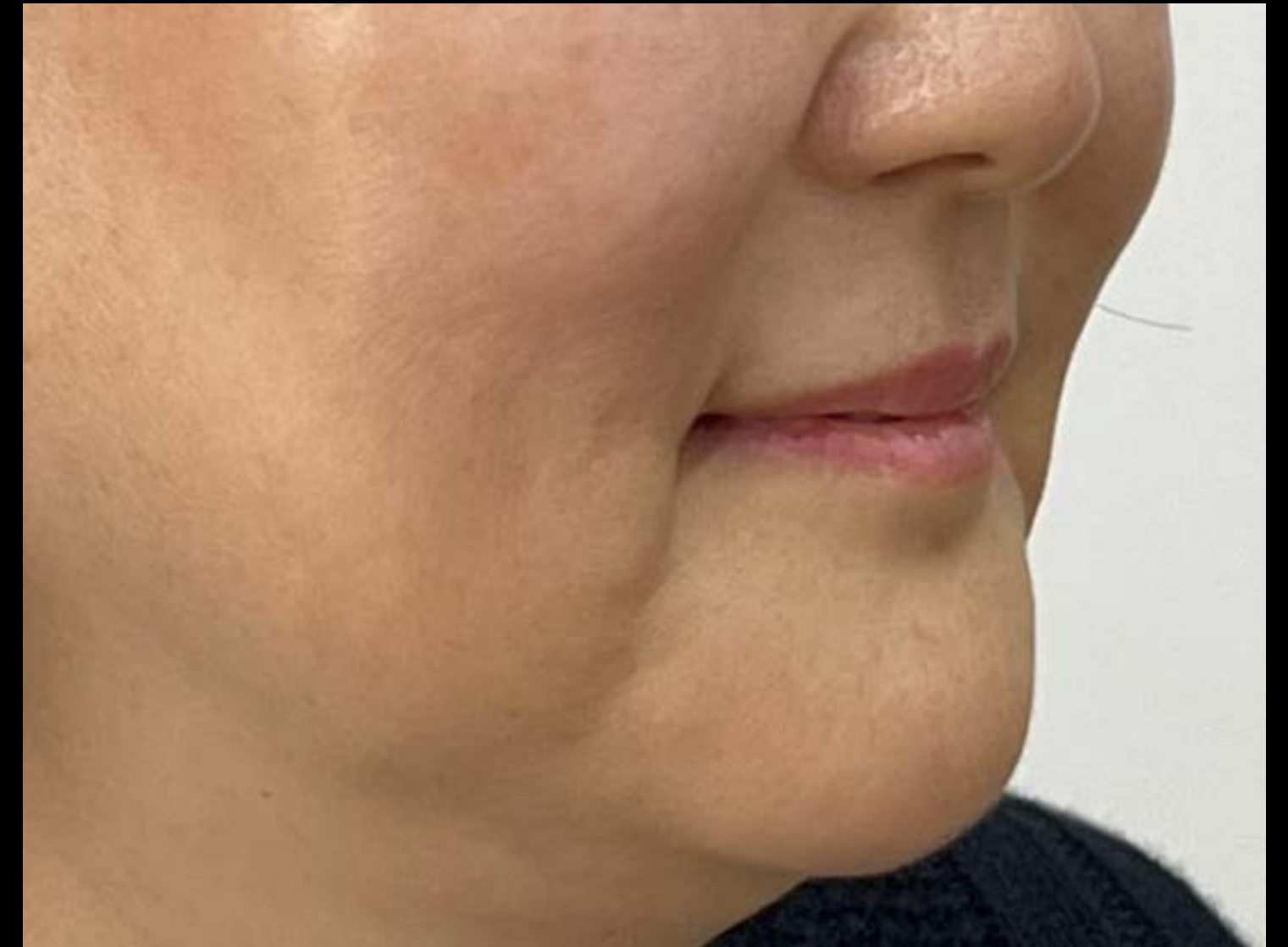
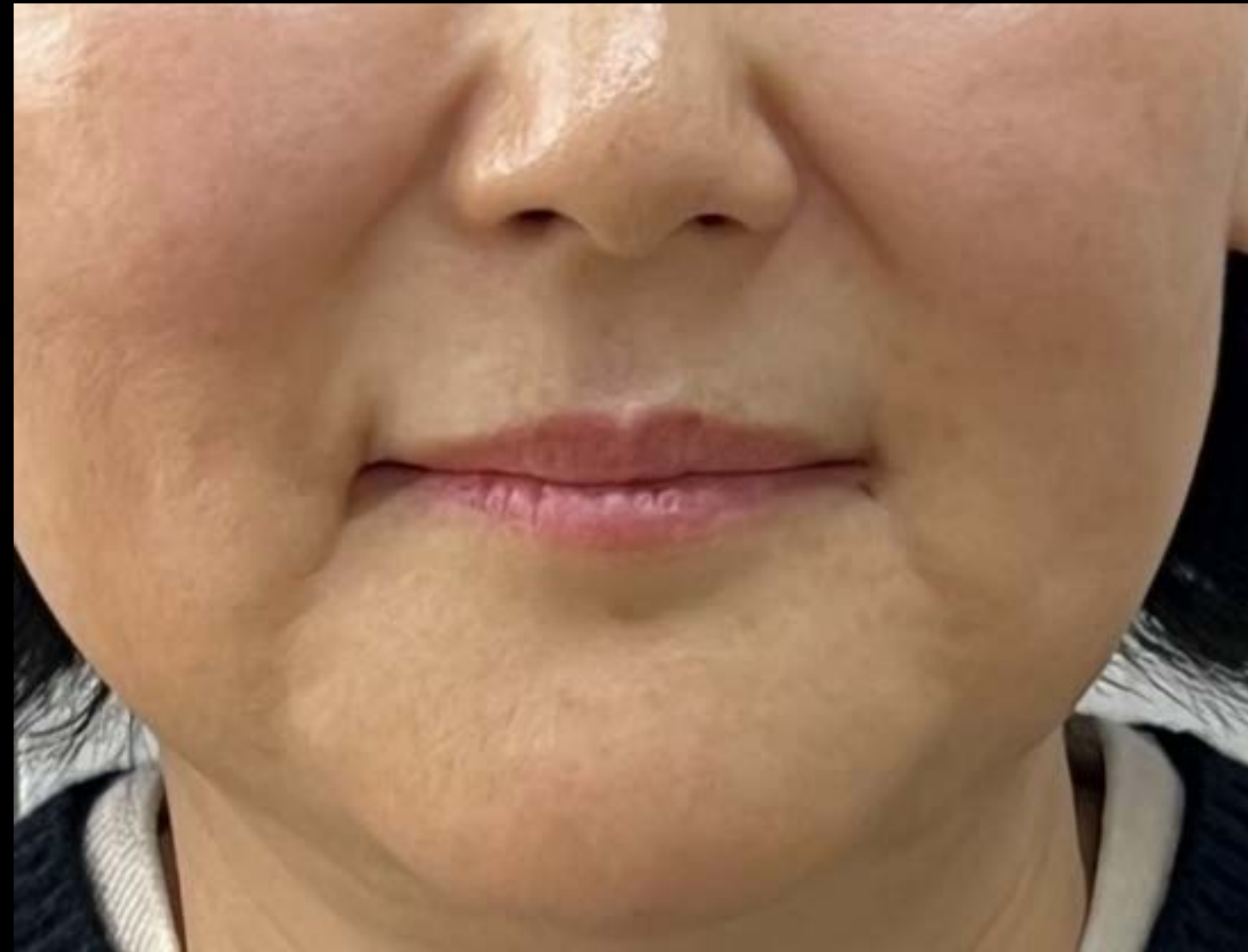
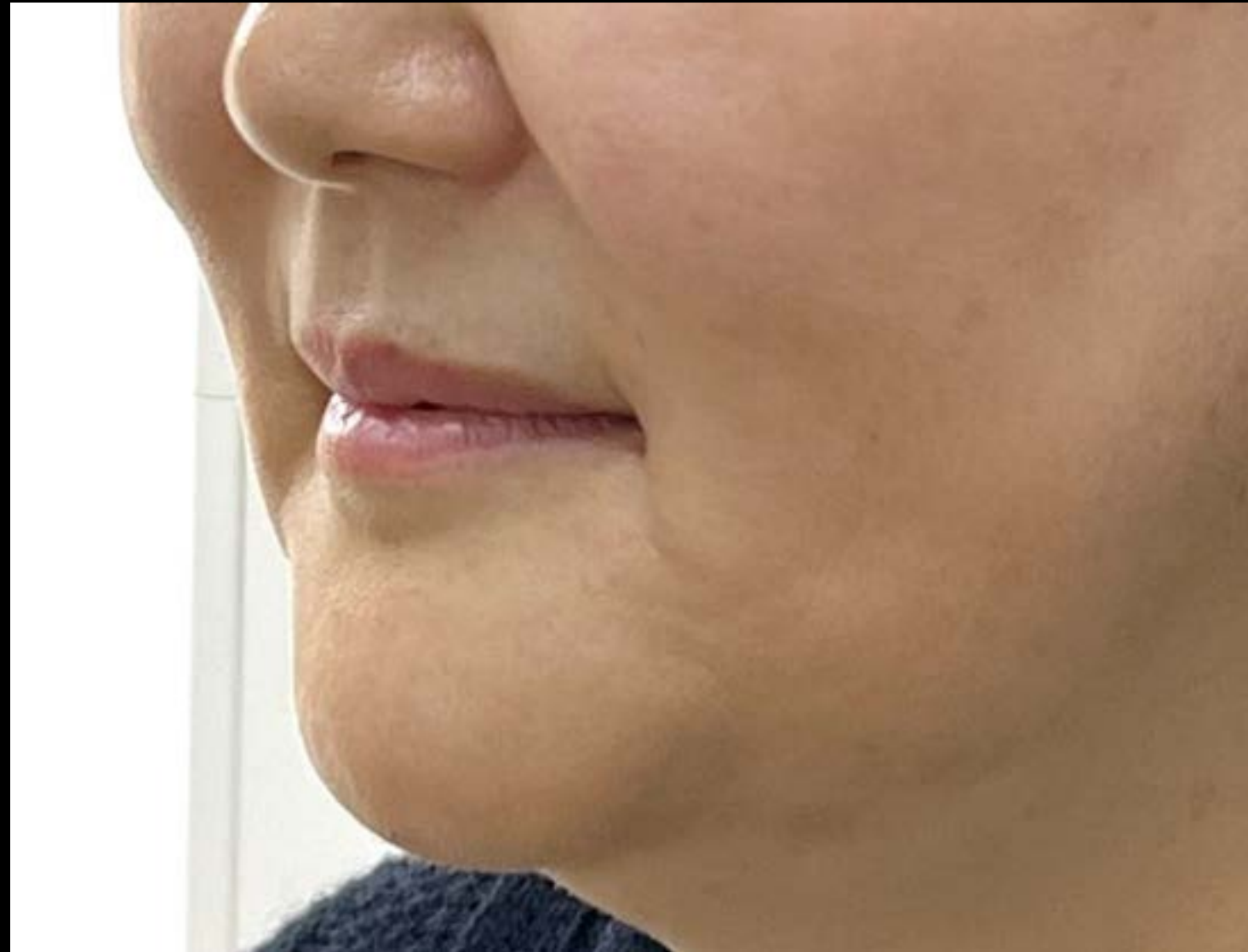Before & After

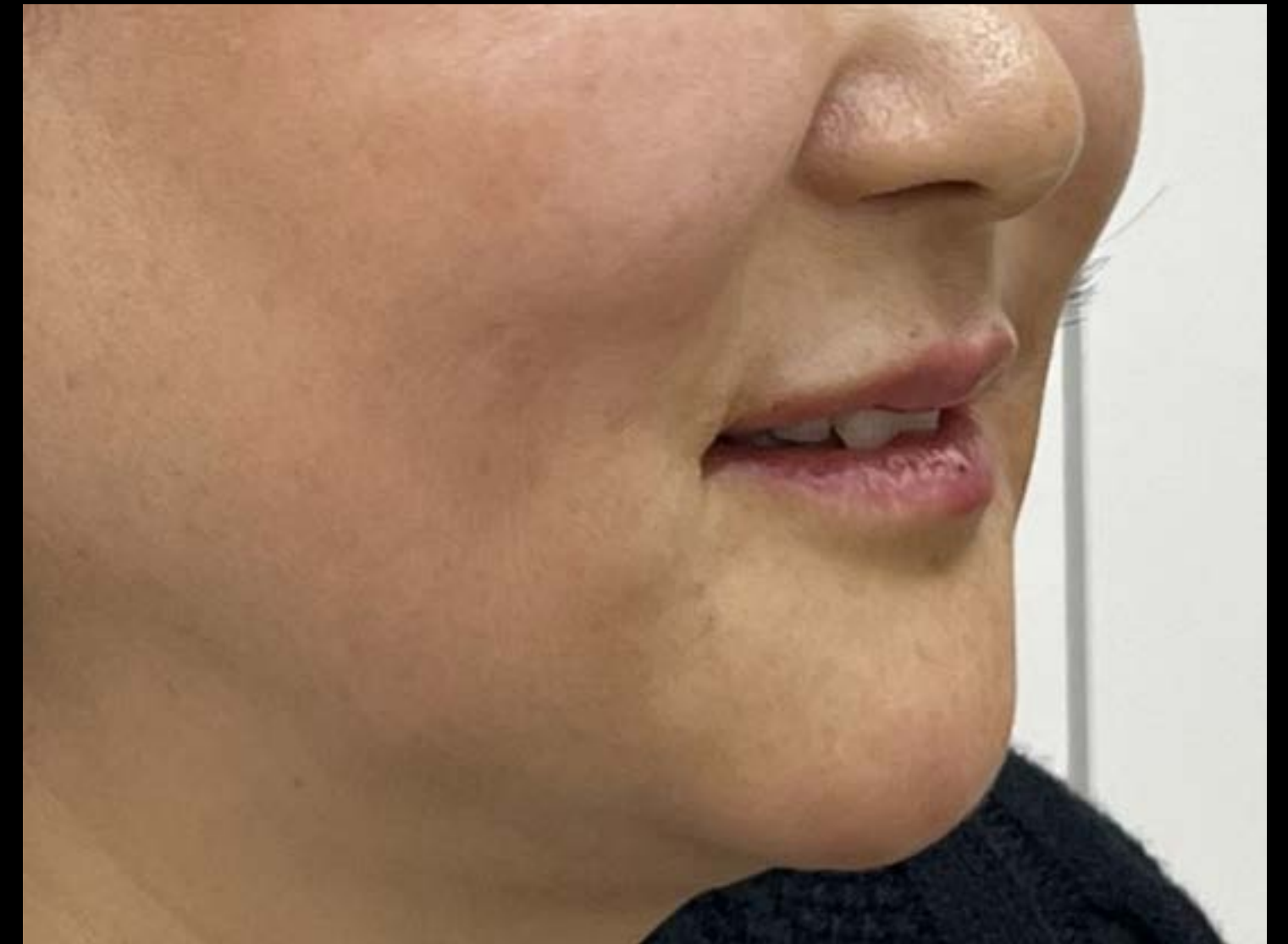
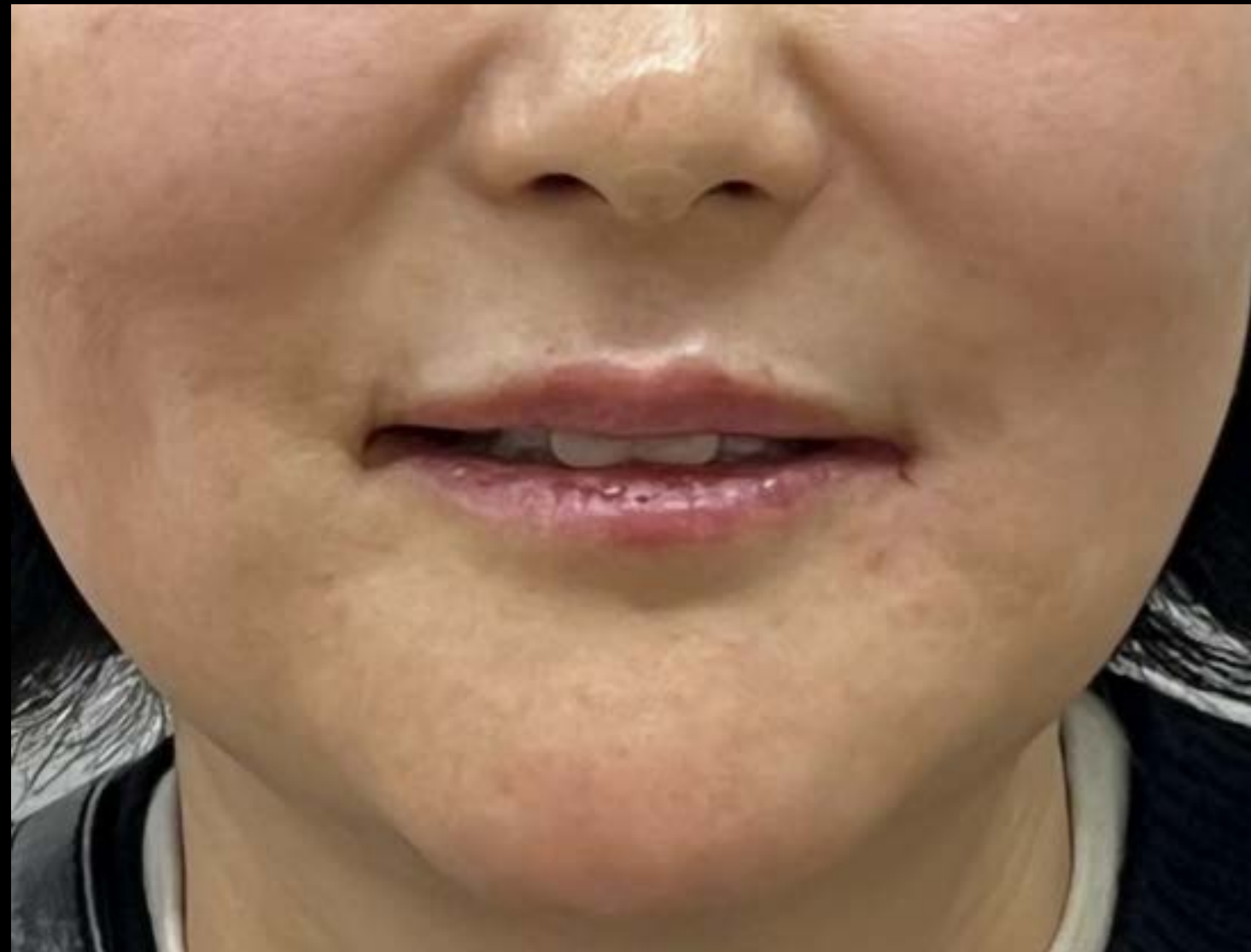
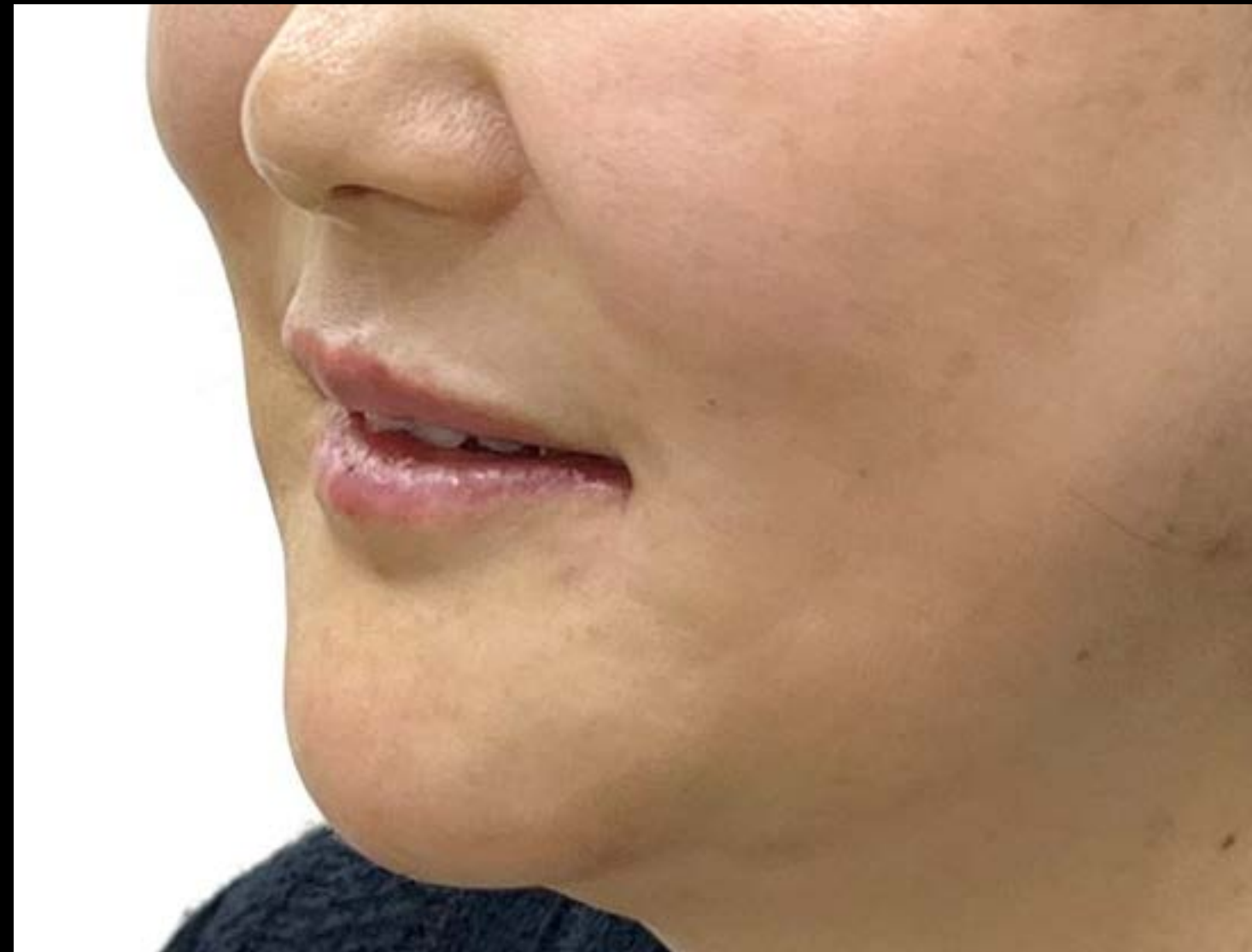Clinical case : Nasolabial folds & Marionette Line & Lip

Before



After



Contents

Bright implant

Narrow and short implants

Bone regeneration materials

Simple and exact digital concepts

Filler and toxin in dental field

bright Implant

2002



2007



2009



2013




2014





2019

NEW





bright Implant

“The Next in Implant?”



Minimal Surgery

Simple Digital

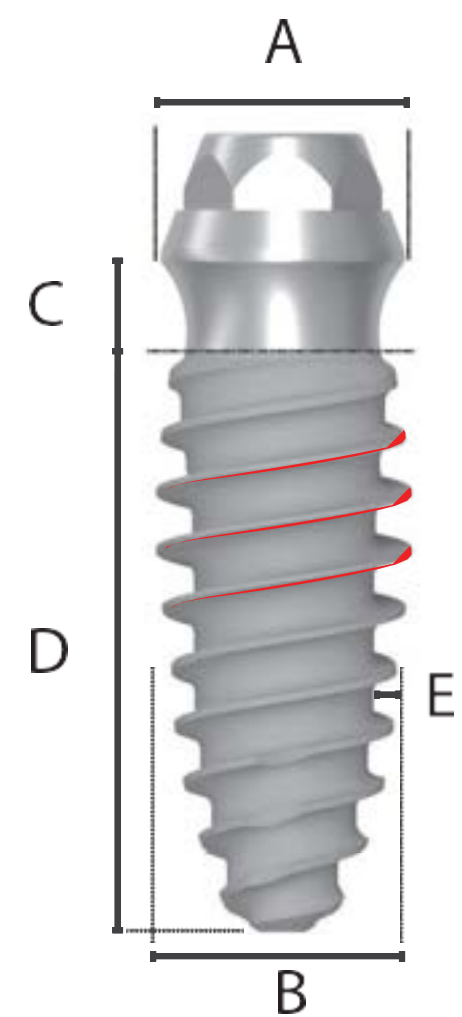


Bone Level

Tissue Level








Tissue Level

Unit: mm



Unified Feature


- Platform Diameter : Ø3.8mm
- Gingival Height : 1.5mm

Cap Color								
		Pink	Sky blue	Gray	Yellow	Green	Blue	Red
A	Platform Diameter	3.8						
B	Body Diameter	2.0	2.5	3.0	3.5	4.0	4.5	5.0
C	Gingival Height	1.5						
D	Thread Length	7.0 / 9.0 / 11.0 / 13.0 / 15.0						
E	Thread Depth	0.15	0.30	0.45	0.50	0.55	0.60	0.60

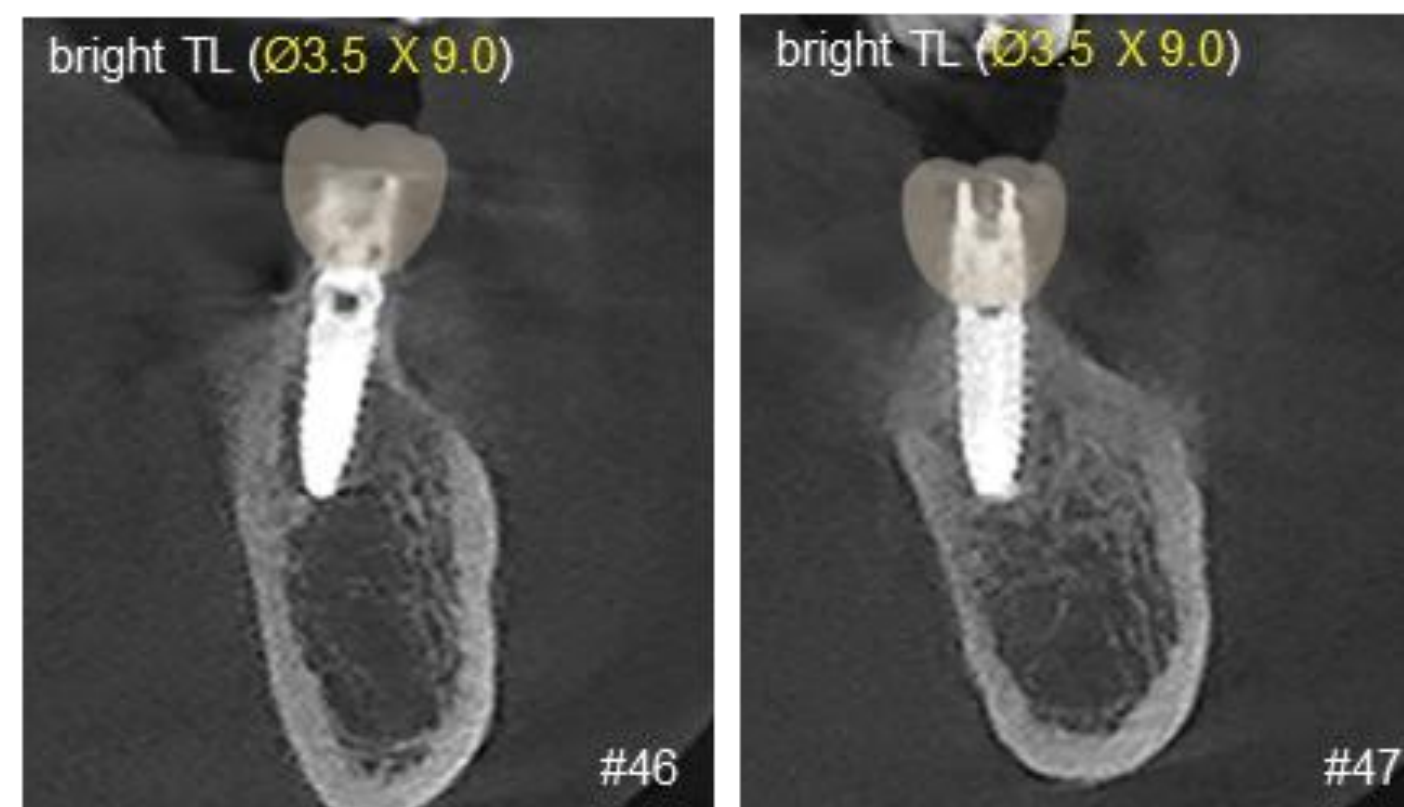
Tissue Level

✓ **Narrow, Yet Strong**

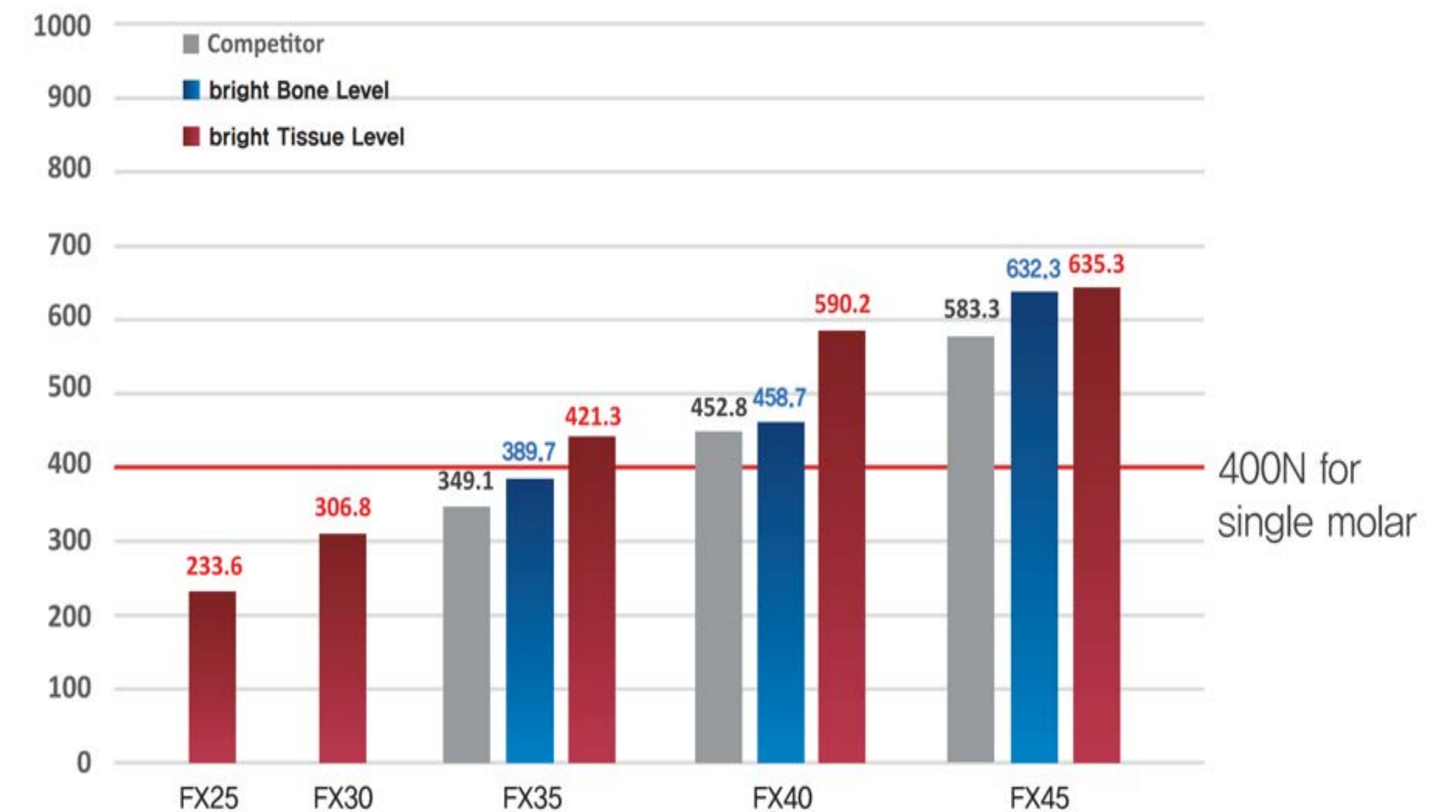
- Excellent Joint Stability



High Compressive Strength

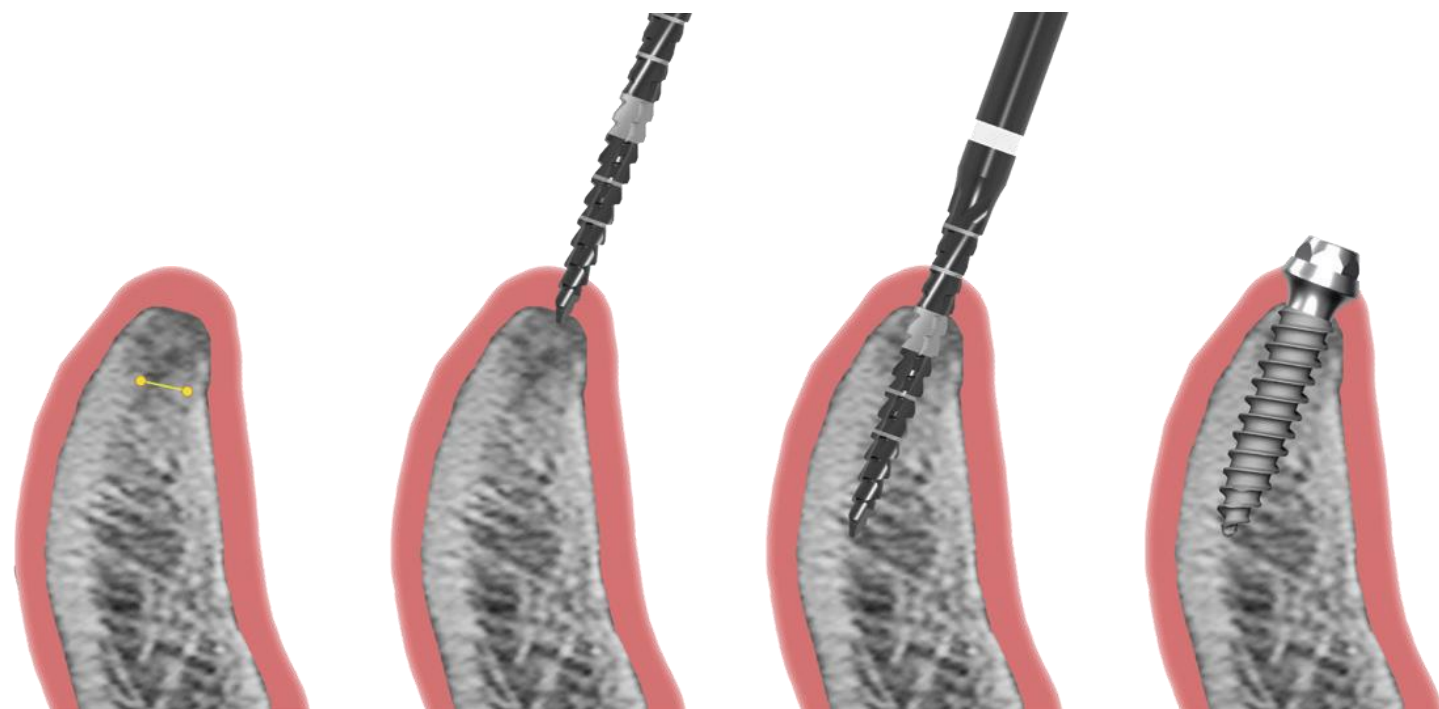

Ø3.5 Implant can be used in Molar Area



※ Caution : heavy bruxer or hard food bite

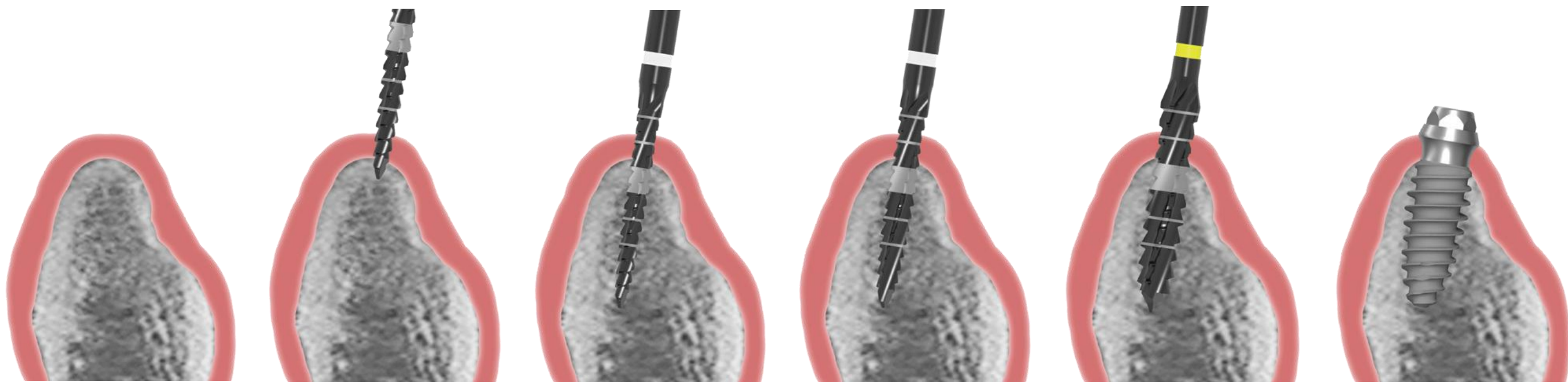
1



Cancellous bone width 2.46mm Scoring Guide Drill Ø2.5mm Fixture Ø2.5mm

Drilling and Fixture Insertion
in the Cancellous Bone Only

2



Cancellous bone width 3.55mm Scoring Guide Drill Ø2.5mm Final Drill Ø3.0mm Final Drill Ø3.5mm Final Drill Ø3.5mm

Simple Digital Prosthetics

Digital Abutment



Healing
Abutment



Scan Body



Impression
Coping



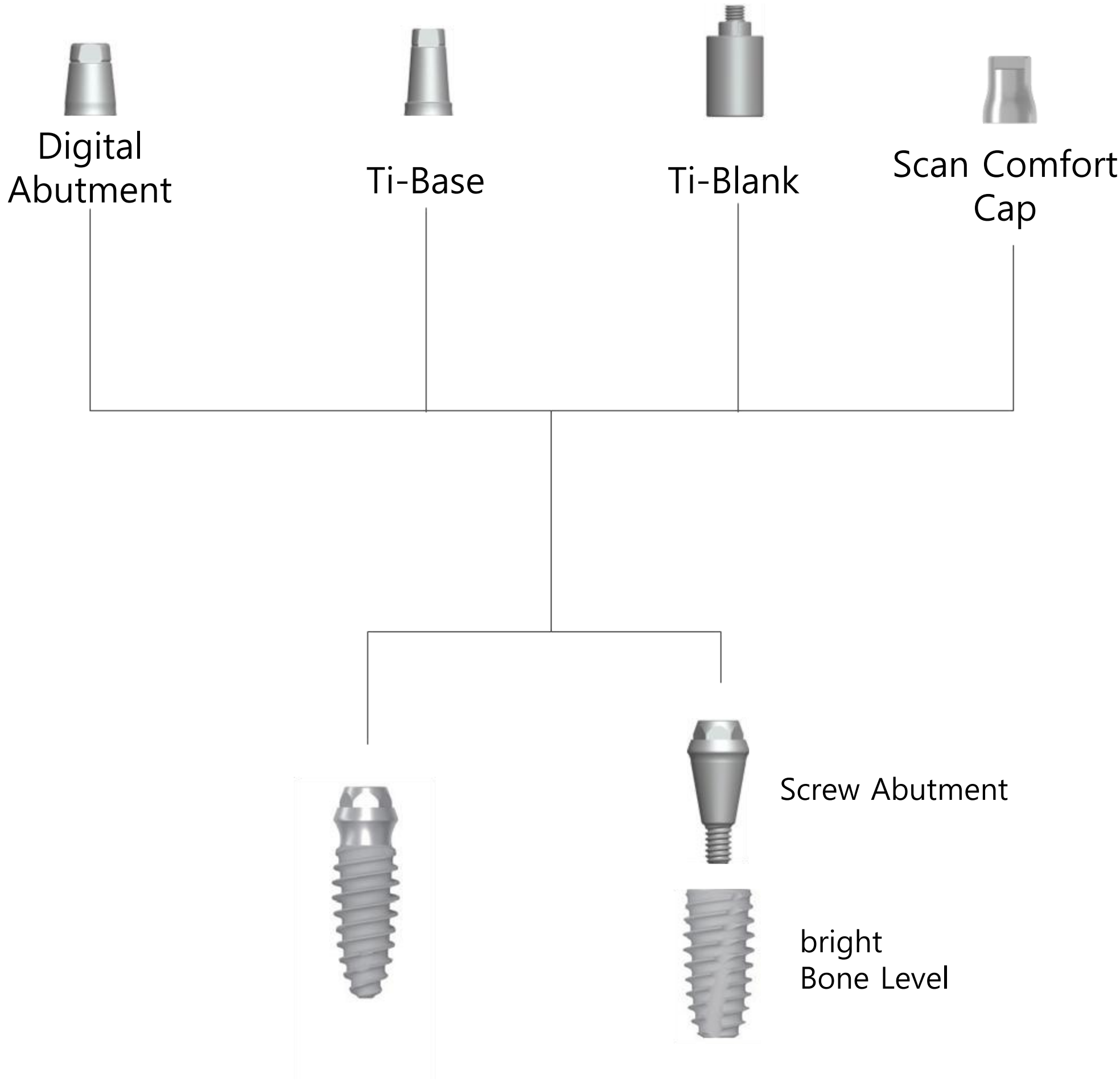
Permanent
Abutment

From healing to final prosthetics,
with **Only One Abutment**

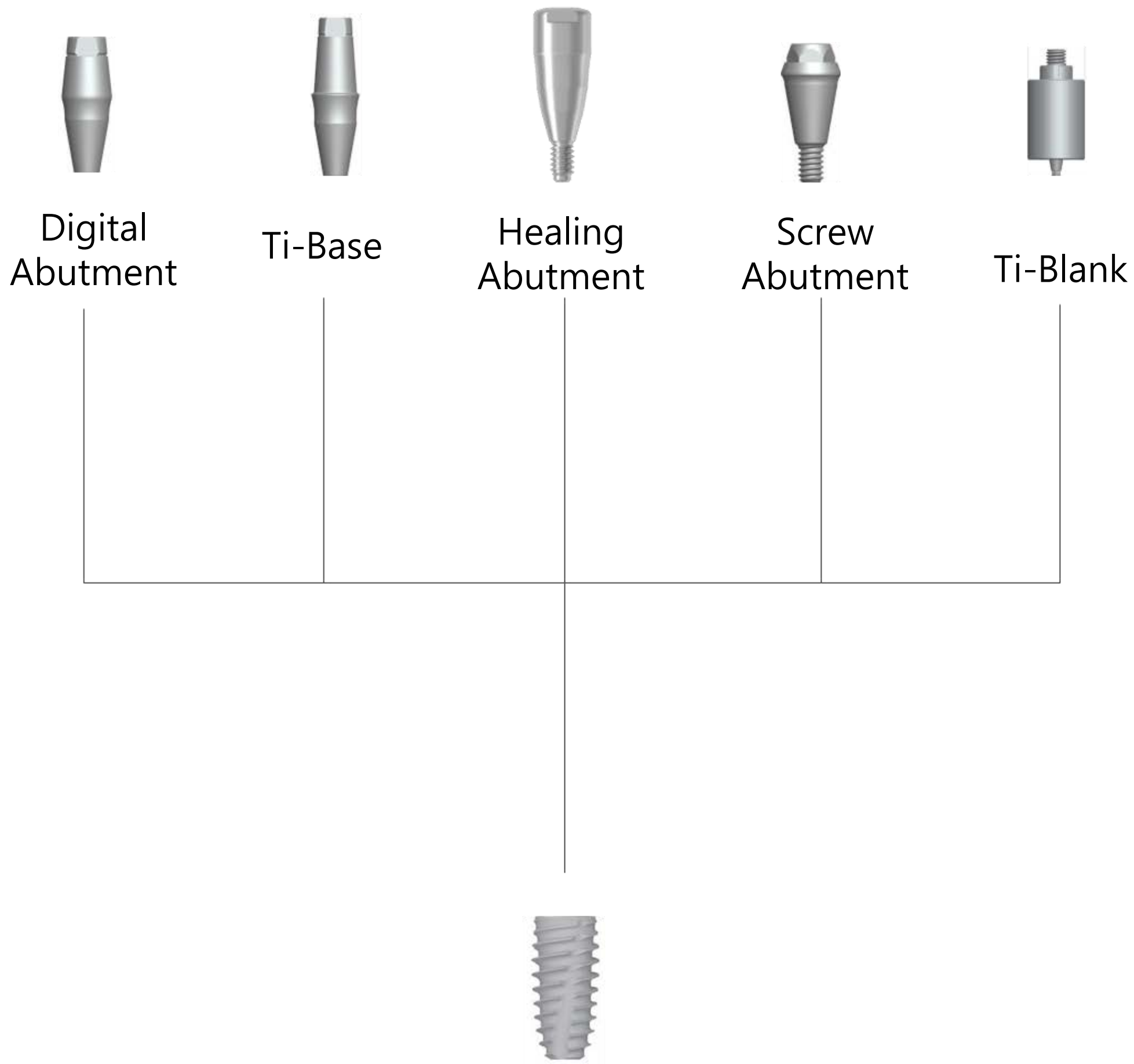
Simple Digital Prosthetics

Note. Total Abutment Procedure Line-Up

Tissue Level Abutment



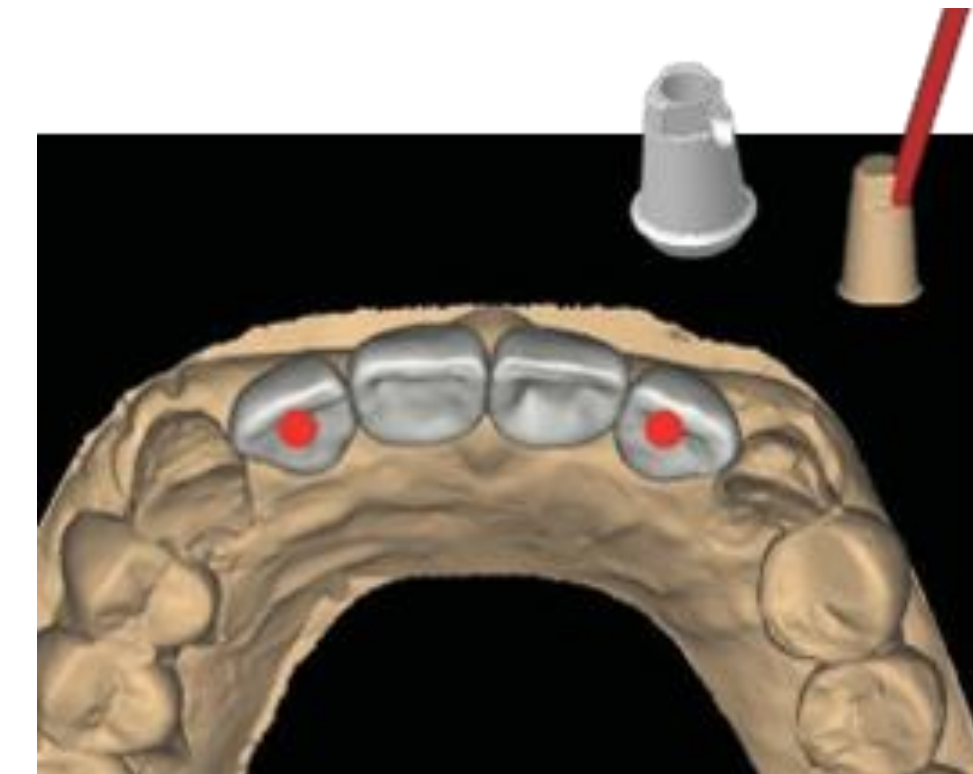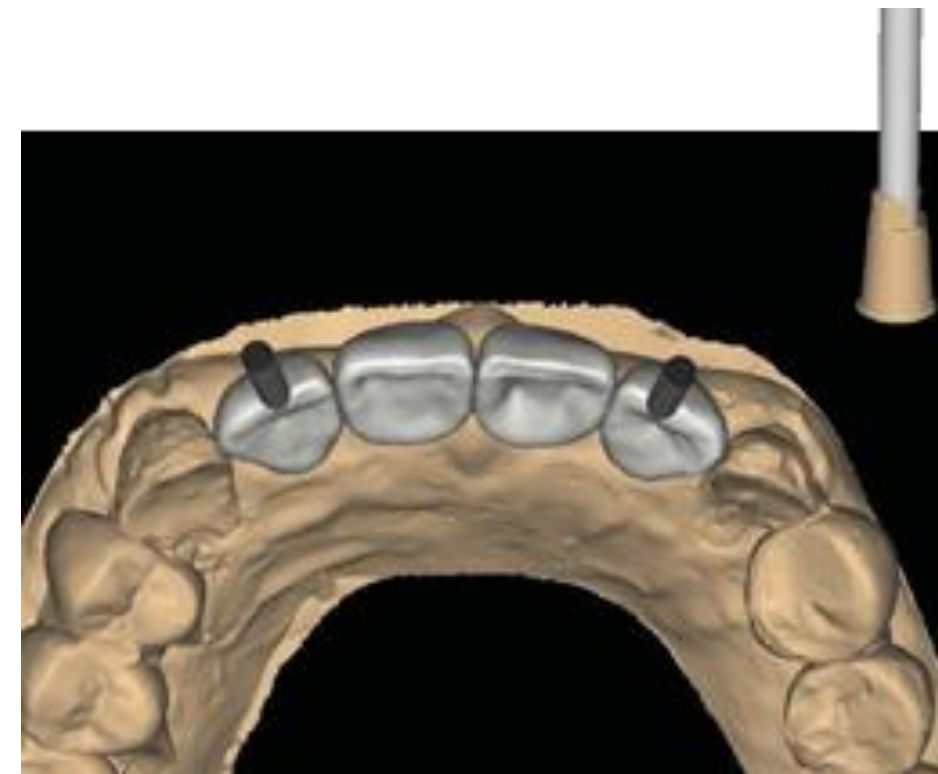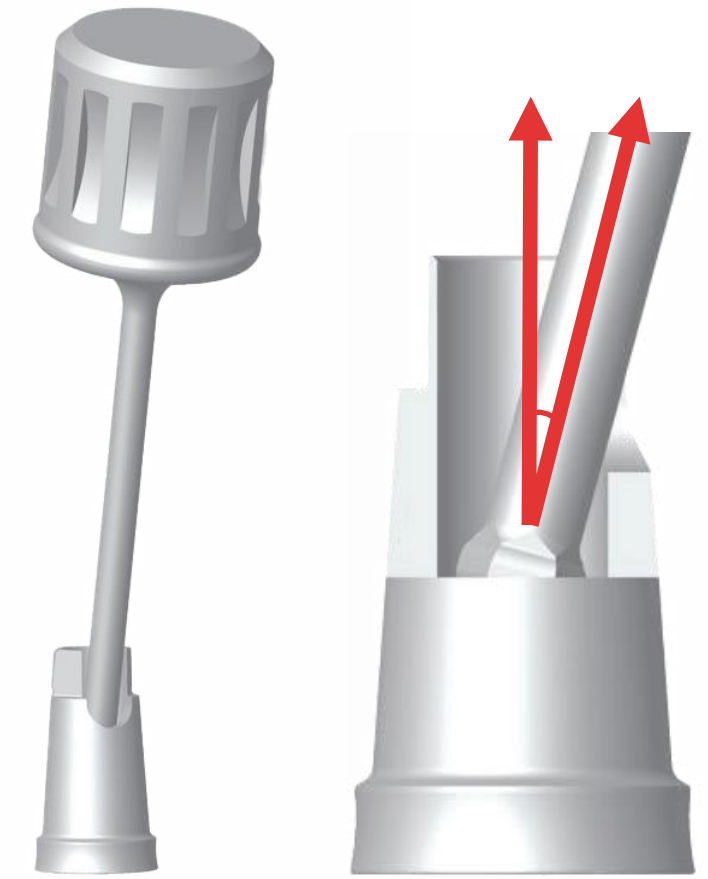
Bone Level Abutment



Ti-Base

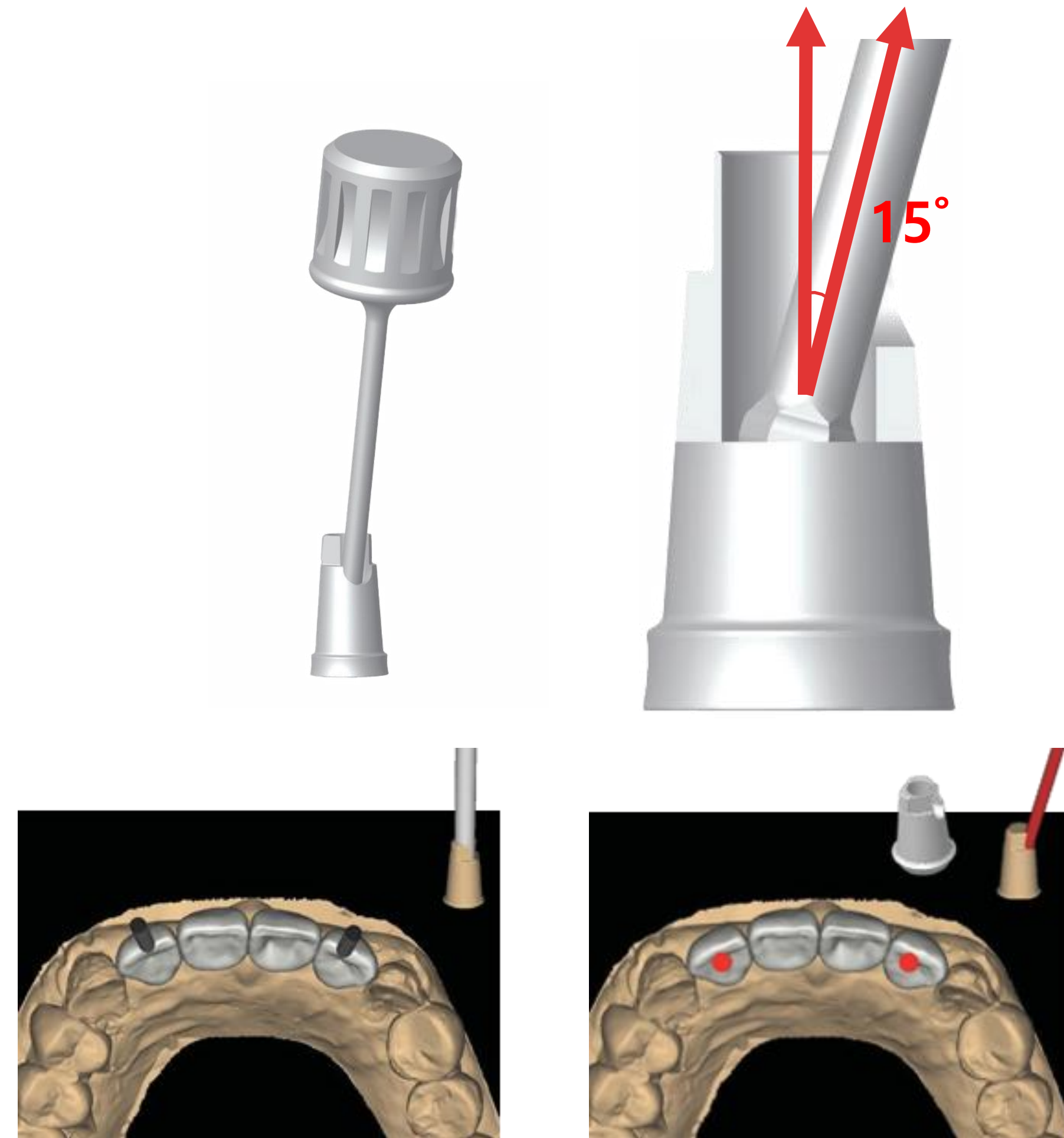



Angled Screw Driver allows
engagement tilted **up to 20°**



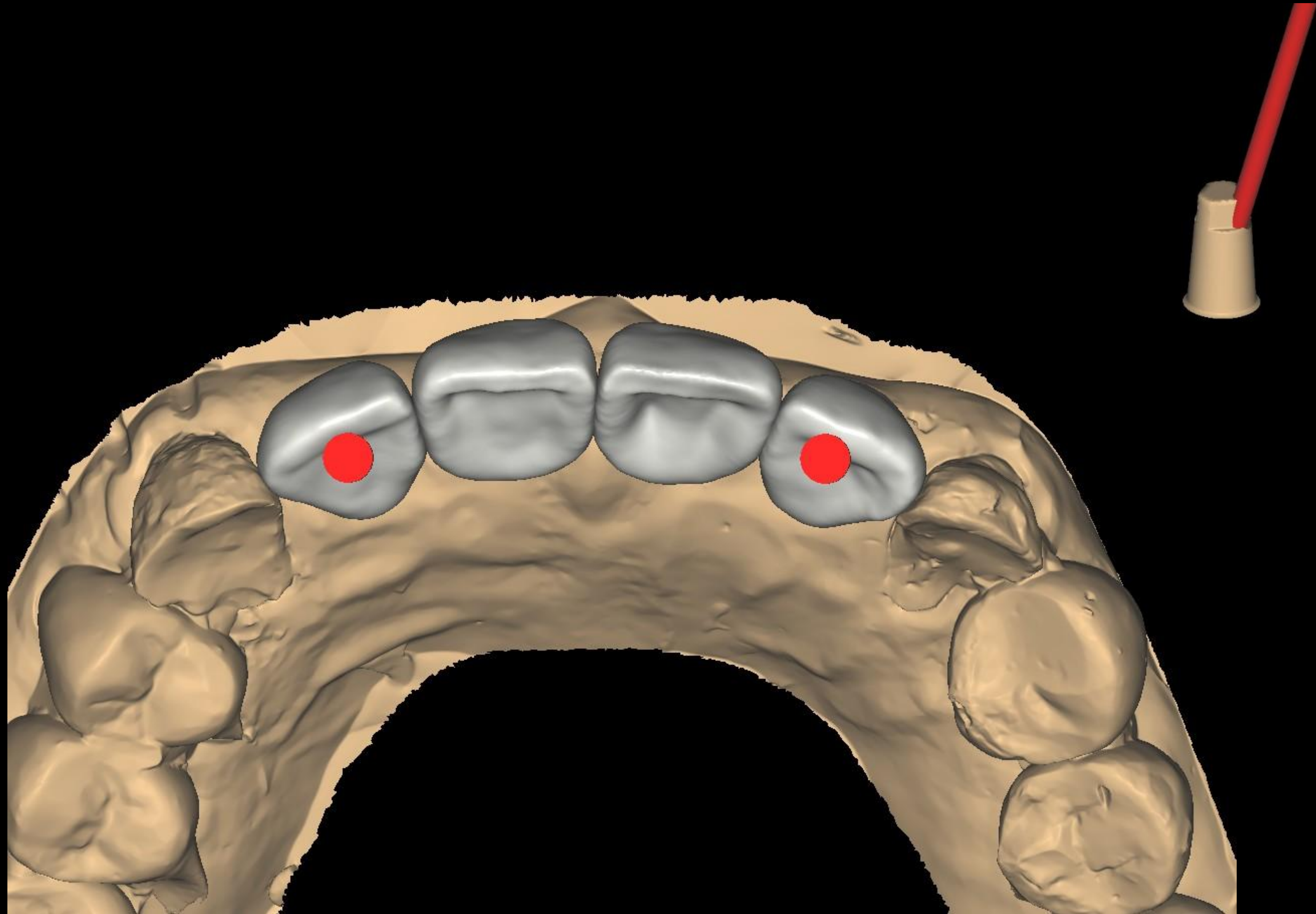
Simple Digital Prosthetics

Ti - Base



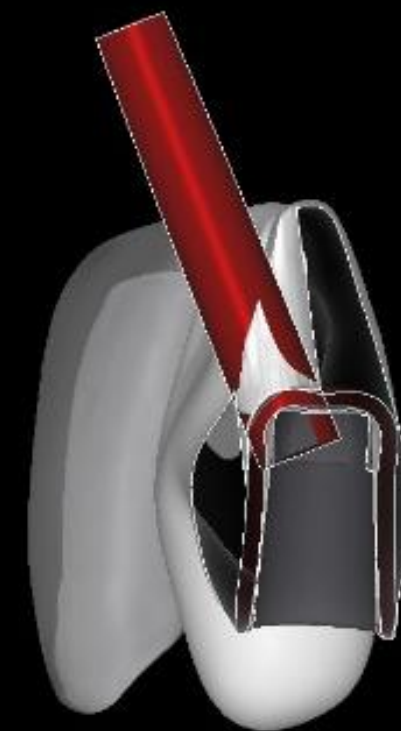
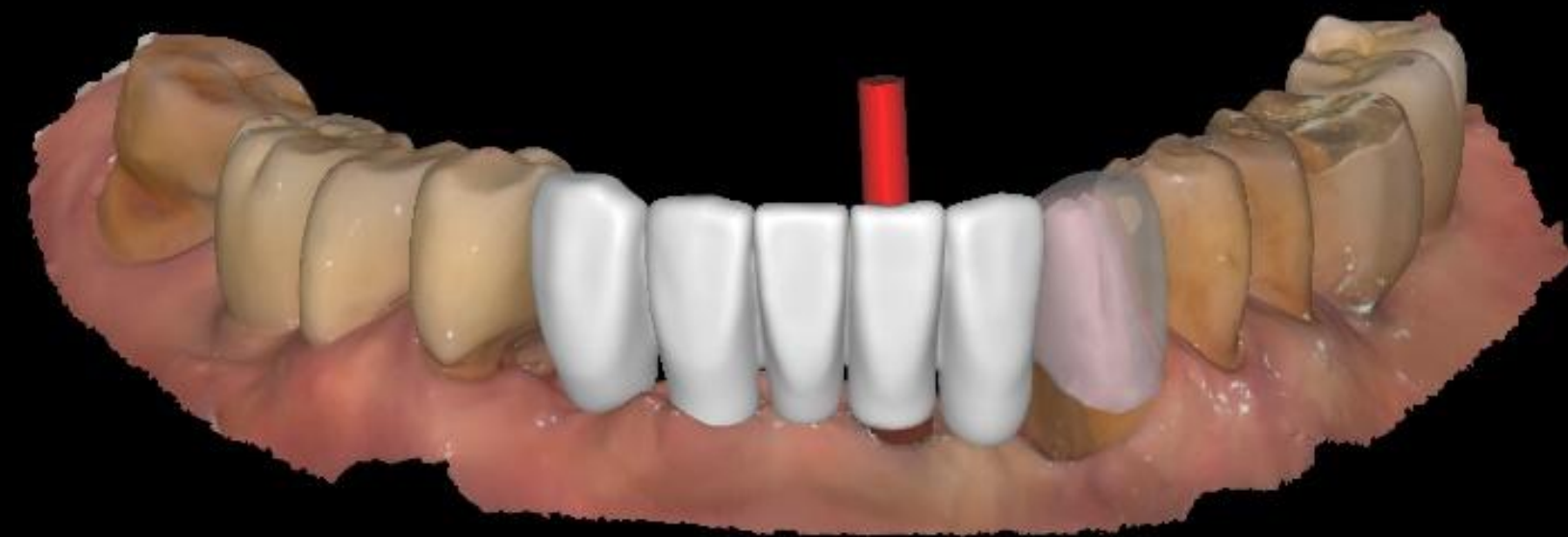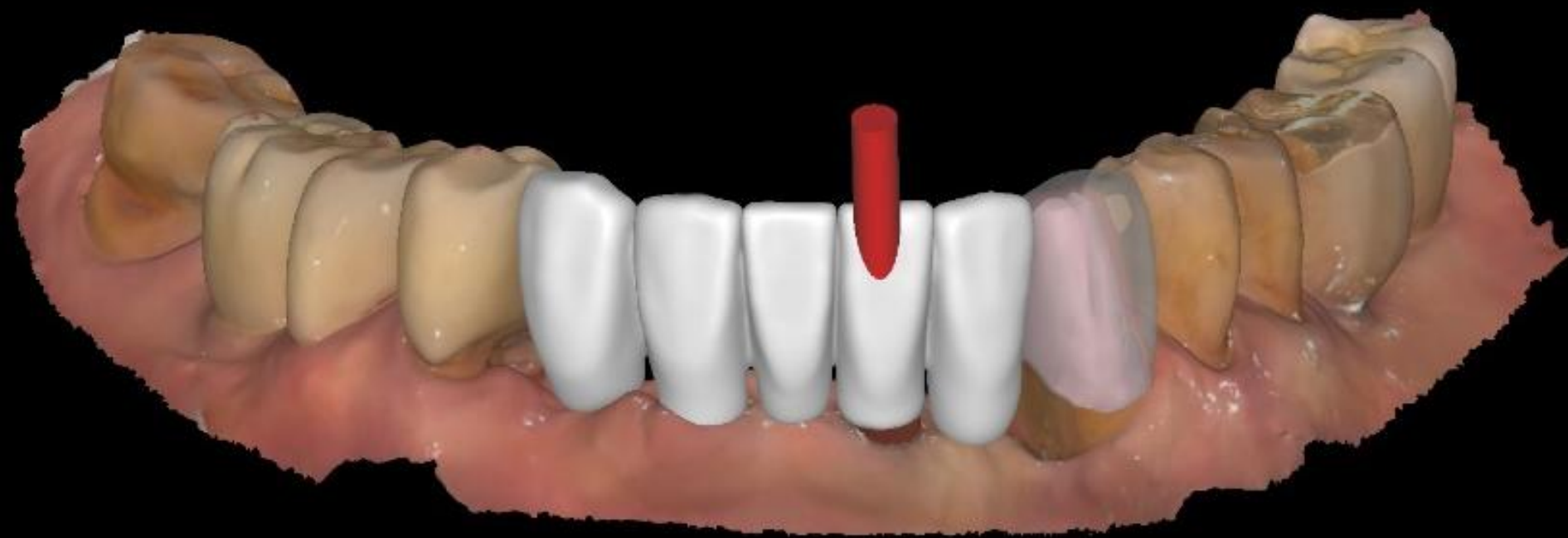Angled hex driver allows engagement tilted **up to 20°**

bright Implant Abutment



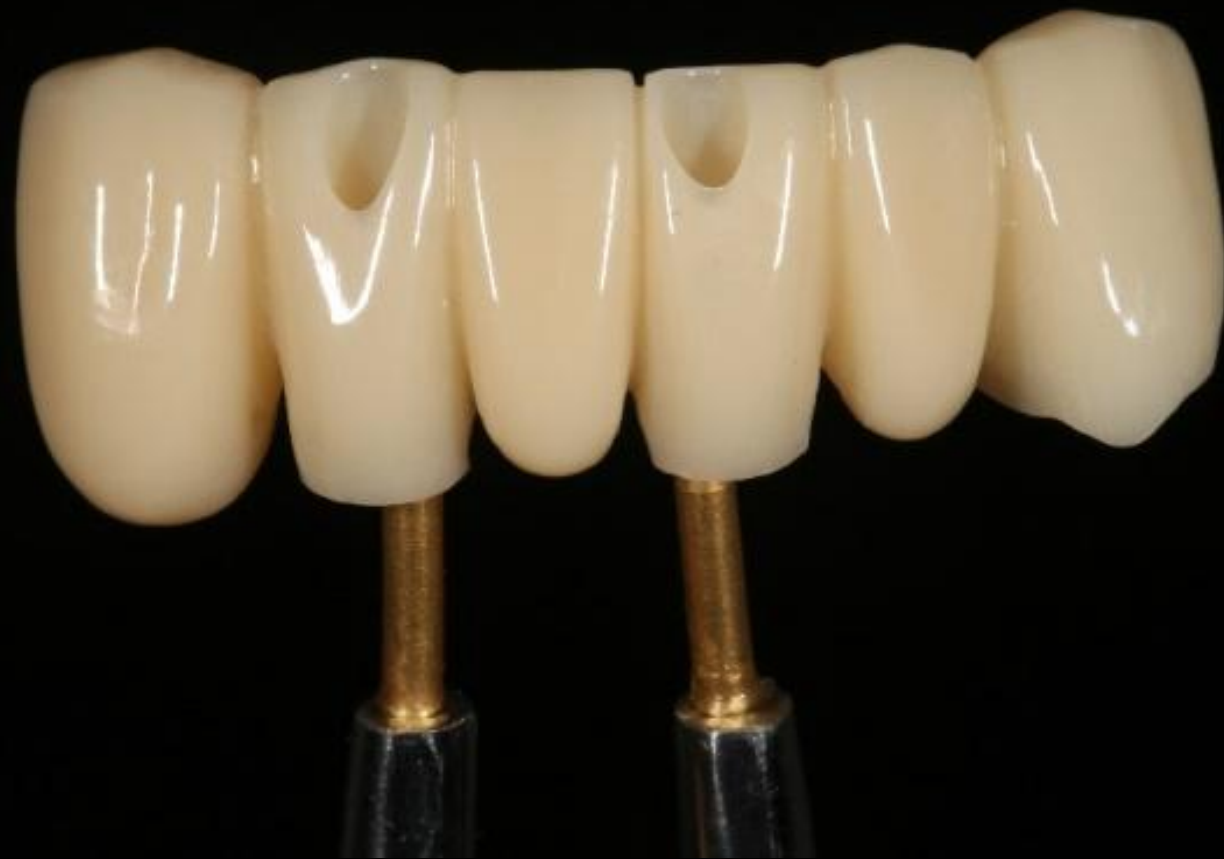Ti base Abutment

bright Implant Abutment

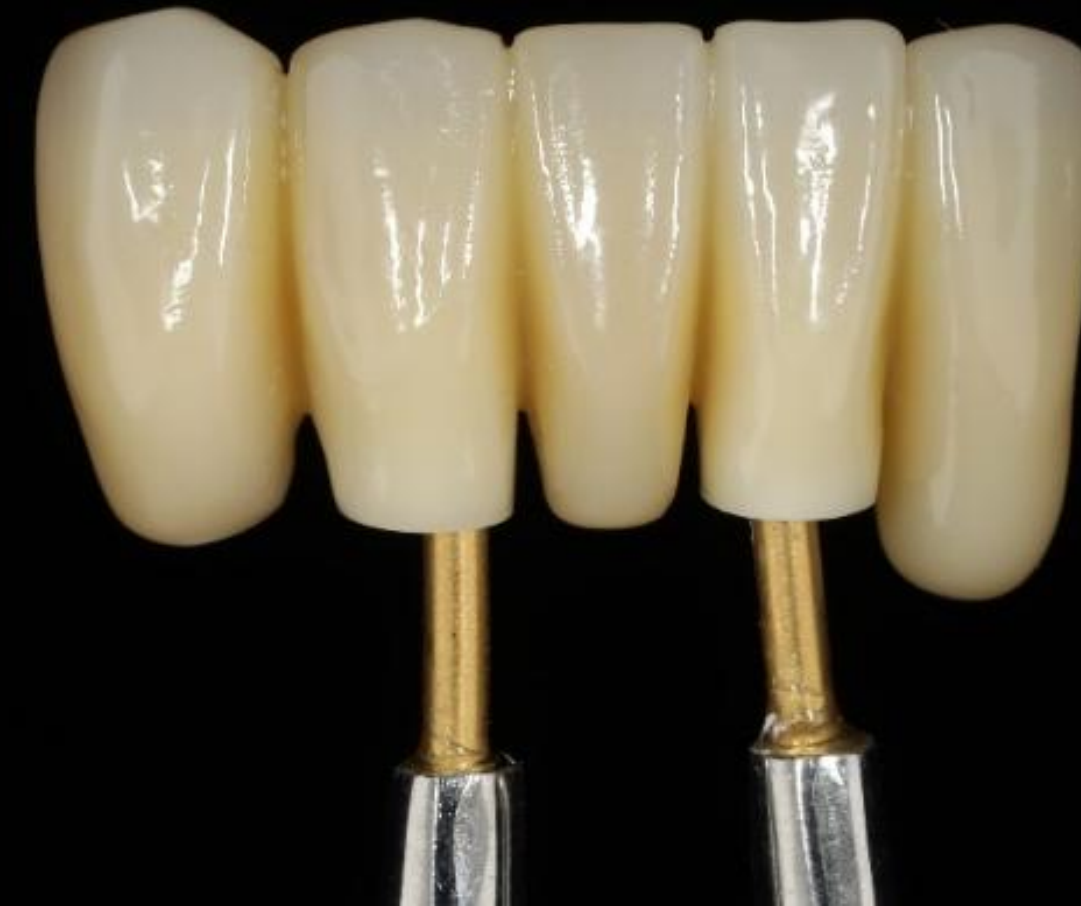

Ti base Abutment

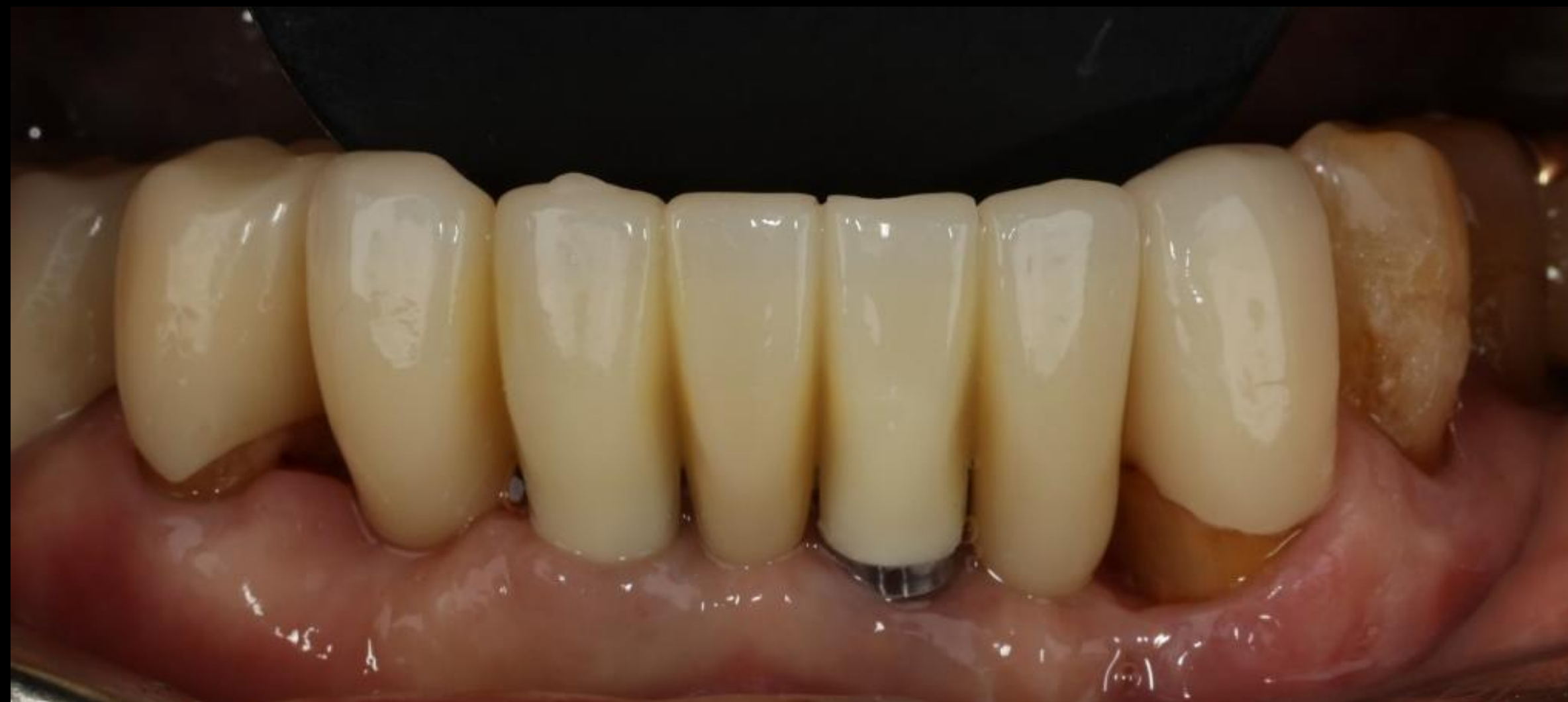bright Implant Abutment



Provisional crown straight hole



Final crown Angled hole

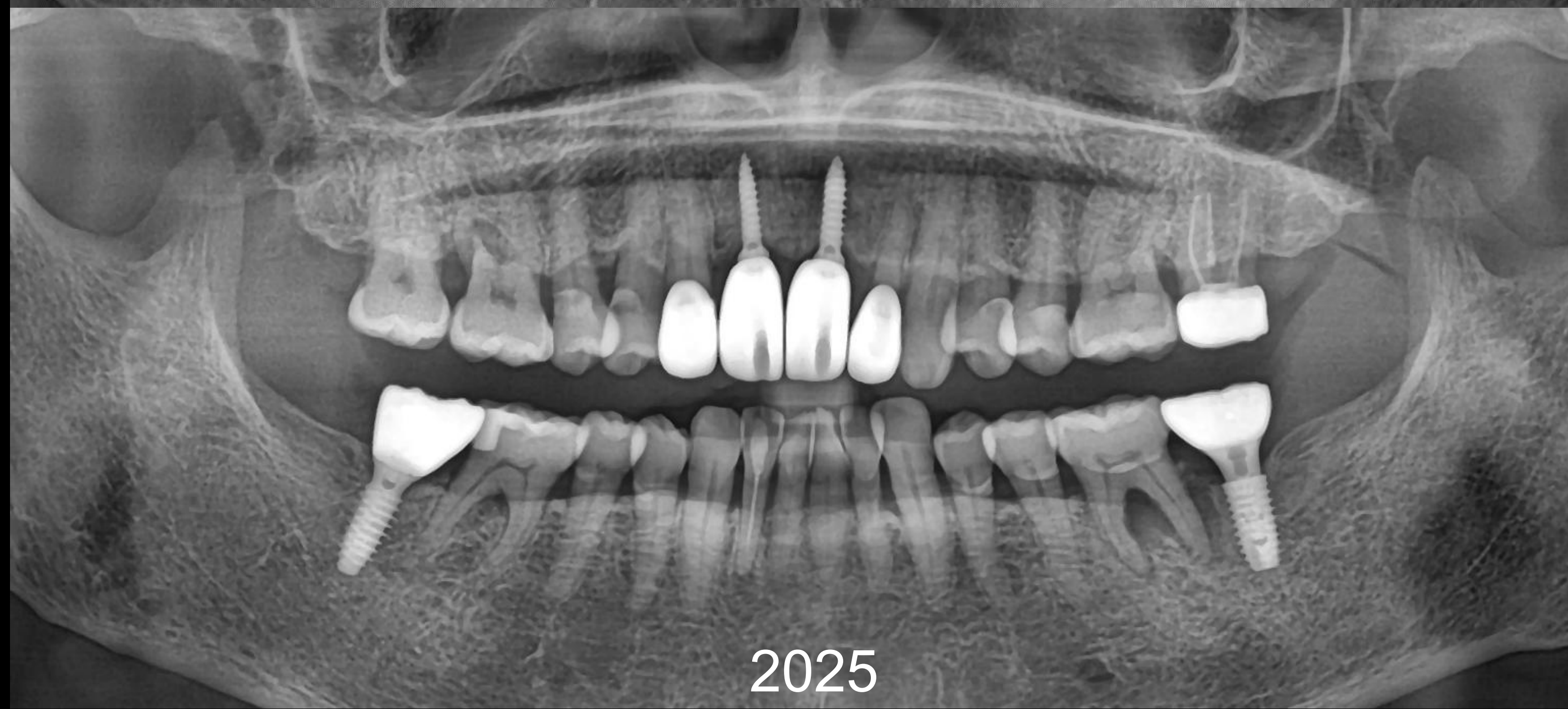
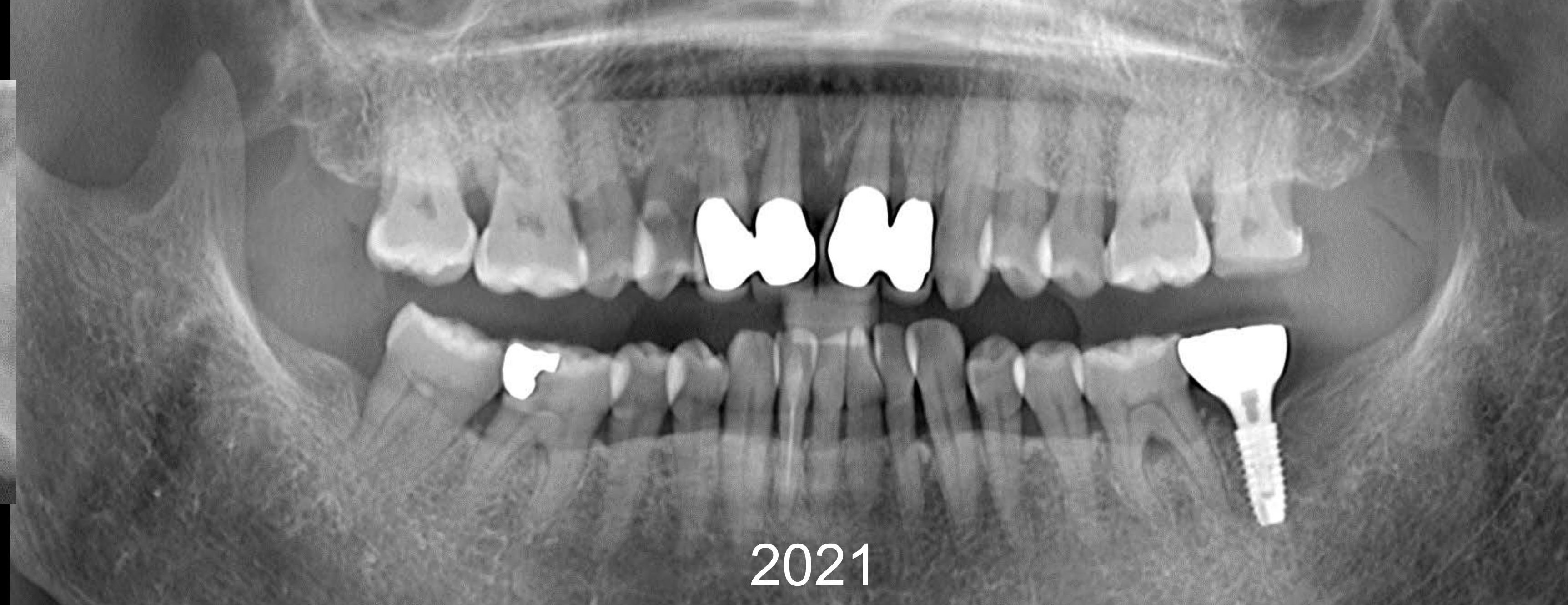
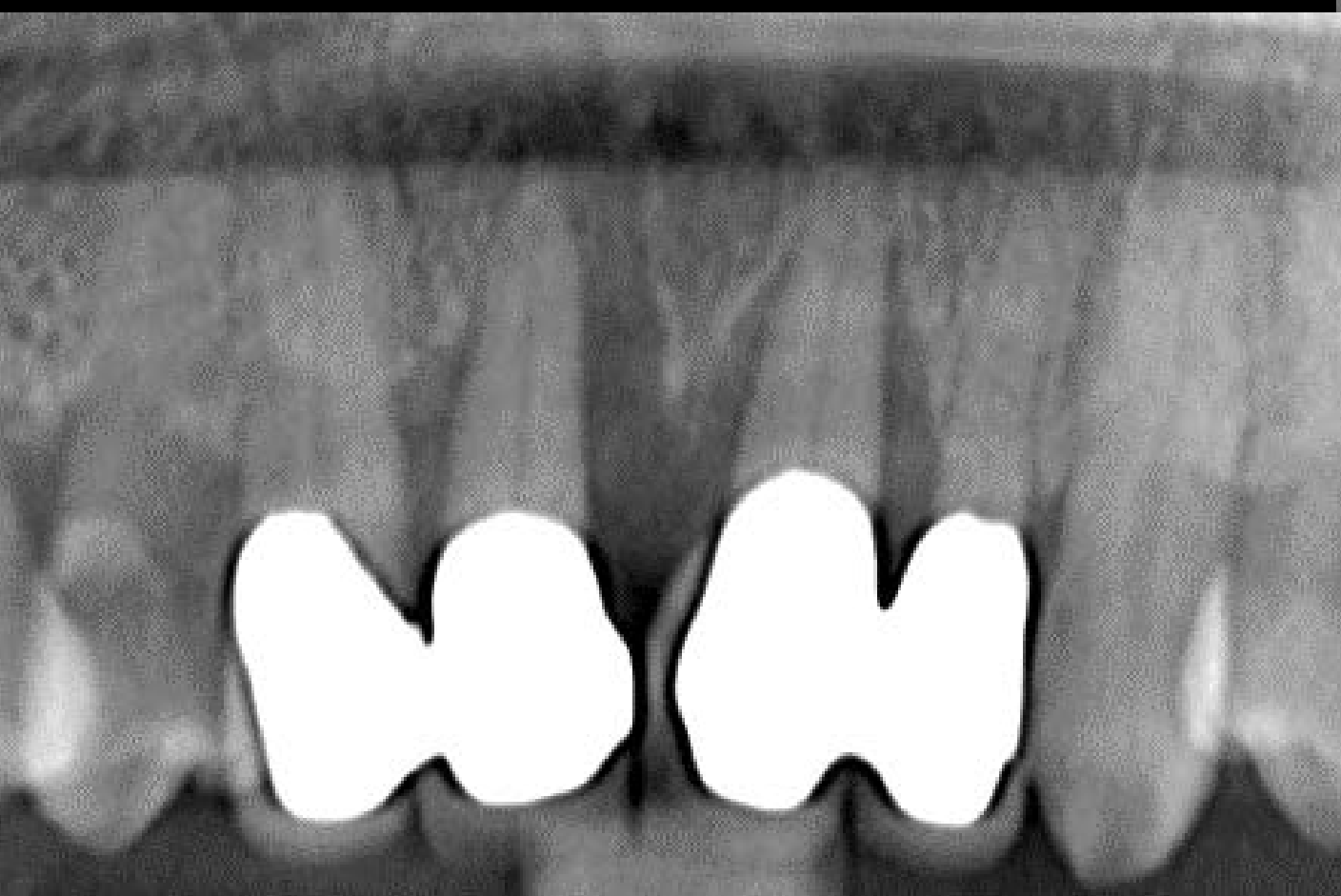

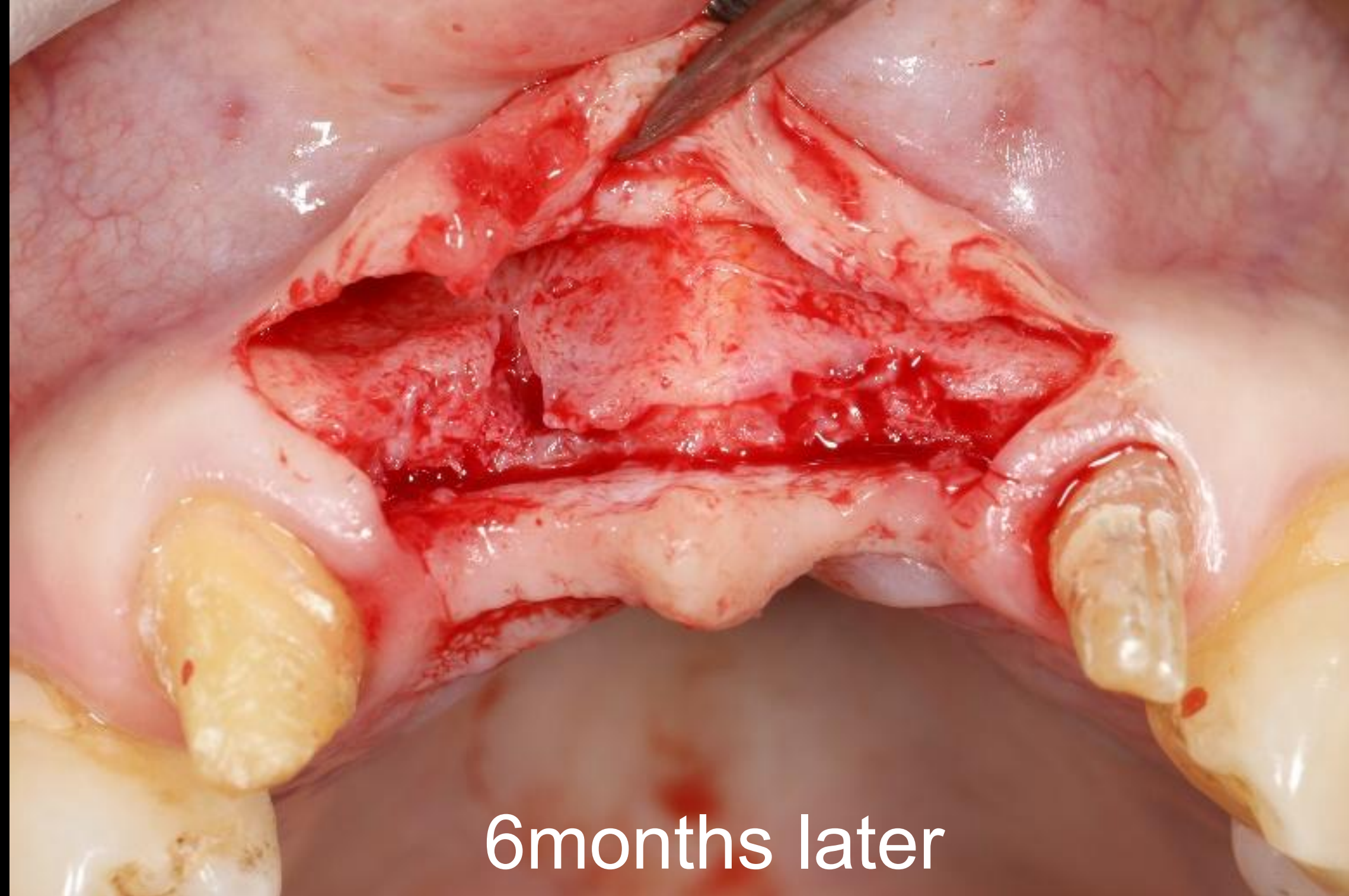
3 layer block x42ix31ix

Screw hole

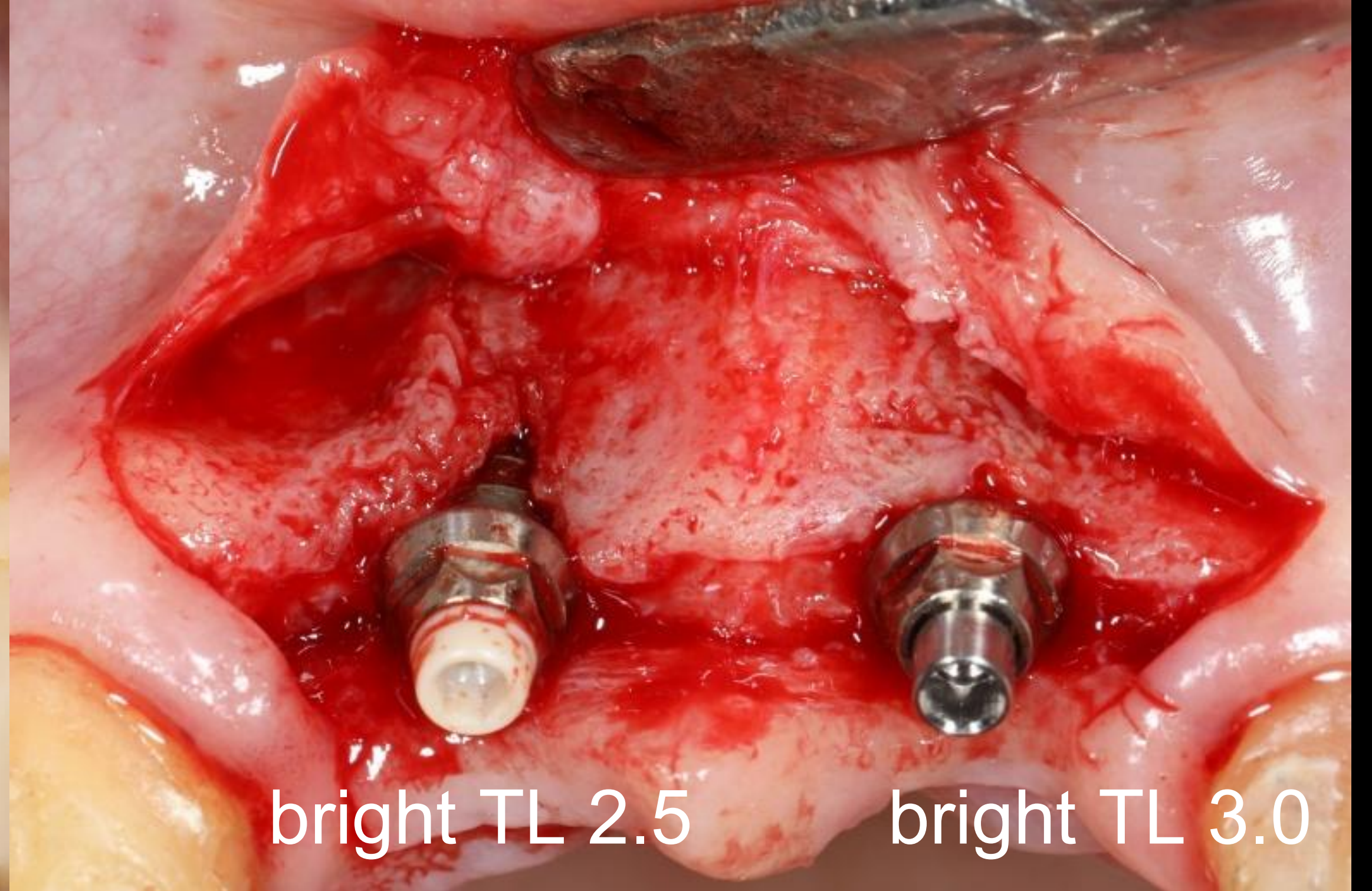
Straight

Vented - usually 15 but maximum to 25 degree



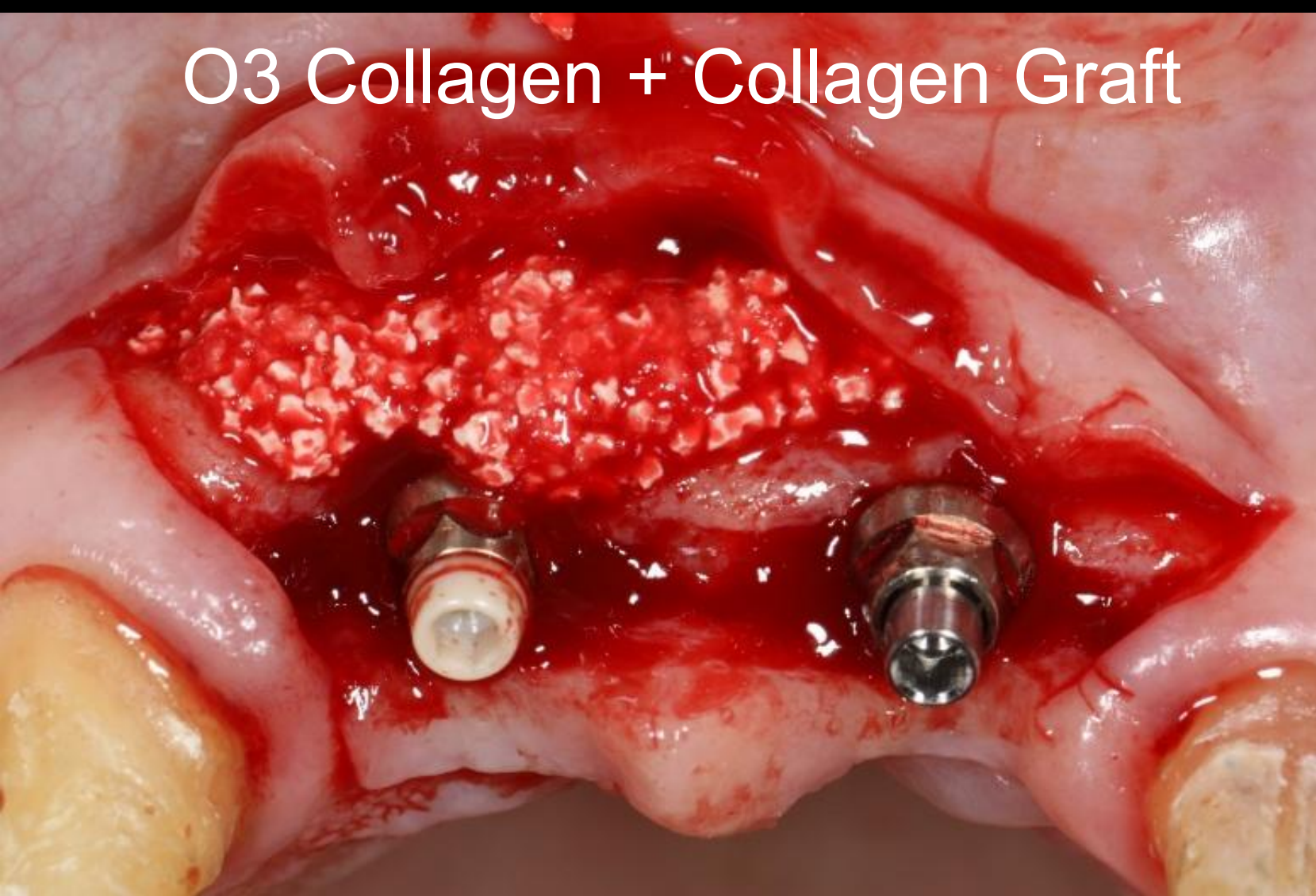

6months later

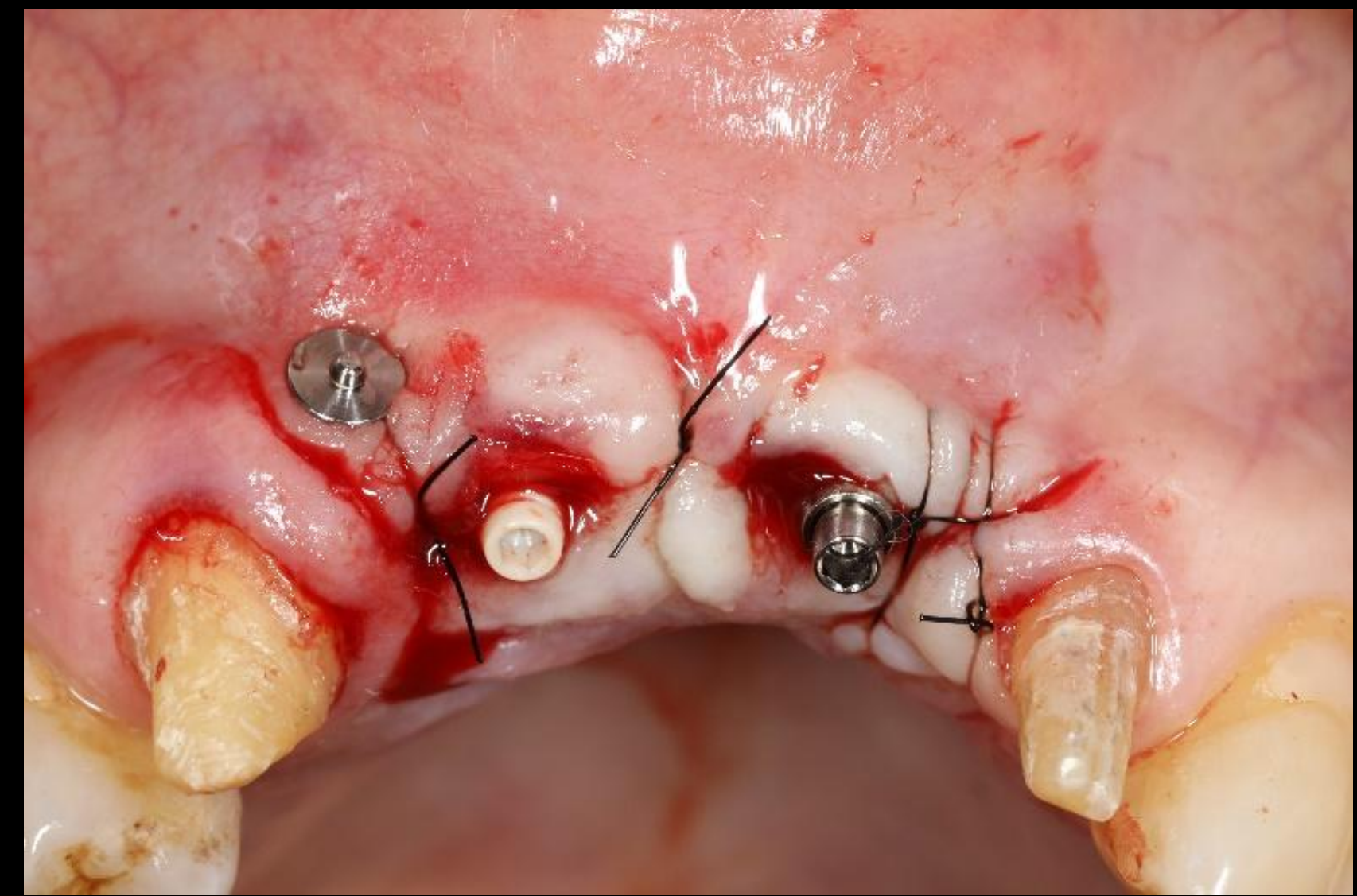
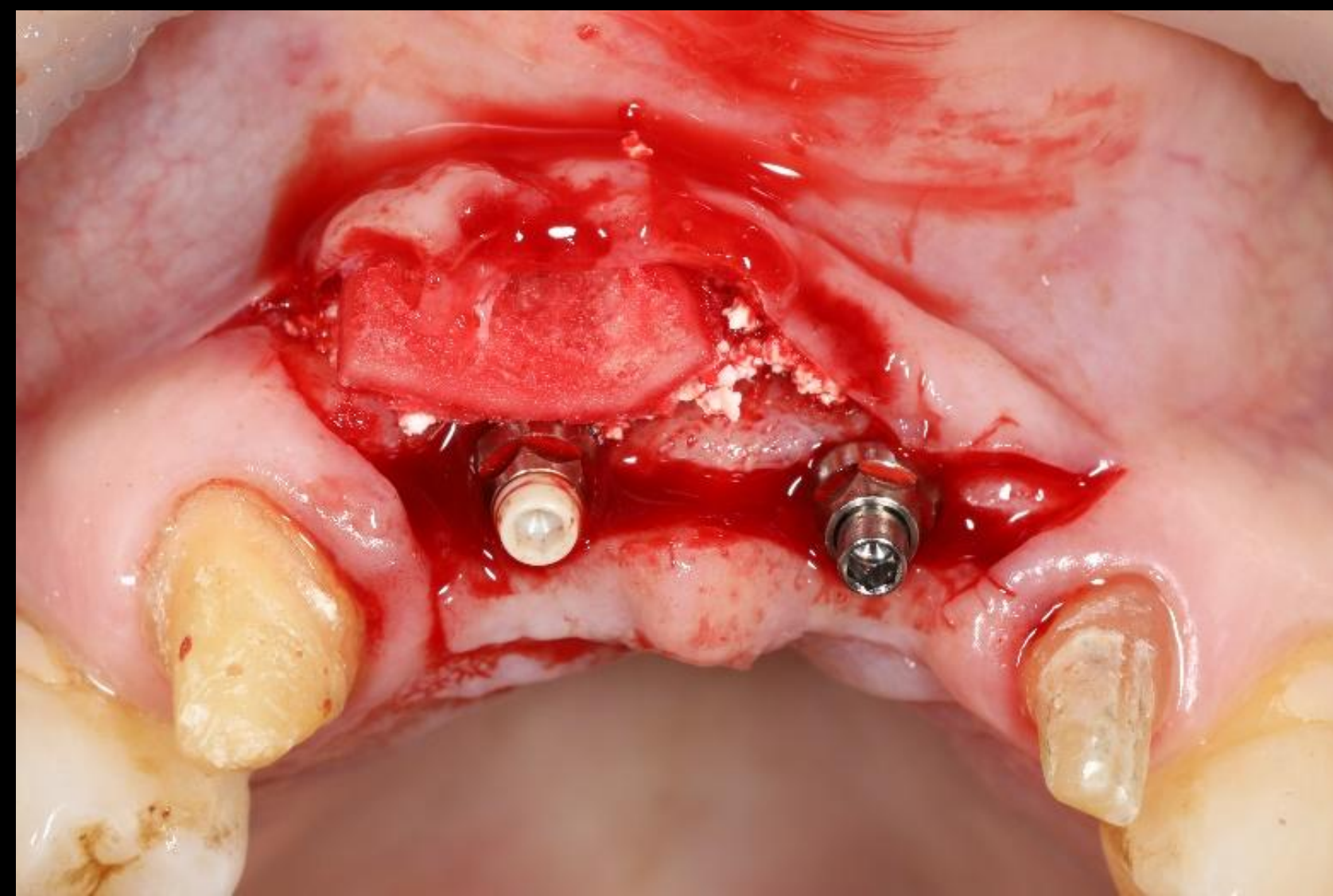


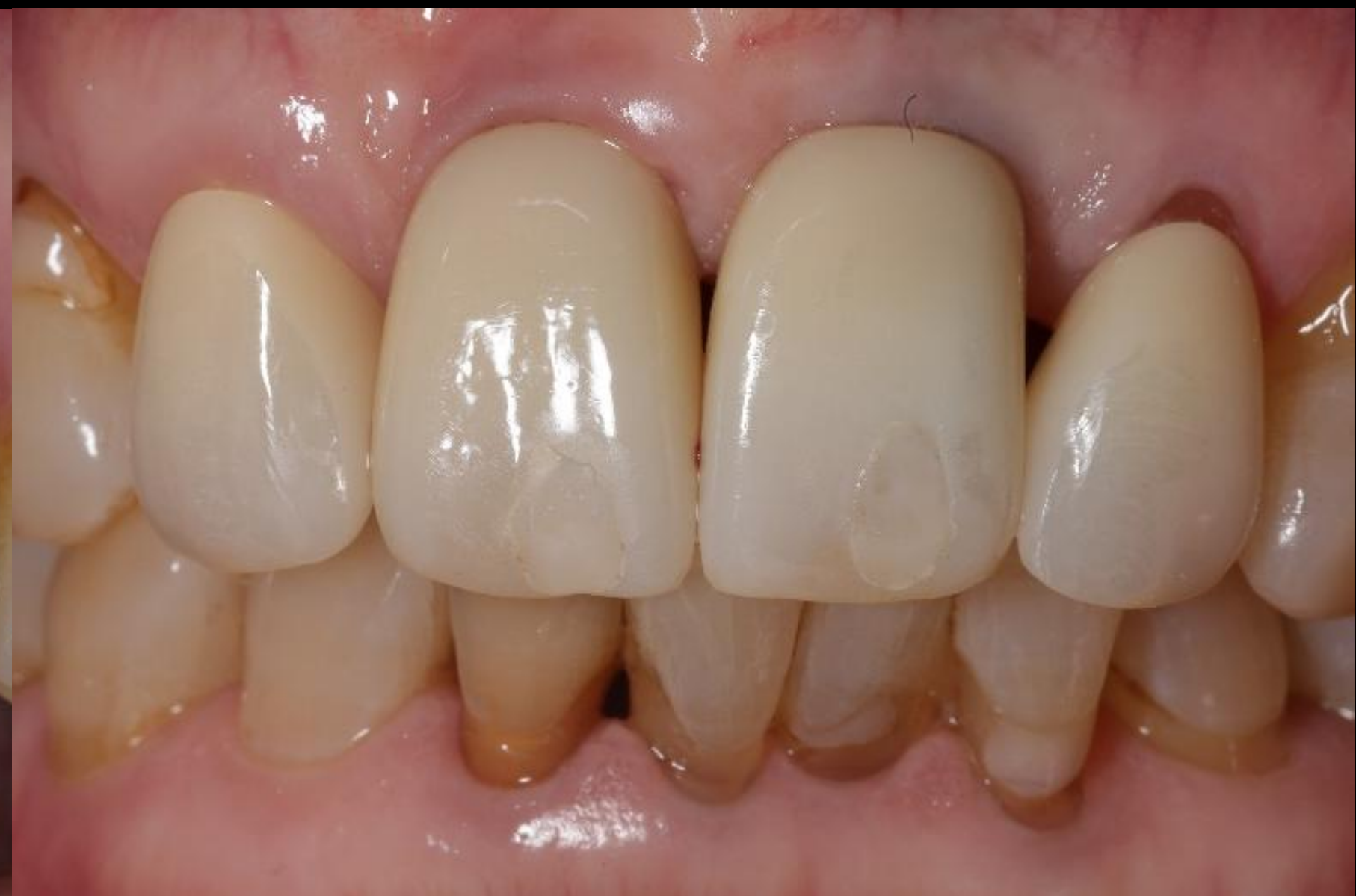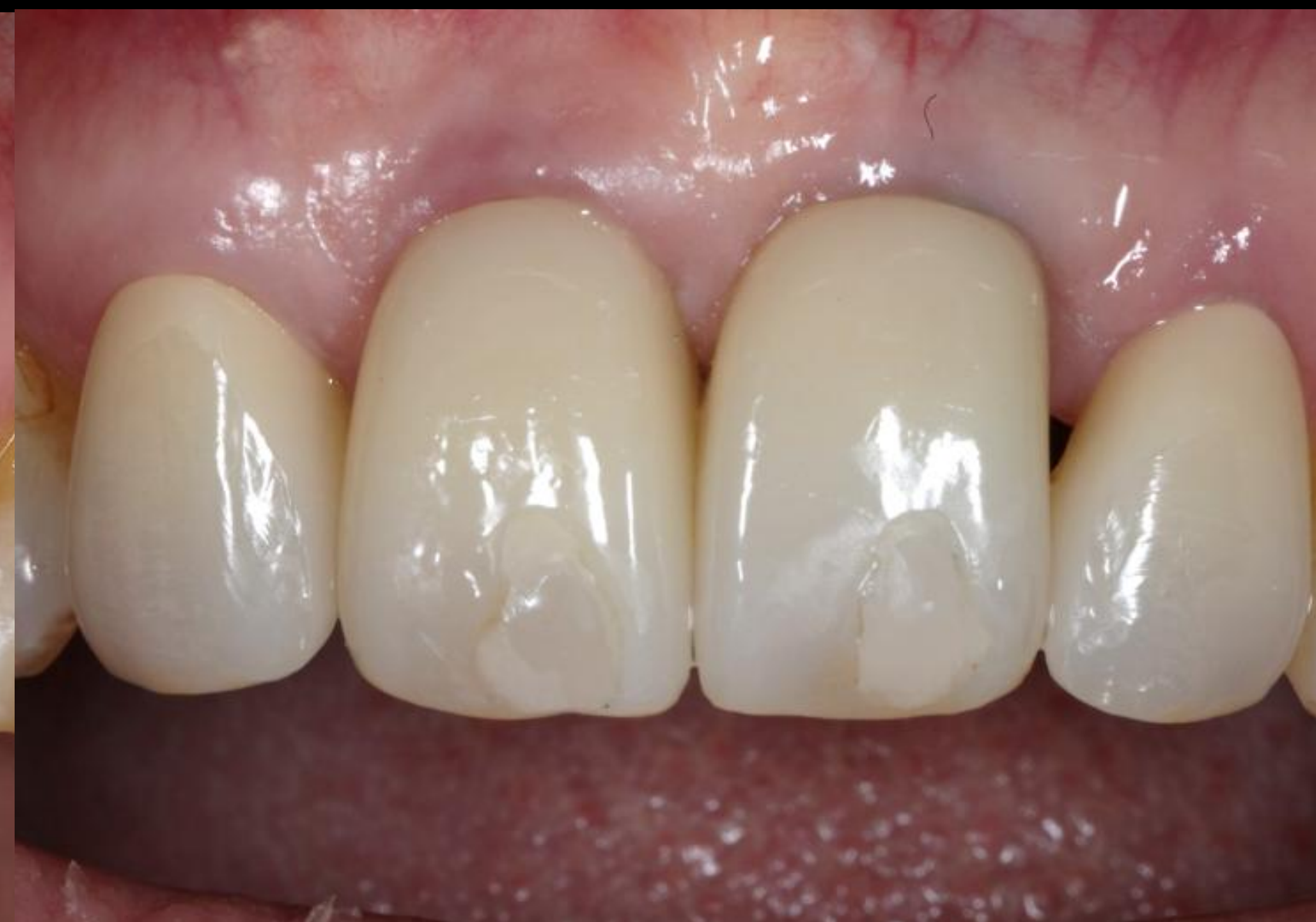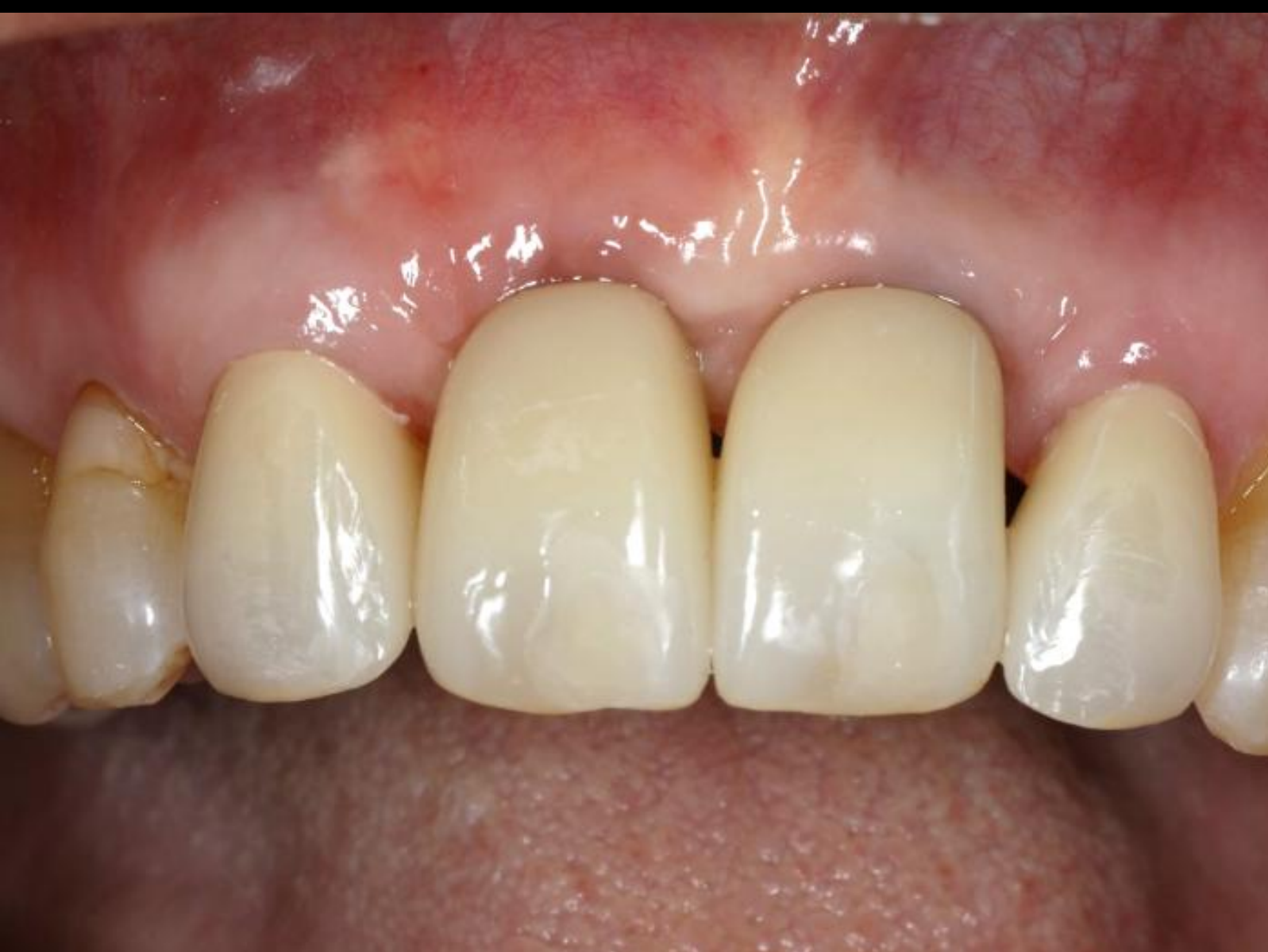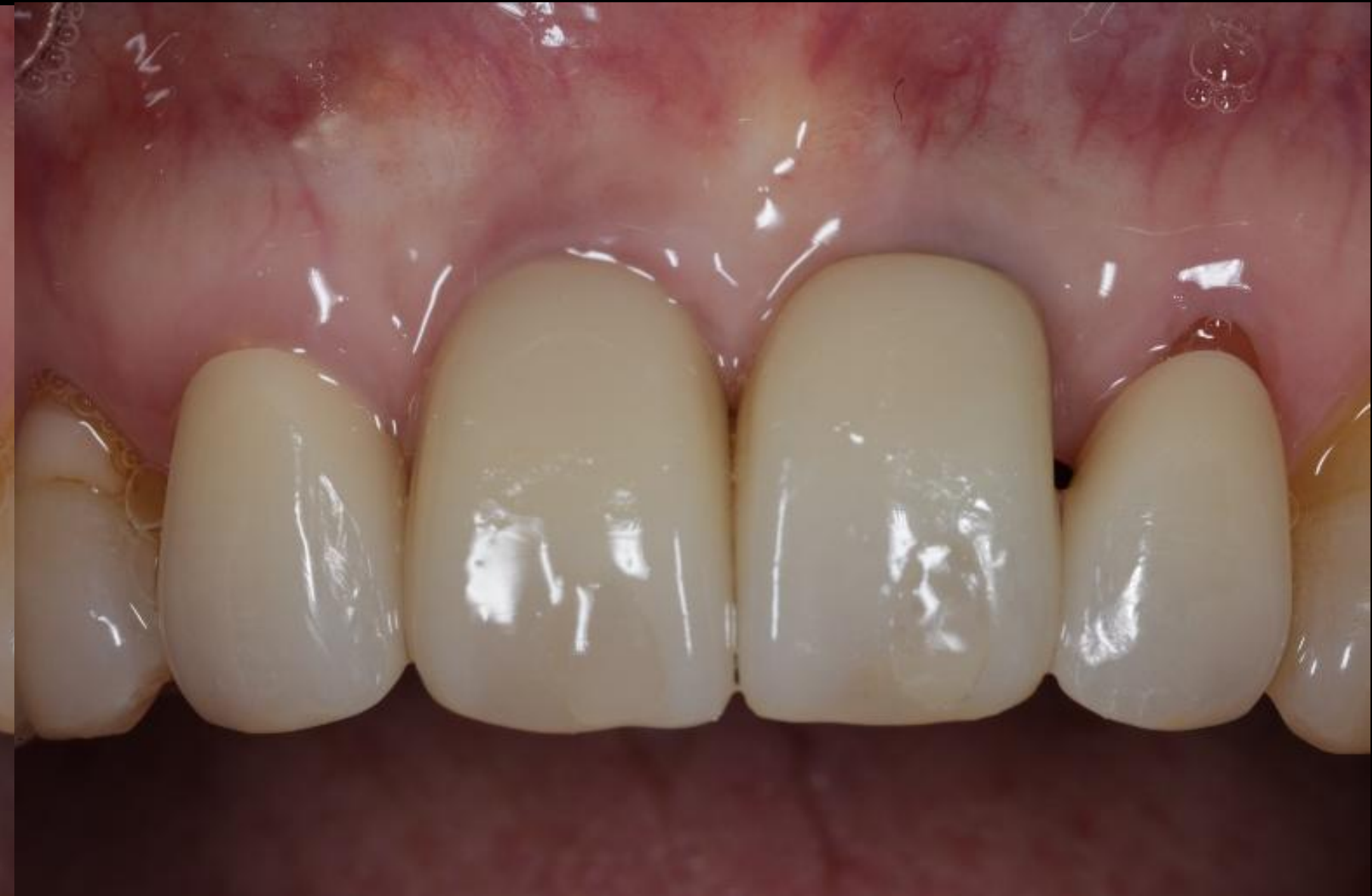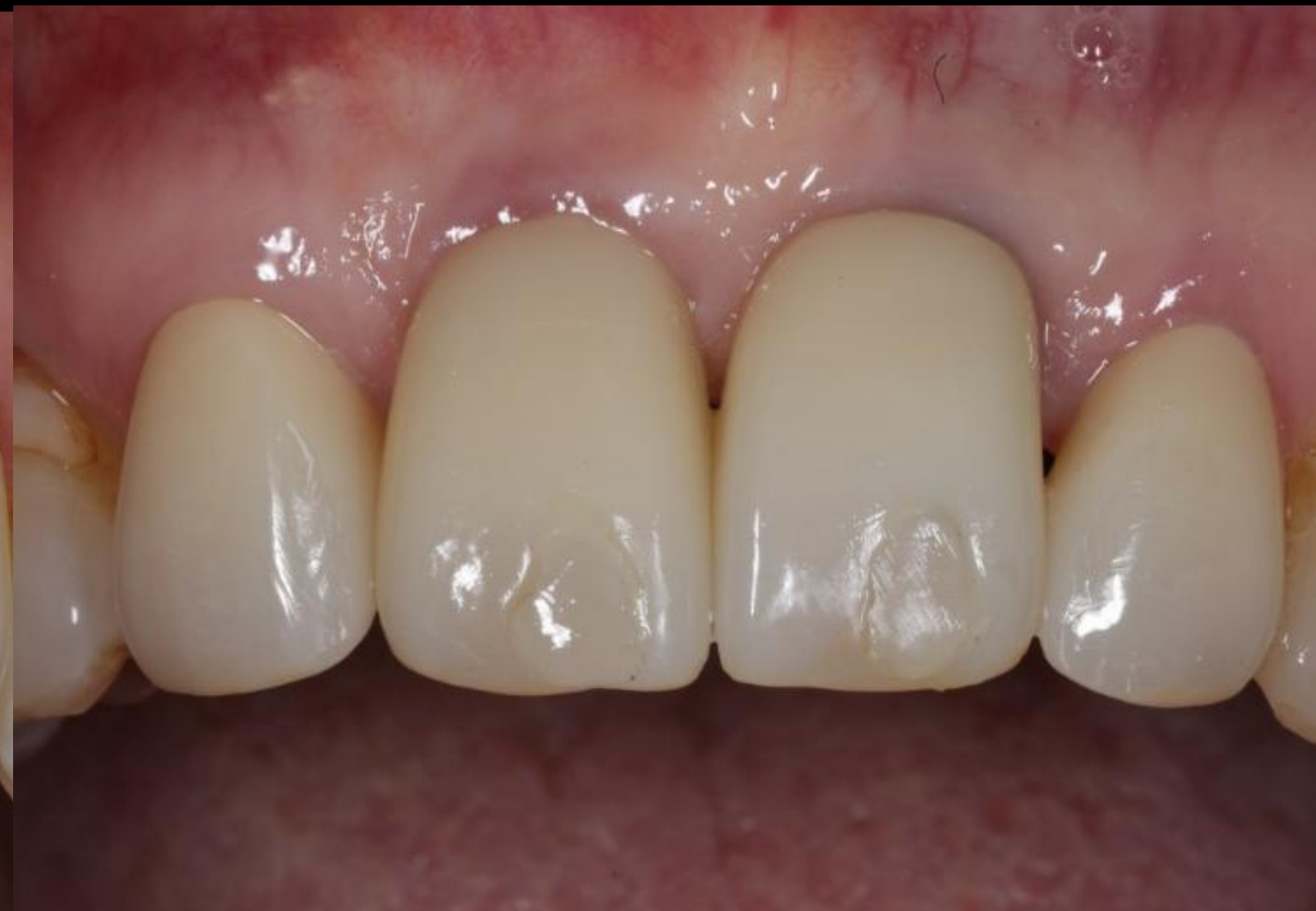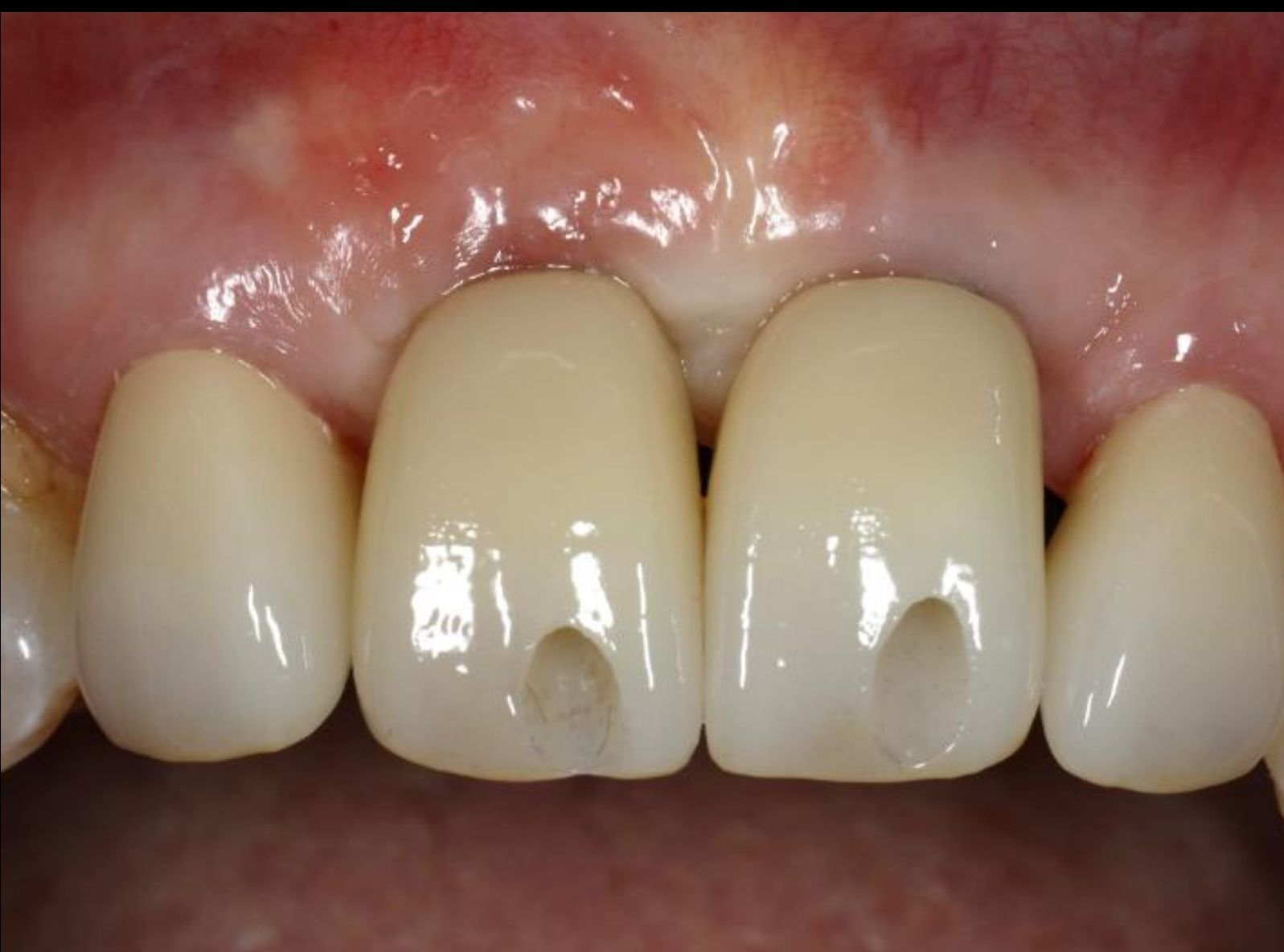bright TL 2.5

bright TL 3.0



O3 Collagen + Collagen Graft





2022

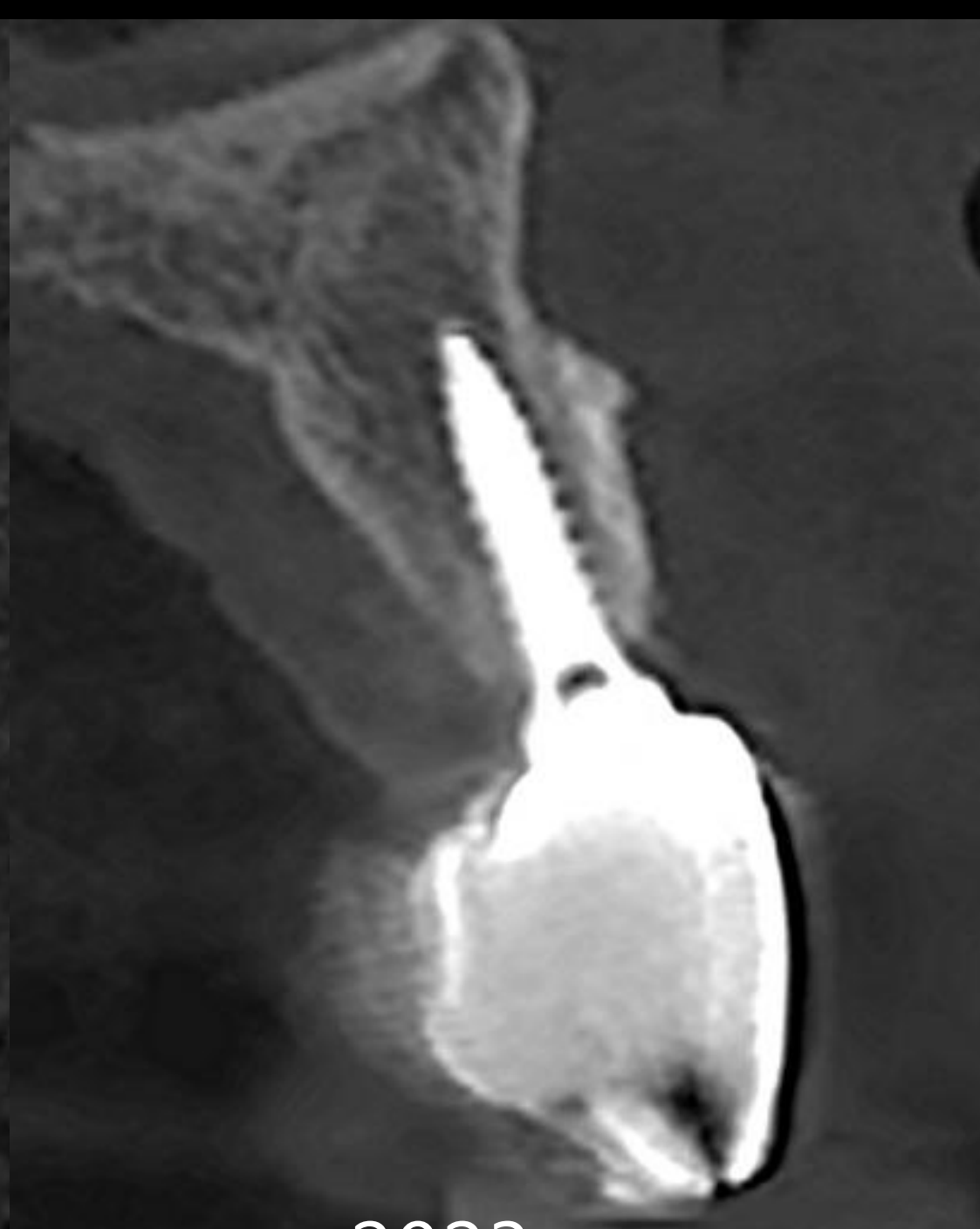2023

2025

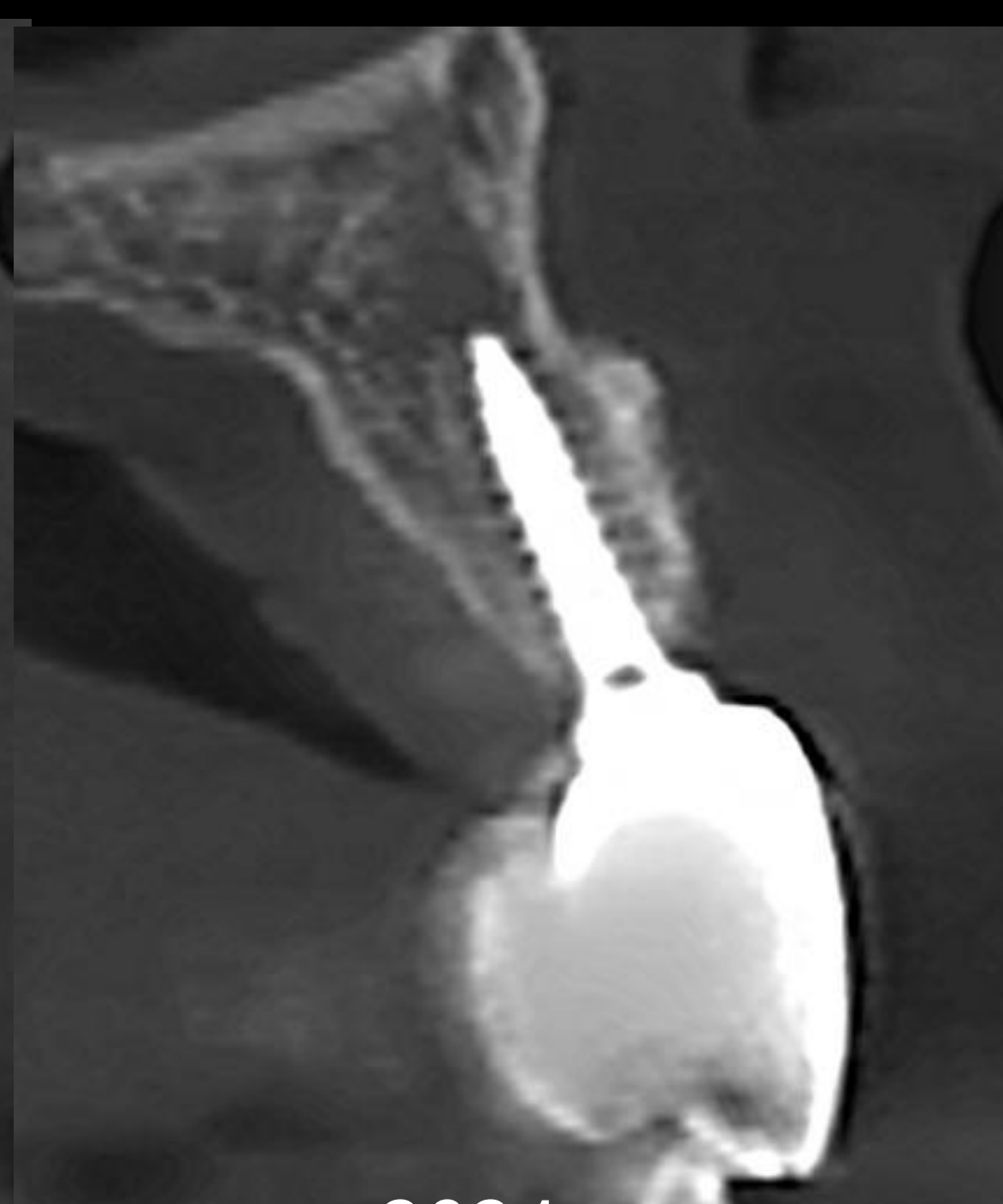
11



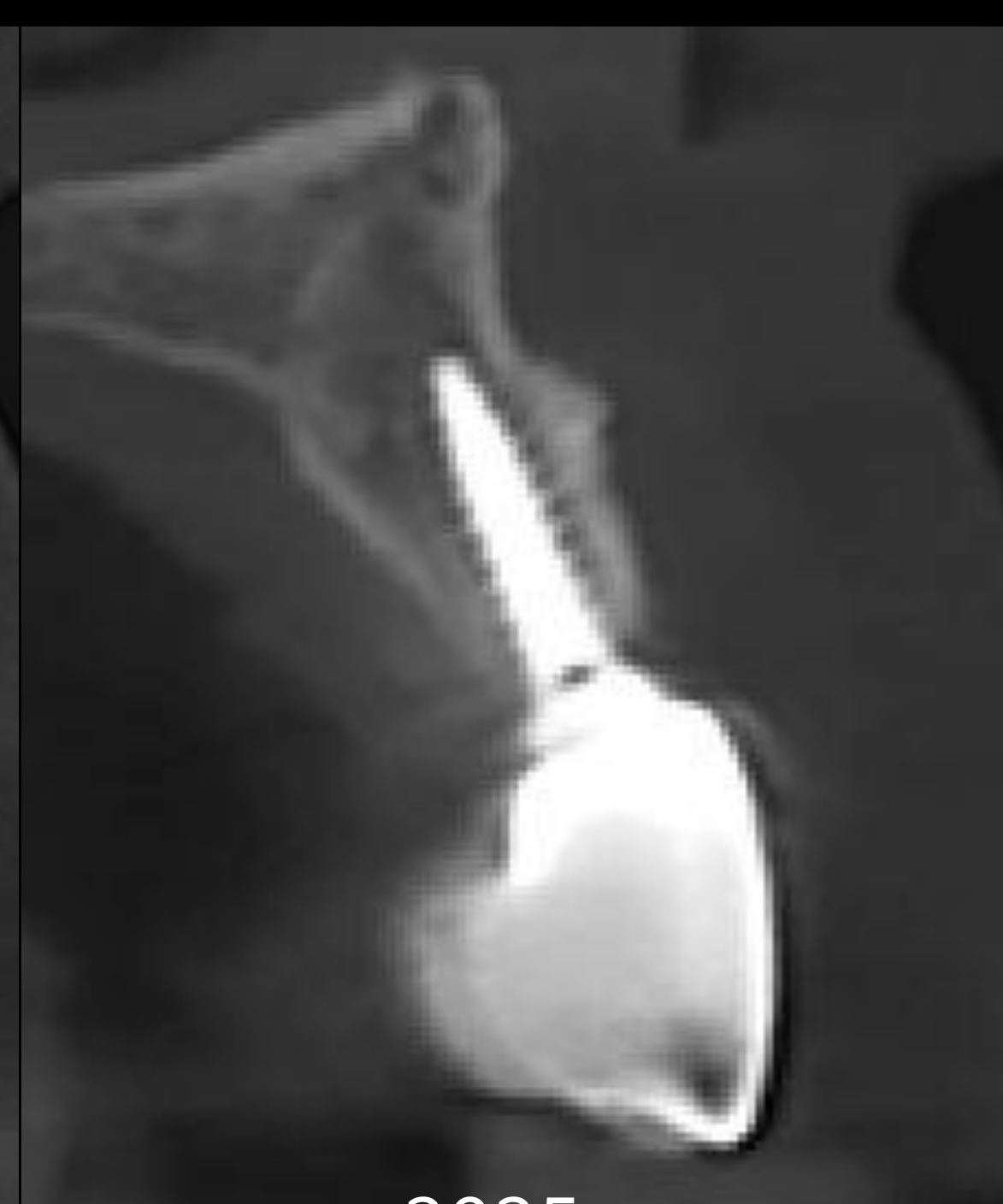Post-OP



2023

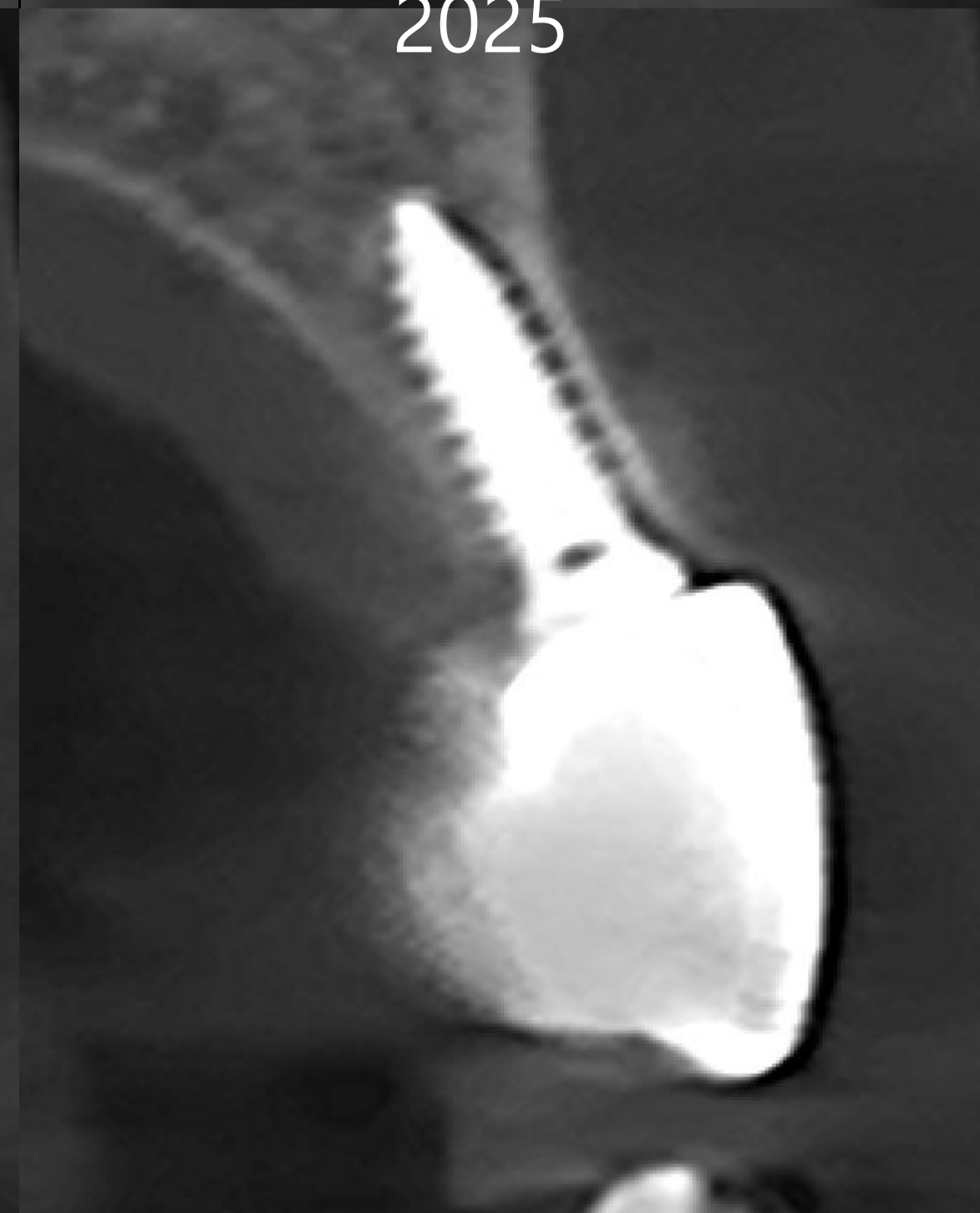
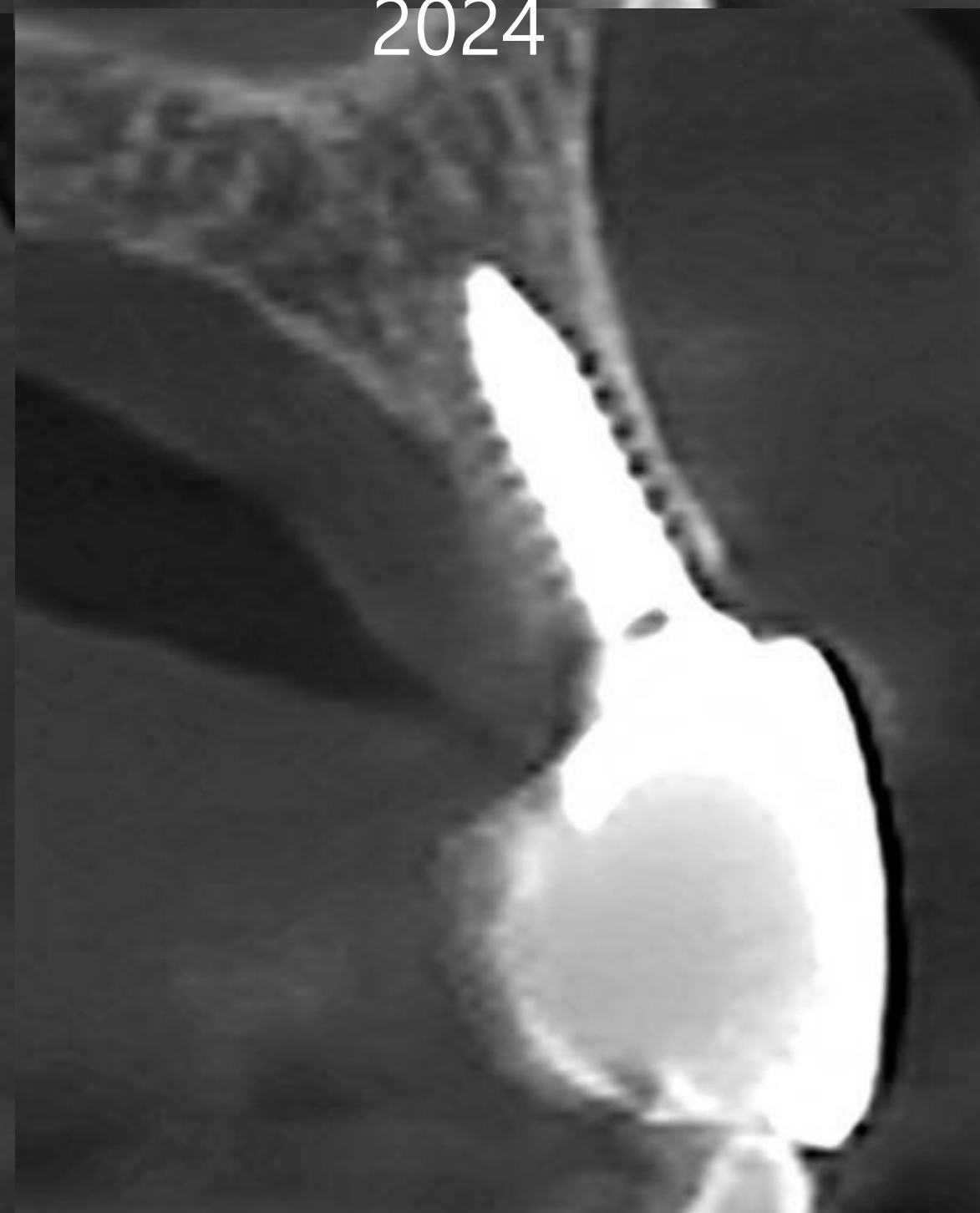
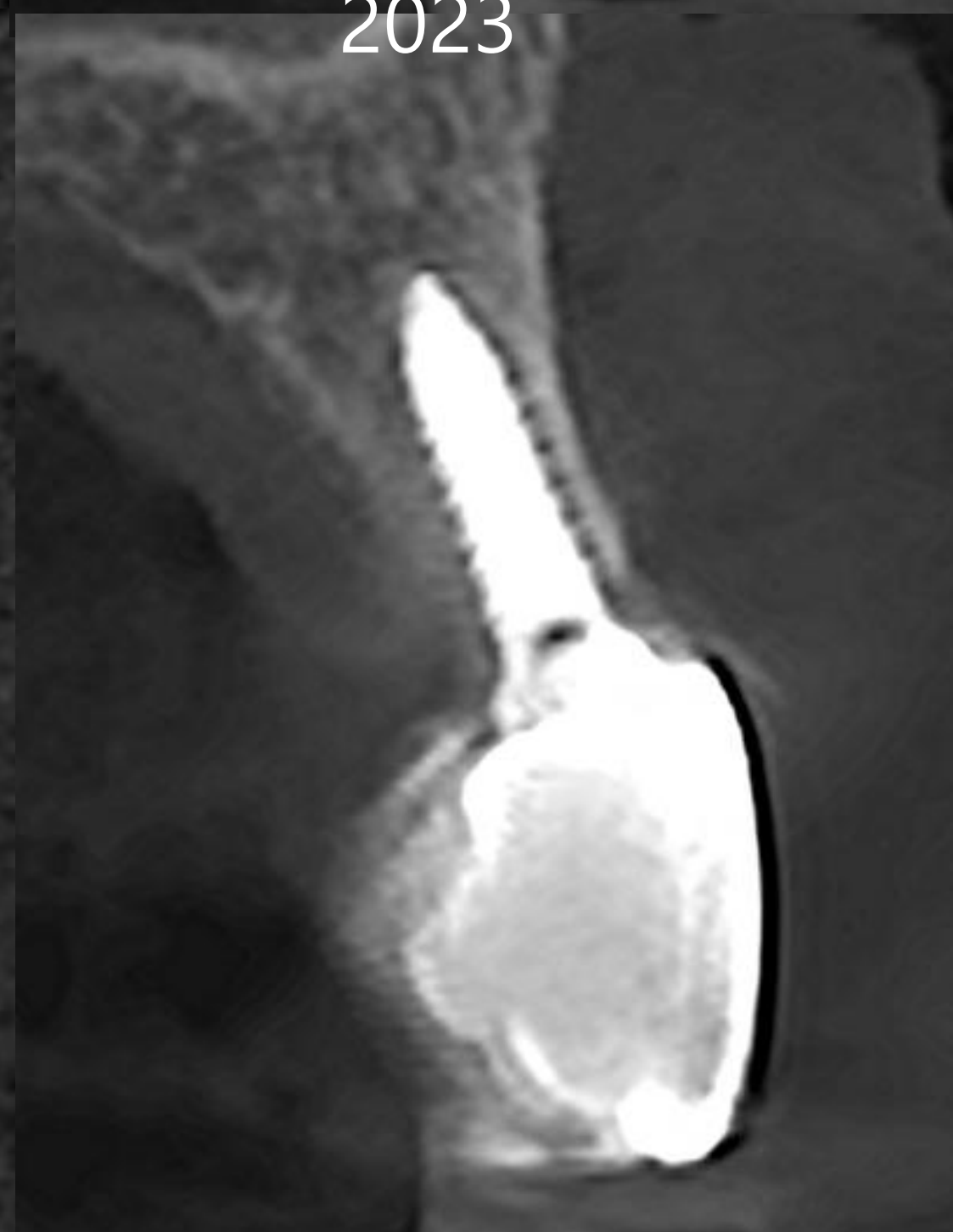
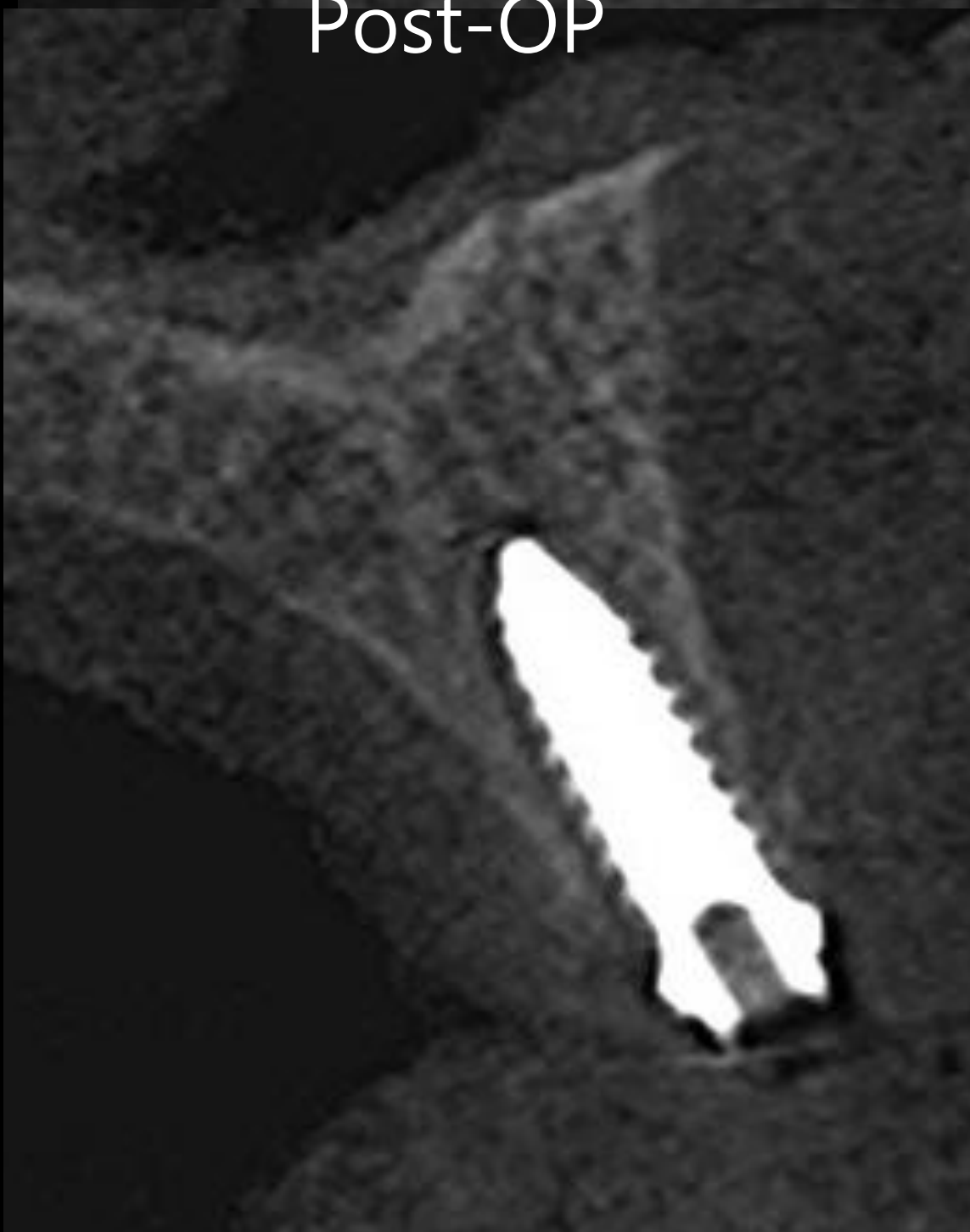
2024

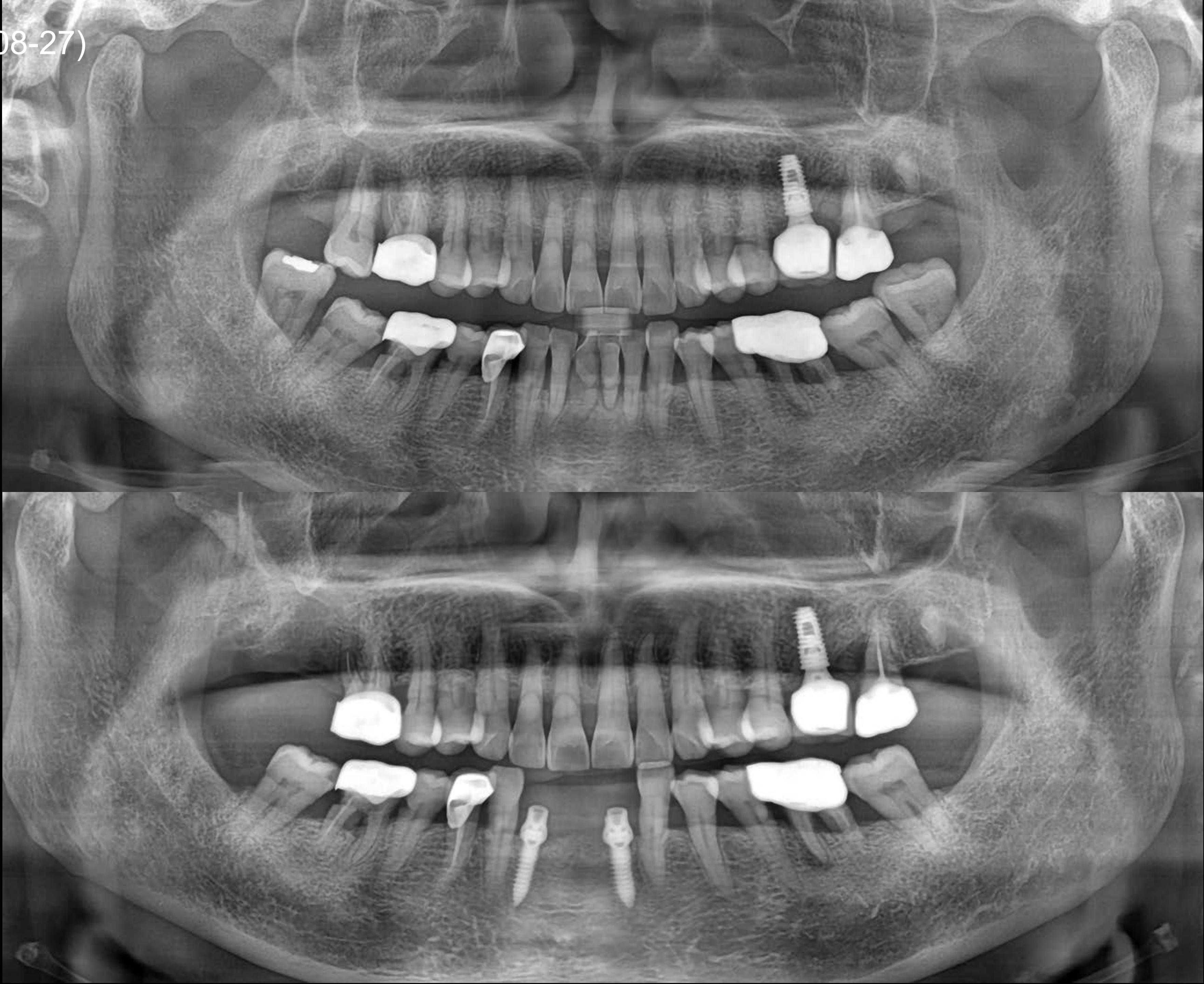


2025

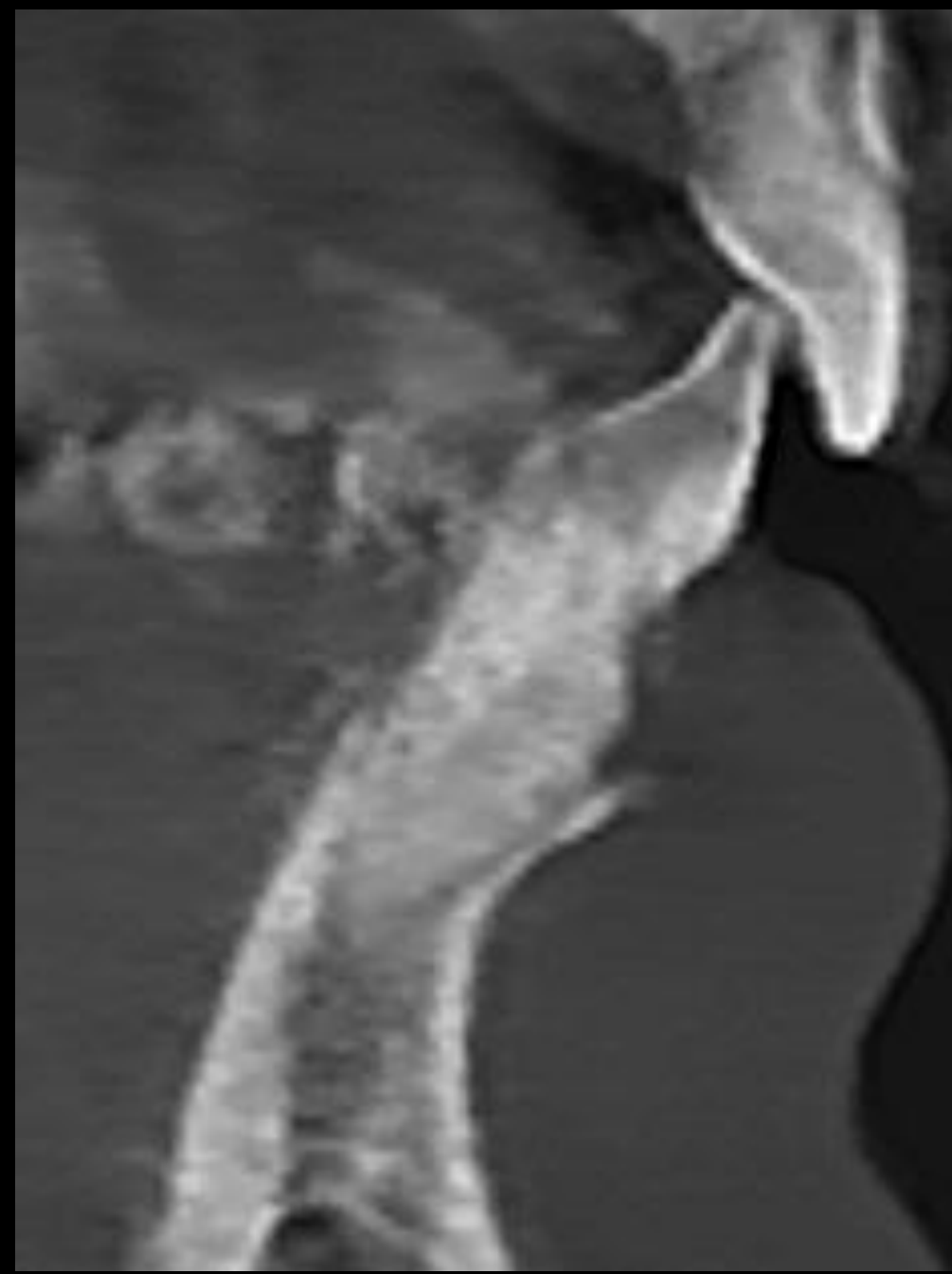
21



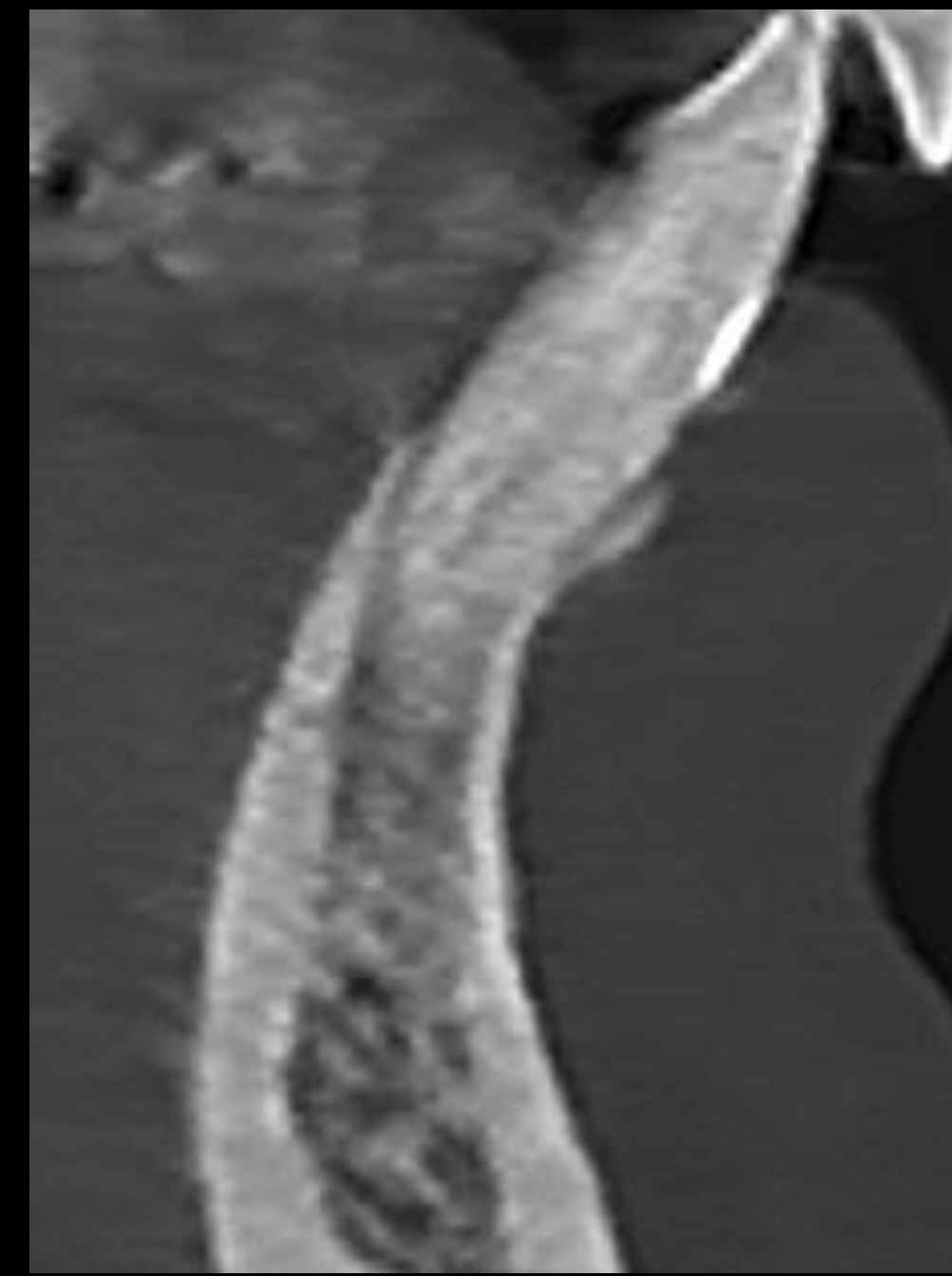
Pre-op (2024-08-27)



Pre-op CT (2024-08-27)

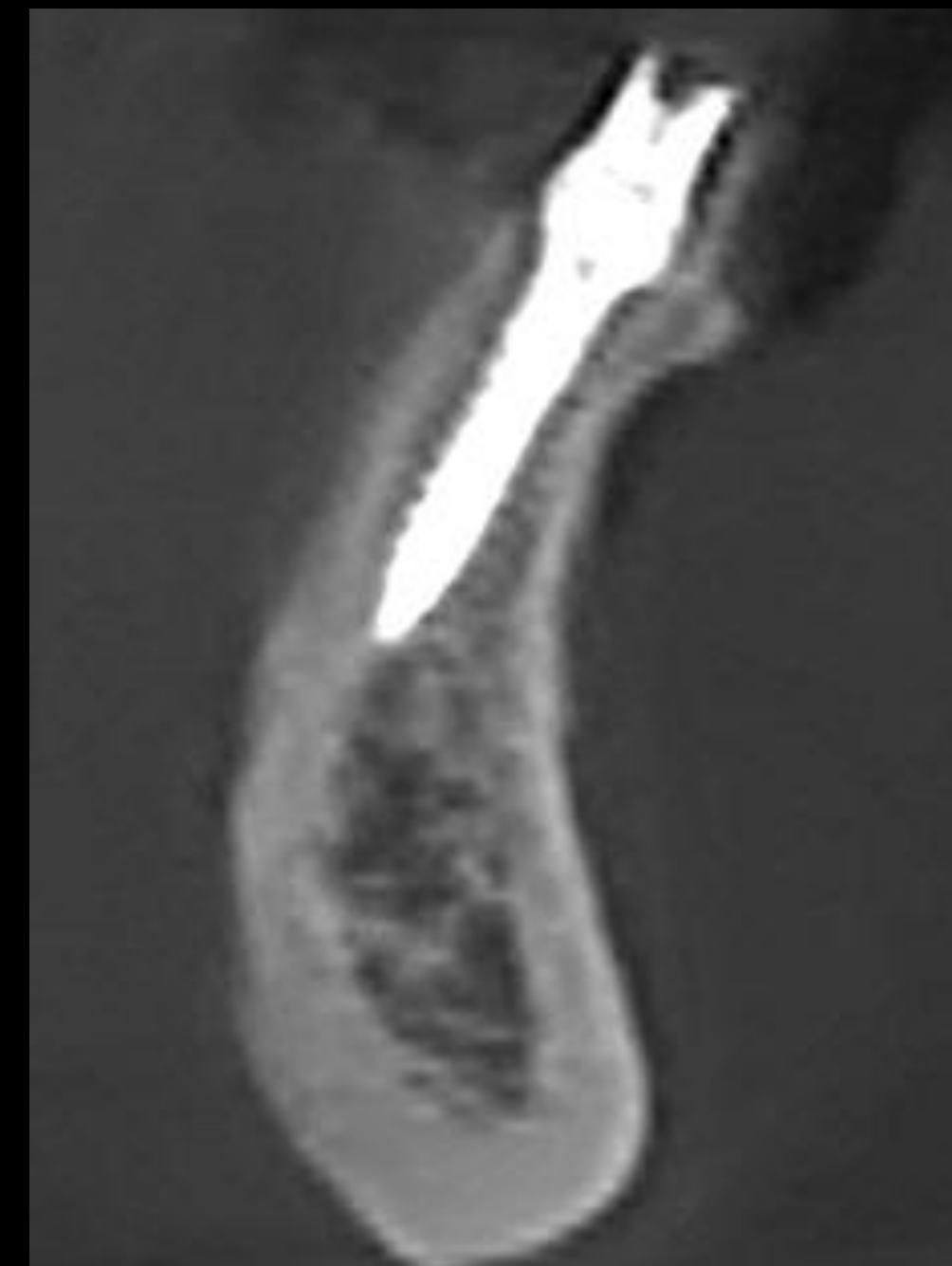
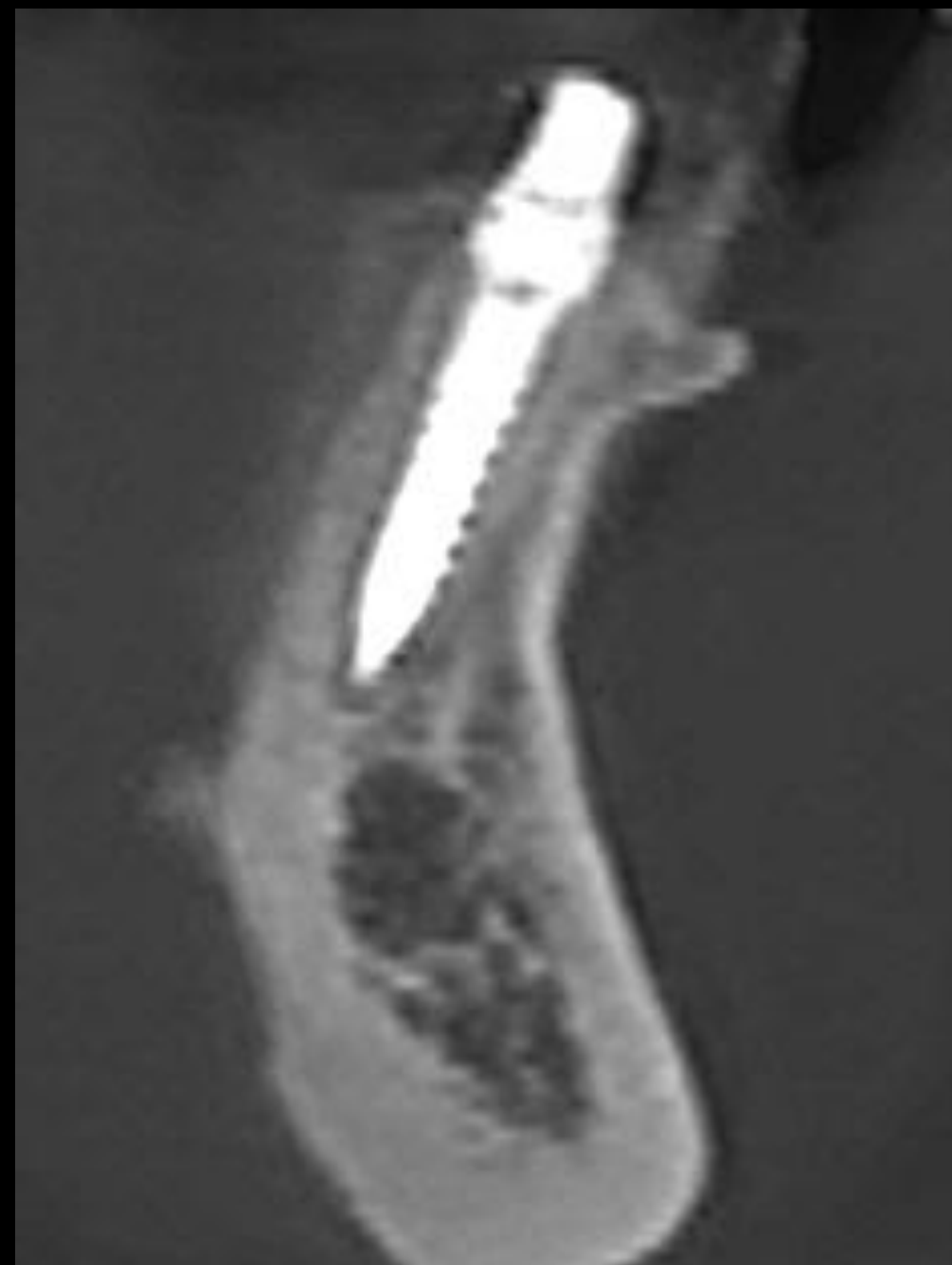

#42

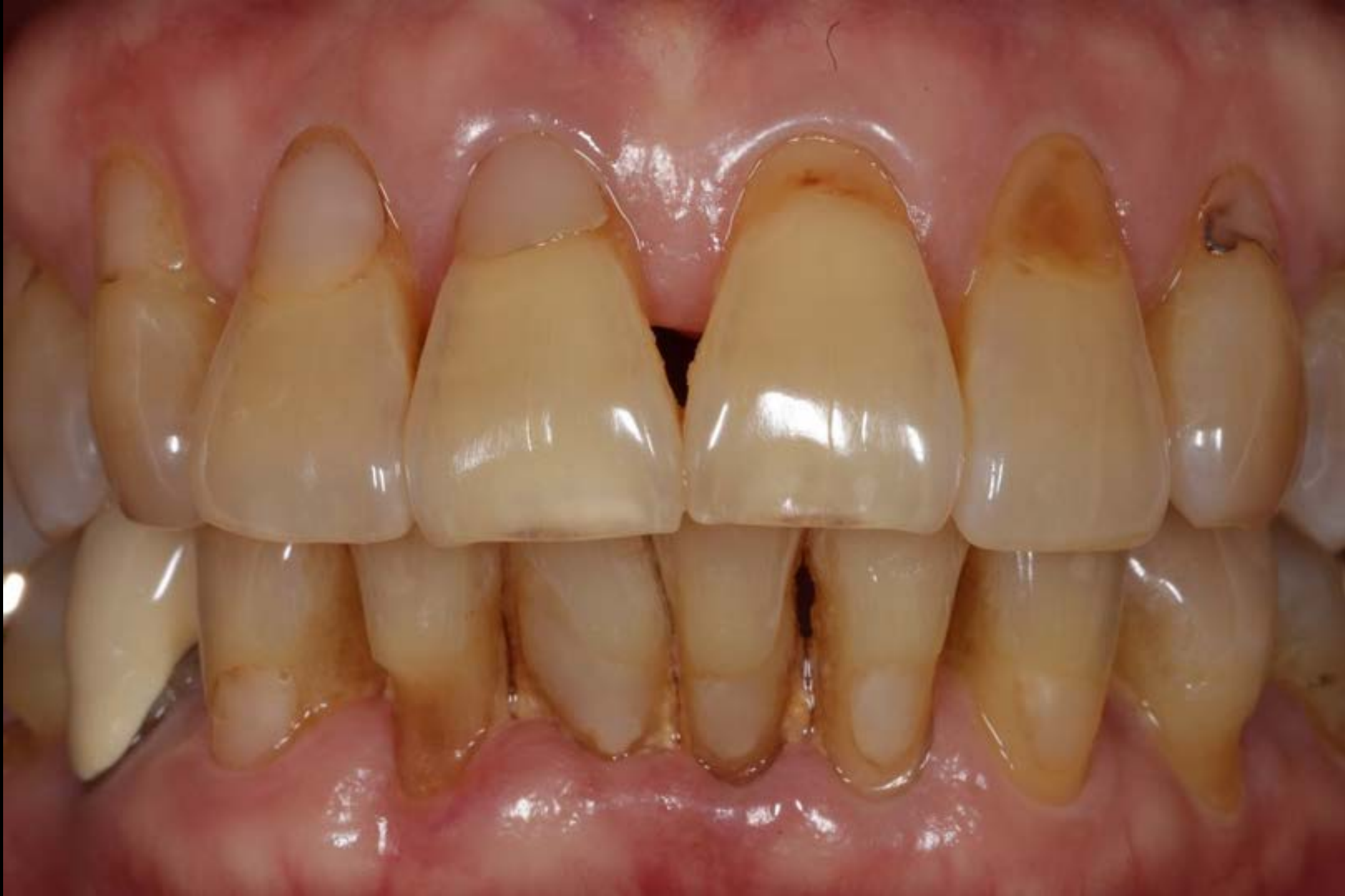
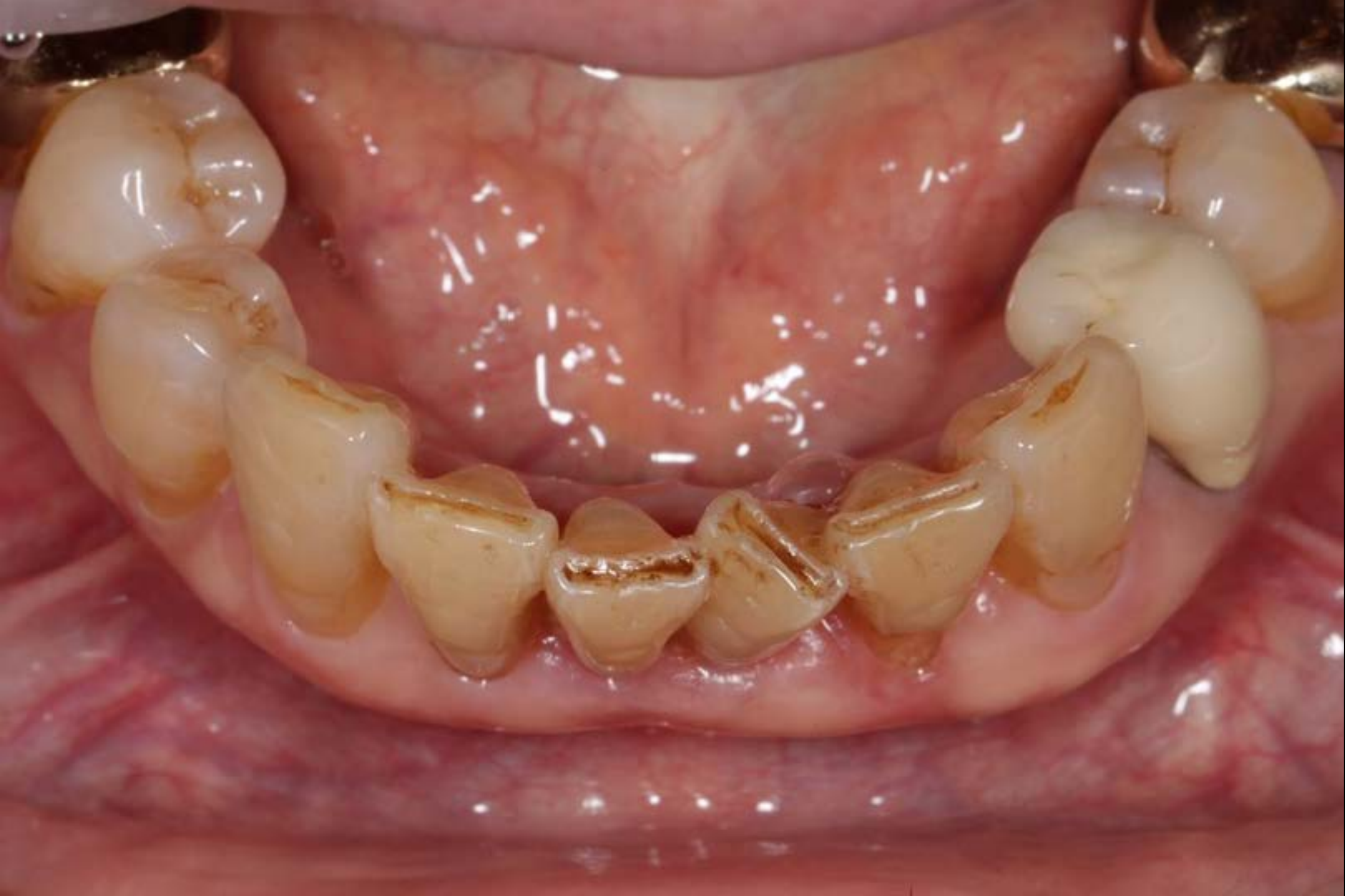
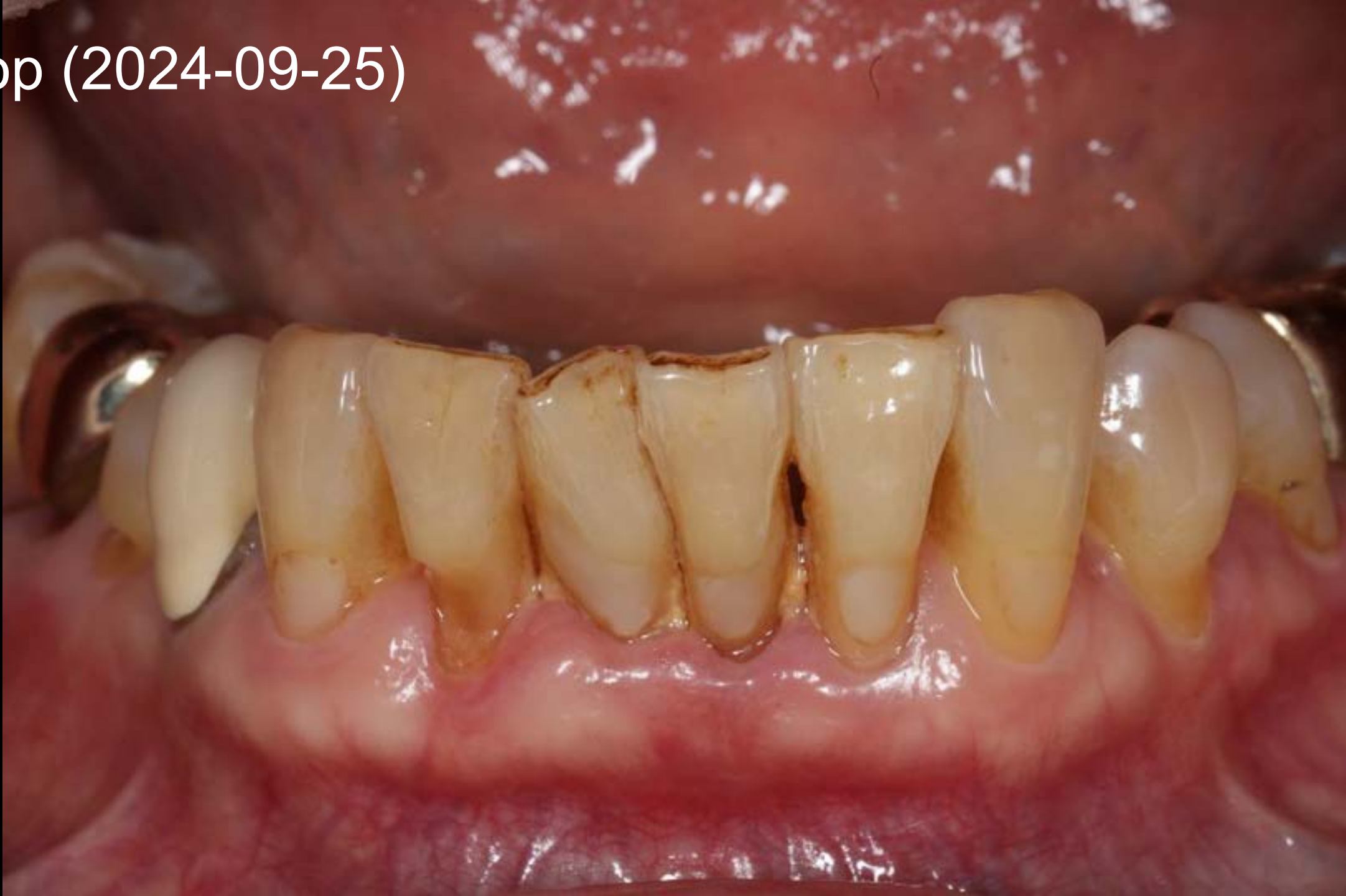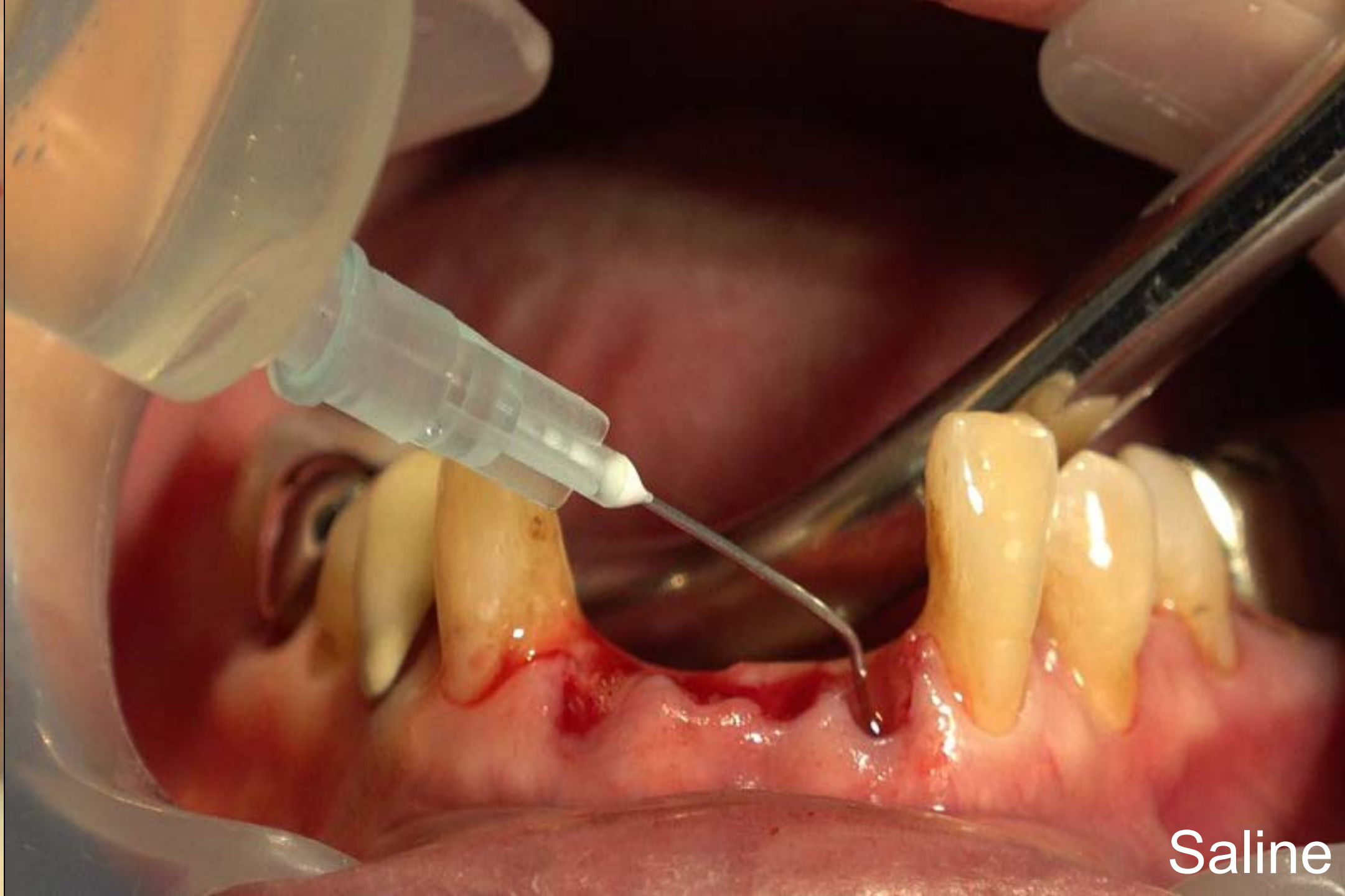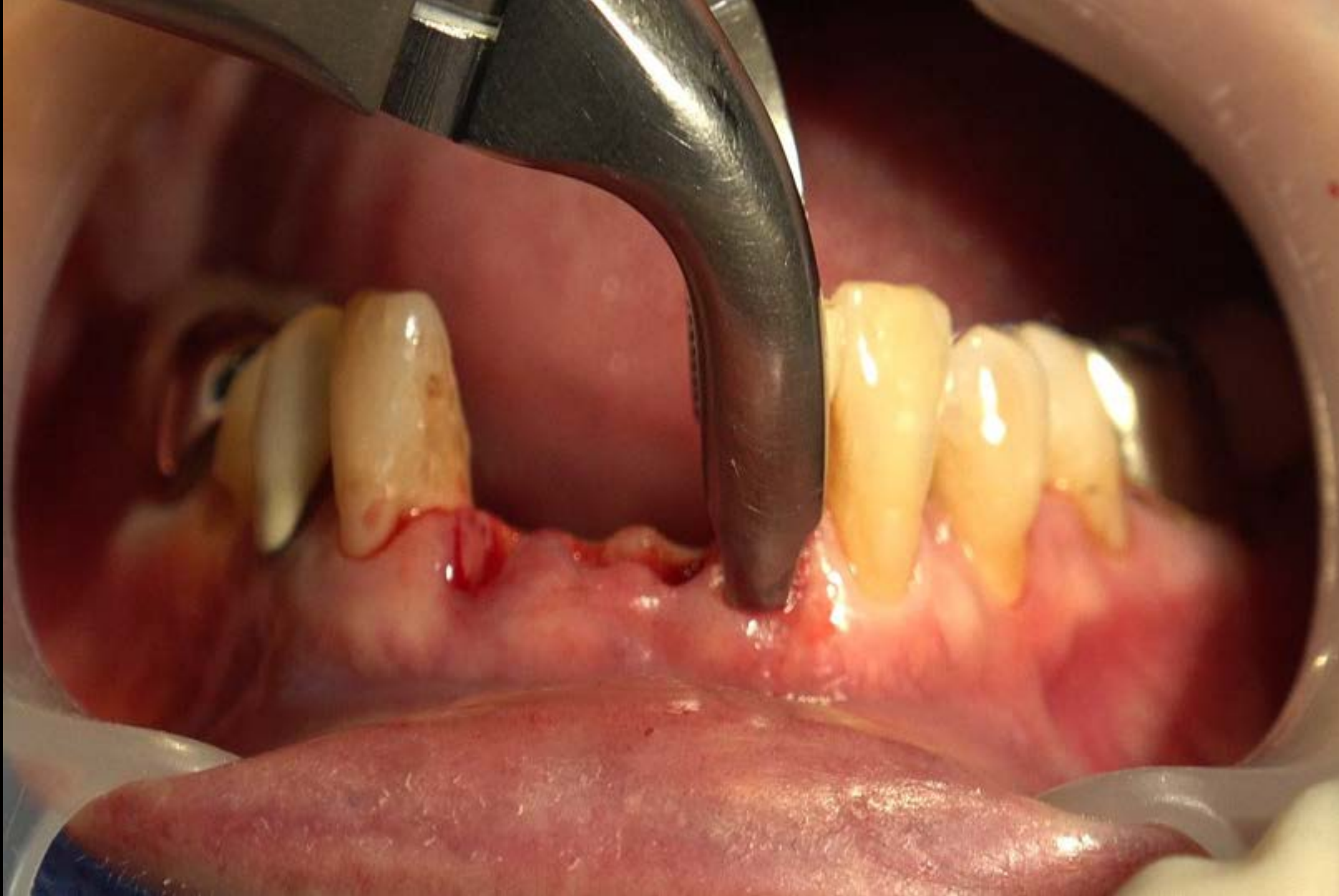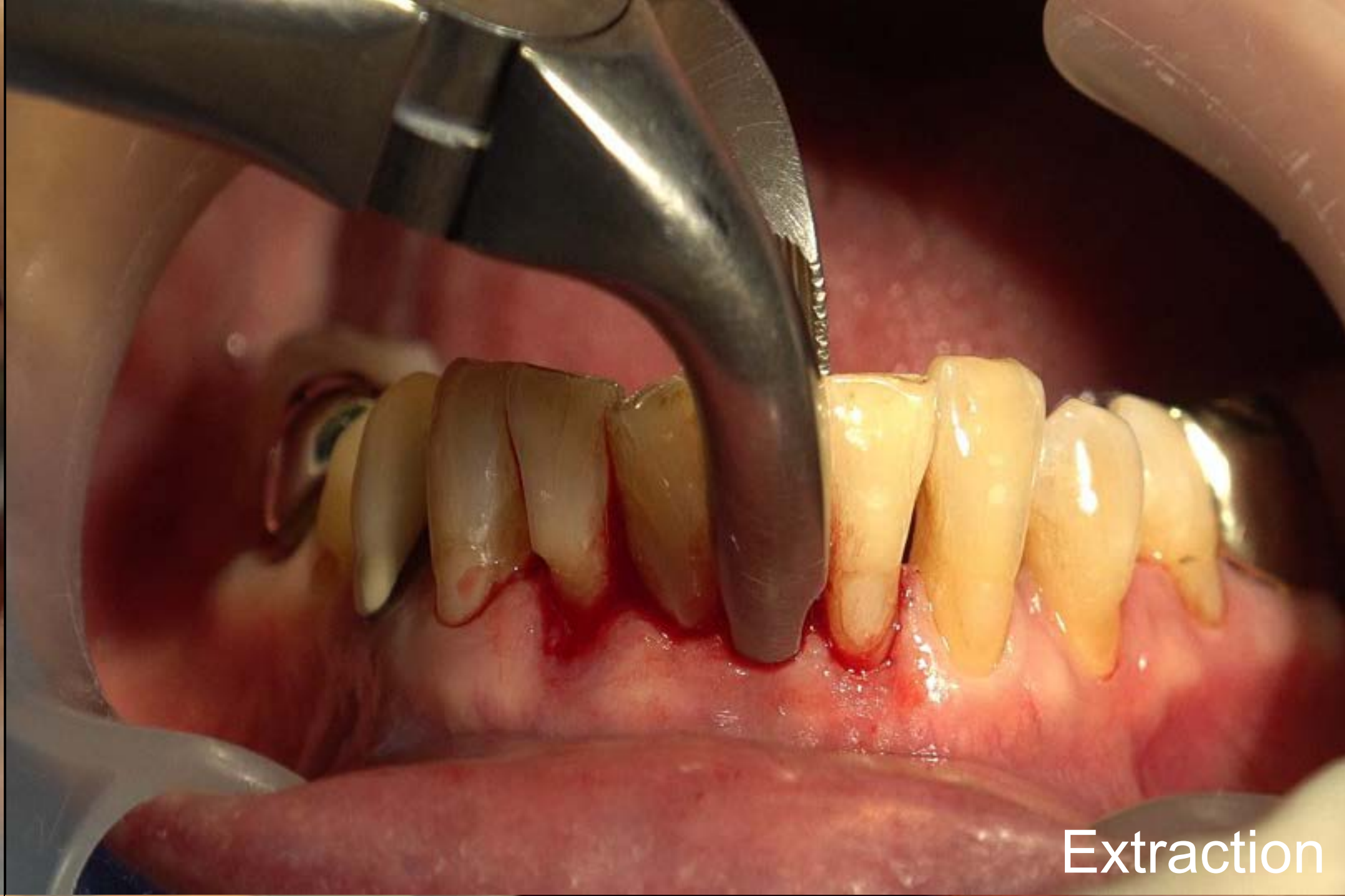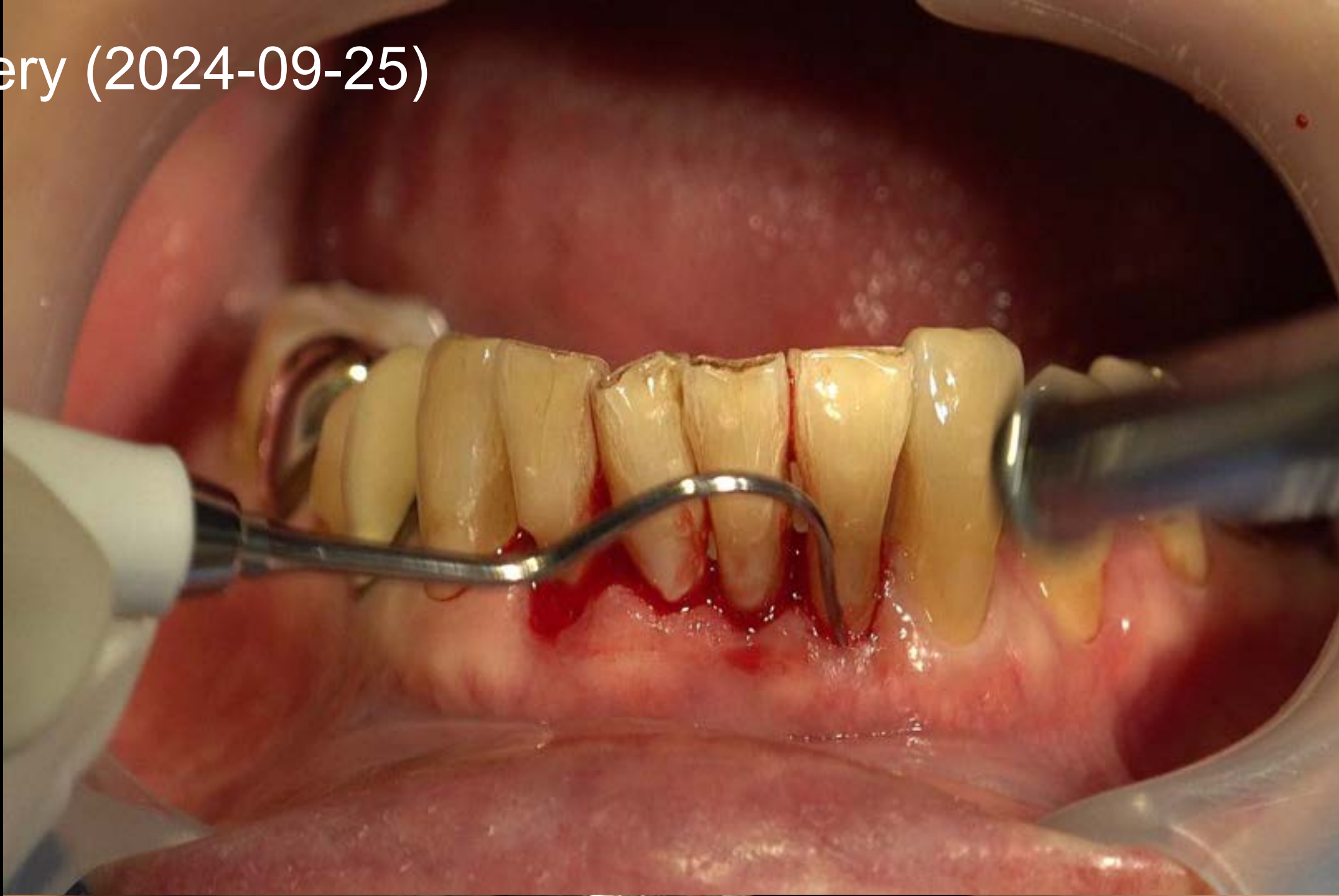#32

Post-op CT (2024-09-25)

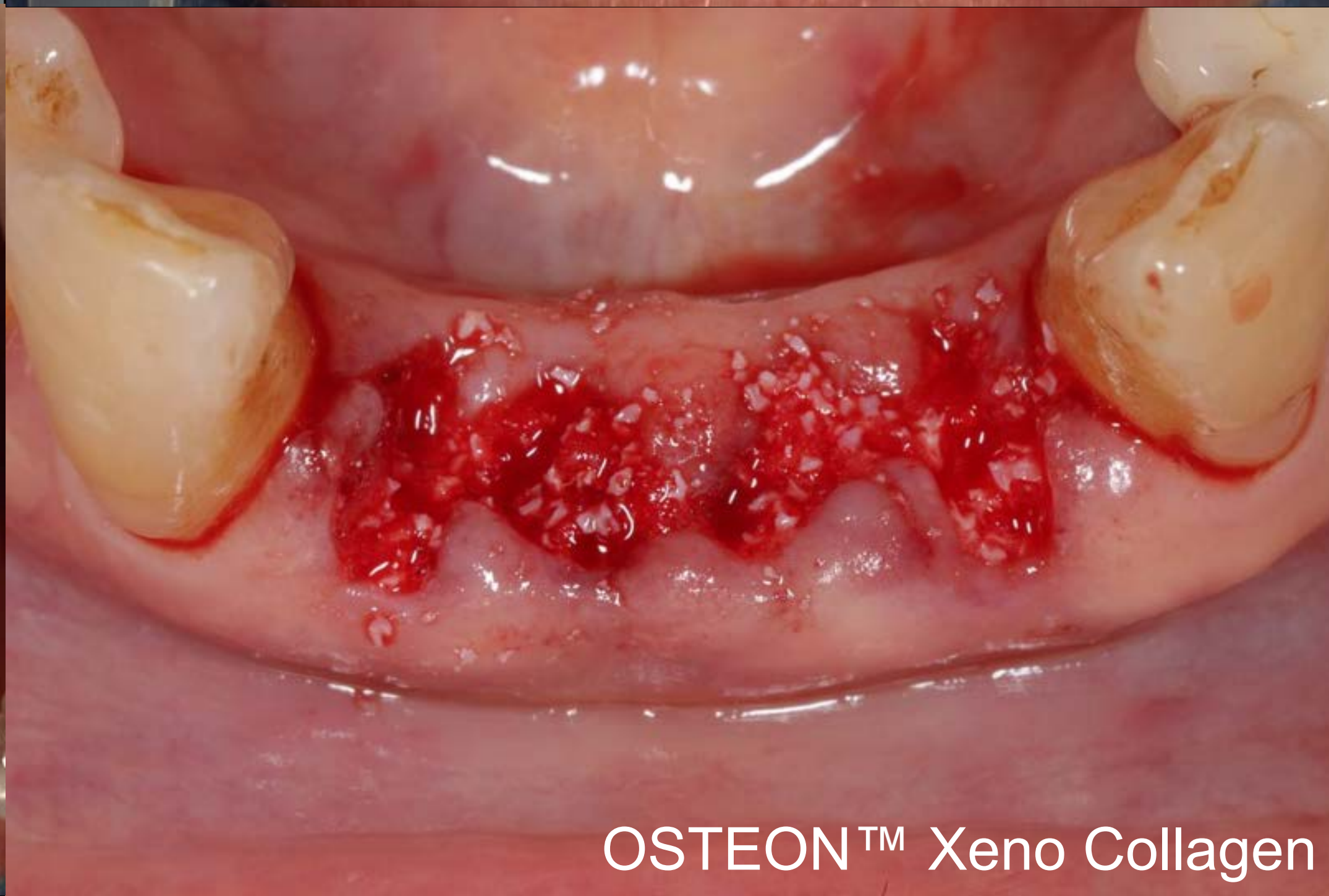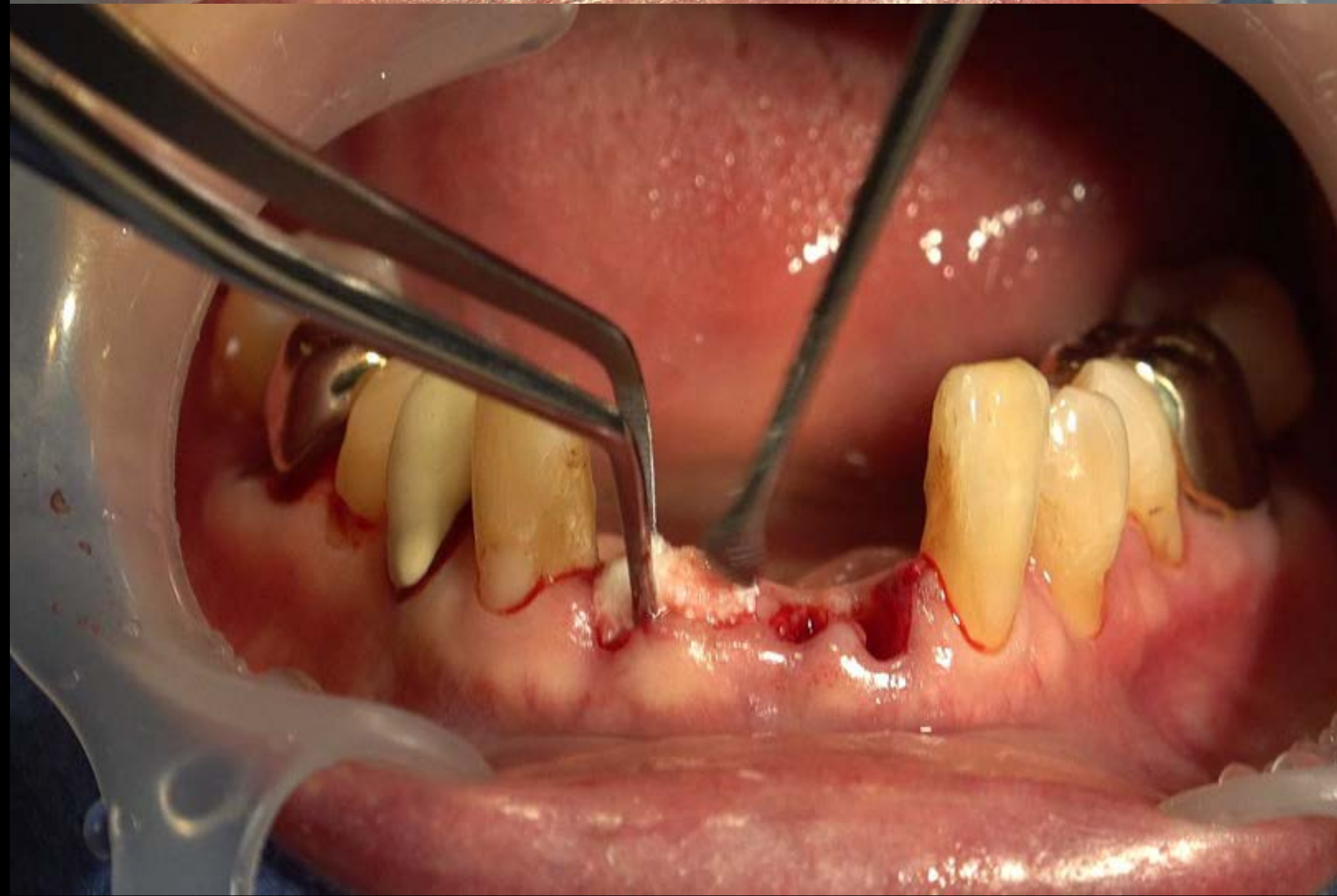
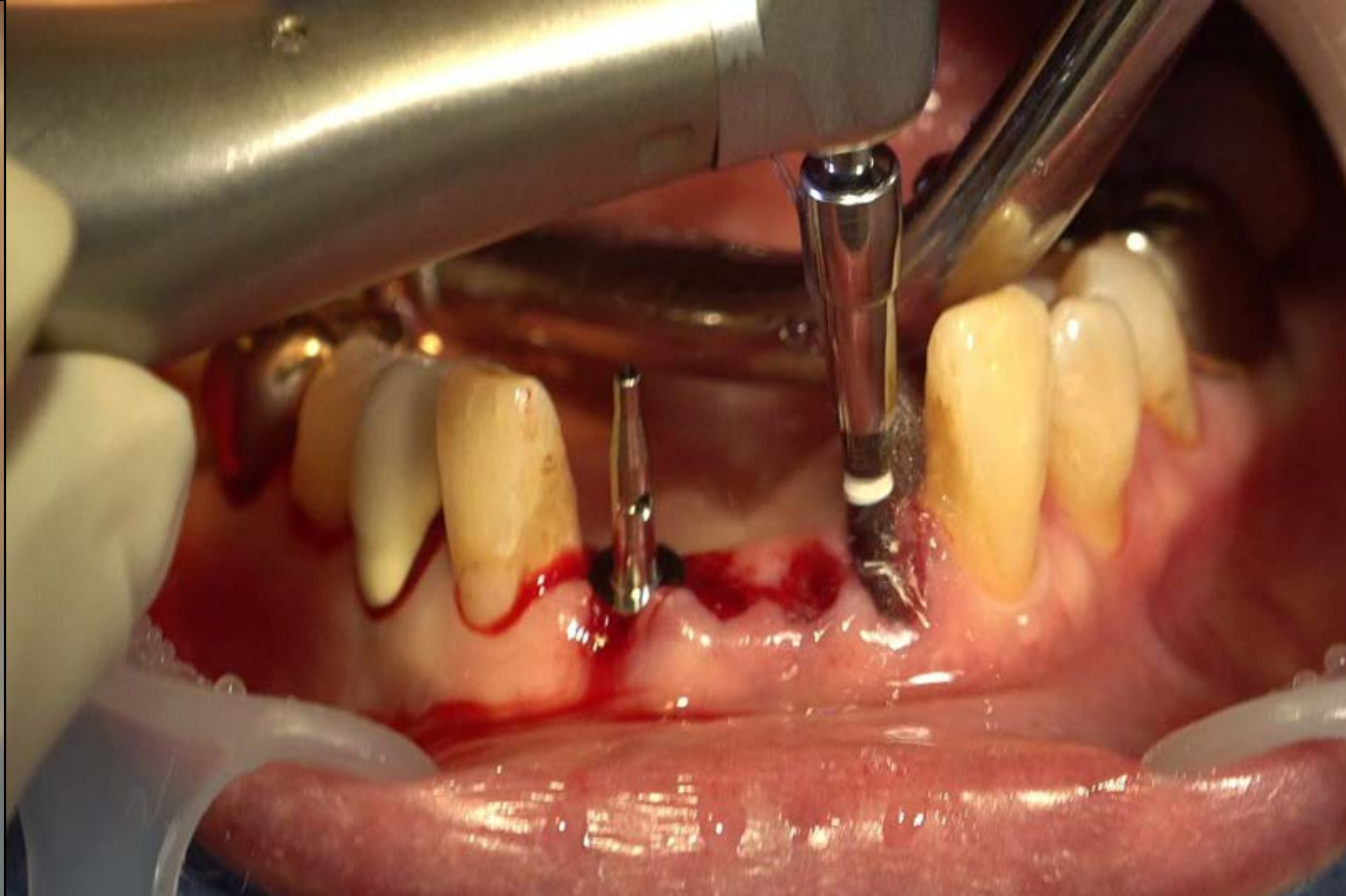

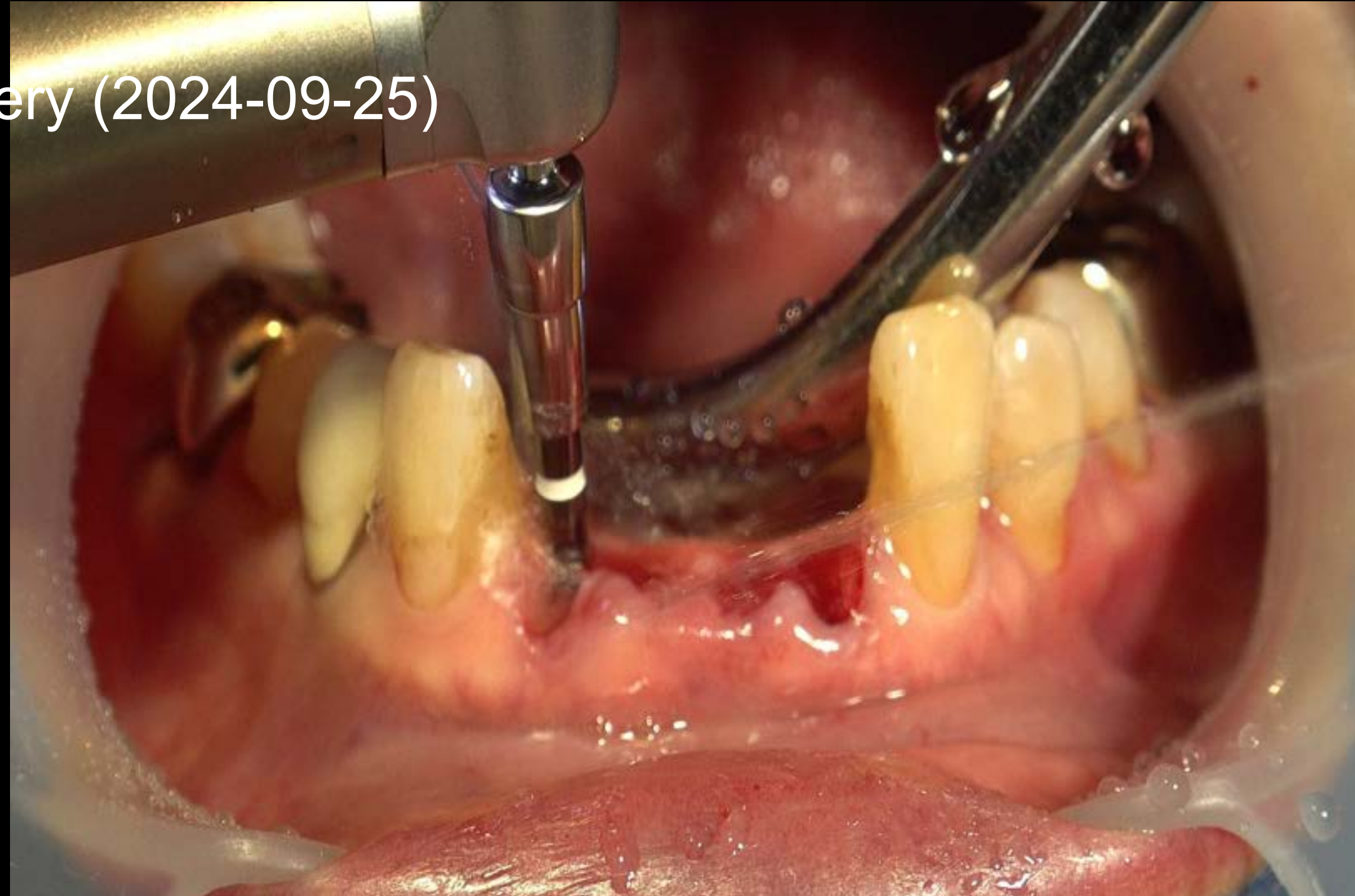
Pre-op (2024-09-25)



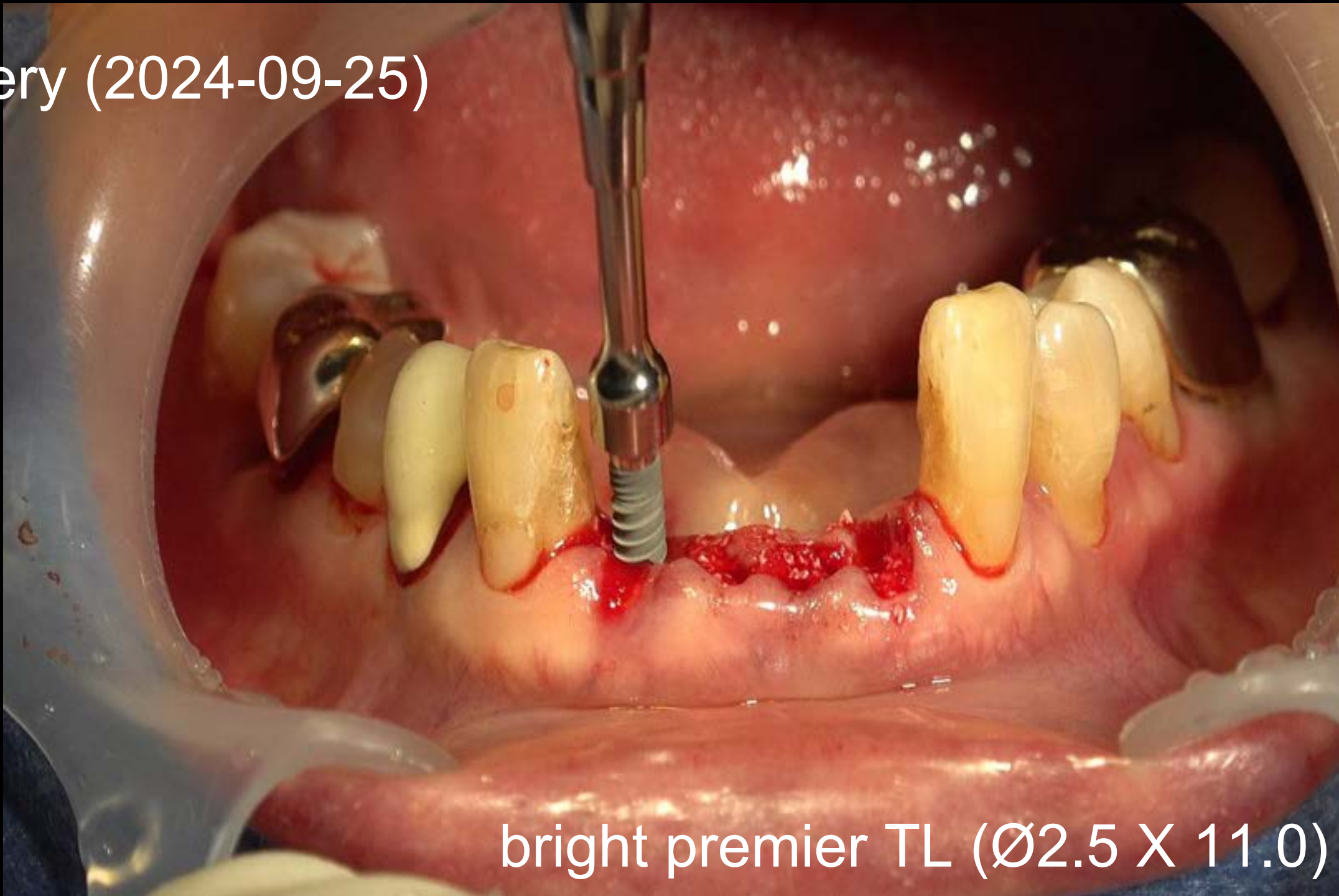


Surgery (2024-09-25)

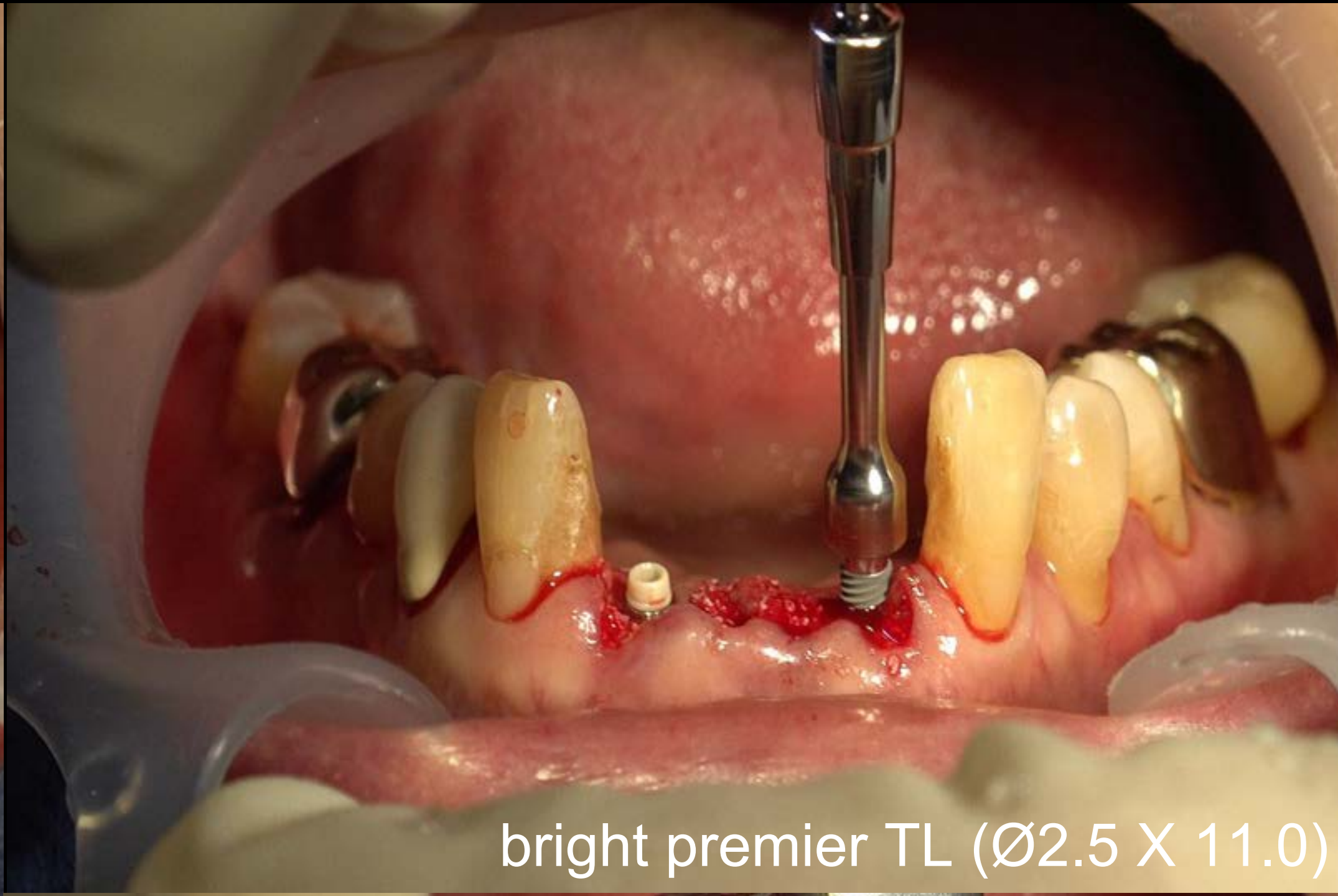

OSTEON™ Xeno Collagen

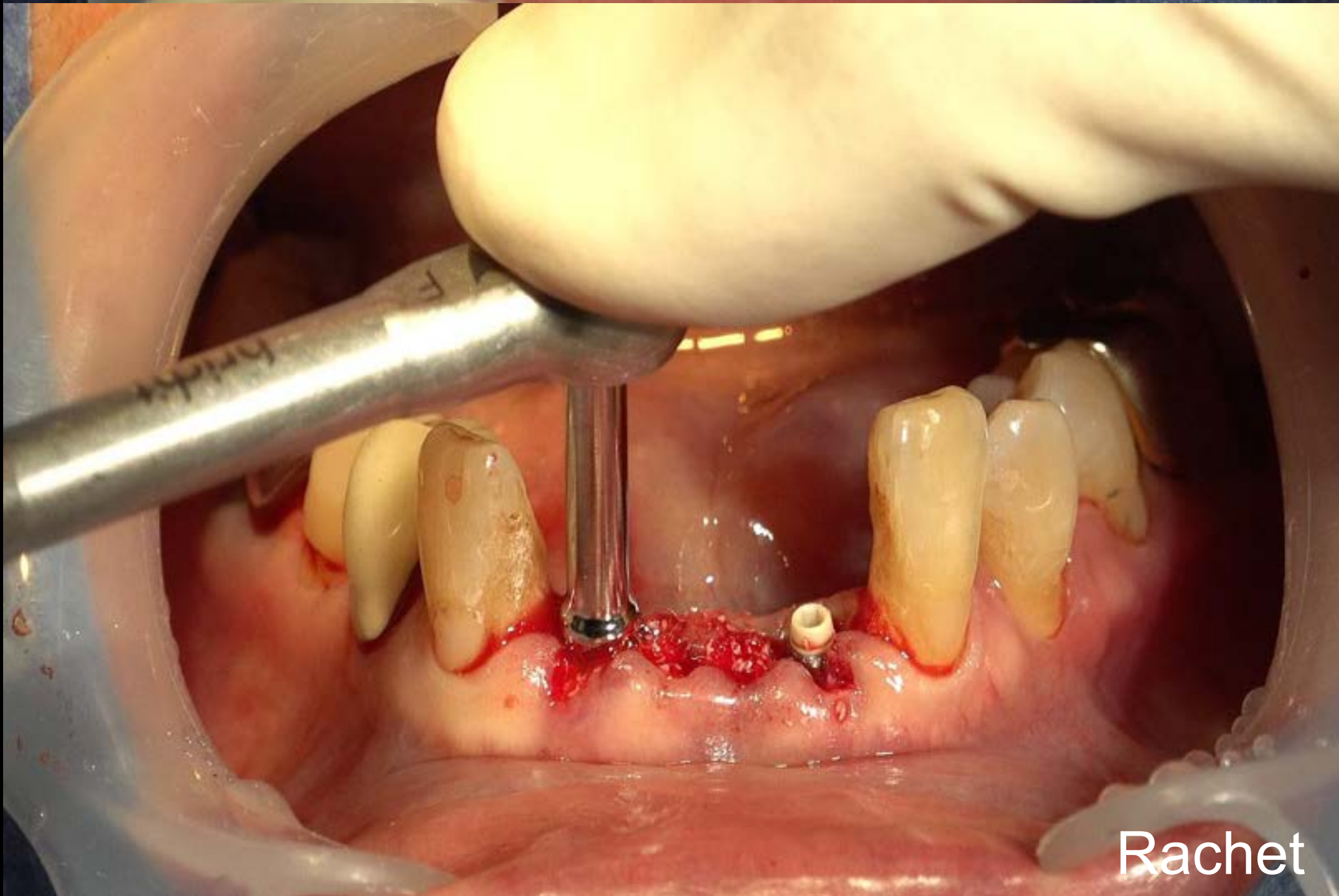
Surgery (2024-09-25)



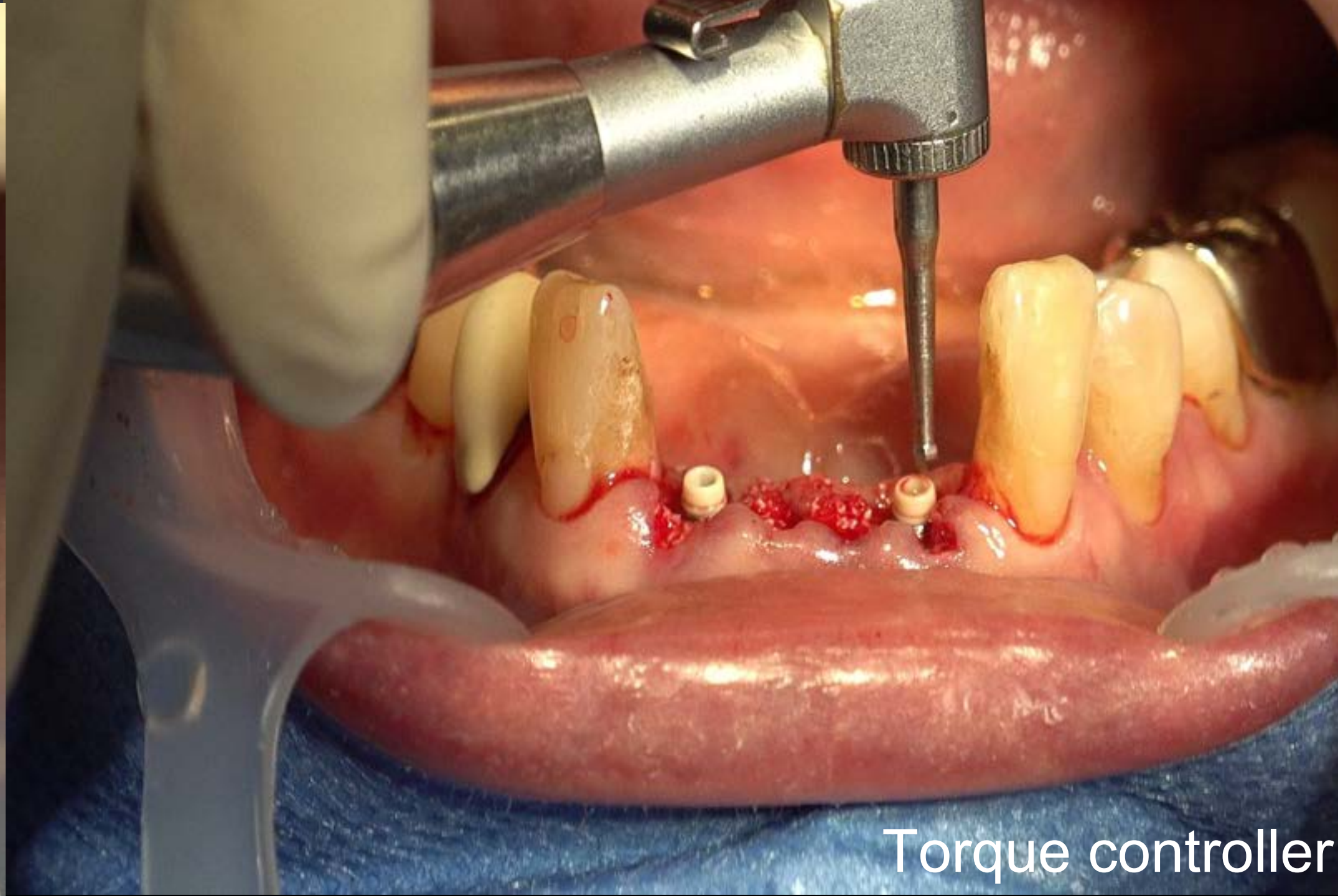
bright premier TL (Ø2.5 X 11.0)



bright premier TL (Ø2.5 X 11.0)

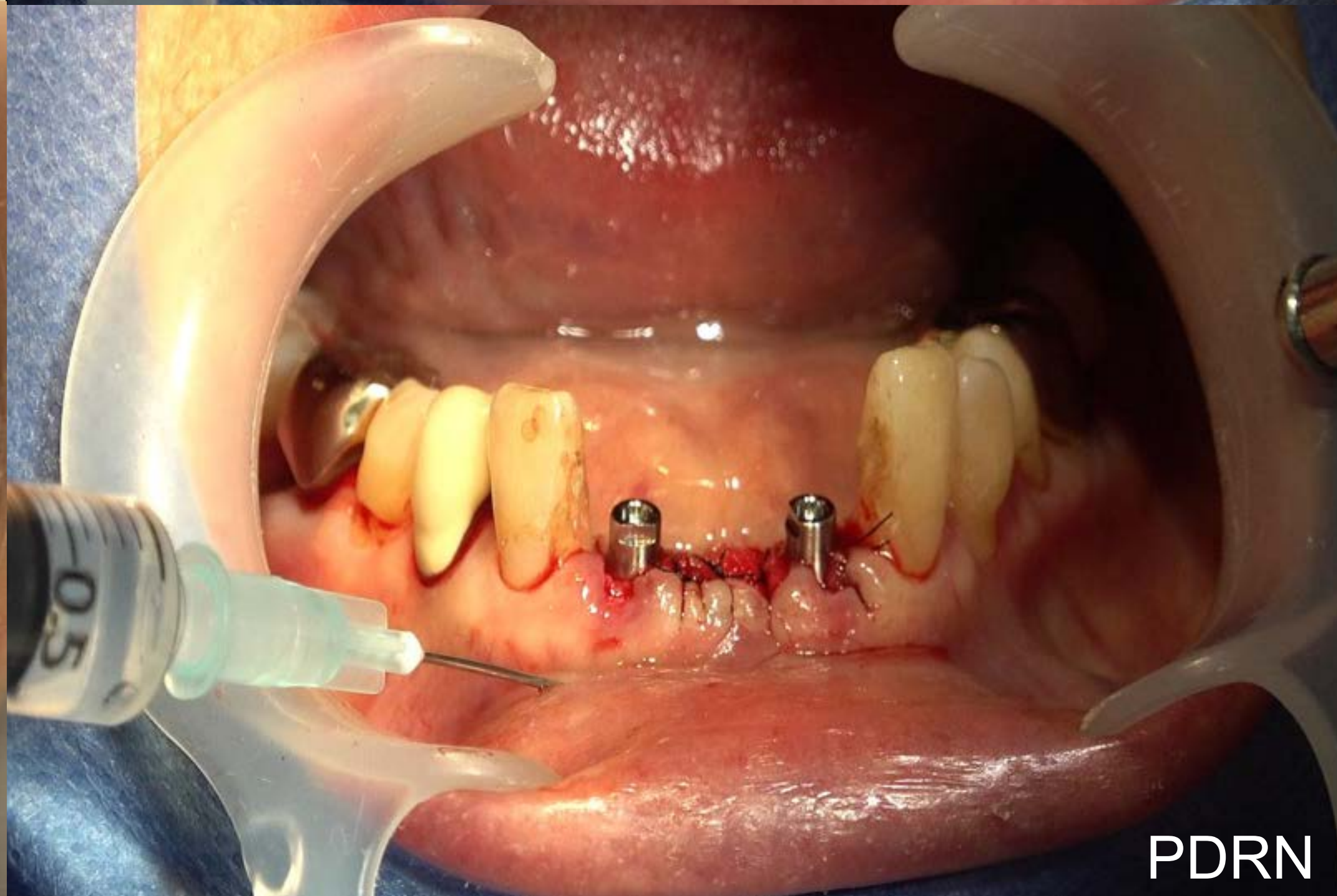
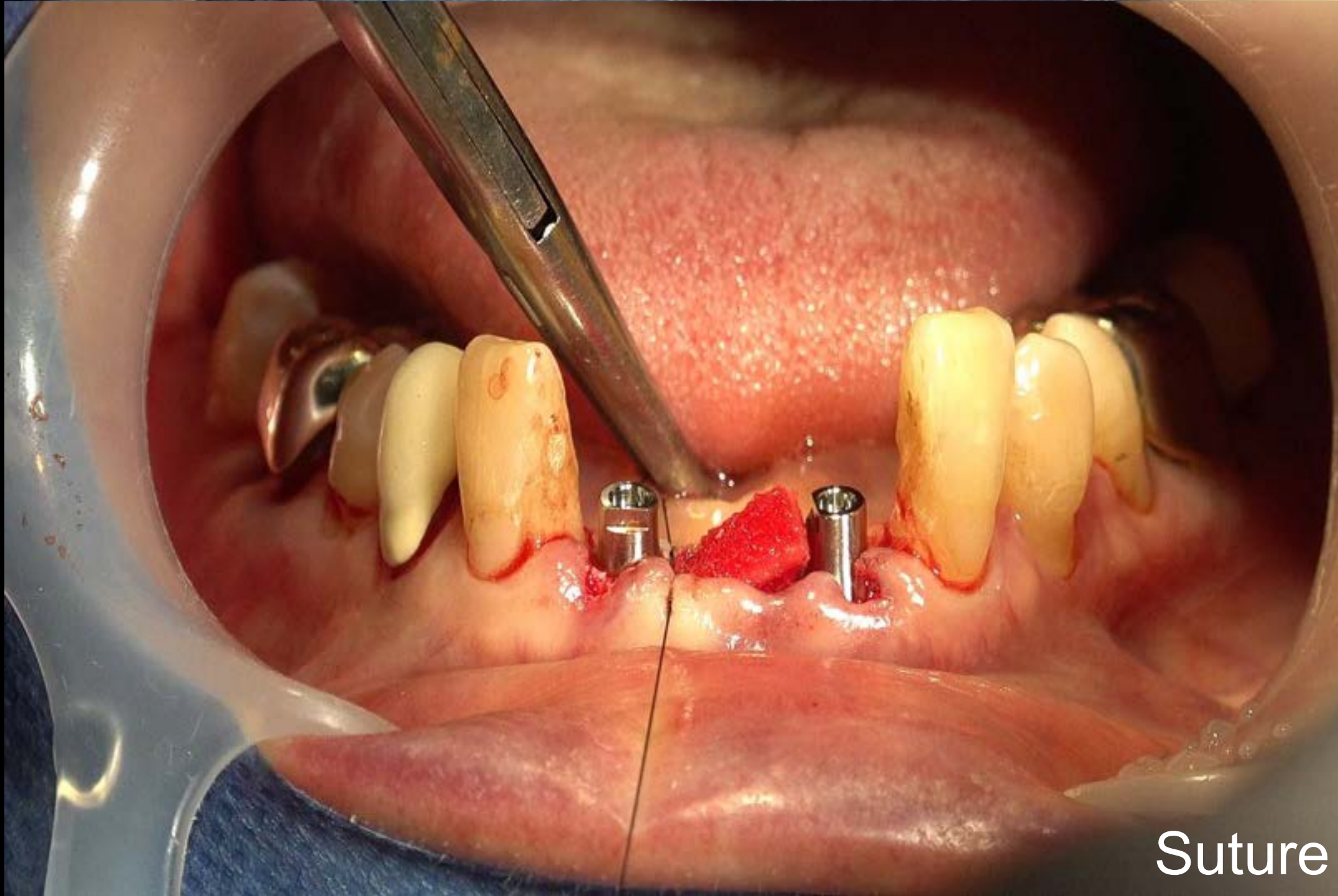
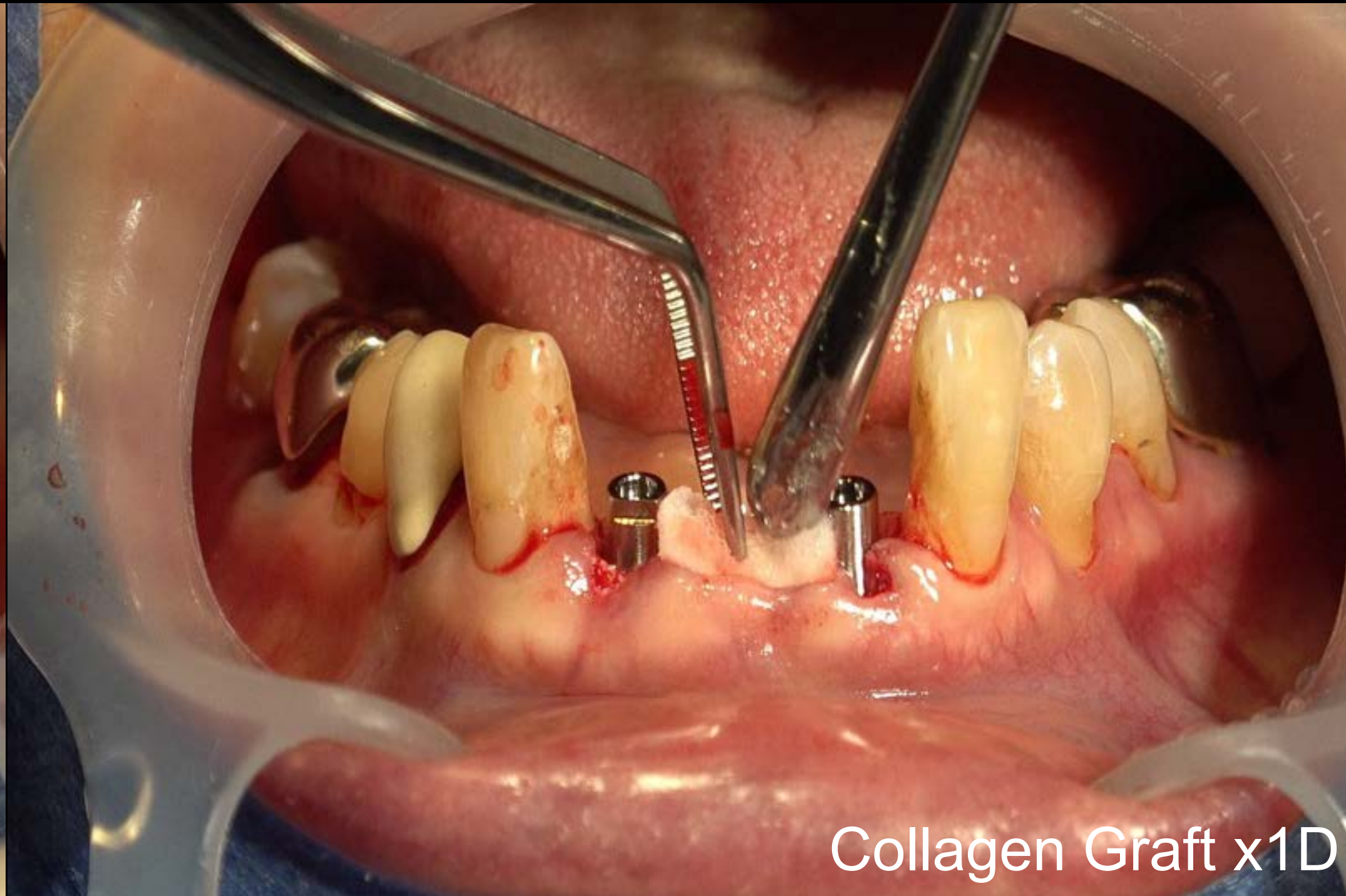
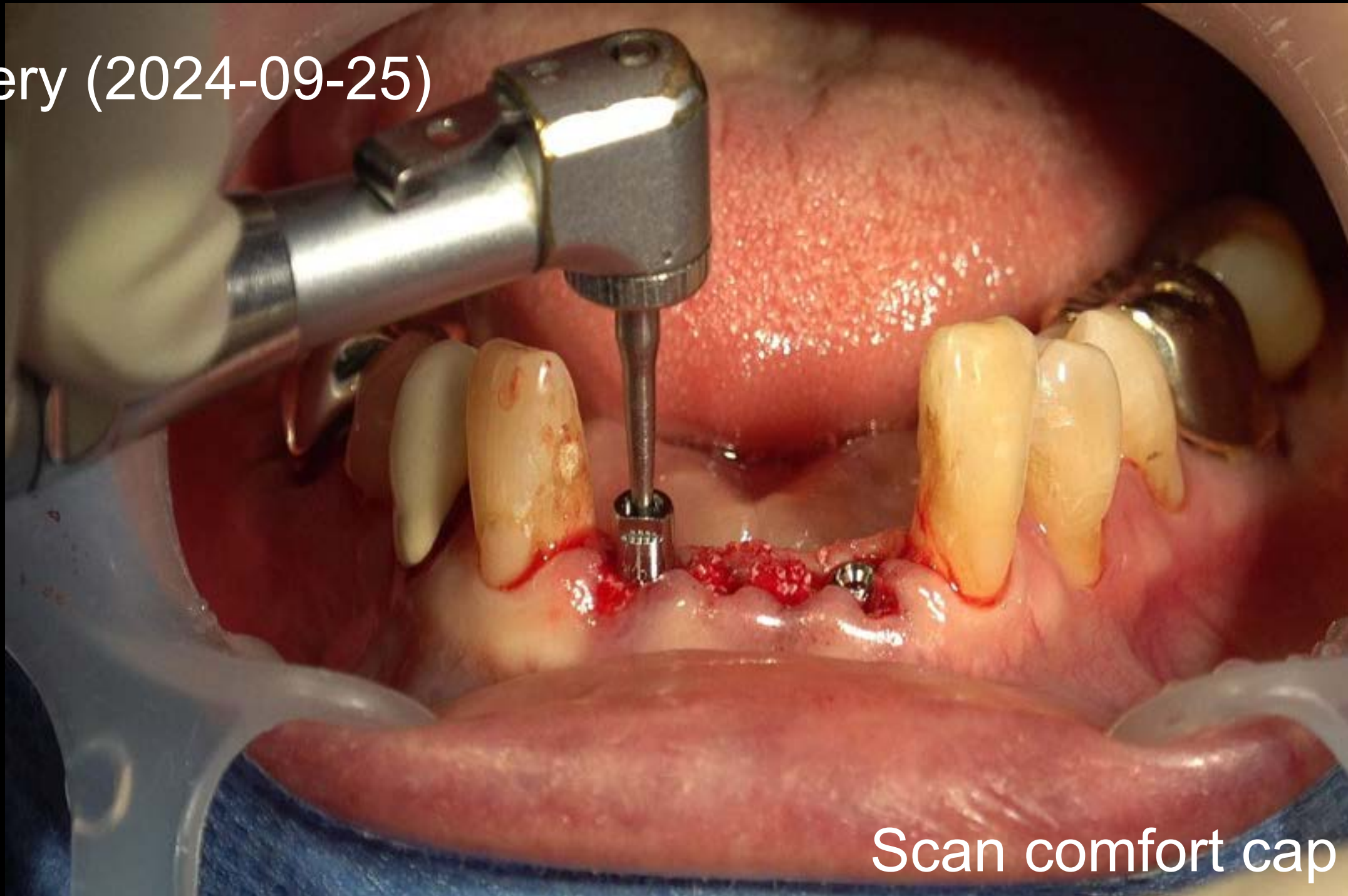

Ratchet

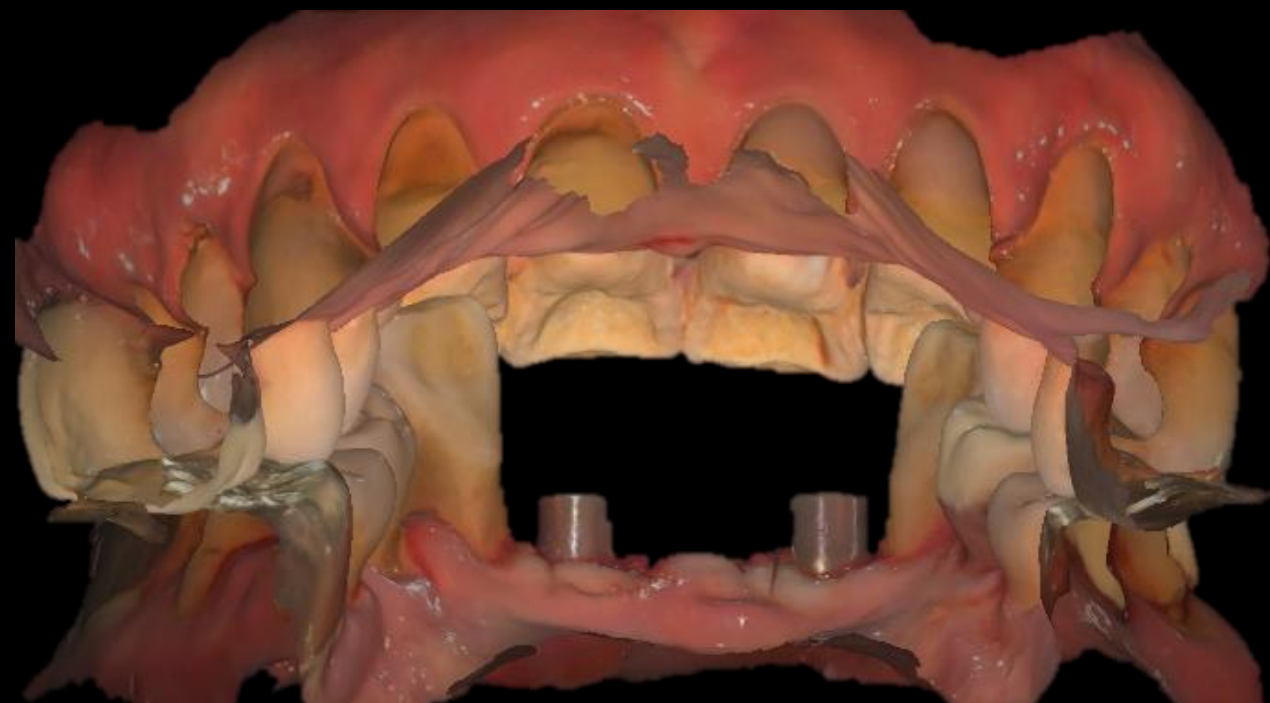
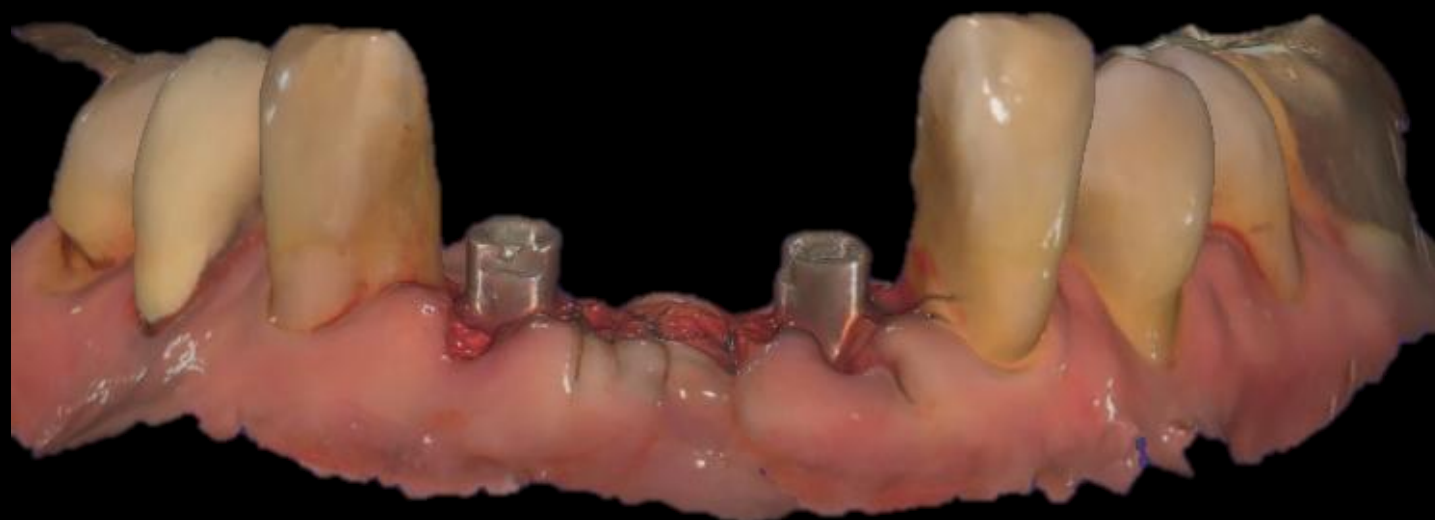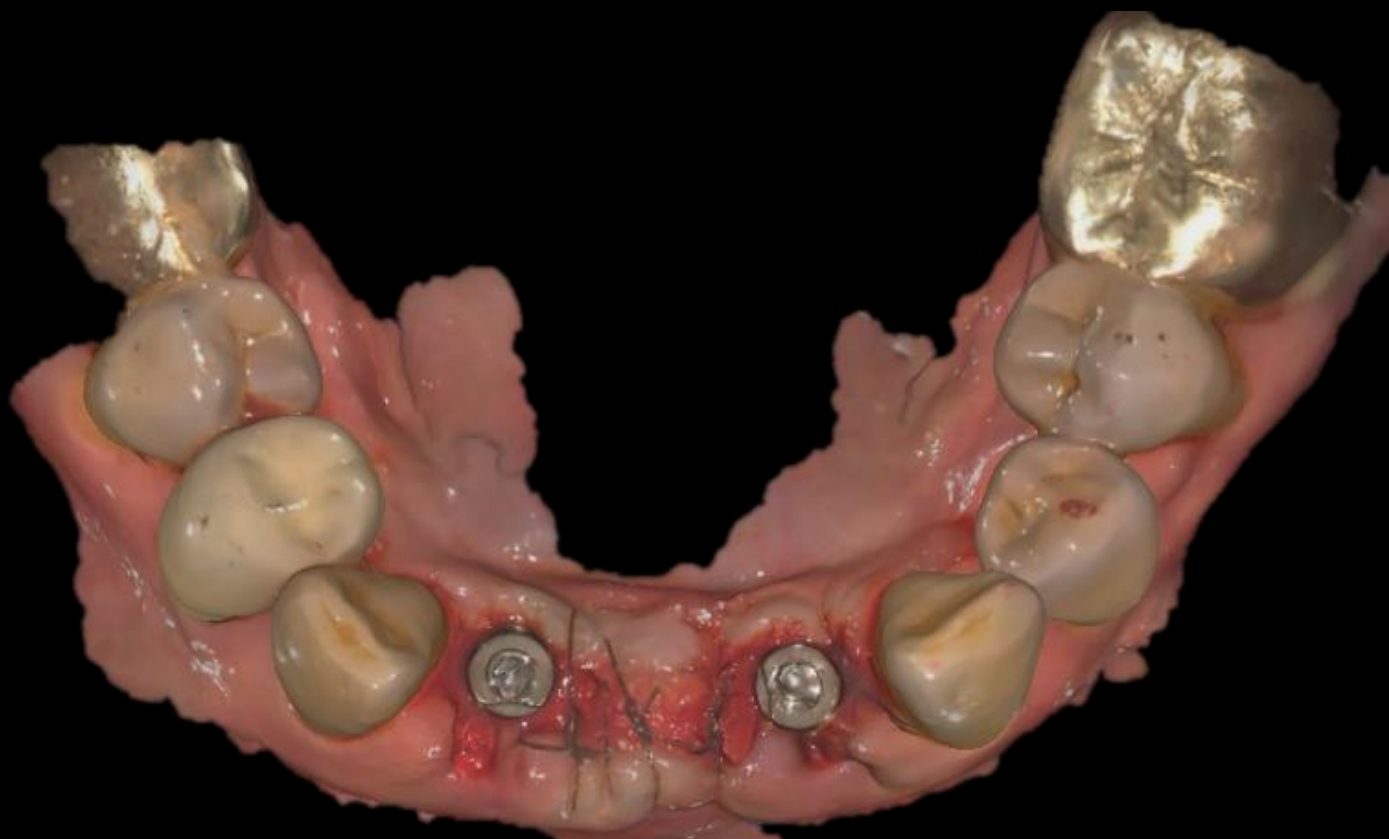
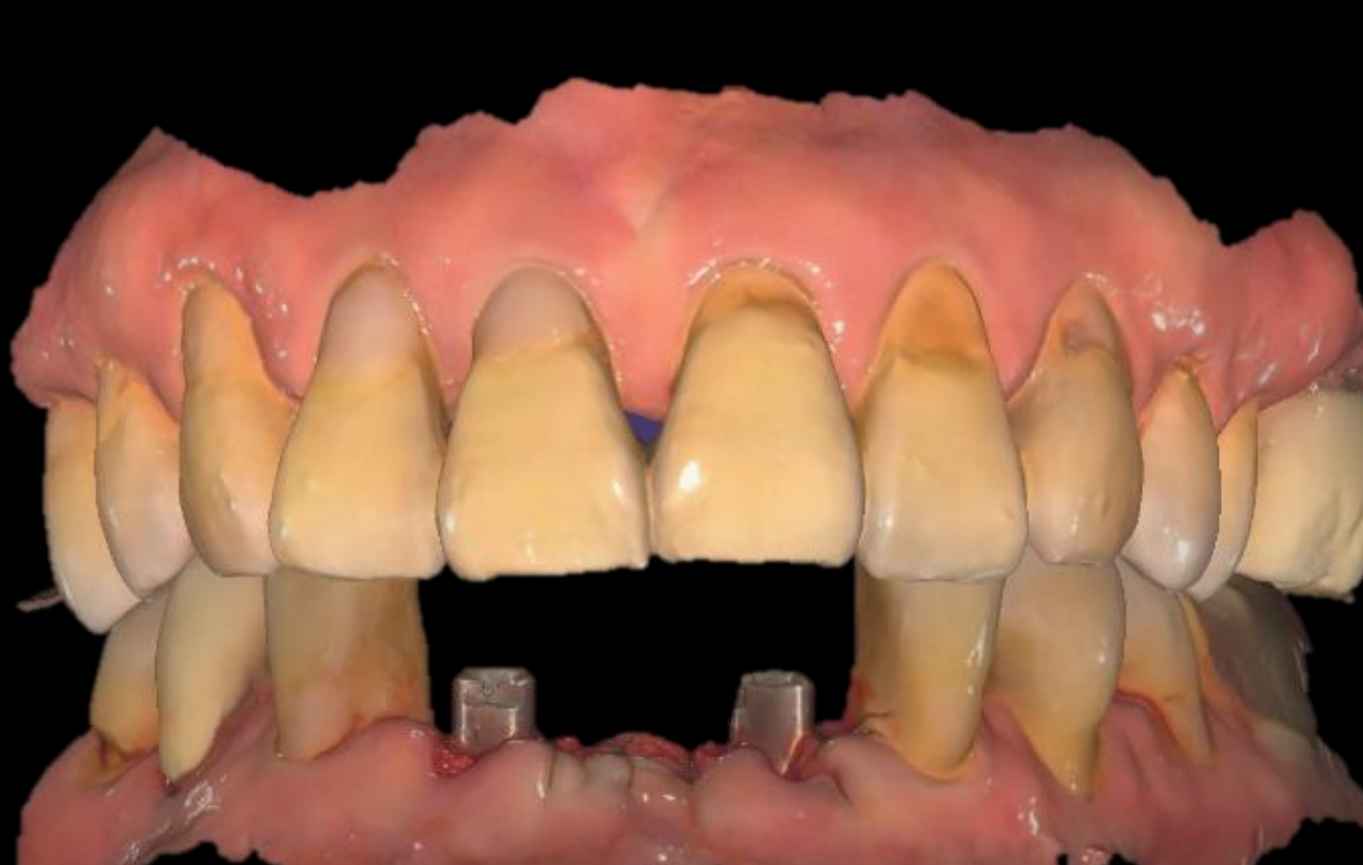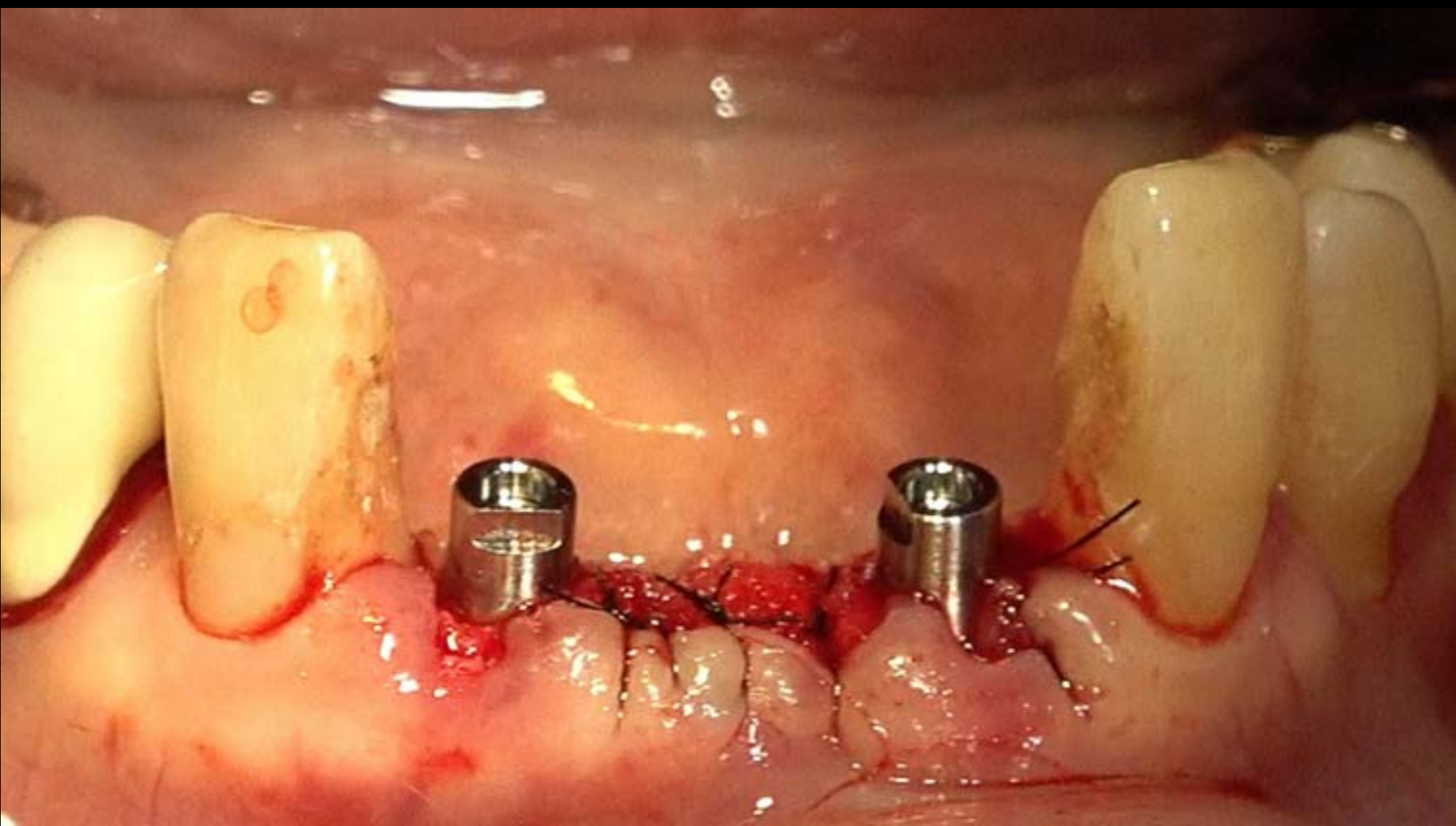


Torque controller

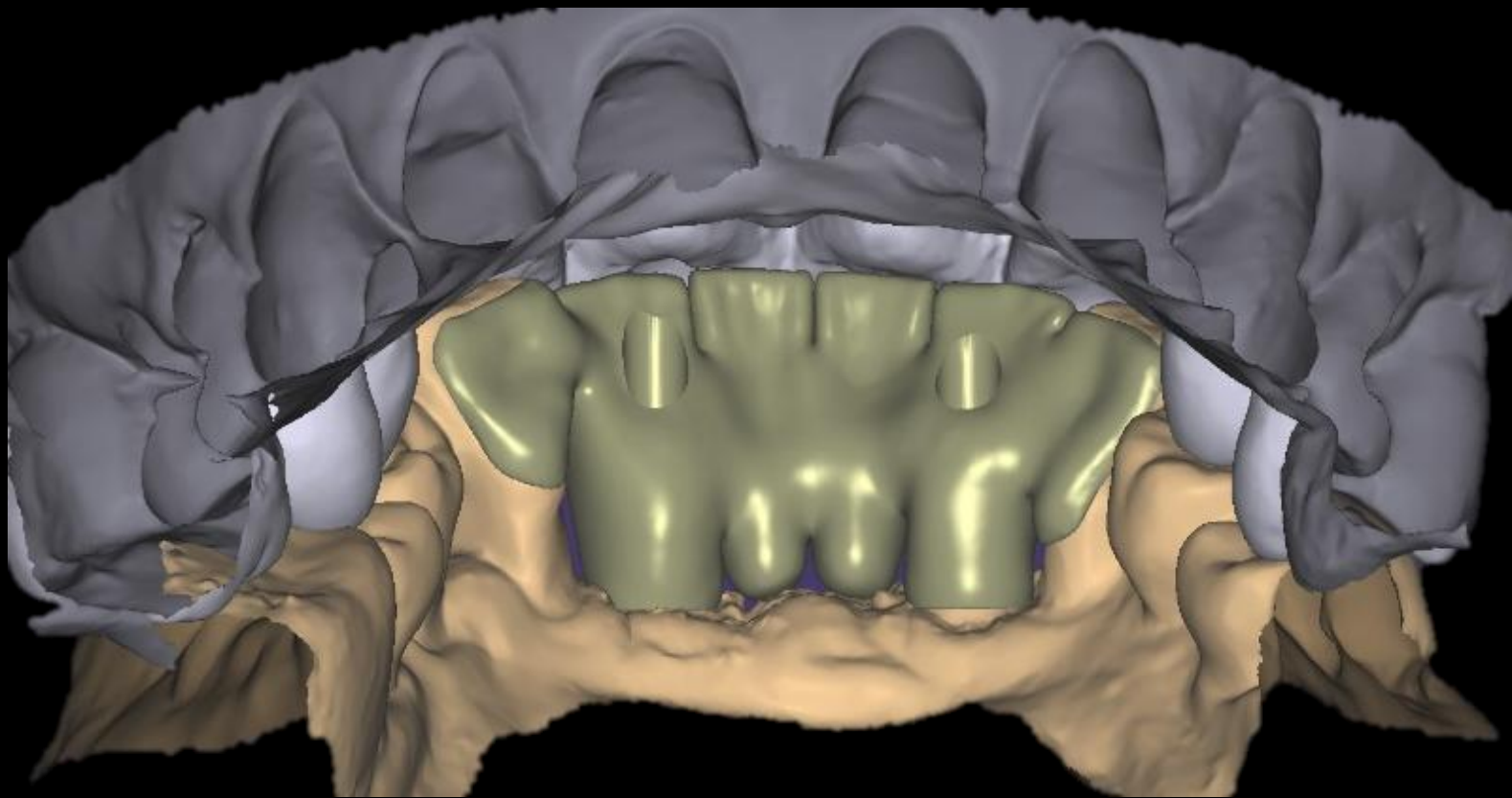
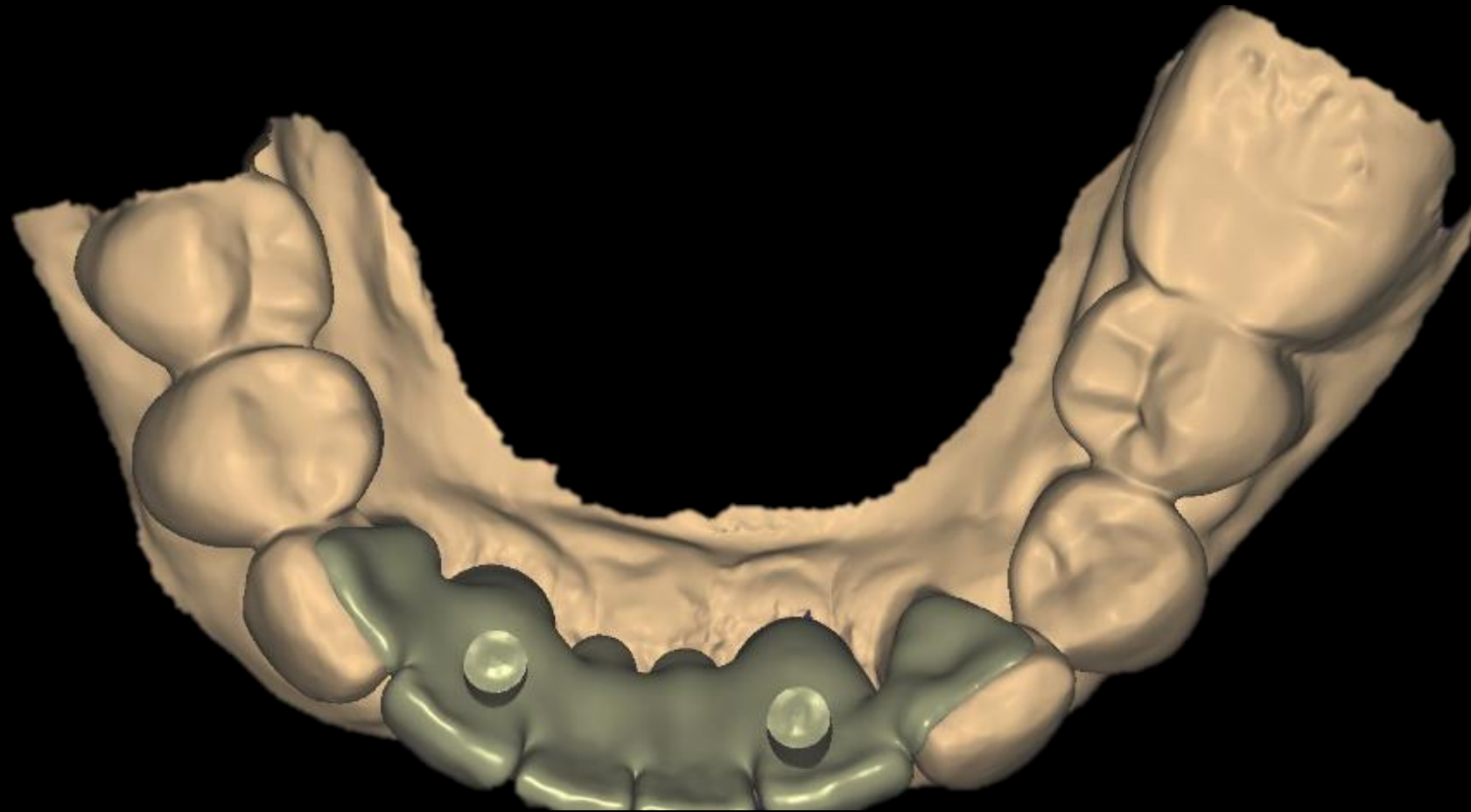
Surgery (2024-09-25)



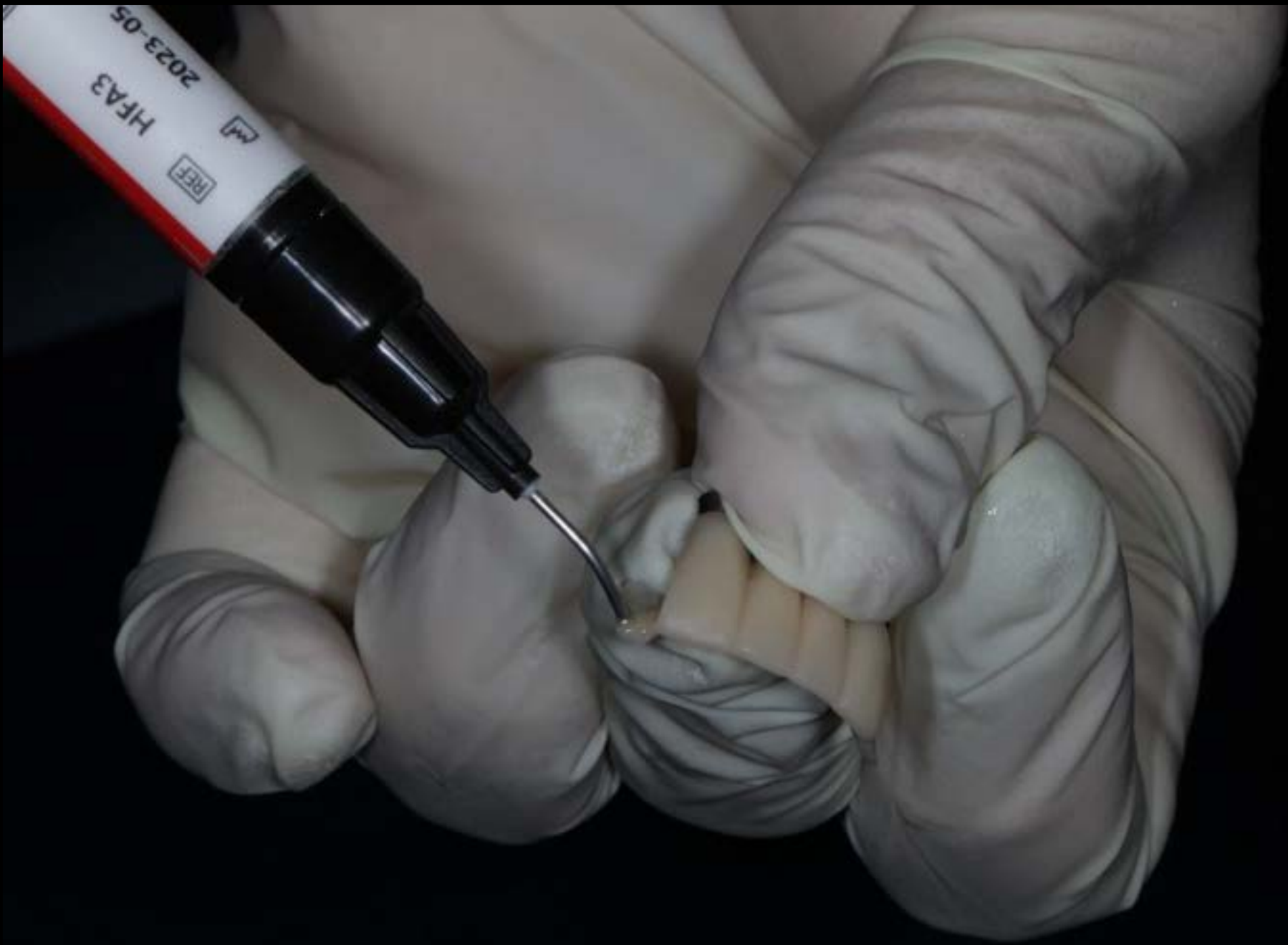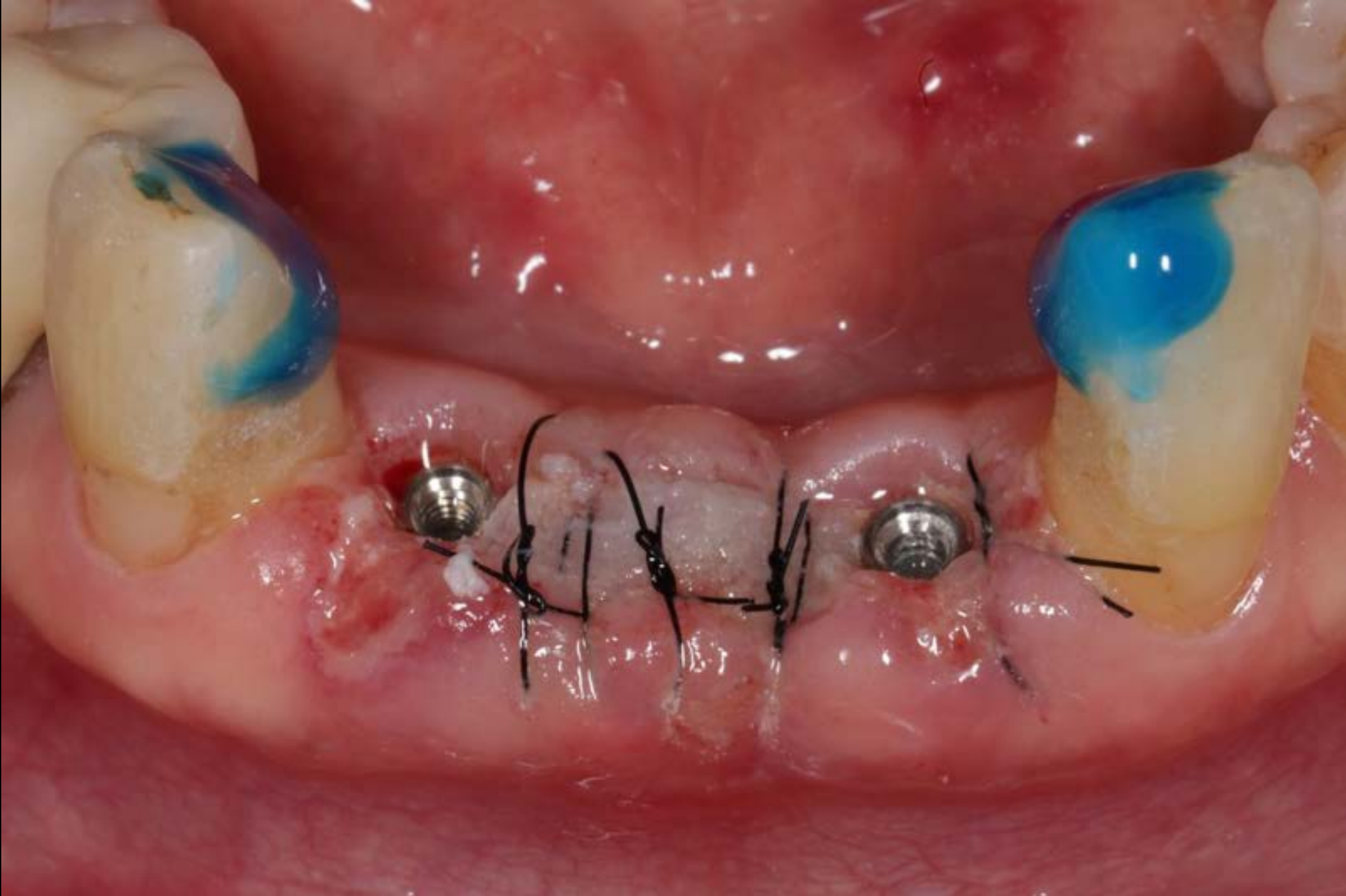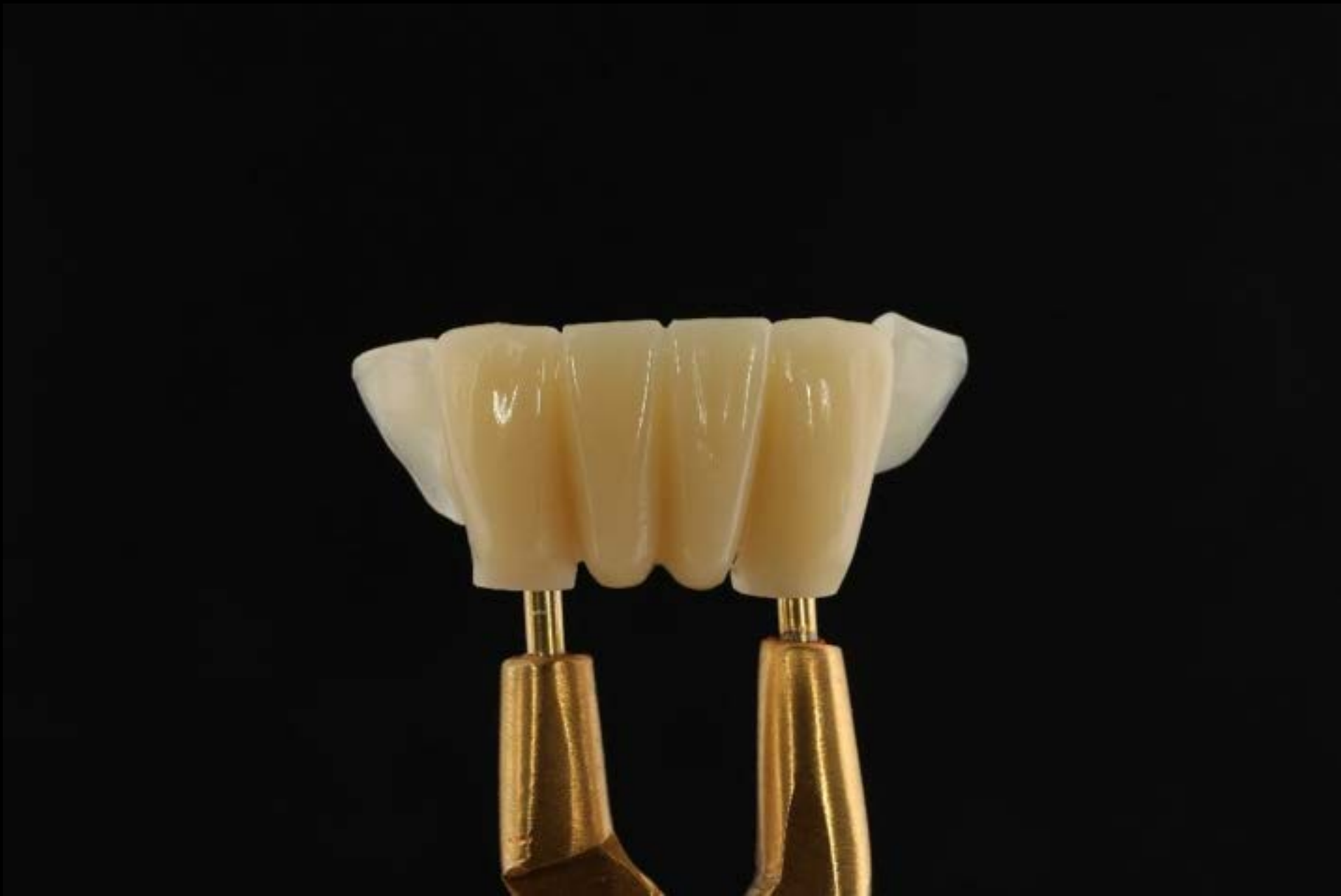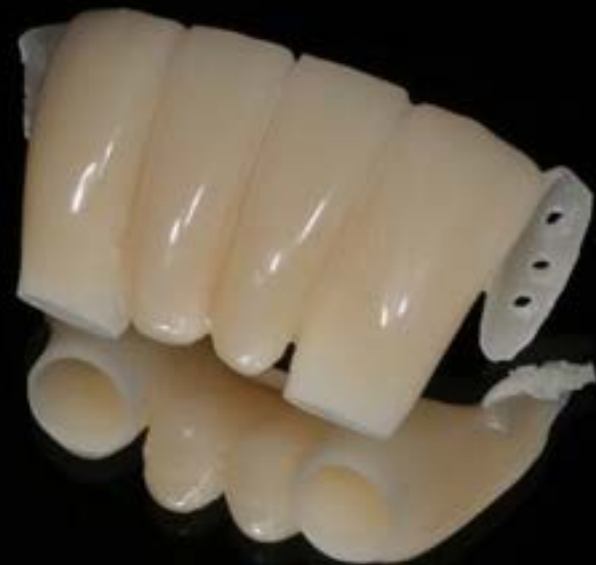Intra Oral Scan



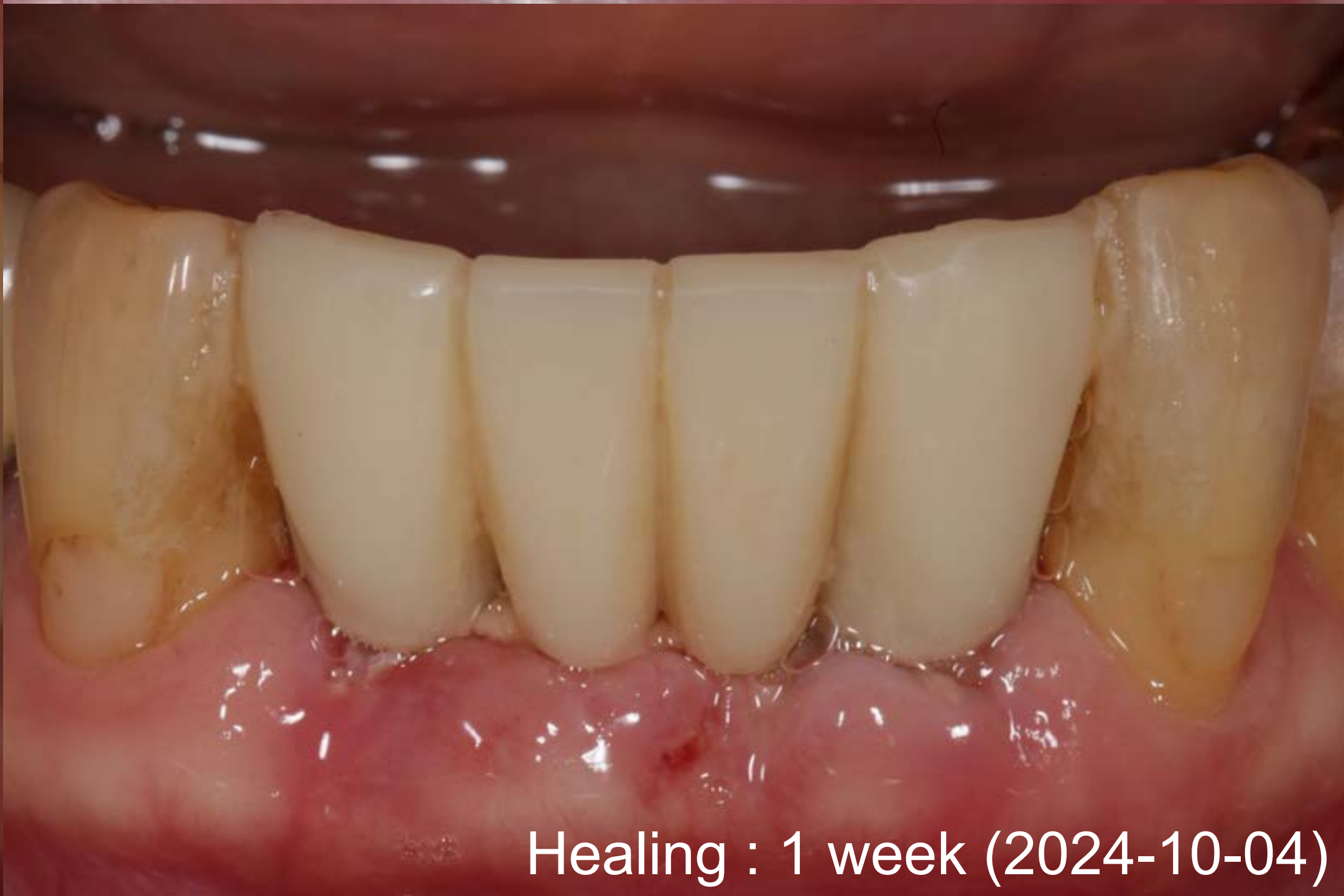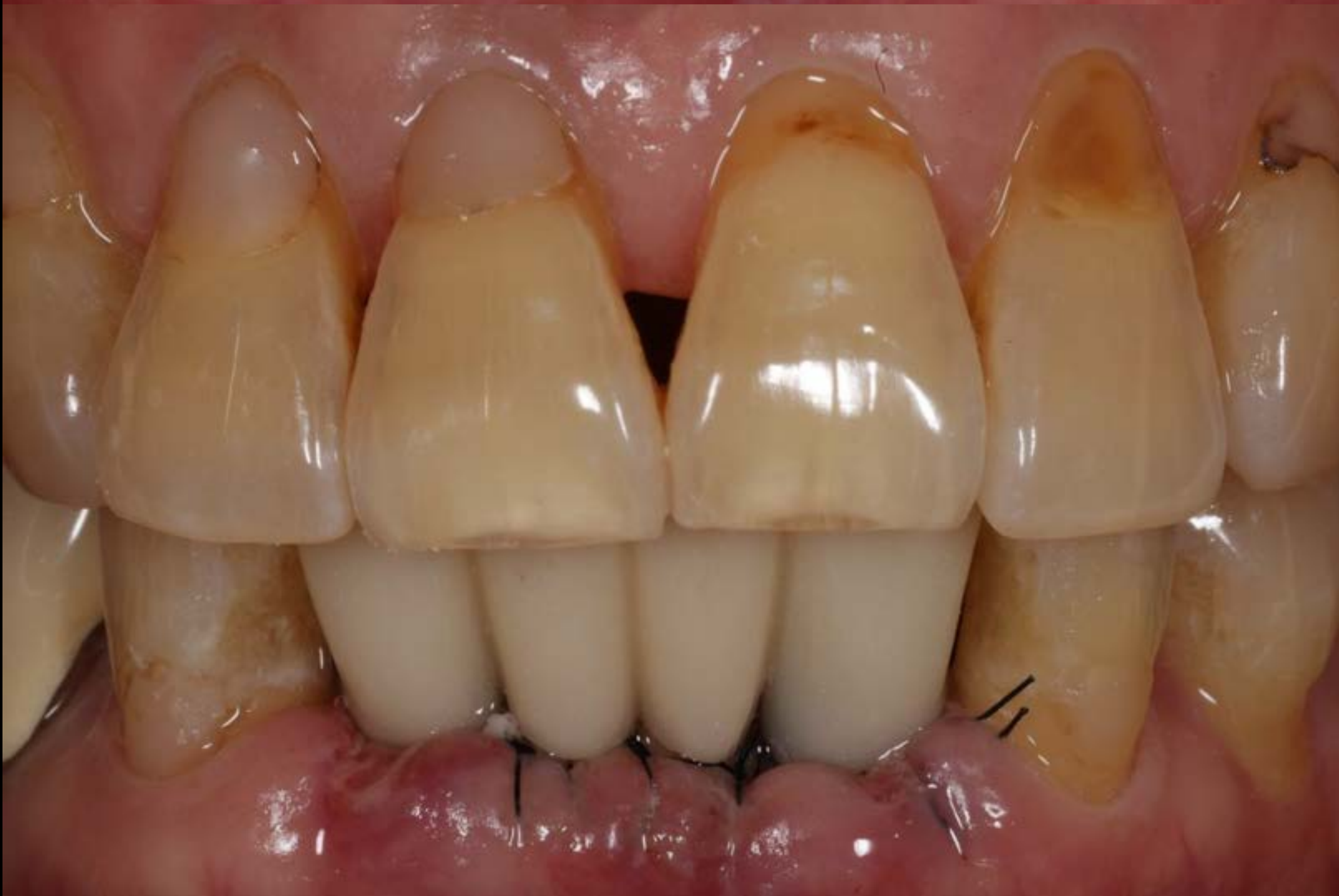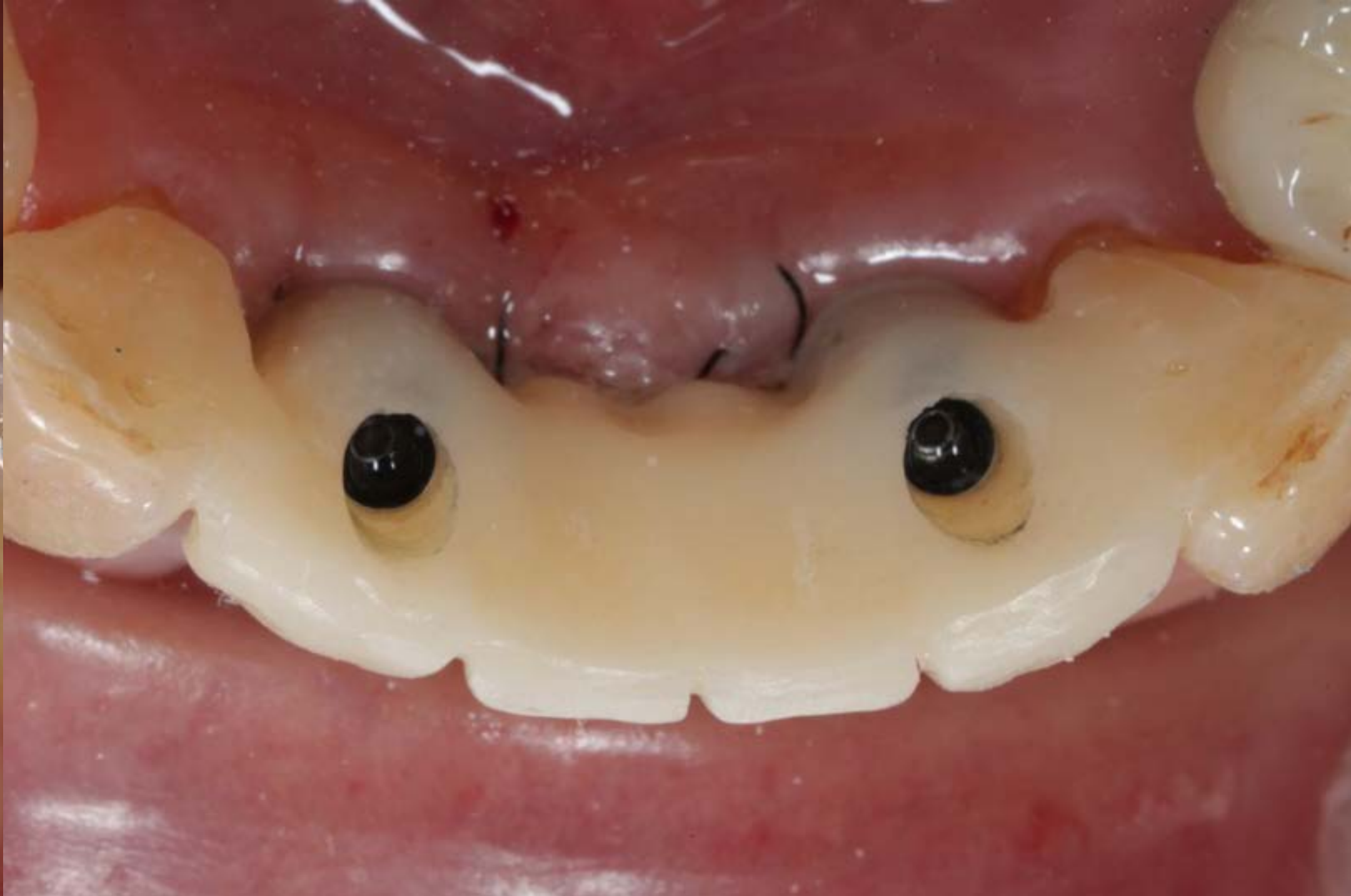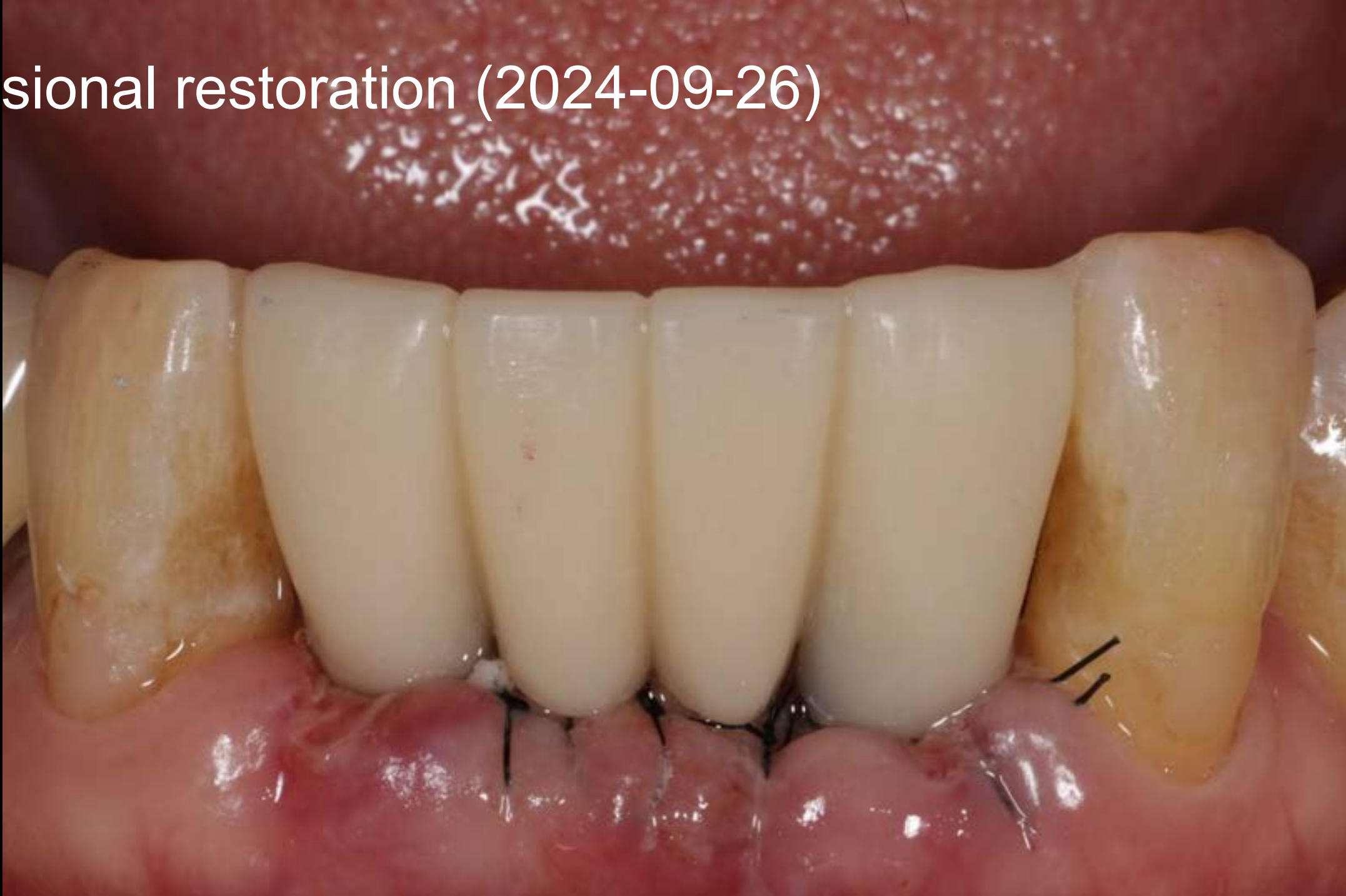CAD(Temporary)



Temporary Crown

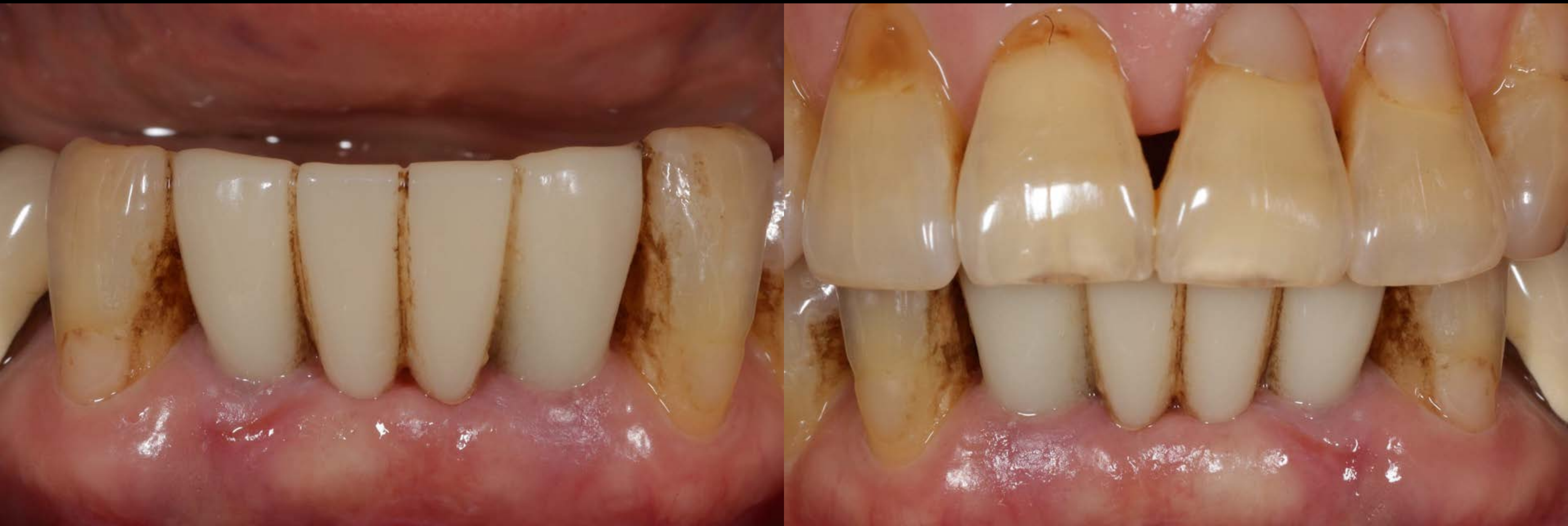

Provisional restoration (2024-09-26)

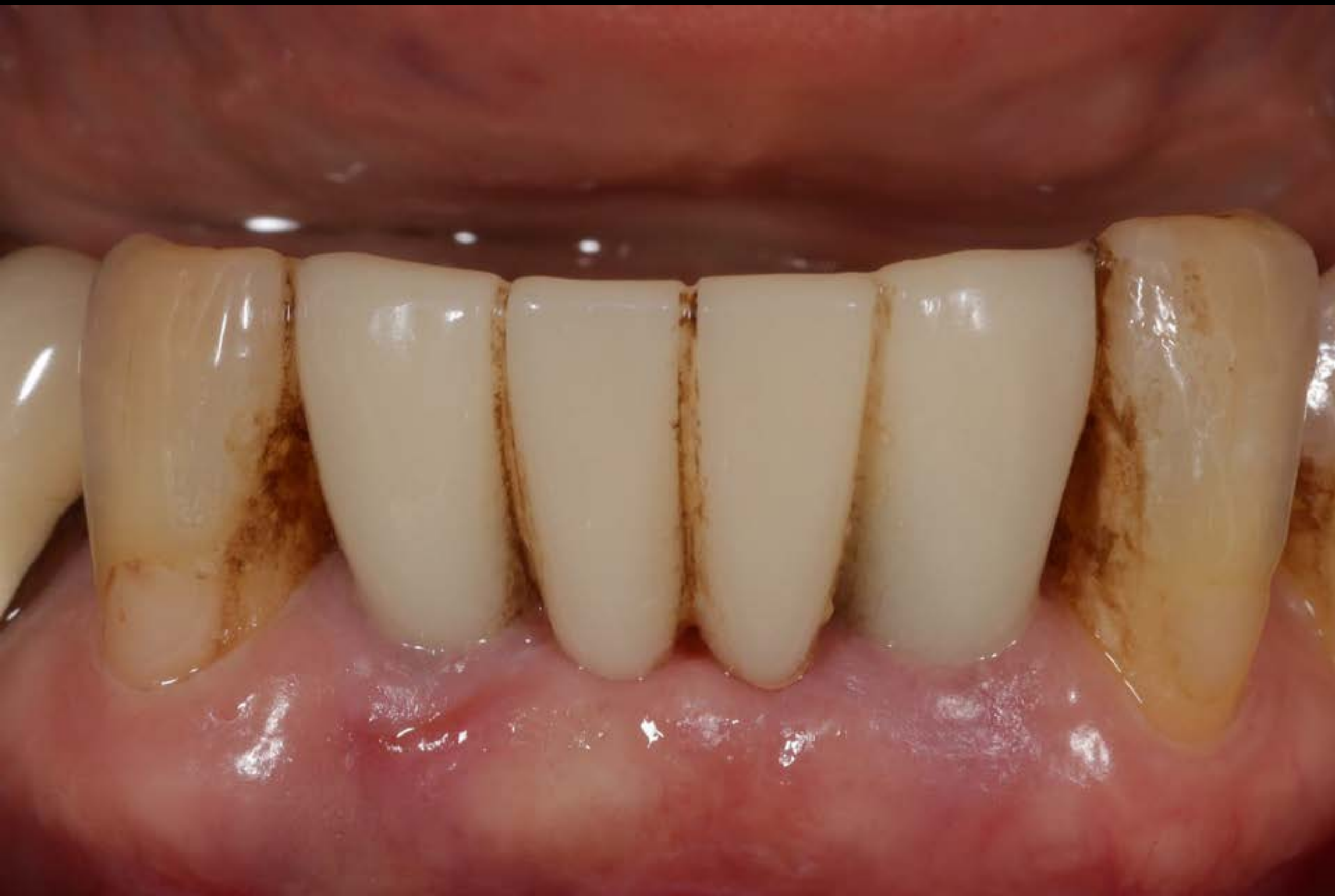

Healing : 1 week (2024-10-04)

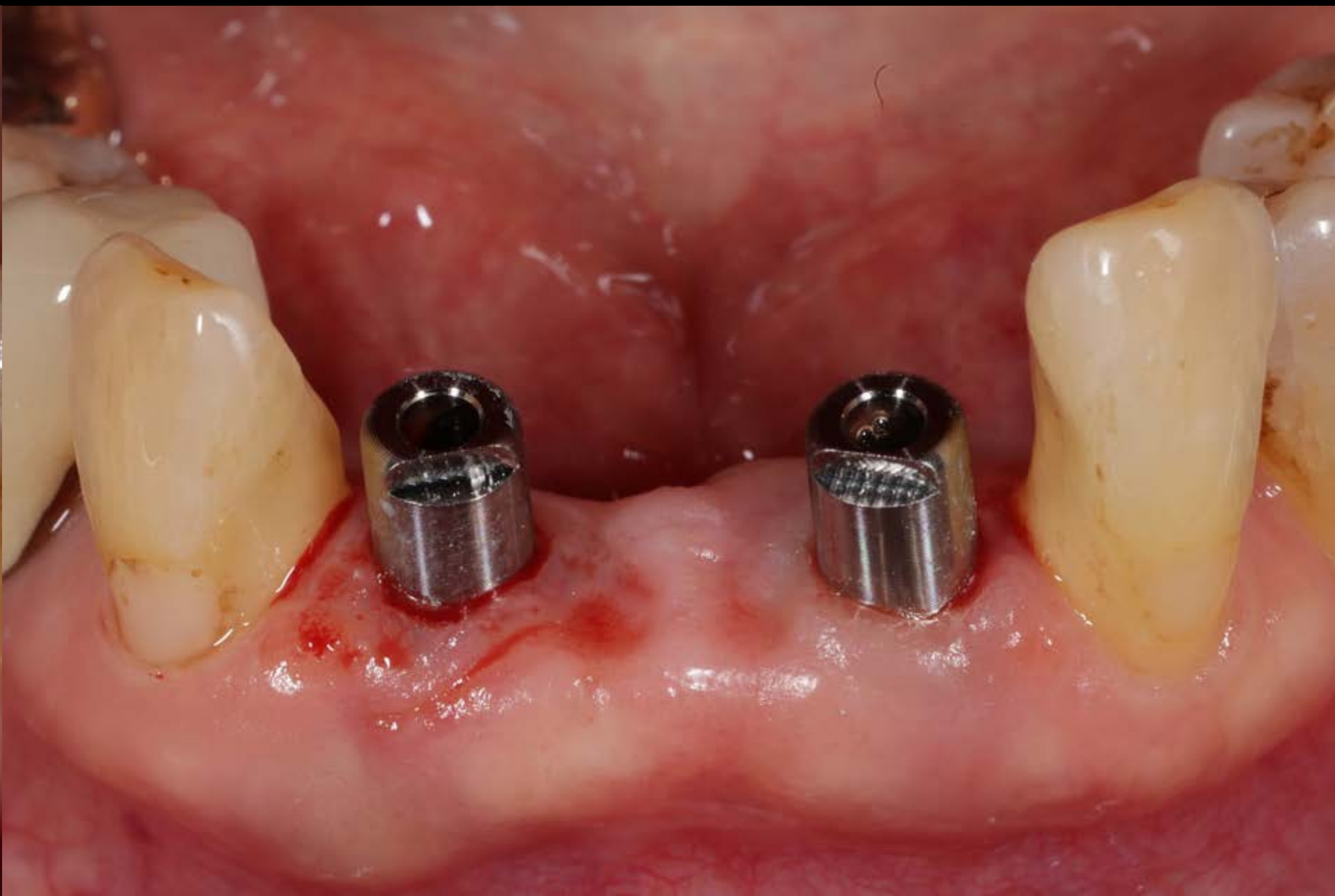Healing : 5 months (2025-03-12)



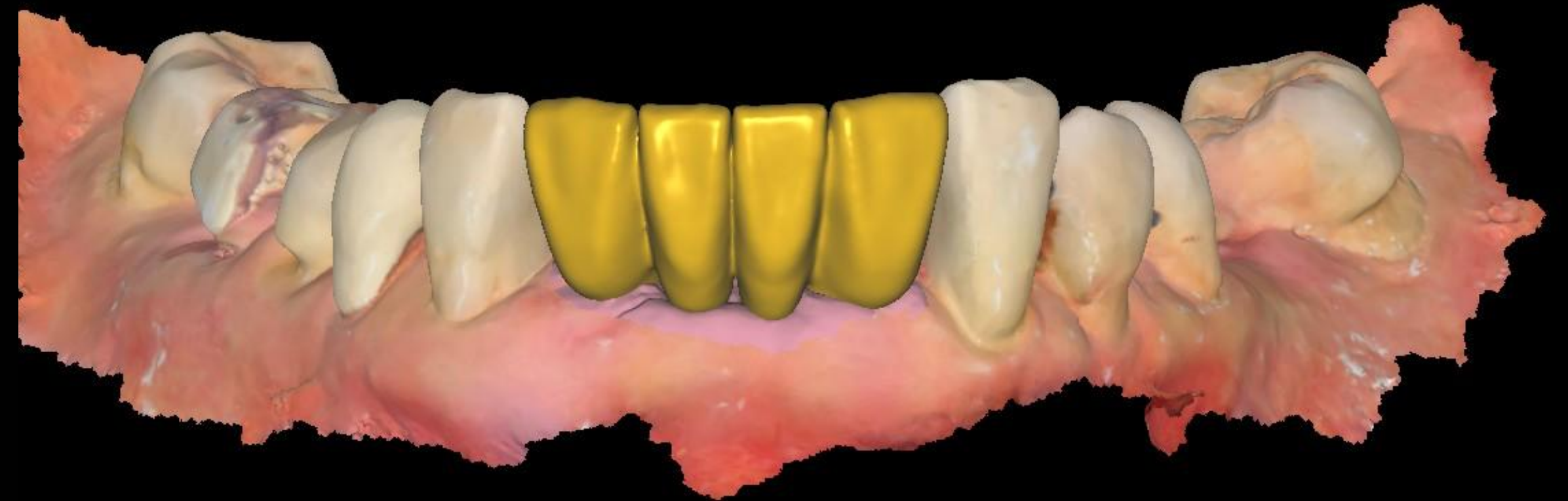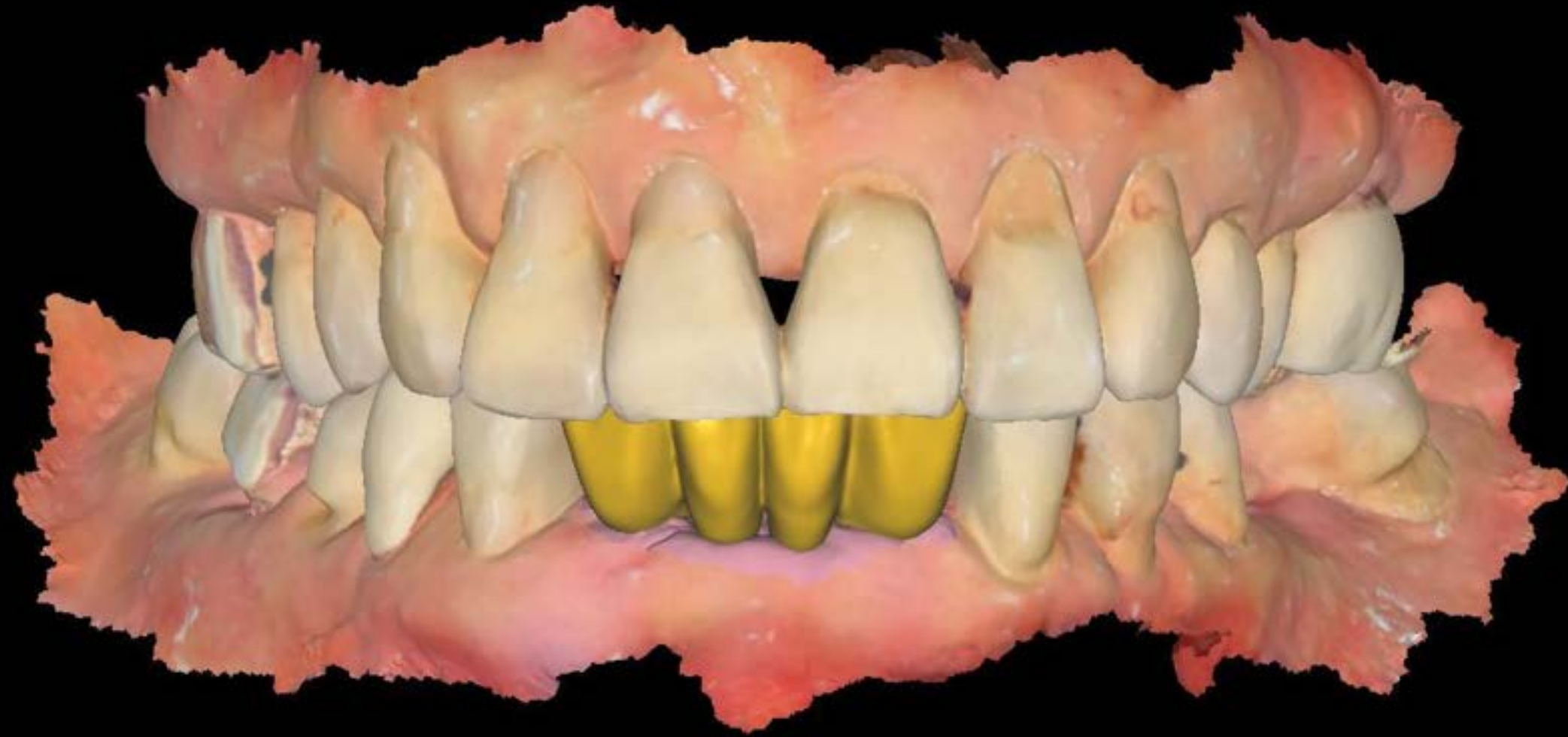Healing : 5 months (2025-03-12)



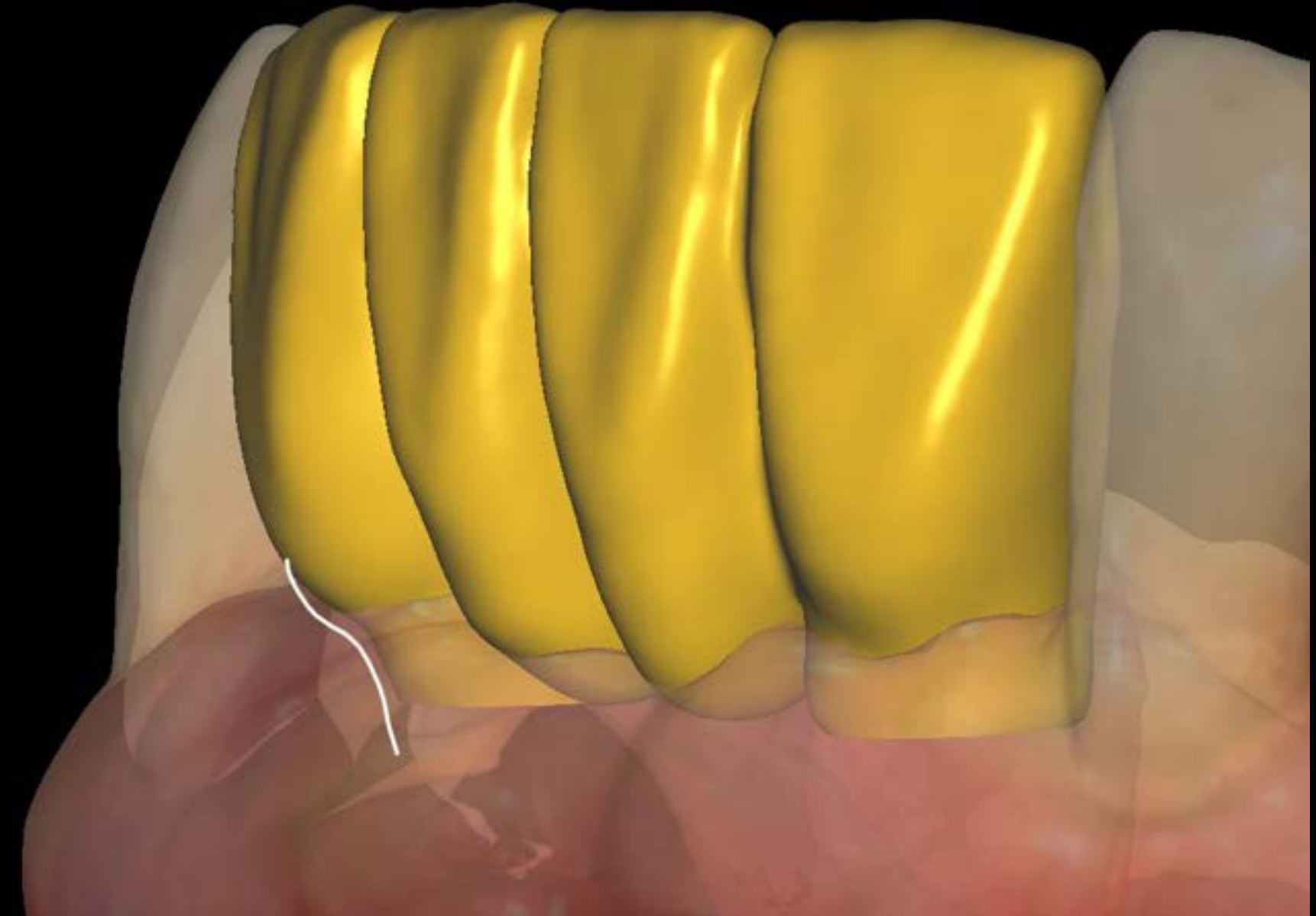
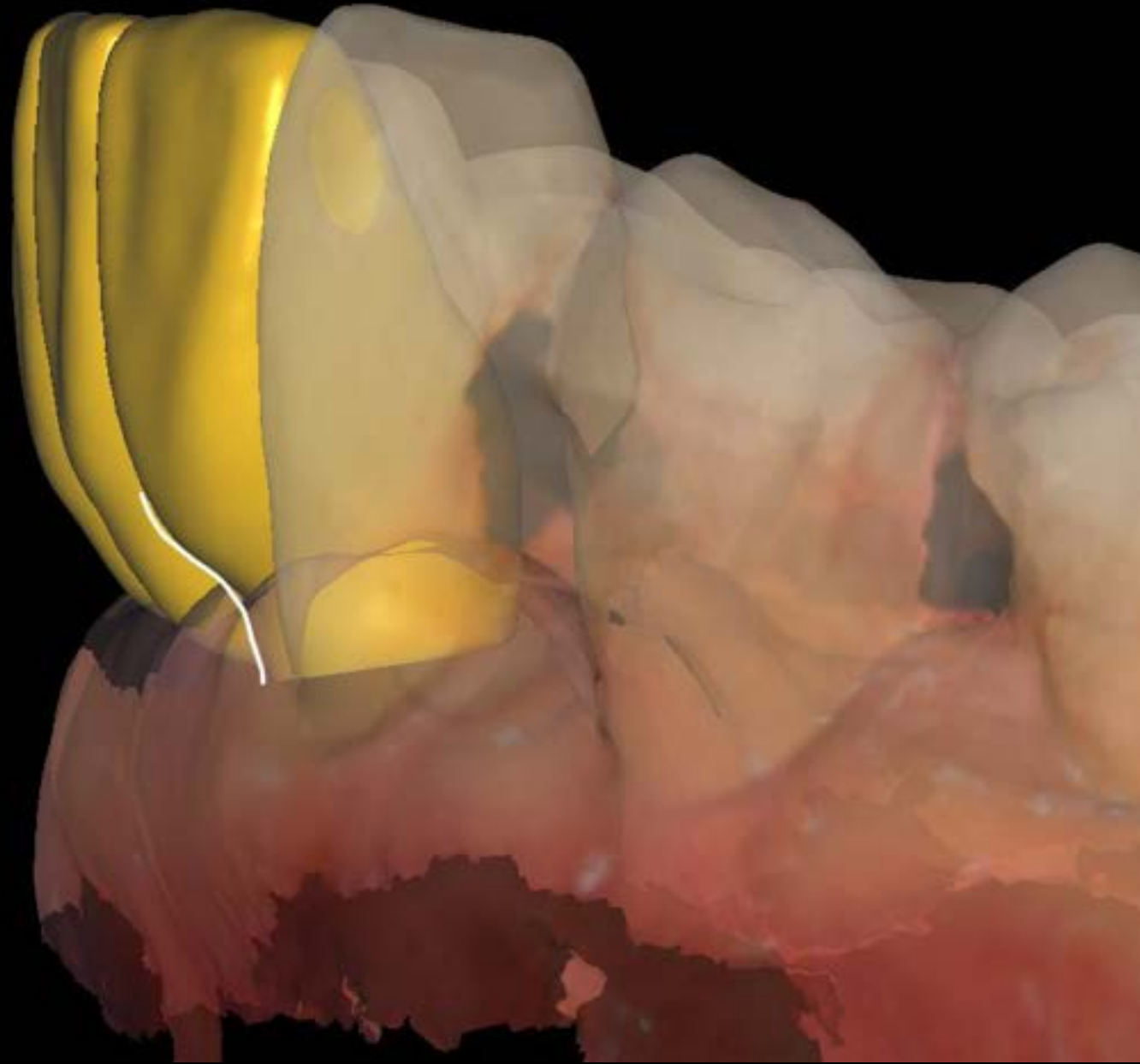Impression (2025-03-12)



Cad Design

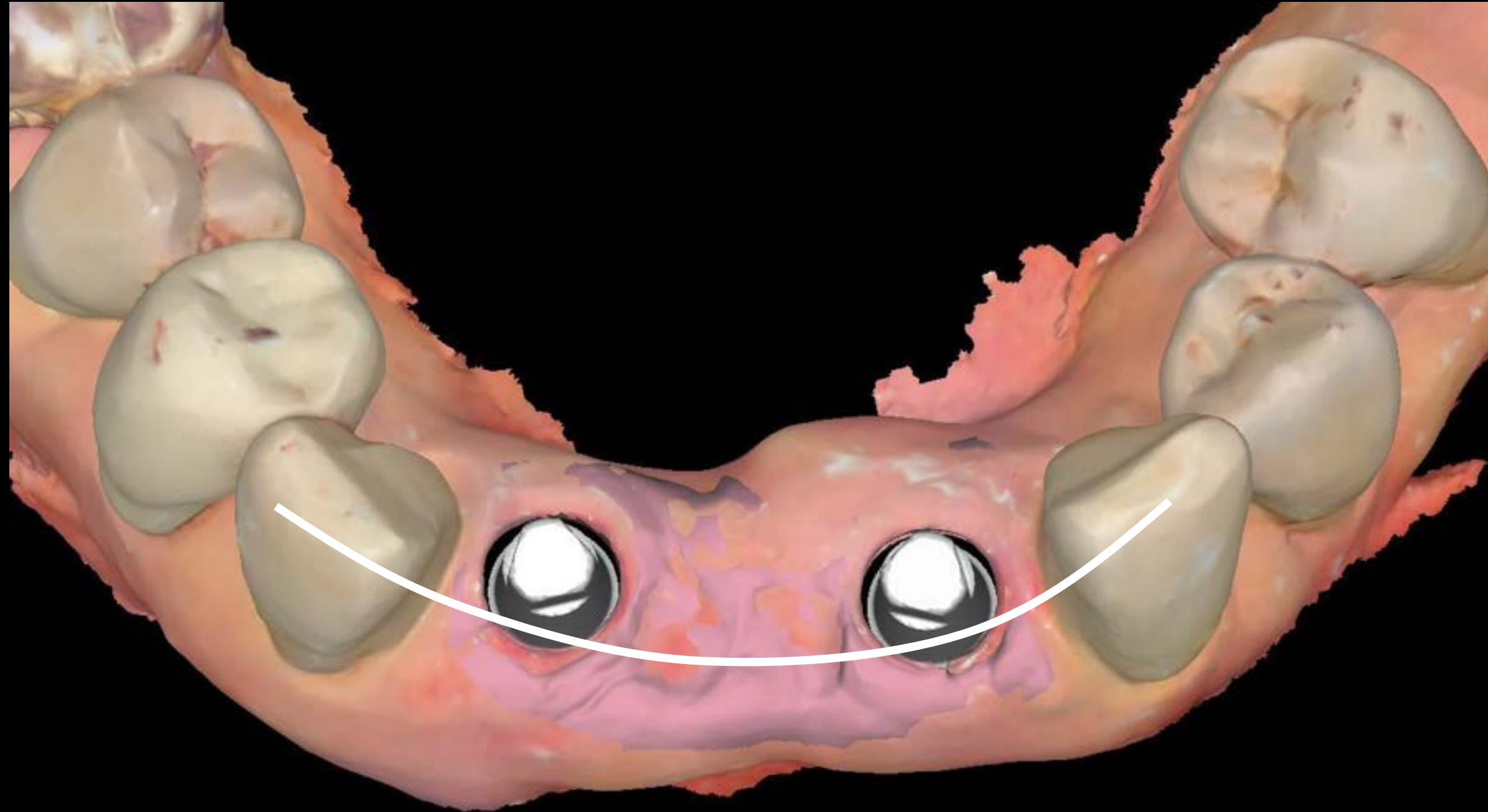


Cad Design

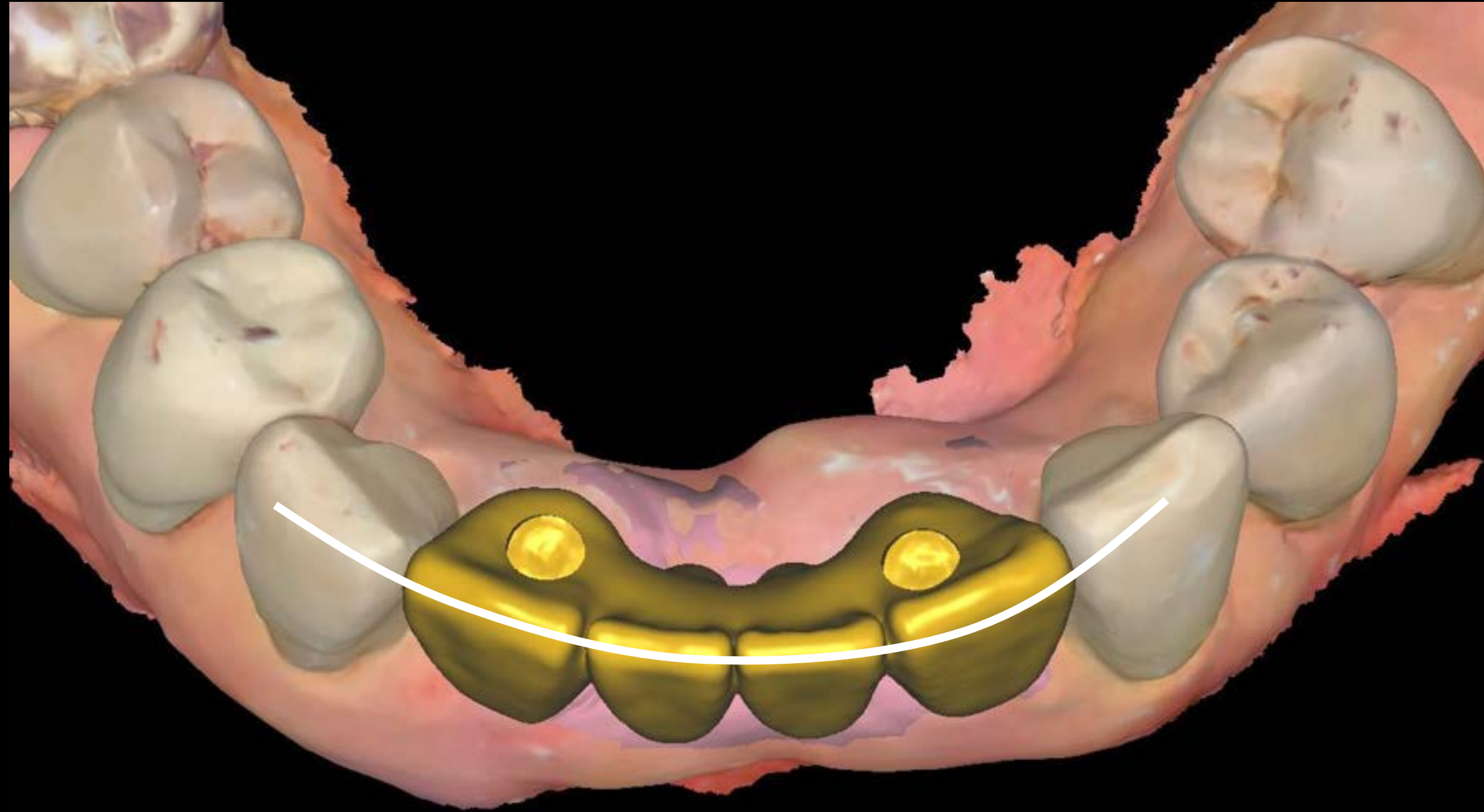


- Stock abutment crown emergency profile design -

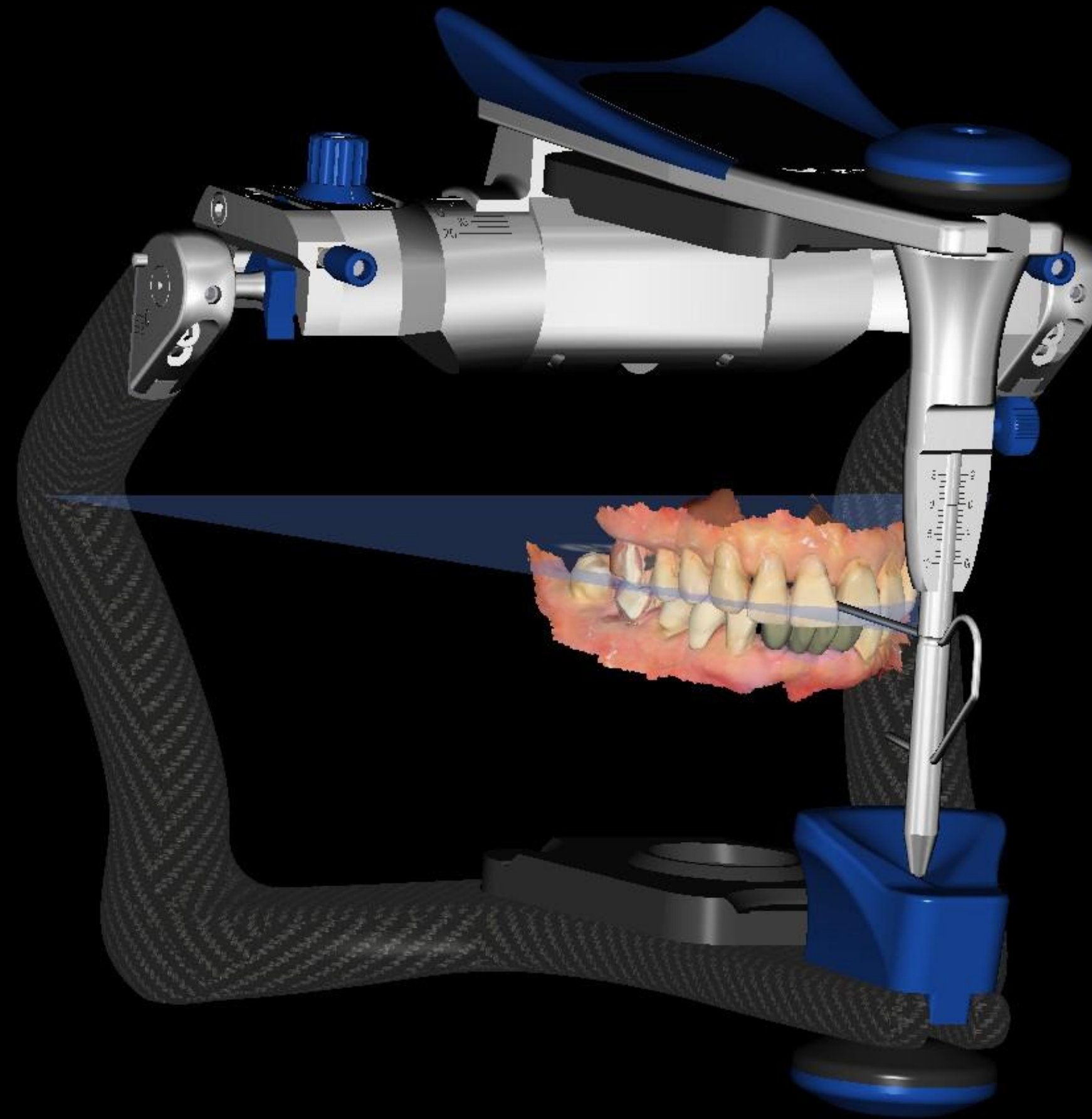Cad Design



Cad Design

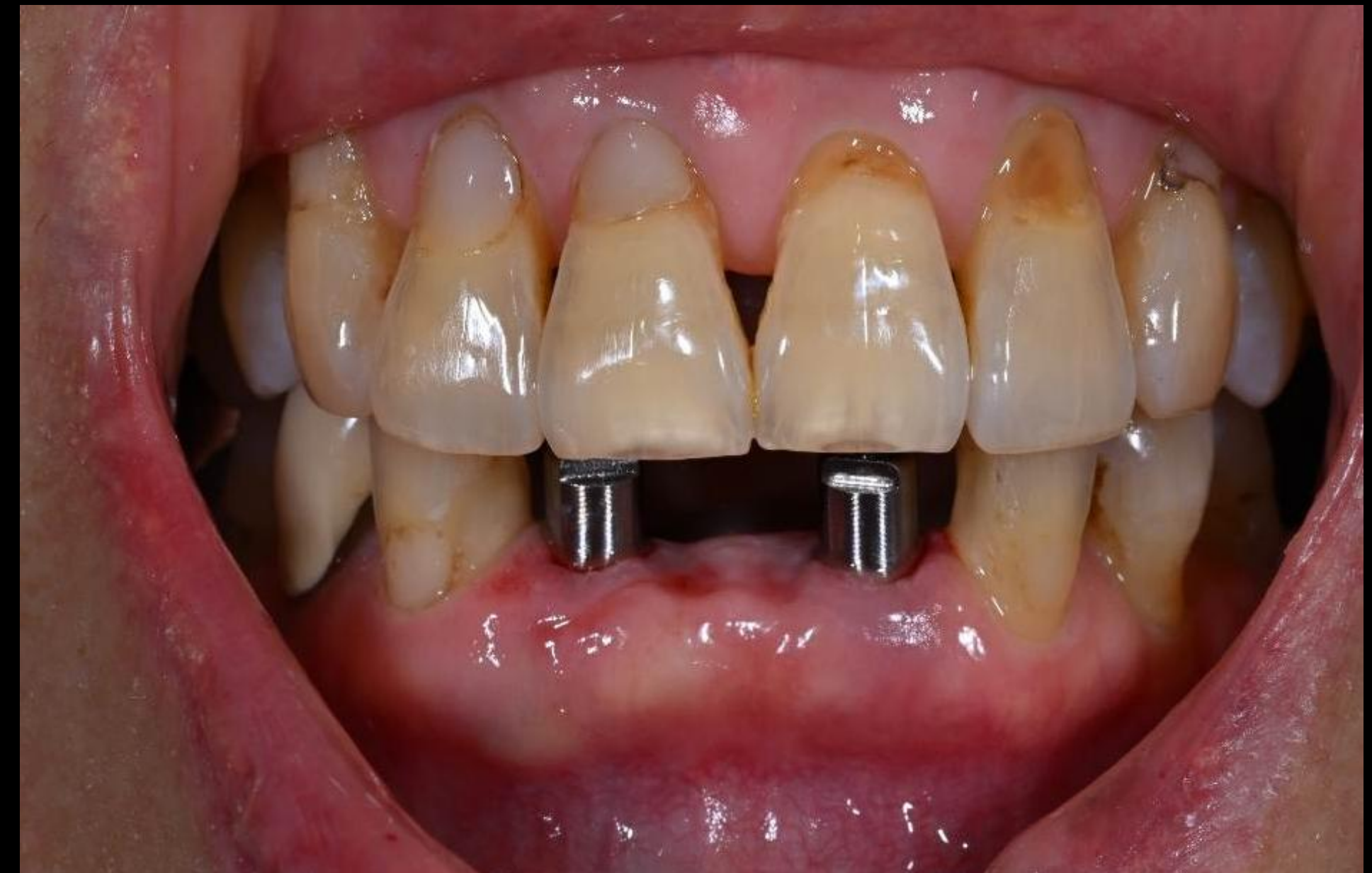
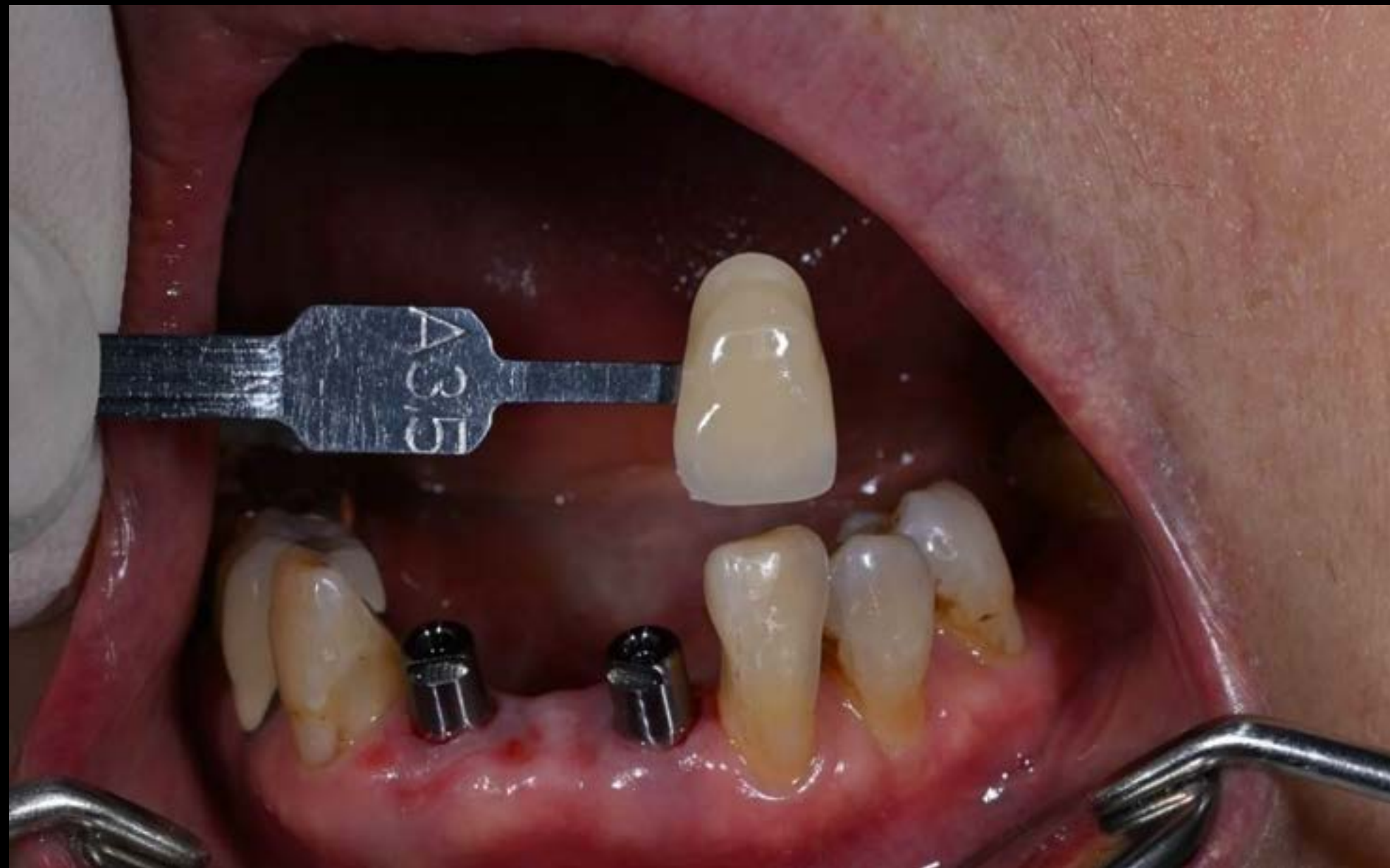
Virtual Articulator

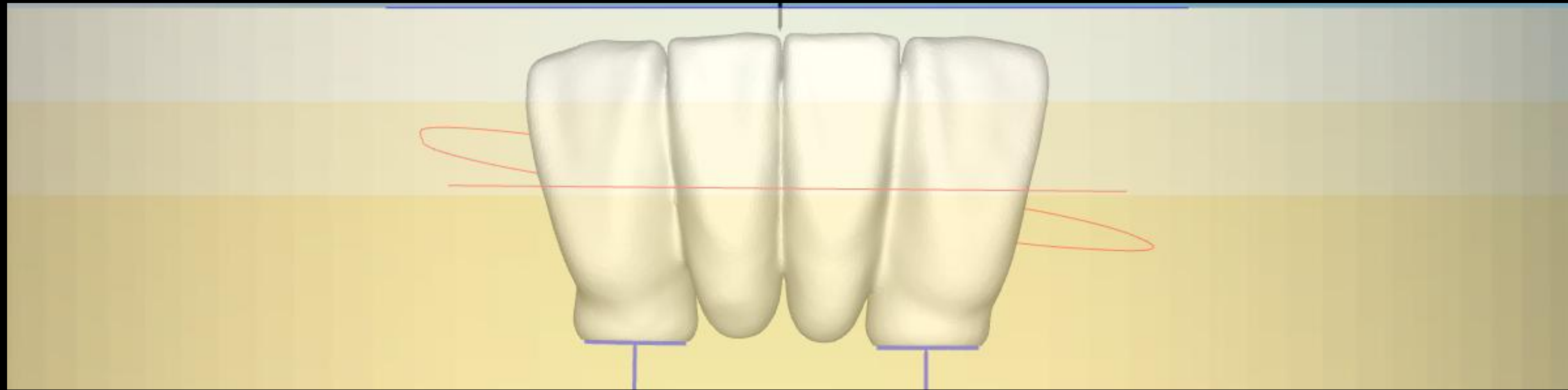


Modelless

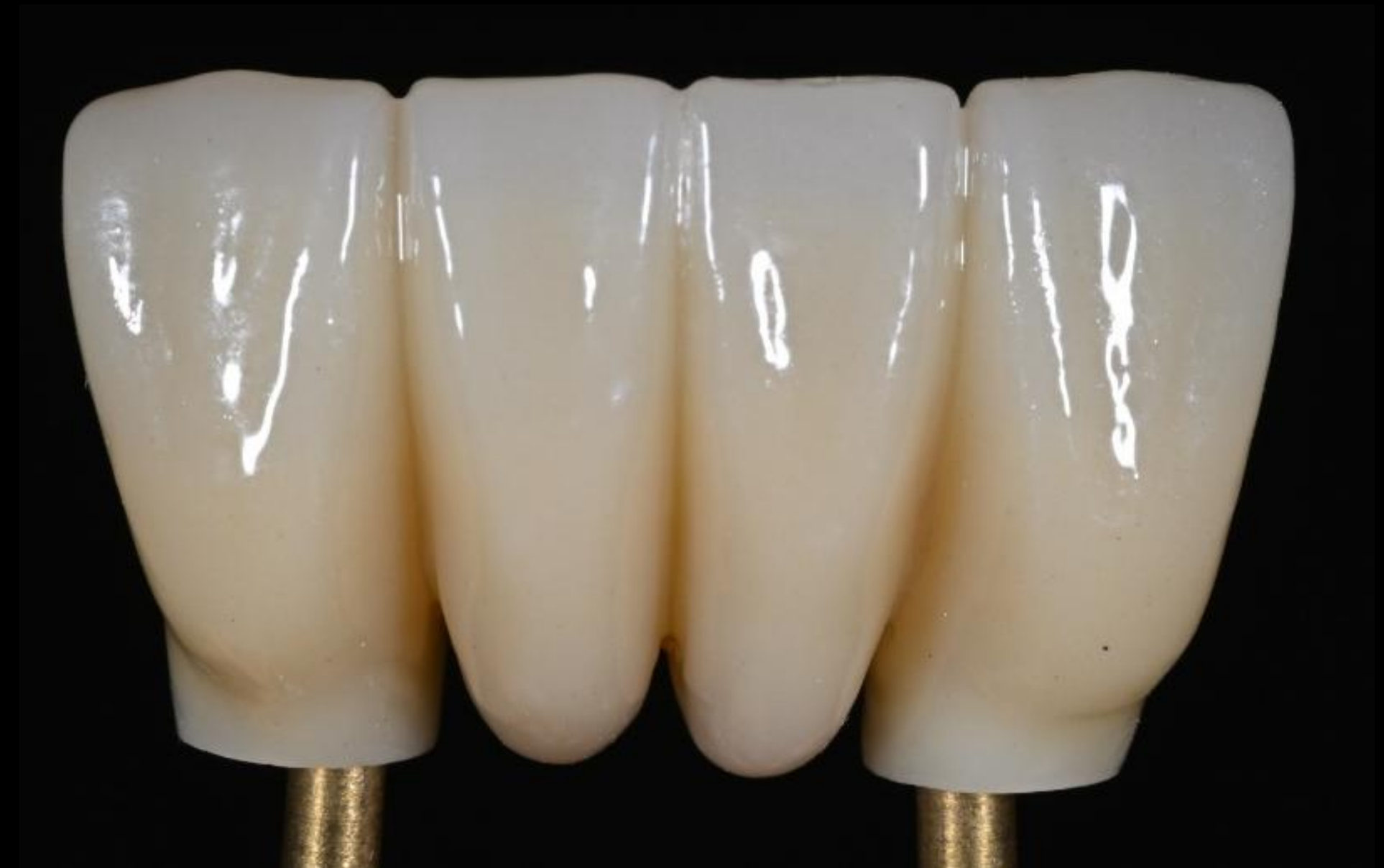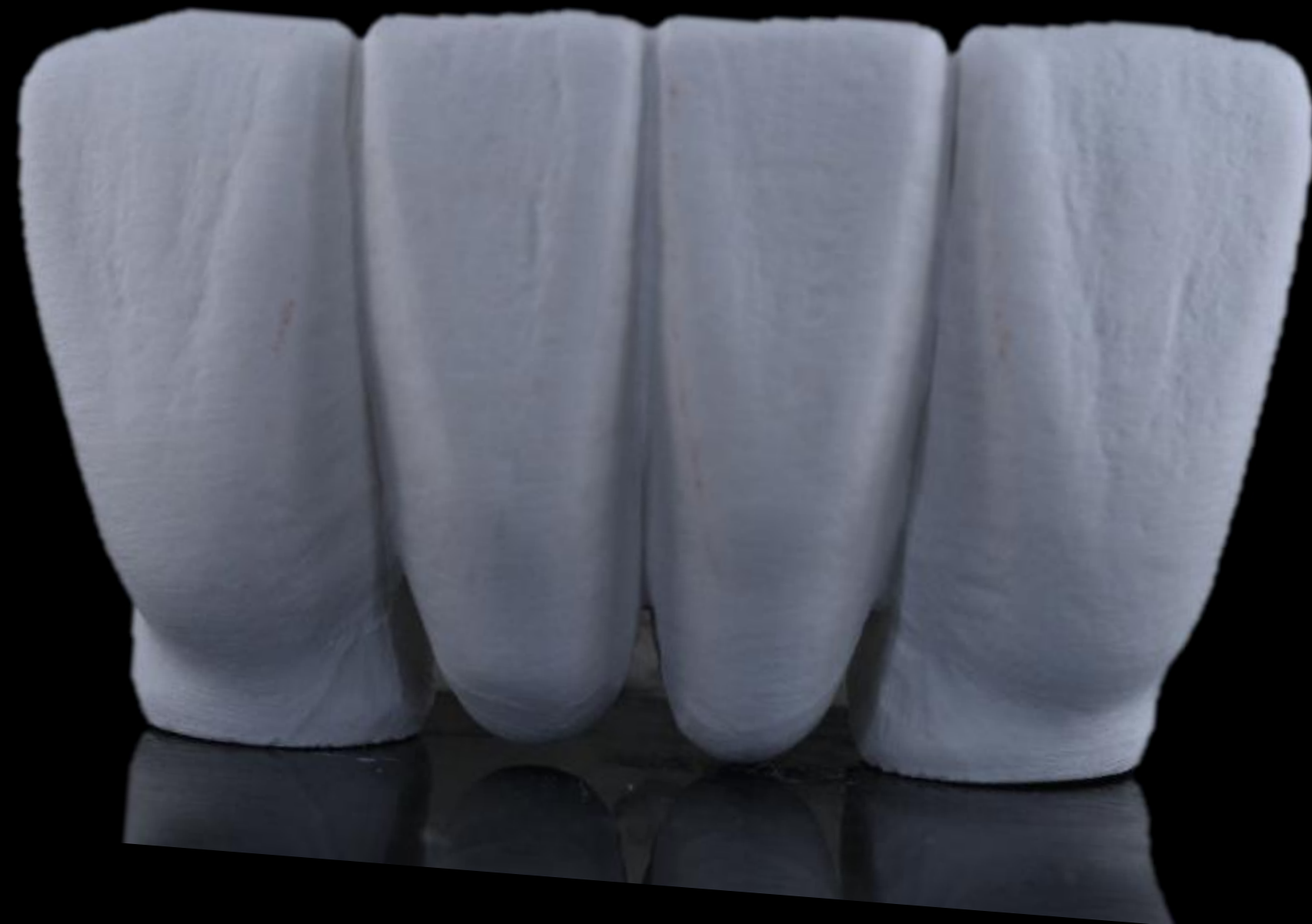Shade Taking



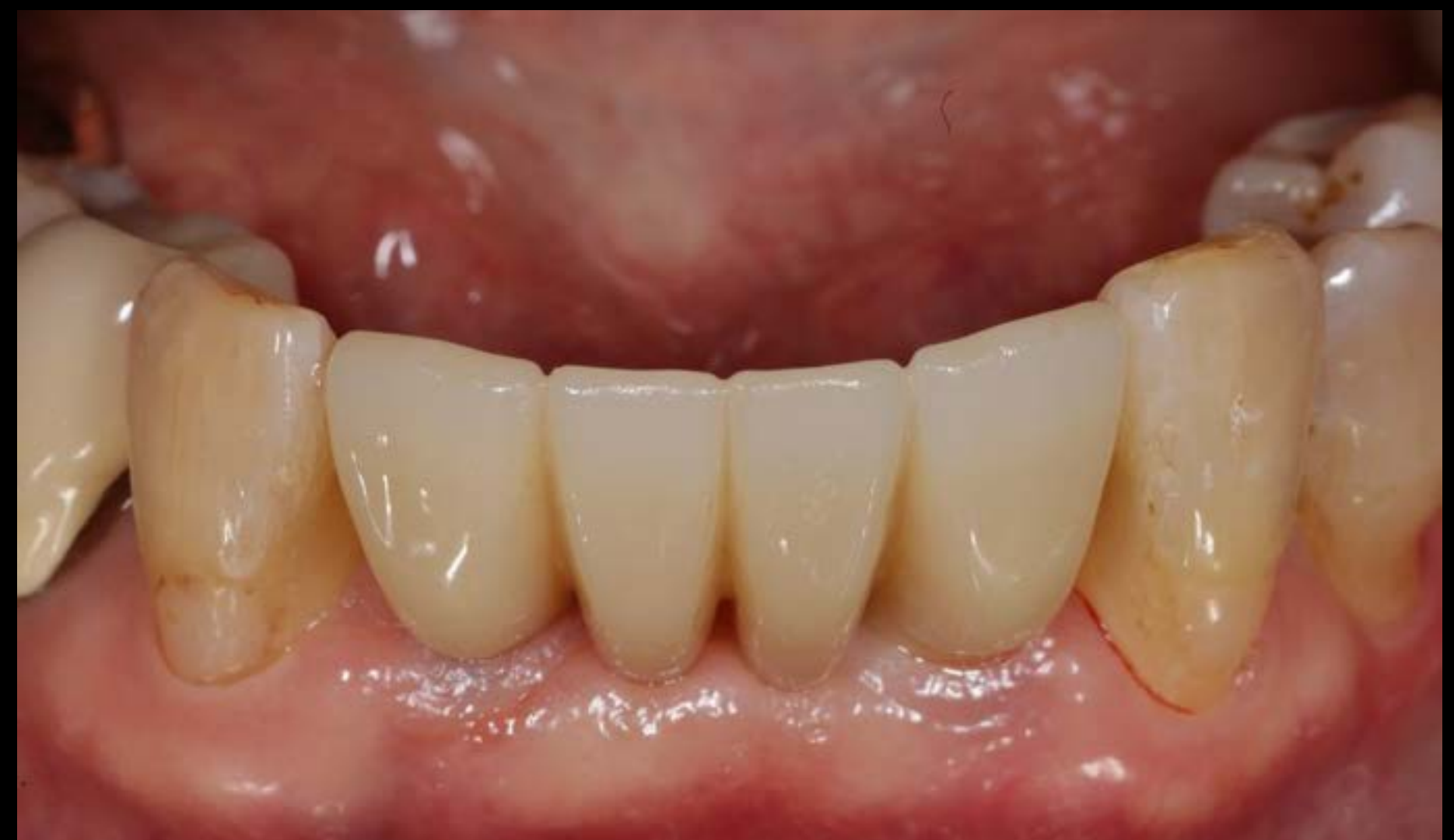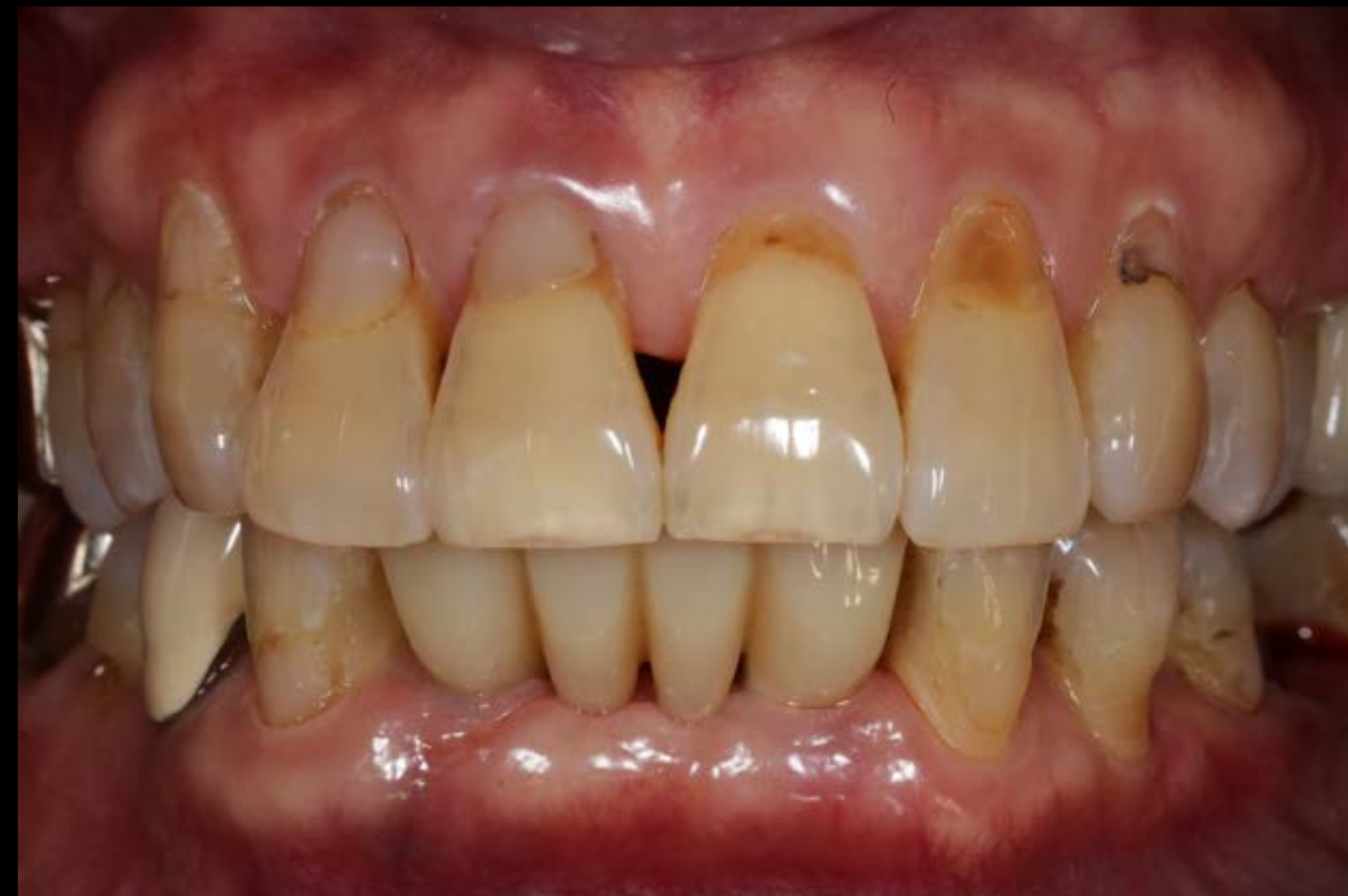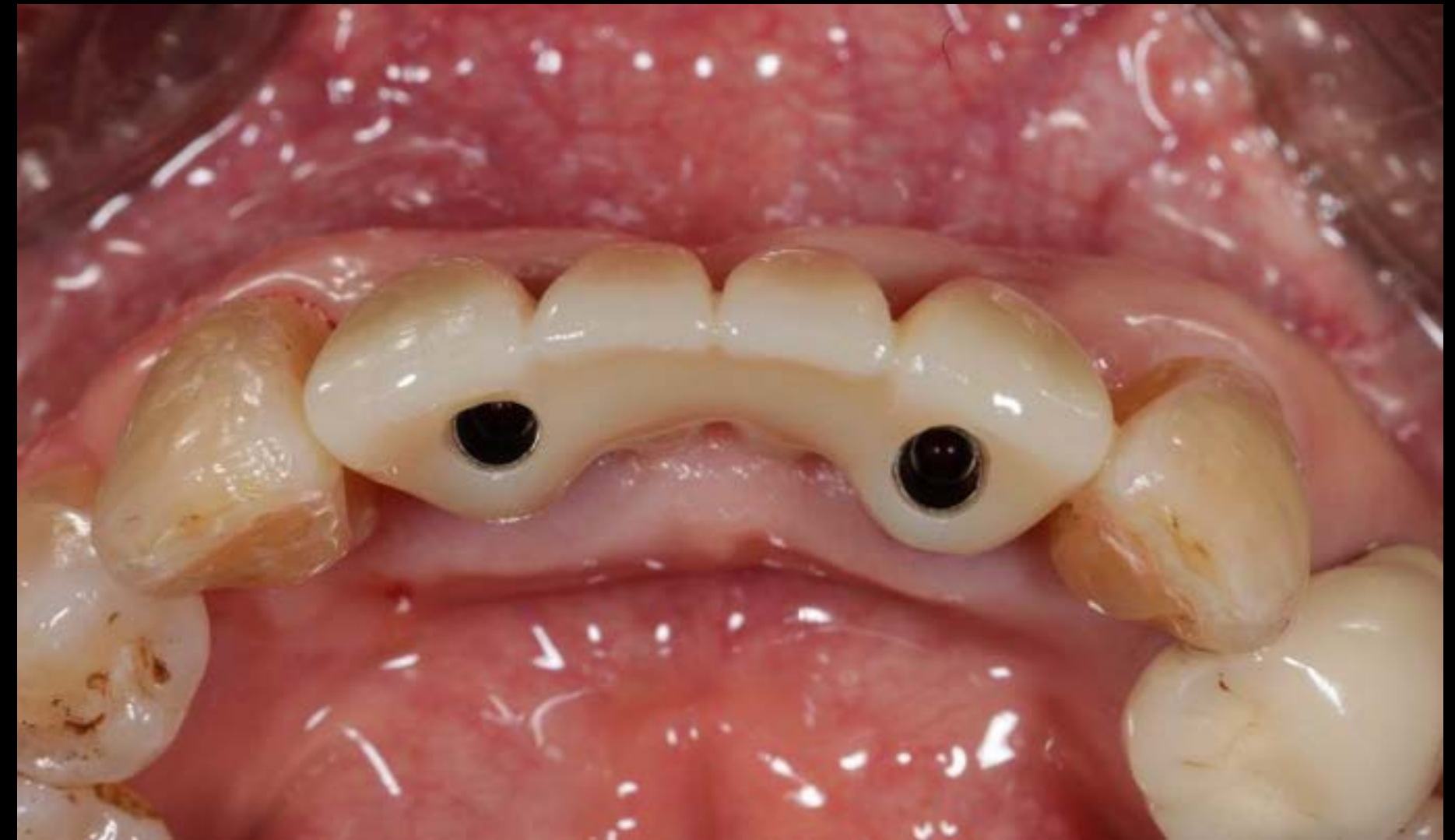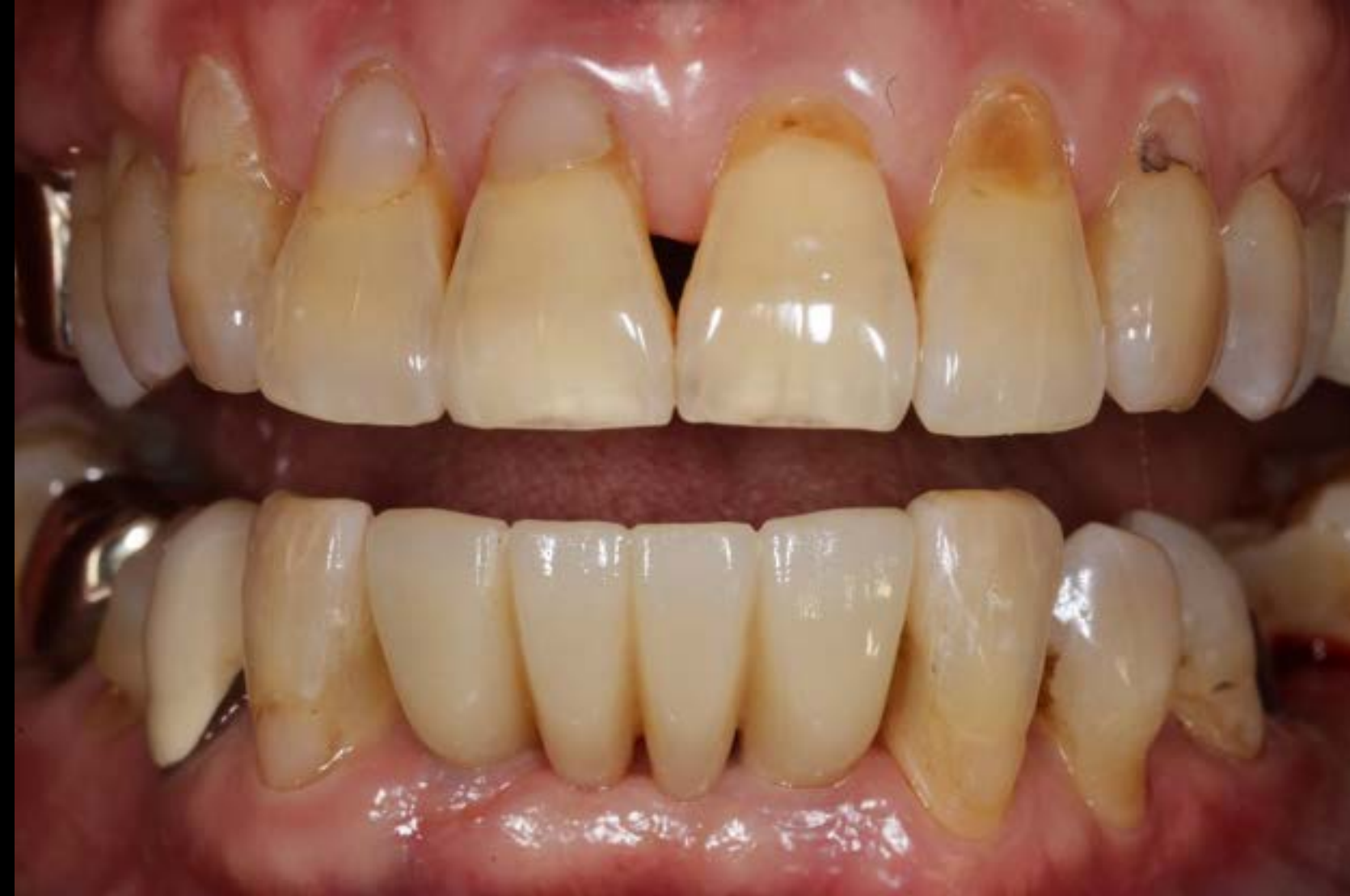Hyper Dent



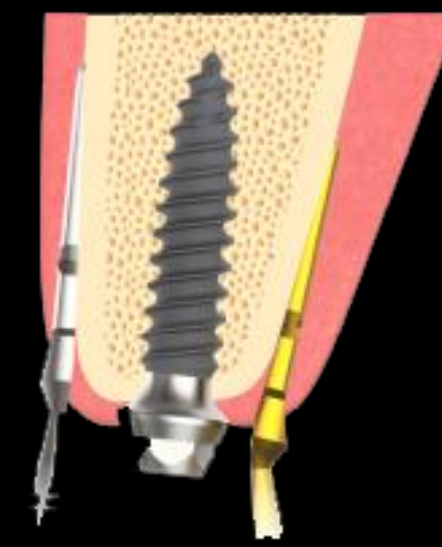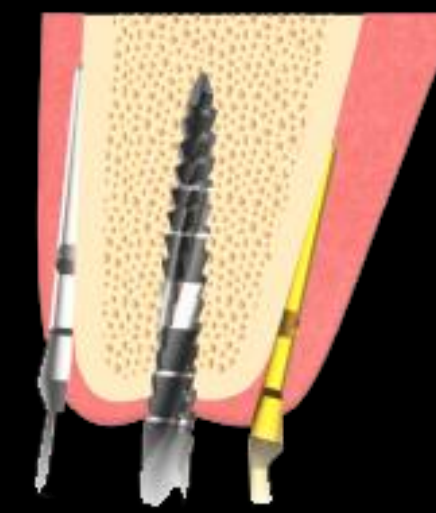
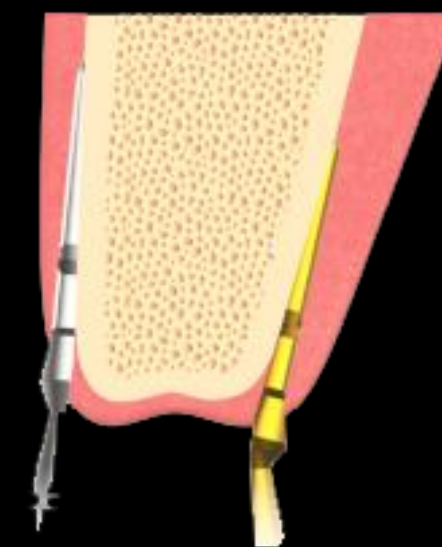
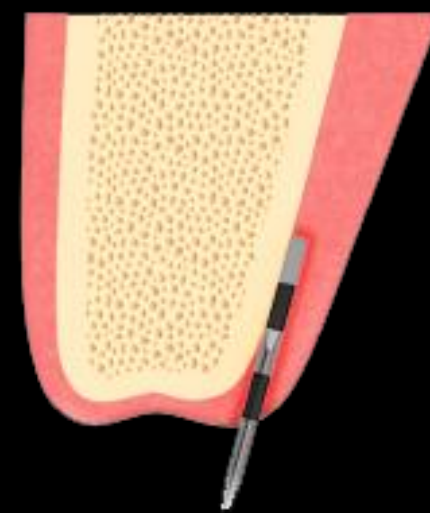3 layer block A3.5



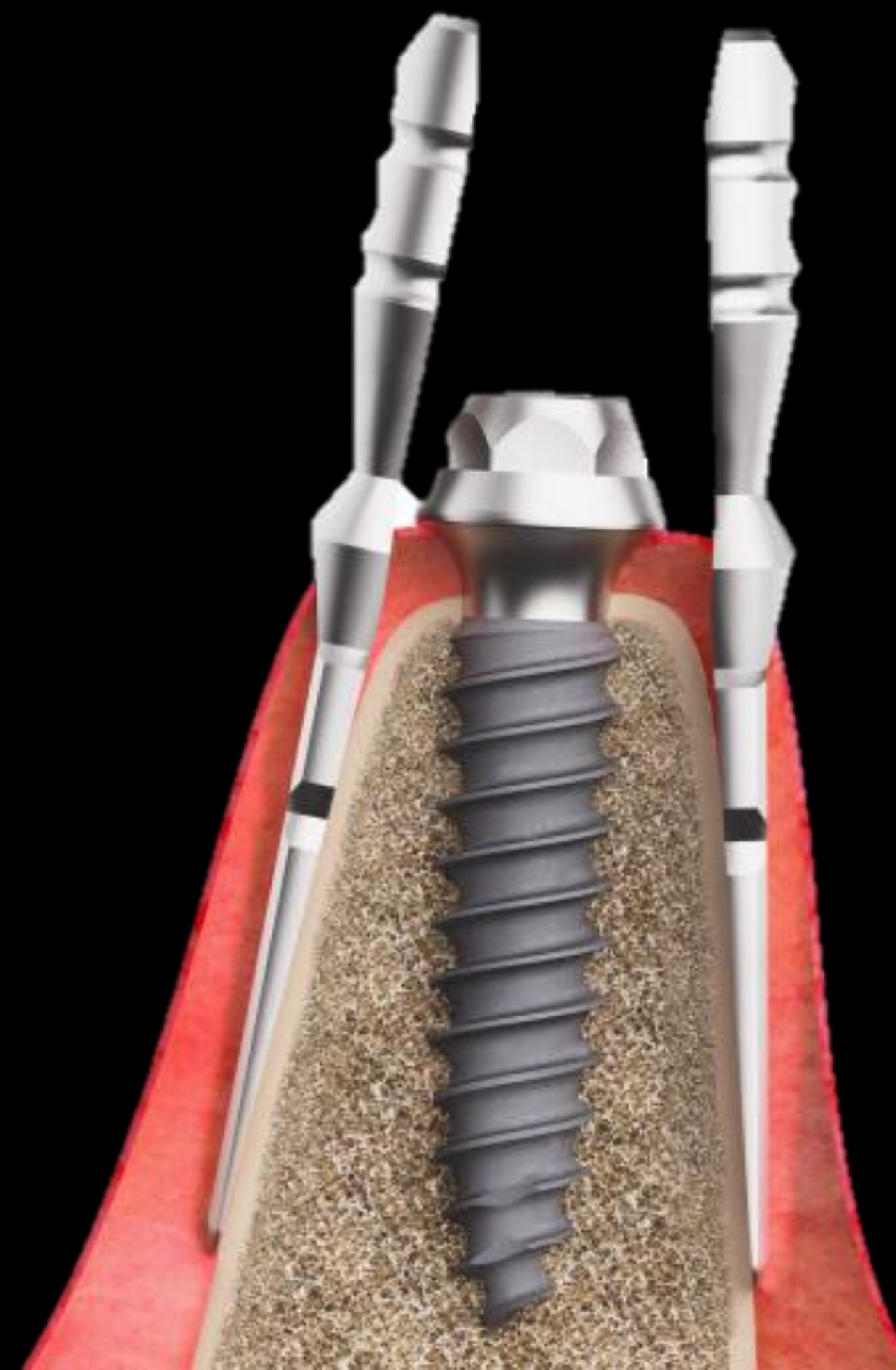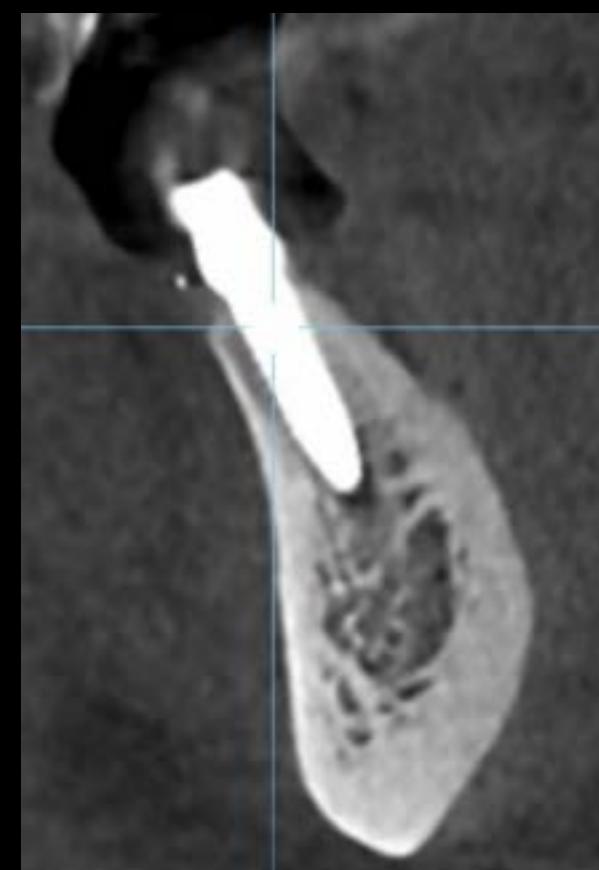
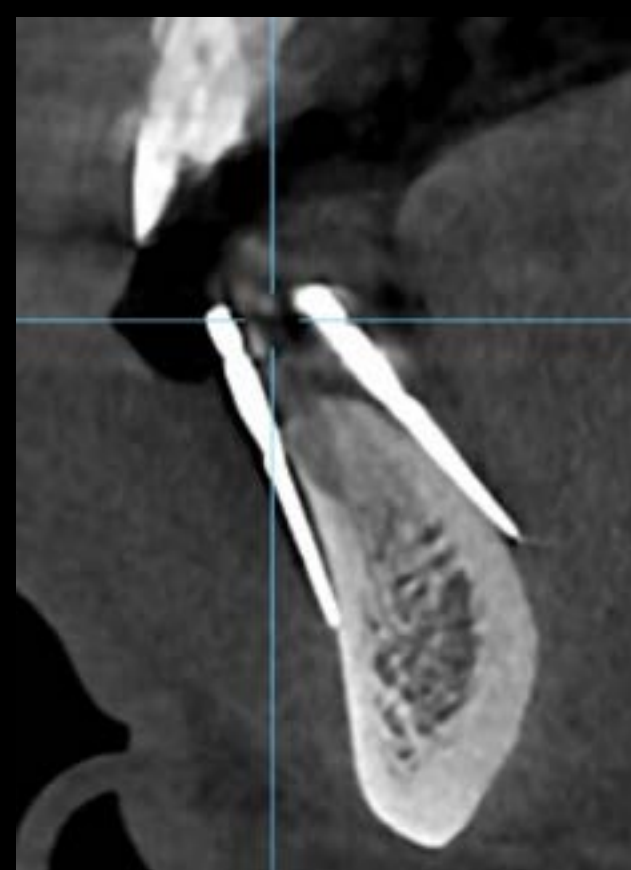
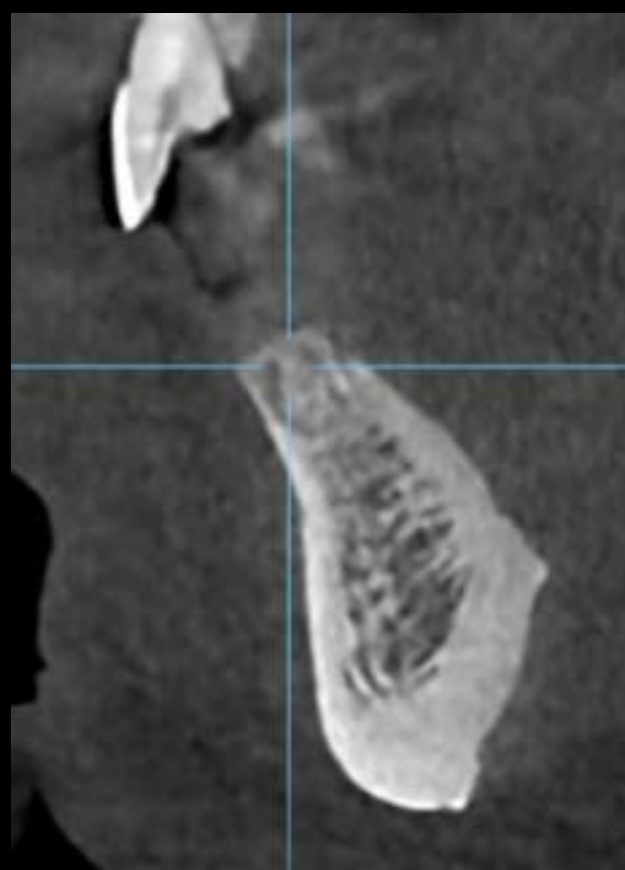
Final Prosthesis



Pin Guide

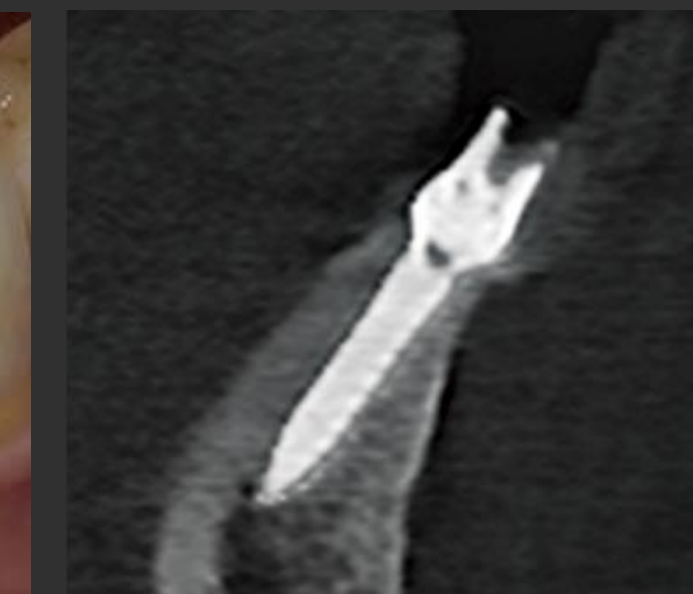
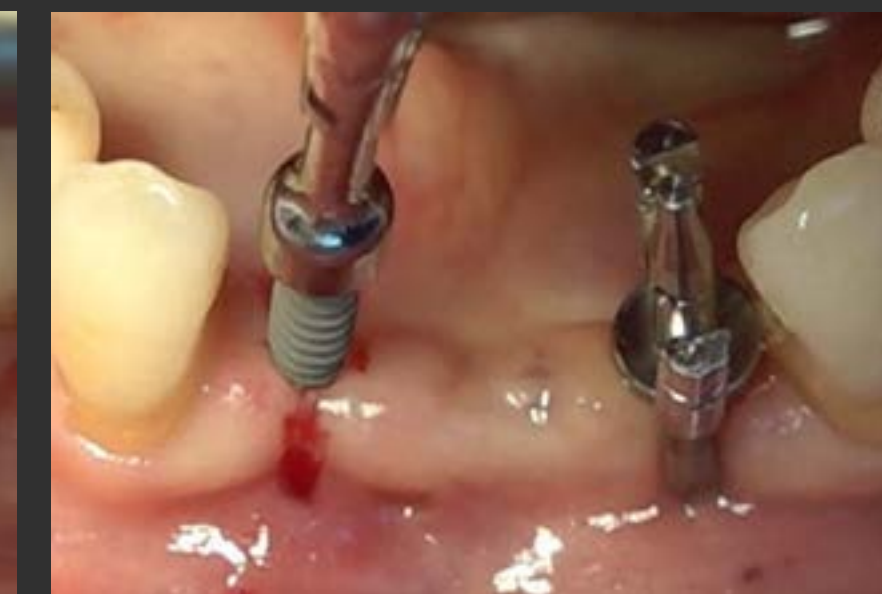
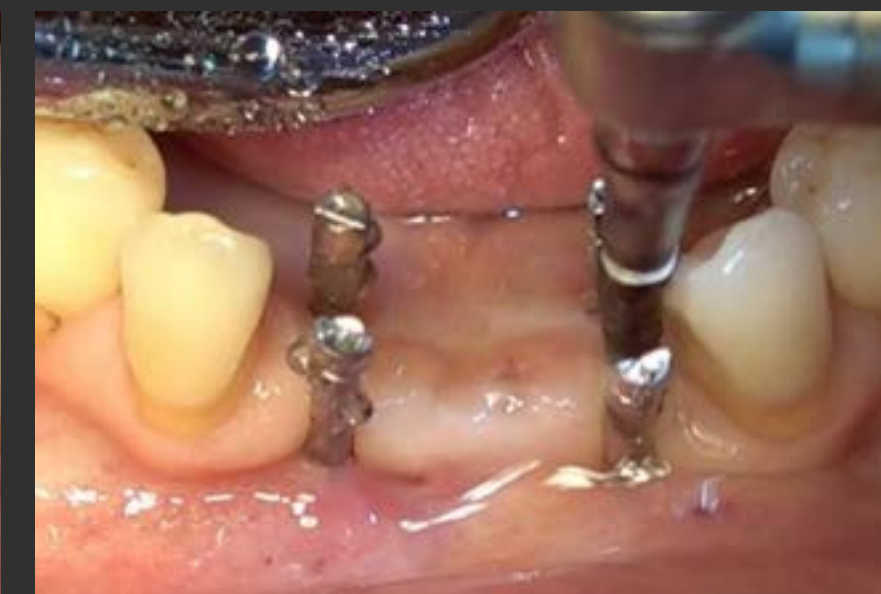
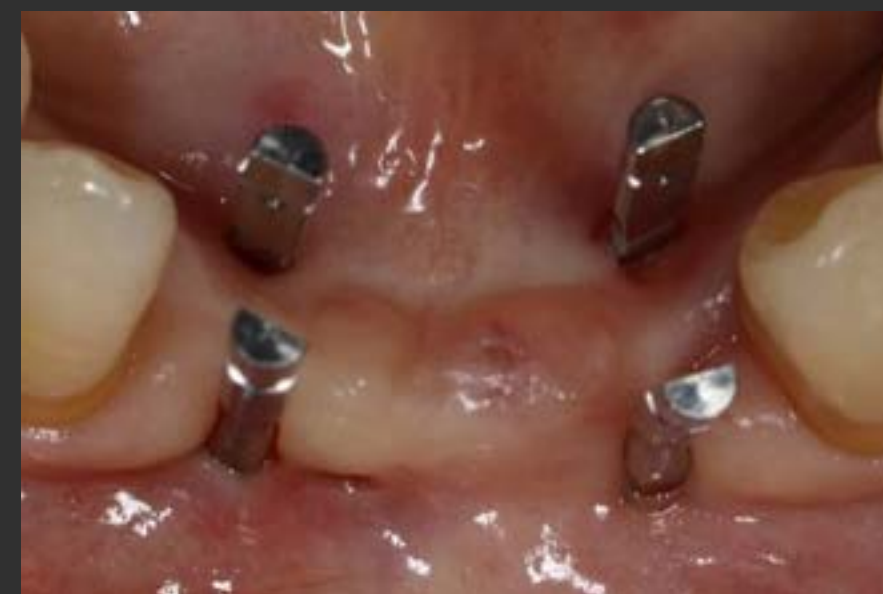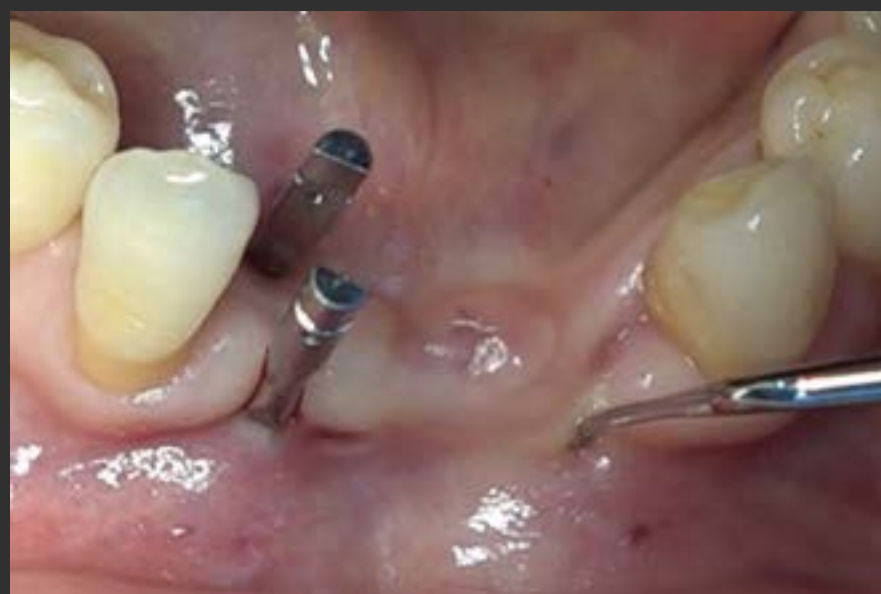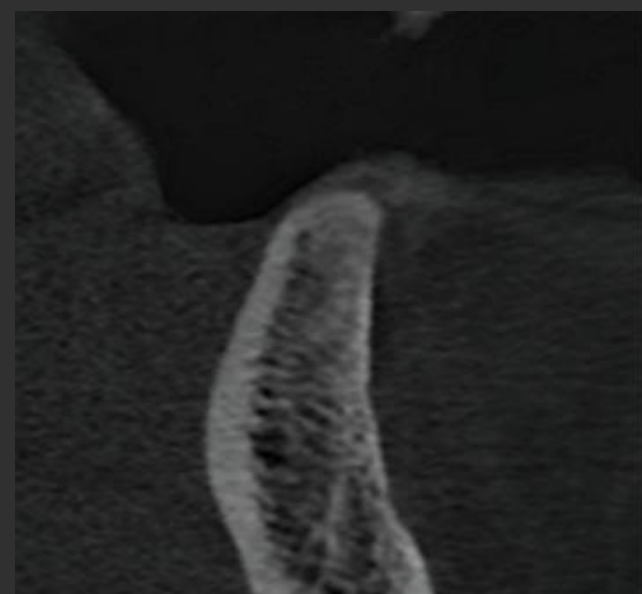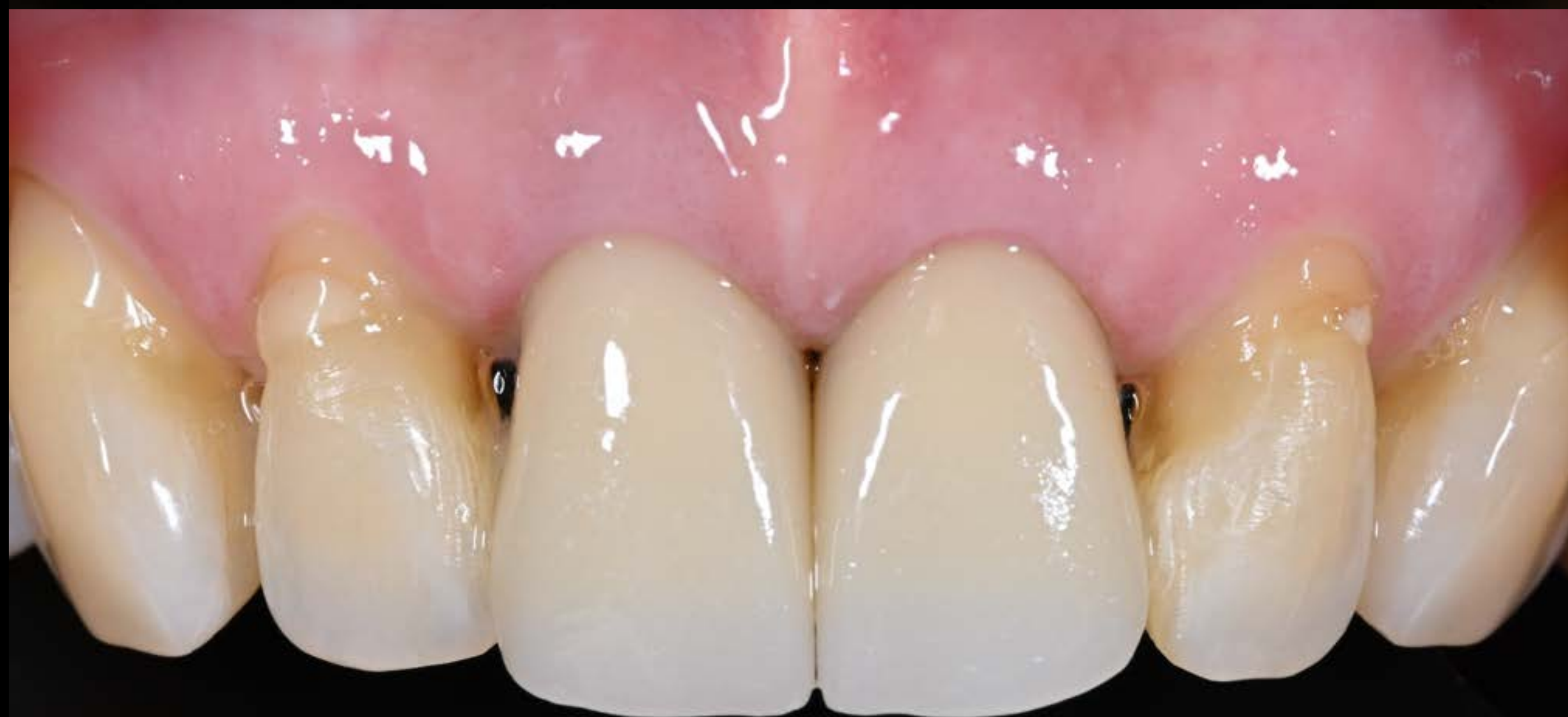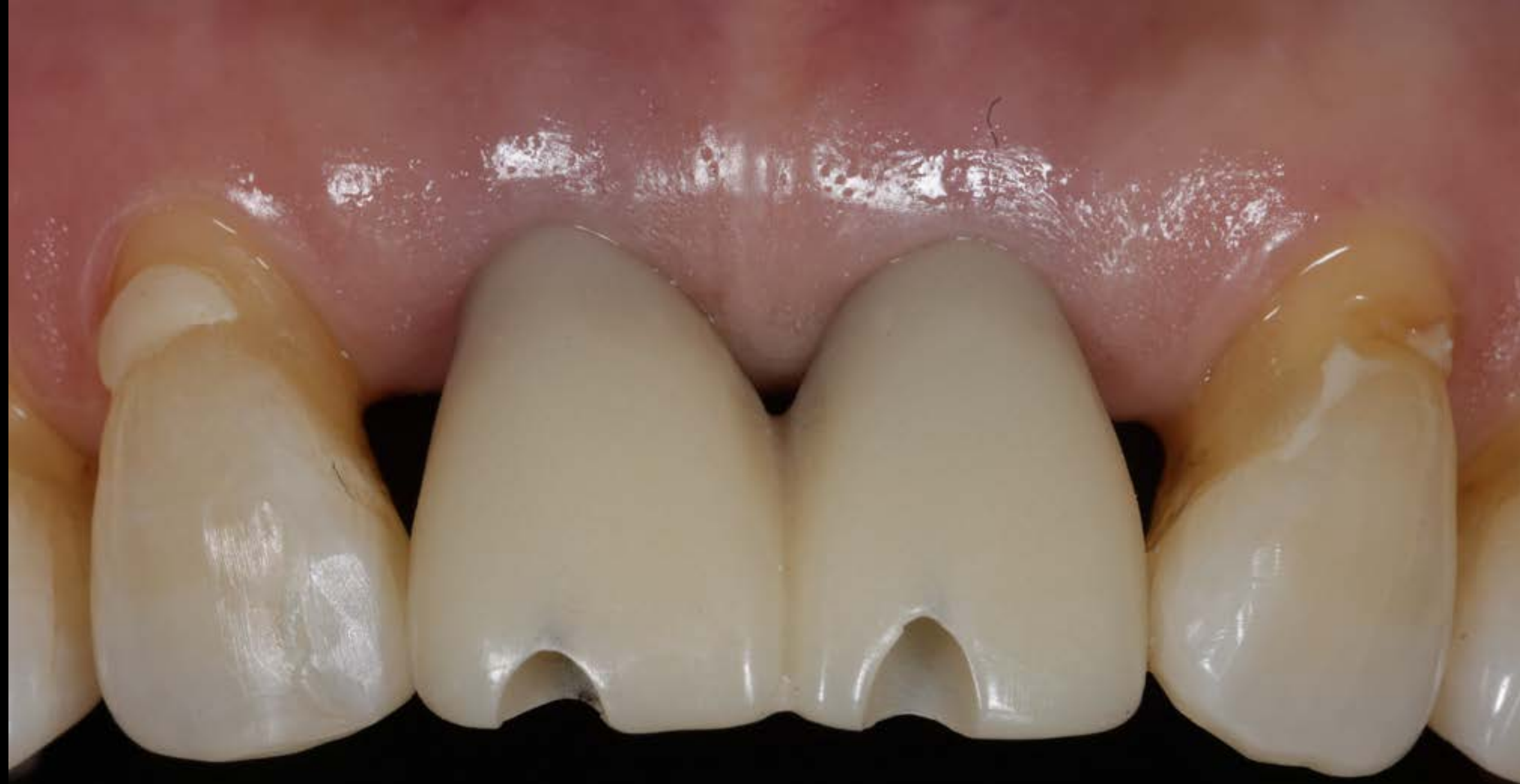- ✓ Mapping alveolar bone
- ✓ Optimized for flapless surgery
- ✓ Excellent performance in narrow ridge case

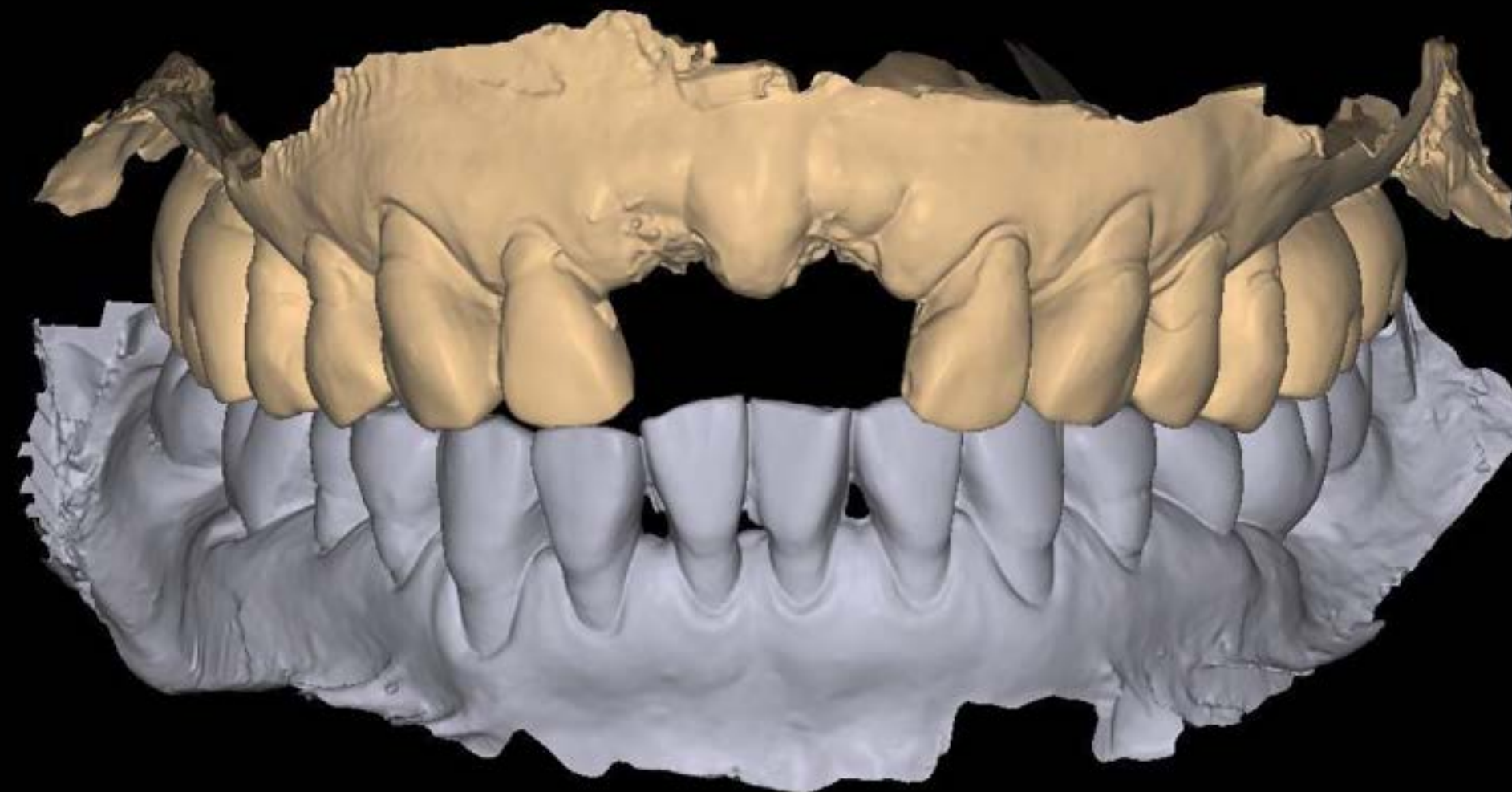
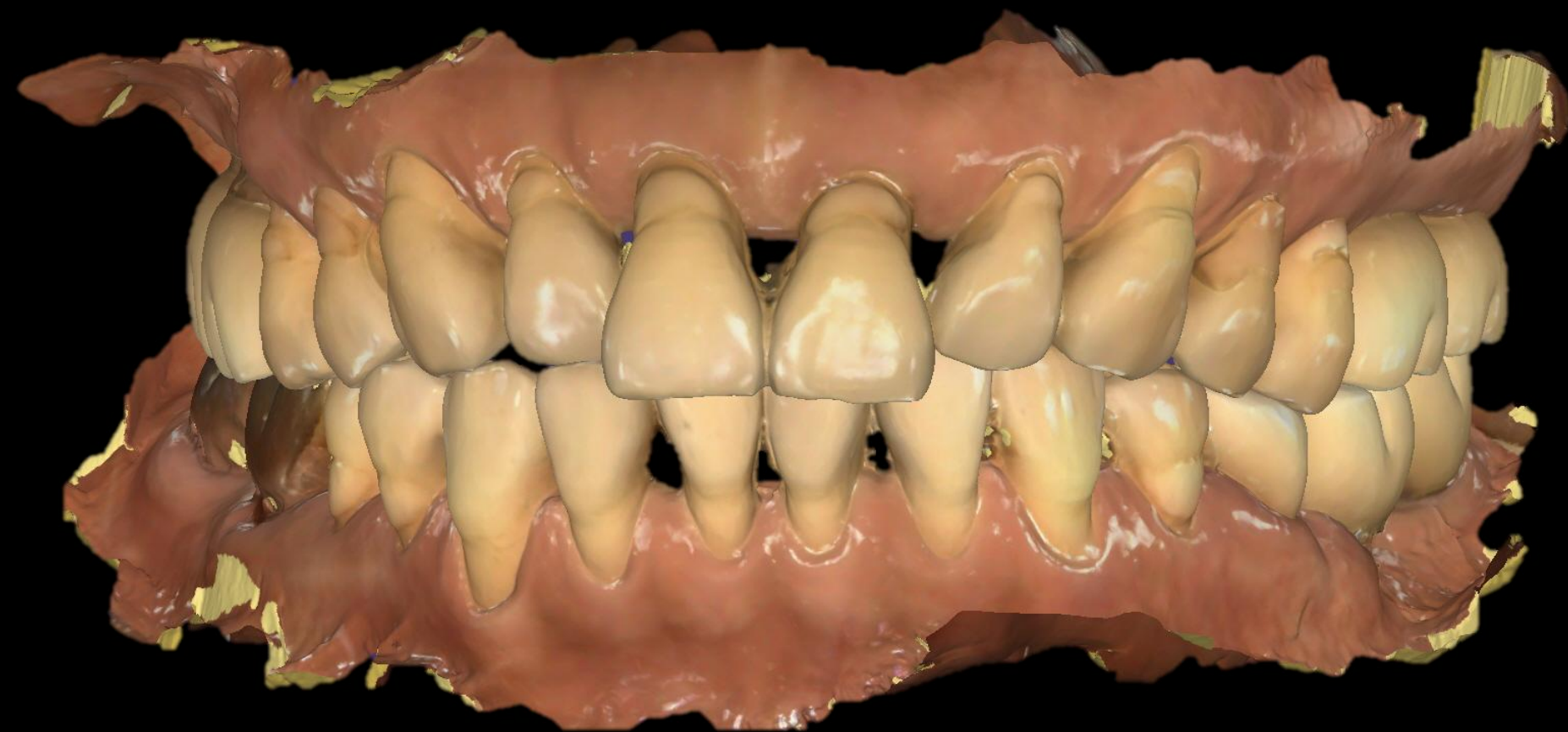

Pin Guide *Simple*

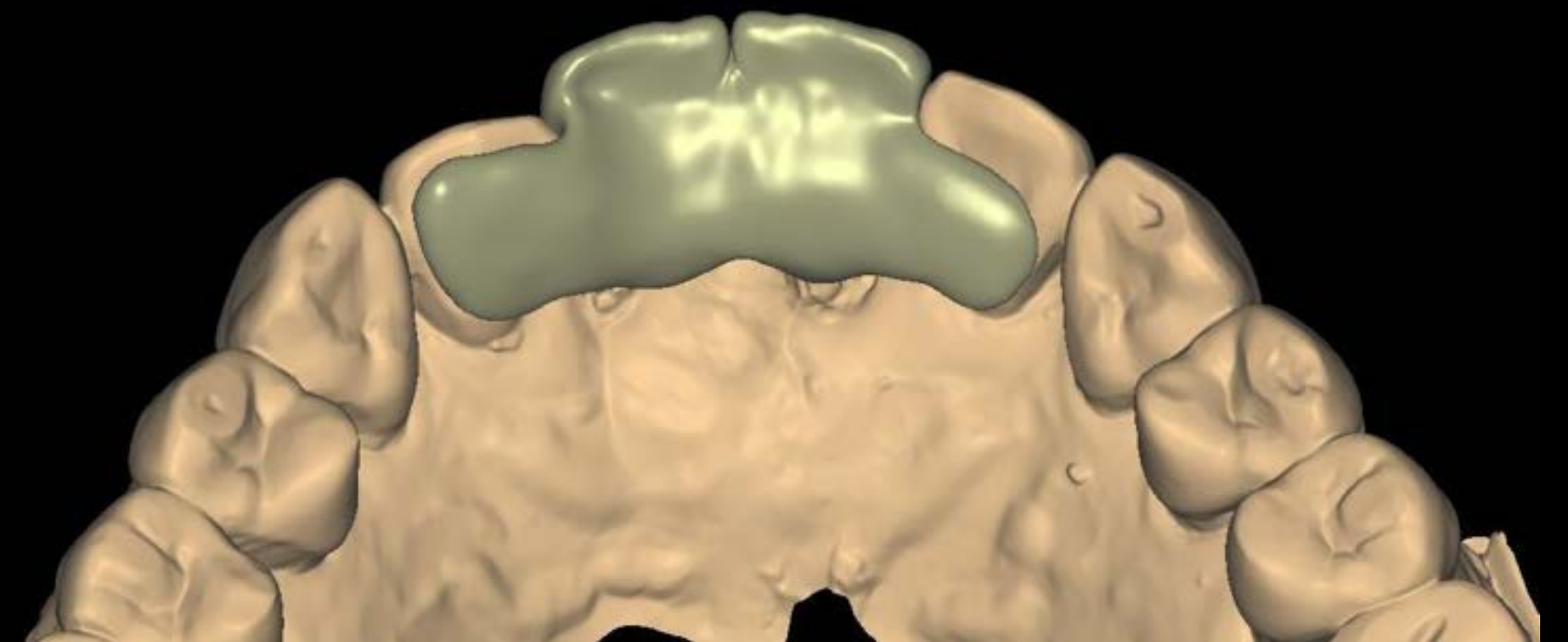
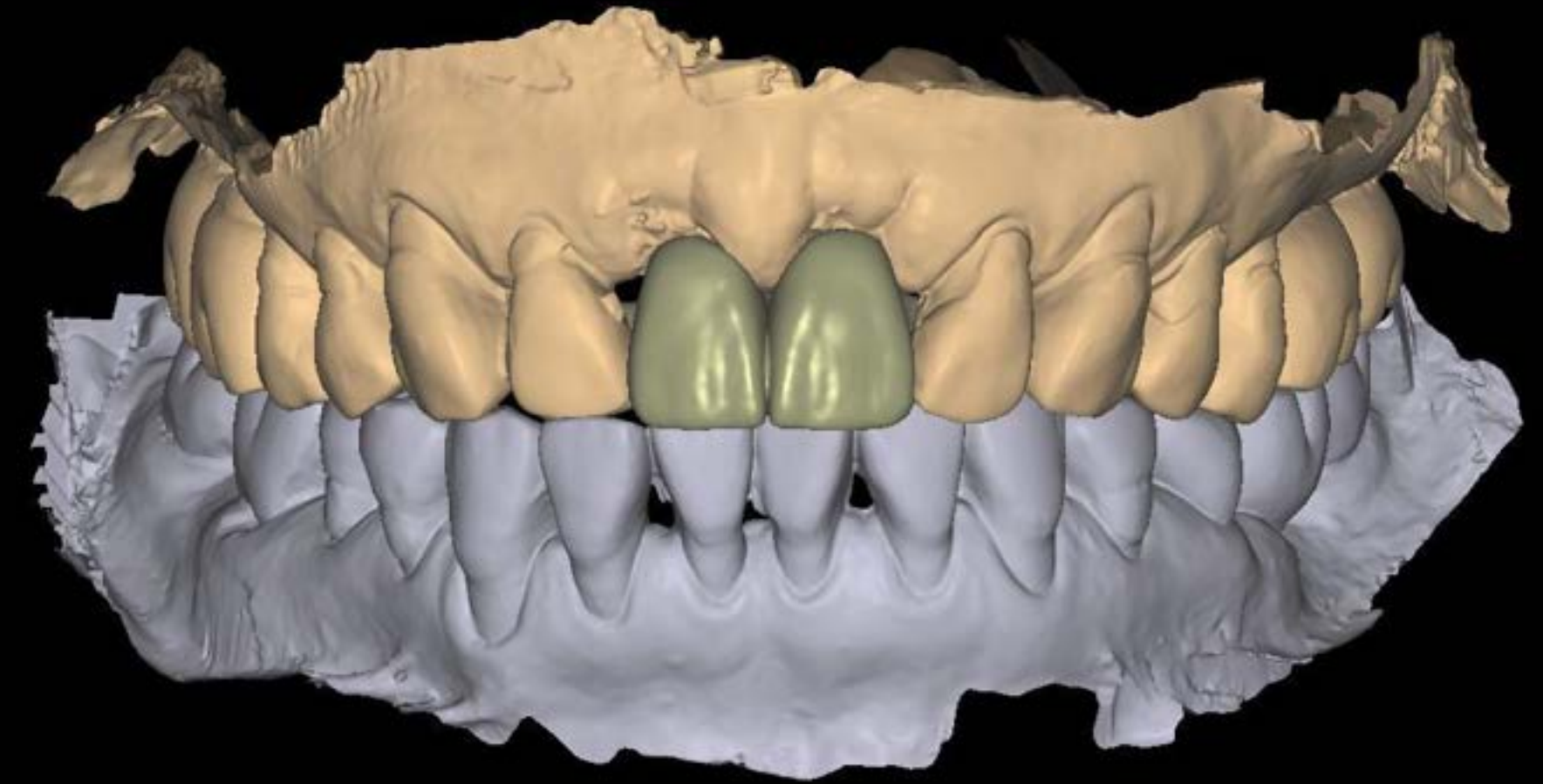
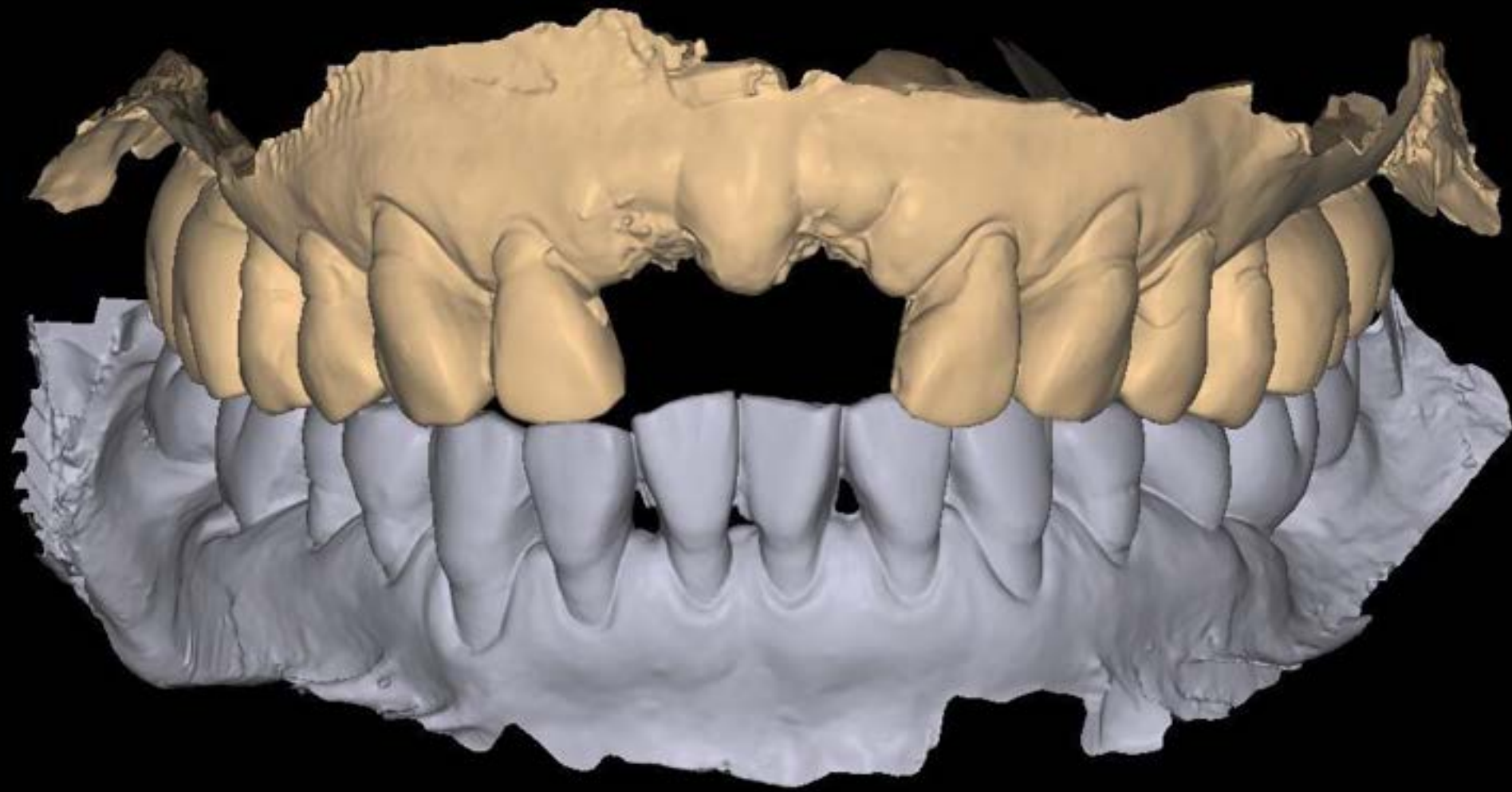
- Mapping the alveolar bone.
- Optimized for flapless surgery.
- Excellent performance in narrow ridge case.



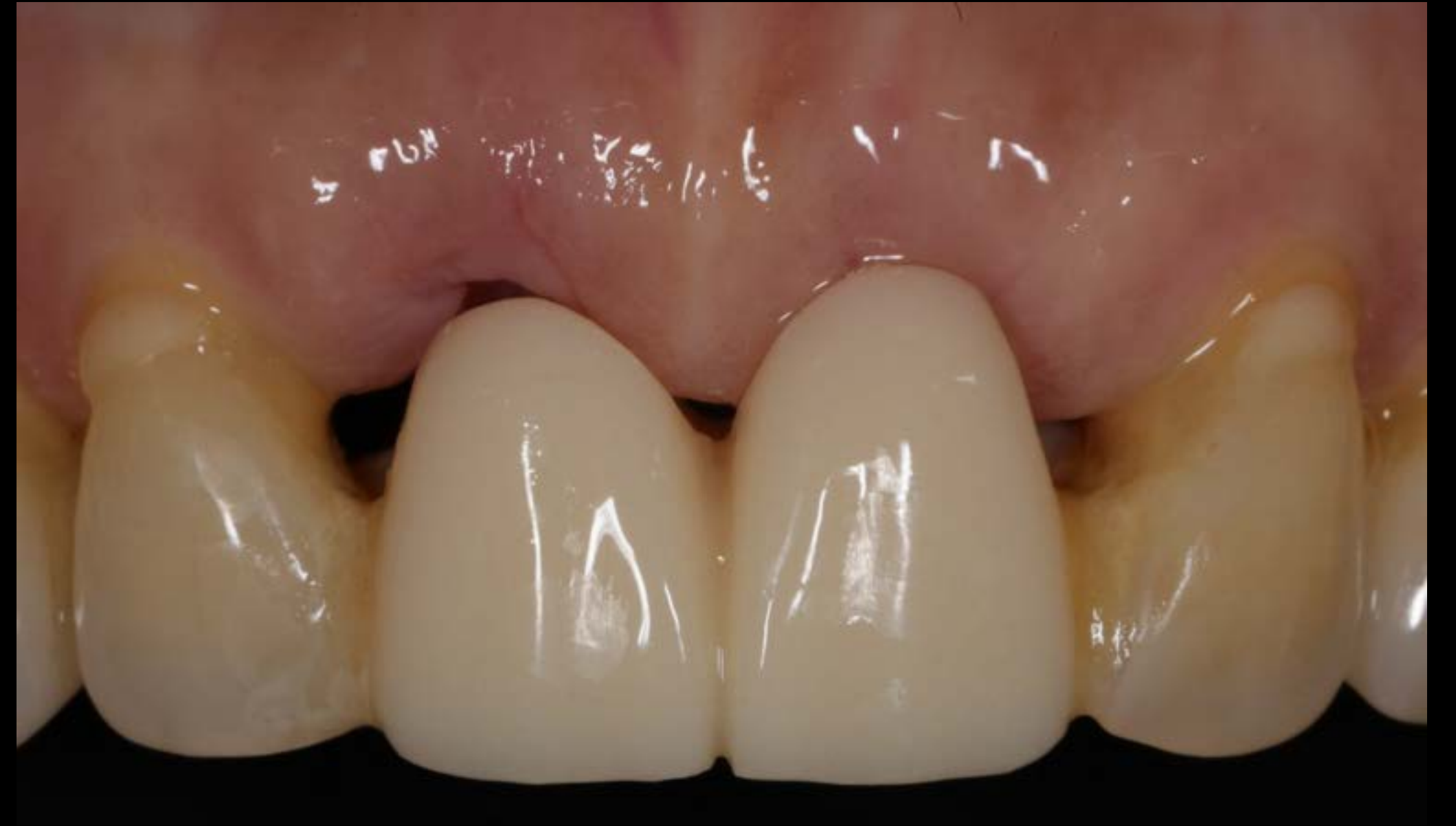
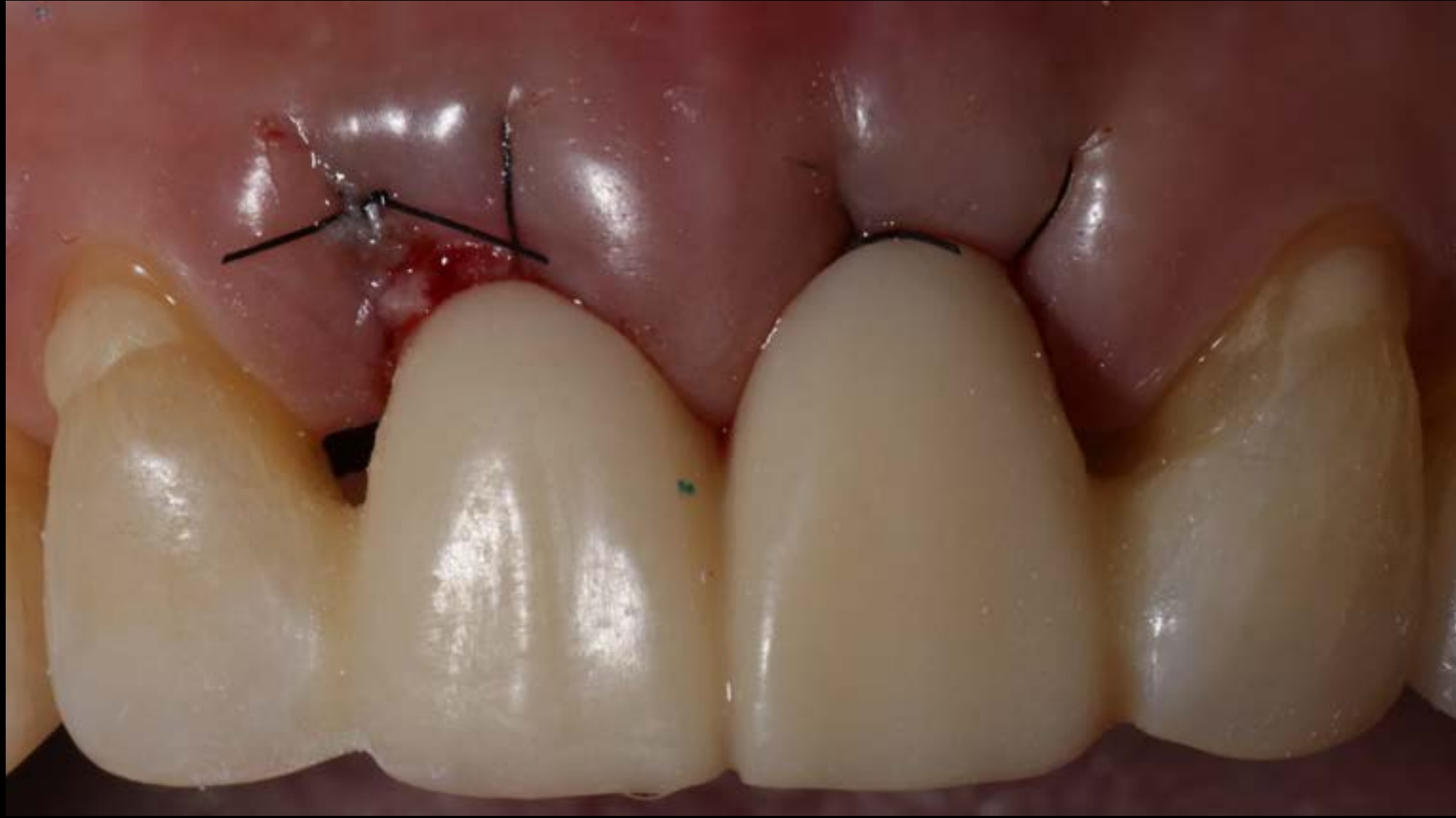


Bone Graft after Extraction

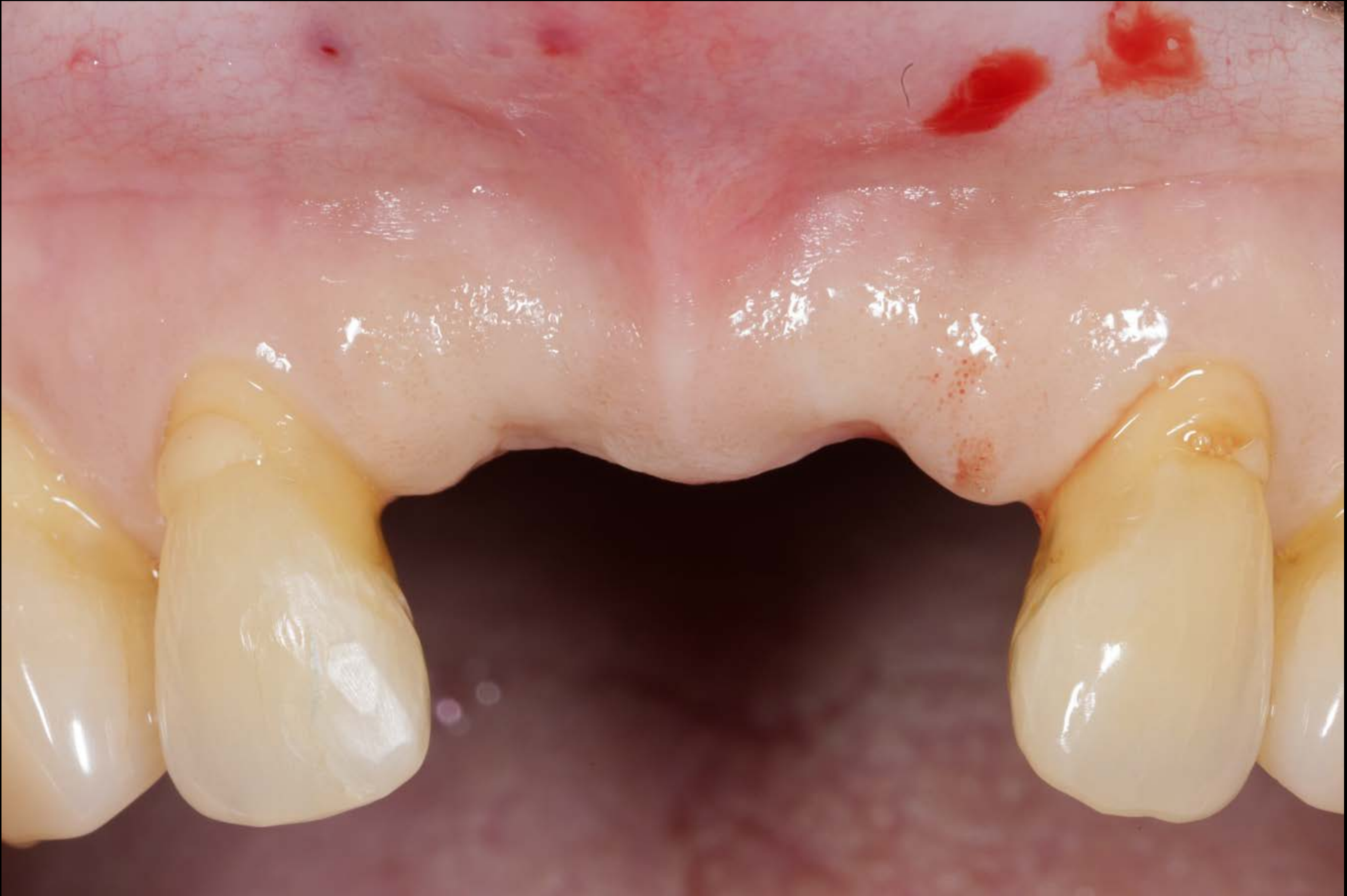

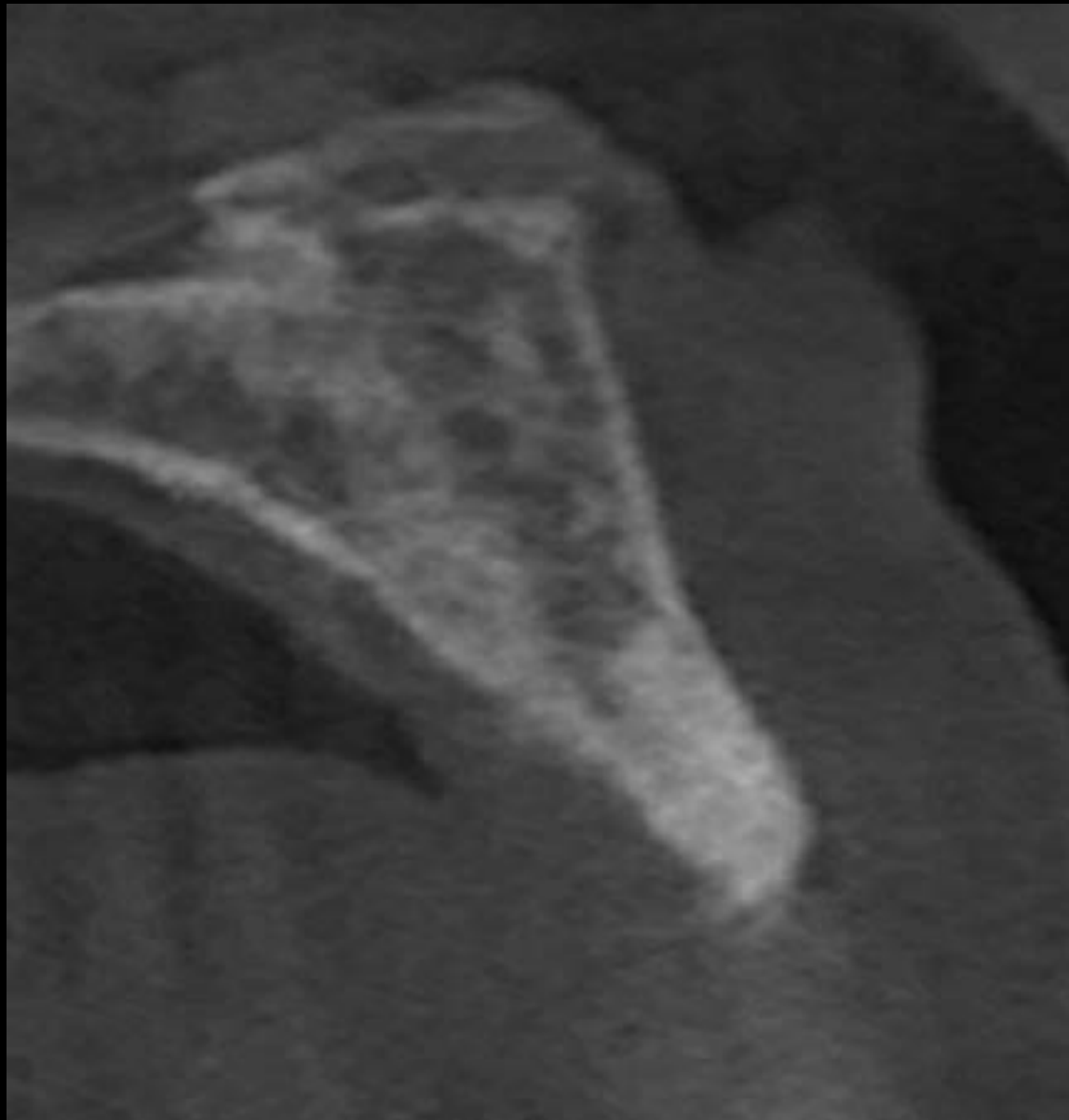For esthetics, a Maryland bridge was made until I.S. placement



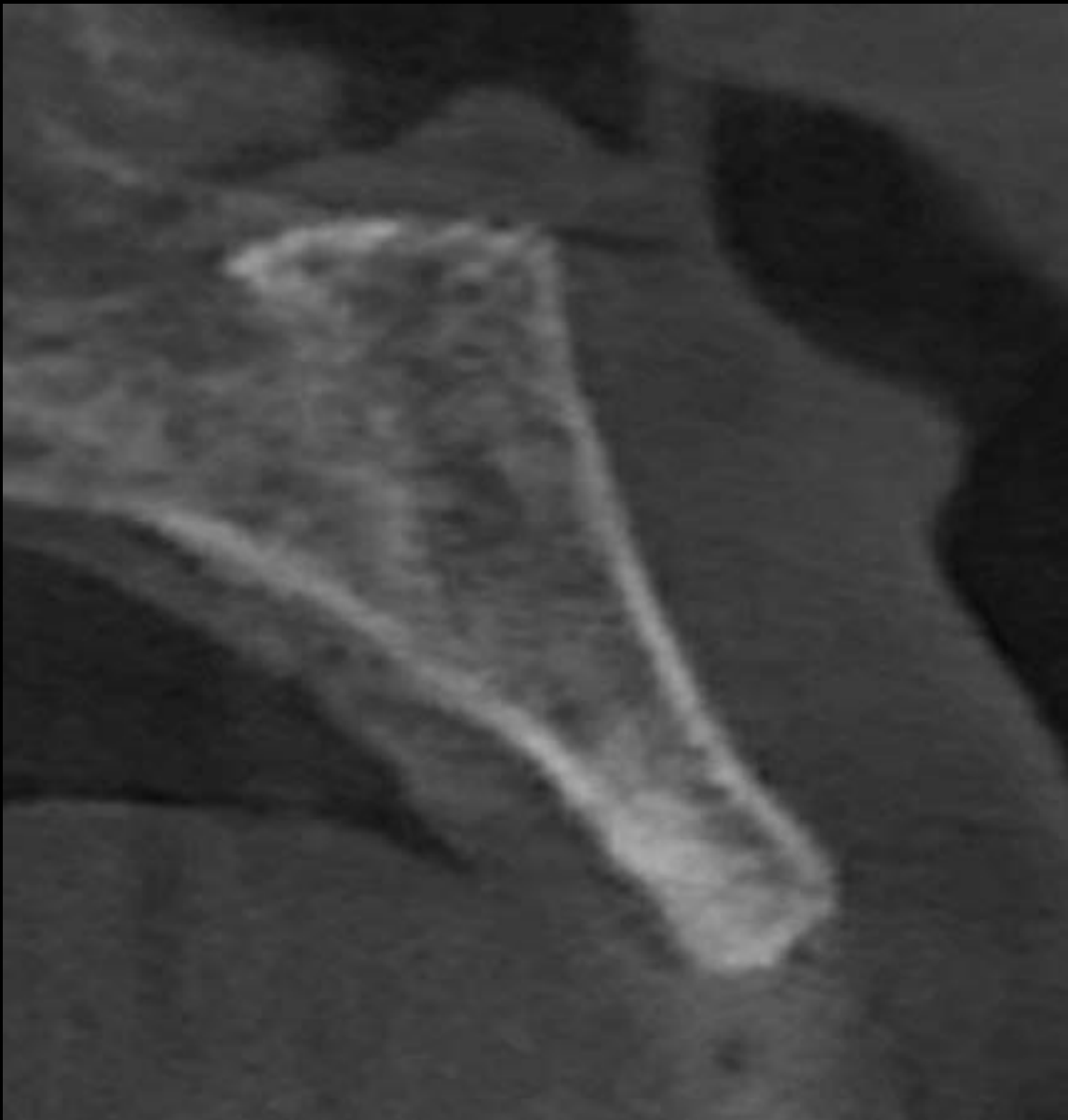
PMMA Maryland br

Pre-op (2025-02-21)



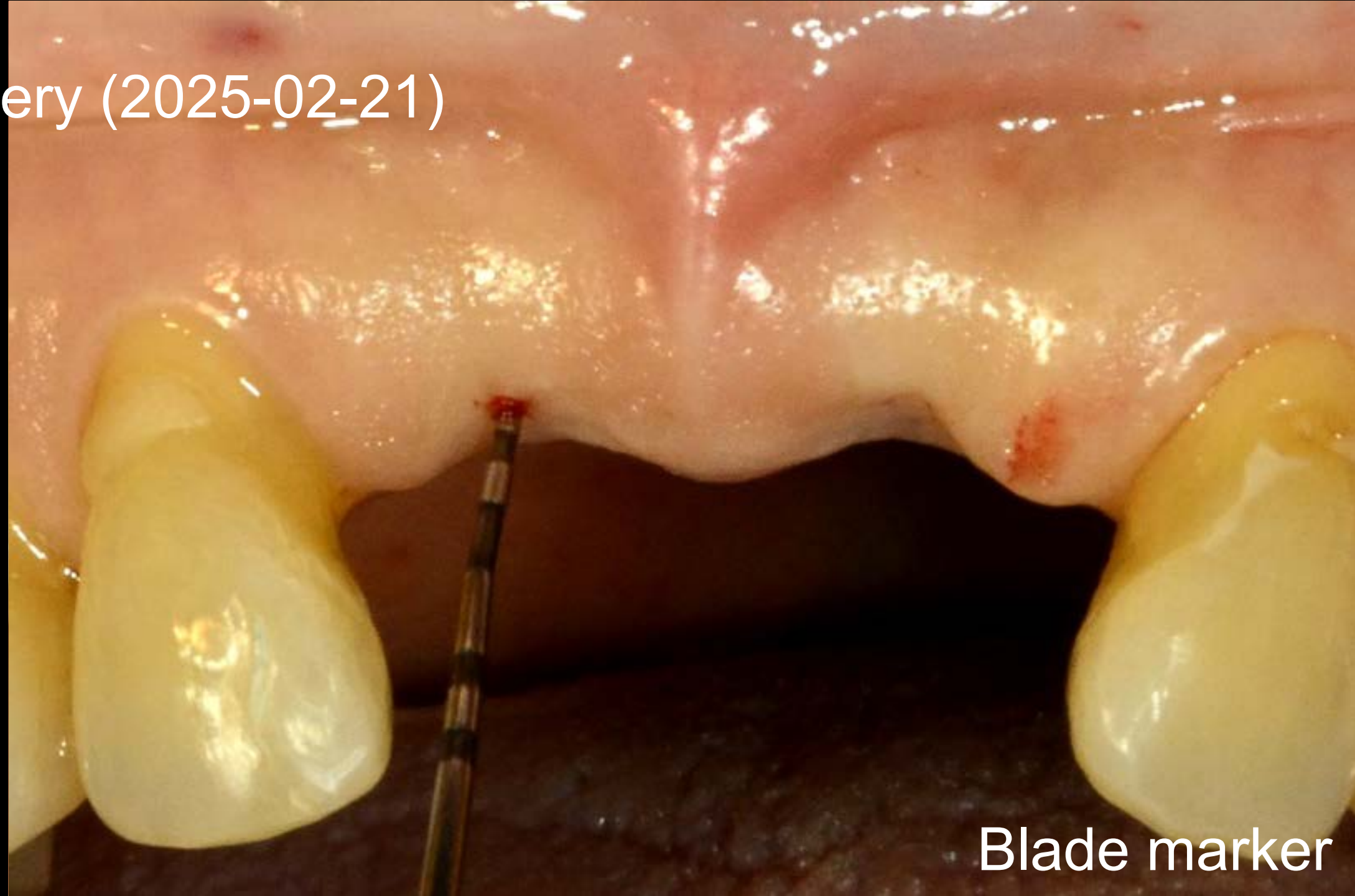


#11

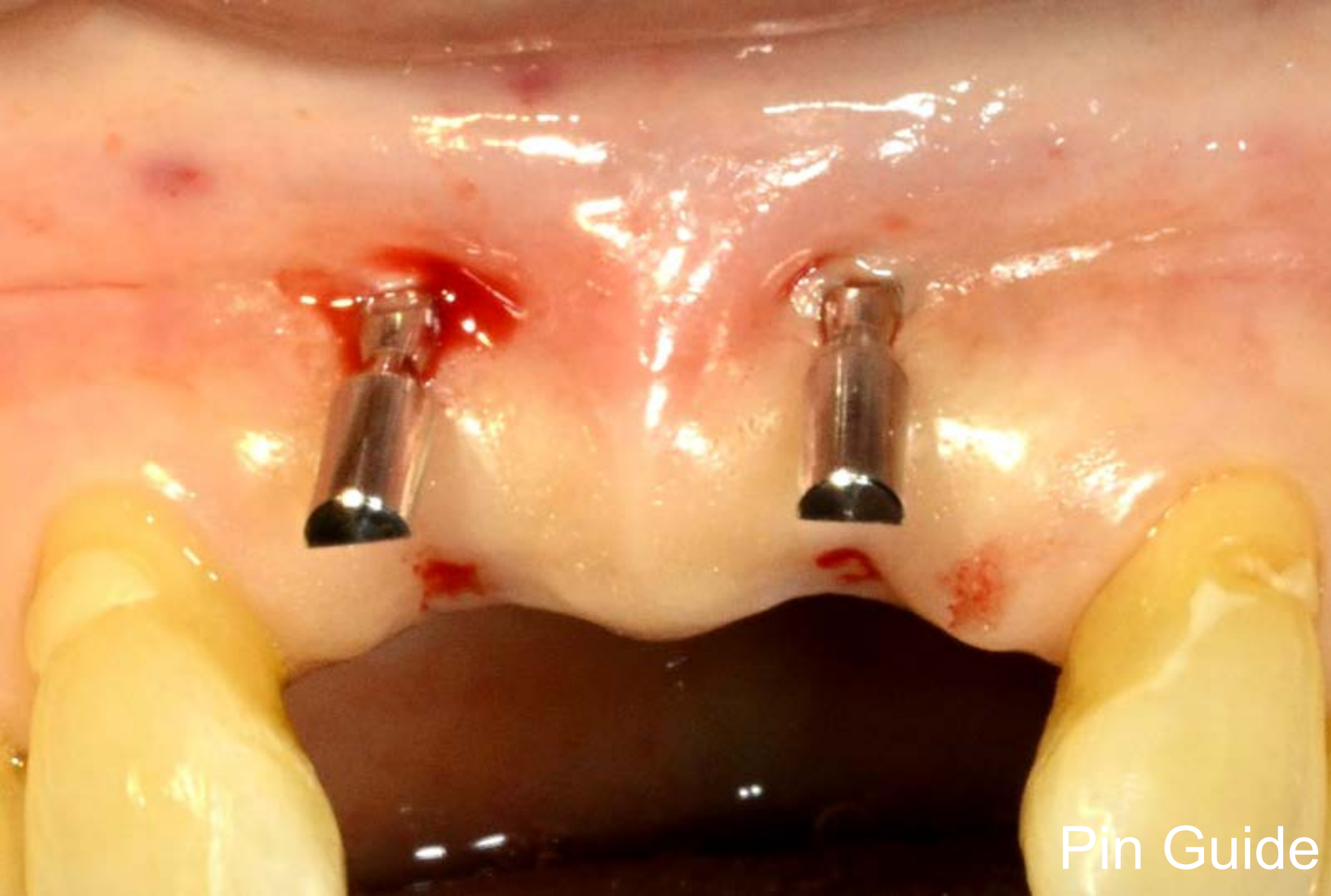


#21

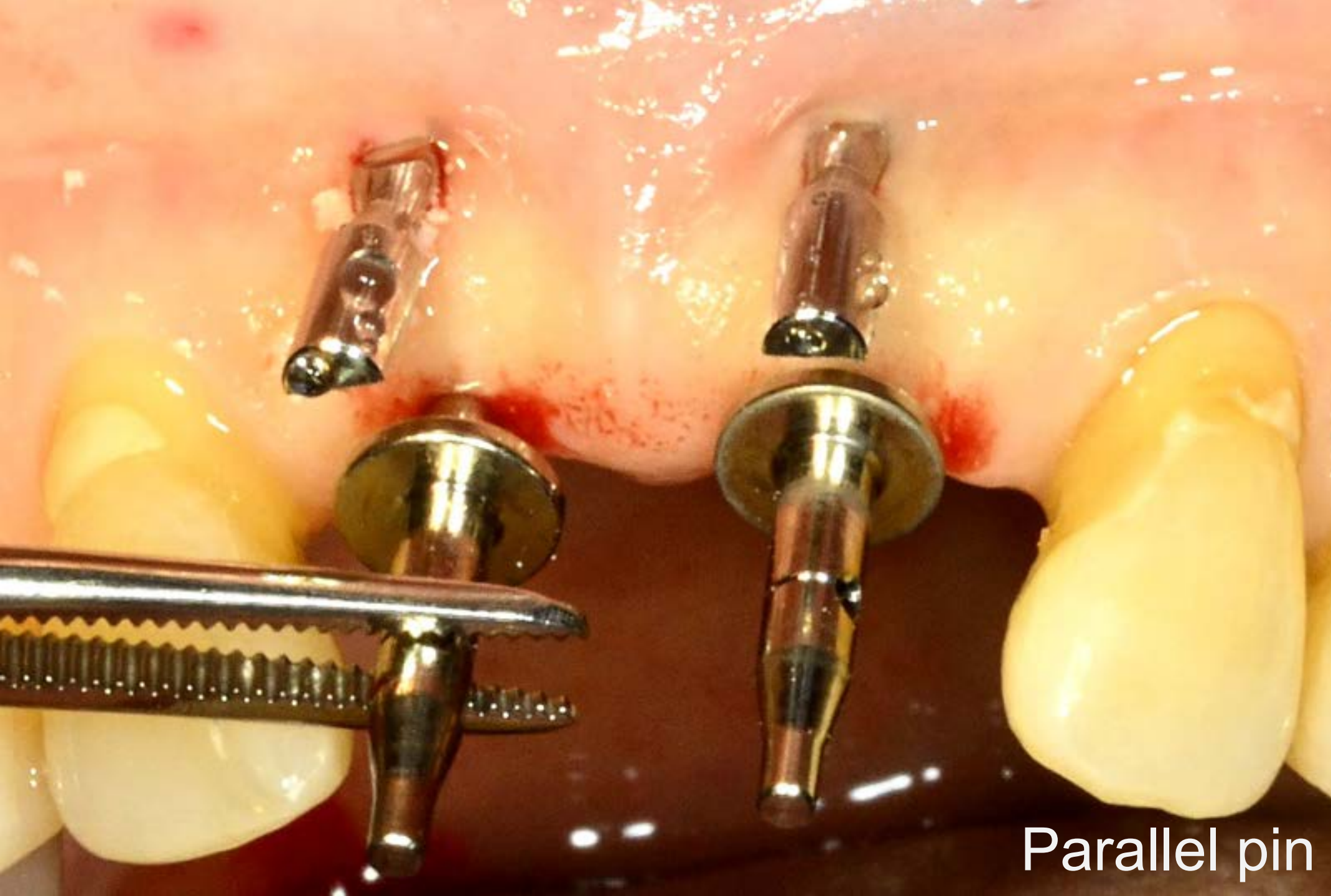
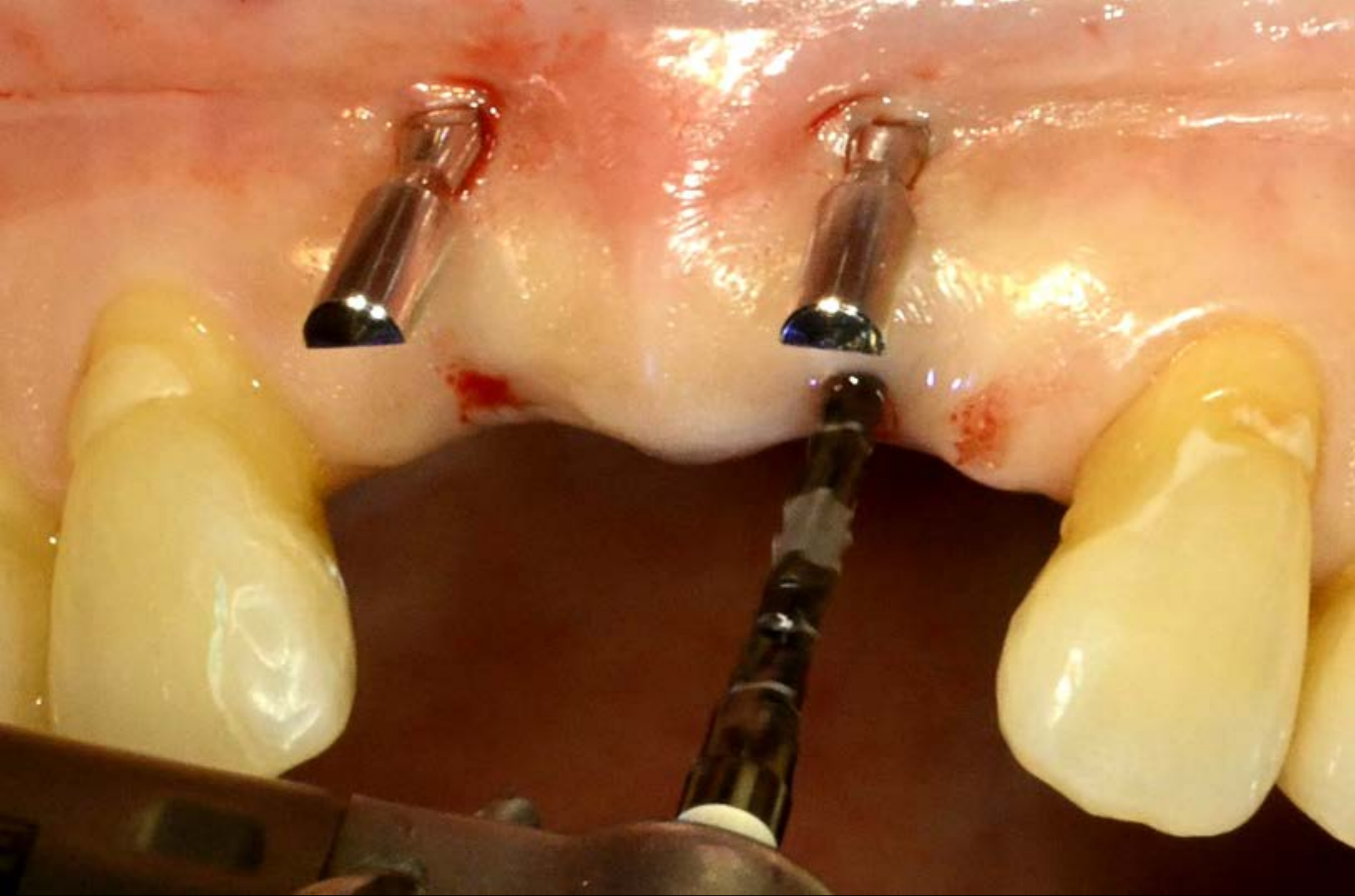
Surgery (2025-02-21)



Blade marker

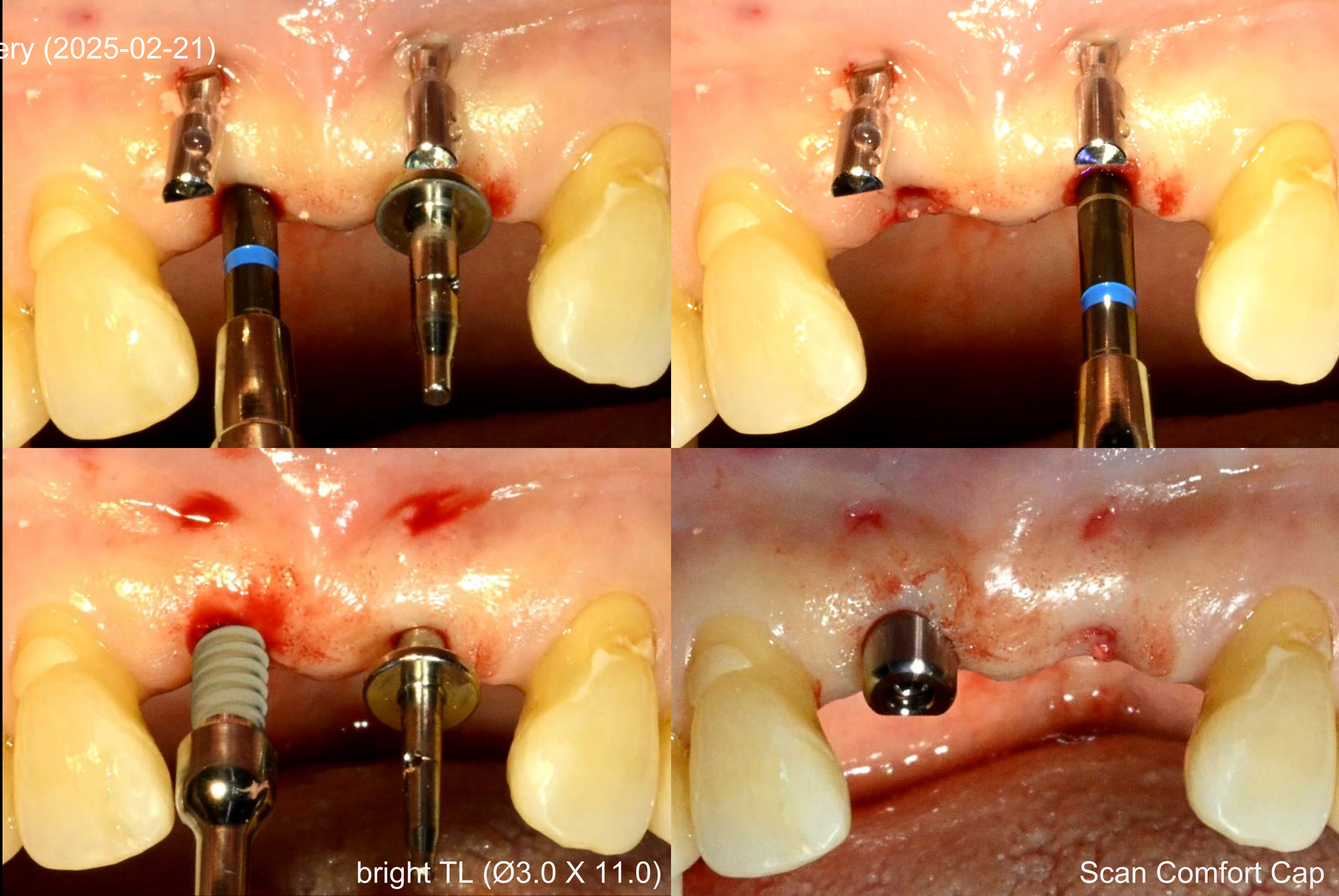


Pin Guide



Parallel pin

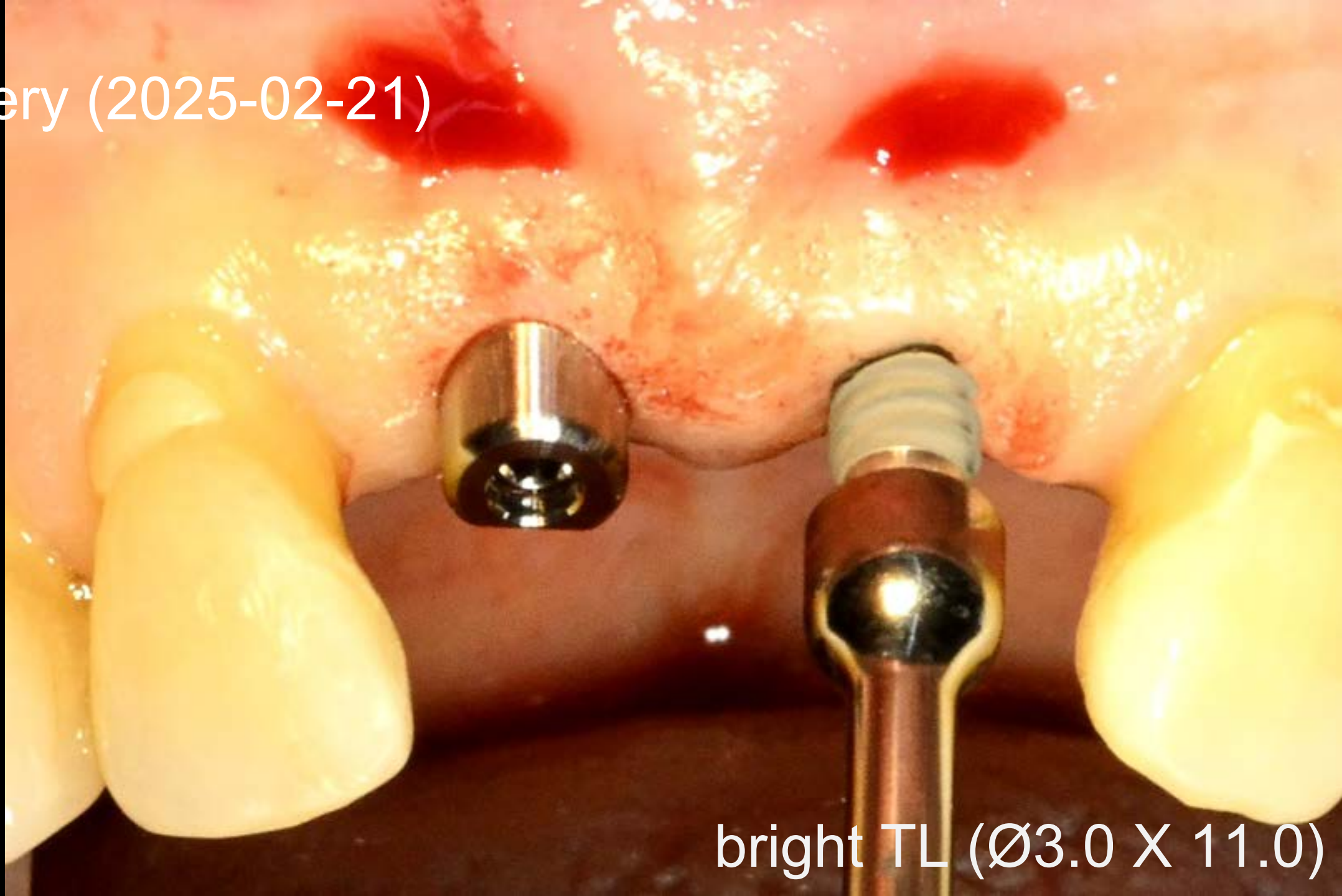
Surgery (2025-02-21)



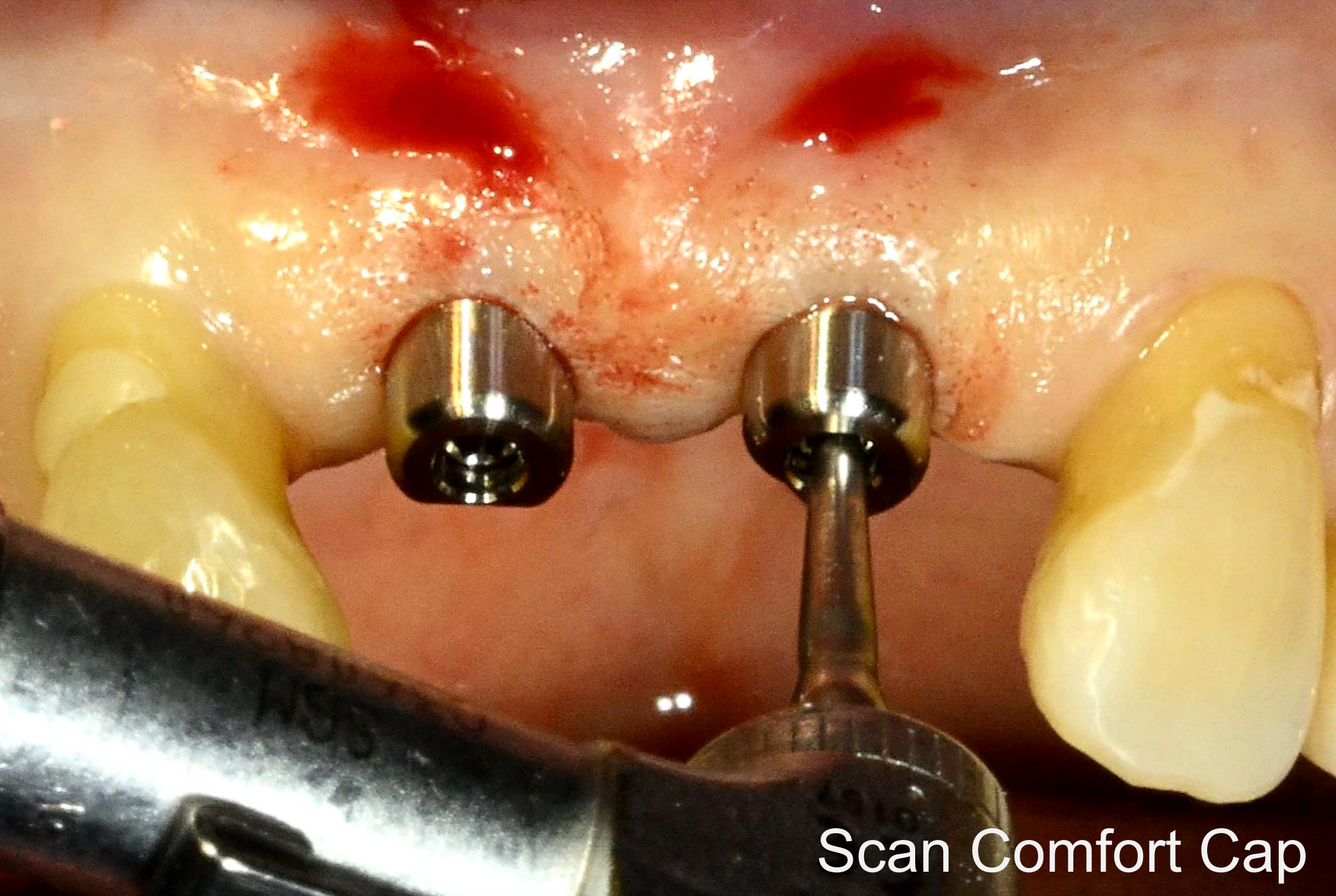
bright TL (Ø3.0 X 11.0)

Scan Comfort Cap

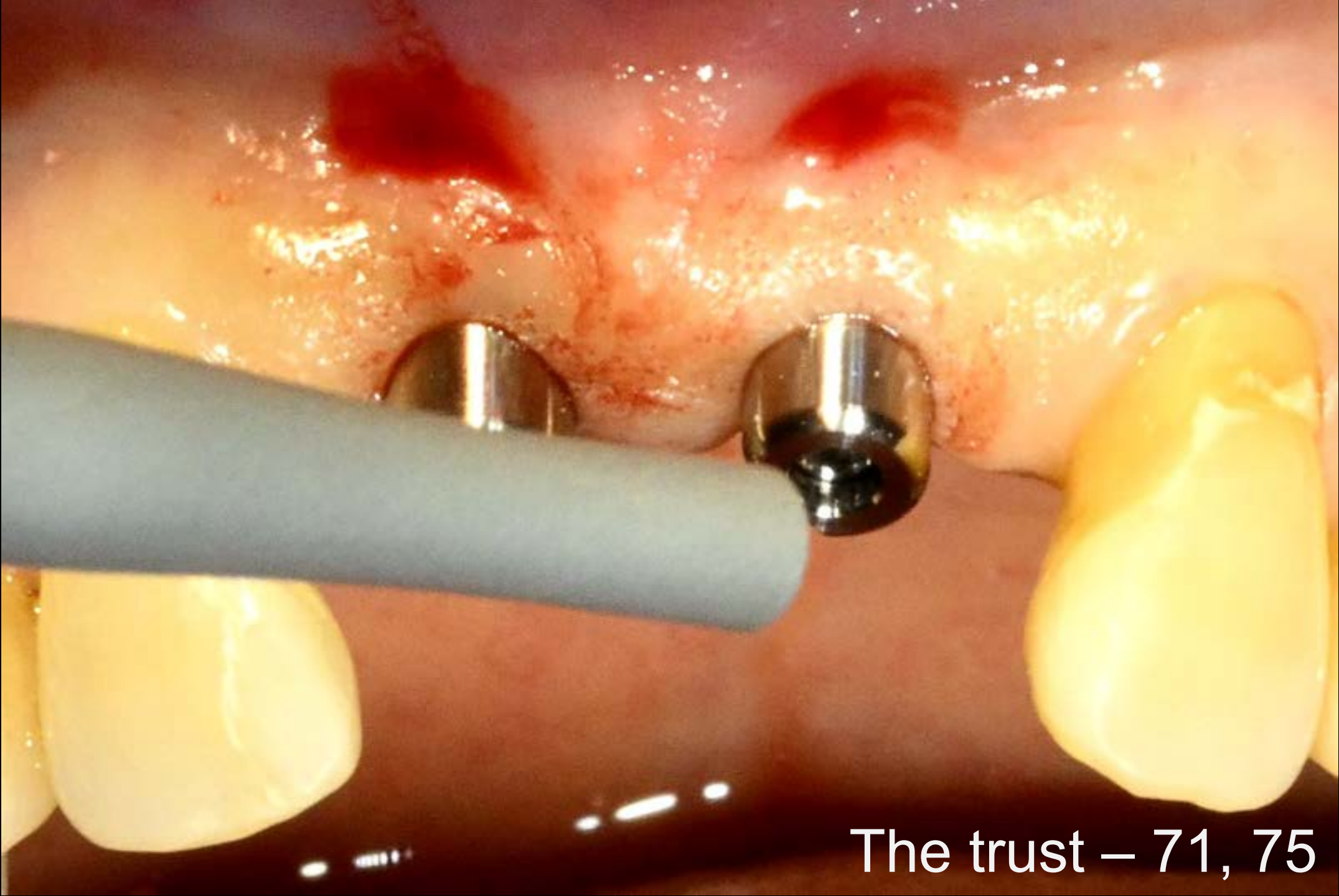Surgery (2025-02-21)



bright TL (Ø3.0 X 11.0)

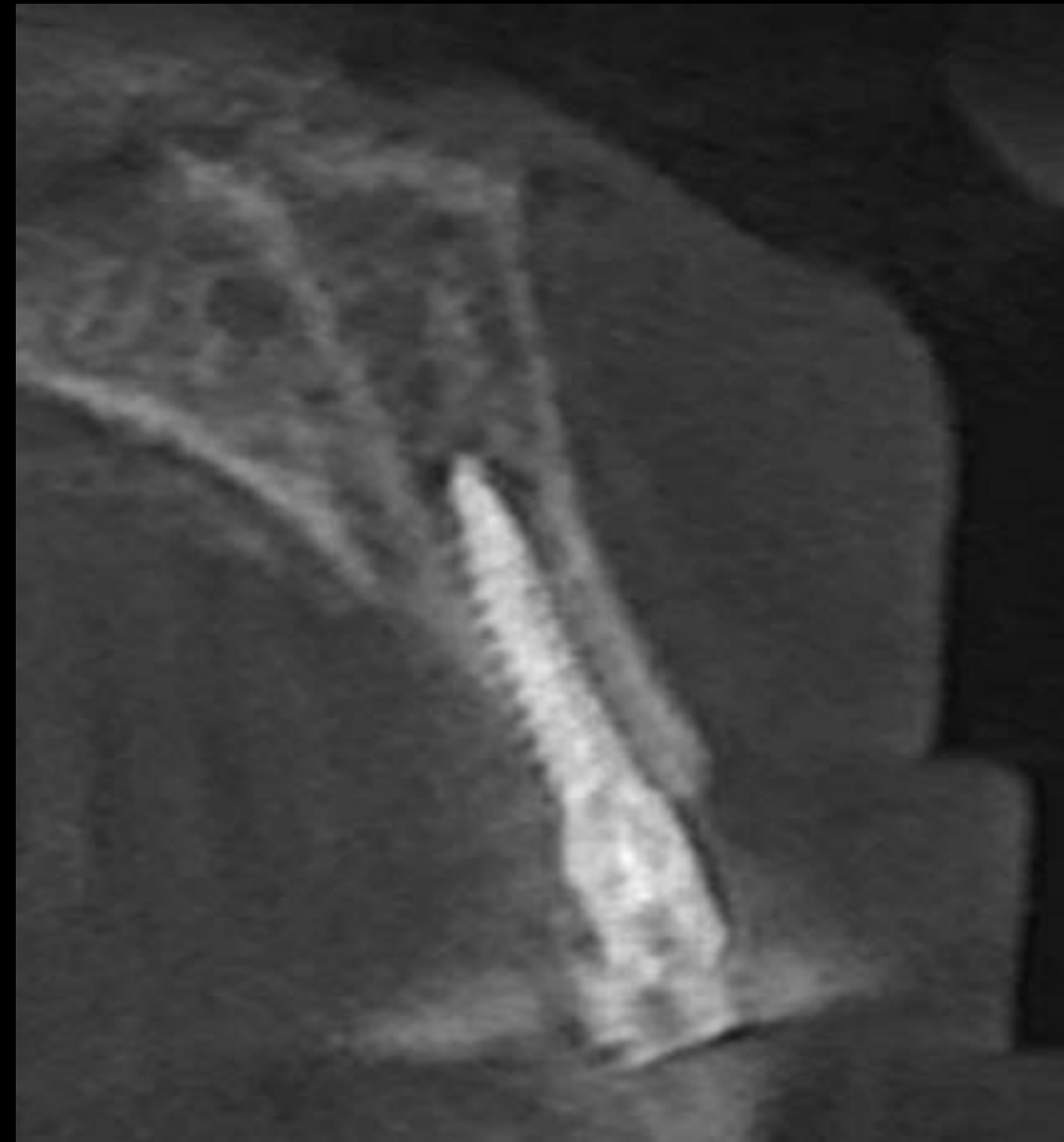


Scan Comfort Cap

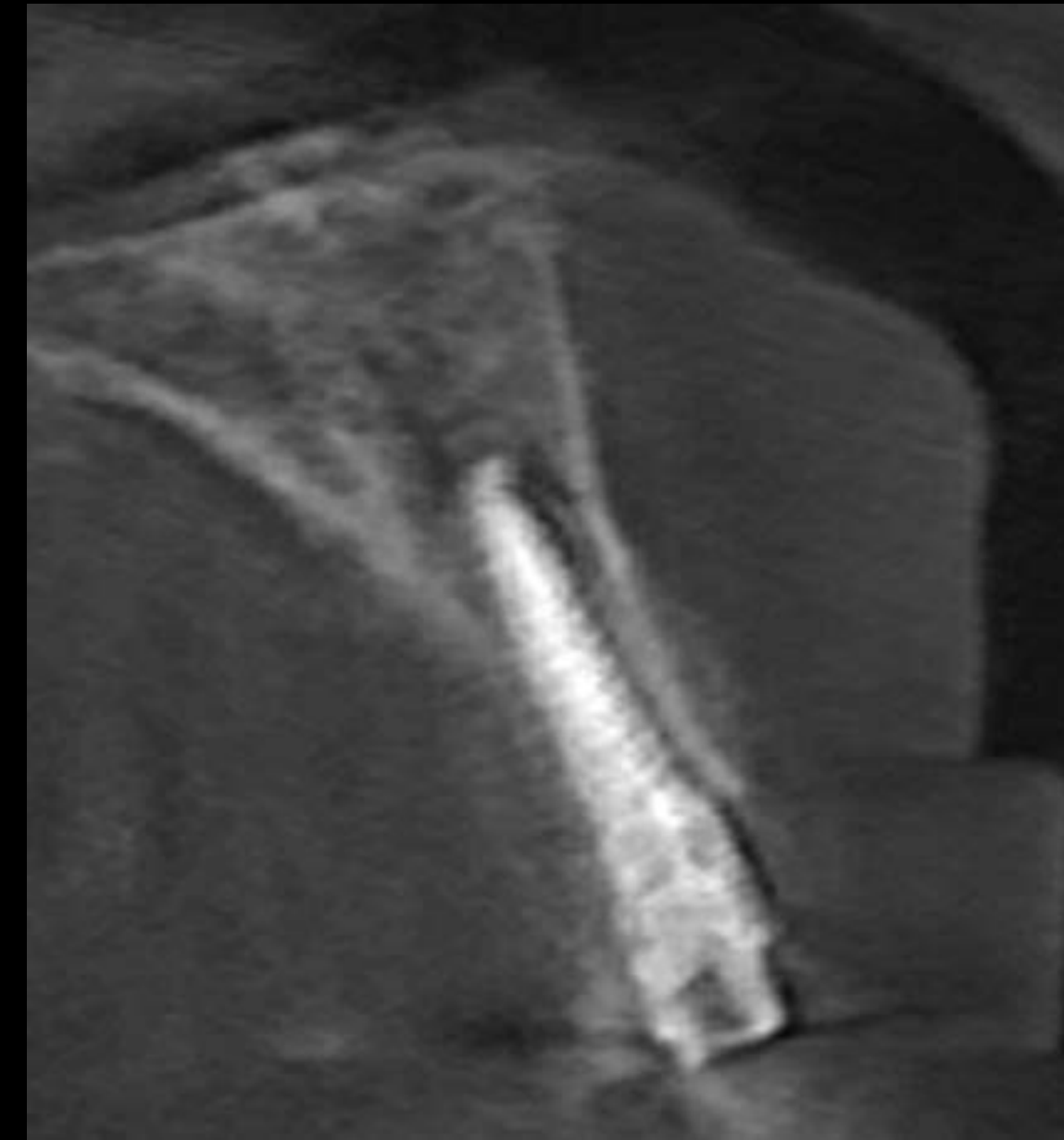


The trust – 71, 75

Post-op CT (2025-02-21)

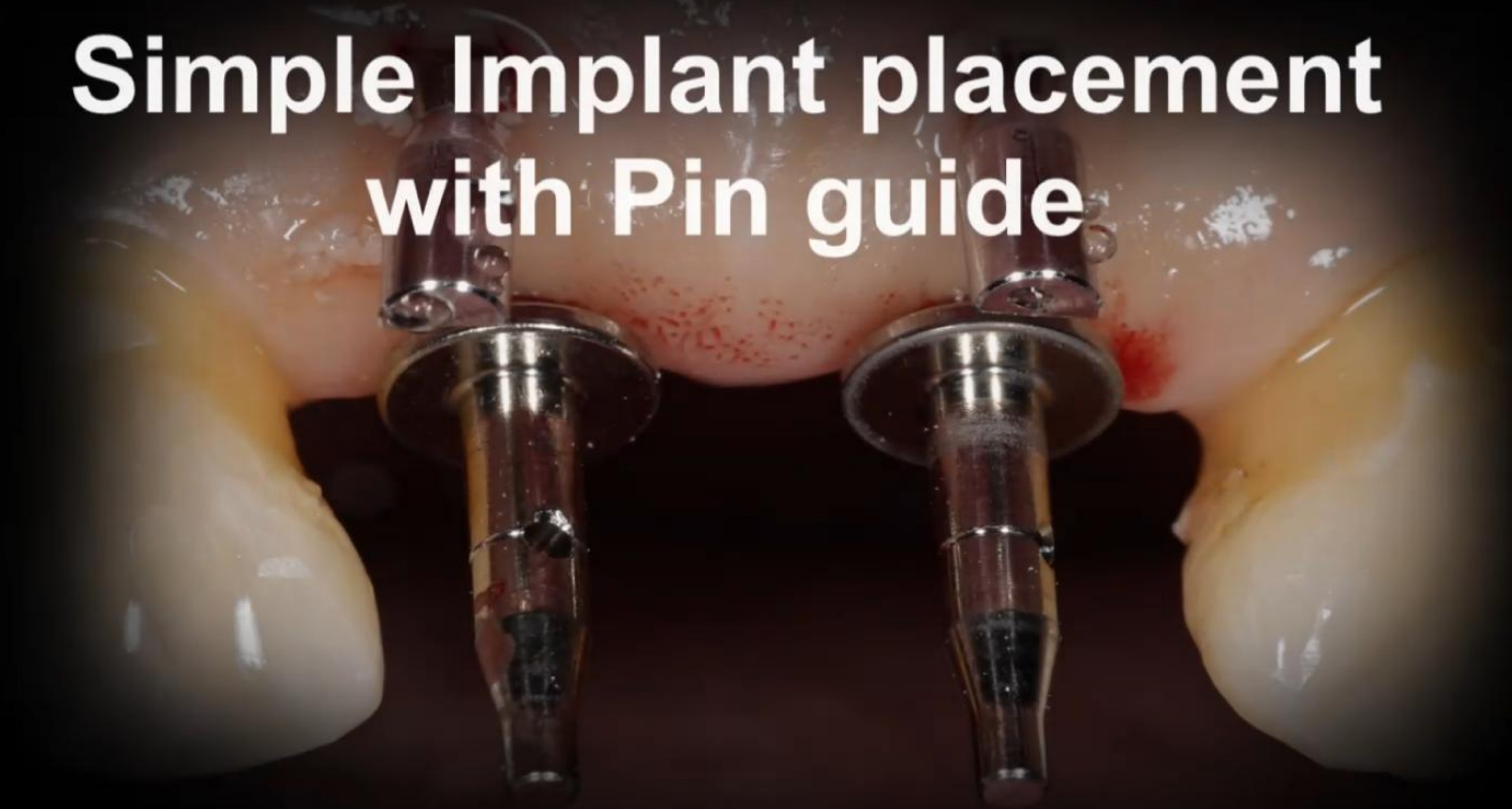

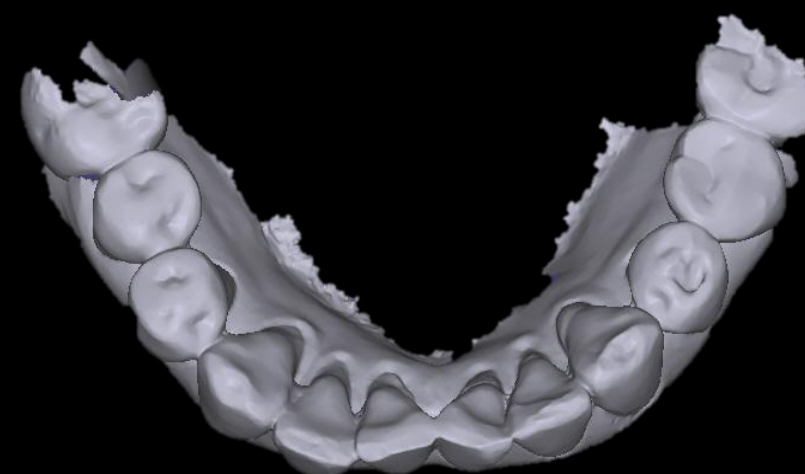
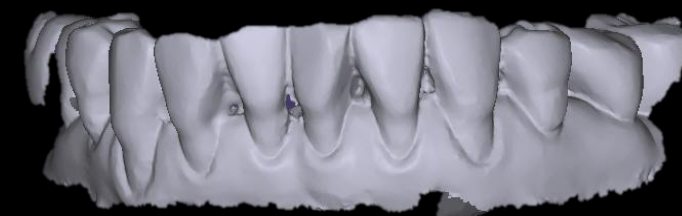
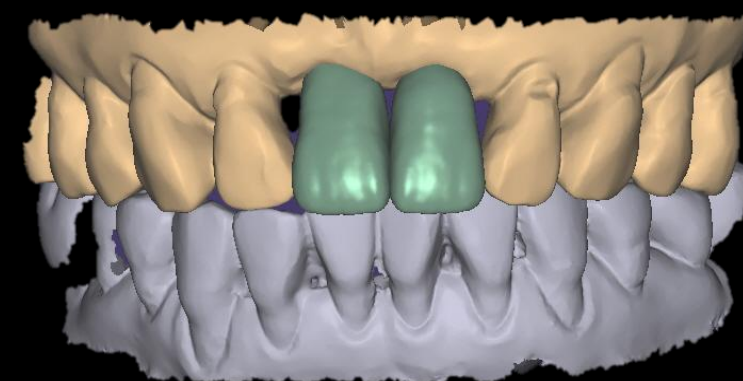
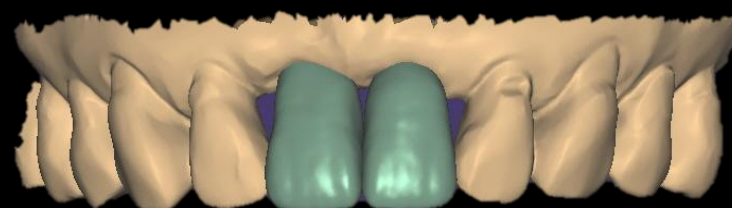
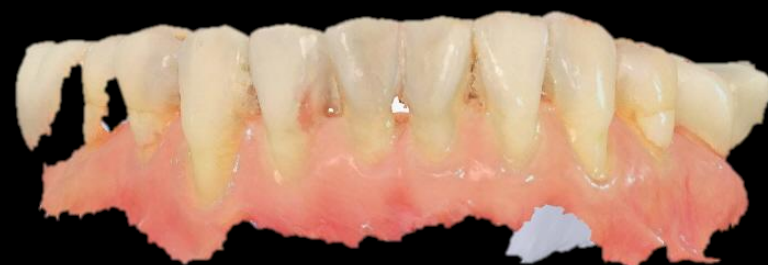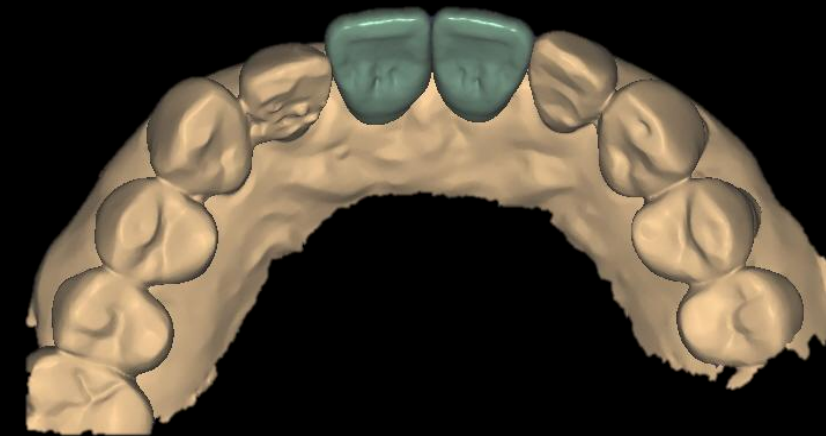
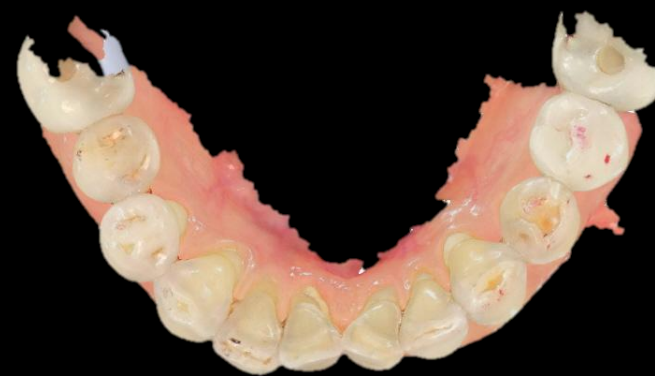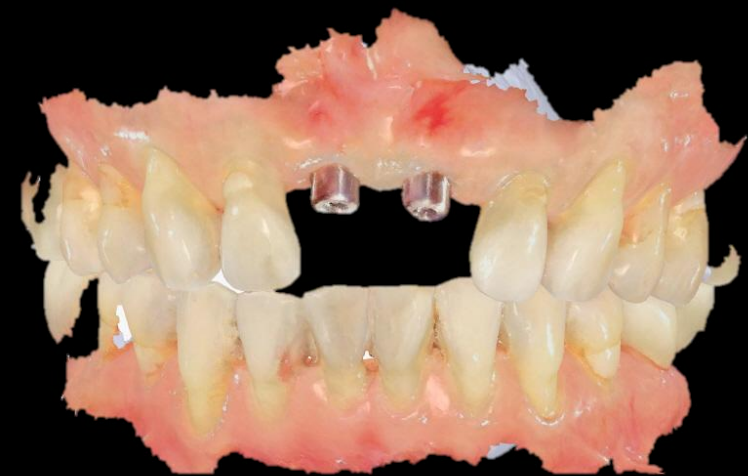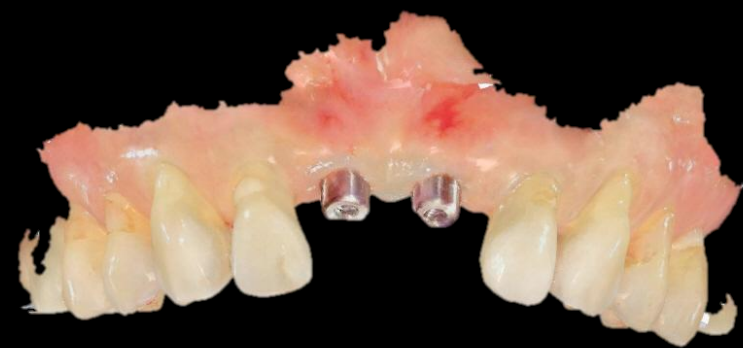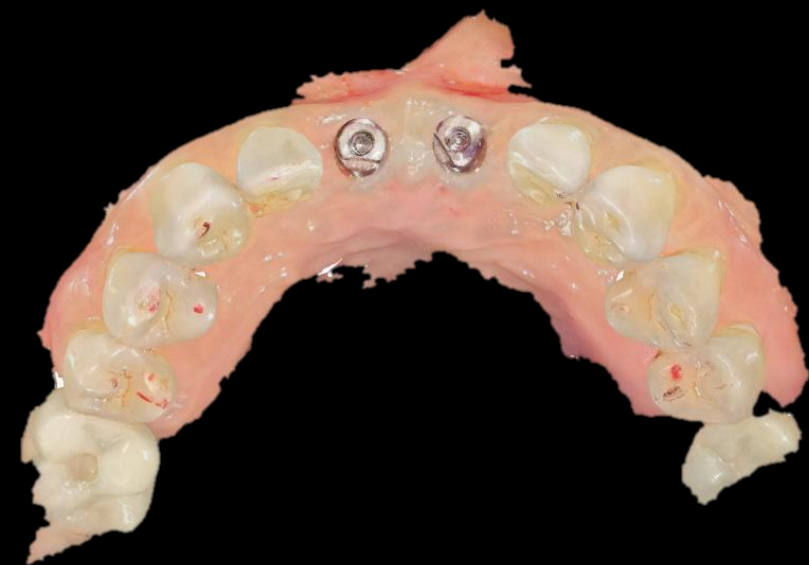#11



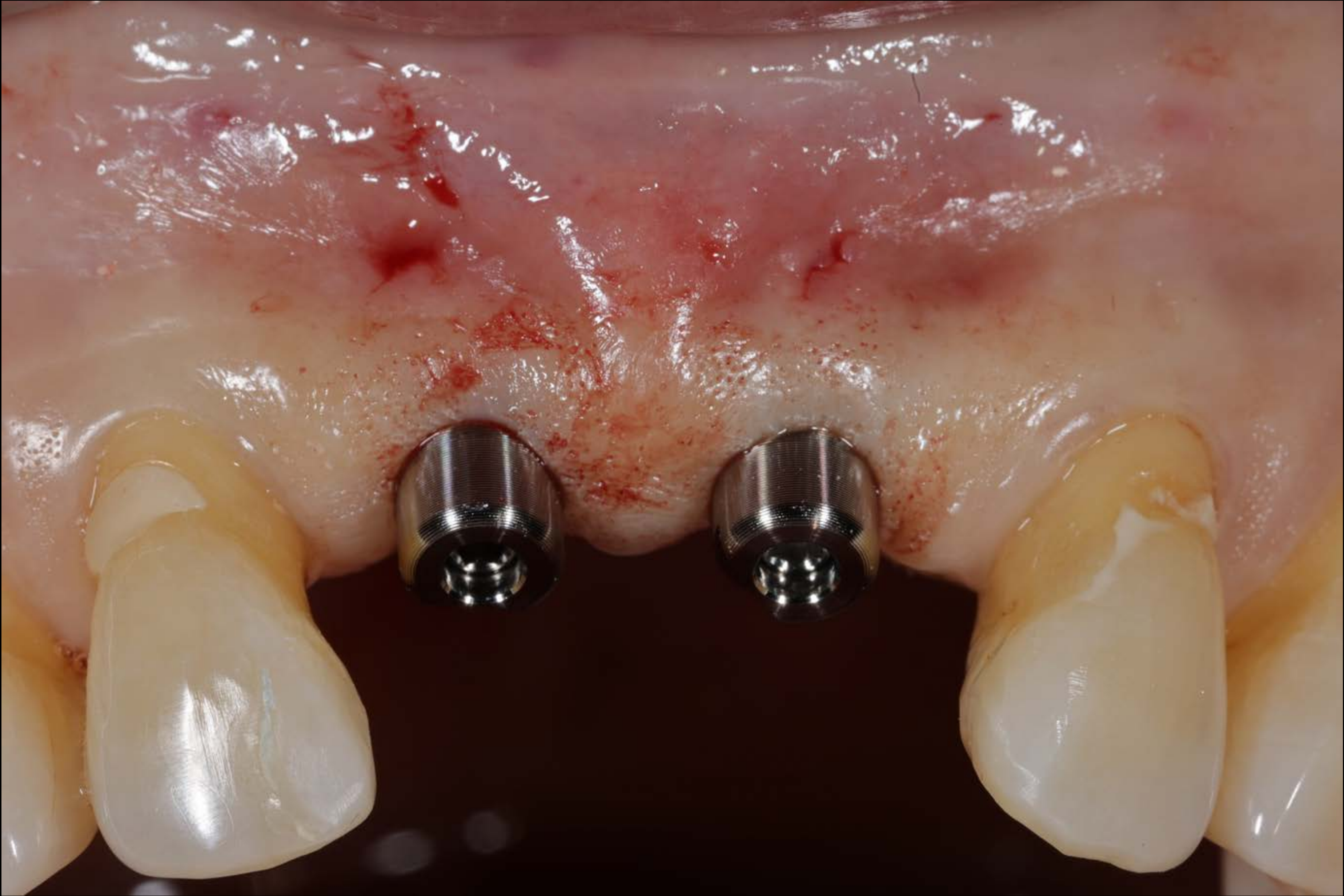
#21

Simple Implant placement with Pin guide

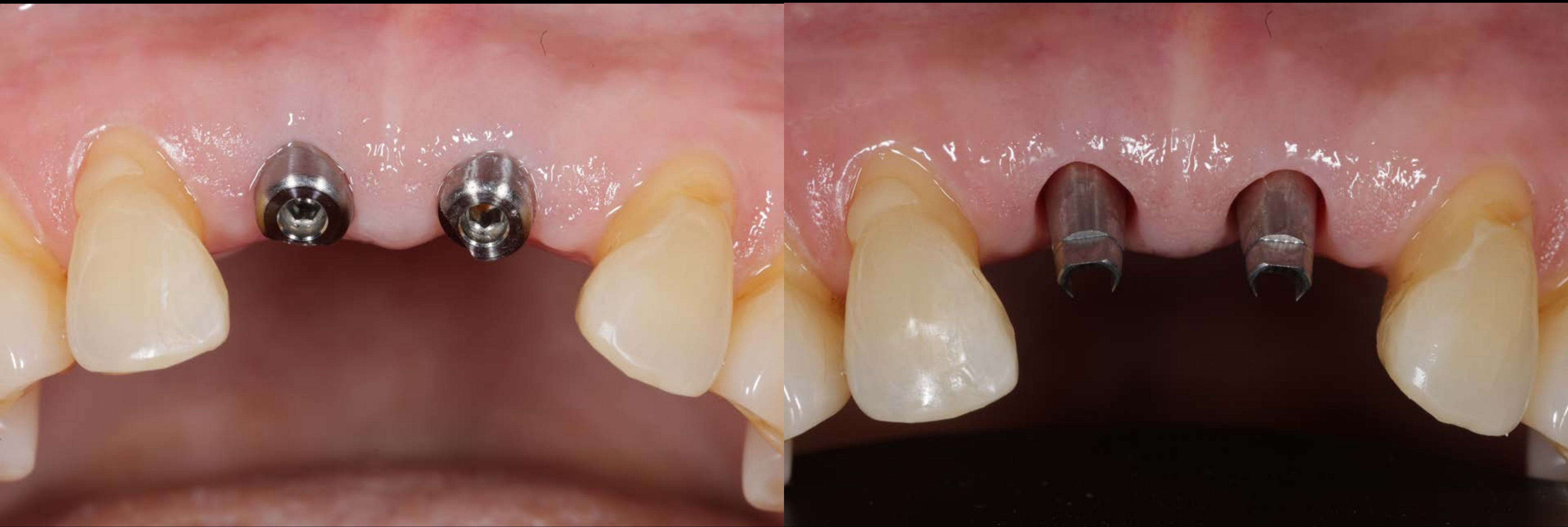



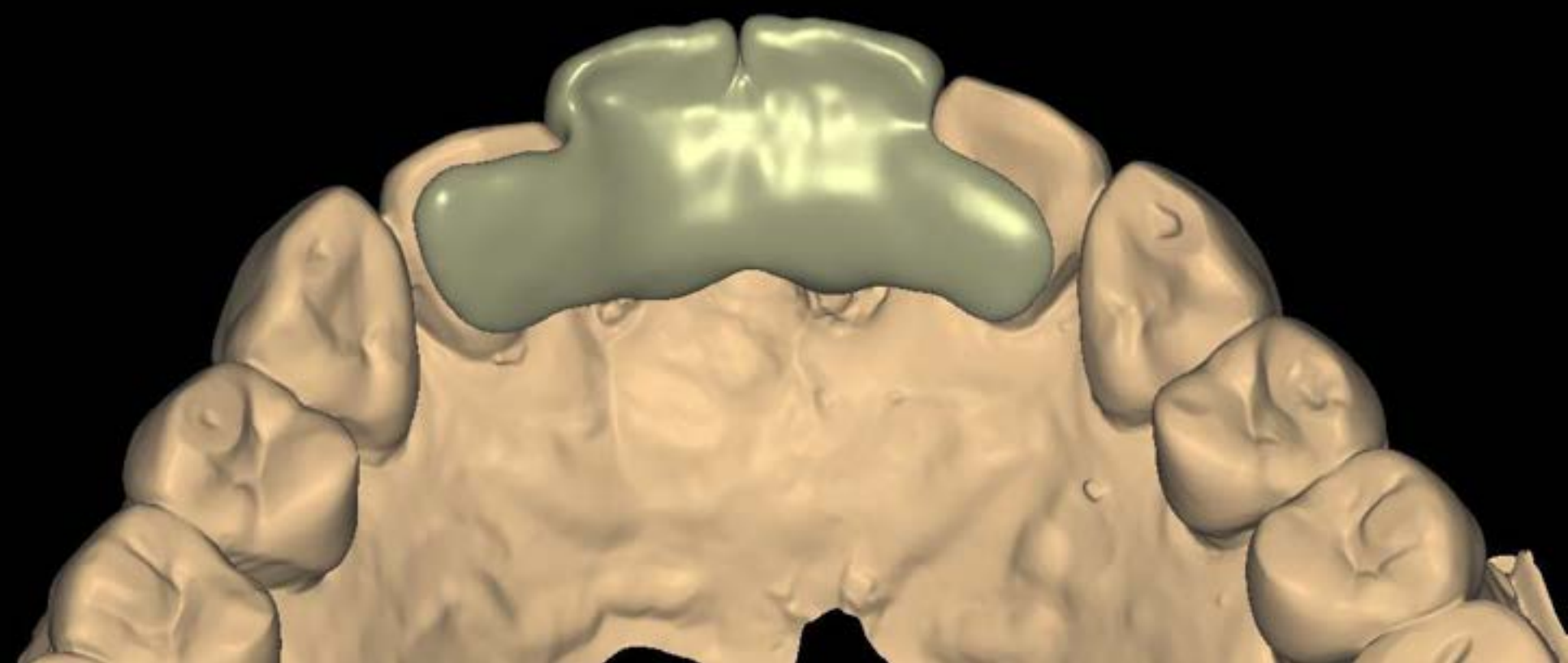
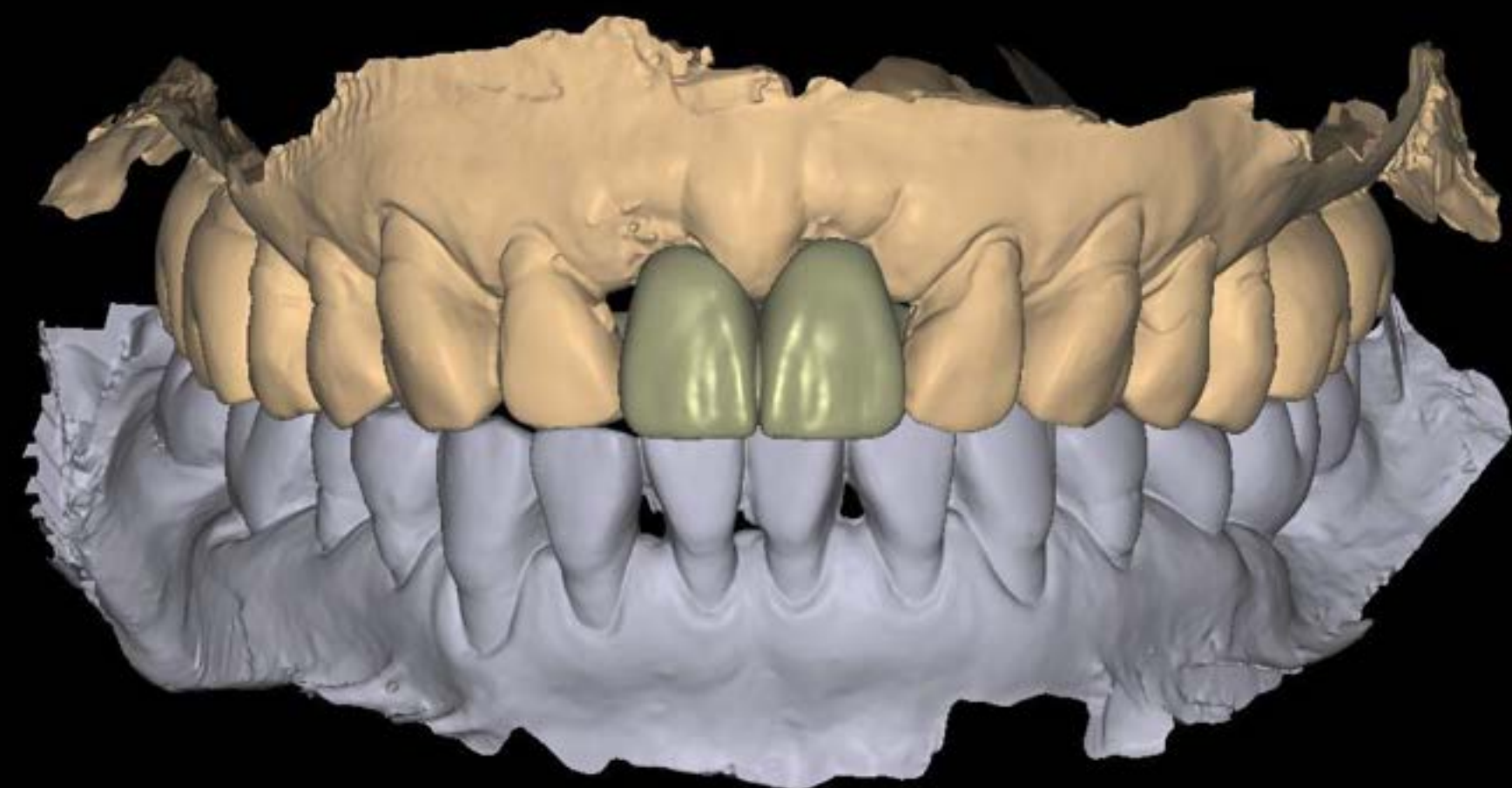
Post-op (2025-02-21)



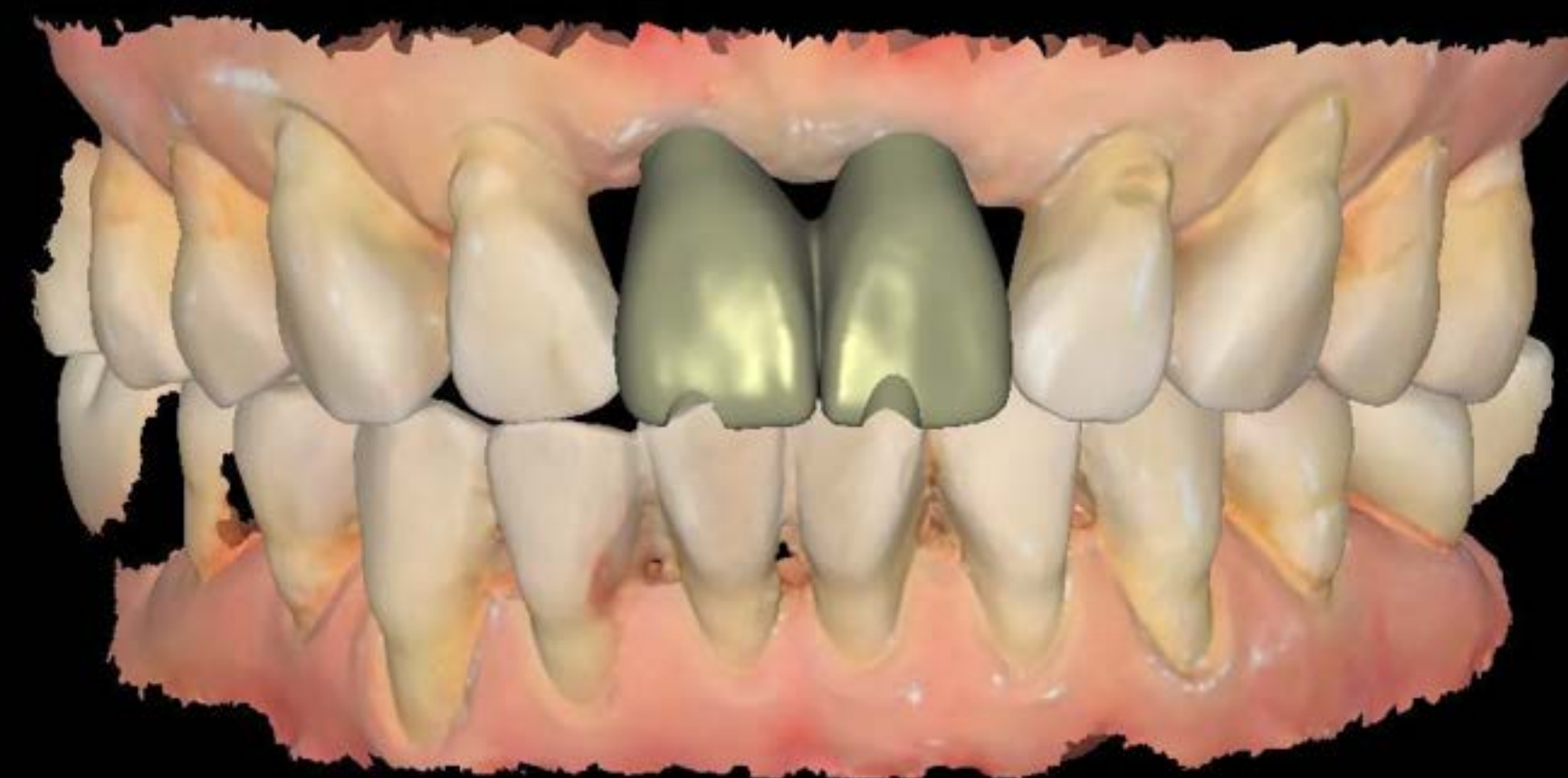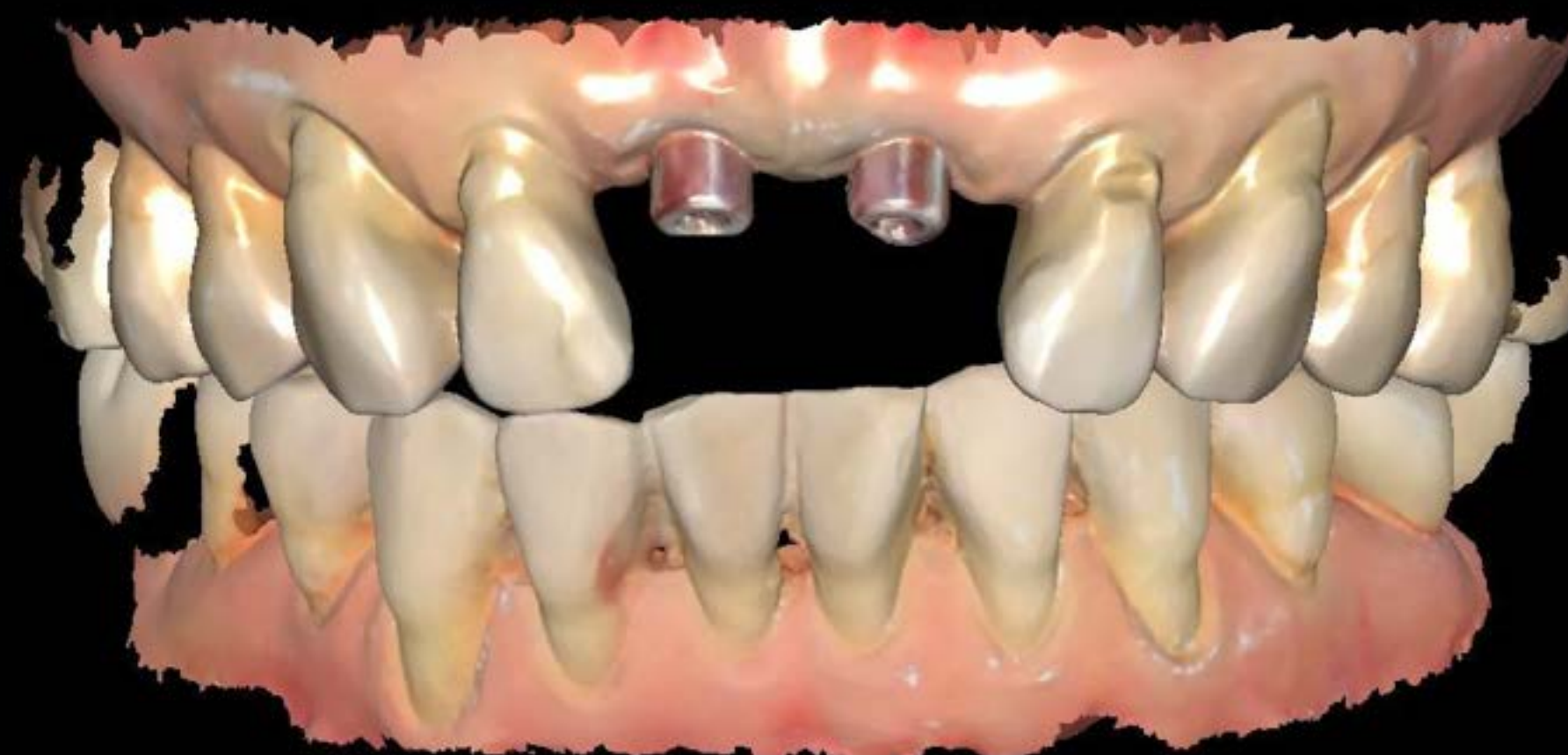Healing : 1 week (2025-02-27)



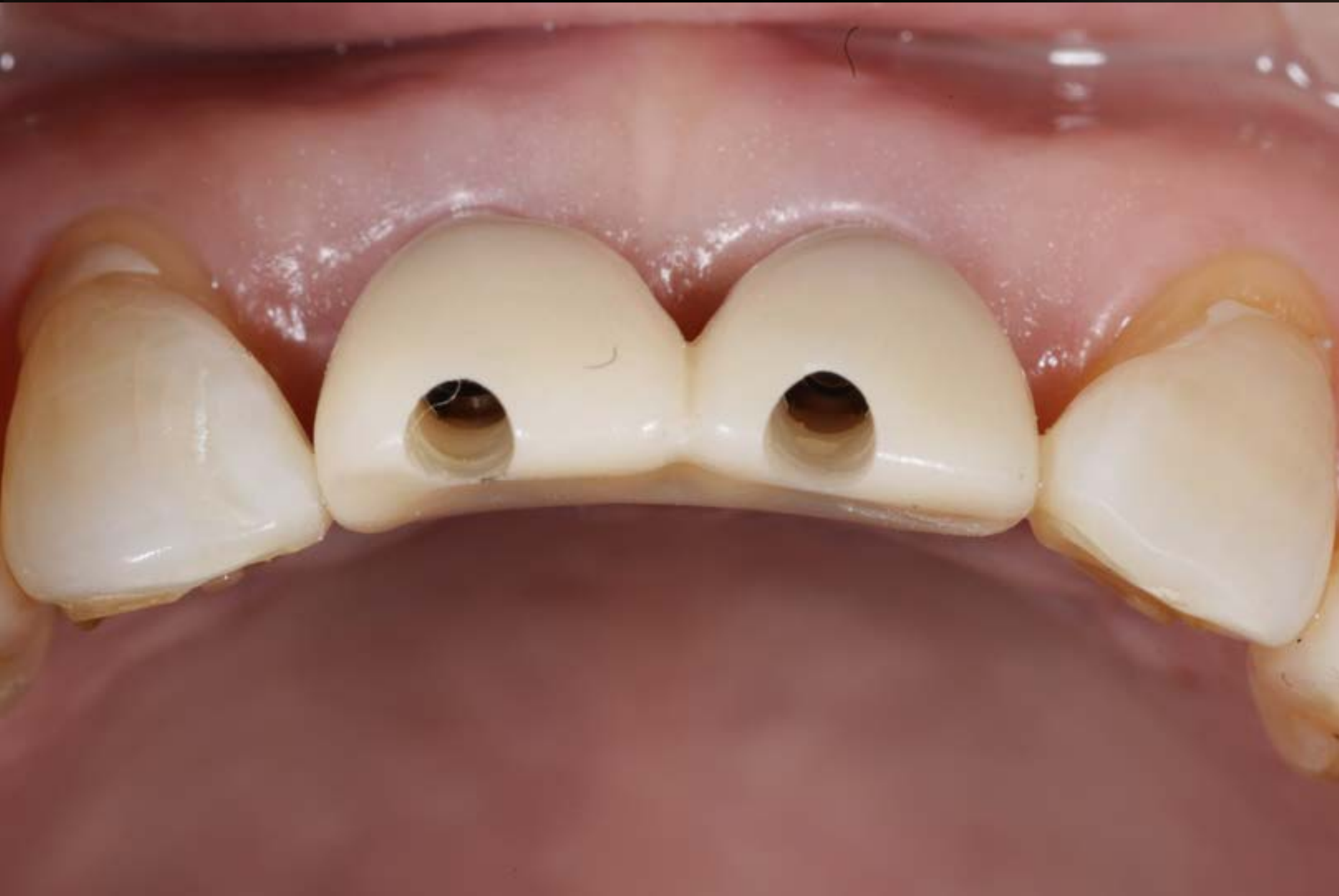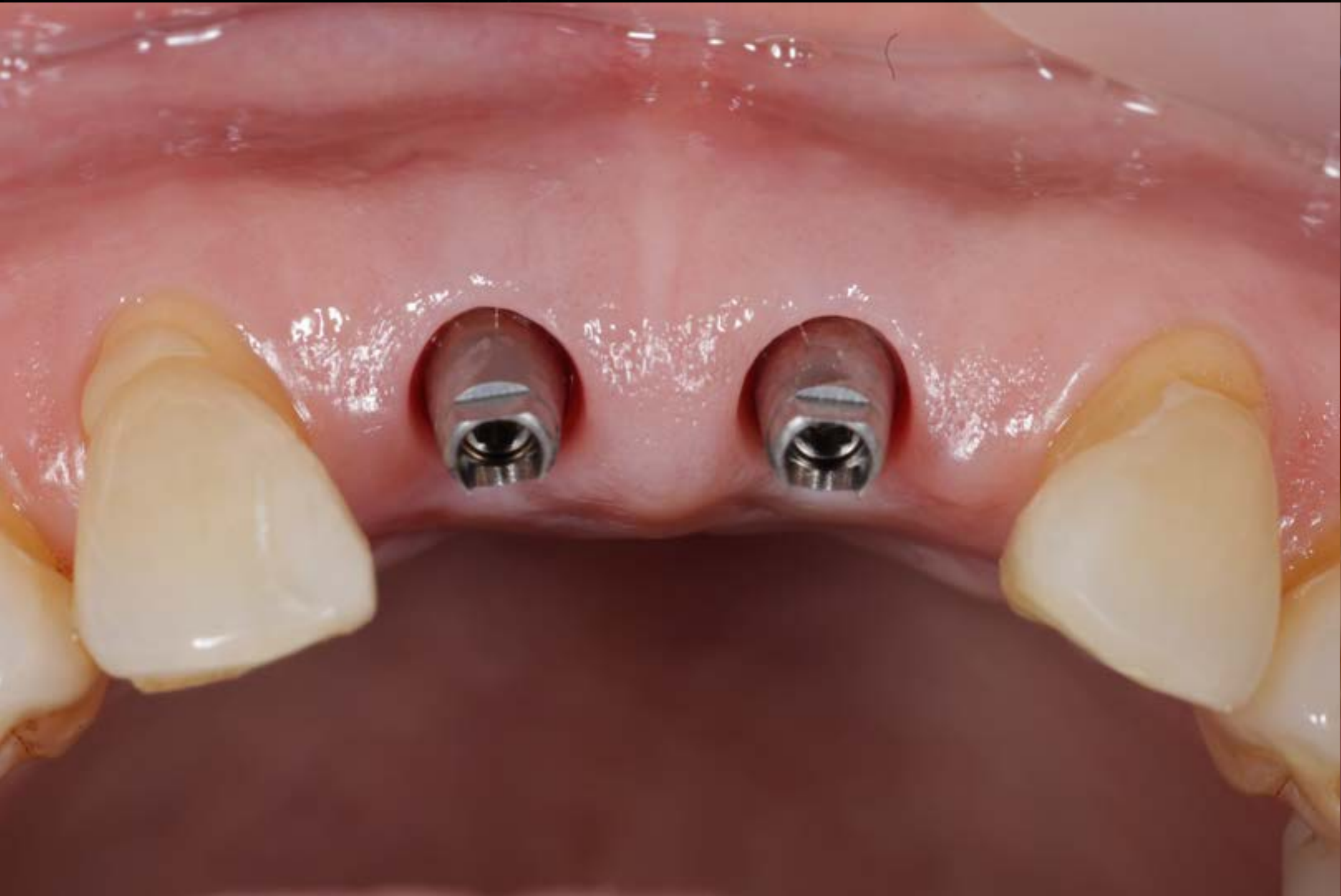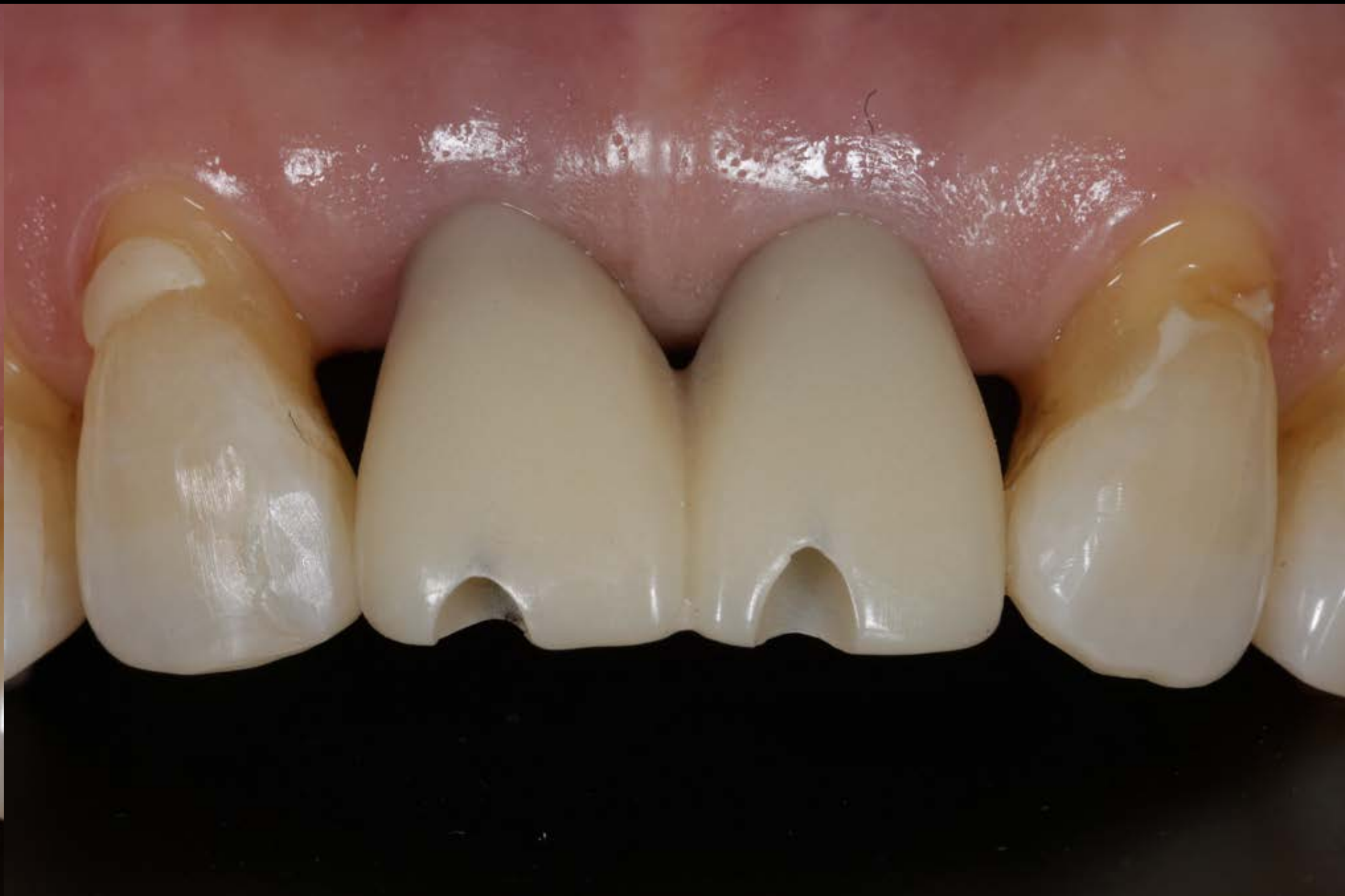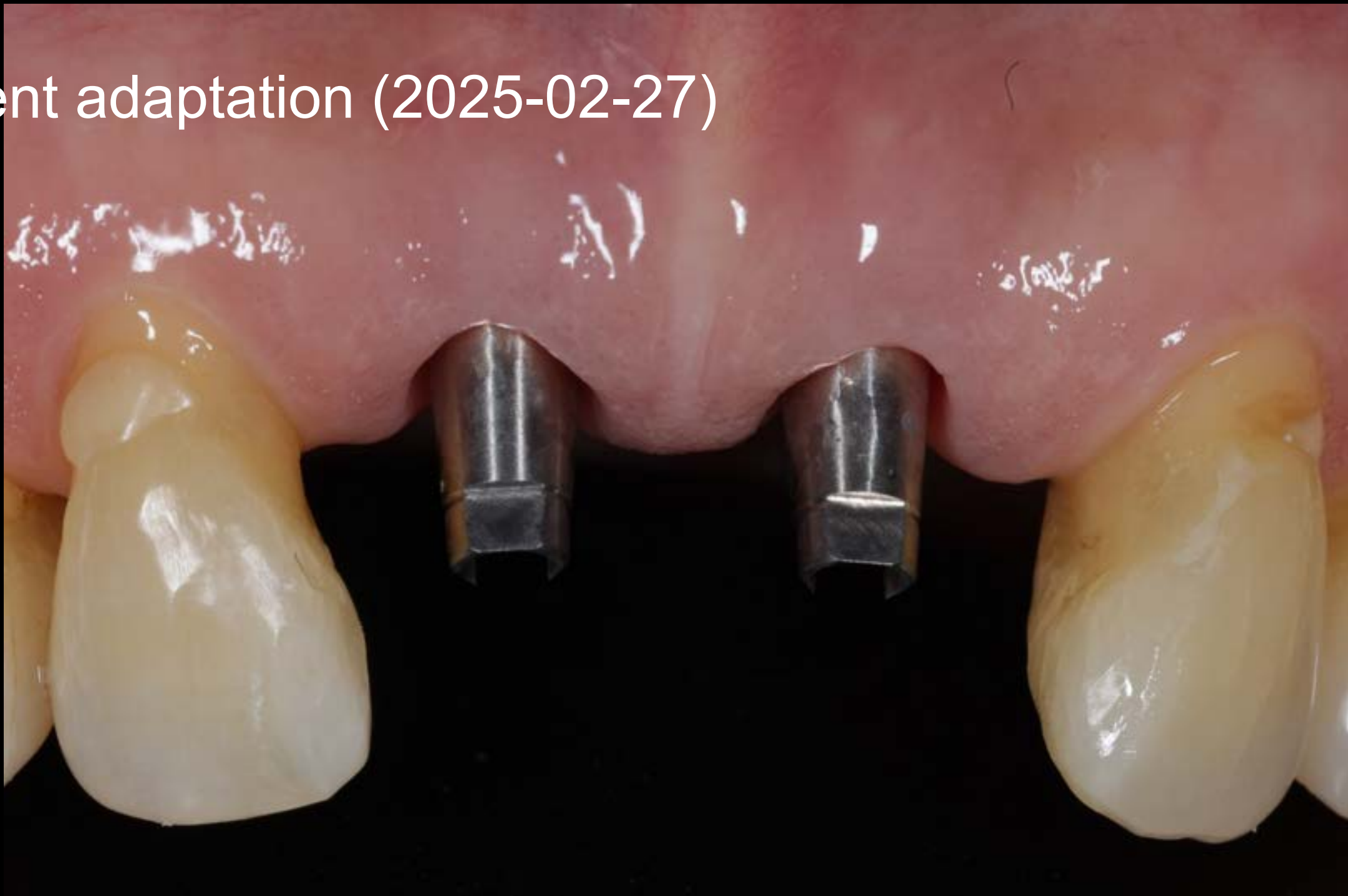Pre Op



Provisional crown



Abutment adaptation (2025-02-27)



CT Viewer

Patient Information

노영래

ID

11604

Age

65

Exam date

20250221

Virtual Ceph

Select Mark

Create Ceph

Create YTI

Occlusal Plane(OP)

AUTO

Render Type

Hard Type

Viewport

HU

2431

Q

78

Q

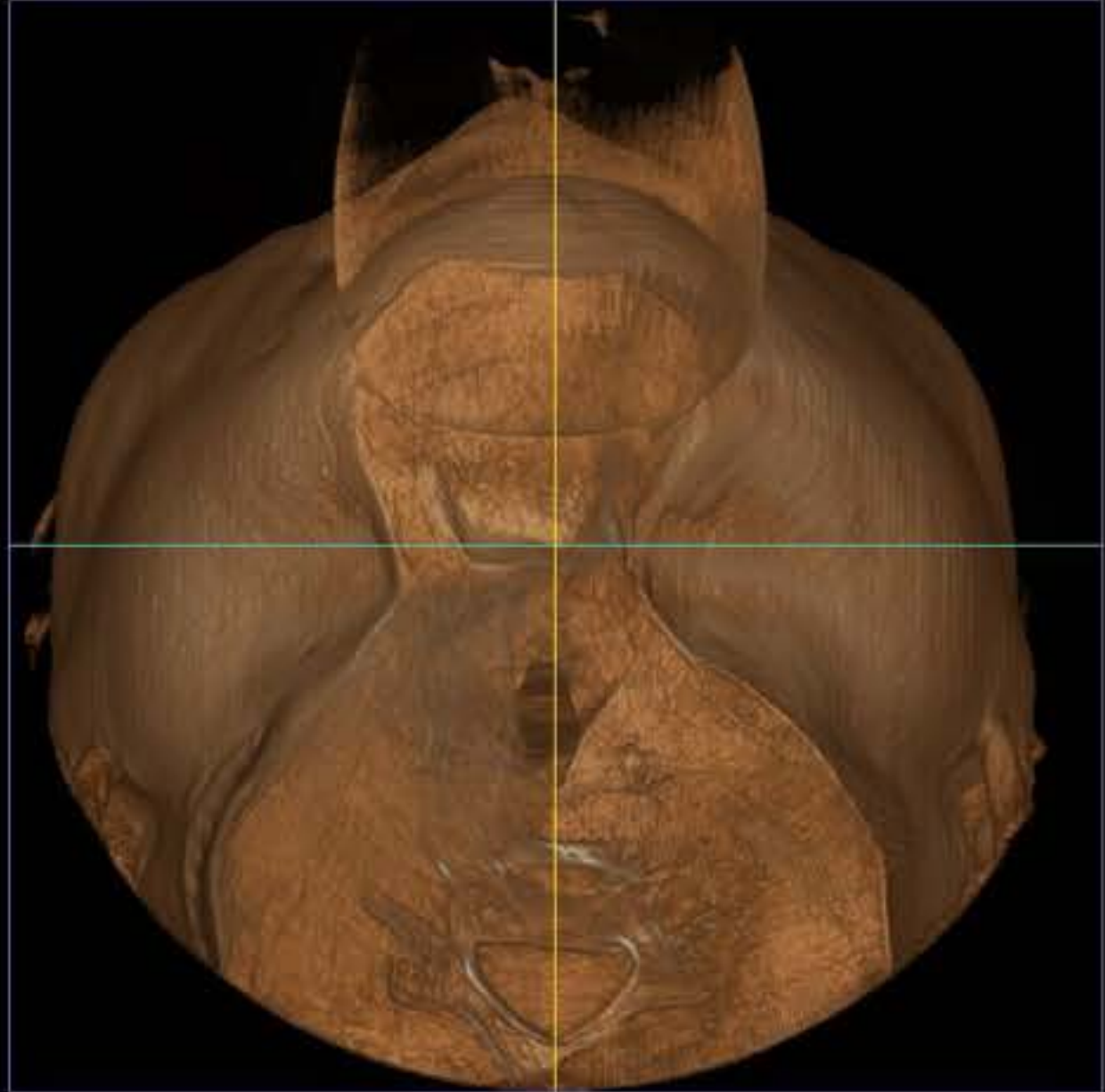
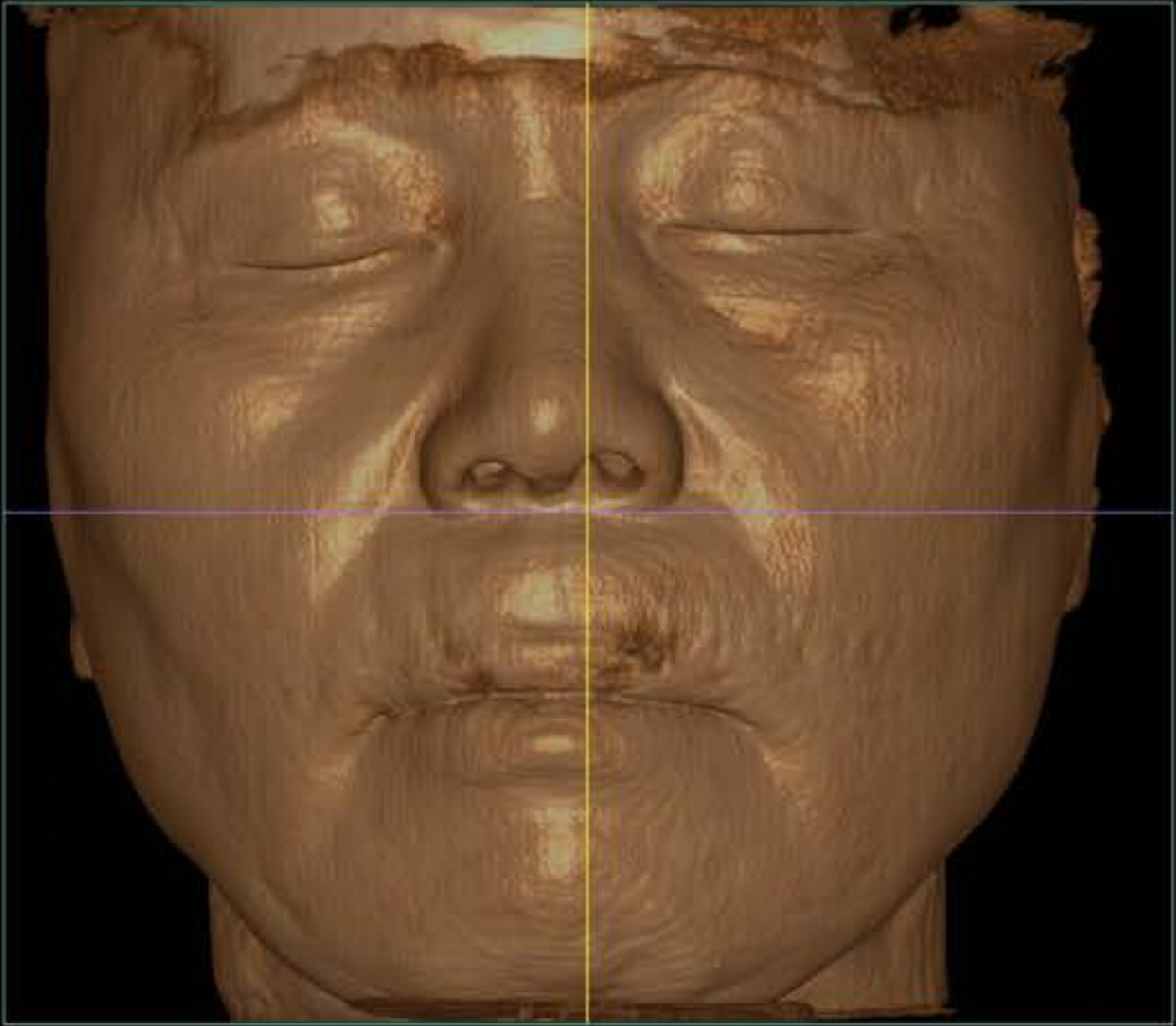
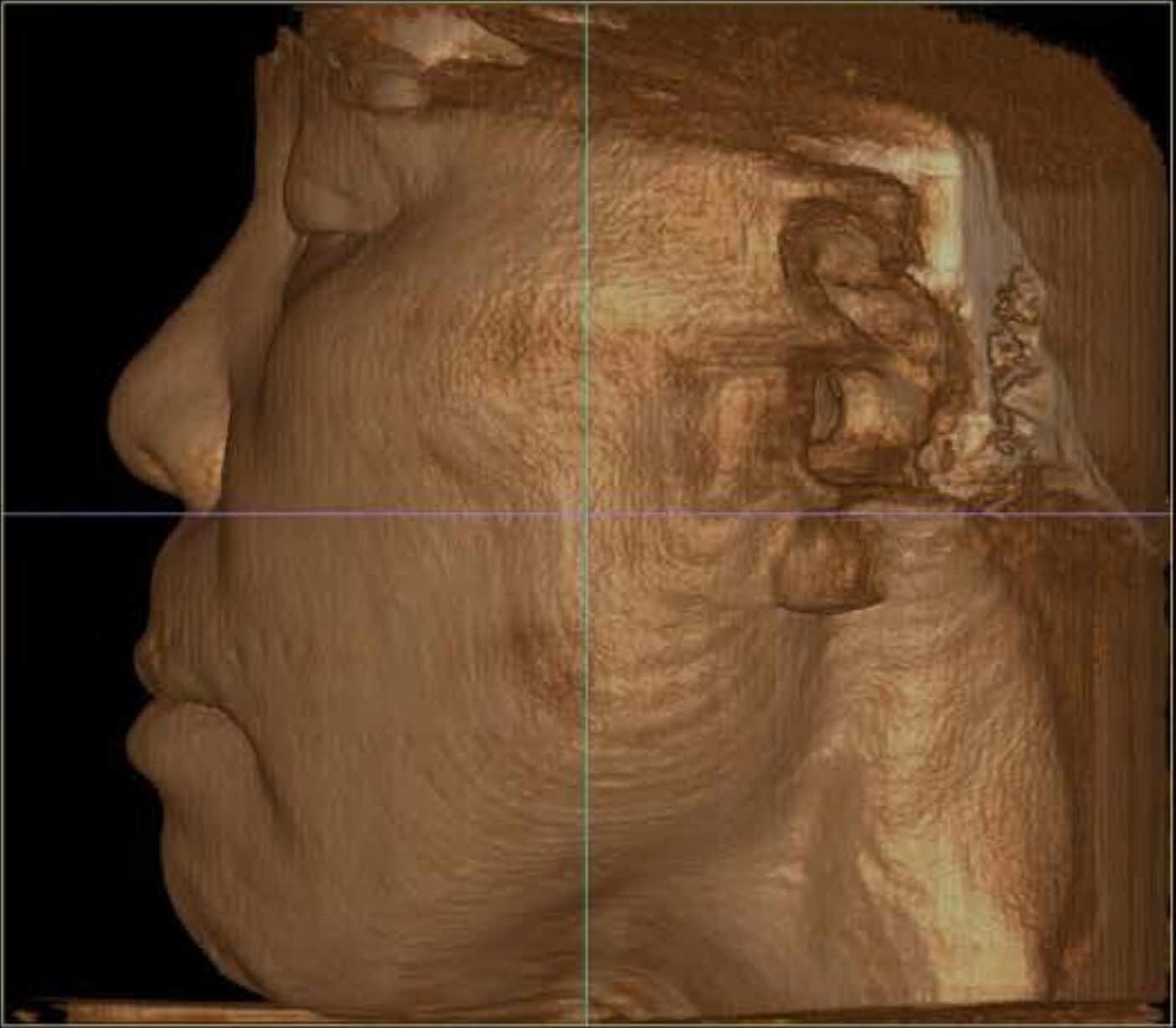
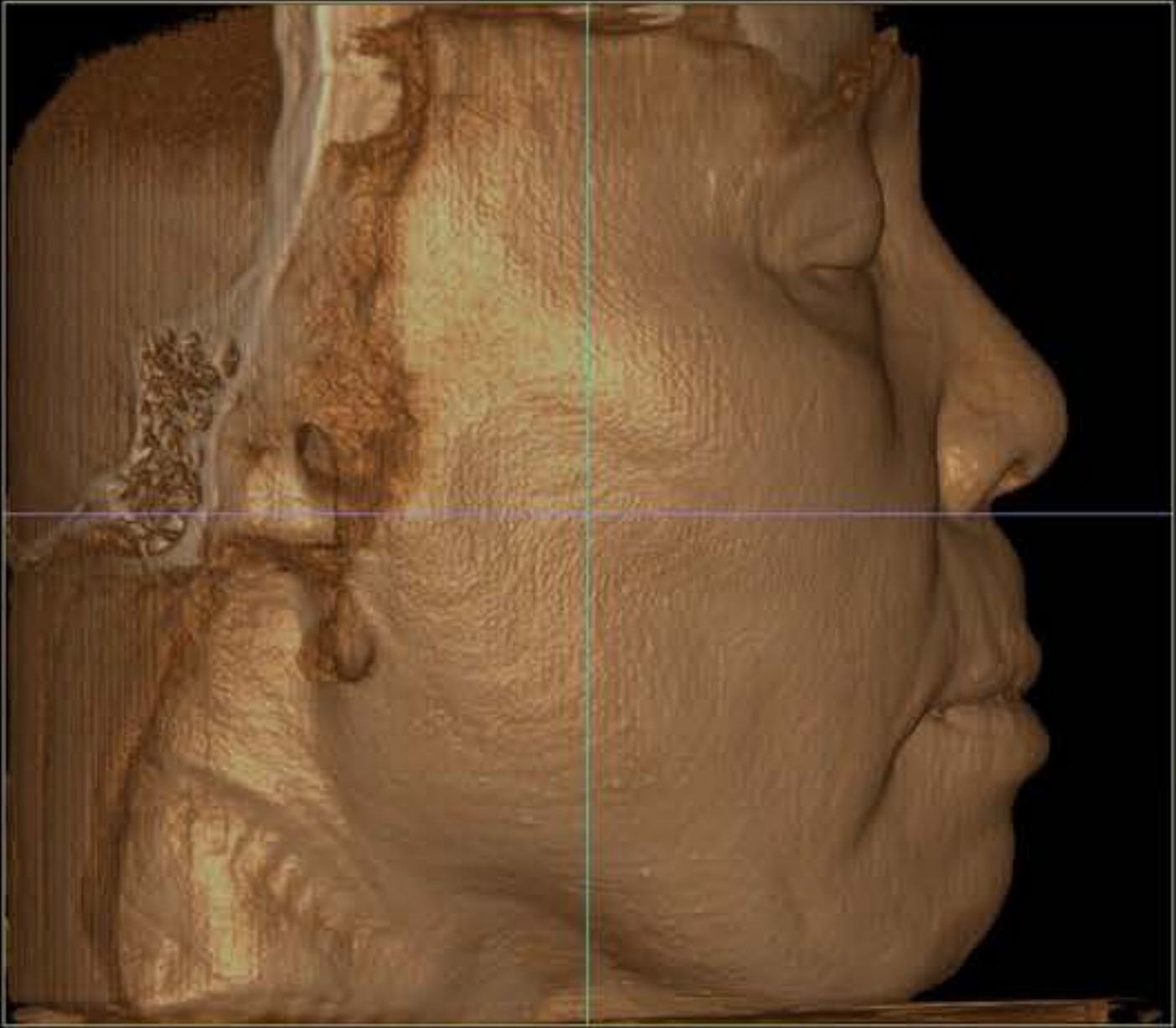
Default

Capture Group

Reset

Ceph Mark

All



CT Viewer

Patient Information

노영래

i

ID

11604

Age

65

Exam date

20250221

Virtual Ceph

Select Mark

Create Ceph

Create YTI

Occlusal Plane(OP)

AUTO

Render Type

Hard Type

Viewport

HU

SMS

Q

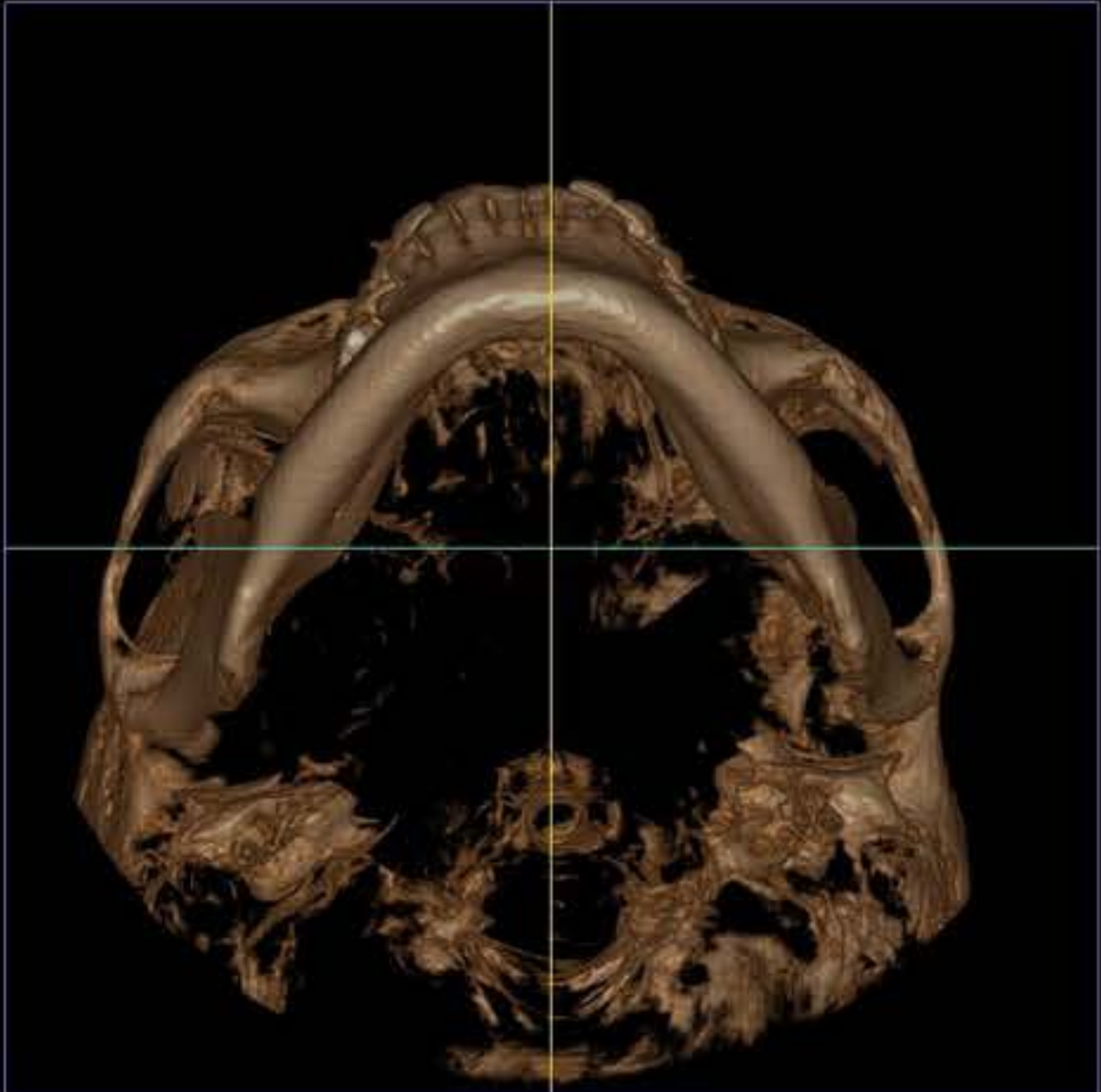
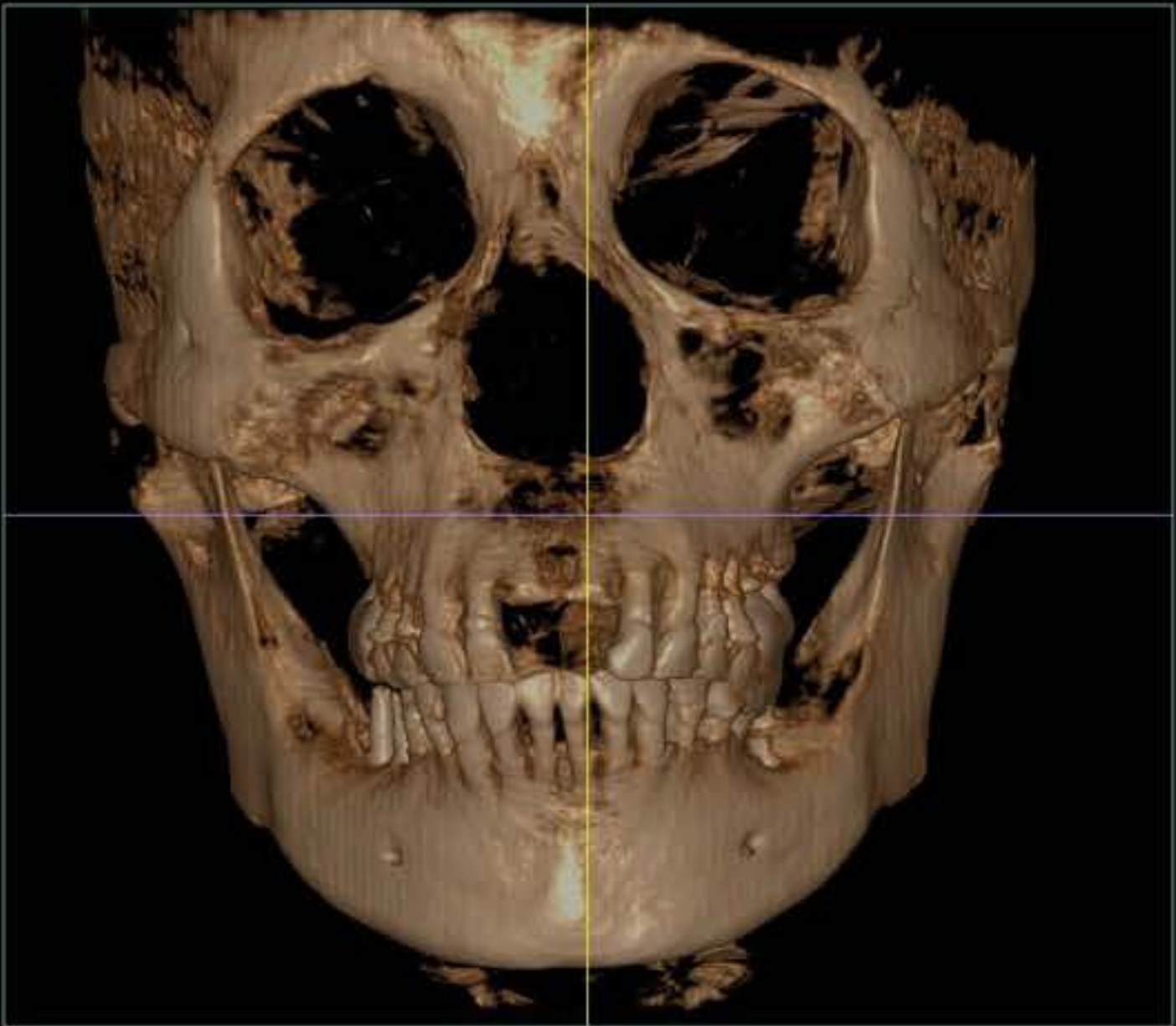
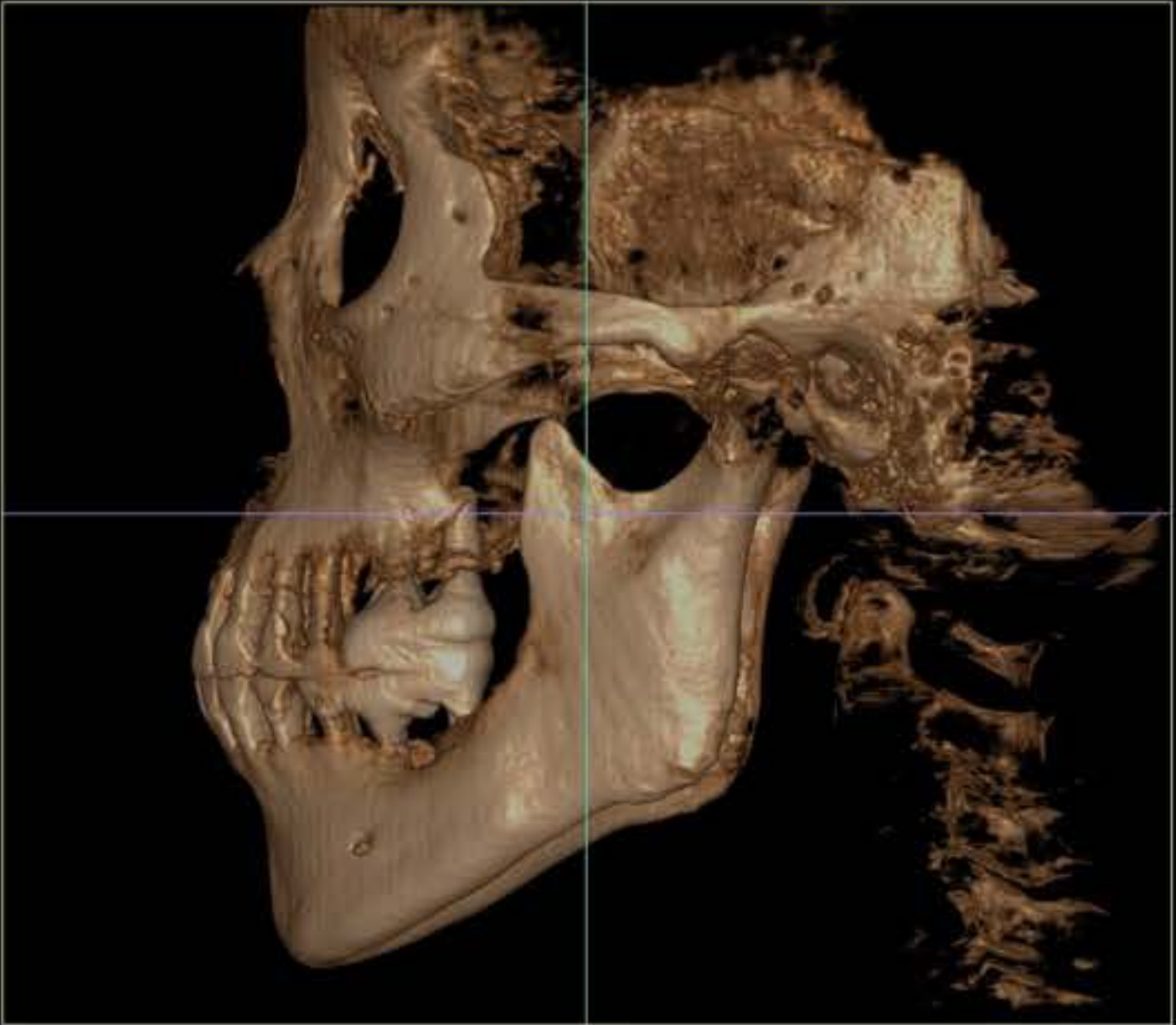
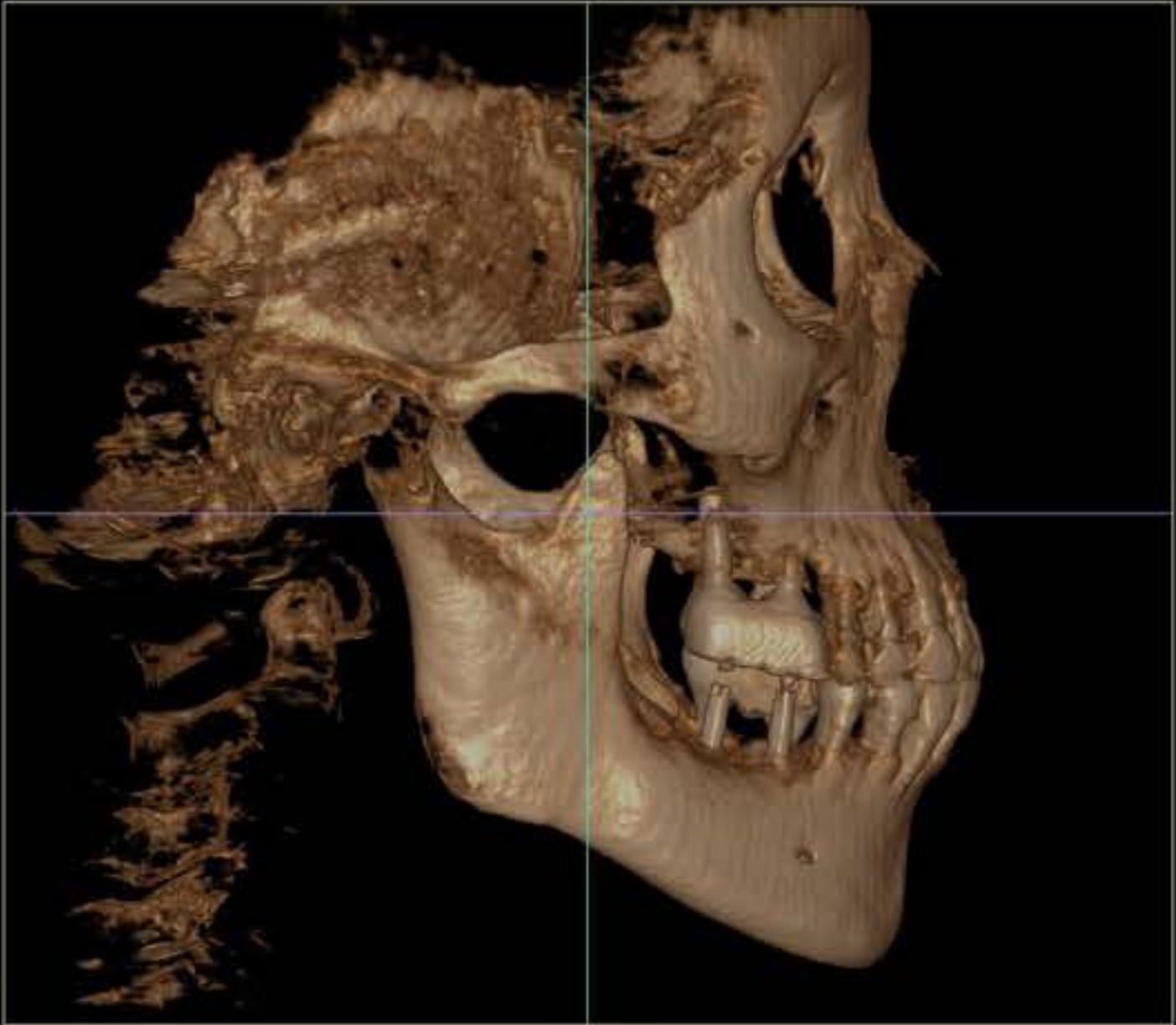Default

Capture Group

Reset

Ceph Mark

All



CT Viewer

Patient Information

노영래

ID11604

Age65

Exam.date20250221

Virtual Ceph

Select Mark

Create Ceph

Create YTI

Occlusal Plane(OP)

AUTO

Landmark Mode

Plane Unlock

Render Type

Hard Type

Viewport

HU

1000

10

Q

Default

Capture Group

Reset

Ceph Mark

All

ANS-PNS Plane

Occlusal Plane

[ANS-Portion] - [Occlusal] Plane : 0.4 deg

Orbitale Plane

Mid Suture Plane

CT Viewer

Patient Information

노영래

ID11604

Age65

Exam.date20250221

Virtual Ceph

Select Mark

Create Ceph

Create YTI

Occlusal Plane(OP)

AUTO

Landmark Mode

Plane Unlock

Render Type

Hard Type

Viewport

HU

2027

20

Q

Default

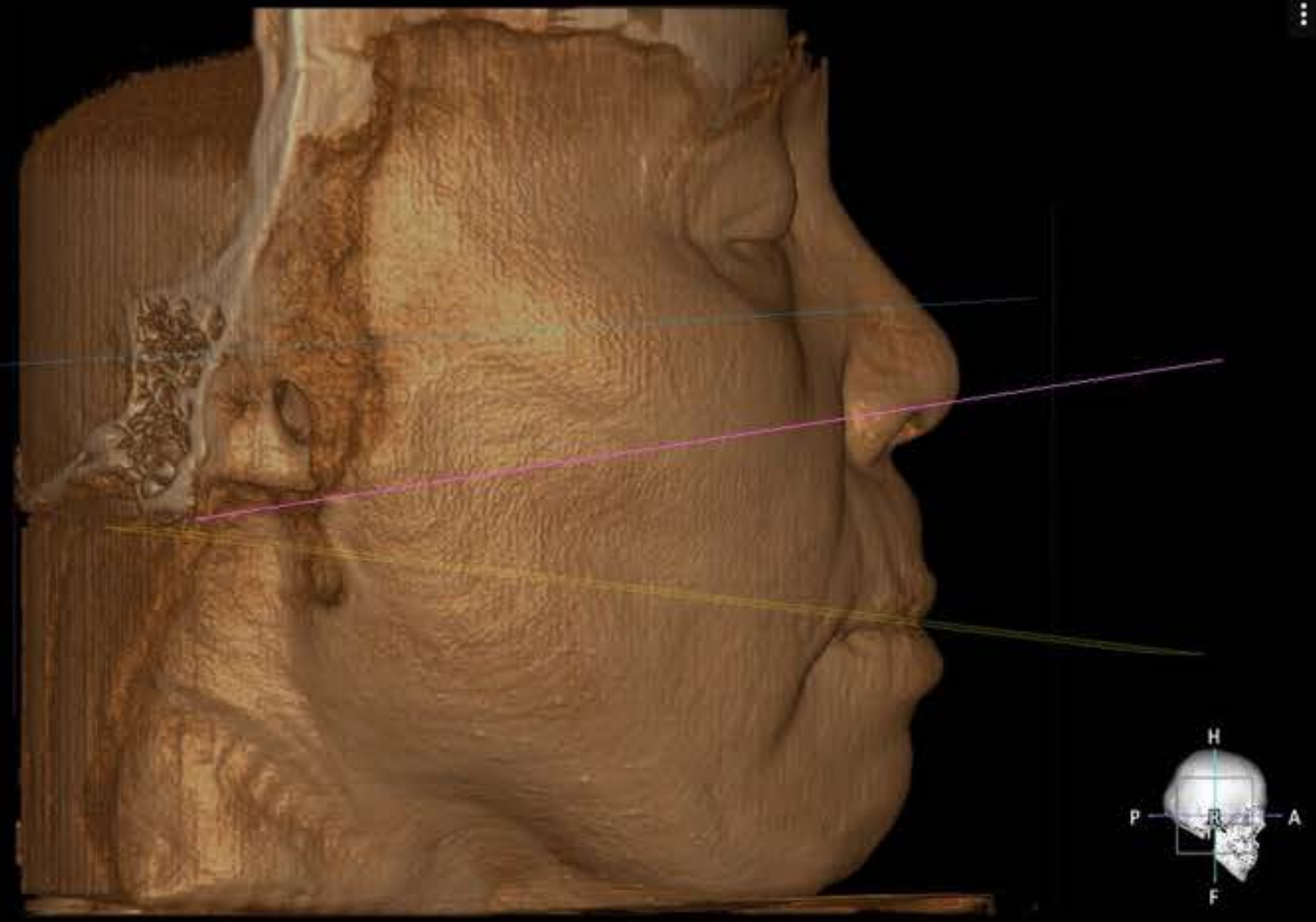
Capture Group

Reset

Ceph Mark

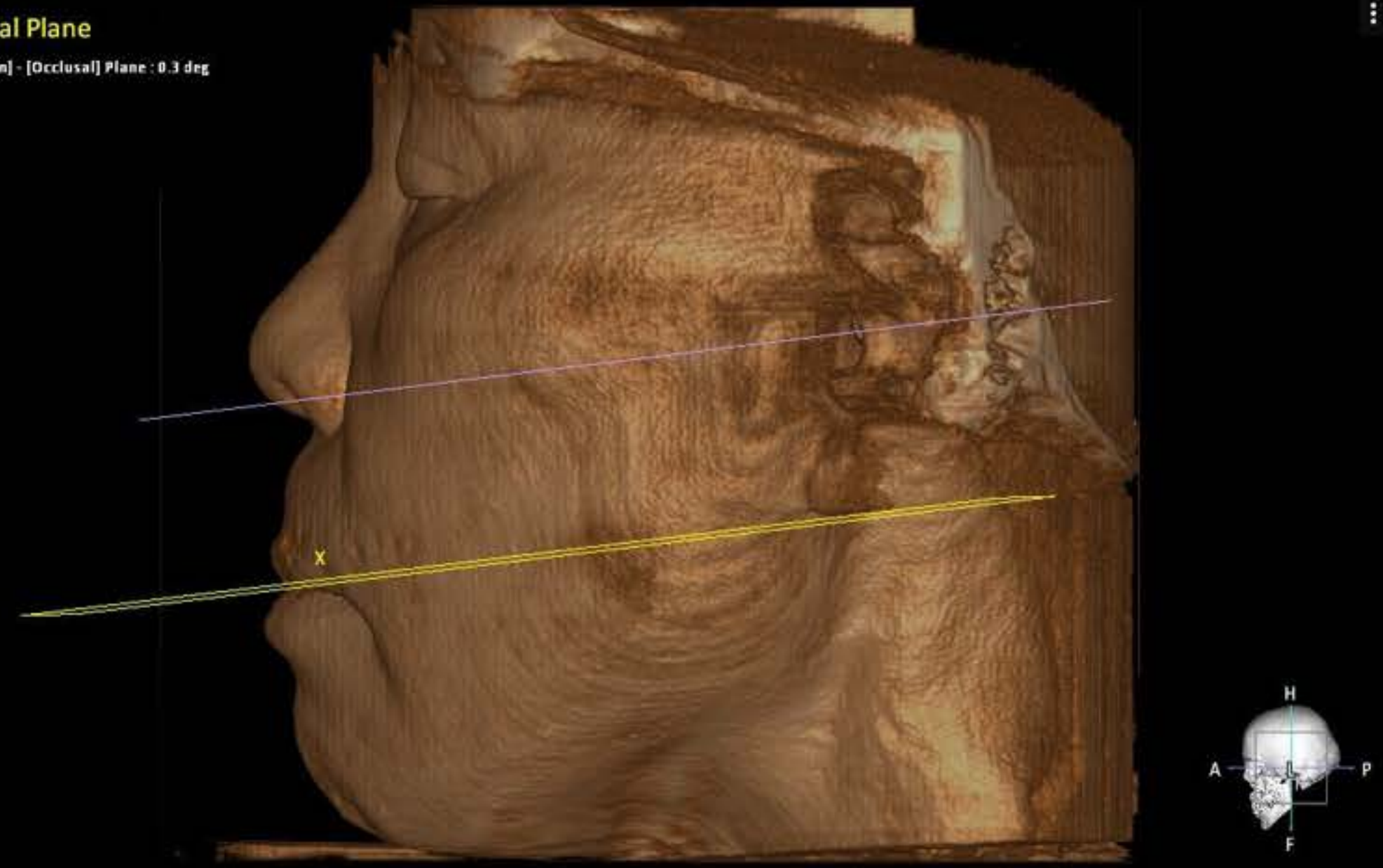
All

ANS-PNS Plane

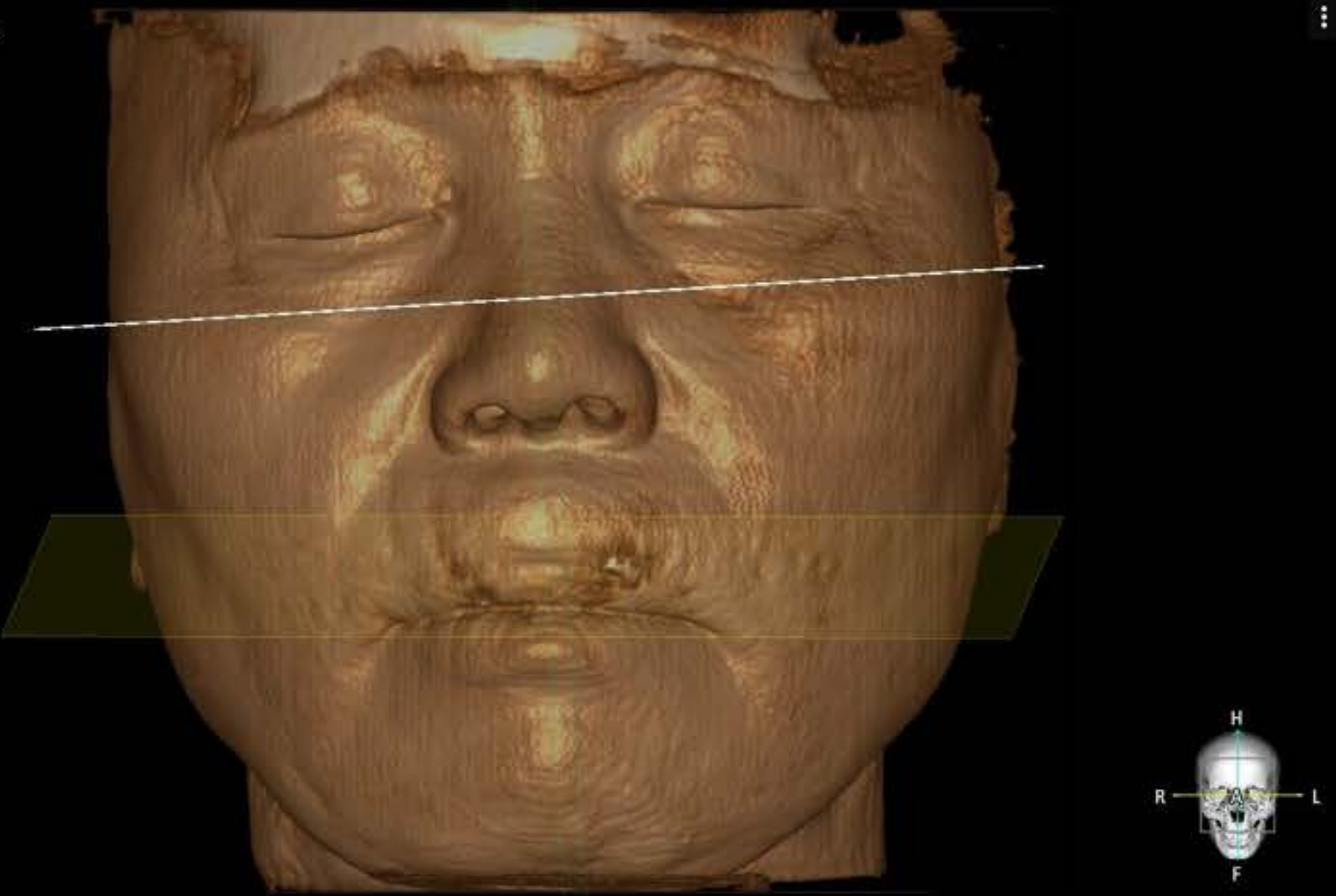


Occlusal Plane

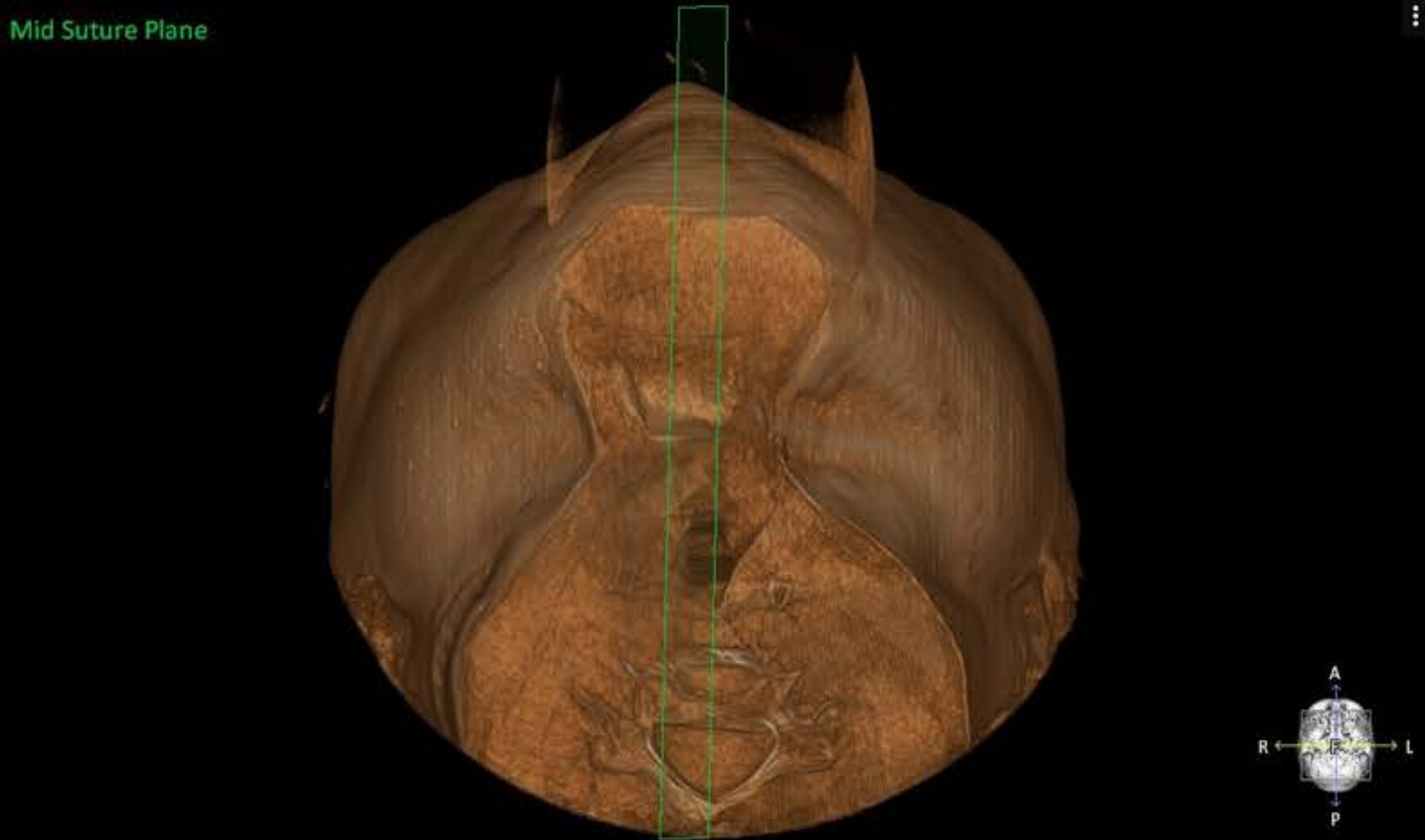
[ANS-Portion] - [Occlusal] Plane : 0.3 deg



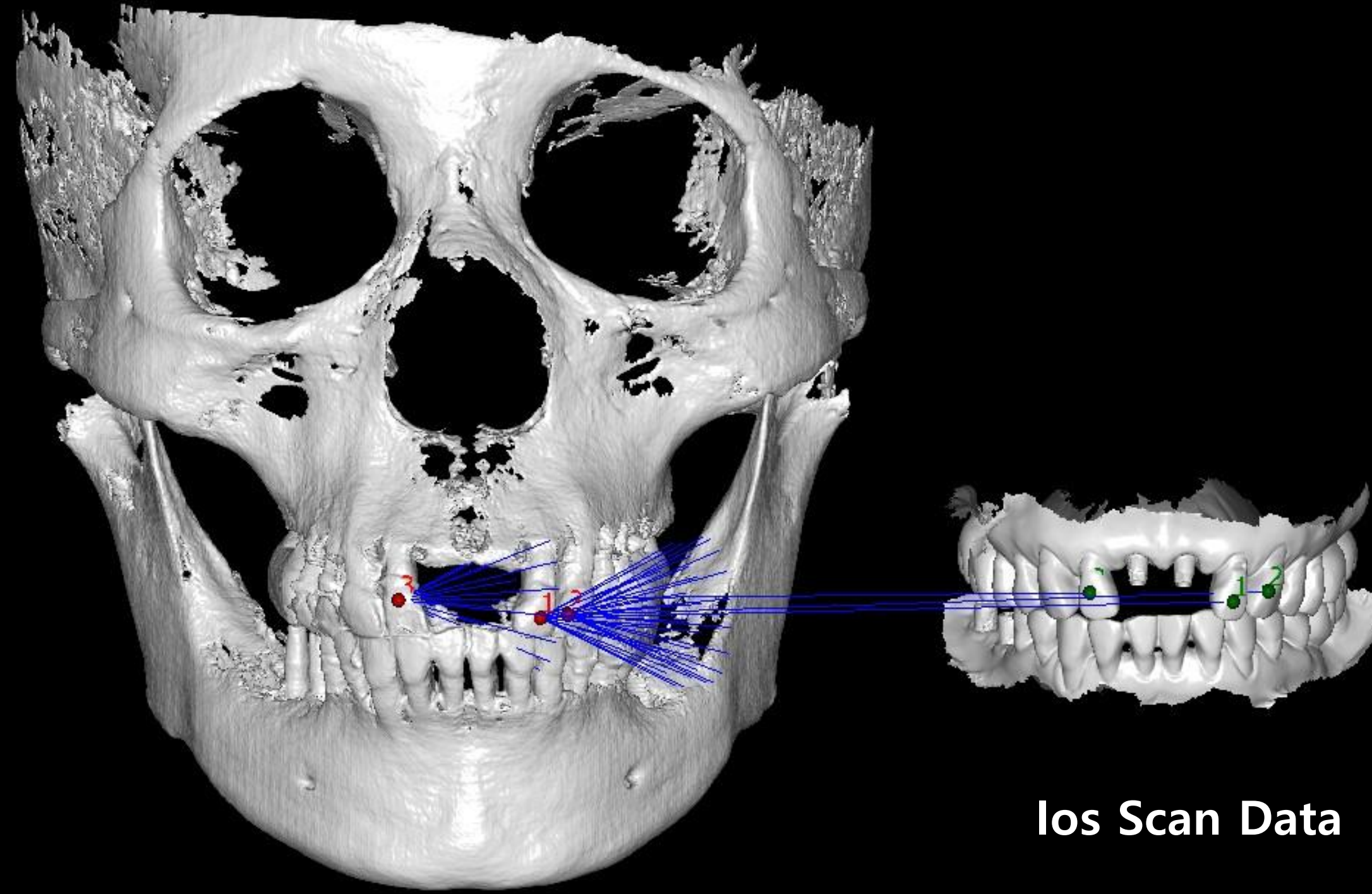
Orbitale Plane



Mid Suture Plane



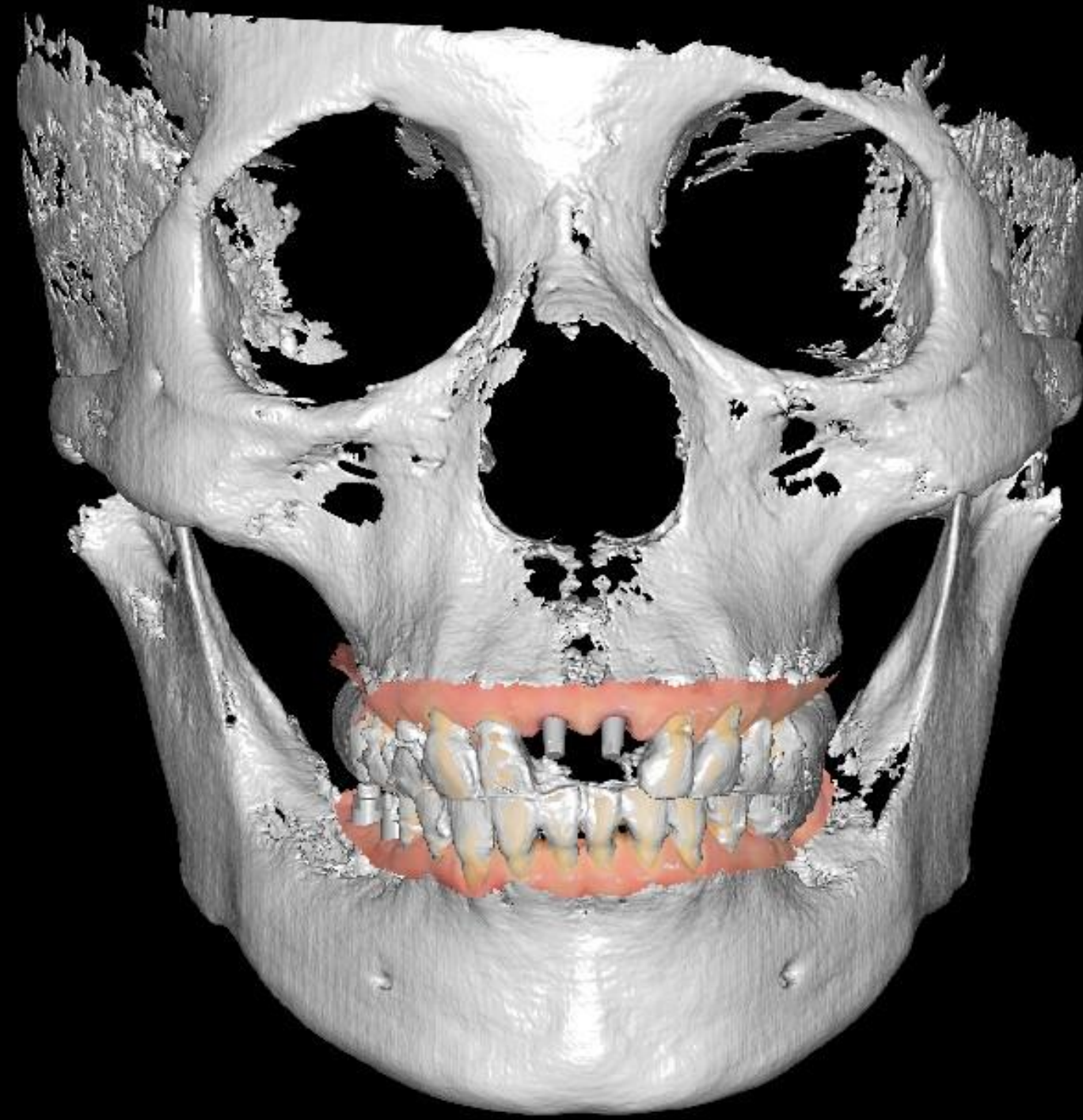Cad Data Stitching



Ios Scan Data

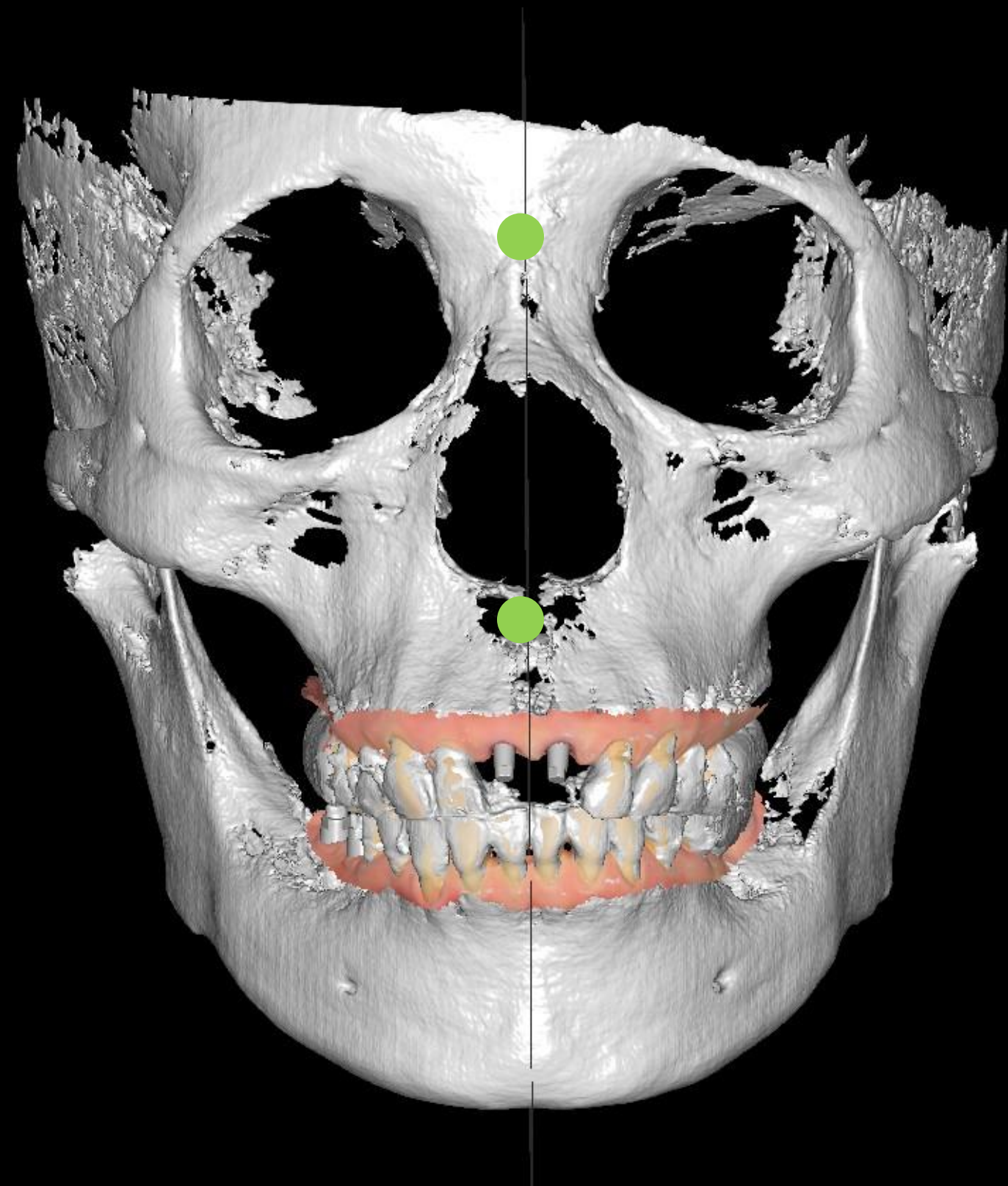
CT data Hard Tissue

Cad Data Stitching

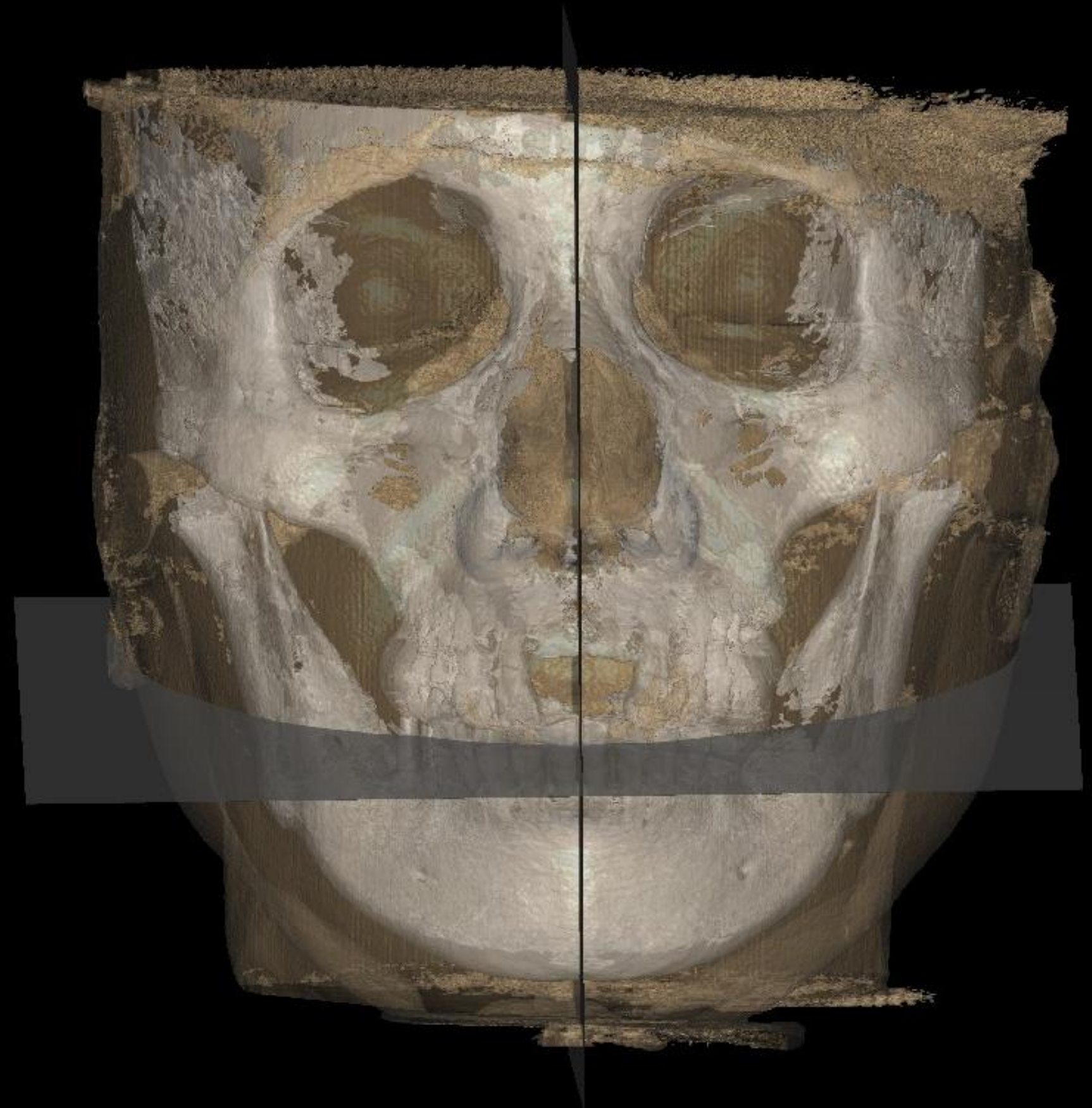


CT data Hard Tissue + Ios Scan Data

Cad Data Stitching

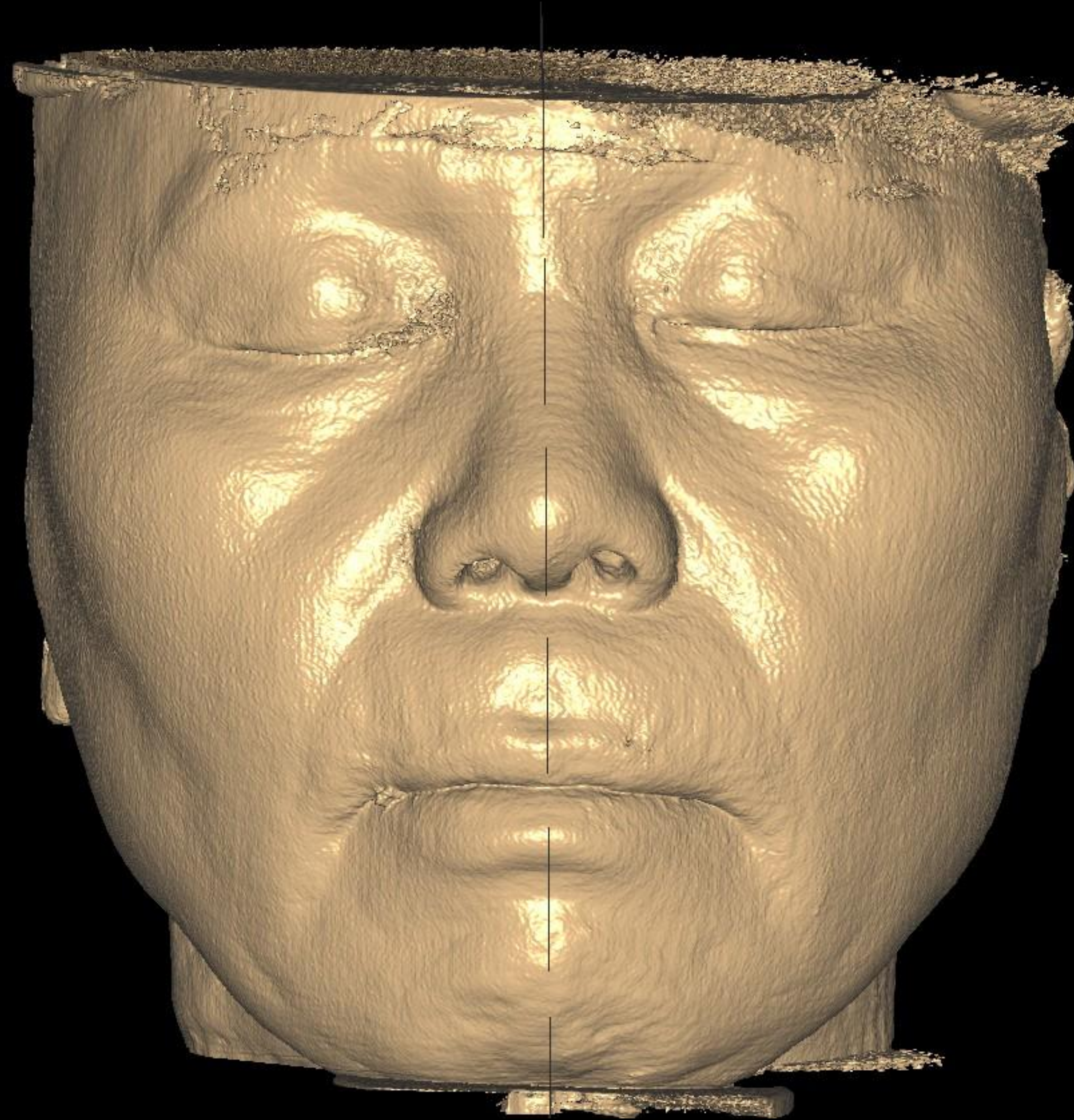


Rasion – Ans to Pns Midline

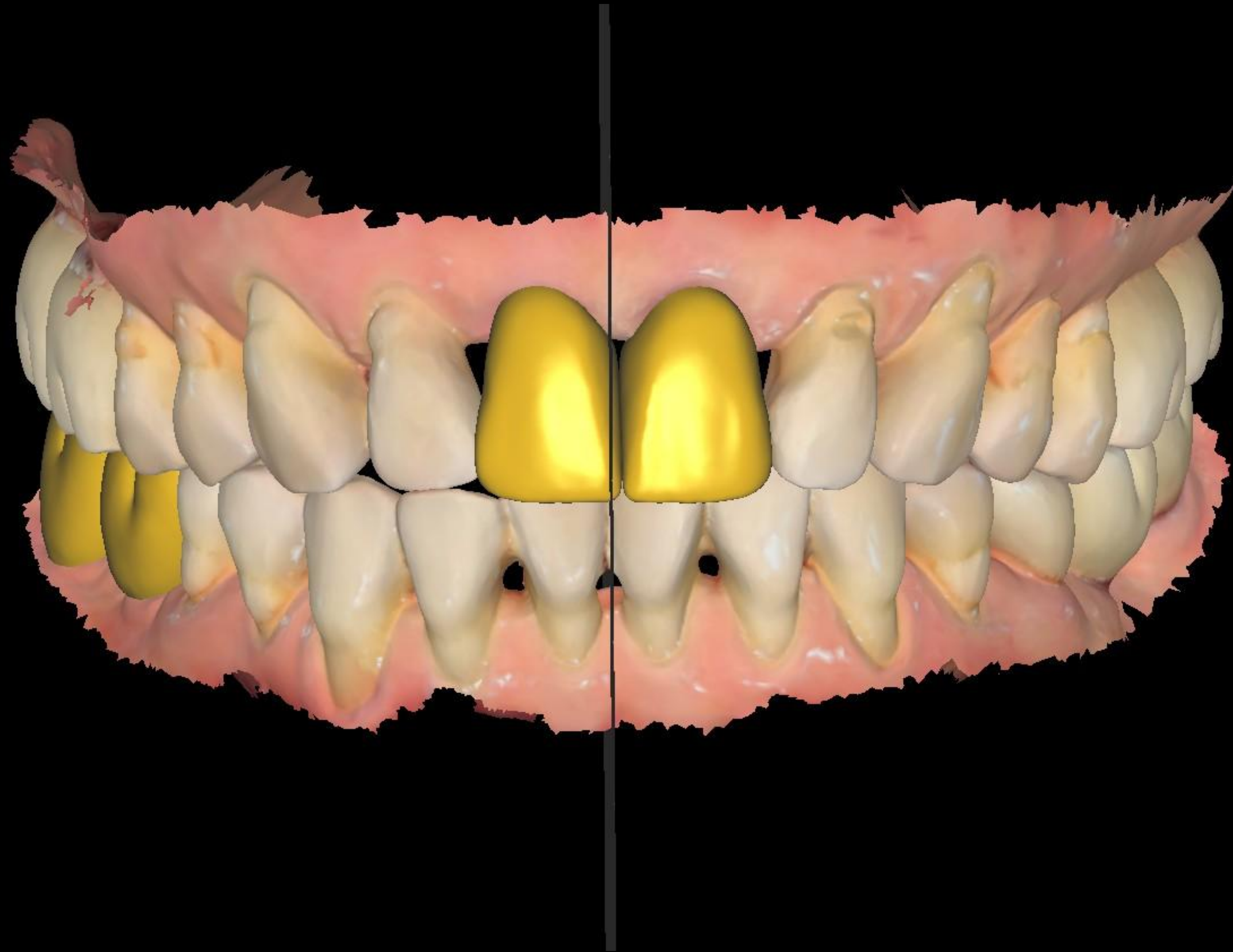


Ios data + CT data(AI Occlusal Plane)

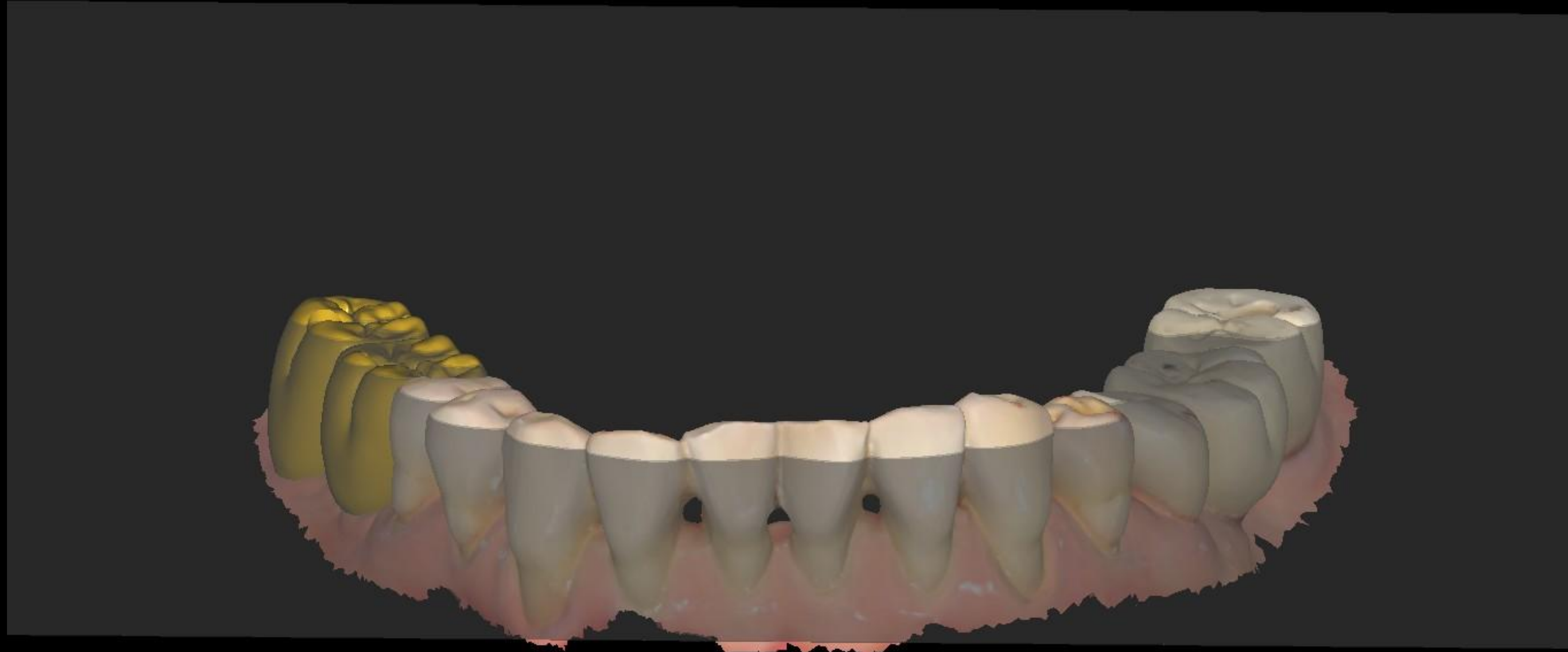Cad Design



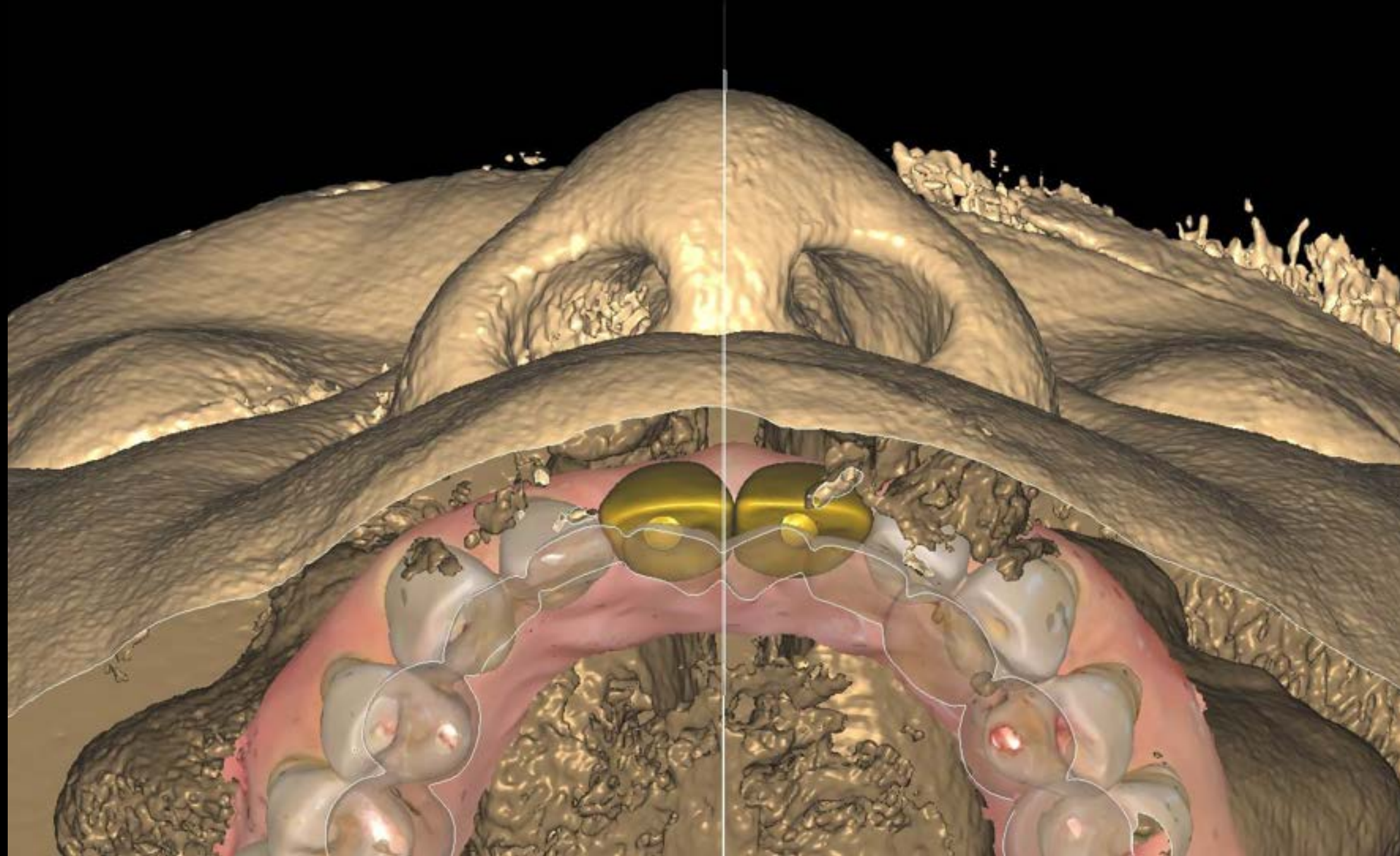
Cad Design



Cad Design

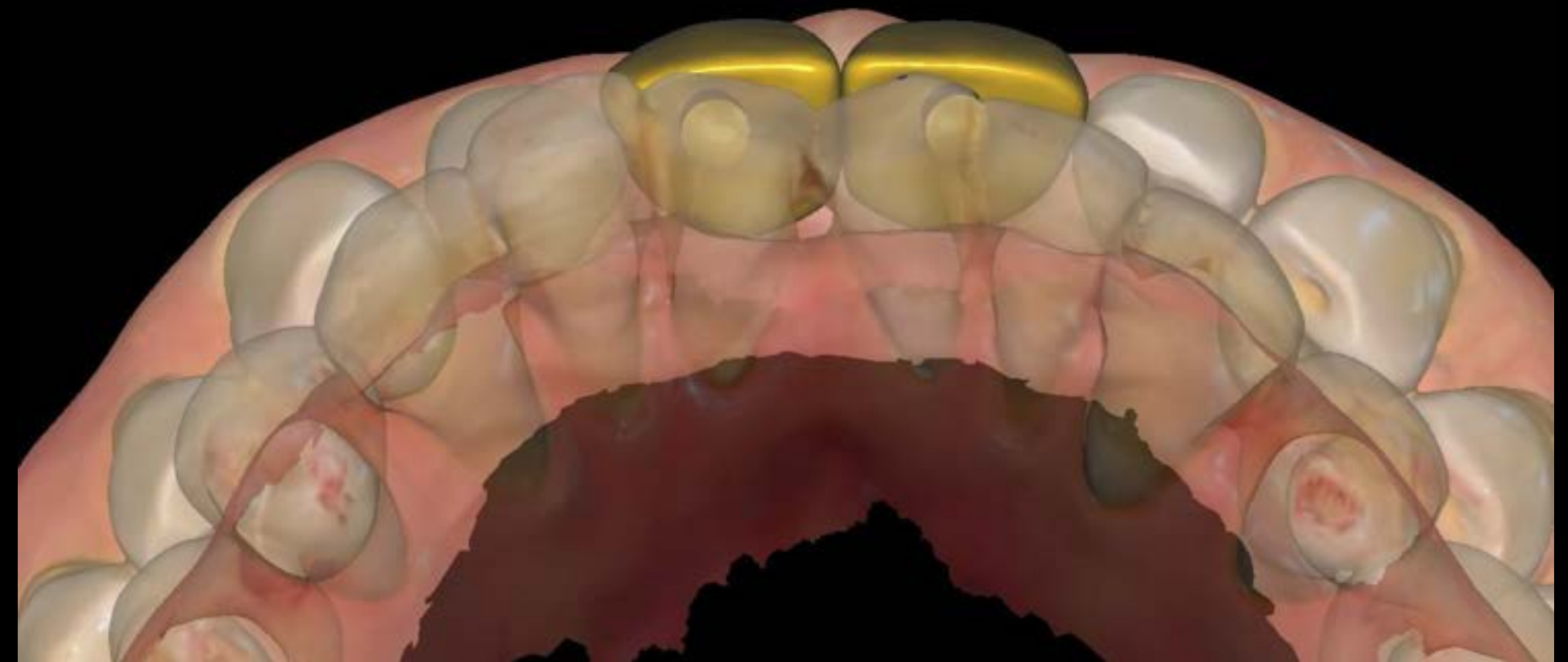
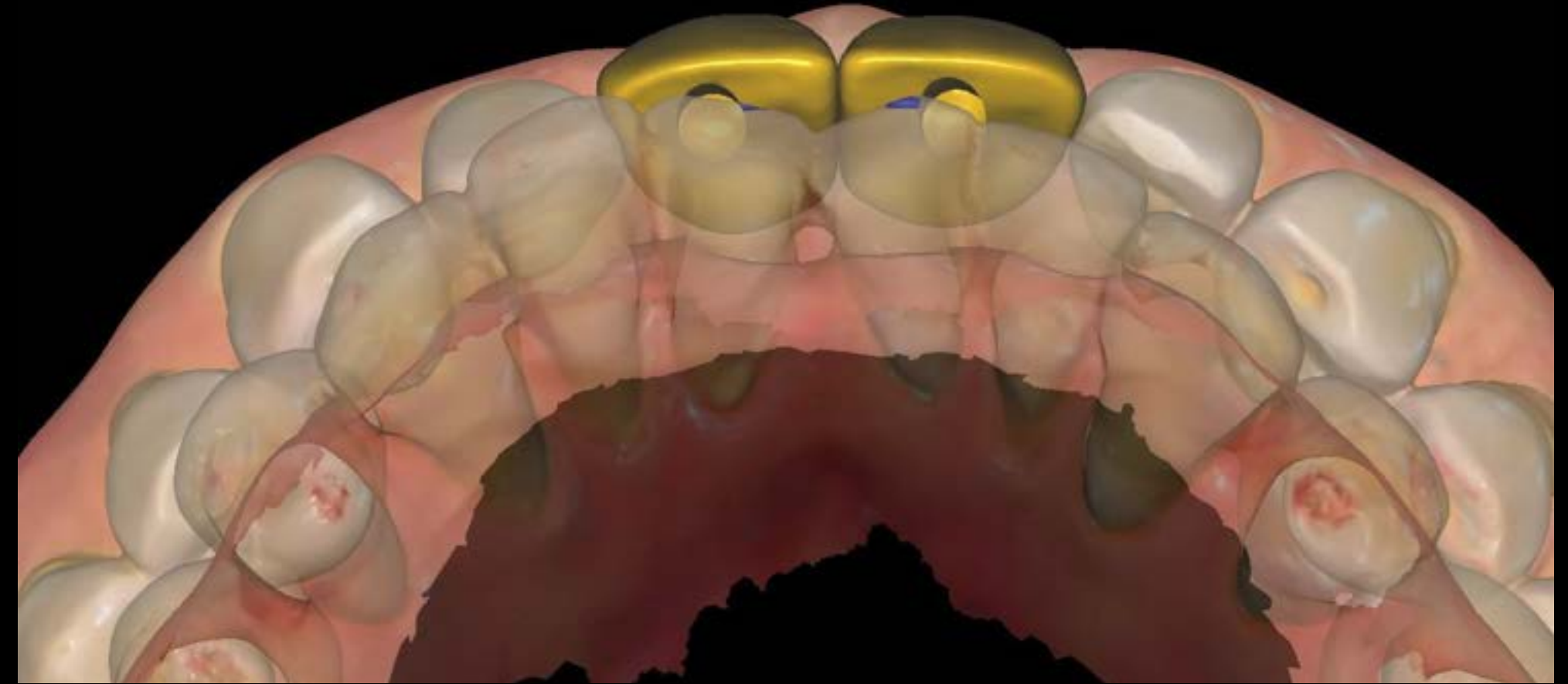
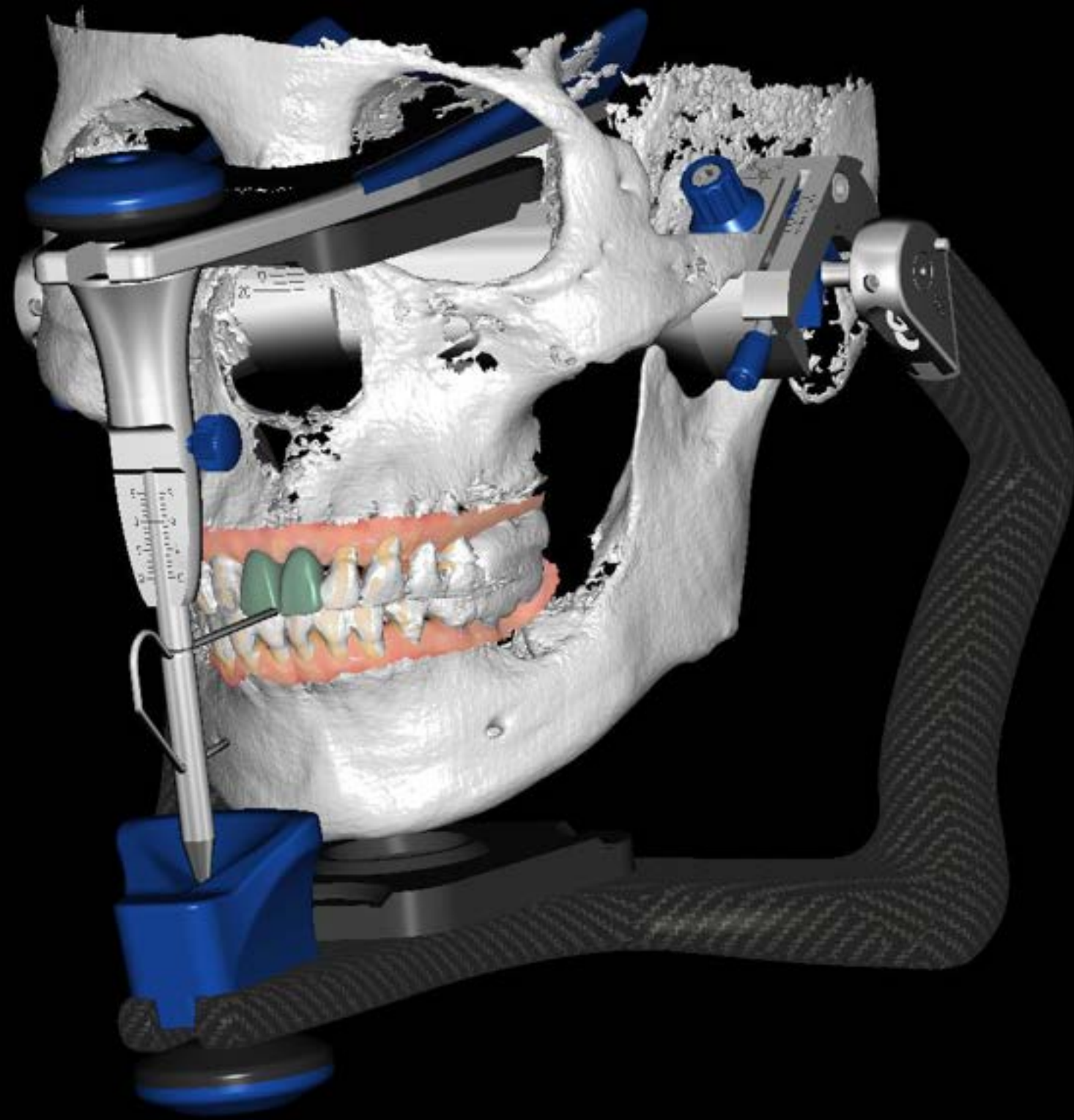


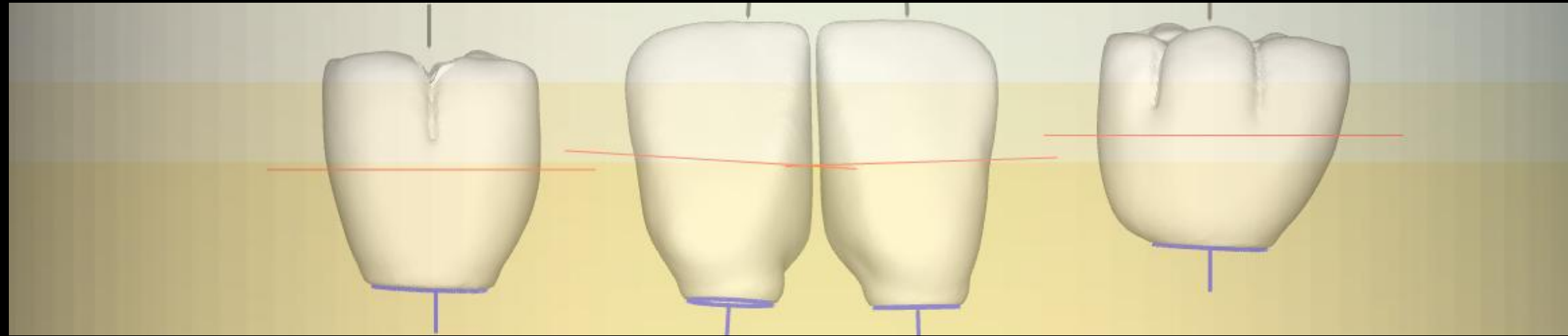
Cad Design



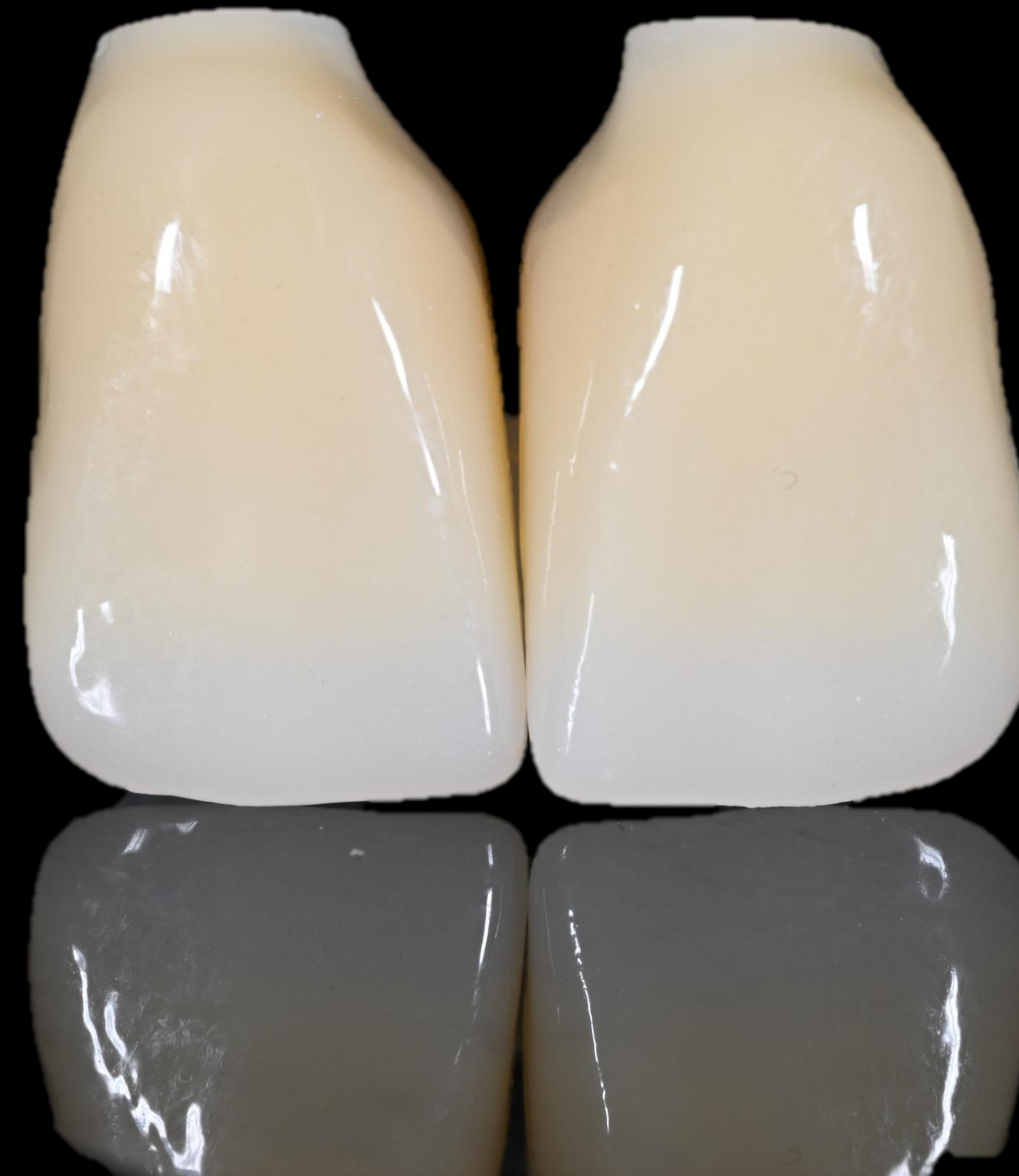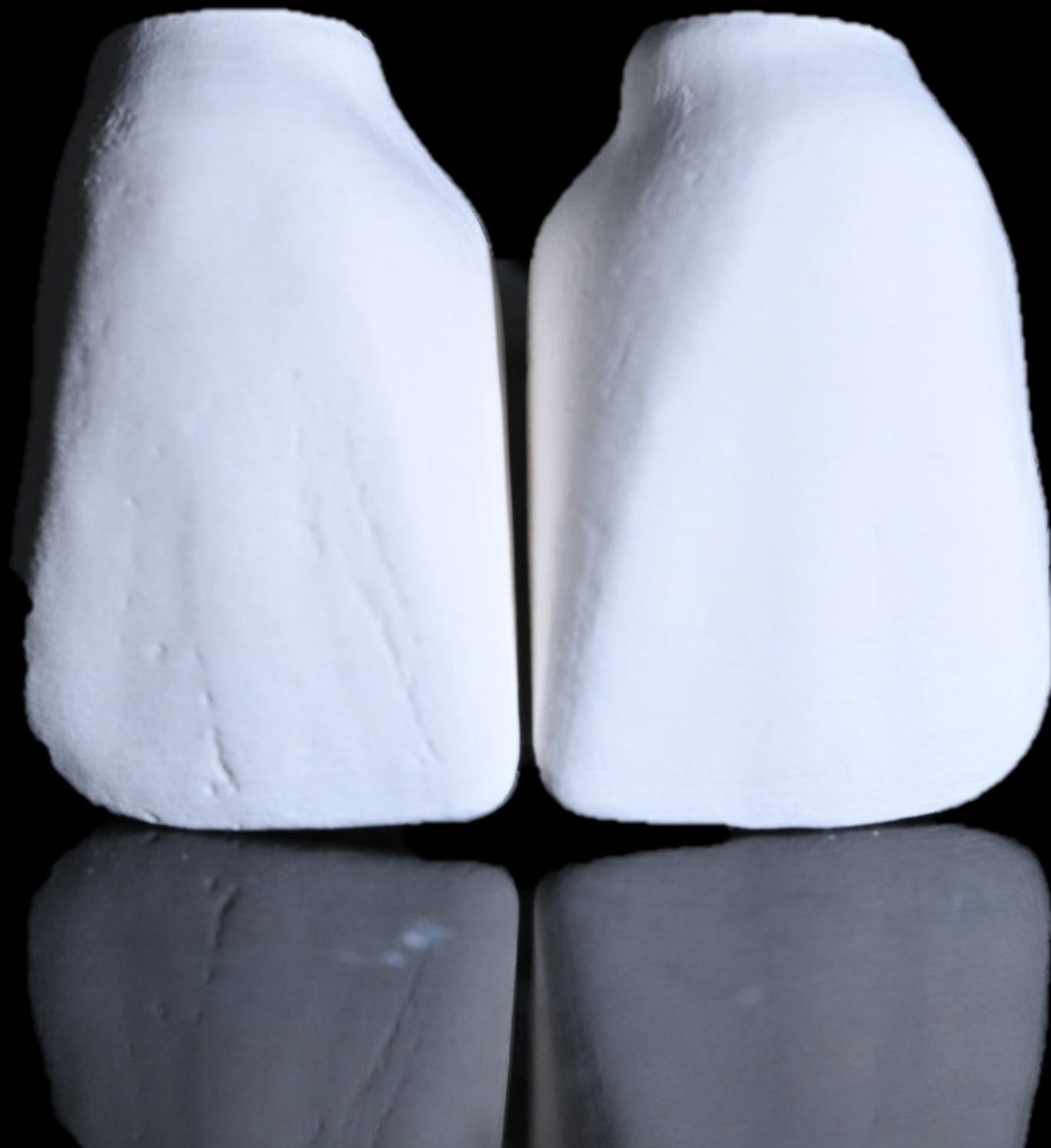Ti base Angled Abutment

Virtual Artricator



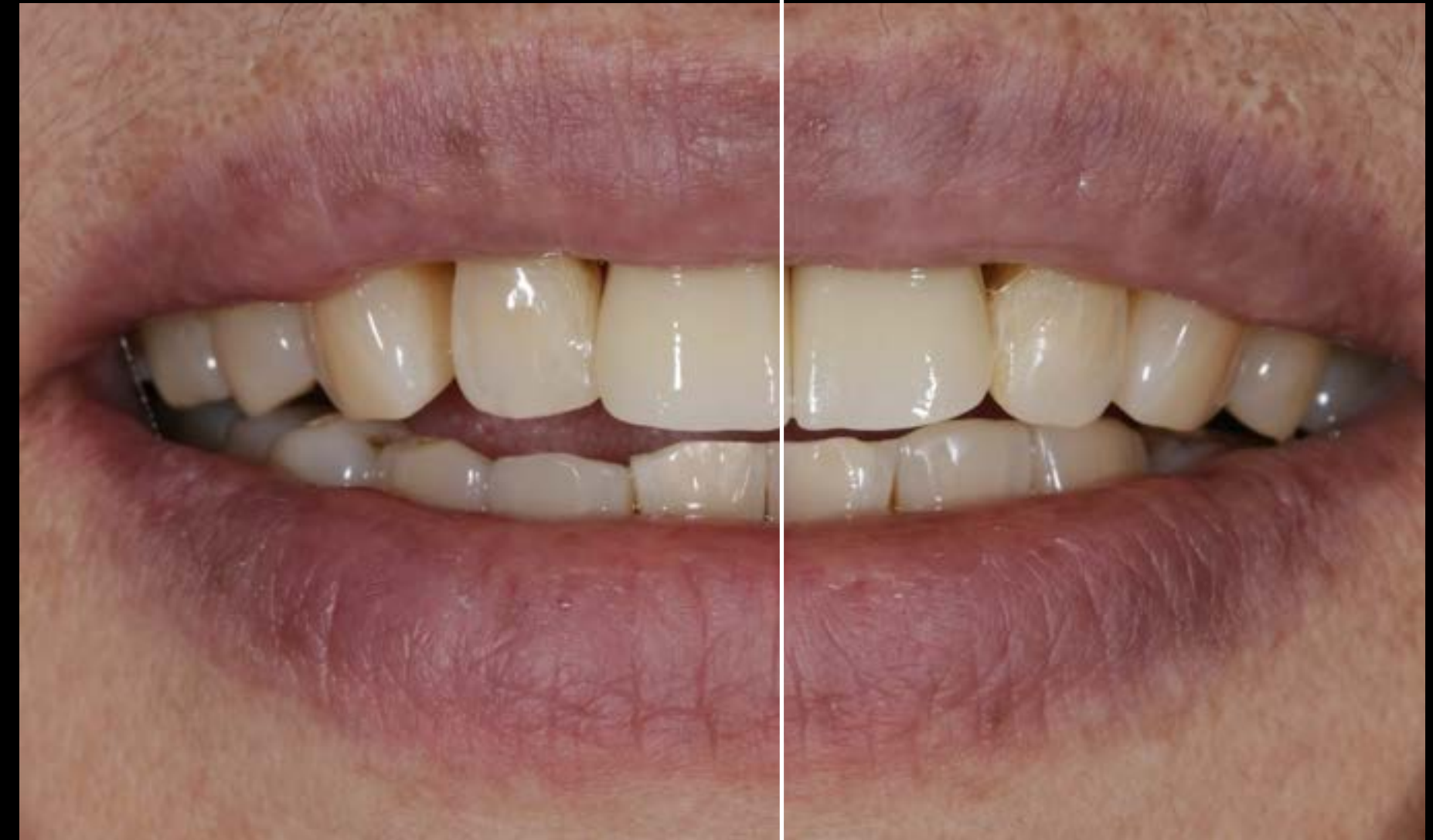
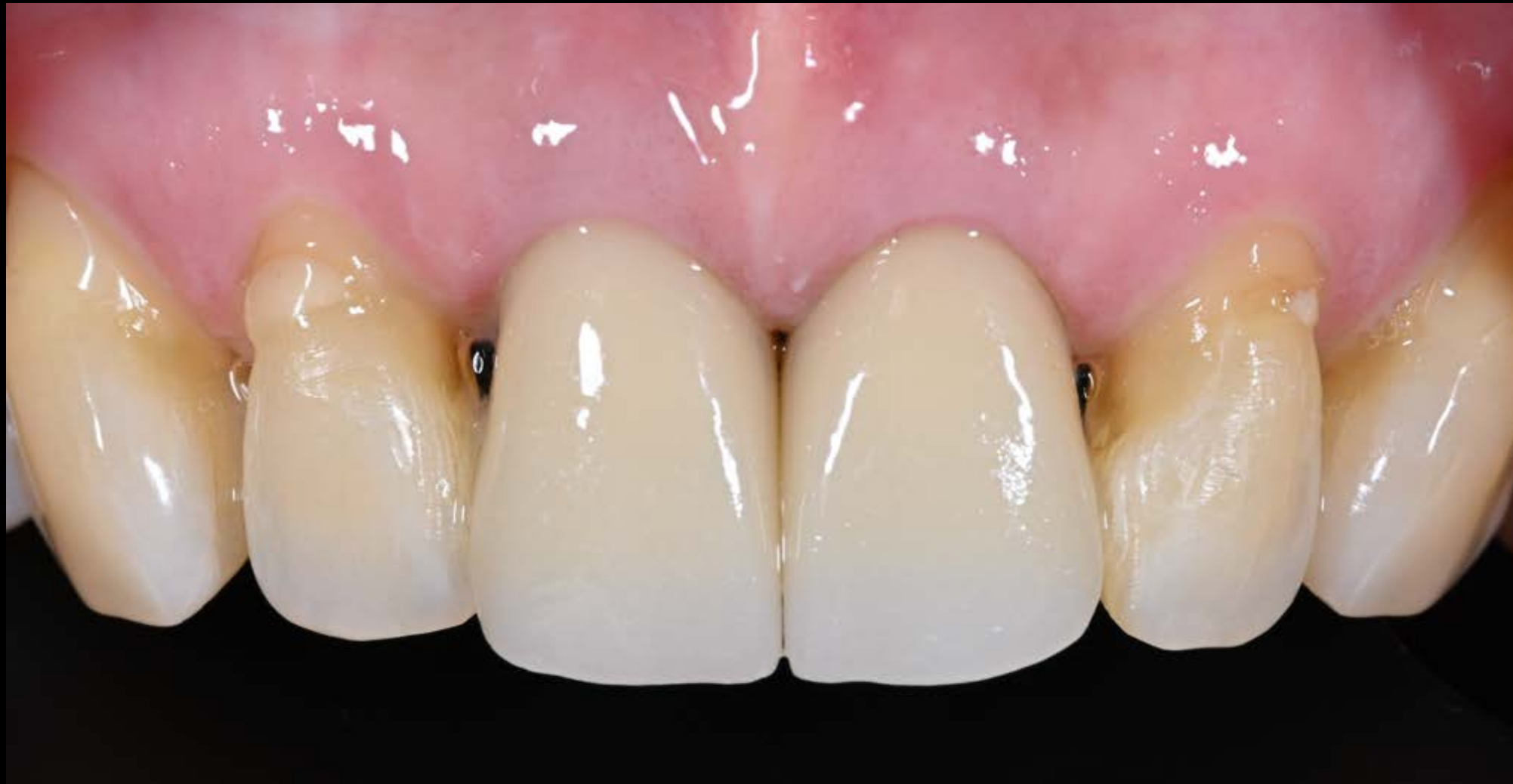
3layer A3.5 block



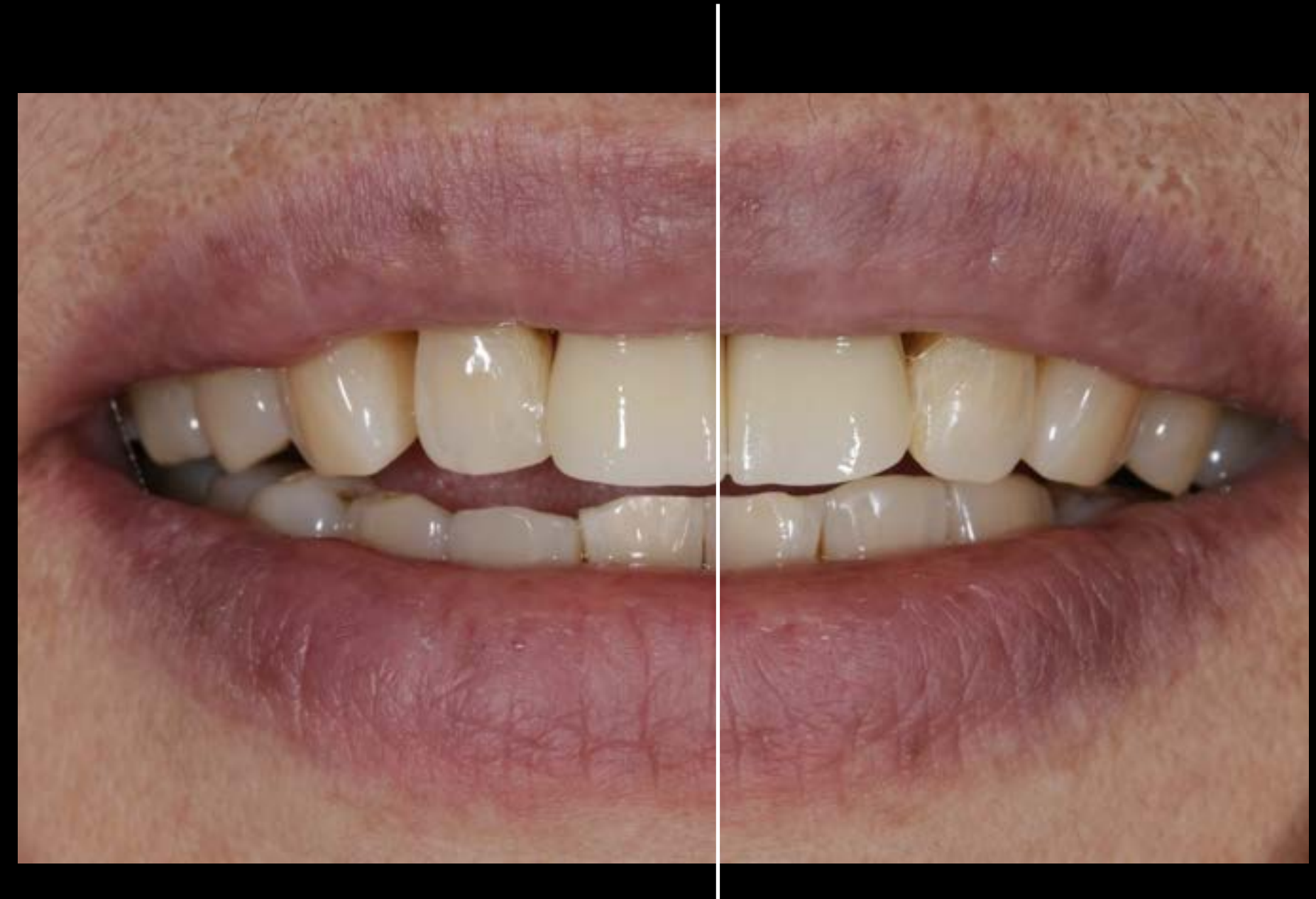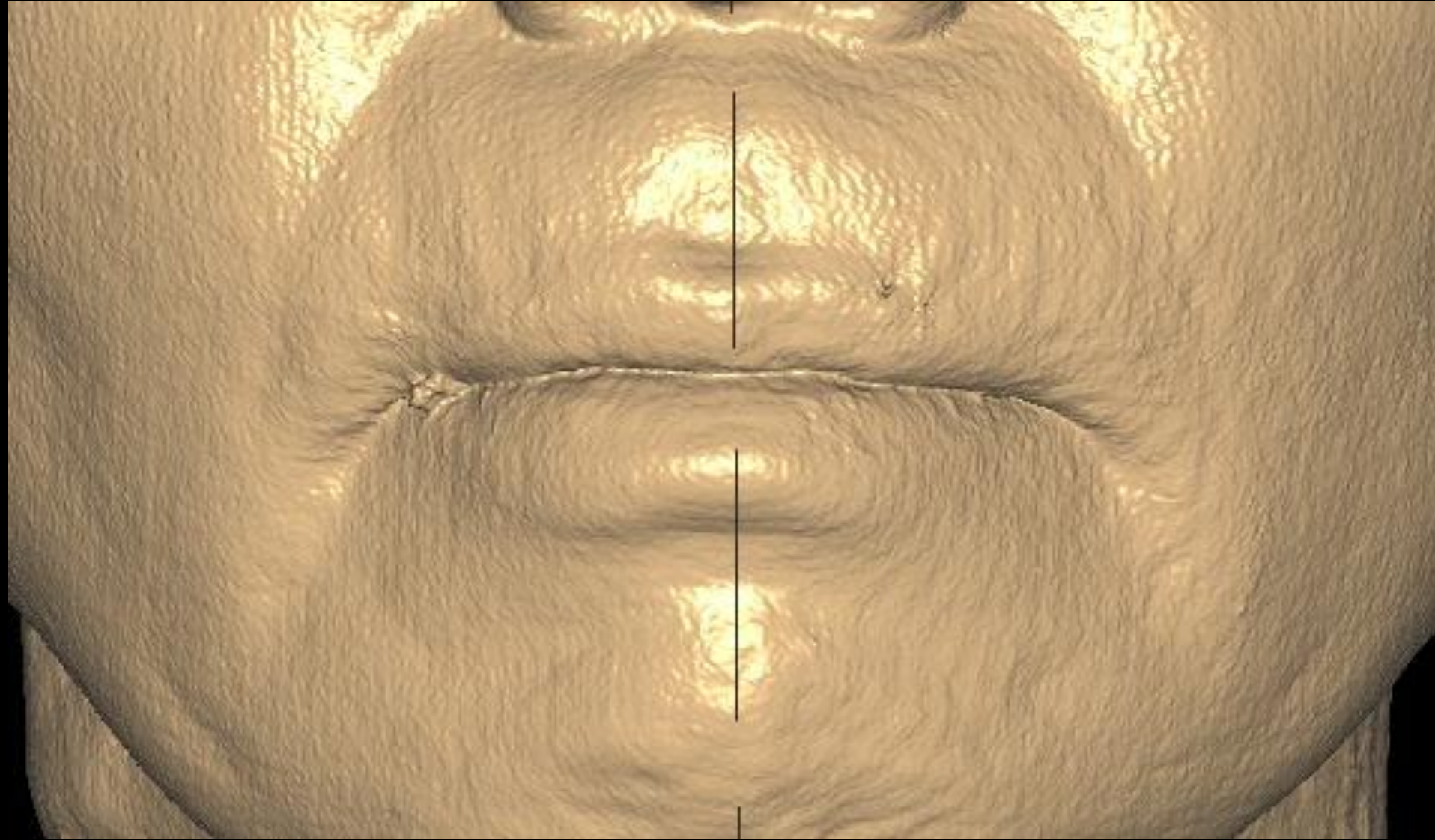
bright 3-Layer

Final Prosthesis



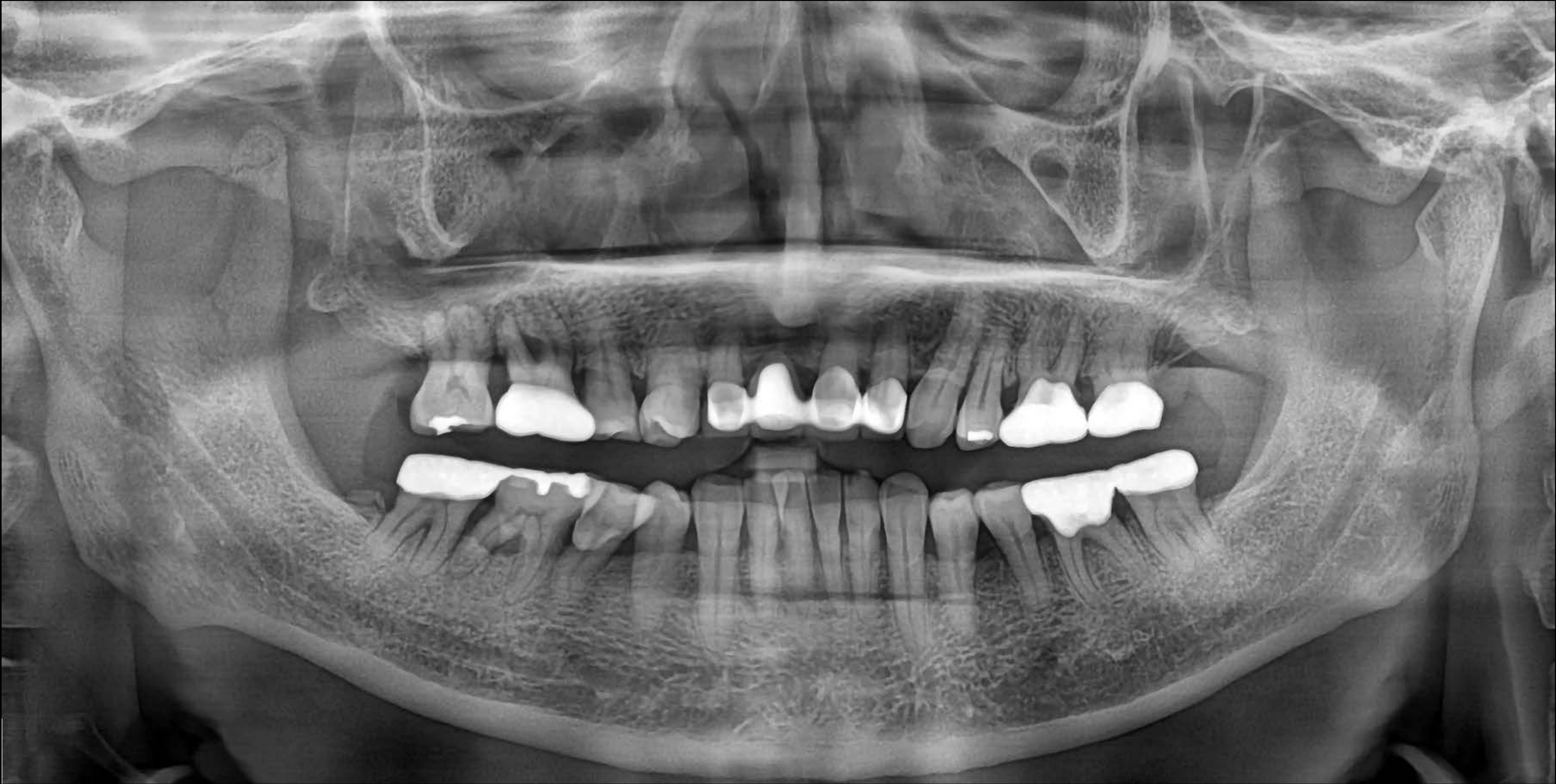Shining 3d Aoral Elite scan data use to model-less with
CT data (Ai Occlusal Plane)

Final Prosthesis

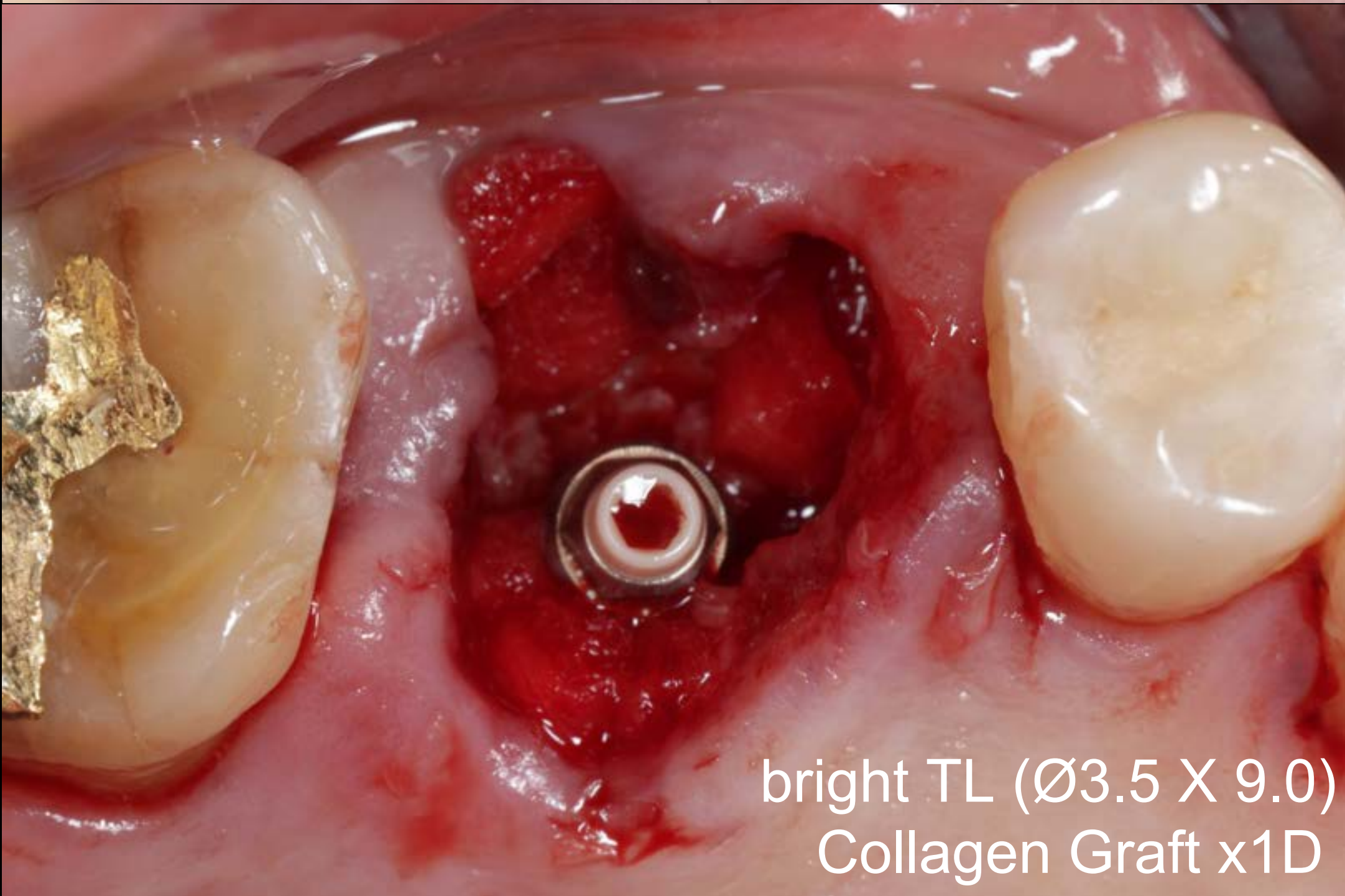
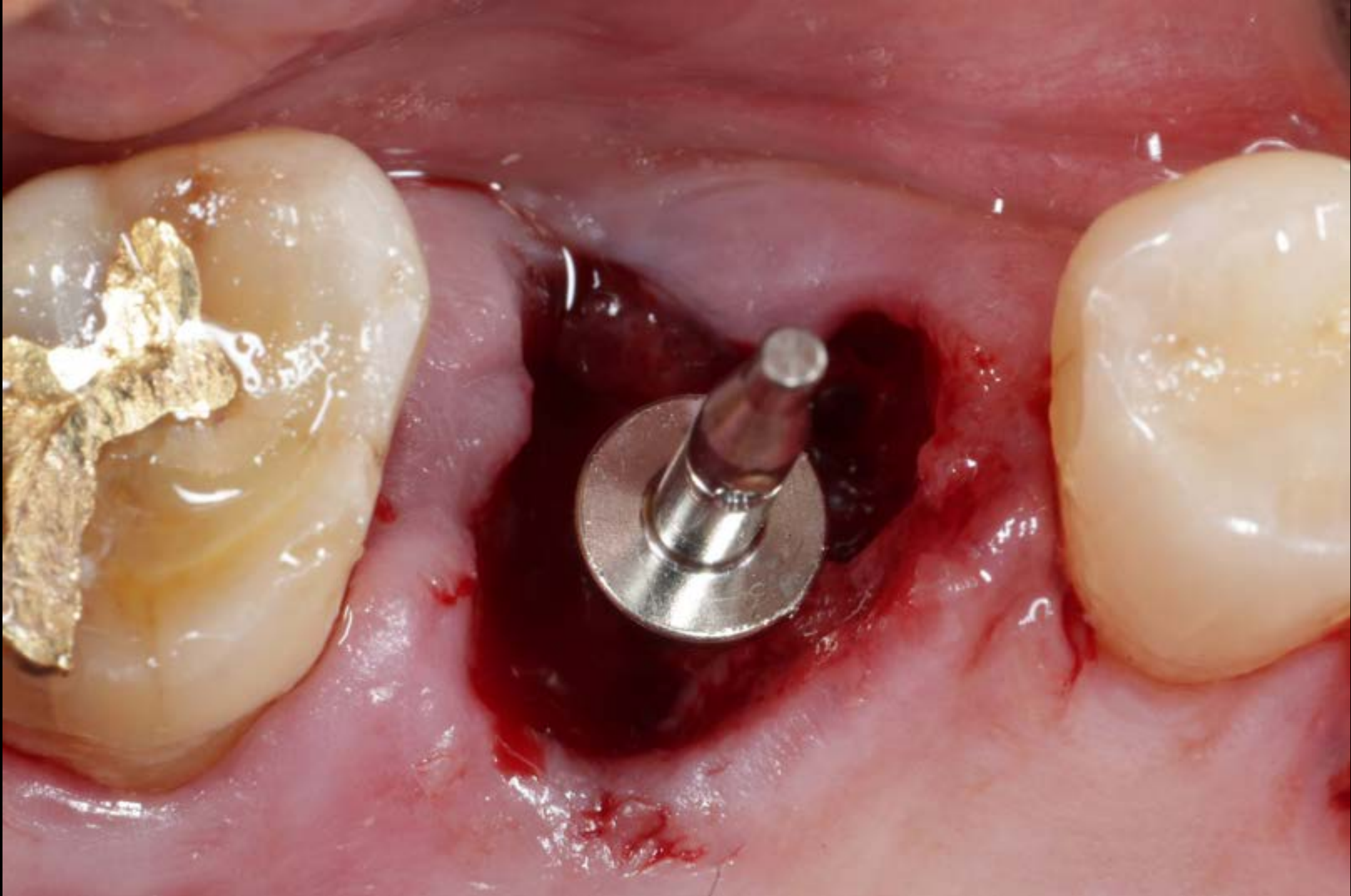
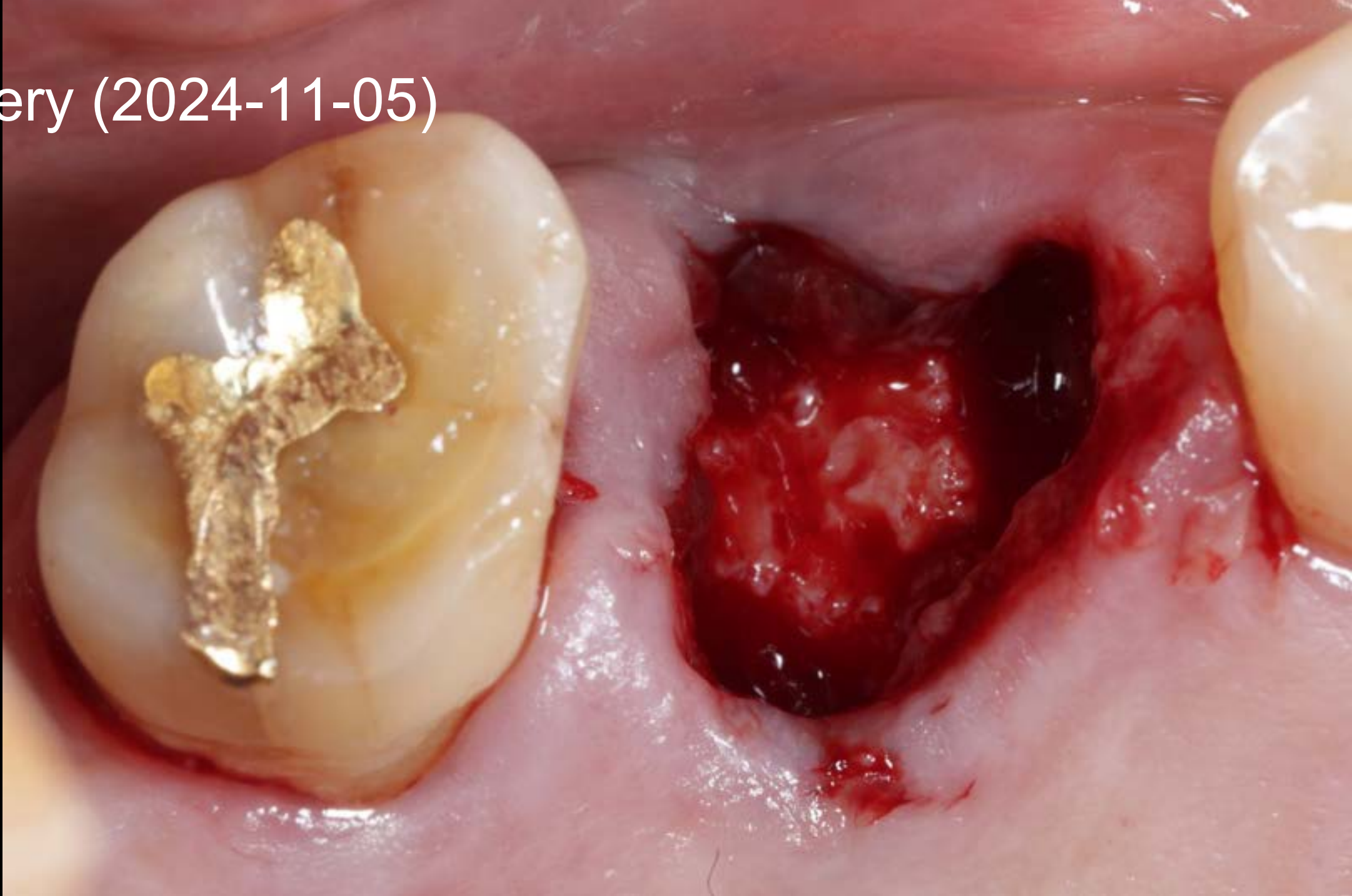


Shining 3d Aoral Elite scan data use to model-less with
CT data (Ai Occlusal Plane)

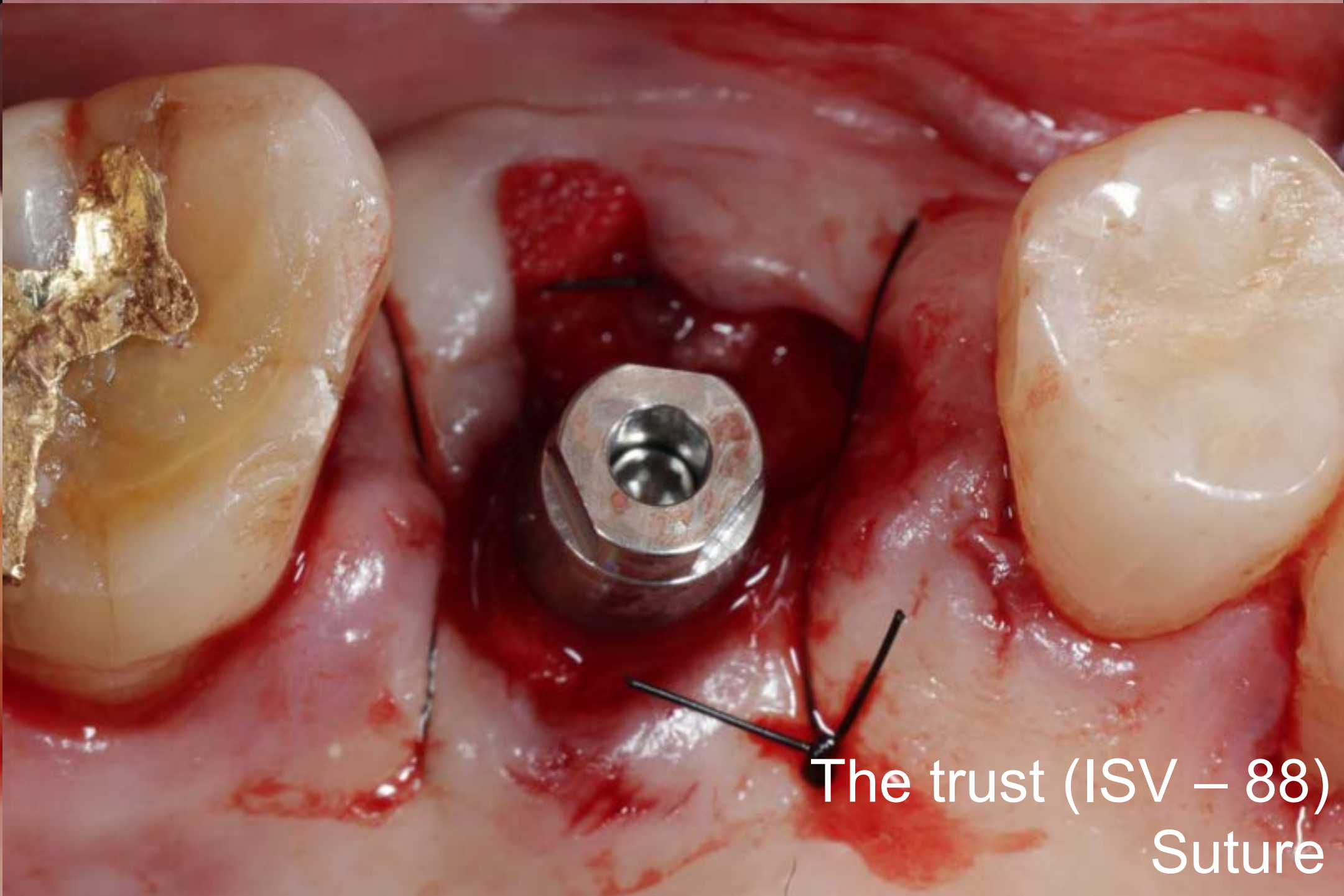
Pre-op (2024-11-05)



Surgery (2024-11-05)

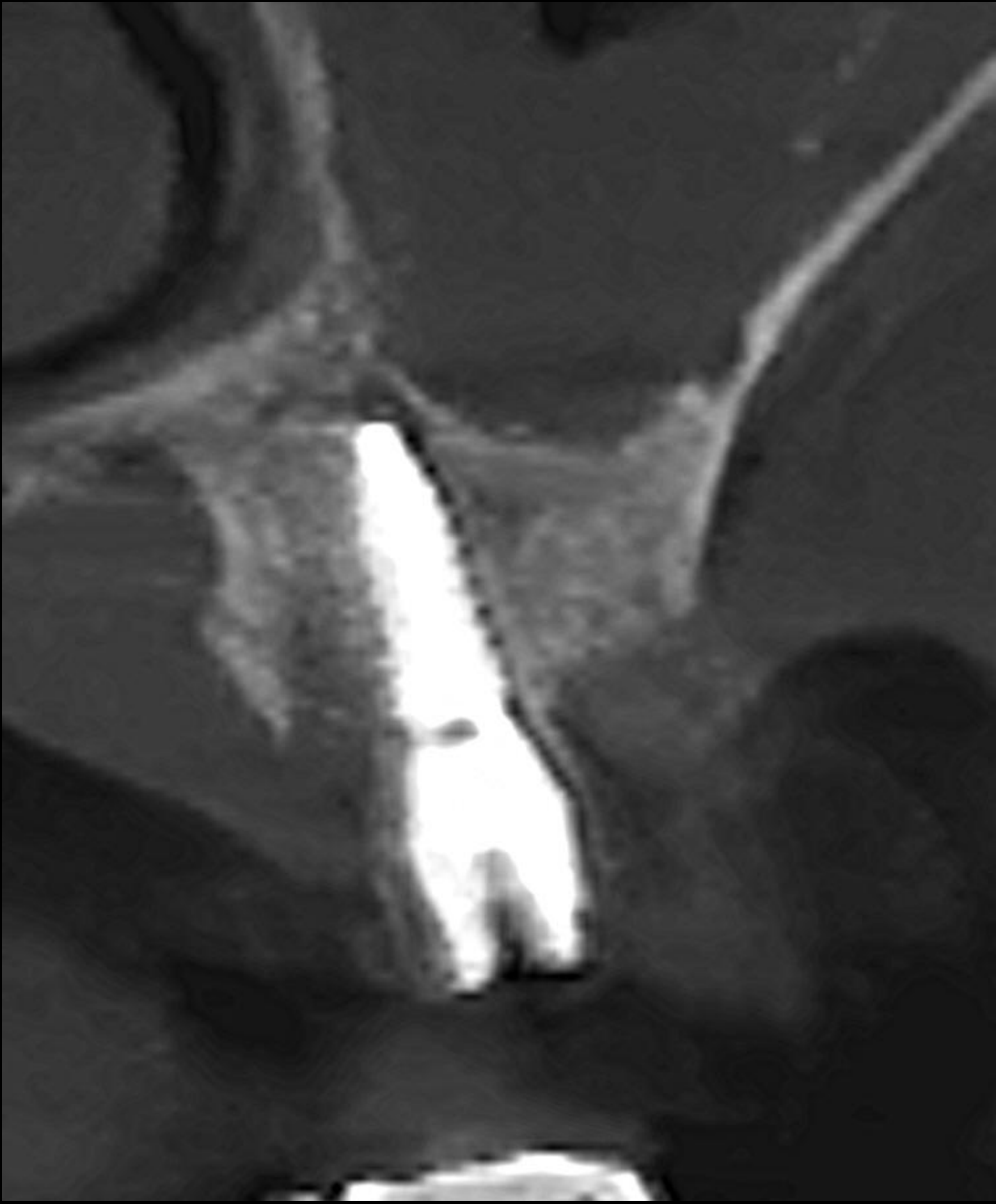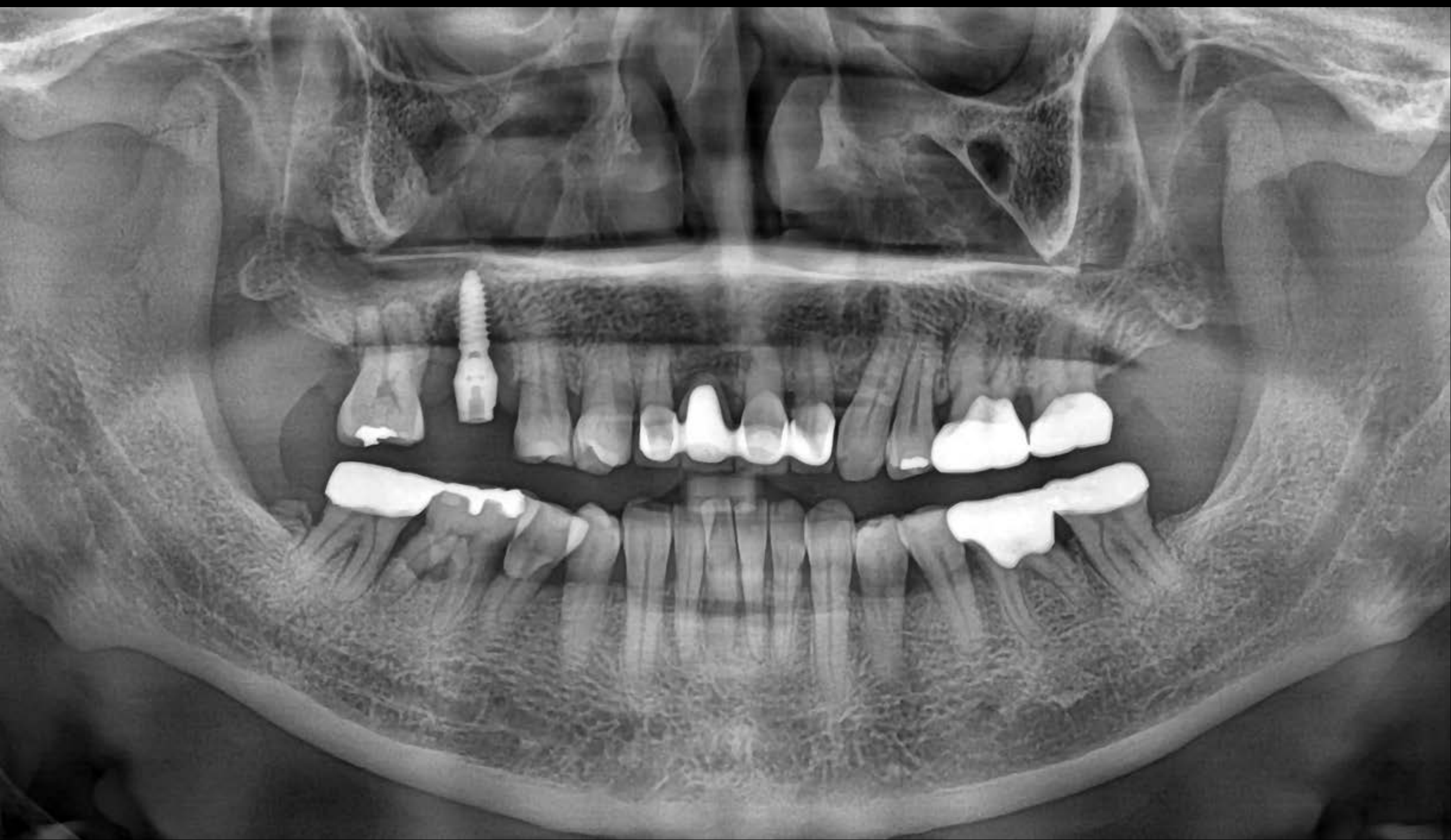


bright TL (Ø3.5 X 9.0)
Collagen Graft x1D



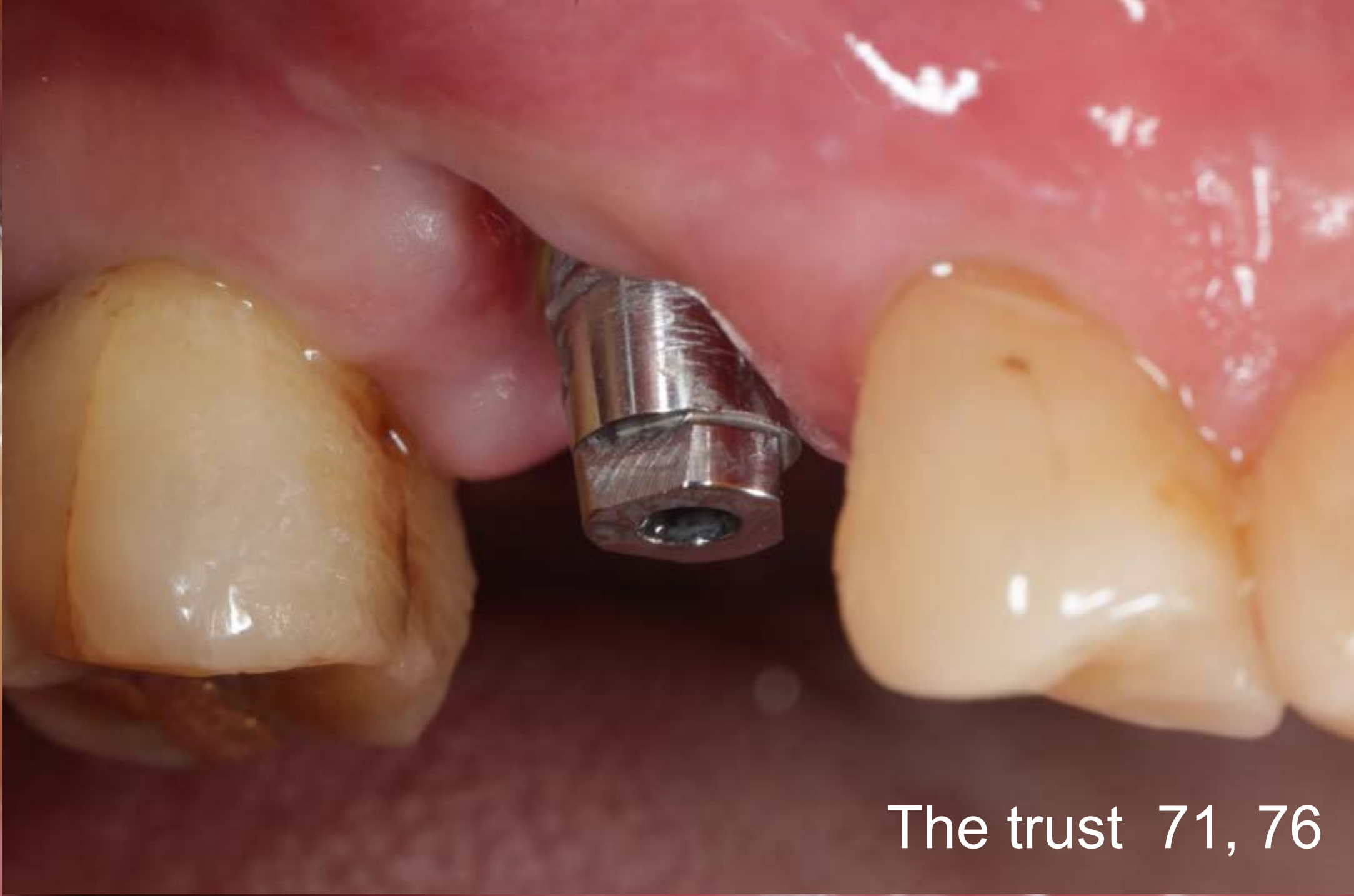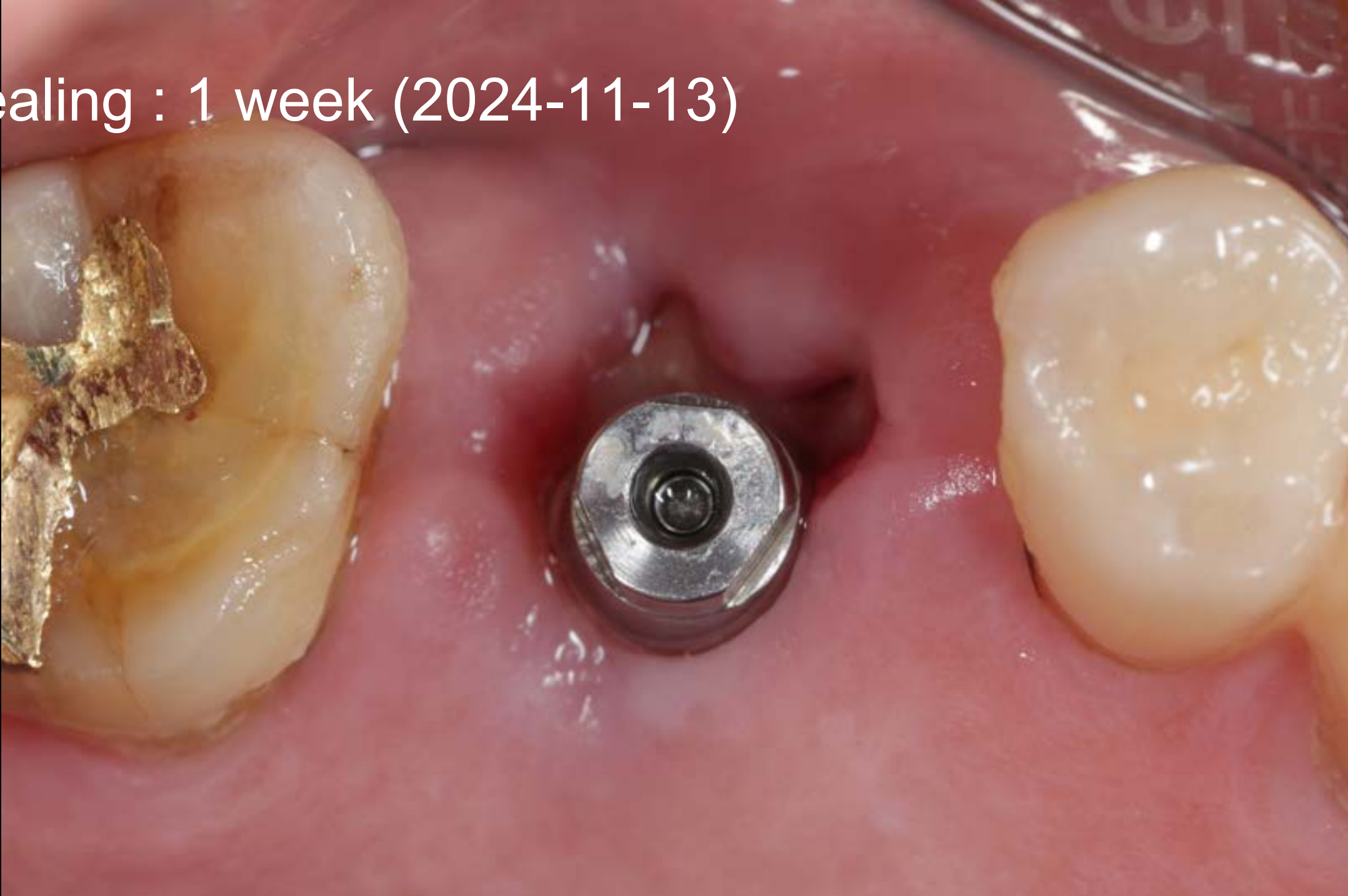The trust (ISV – 88)
Suture

Post-op (2024-11-13)

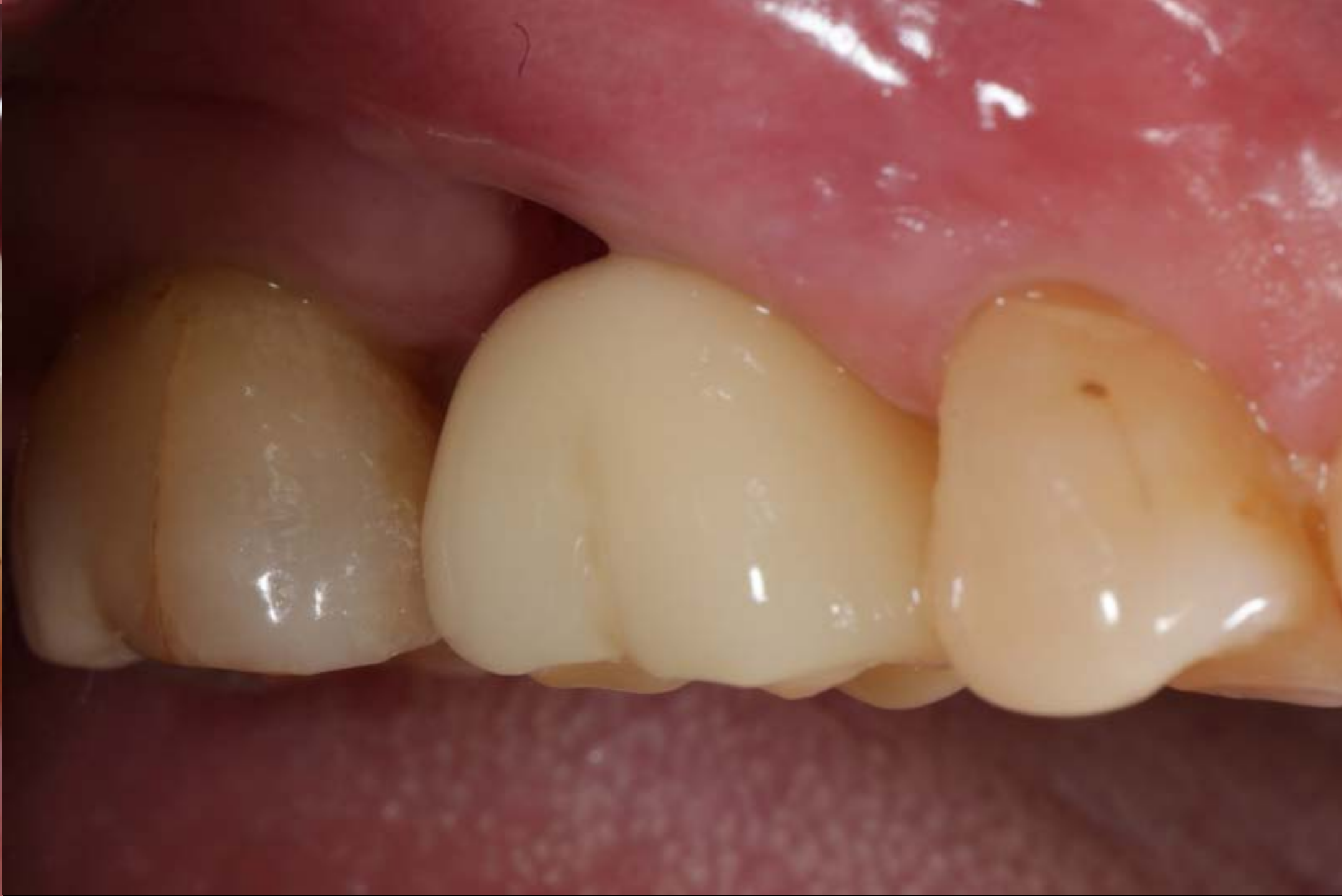
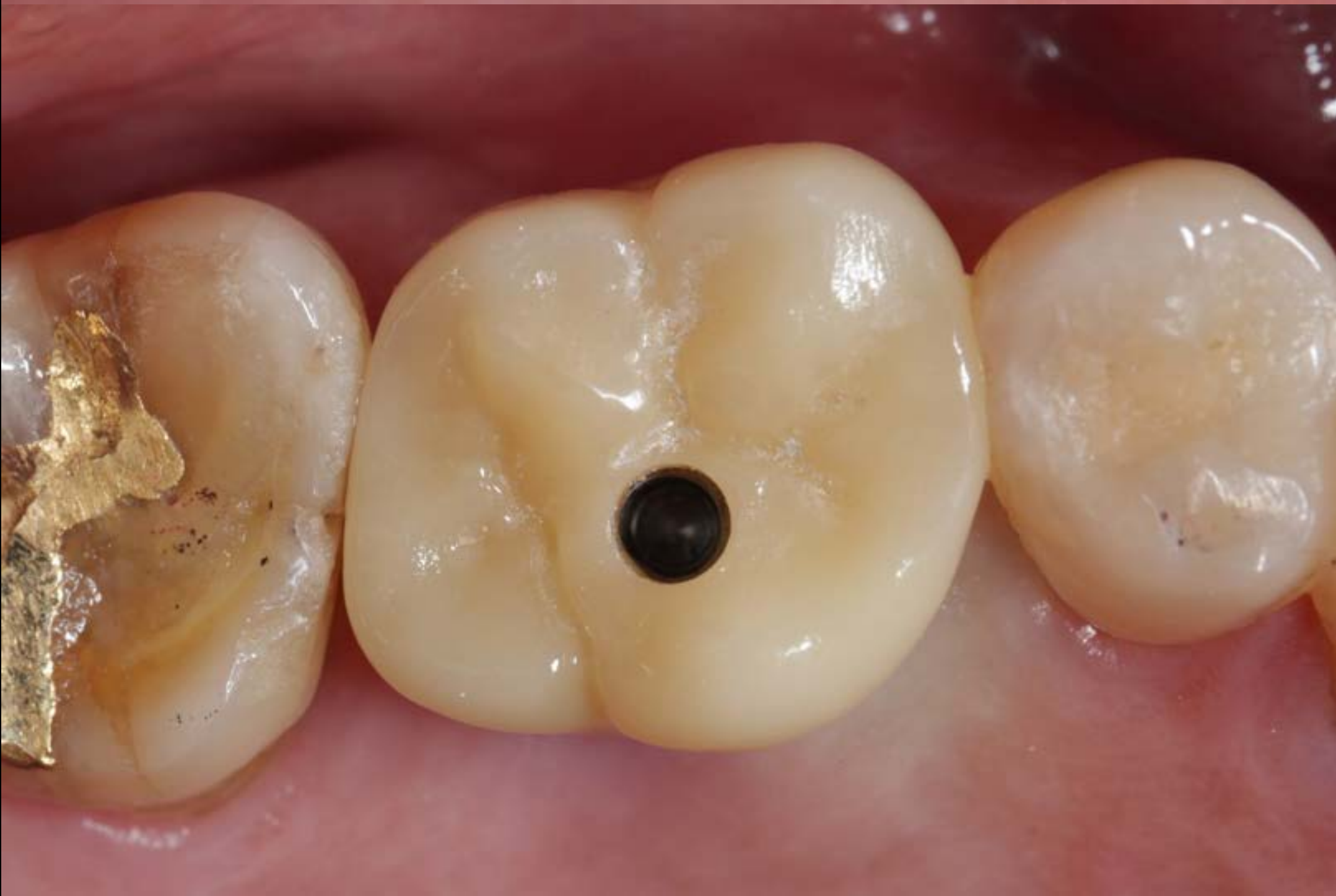
#16

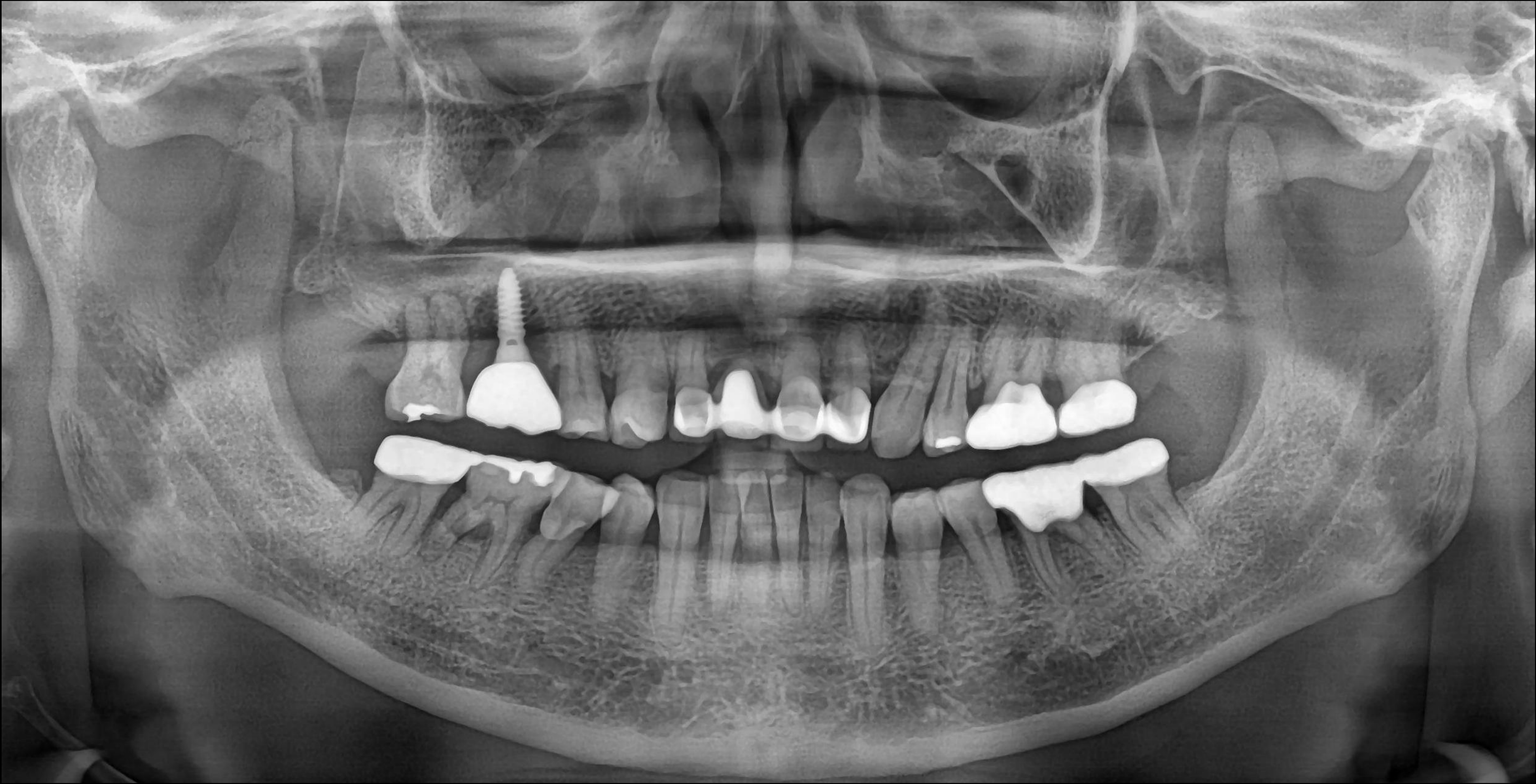Healing : 1 week (2024-11-13)



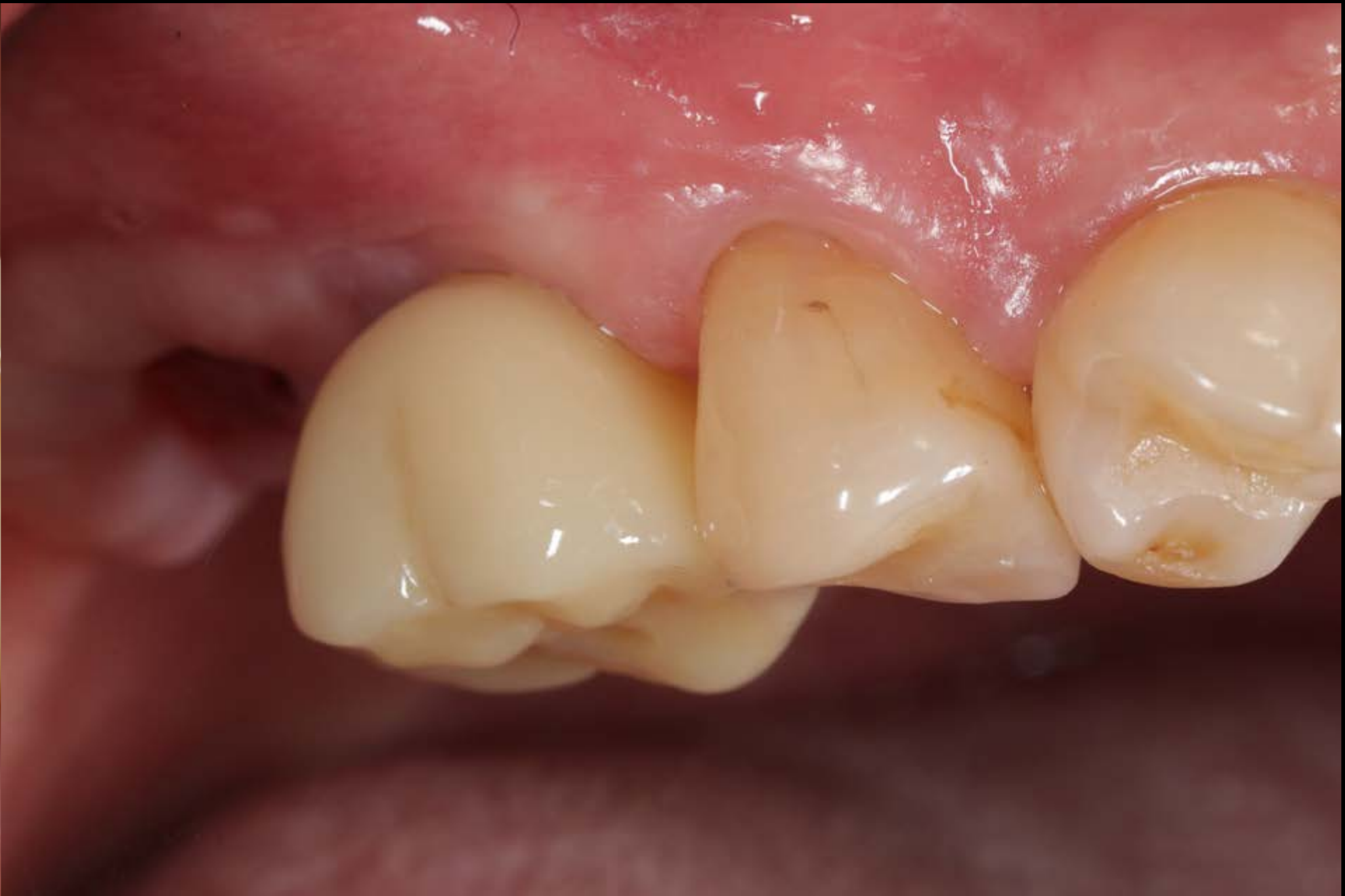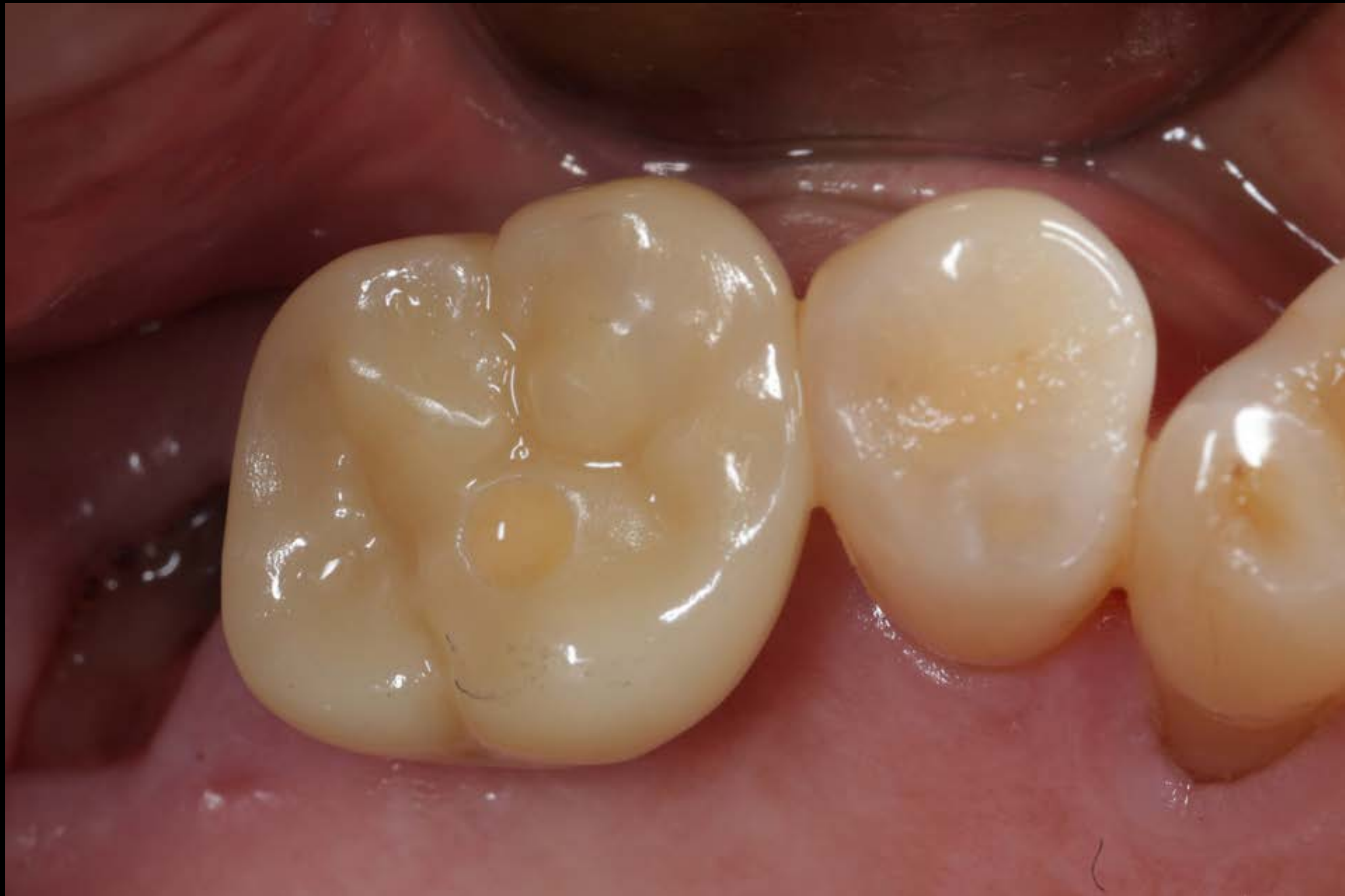The trust 71, 76



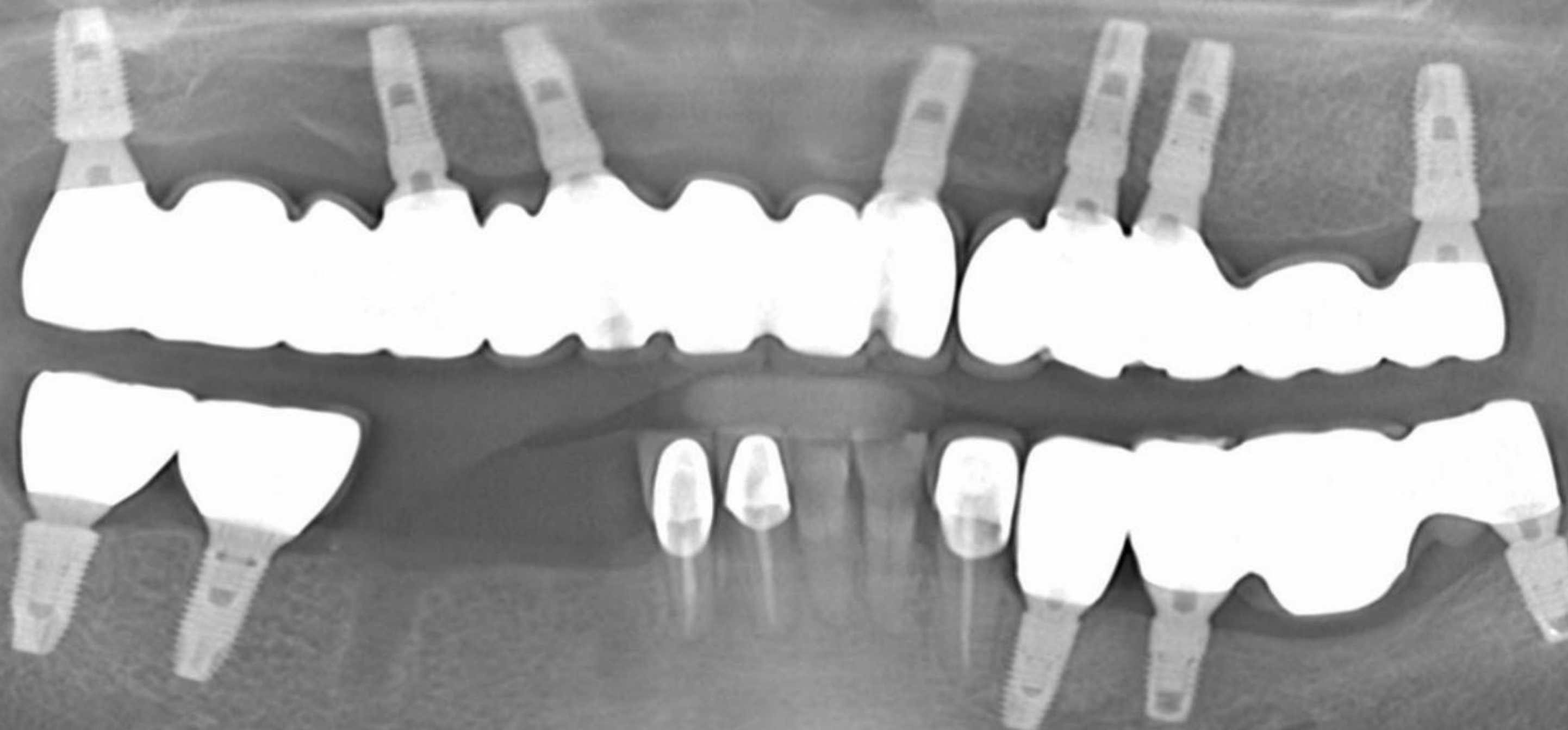Final prosthesis (2024-11-13)



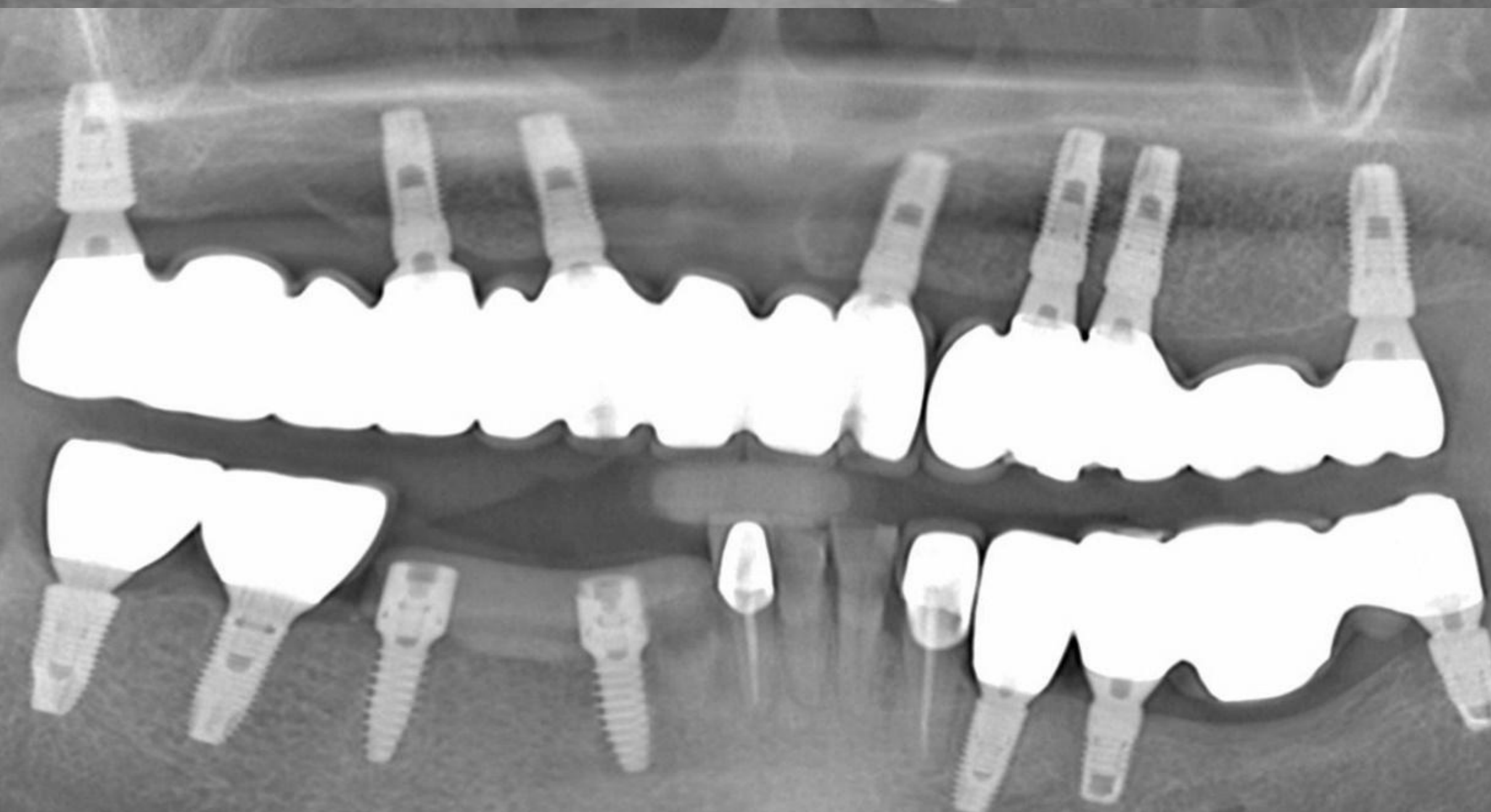
Follow up : 2 months (2025-01-10)



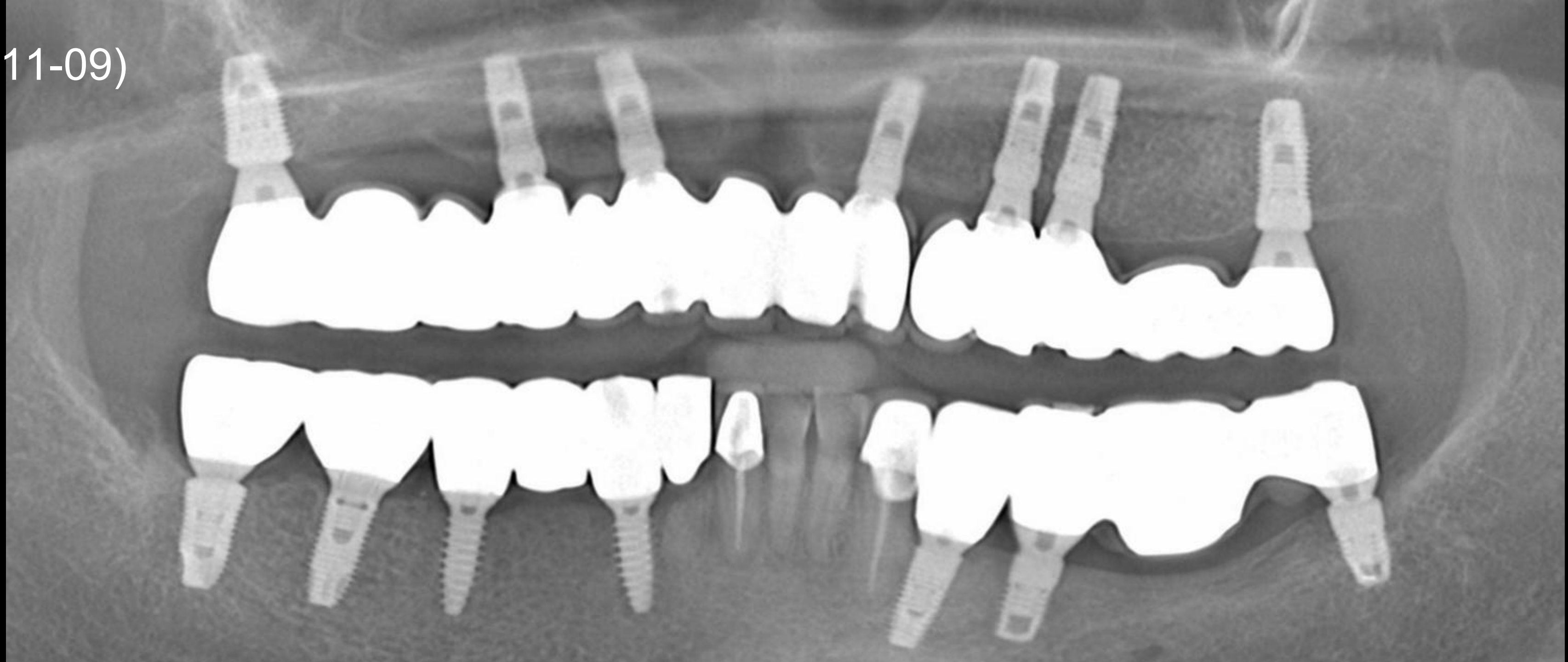
Pre-op (2020-07-15)



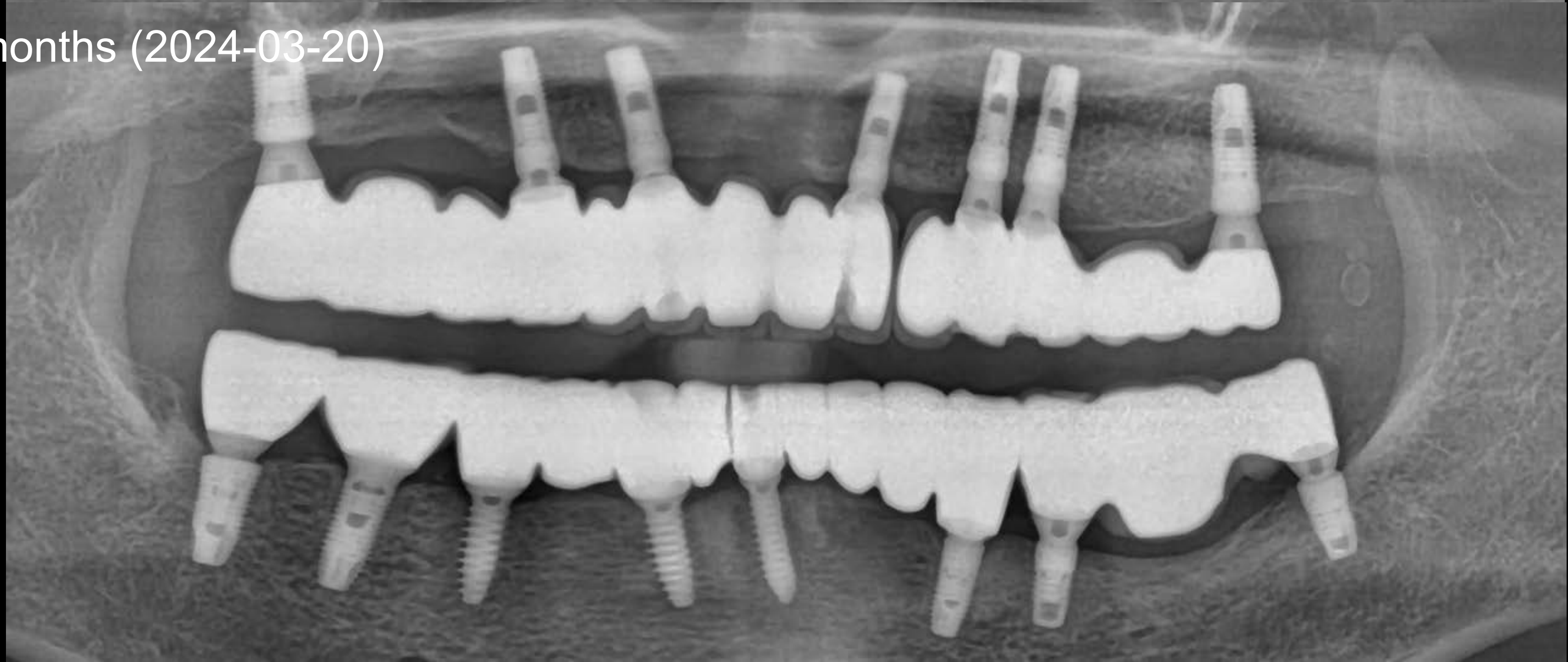
Post-op (2020-07-15)



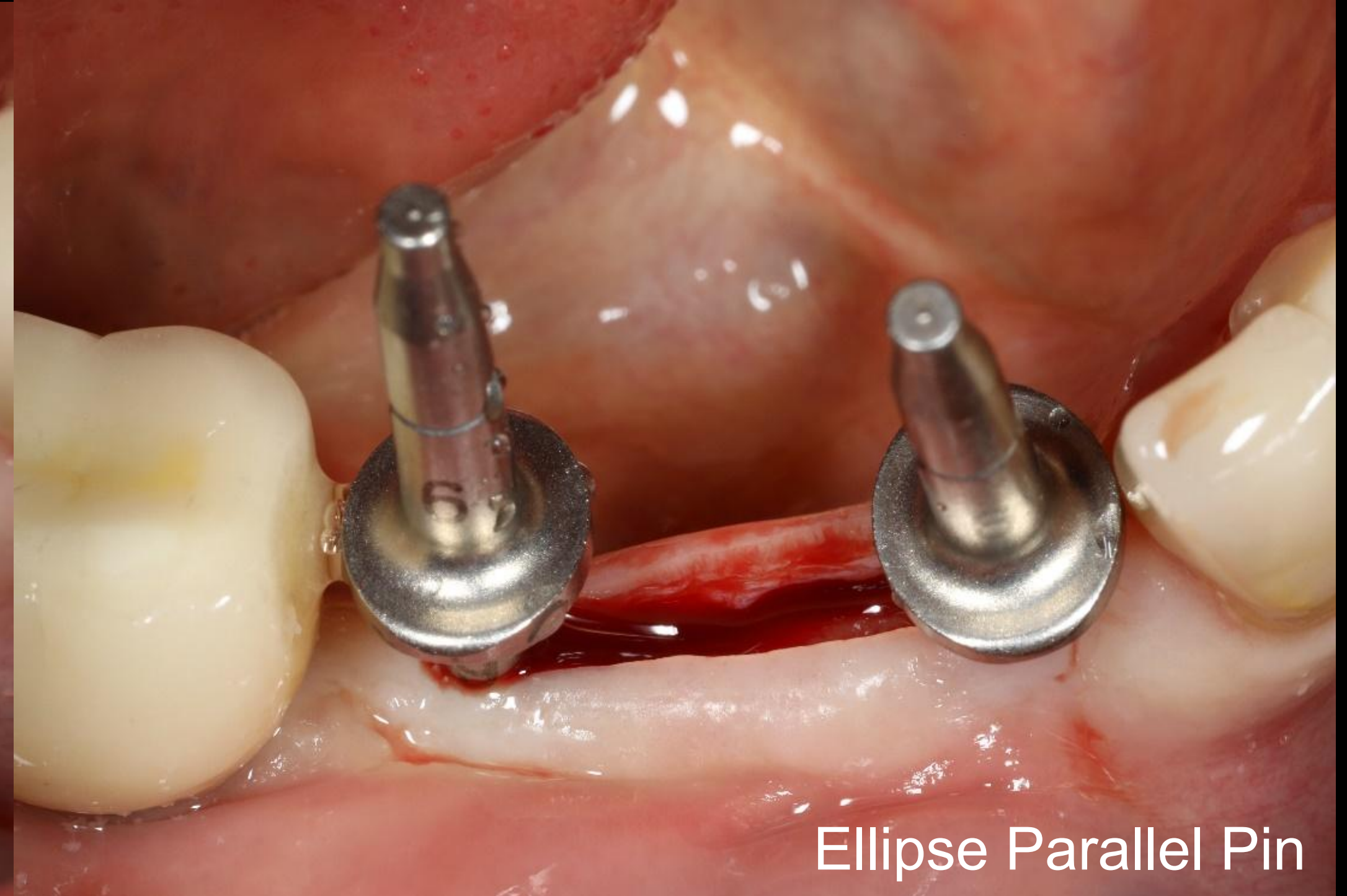
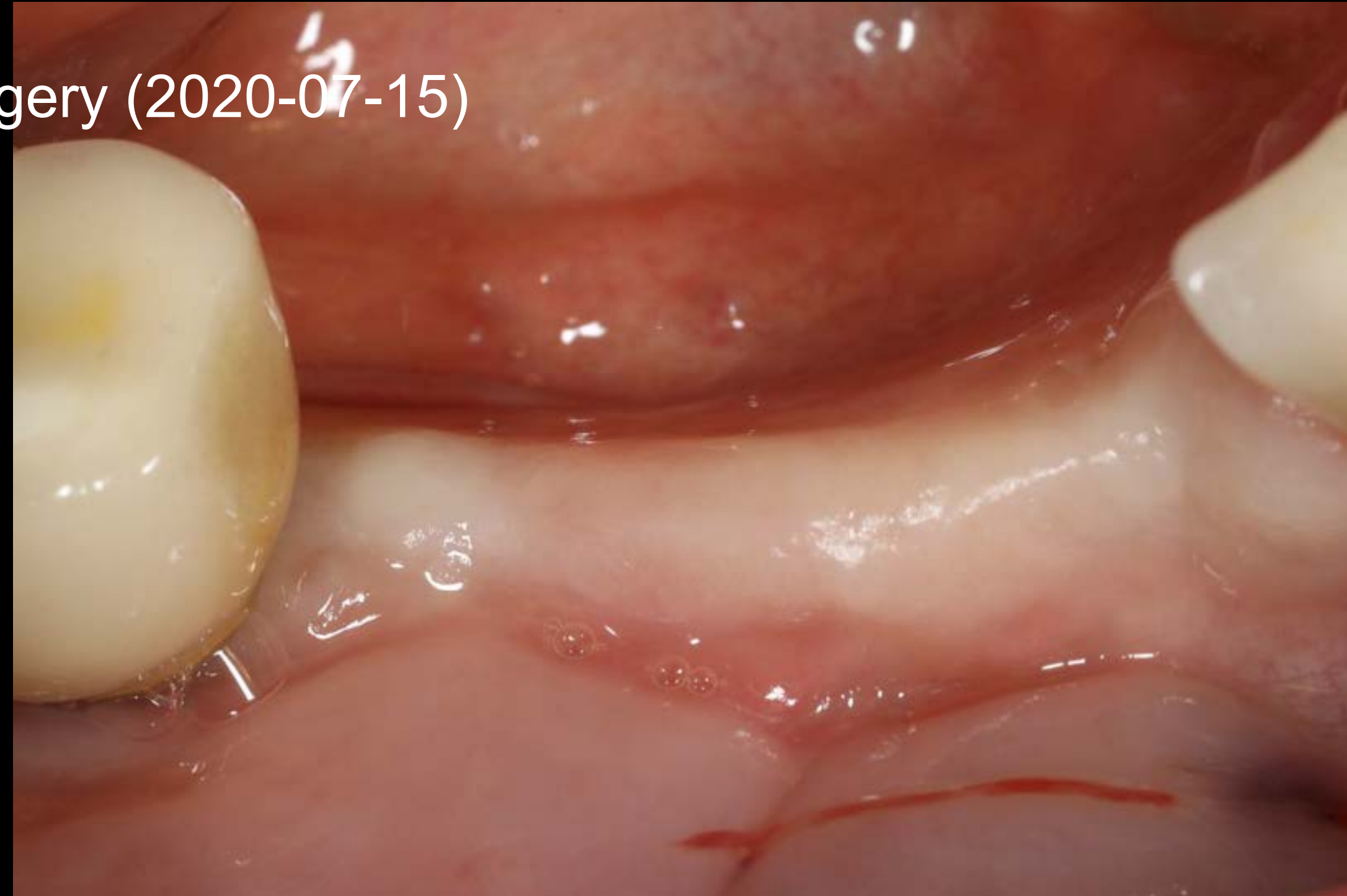
Final prosthesis (2020-11-09)



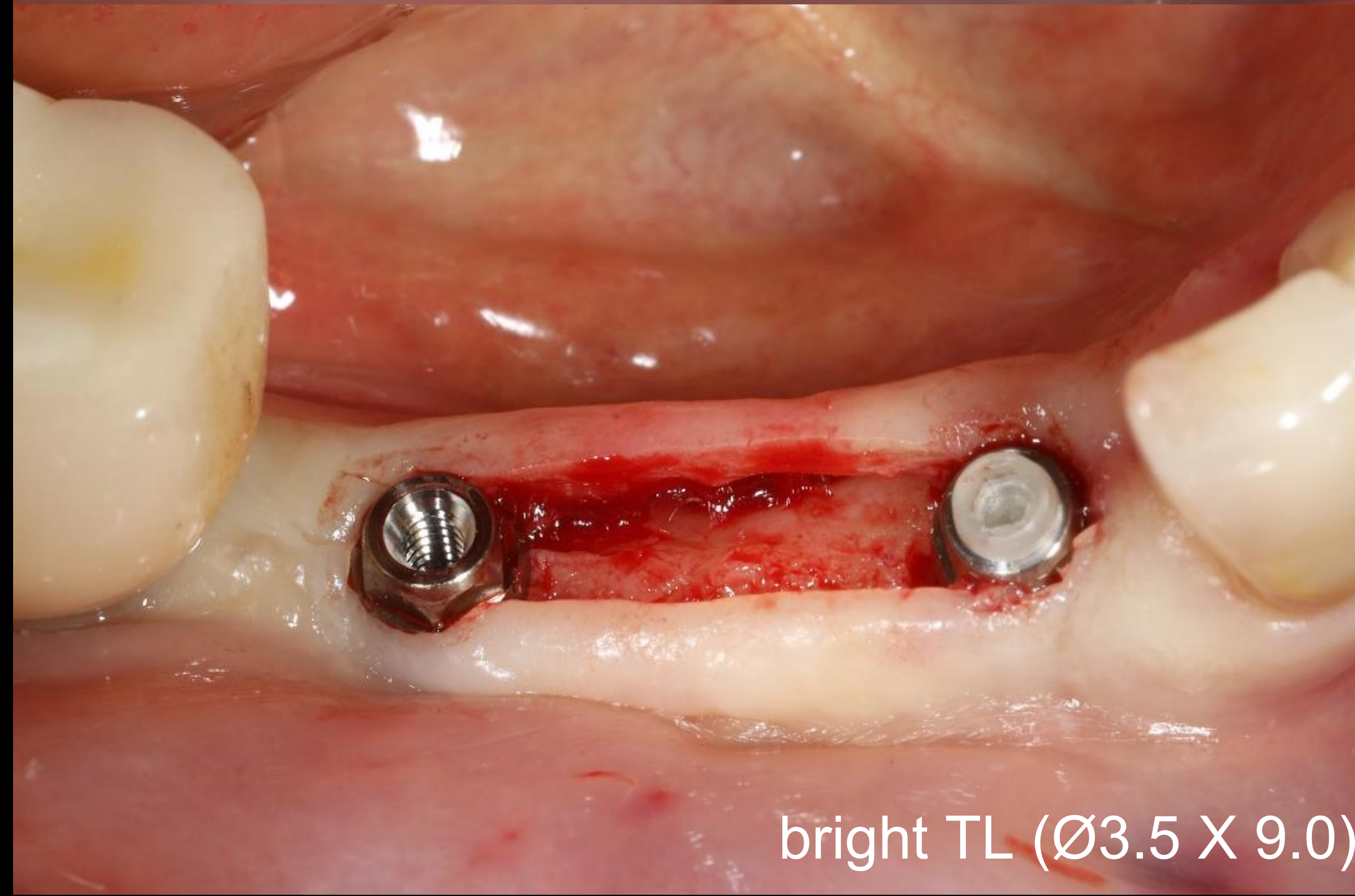
Follow up : 3 years 4 months (2024-03-20)



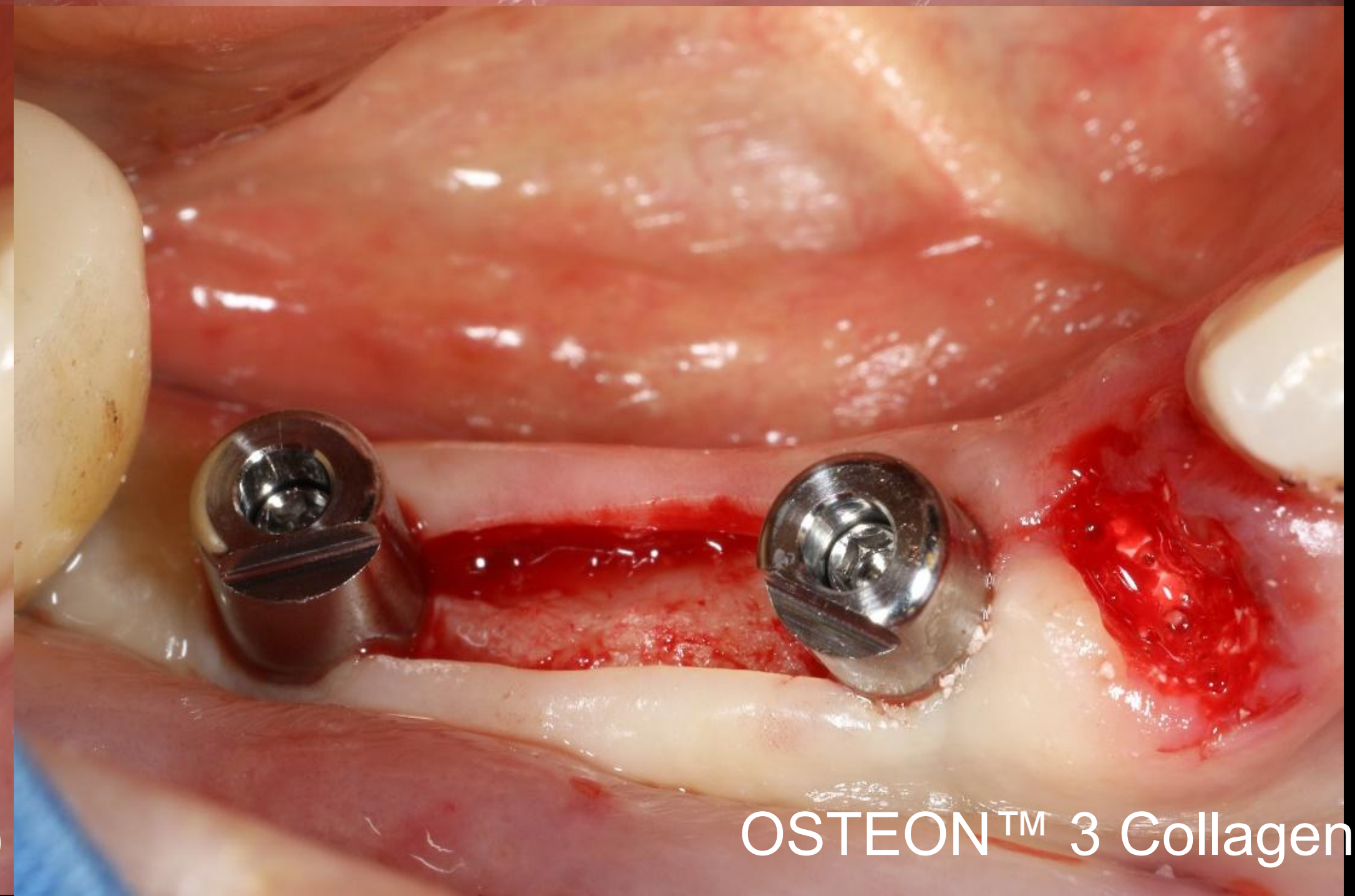
Surgery (2020-07-15)



Ellipse Parallel Pin

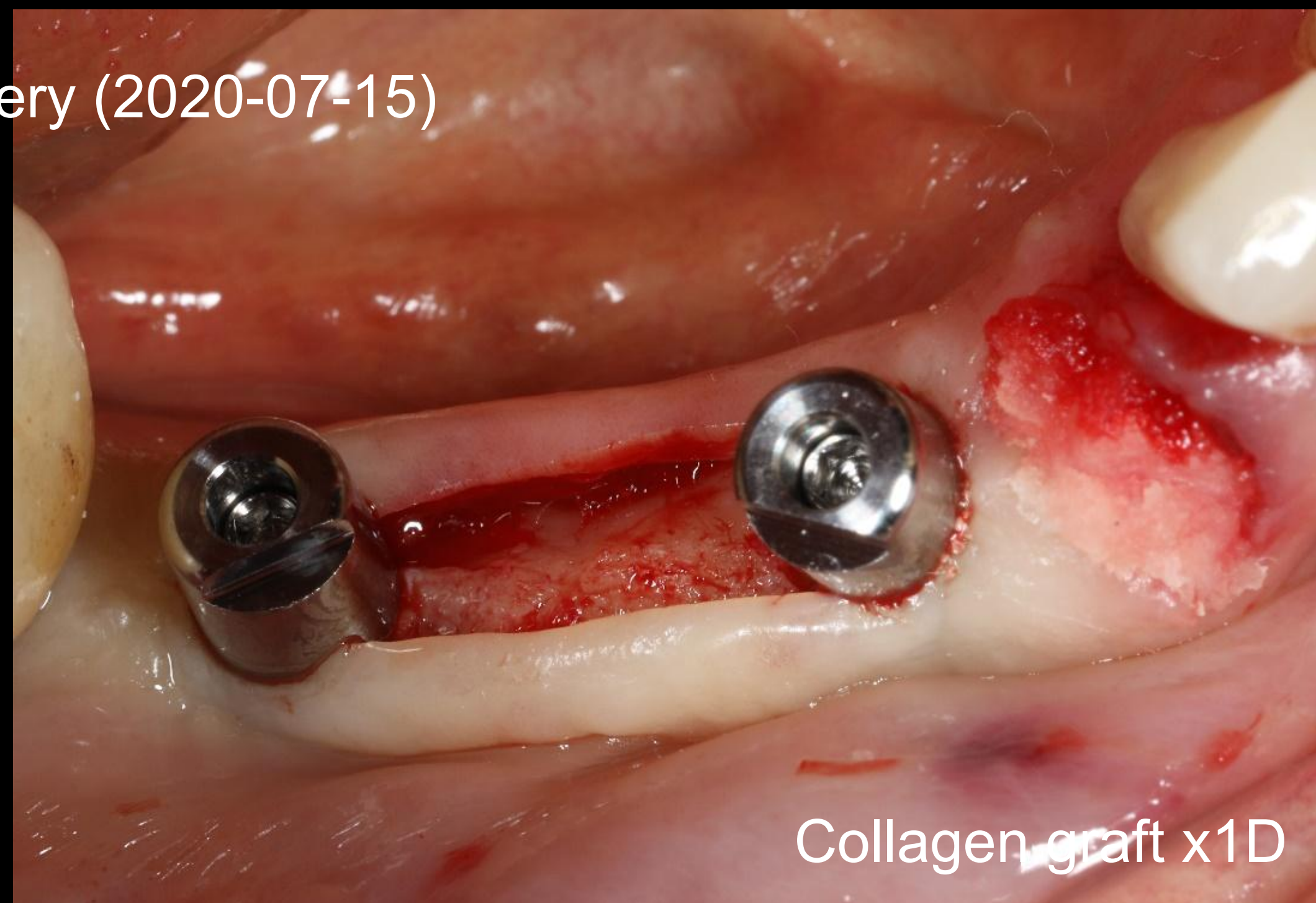


bright TL (Ø3.5 X 9.0)

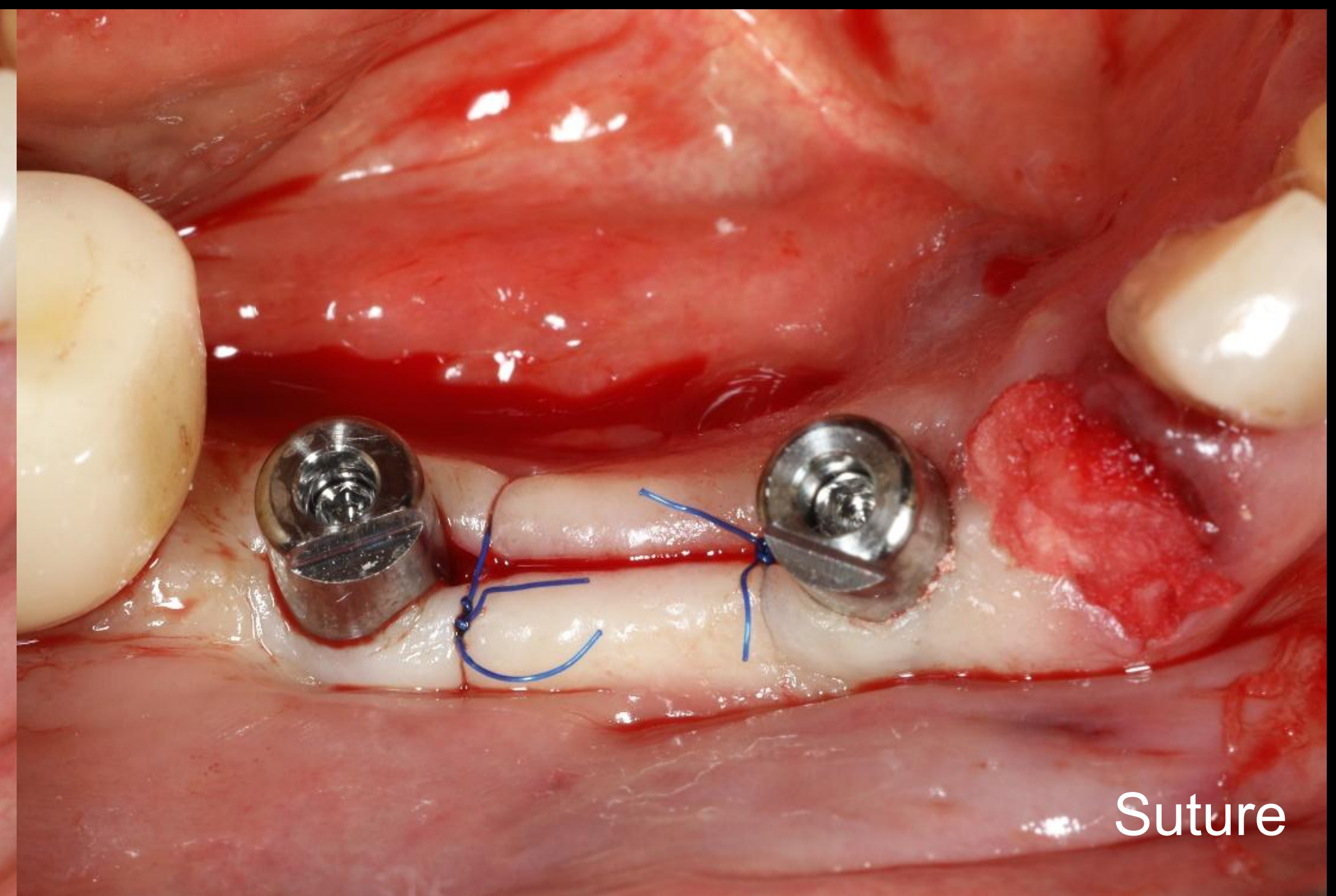


OSTEON™ 3 Collagen

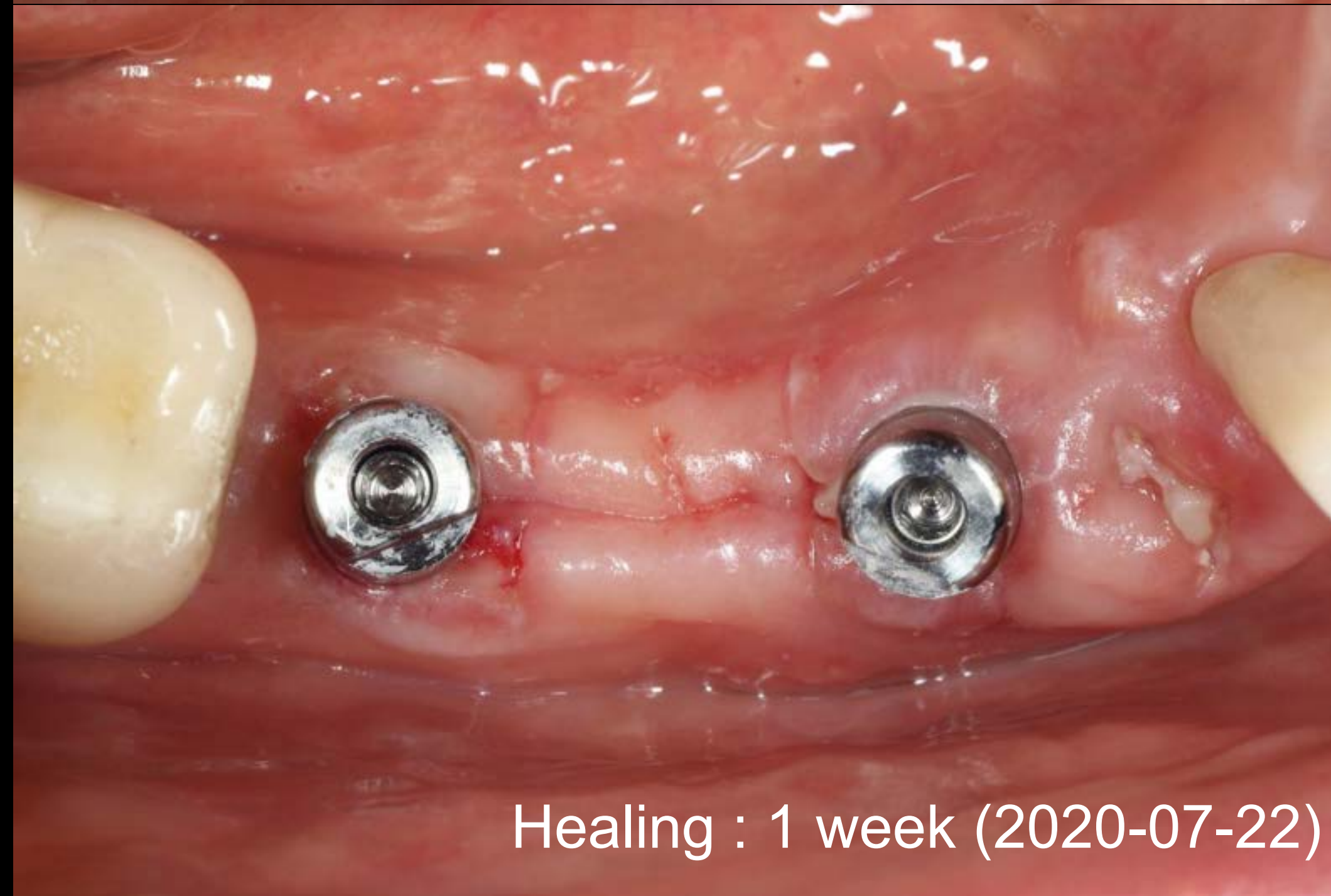Surgery (2020-07-15)



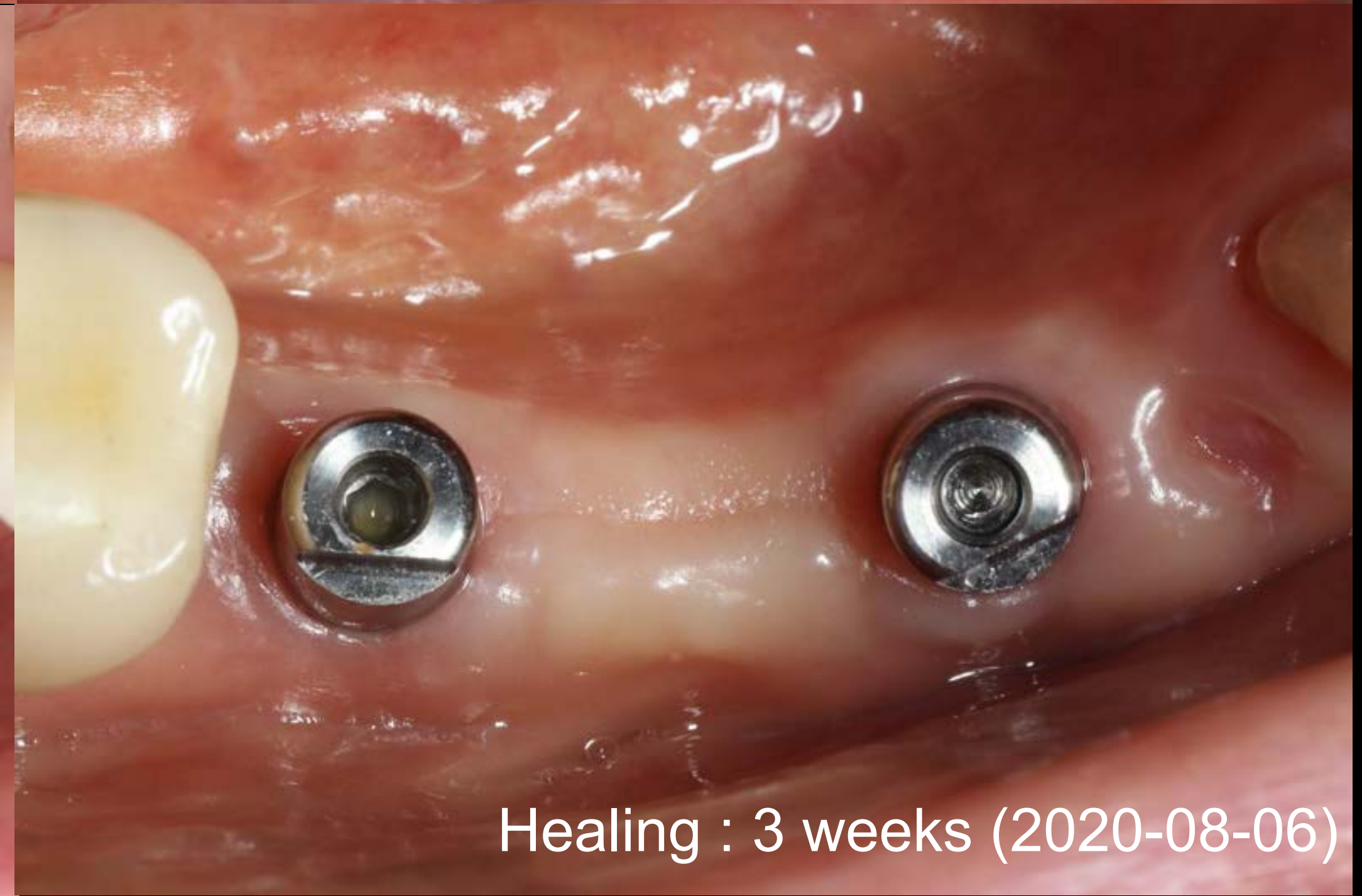Collagen graft x1D



Suture

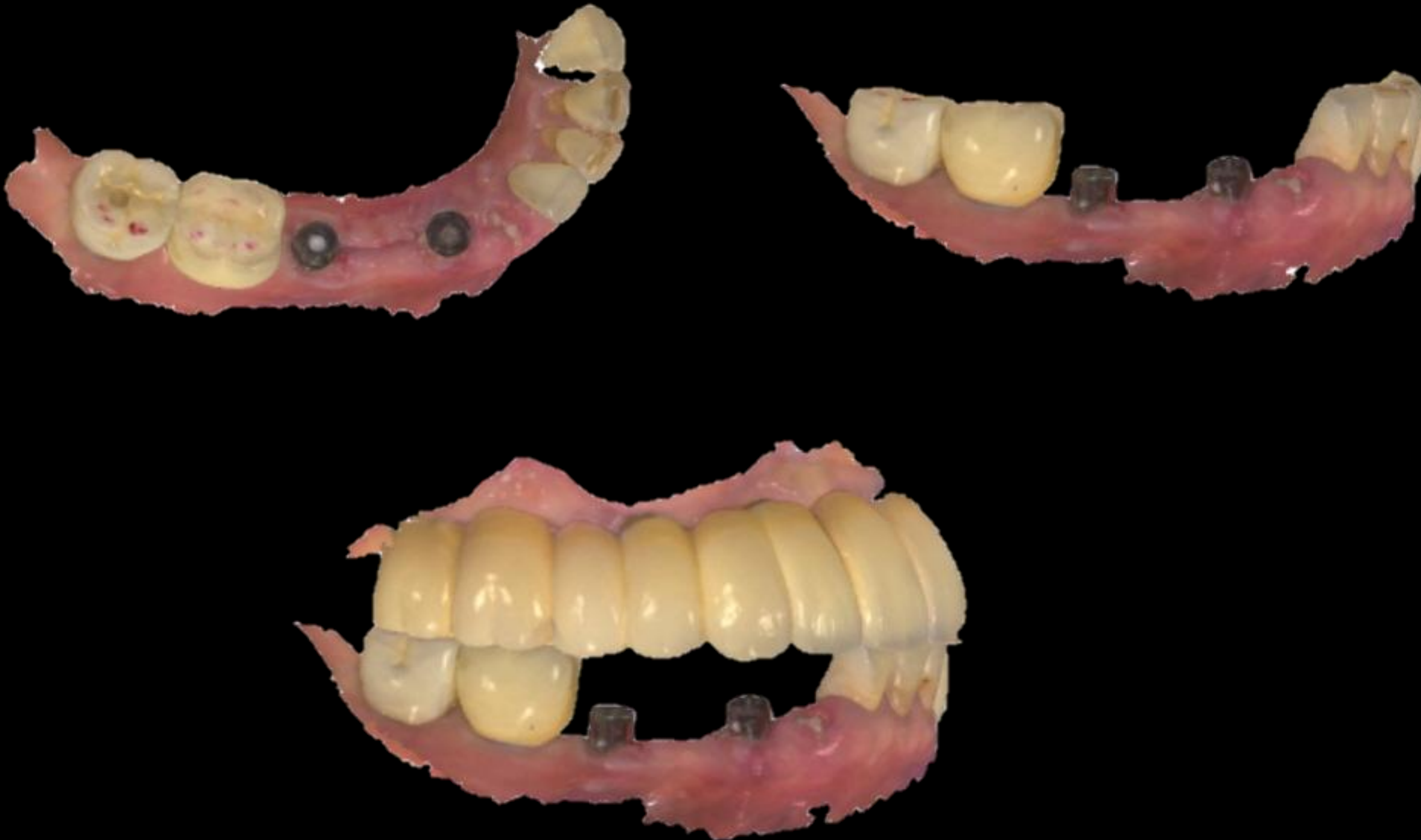

Healing : 1 week (2020-07-22)

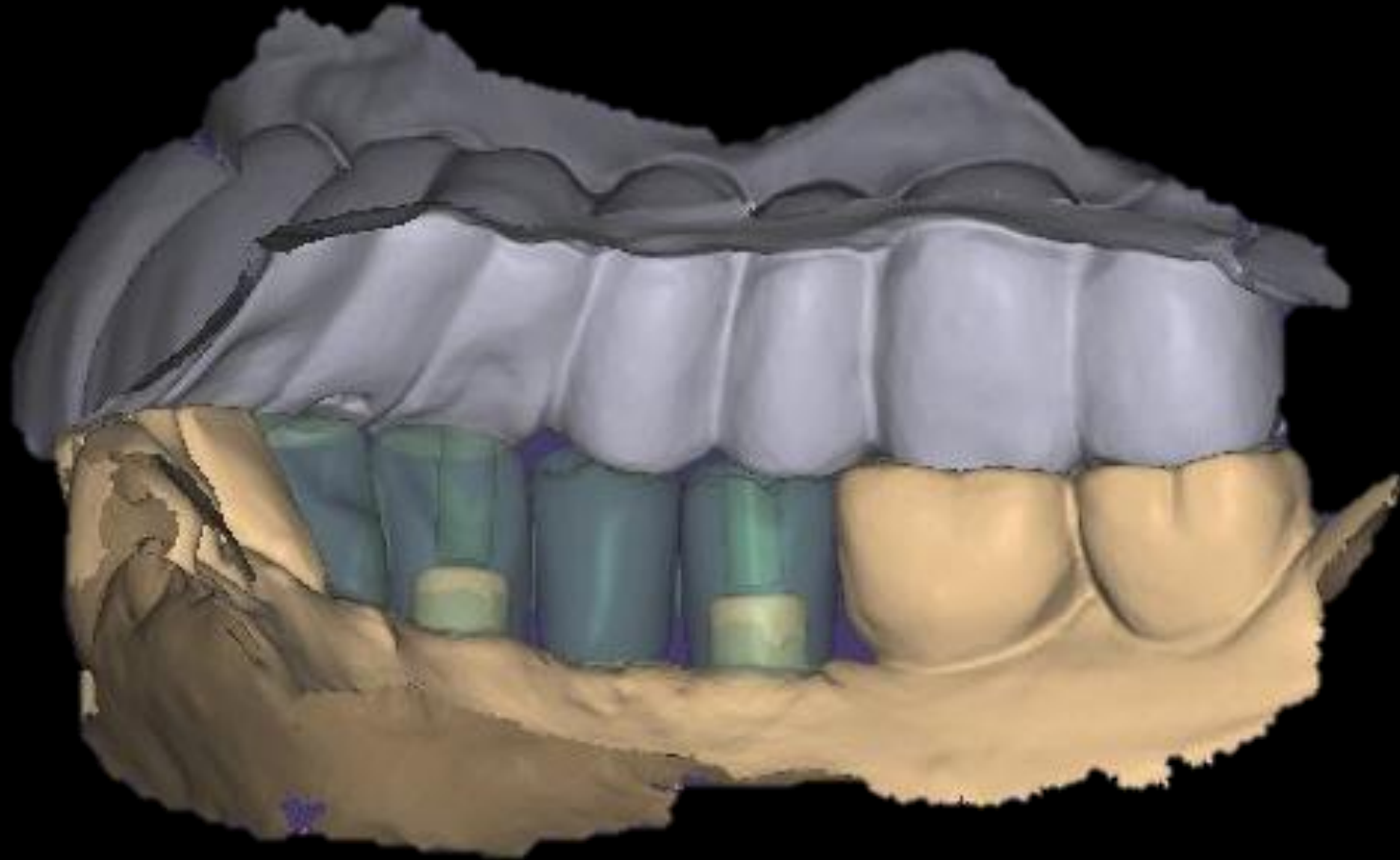
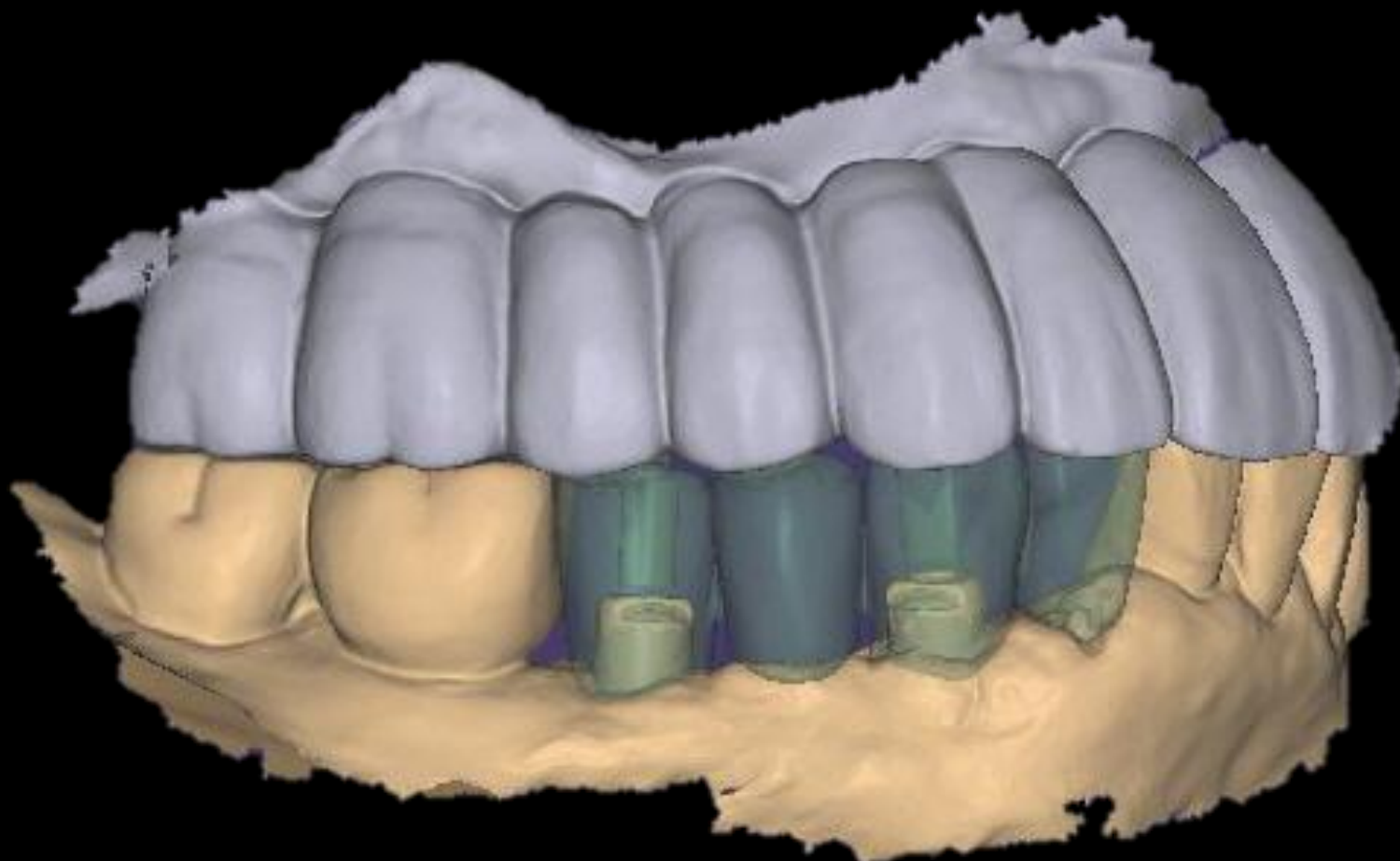
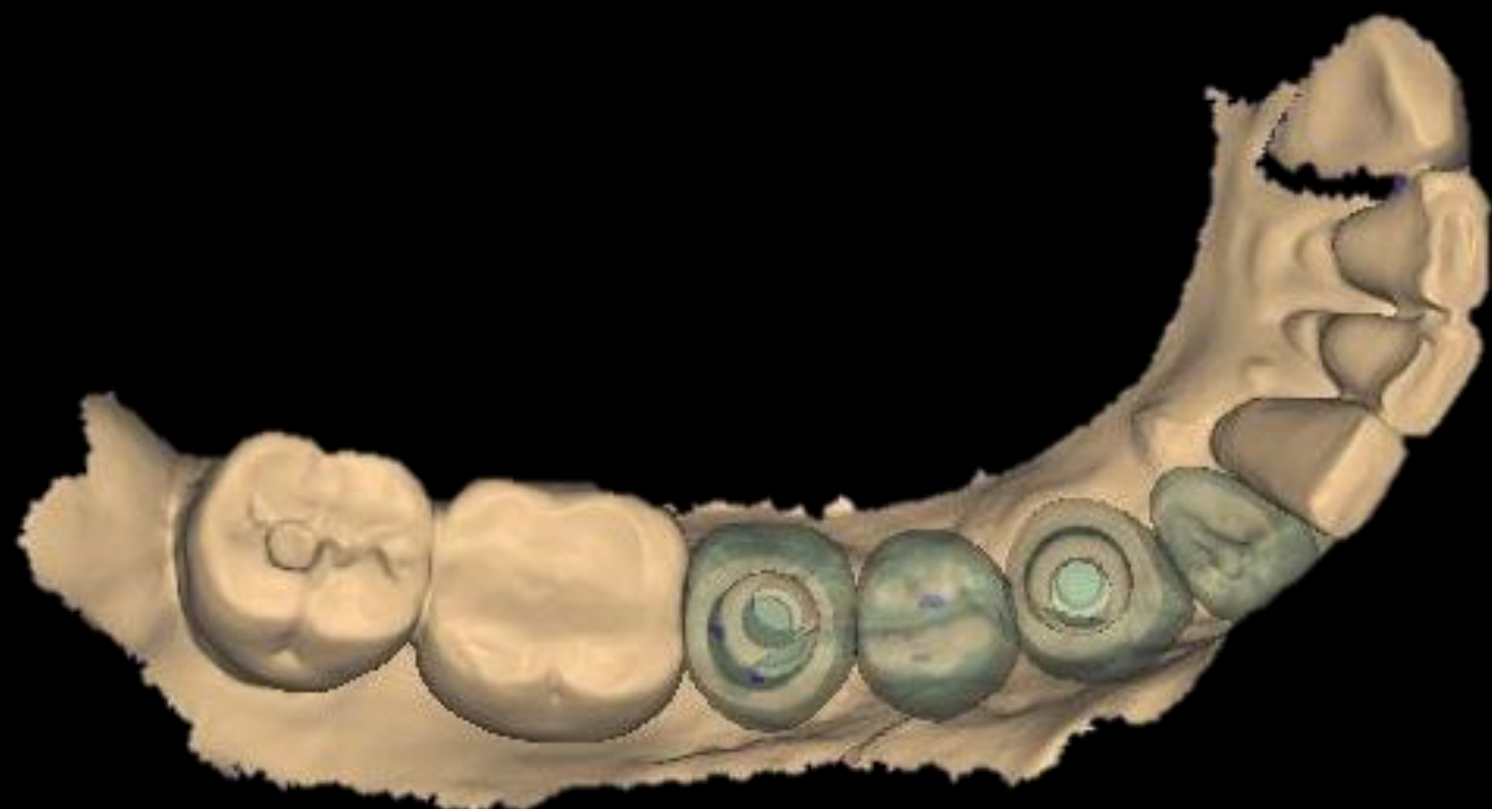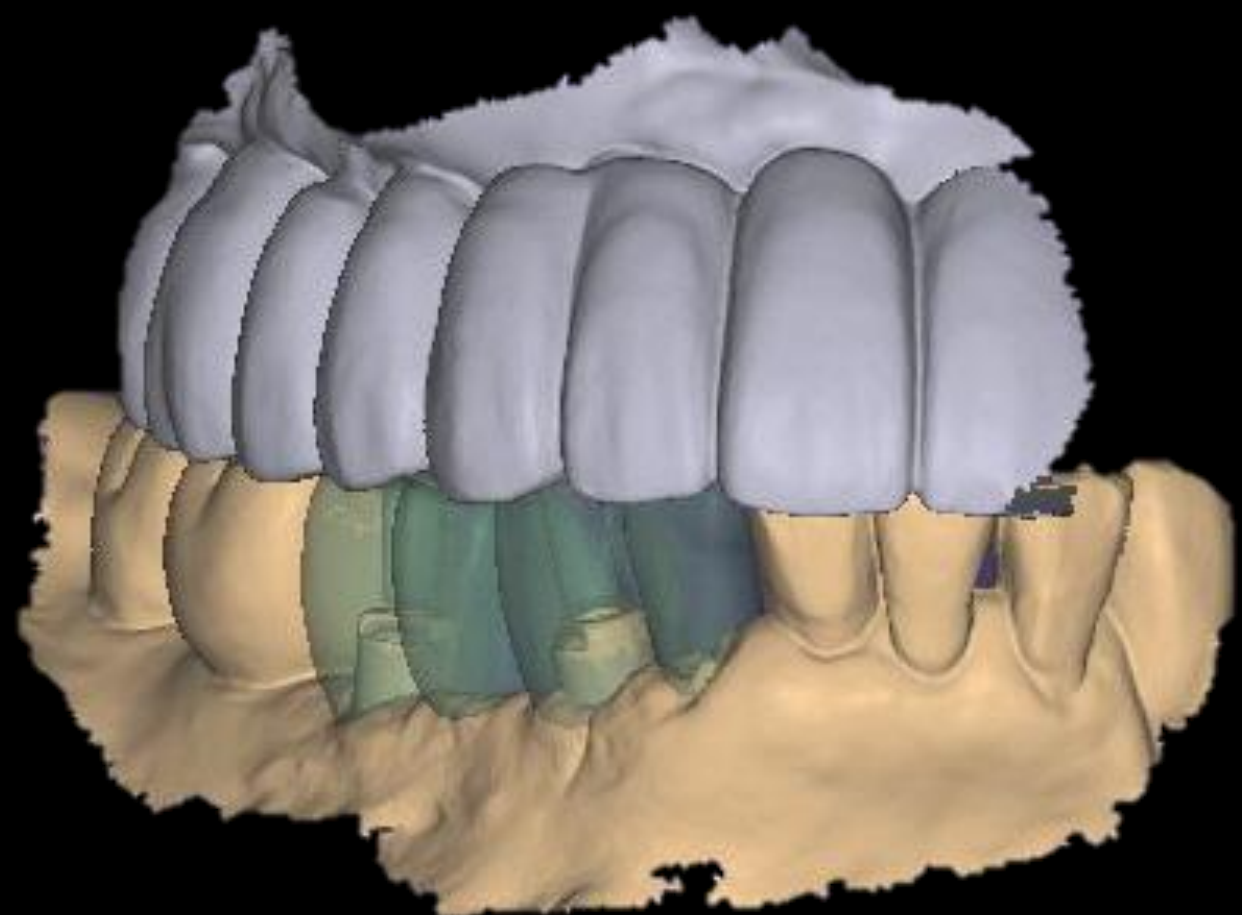


Healing : 3 weeks (2020-08-06)

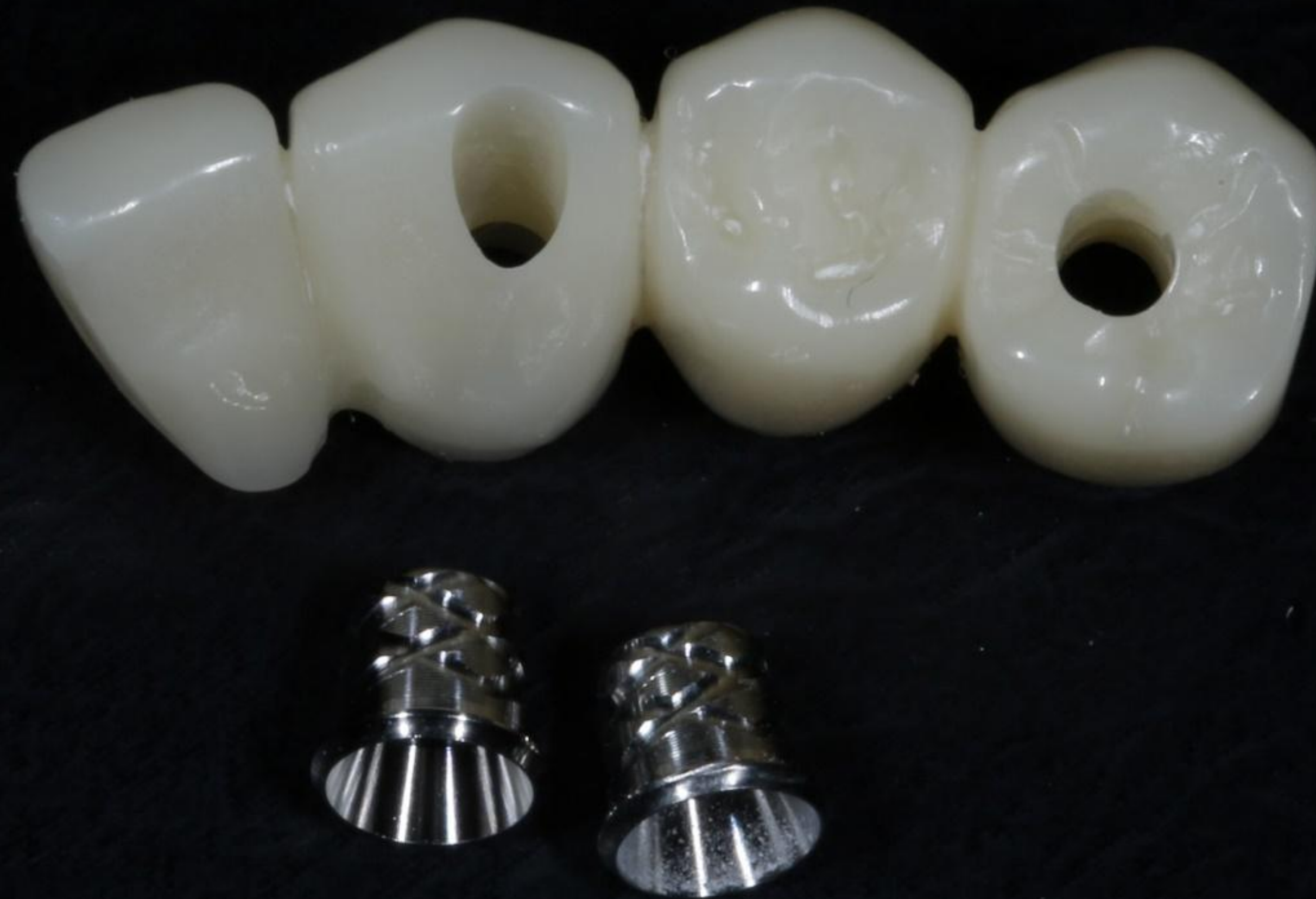Intra Oral Scan



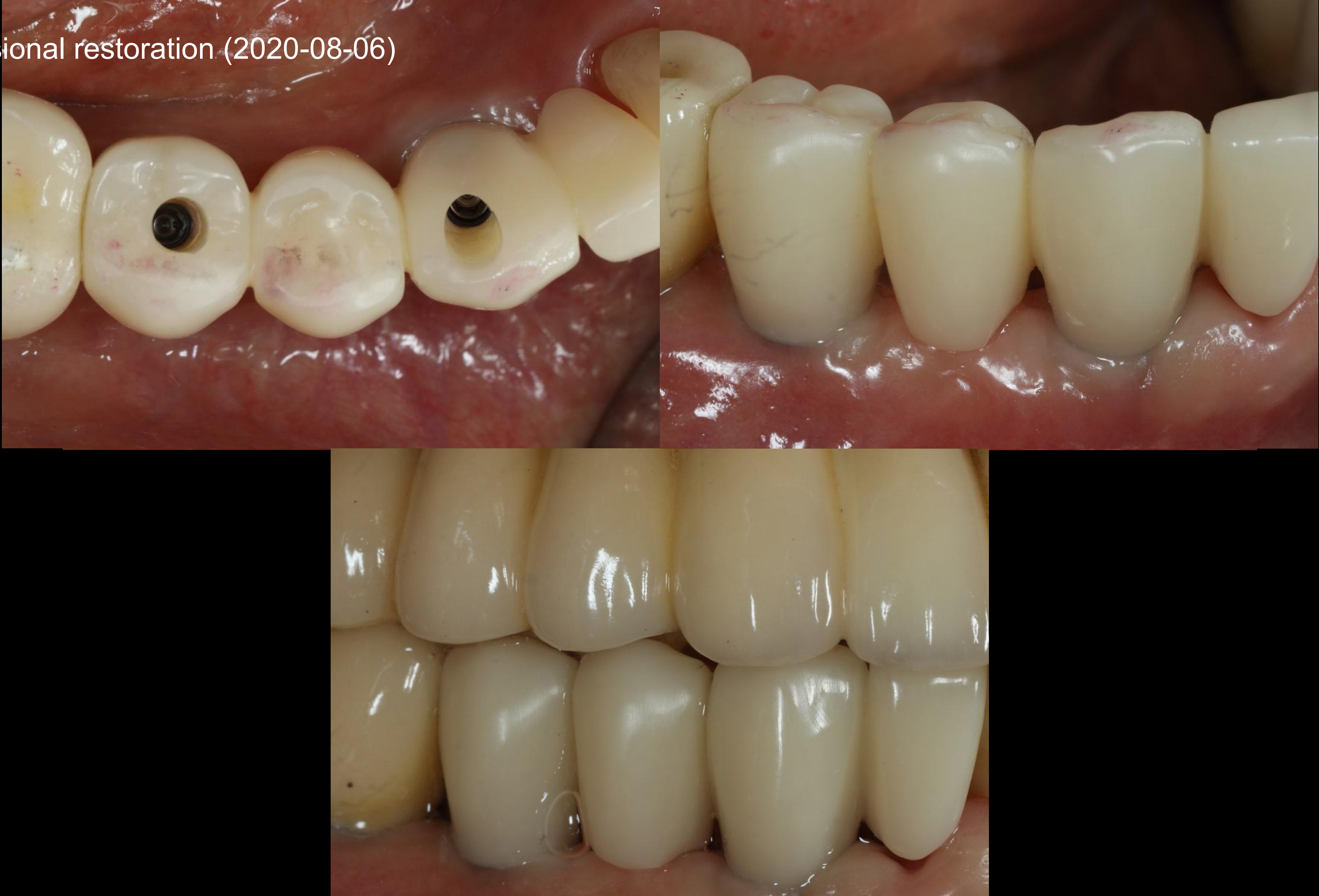CAD (Temporary)



Metal Link / Temporary crown



Provisional restoration (2020-08-06)



Normal bone

ø2.5

ø3.0

bright TL
ø3.5 X 9.0mm

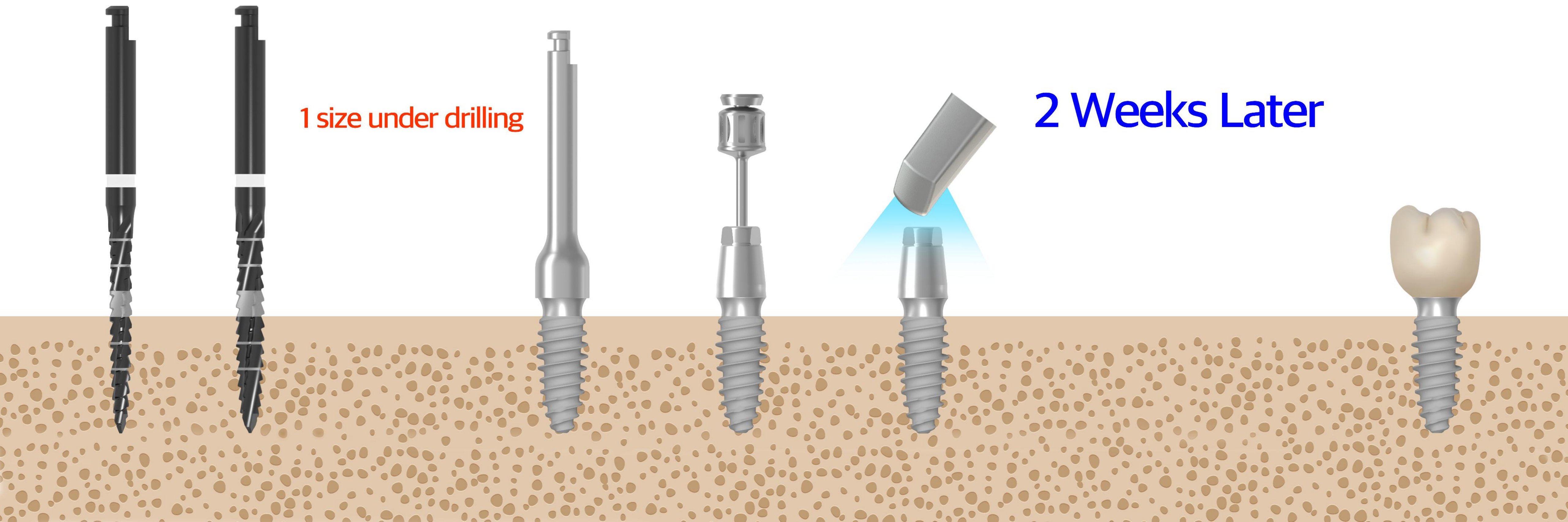
Intra Oral Scan

Crown loading

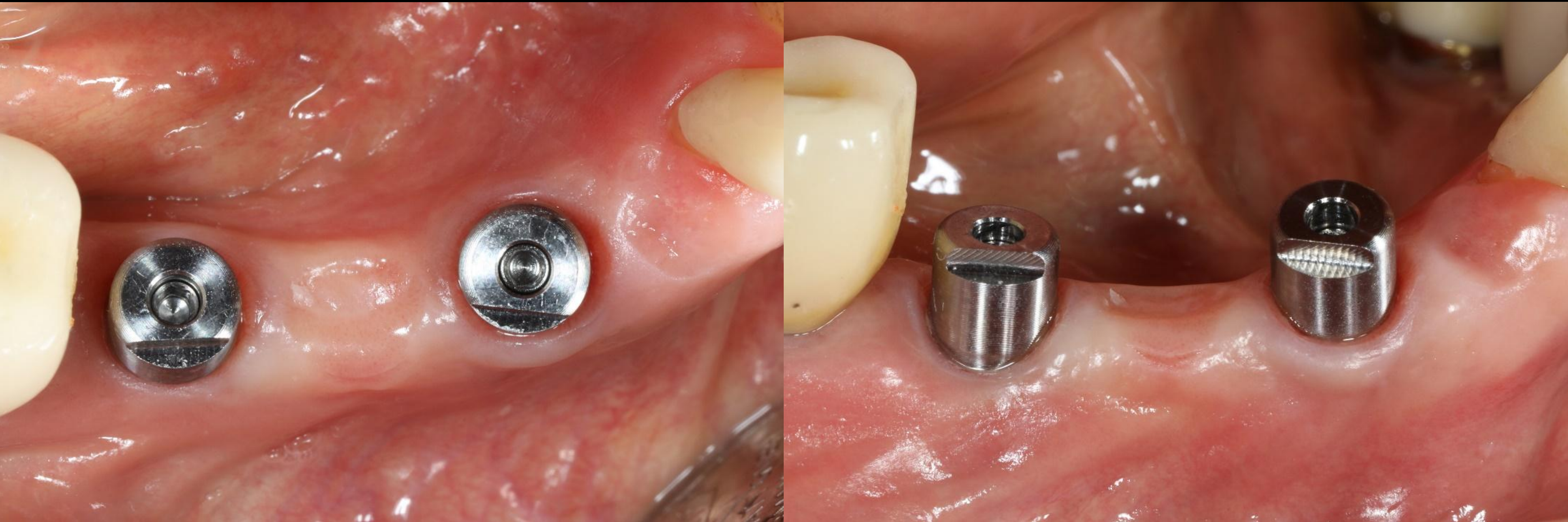Digital Abutment

1 size under drilling

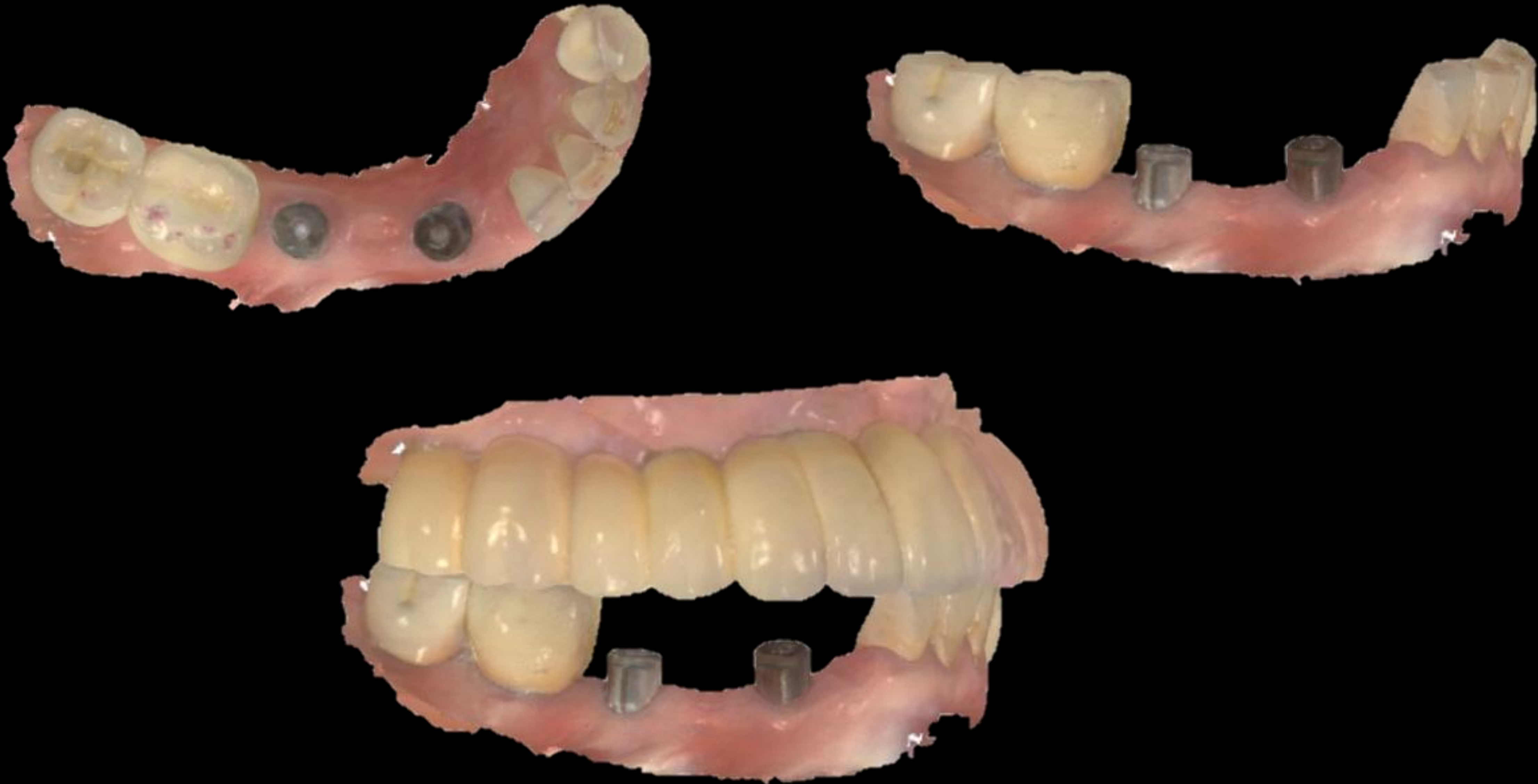2 Weeks Later



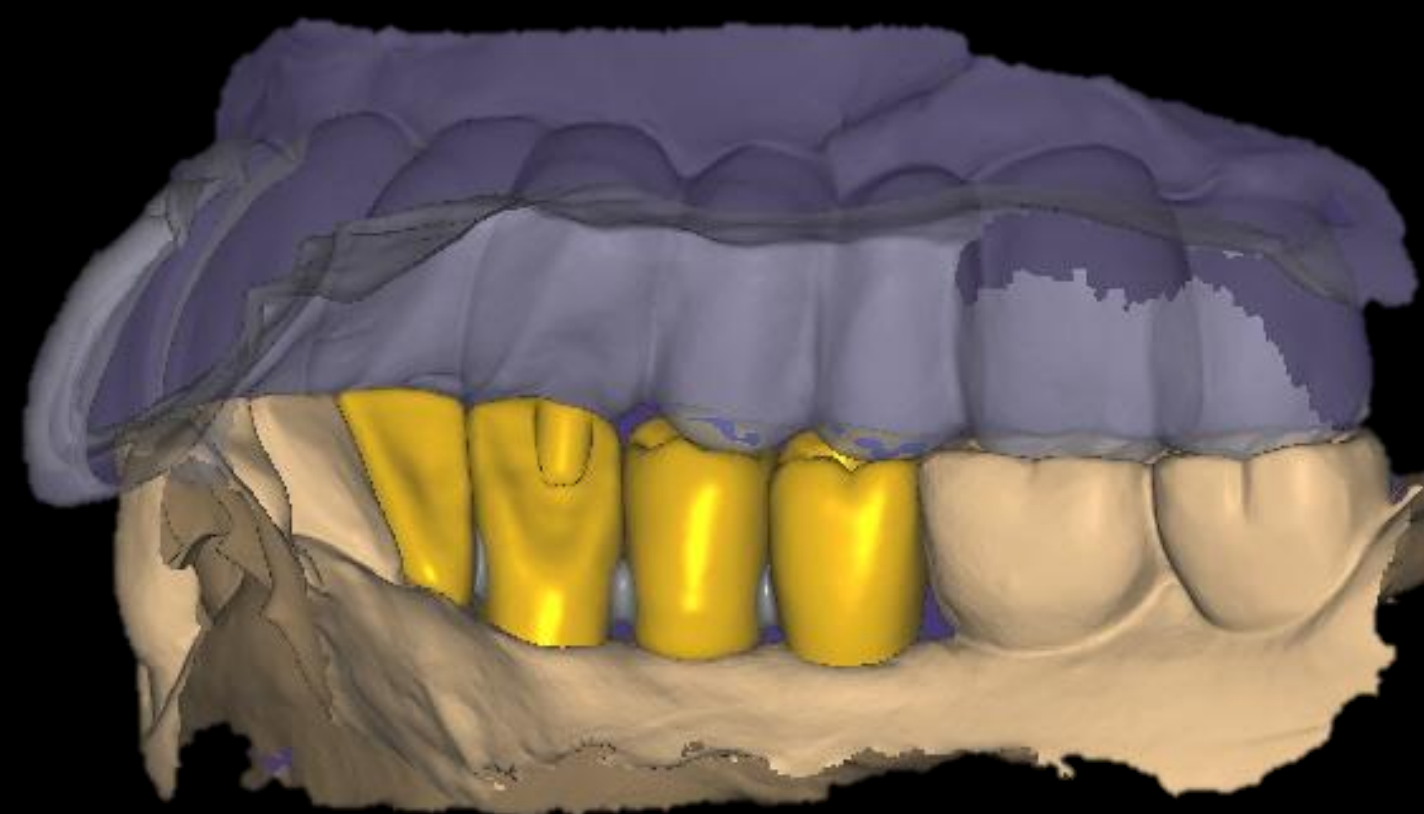
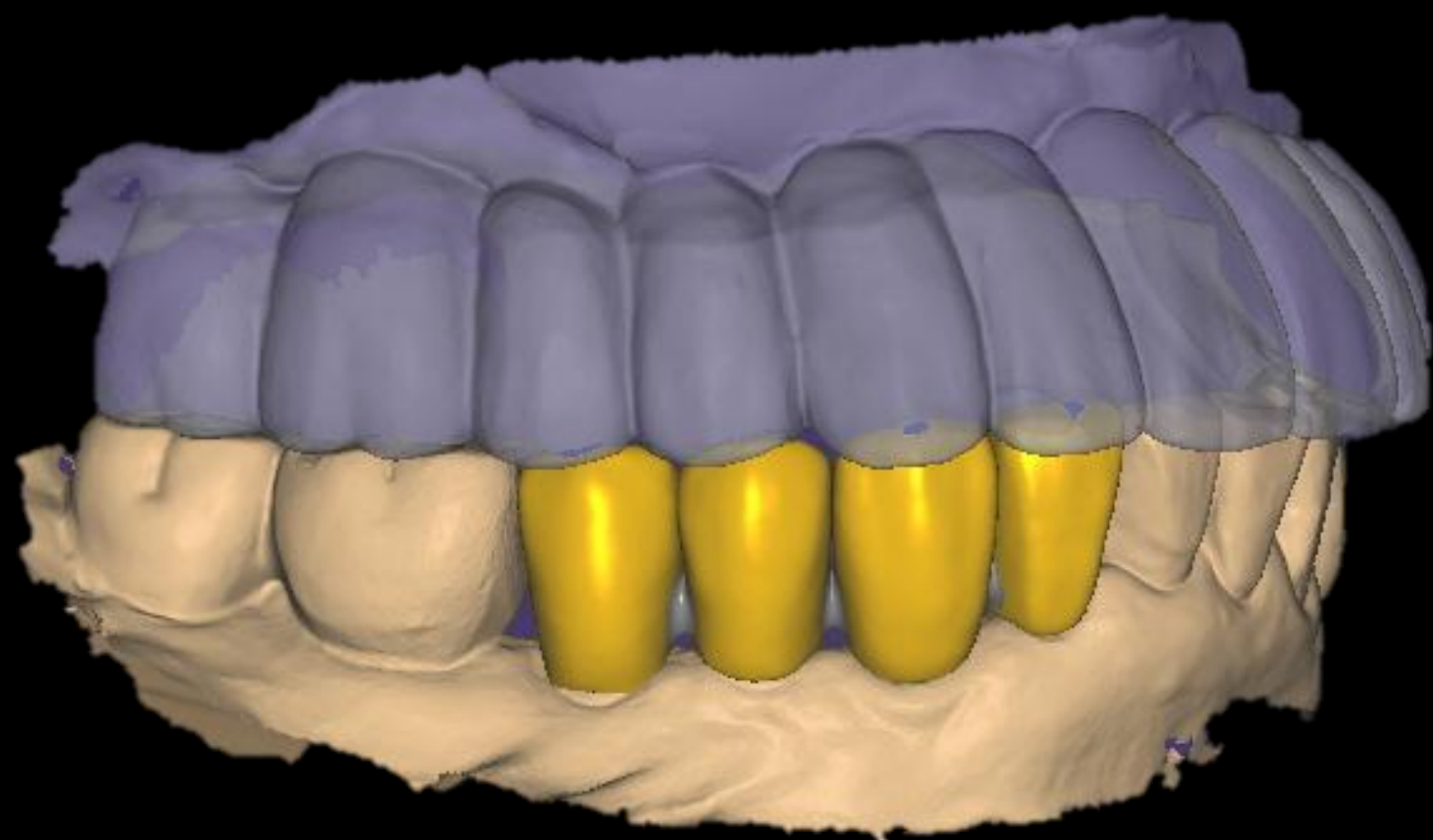
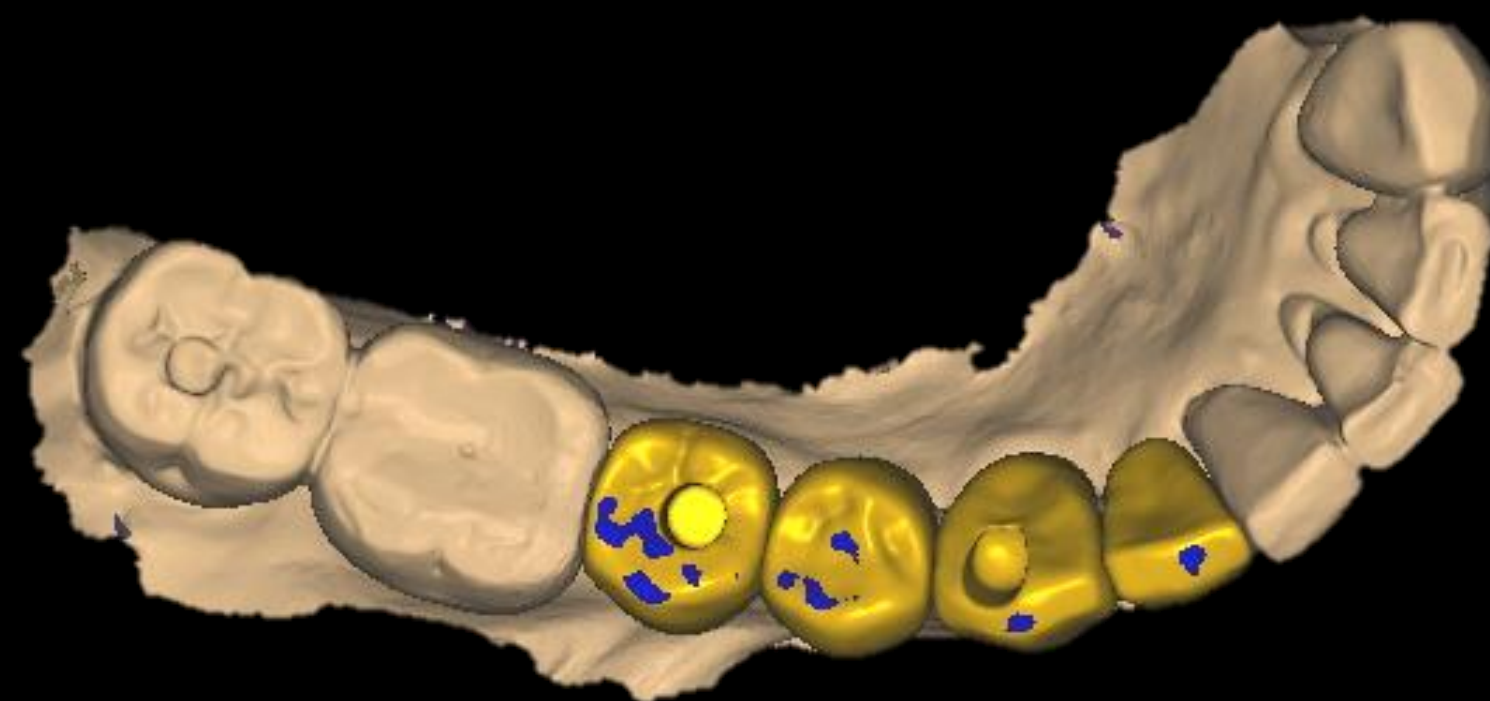
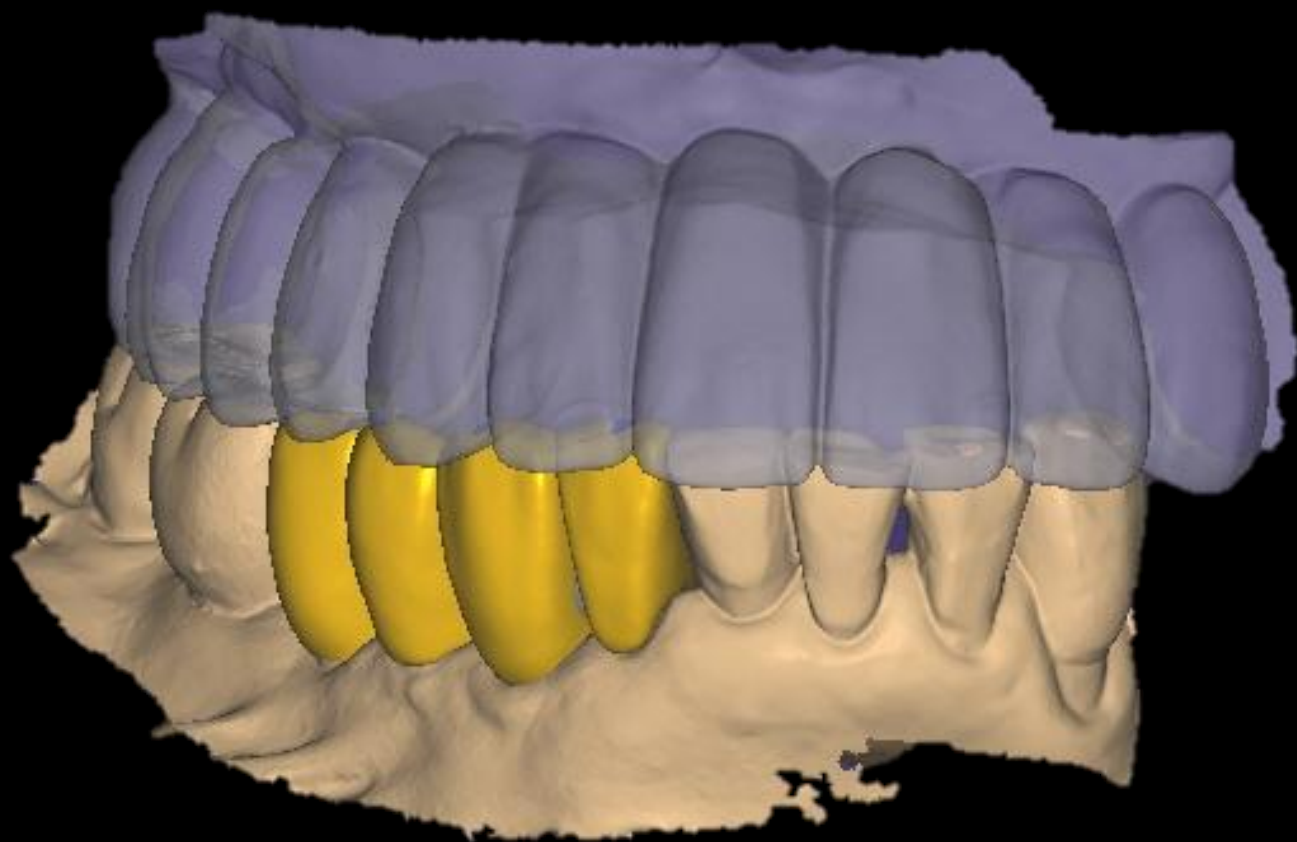
Final Impression (2020-10-15)



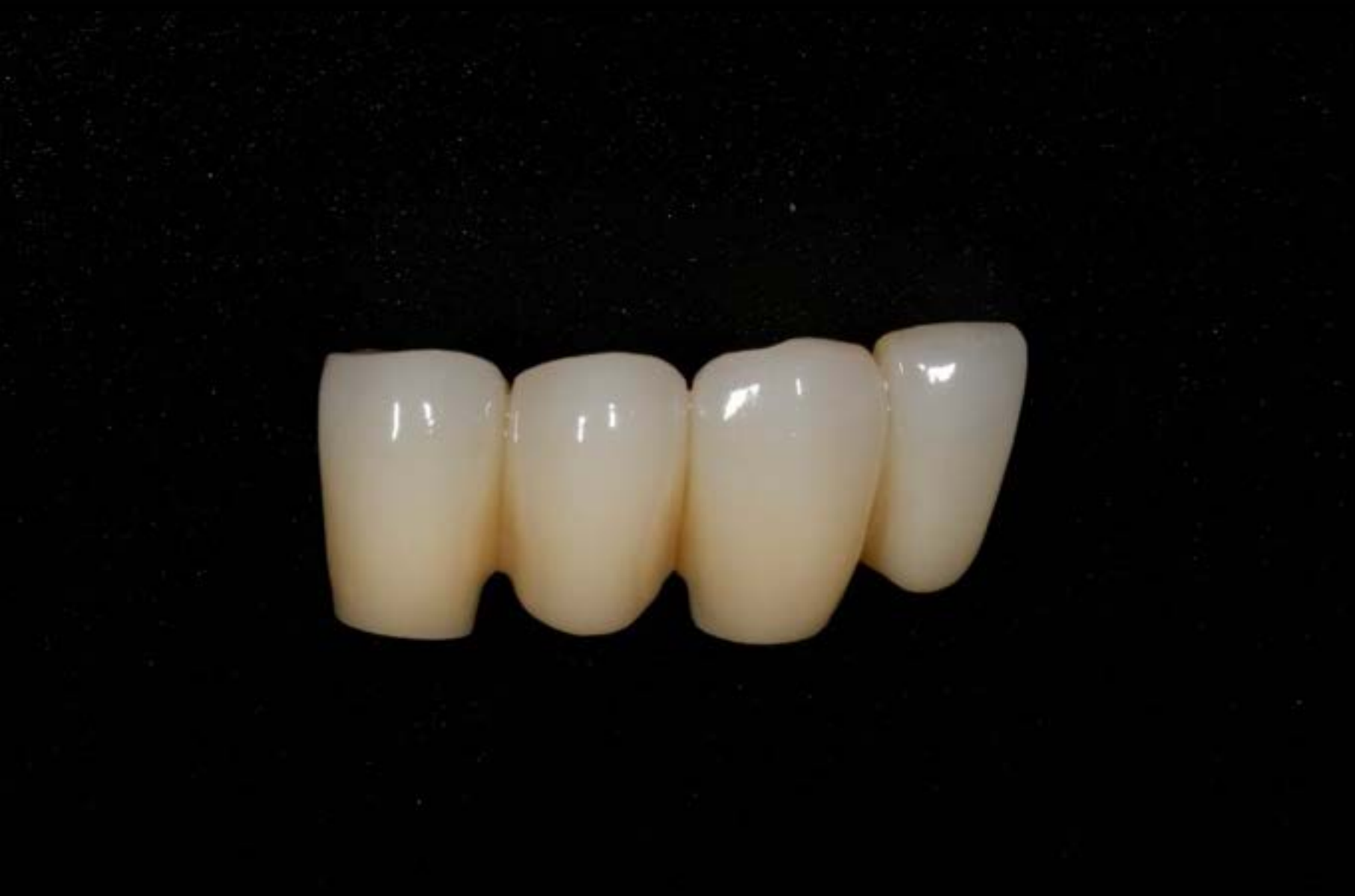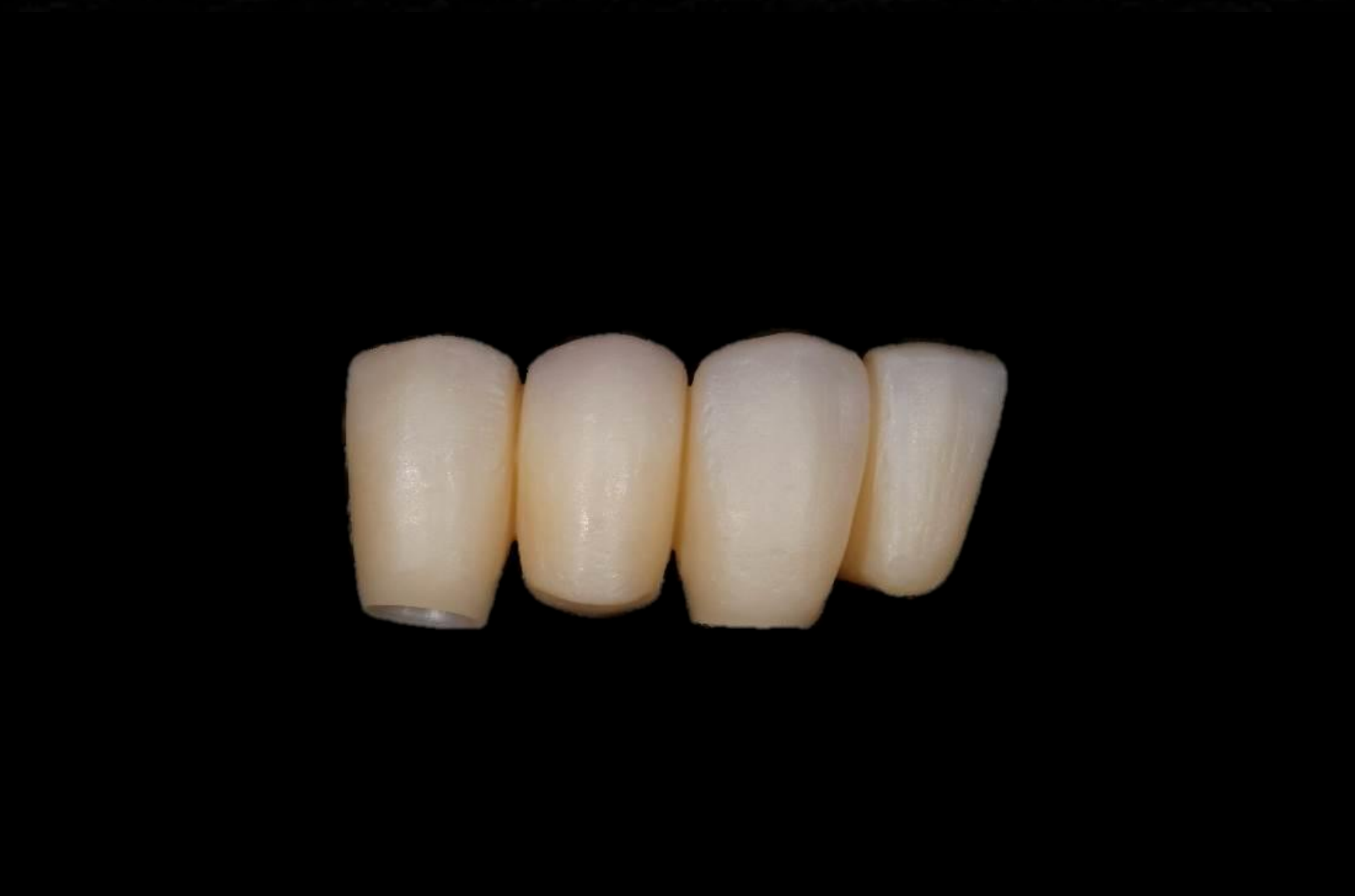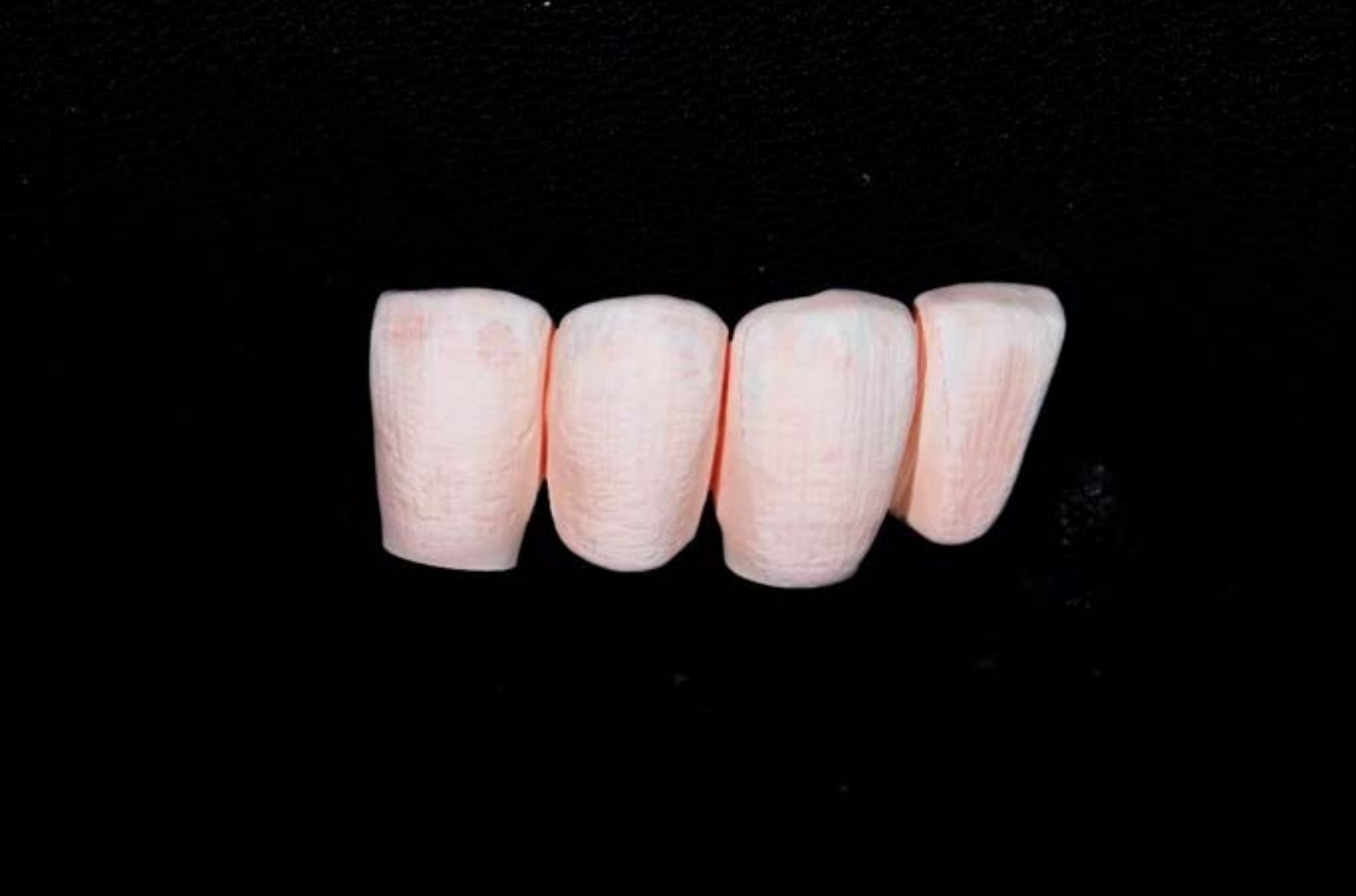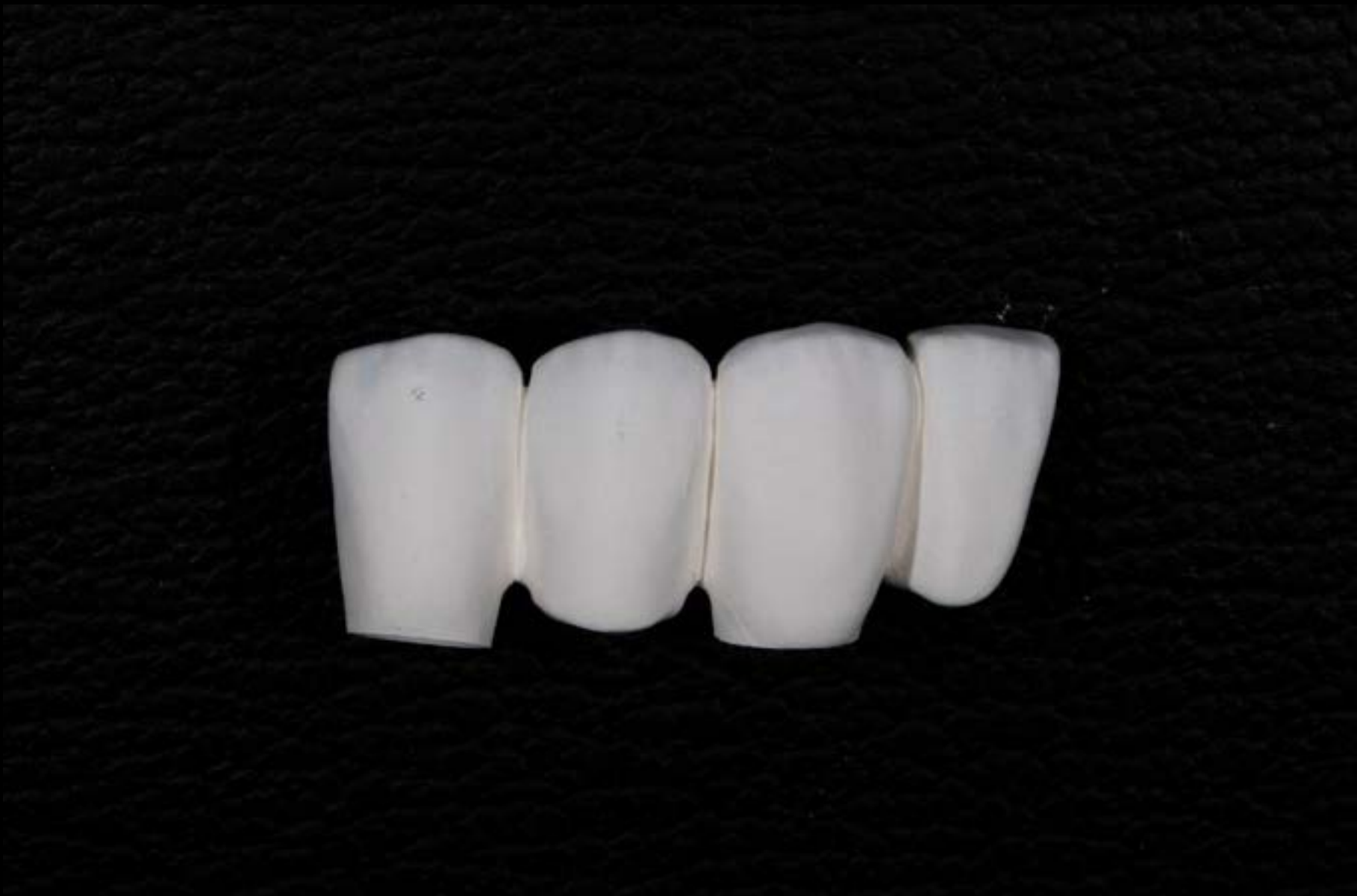Intra Oral Scan



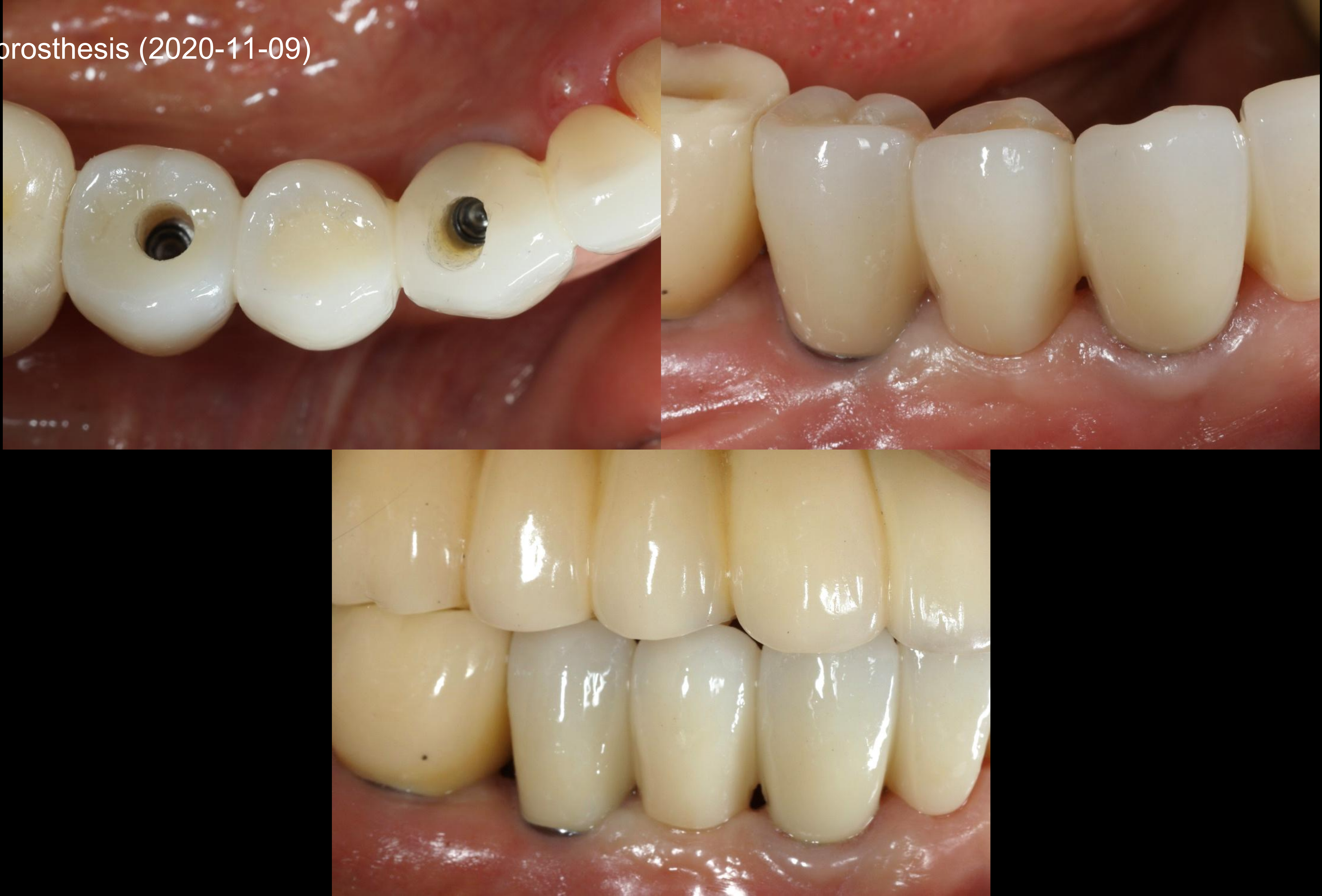CAD (Final prosthesis)

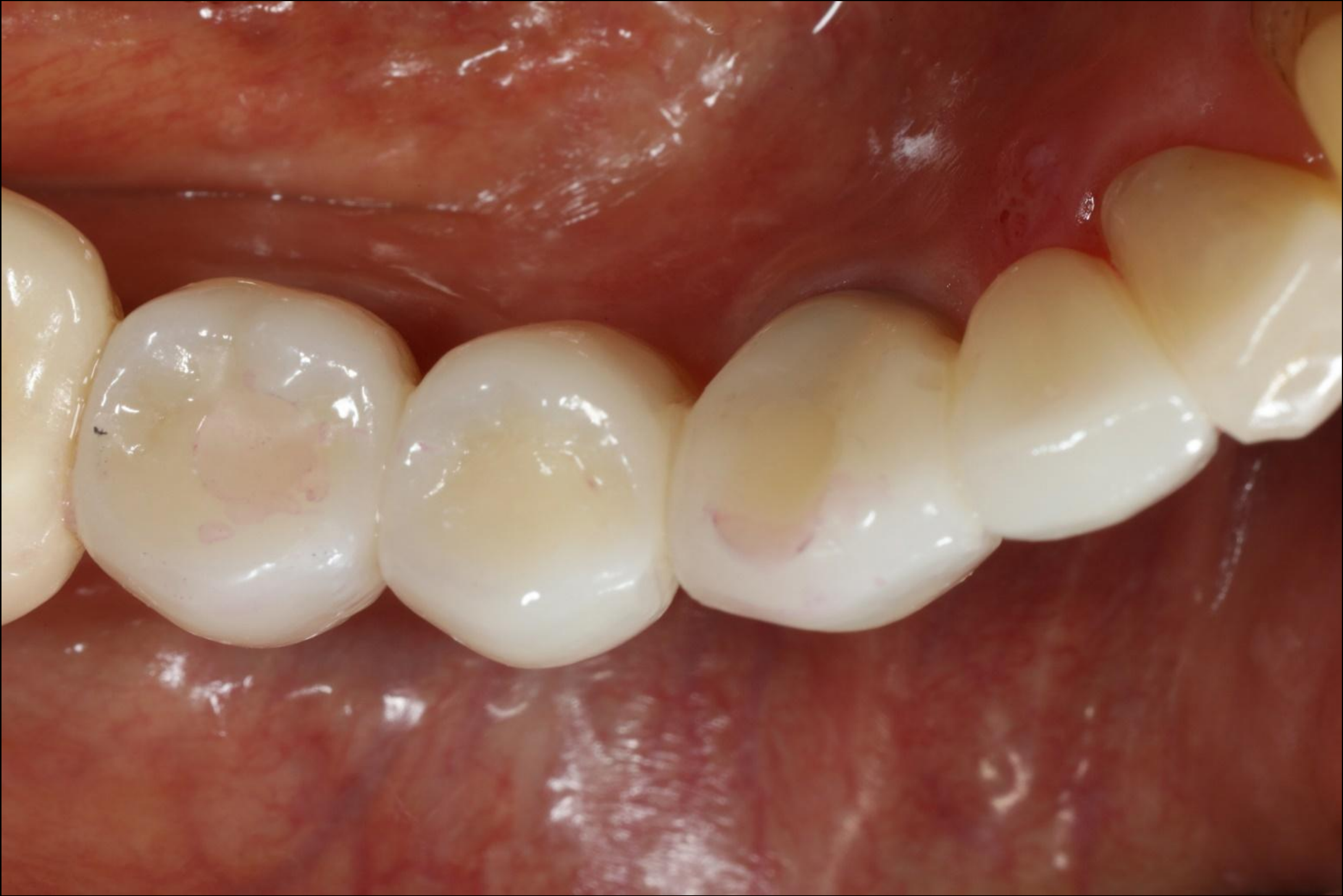

Milling / Coloring / Sintering / Glazing

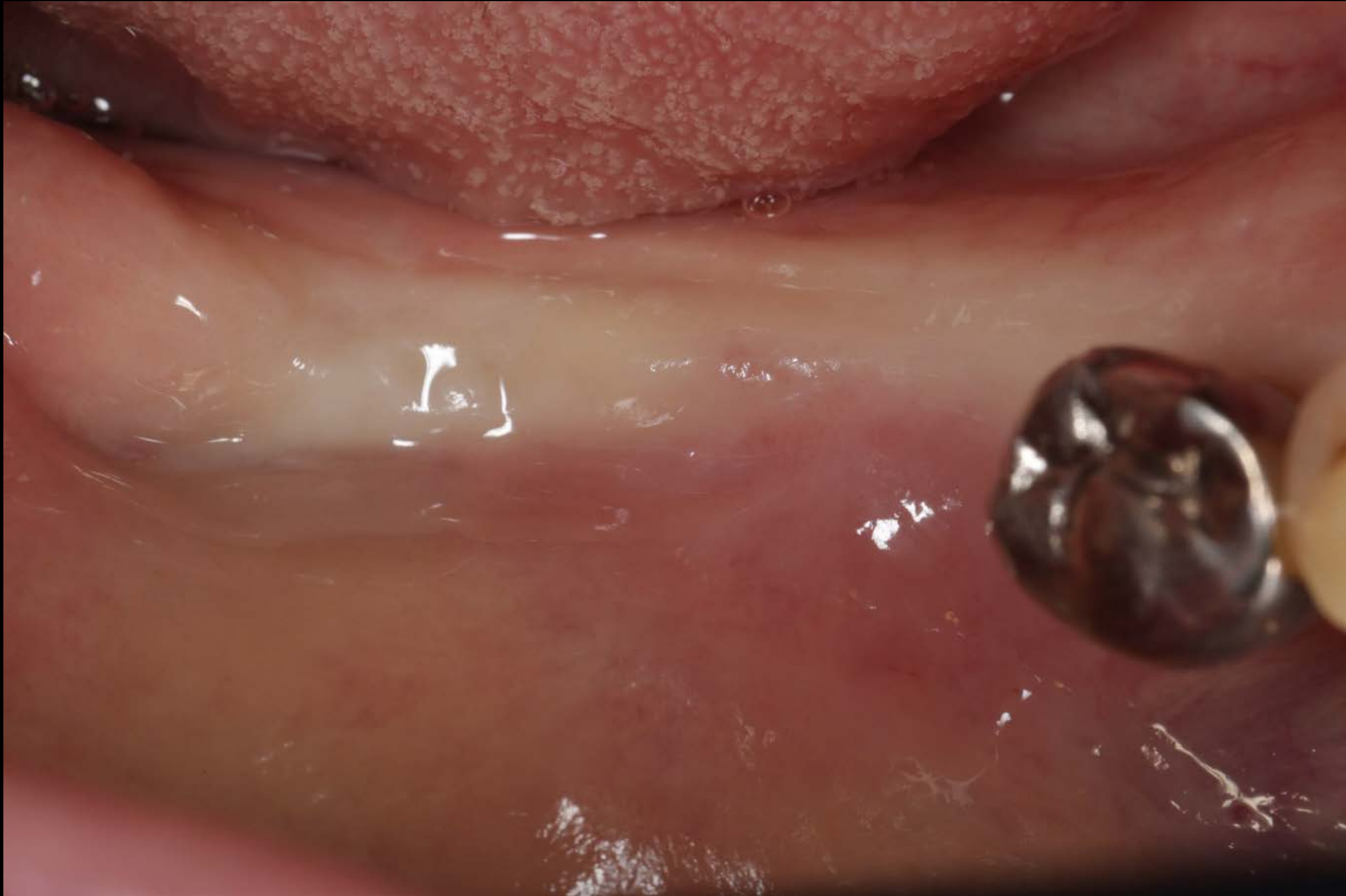

Final prosthesis (2020-11-09)

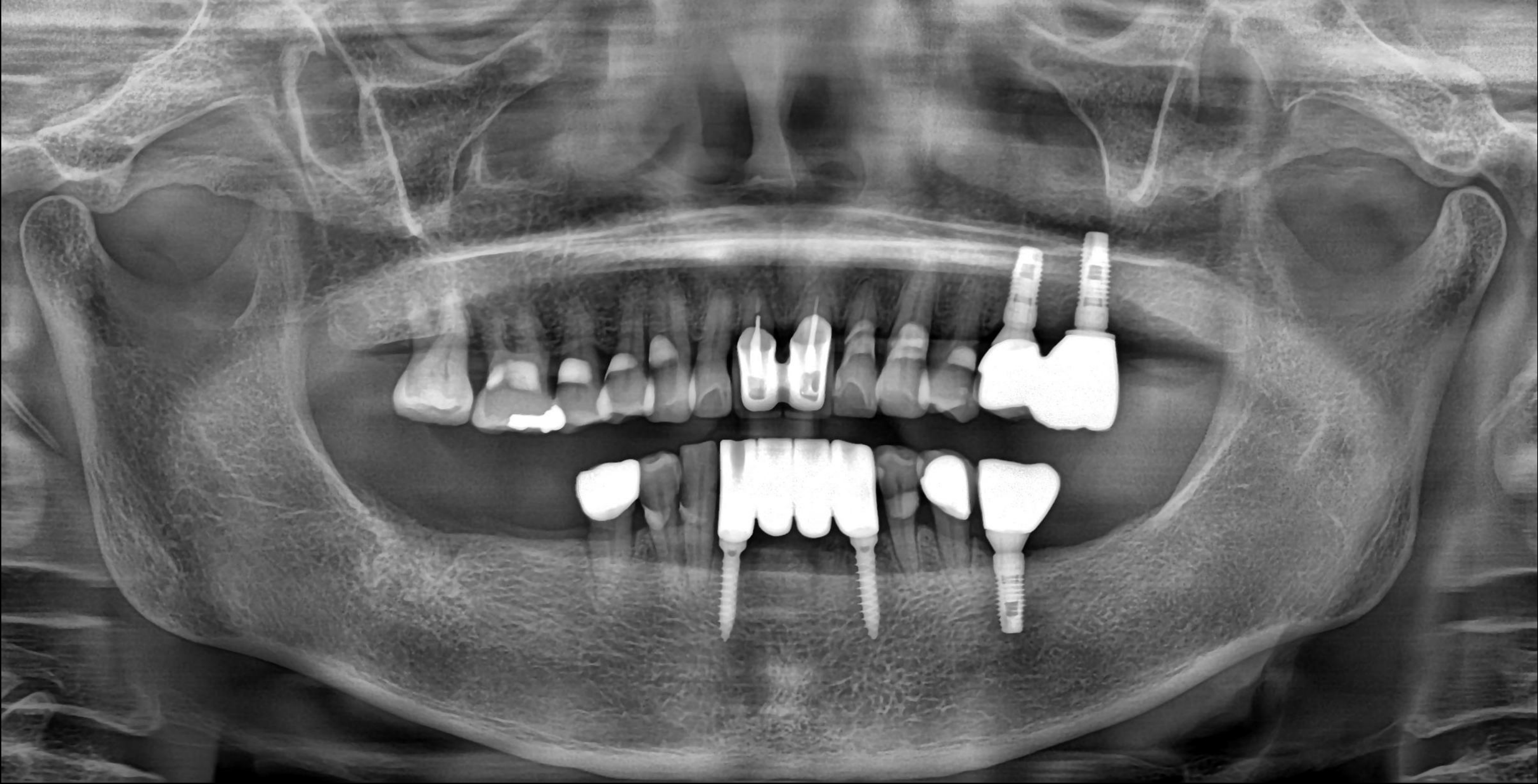



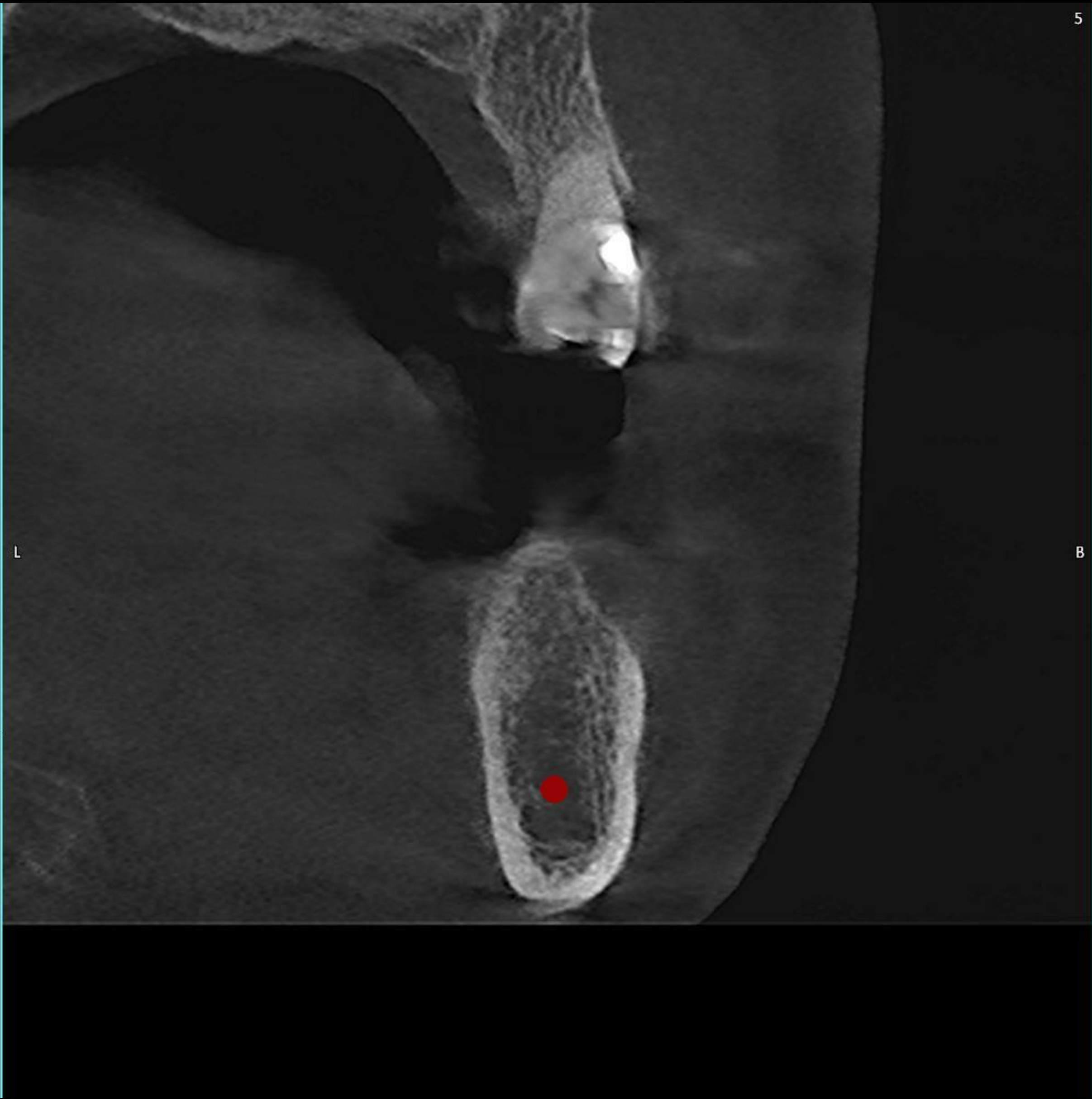
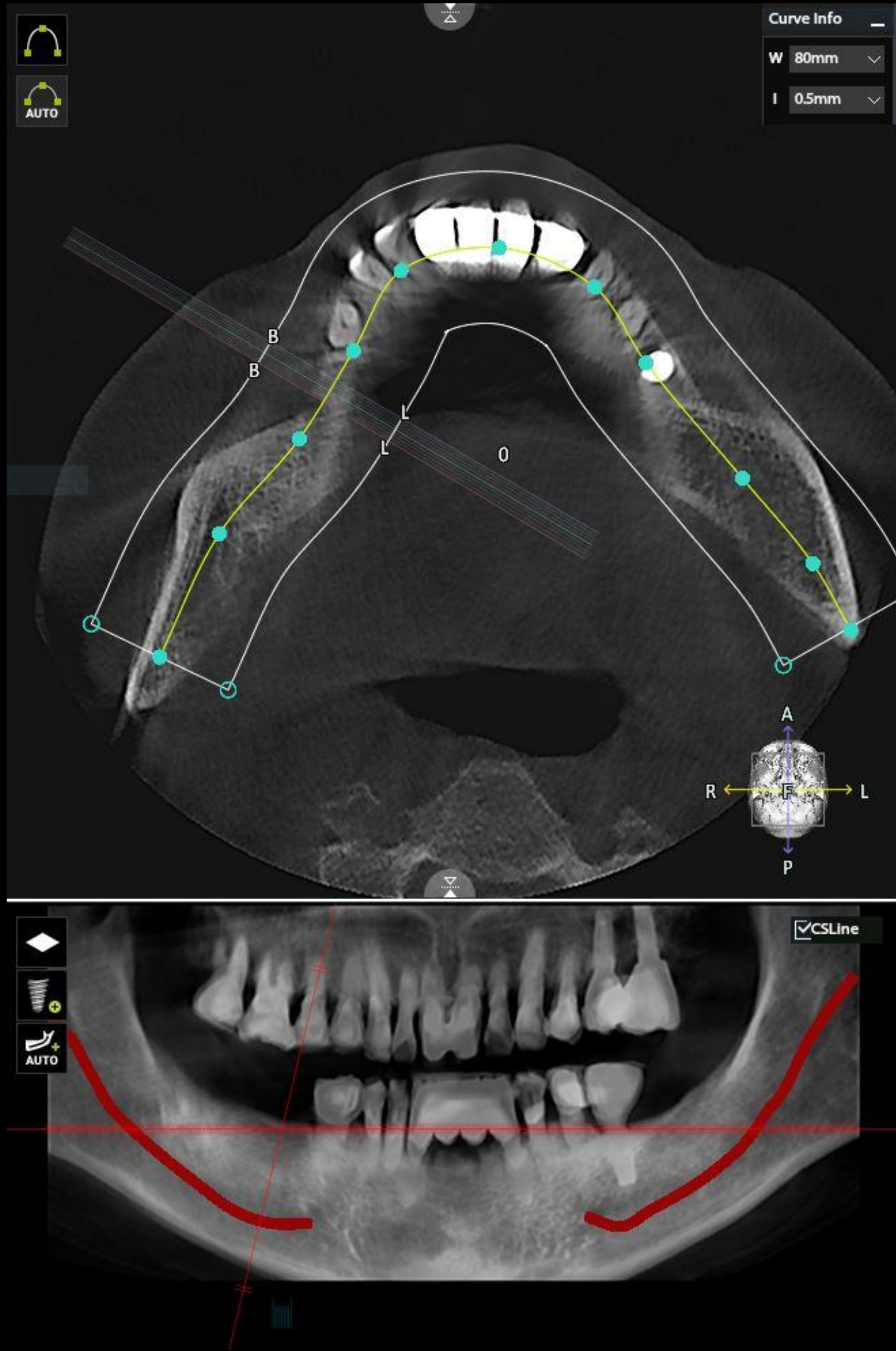
Pre-op (2023-04-19)



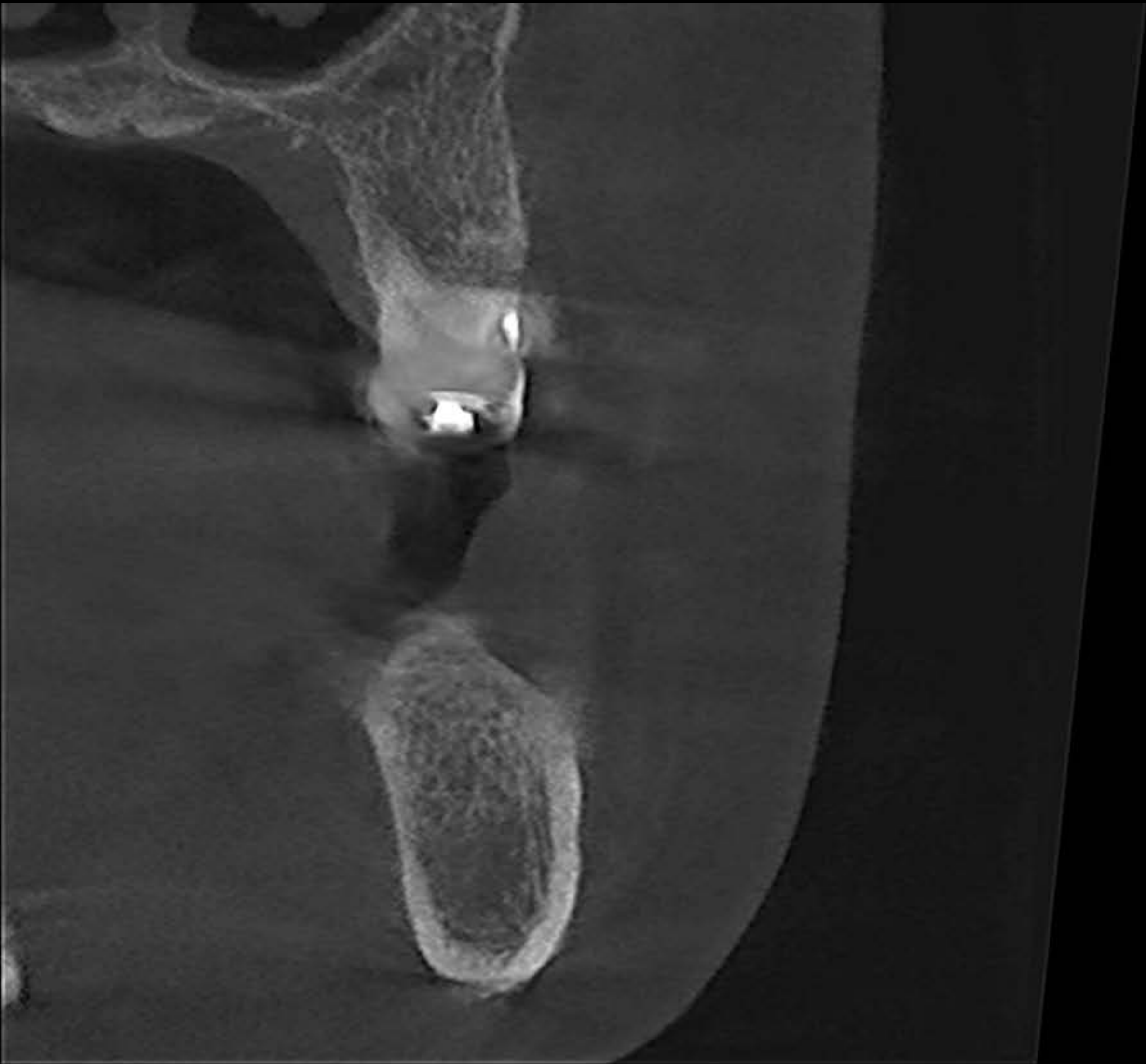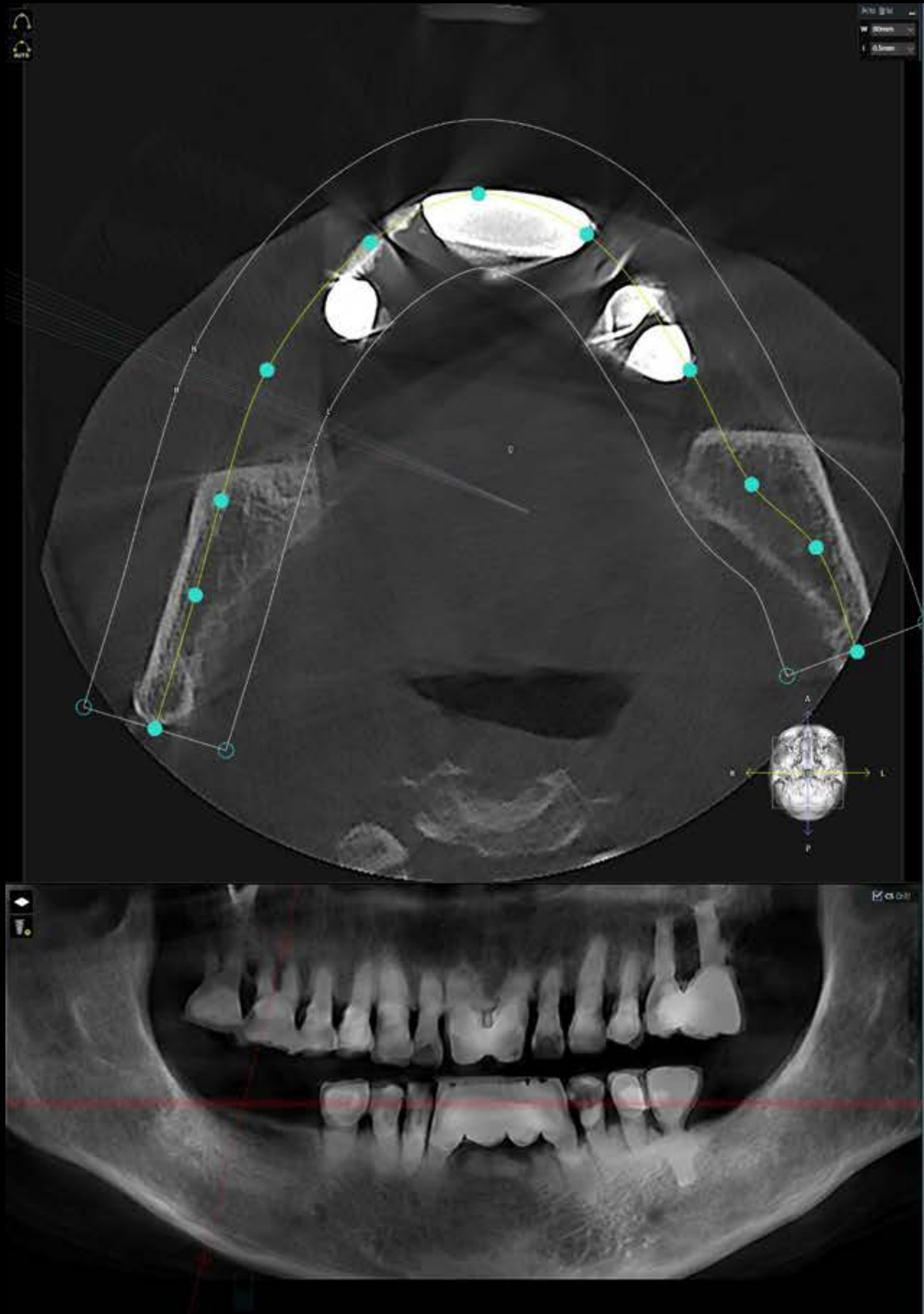
Pre-op (2022-12-08)



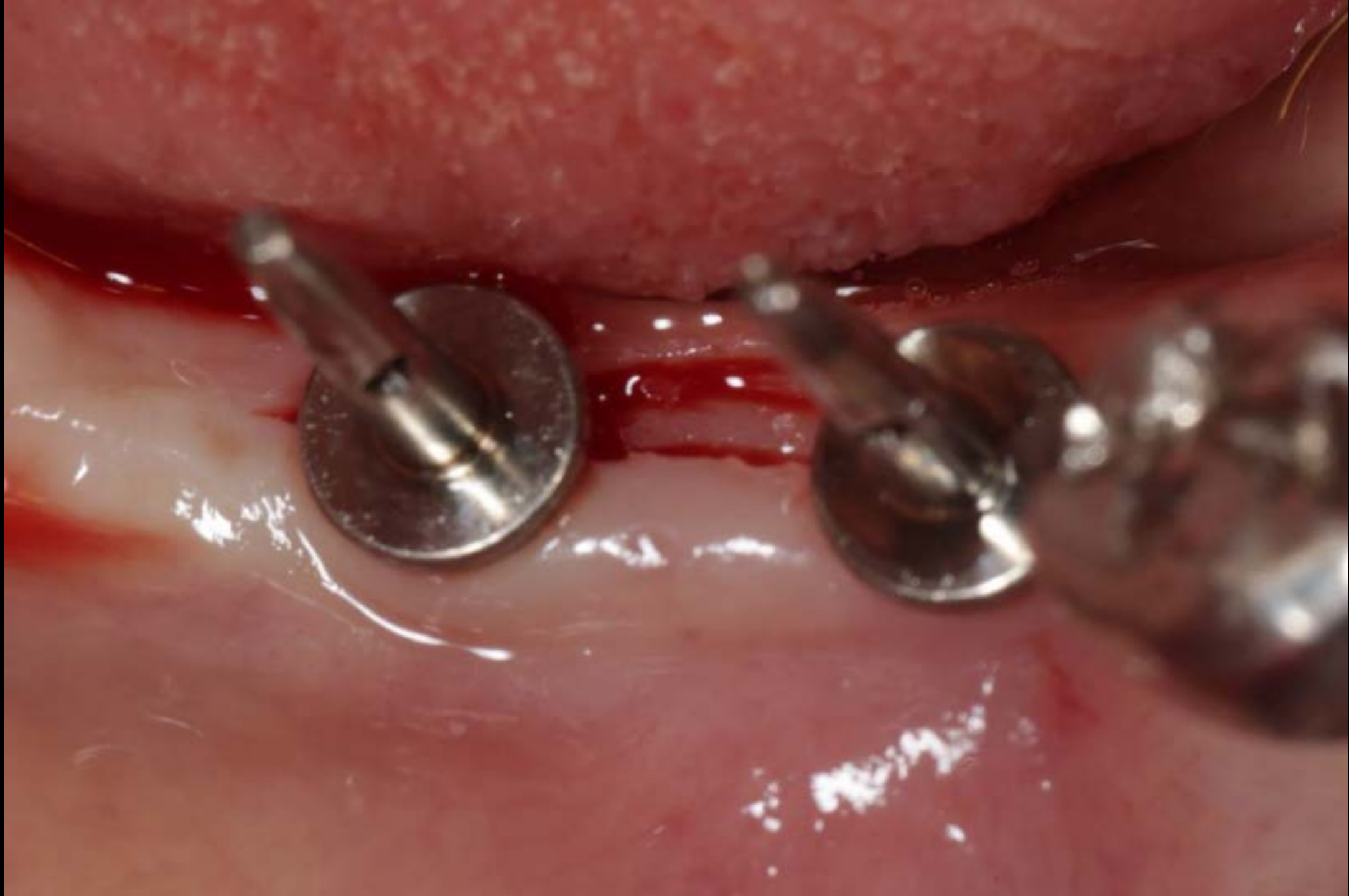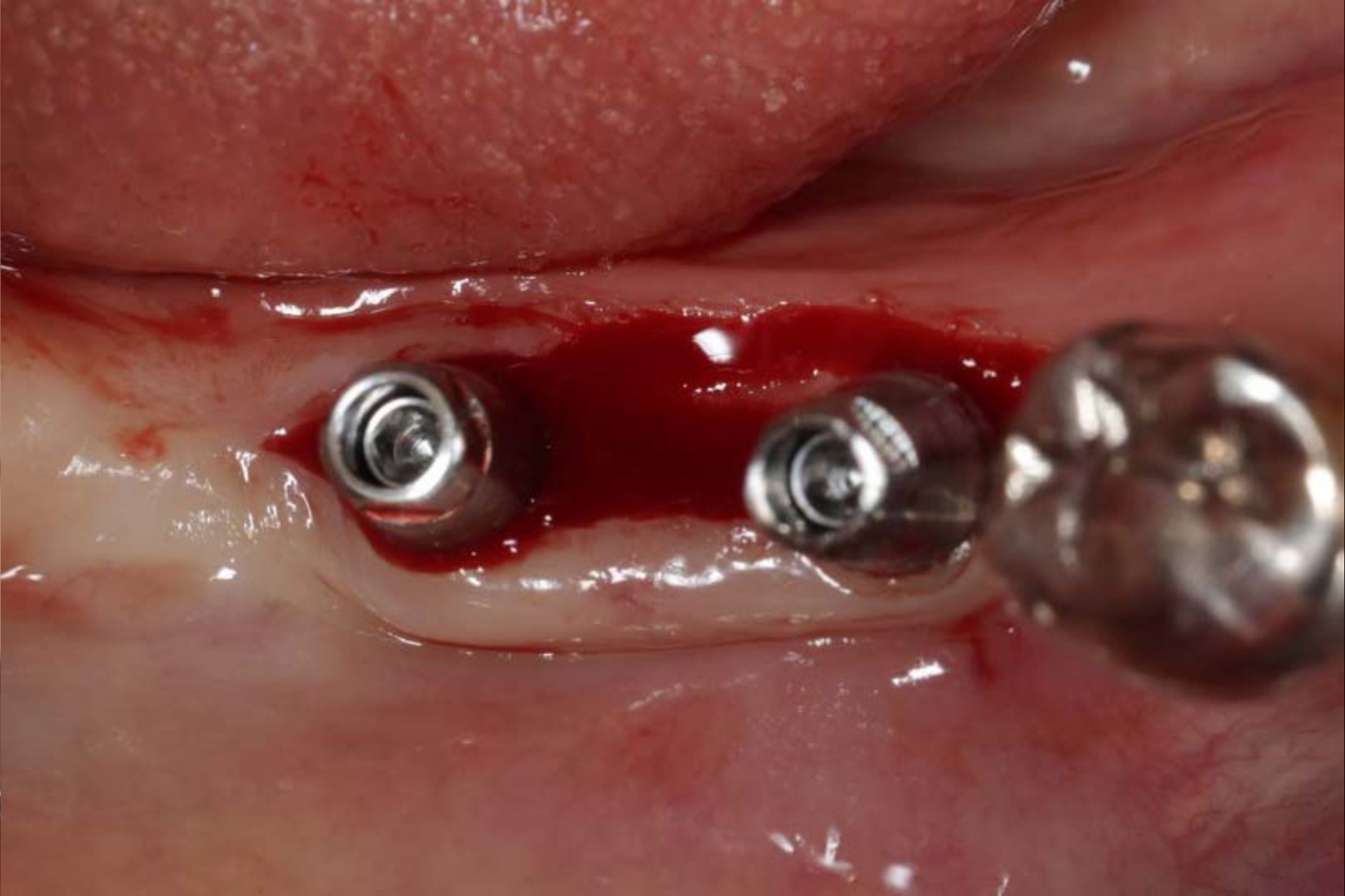
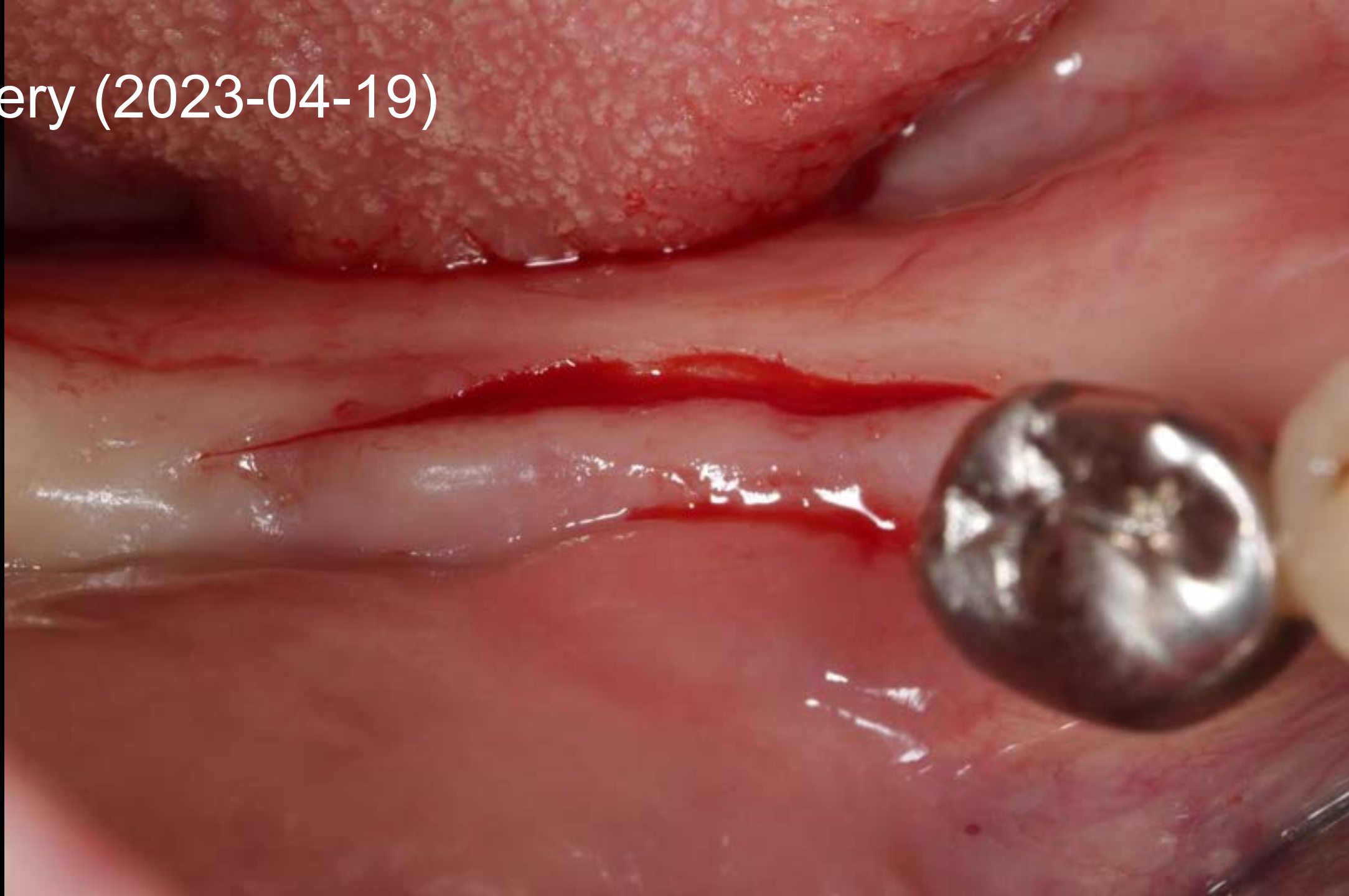#46 Pre-op CT (2022-12-08)



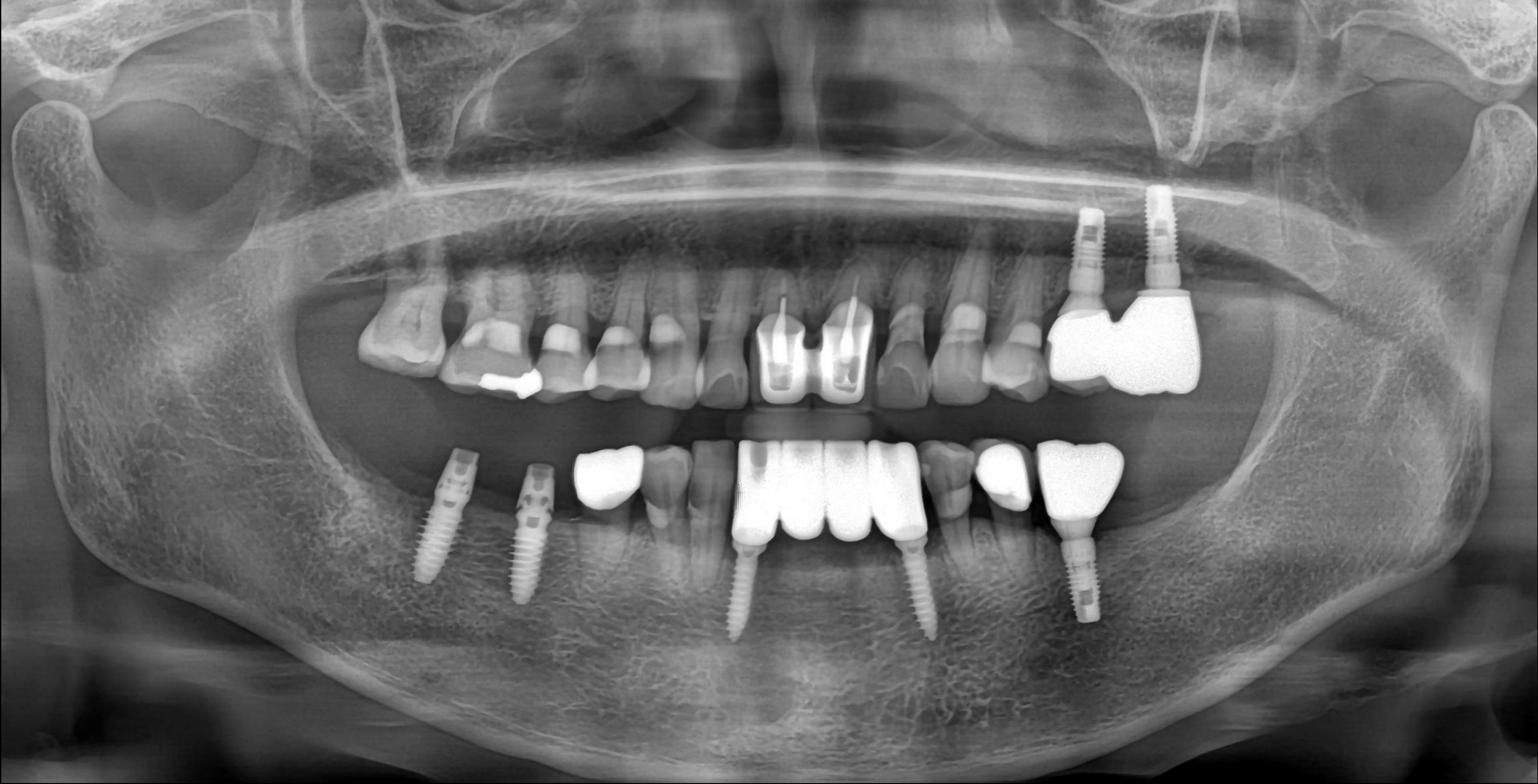#47 Pre-op CT (2022-12-08)



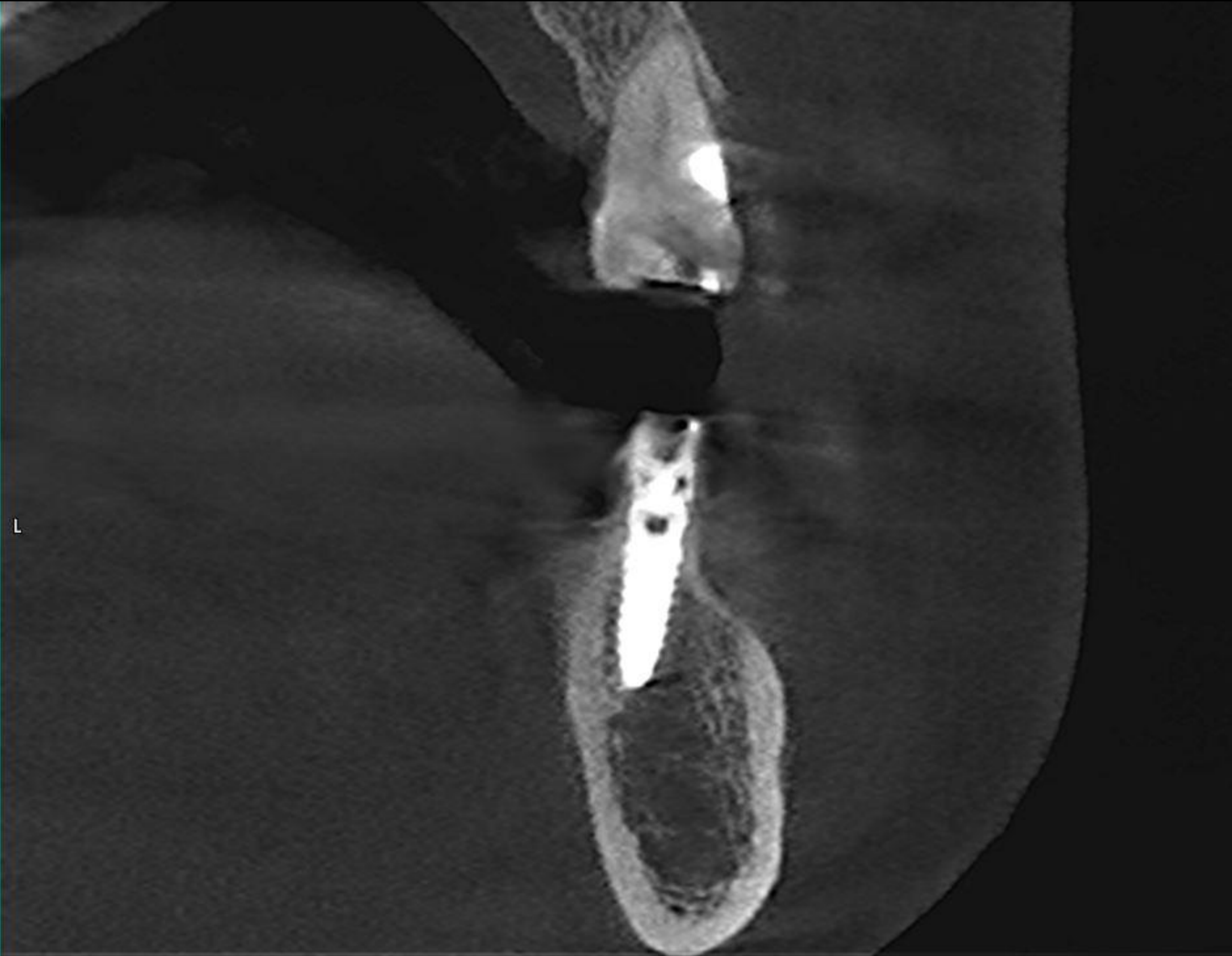
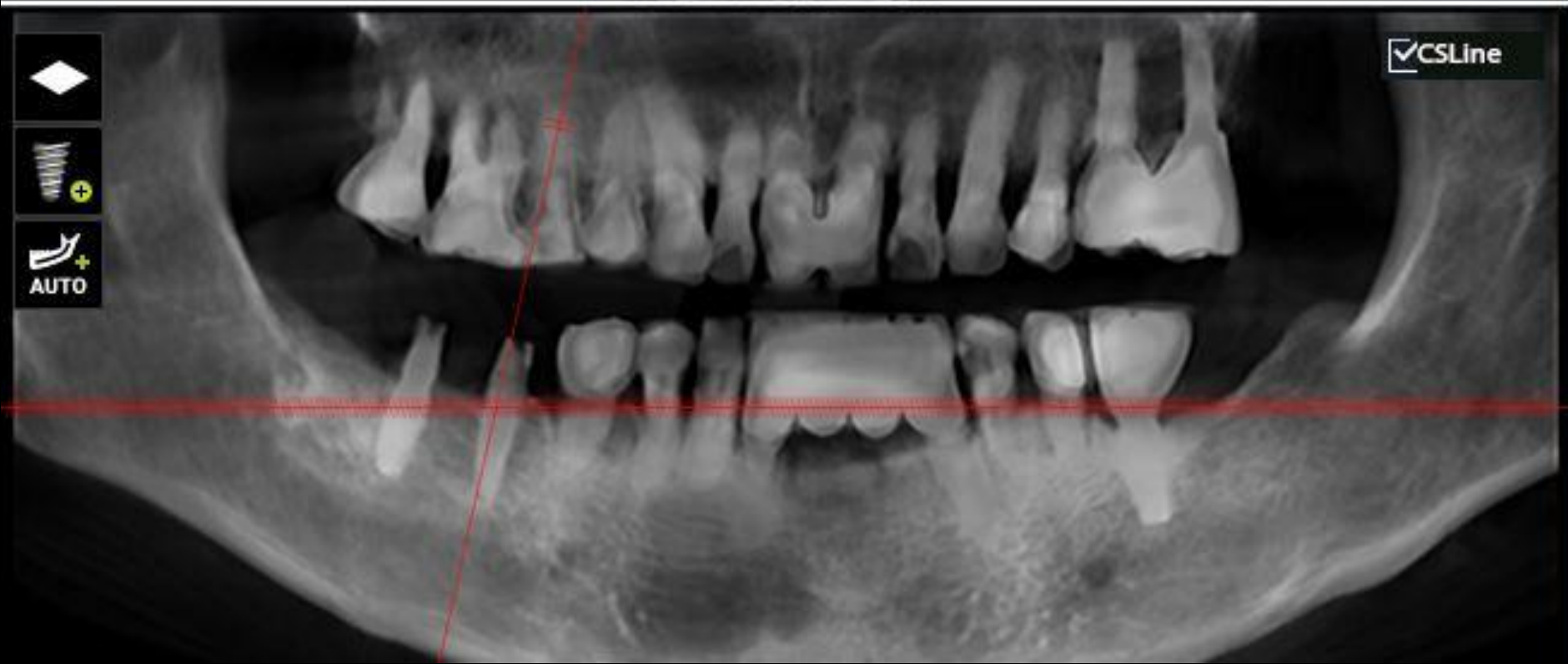
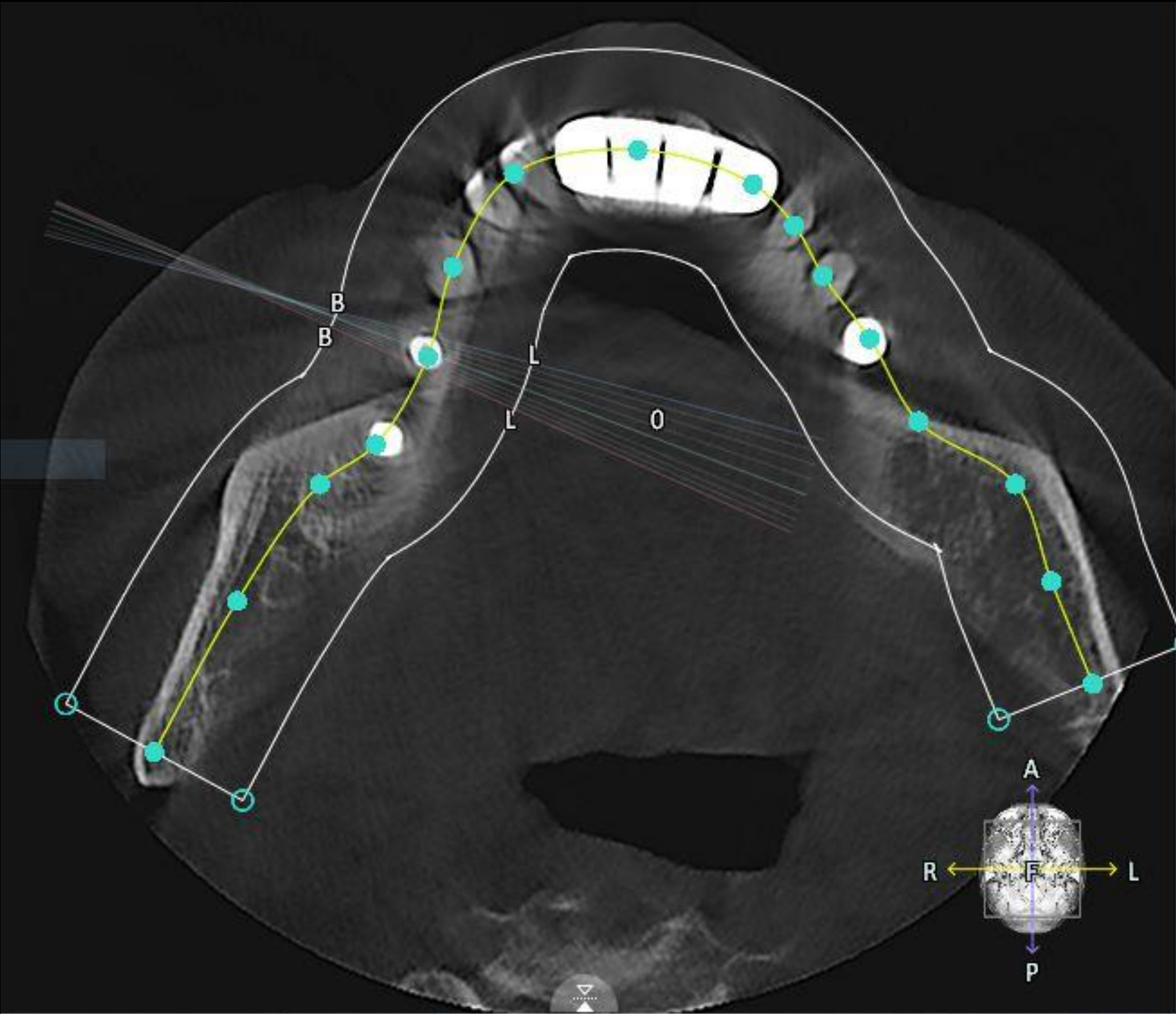
Surgery (2023-04-19)



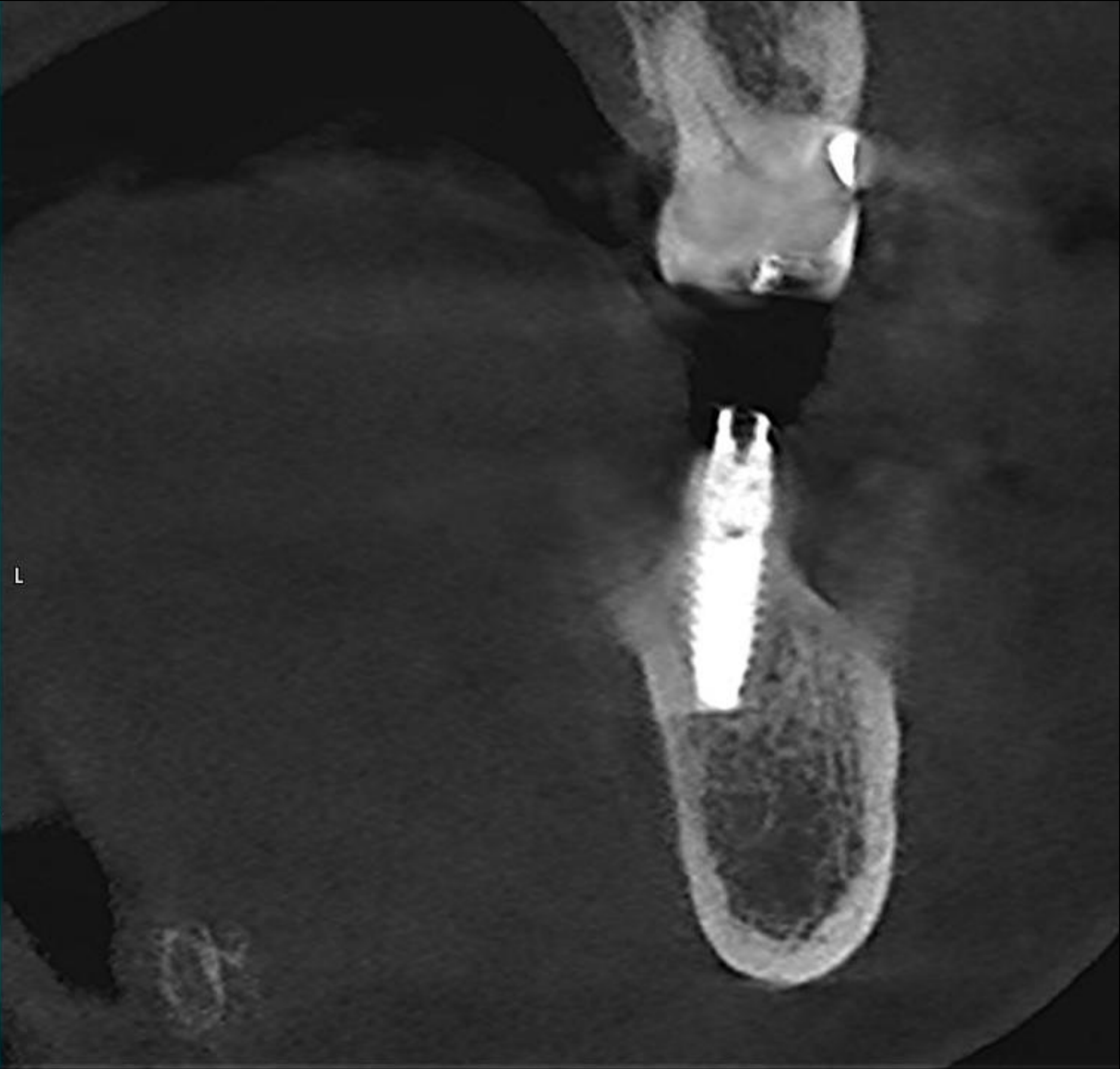
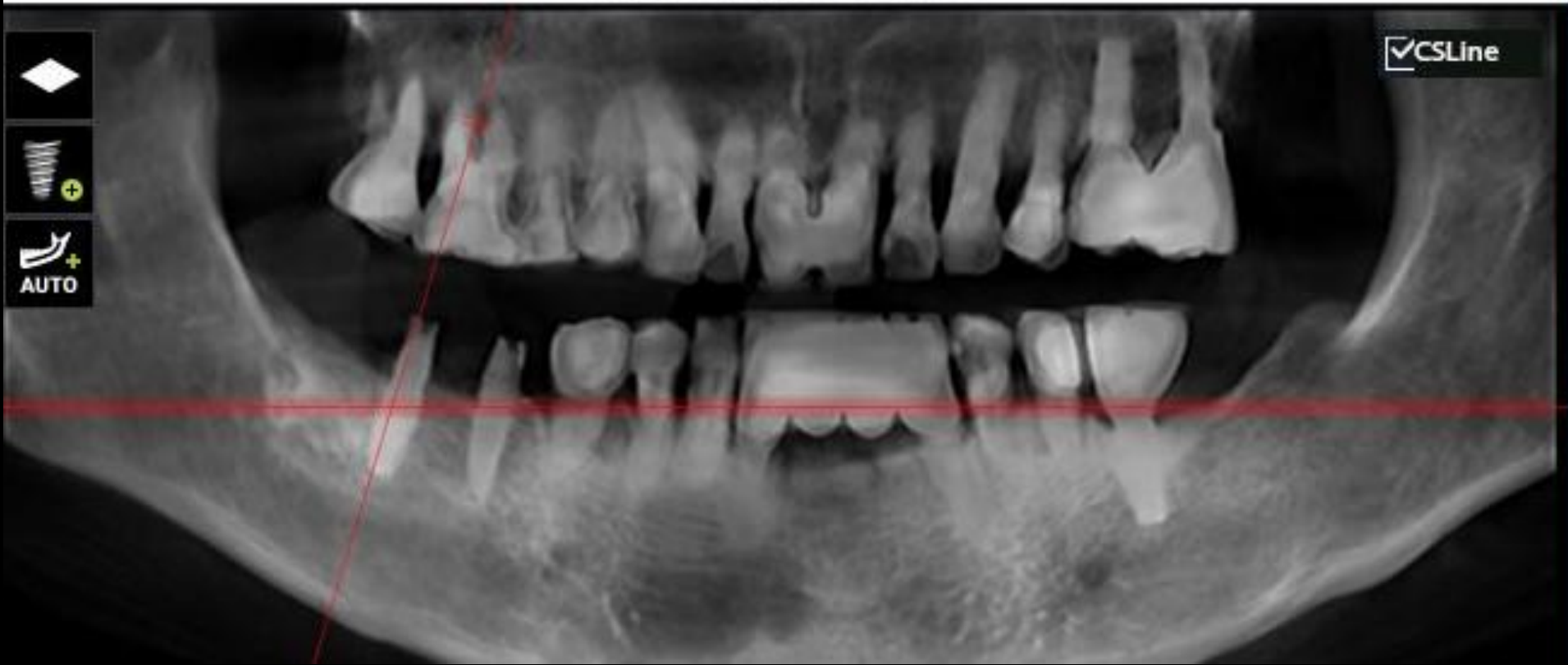
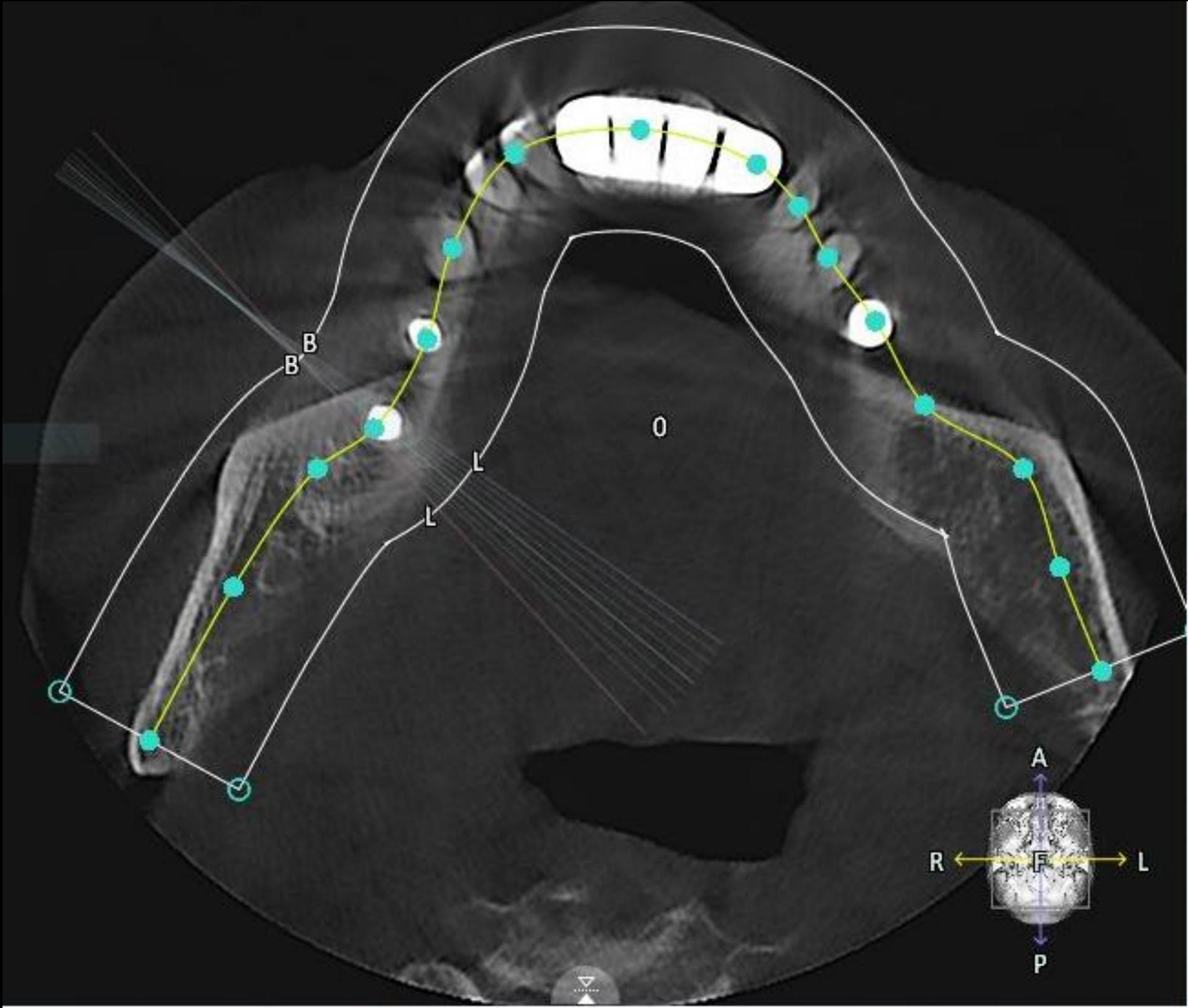
Post-op (2023-04-26)



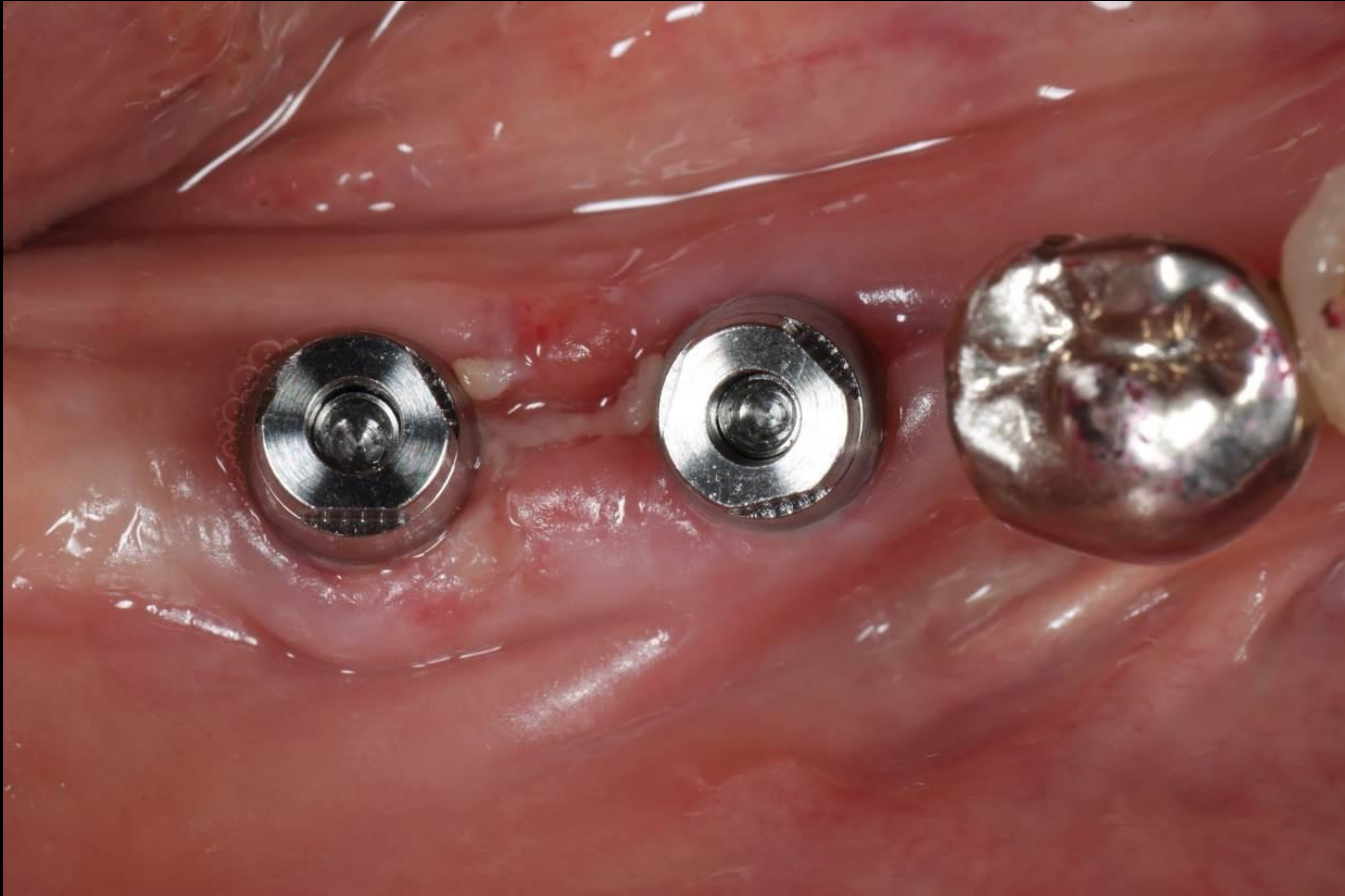
#46 Post-op CT (2023-04-26)



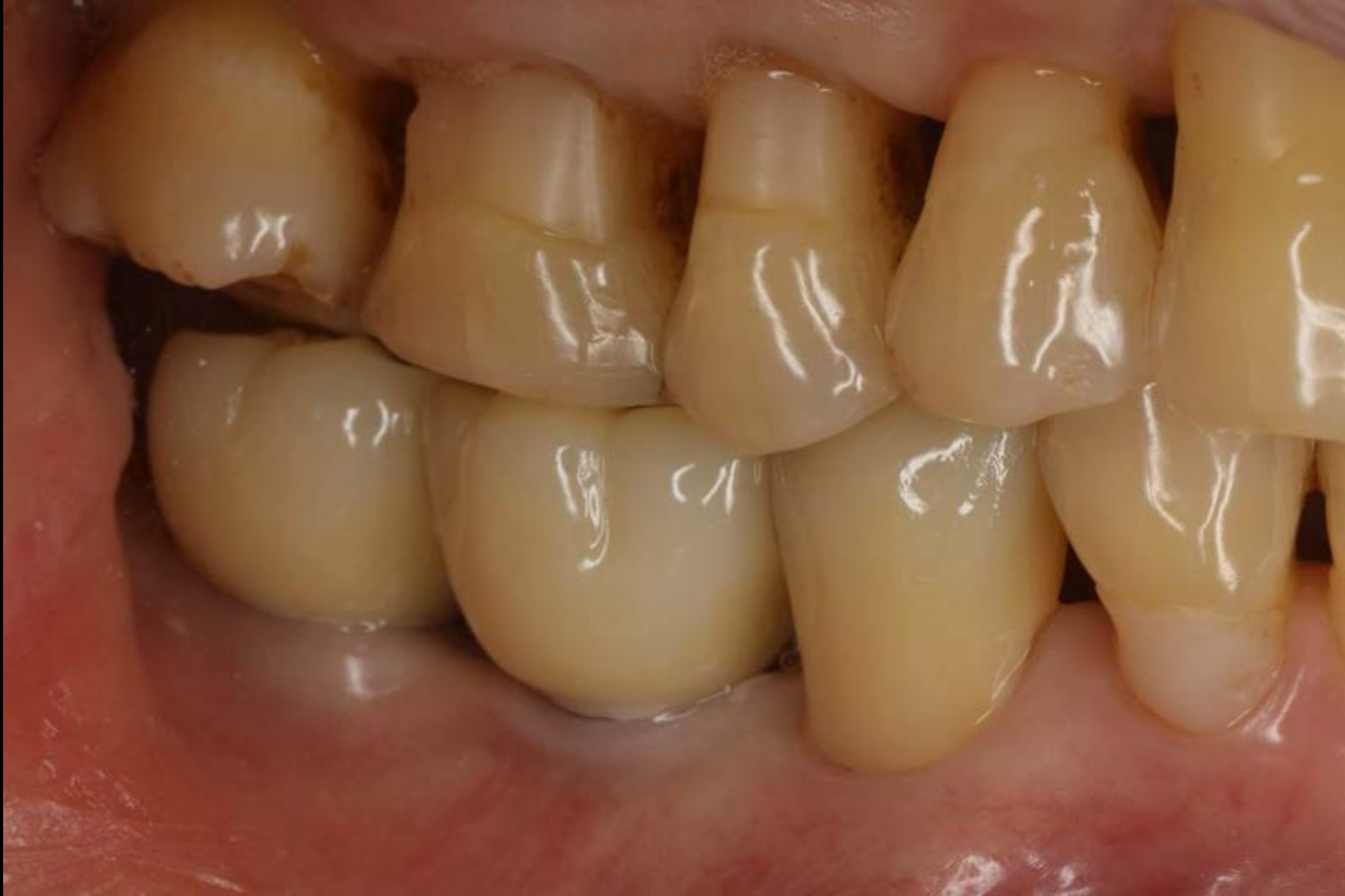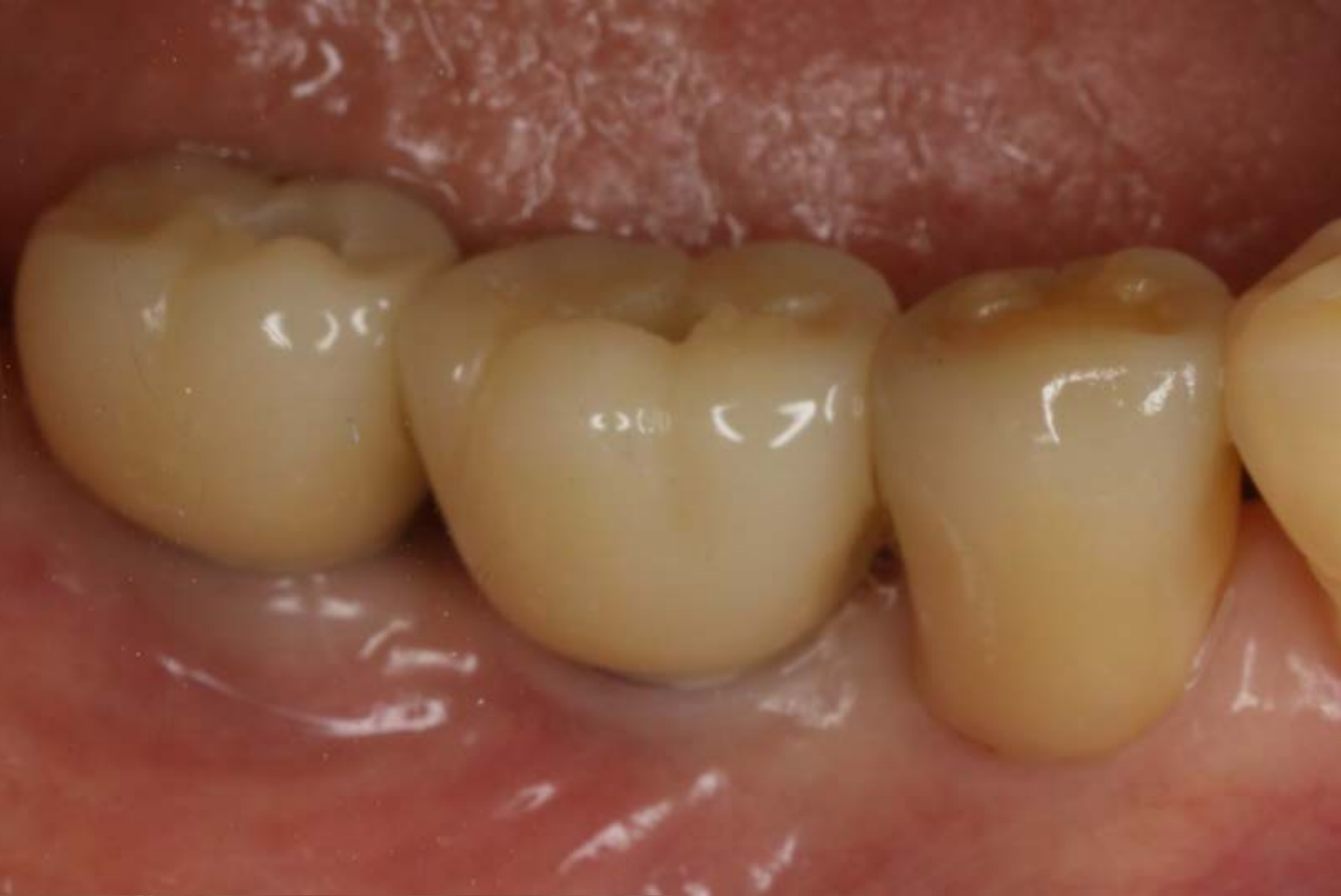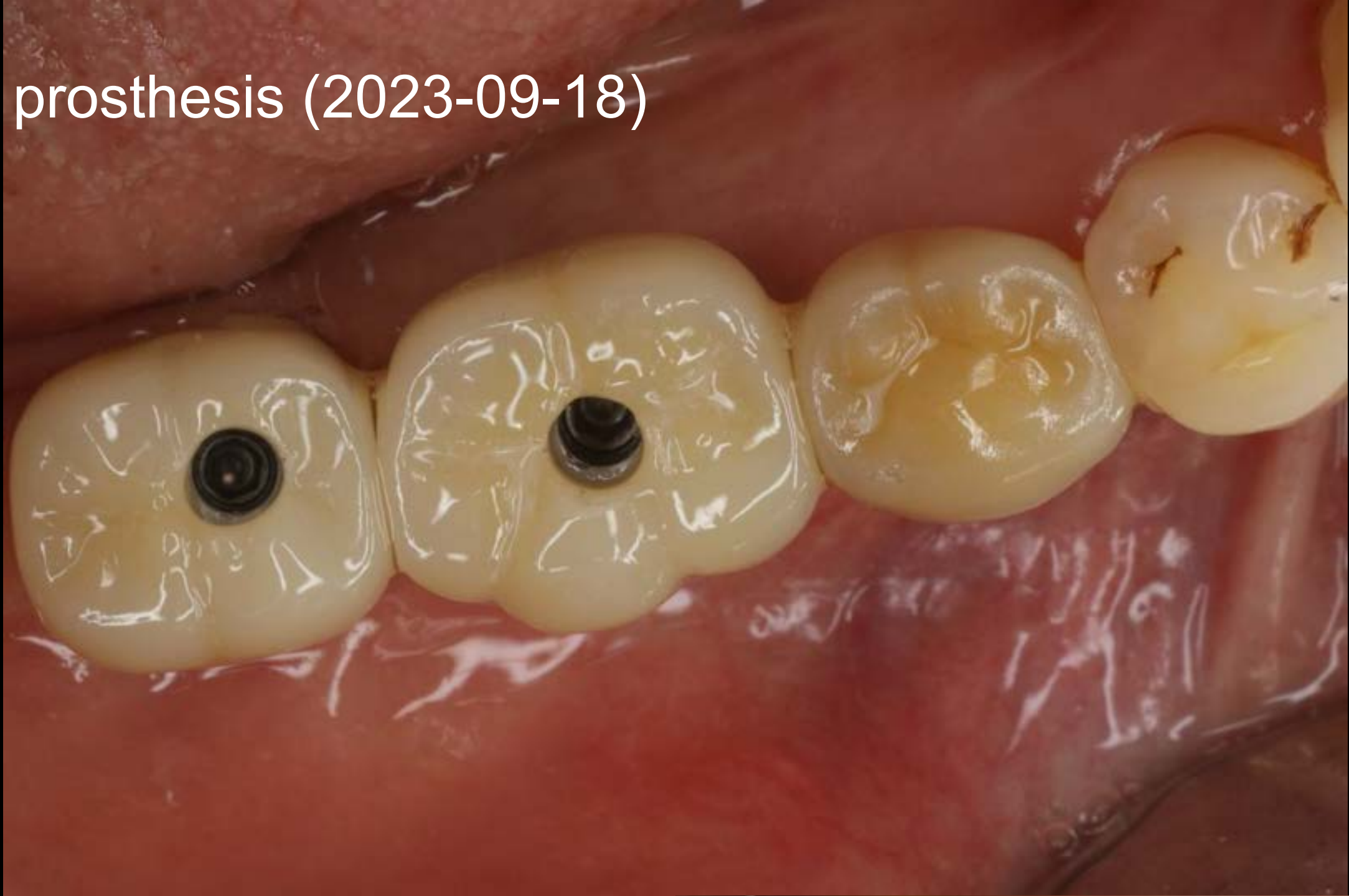#47 Post-op (2023-04-26)



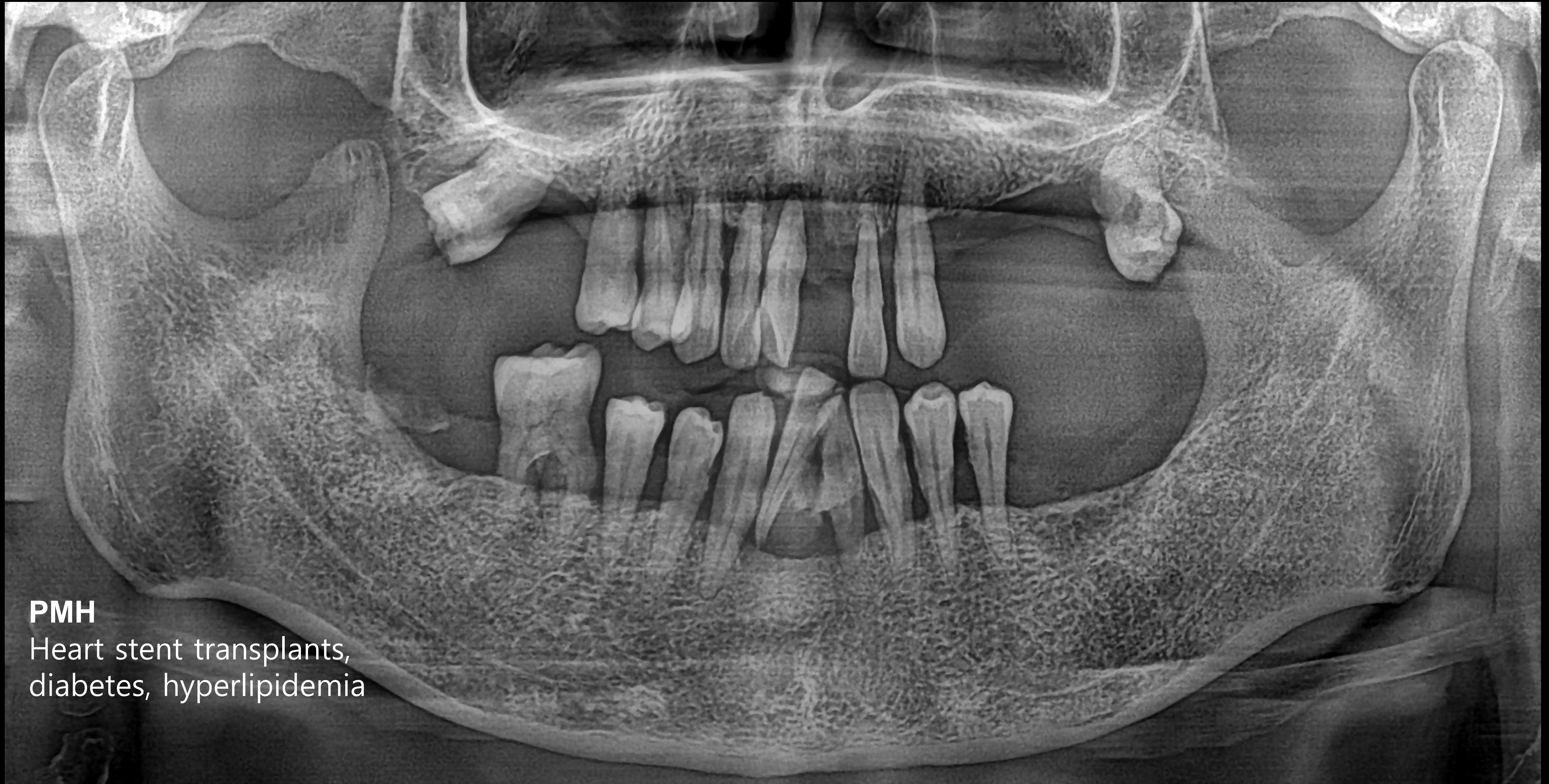Healing : 1 week (2023-04-26)



Final prosthesis (2023-09-18)



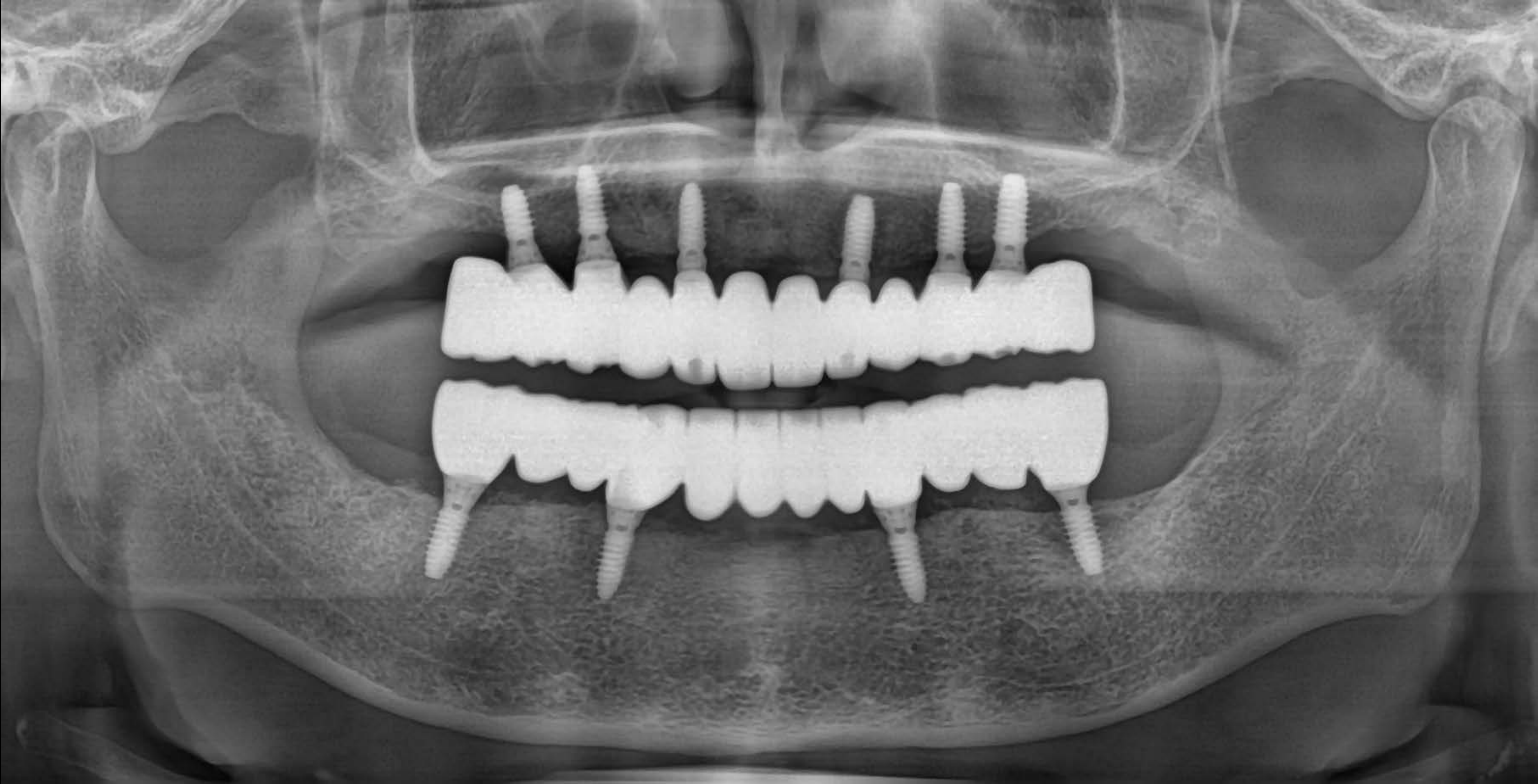Pre-op (2023-08-08)



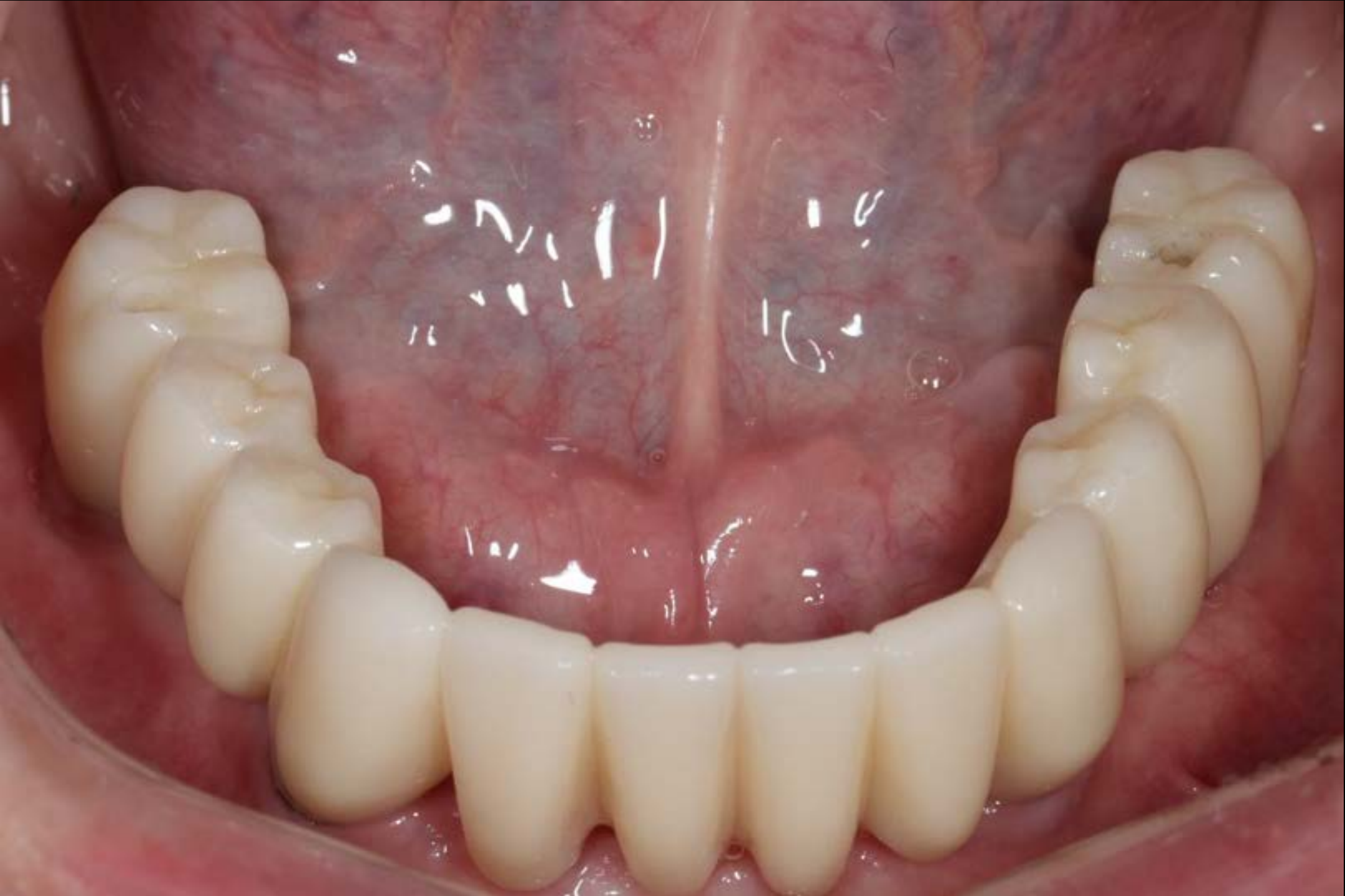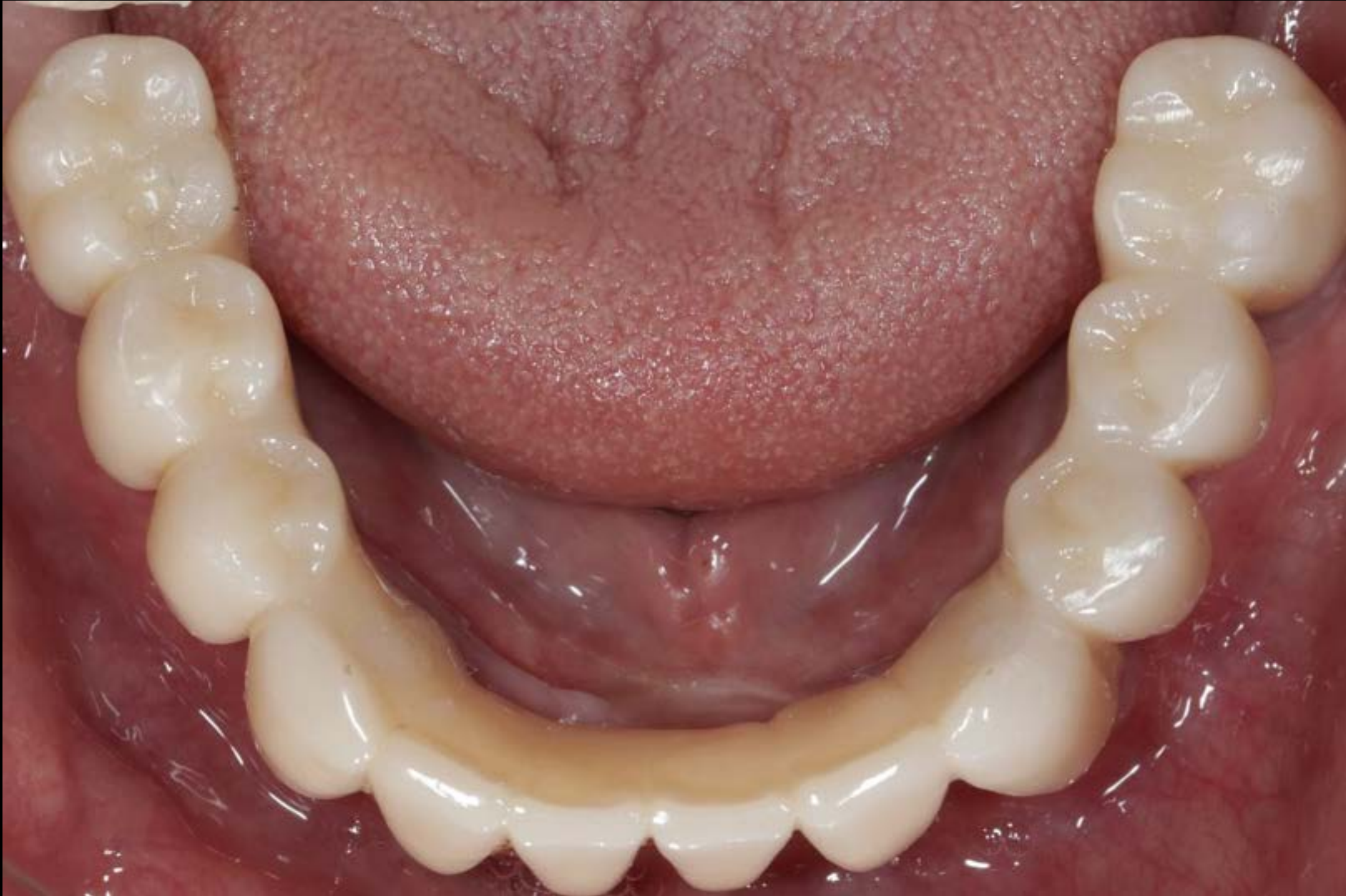
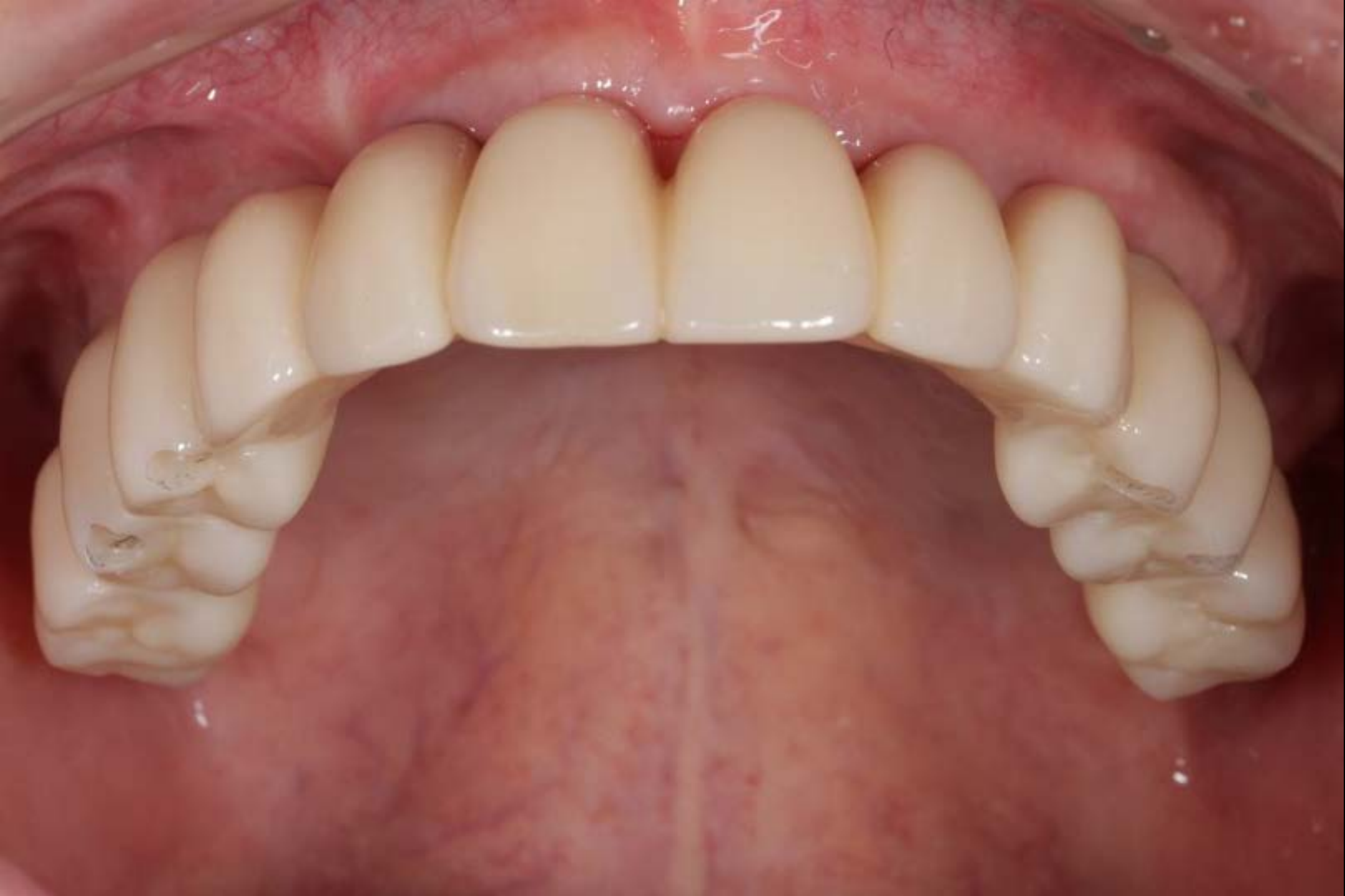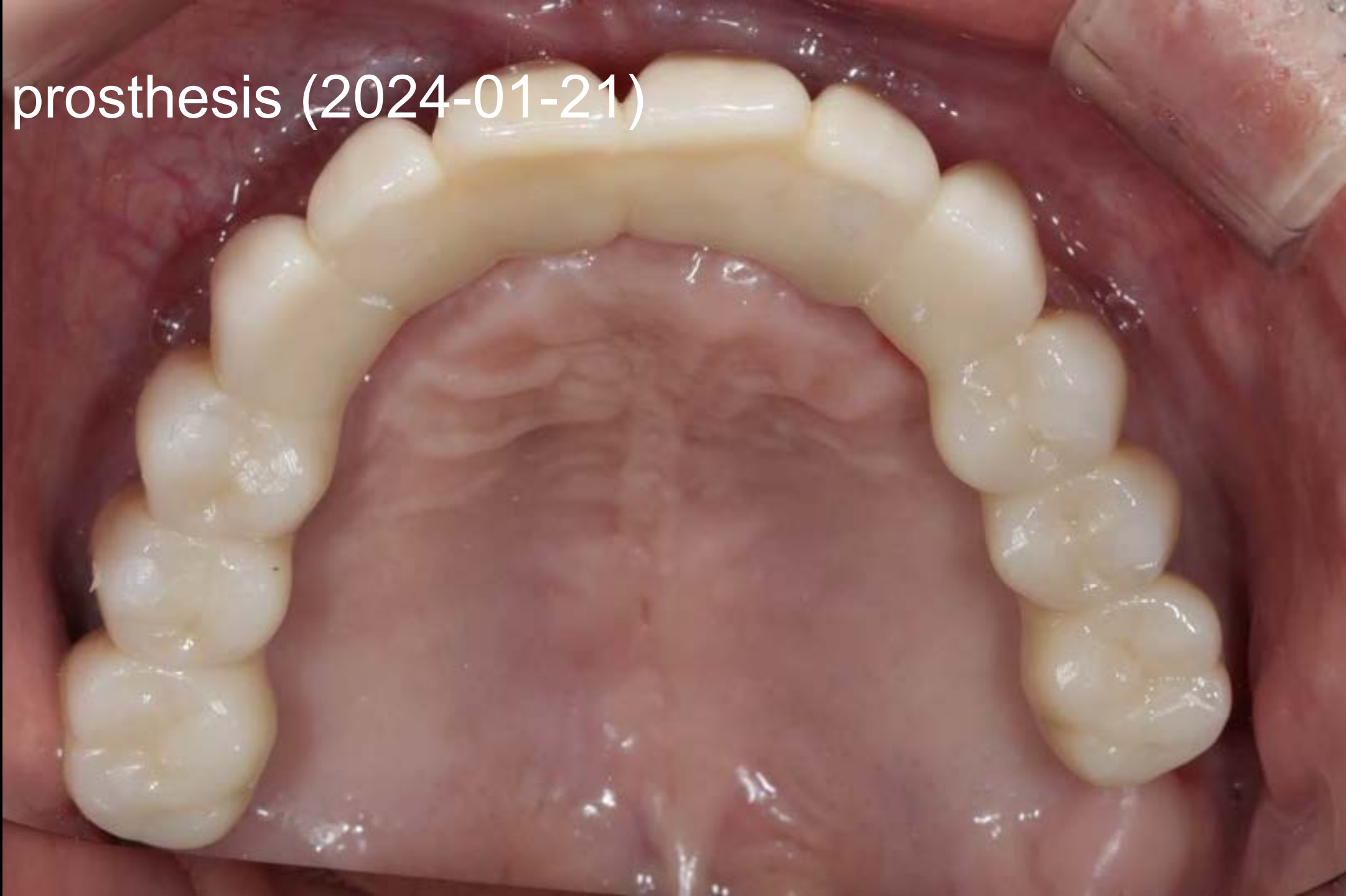PMH

Heart stent transplants,
diabetes, hyperlipidemia

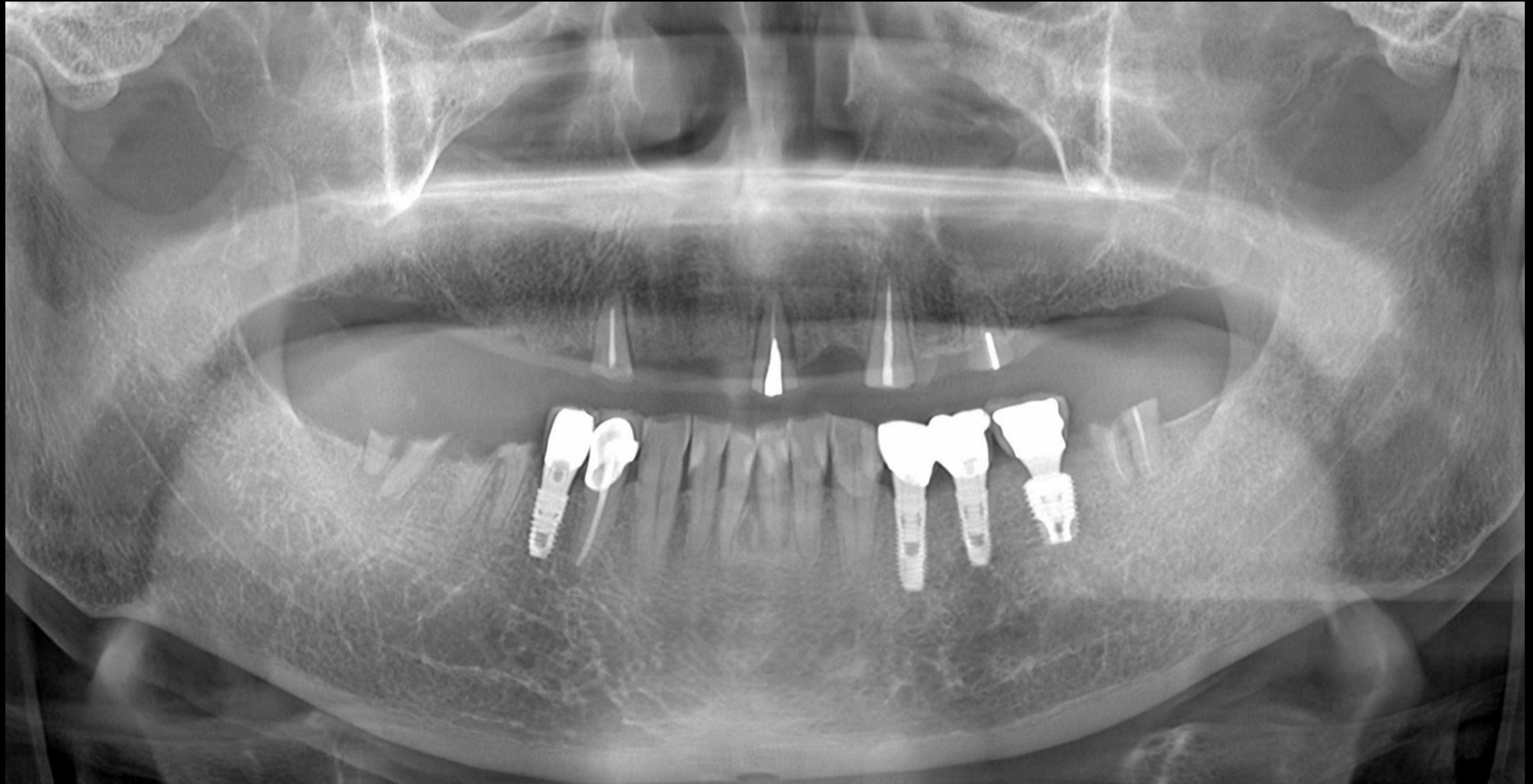Final prosthesis (2024-01-16)



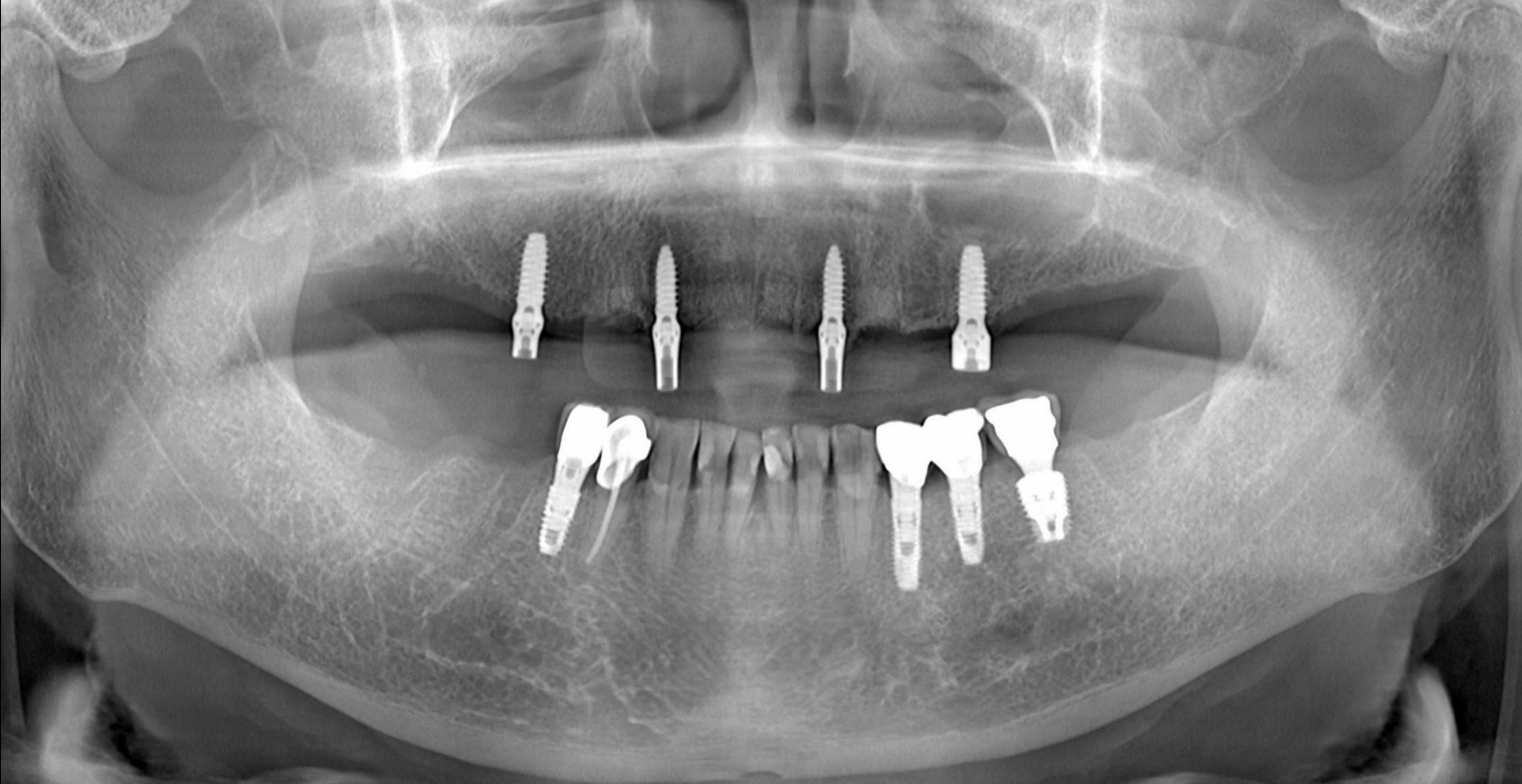Final prosthesis (2024-01-21)



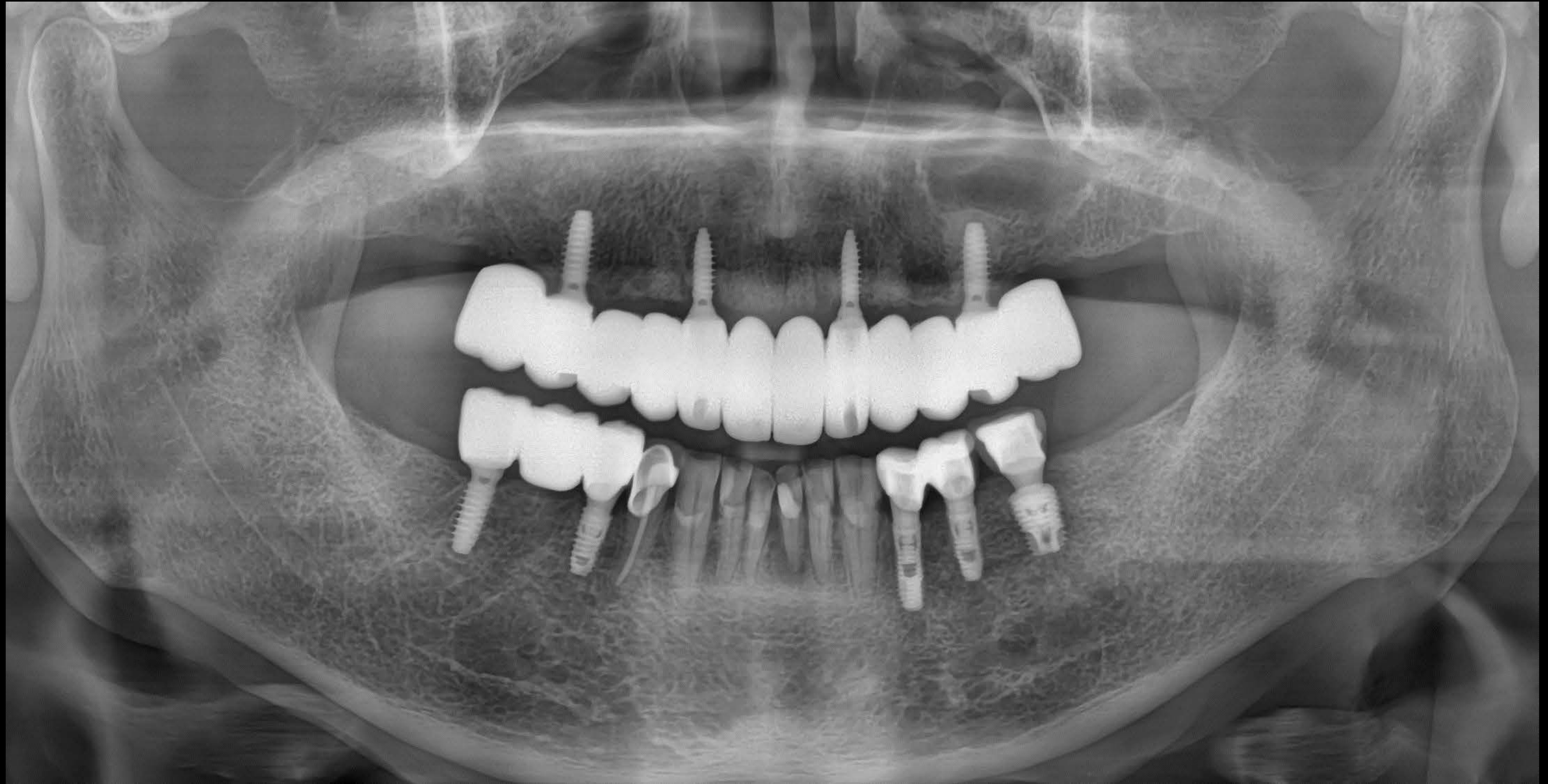Pre-op (2021-04-07)



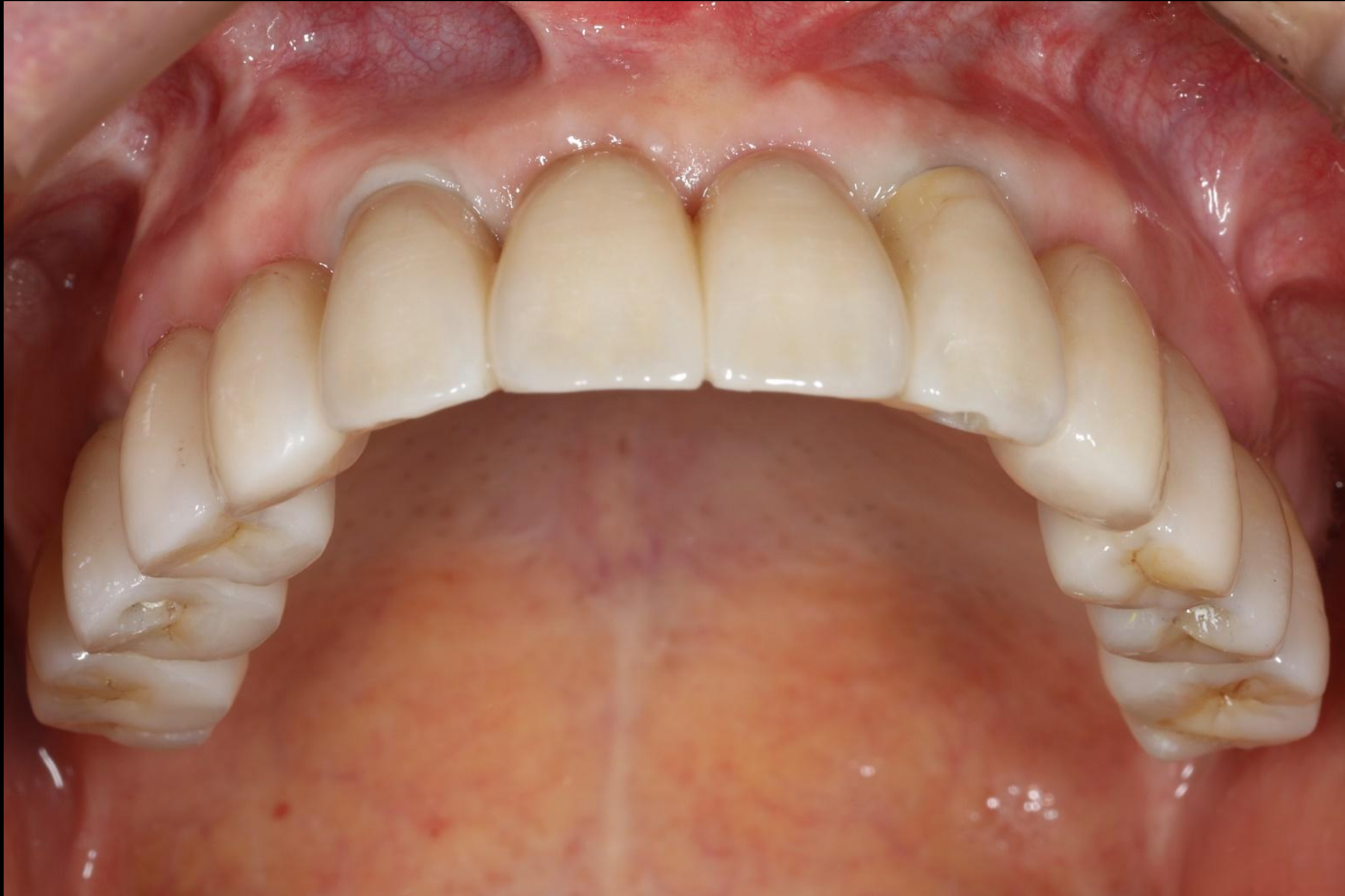Post-op (2021-05-07)



Follow up : 1 year (2022-10-14)



Final prosthesis (2021-10-08)



Minimalism is

Not only minimal invasive surgery

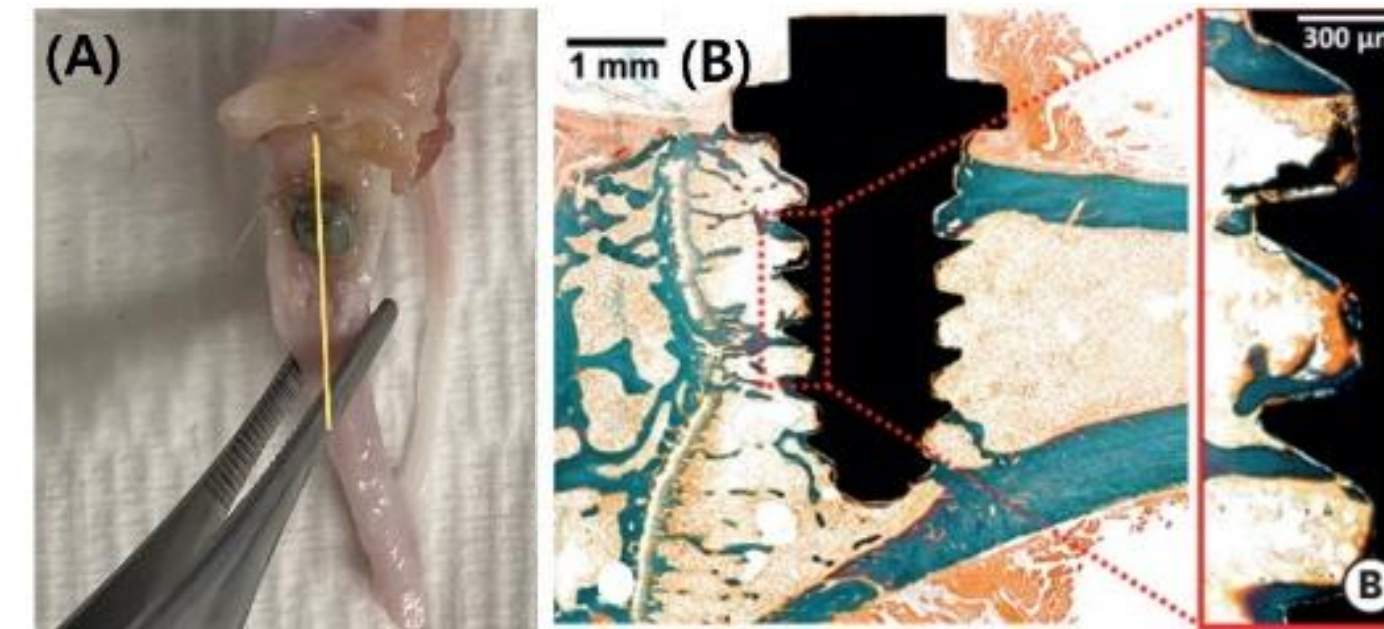
But also minimal number, short and narrow

And early loading - normally 4 week loading

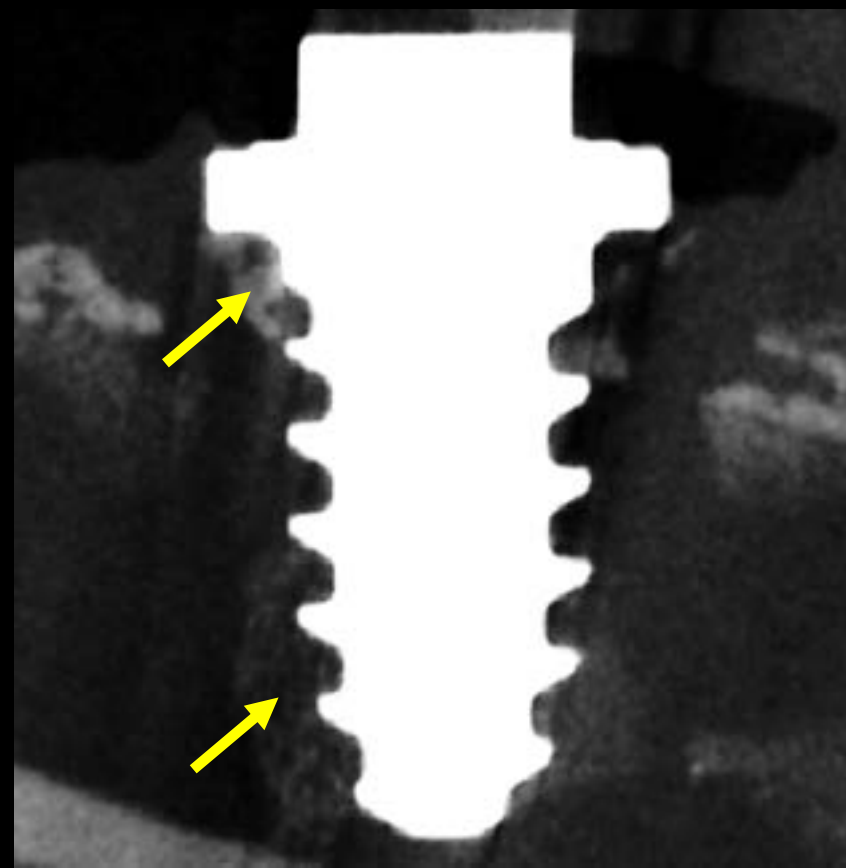
Implant + GENOSS PDRN : 7 day

1 Objective : To evaluate the effect of PDRN on early bone regeneration

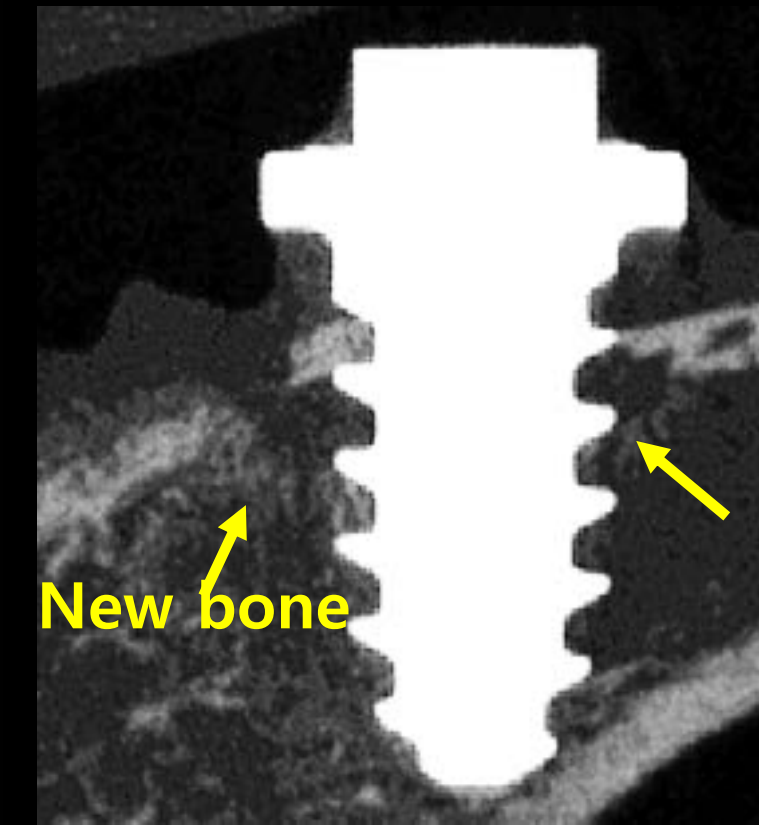
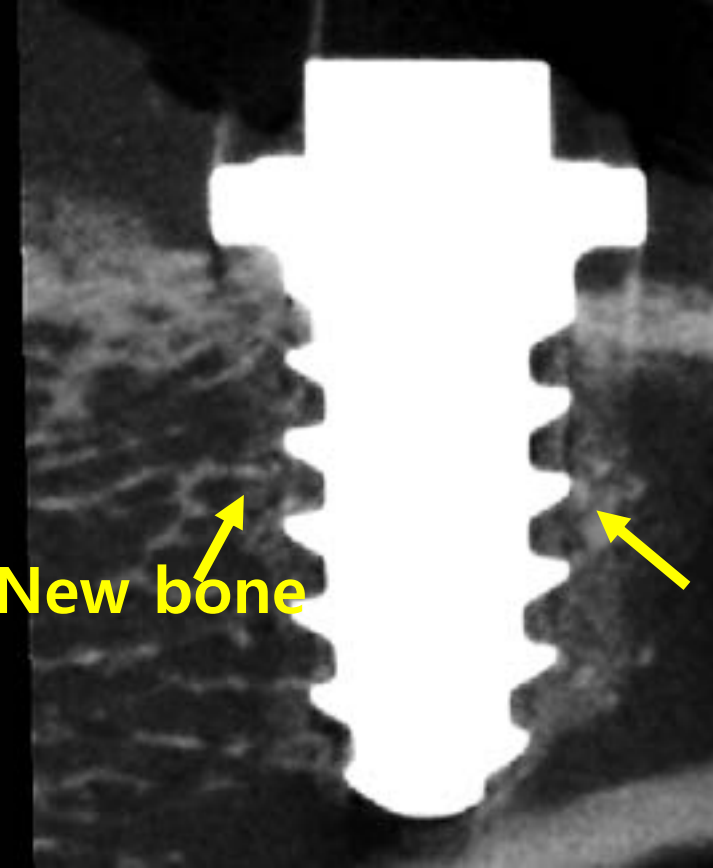
2 Conclusion : **PDRN increased bone formation by 54%**



* Experimental procedure: Implant placement in rat tibia after PDRN soaking



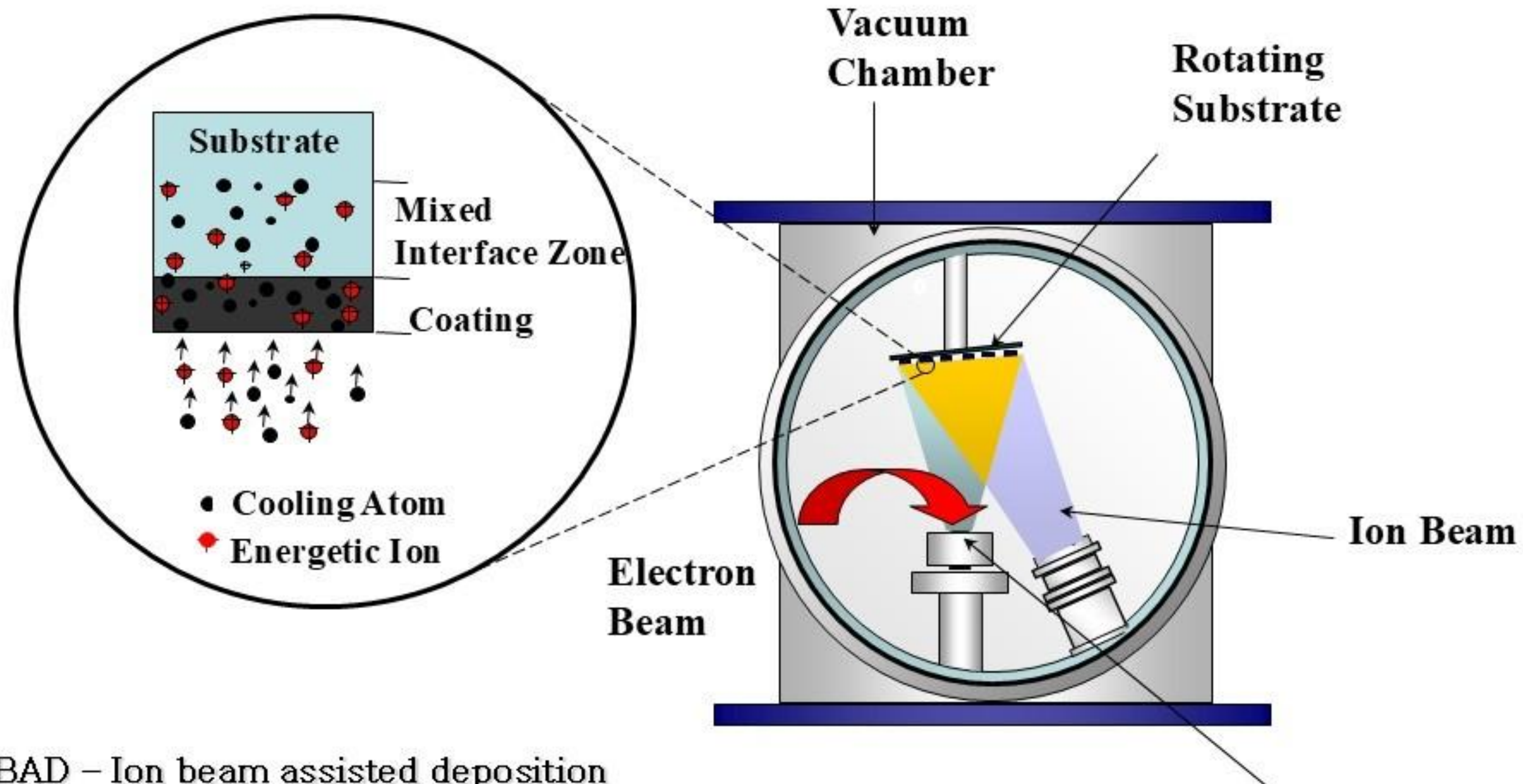
Implant +Saline



Implant +PDRN




IBAD Ca-P Coating System



1. IBAD – Ion beam assisted deposition
2. Evaporant – Hydroxyapatite + CaO, Sintering at 1000°C
3. The thickness and component of thin film is easily control.

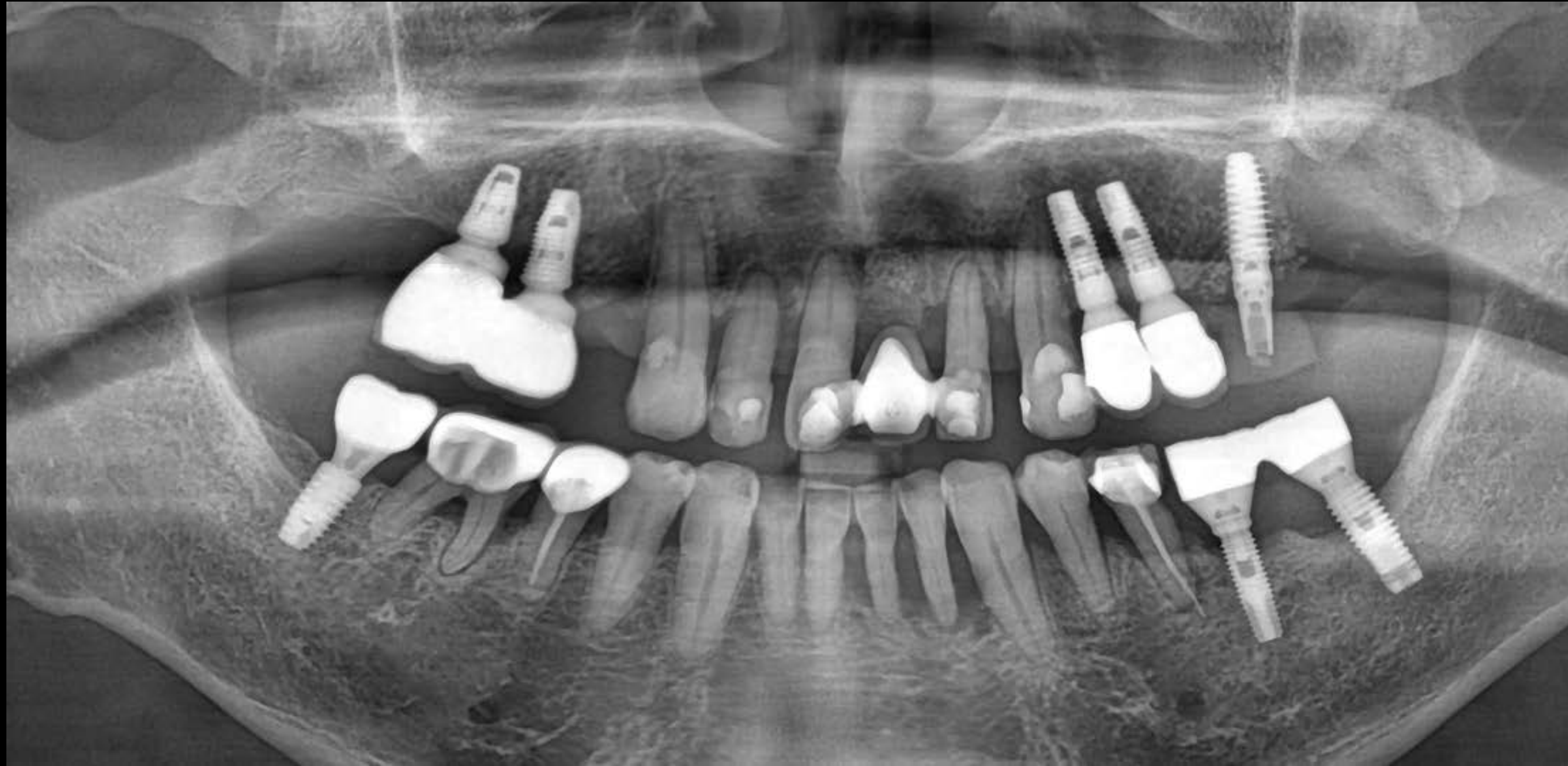


Ca-P Coating Thickness

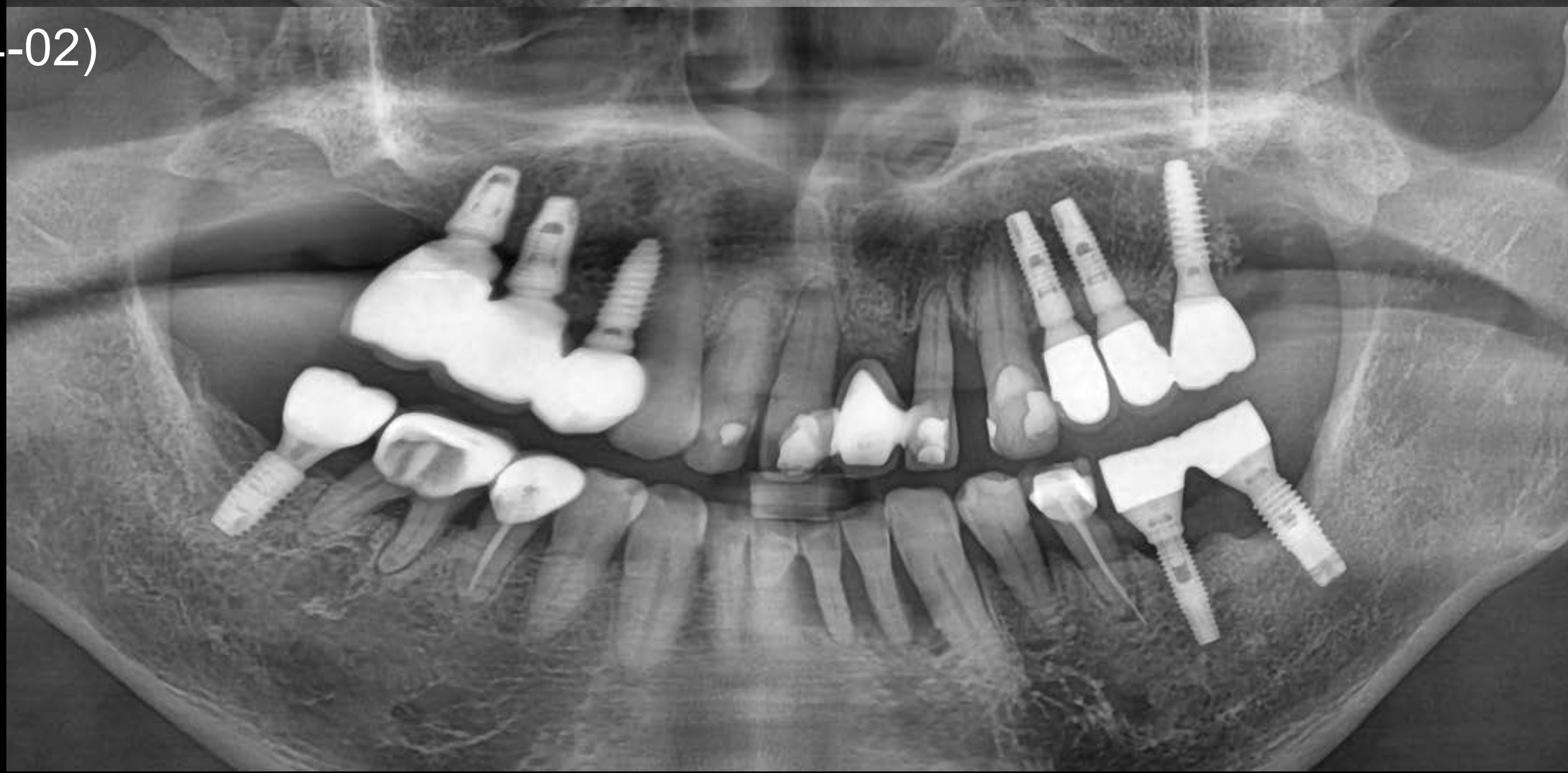


1. Thickness ~ 500 nm
2. The thin film is closely adherent on Ti substrate.
3. Bonding strength > 50 MPa

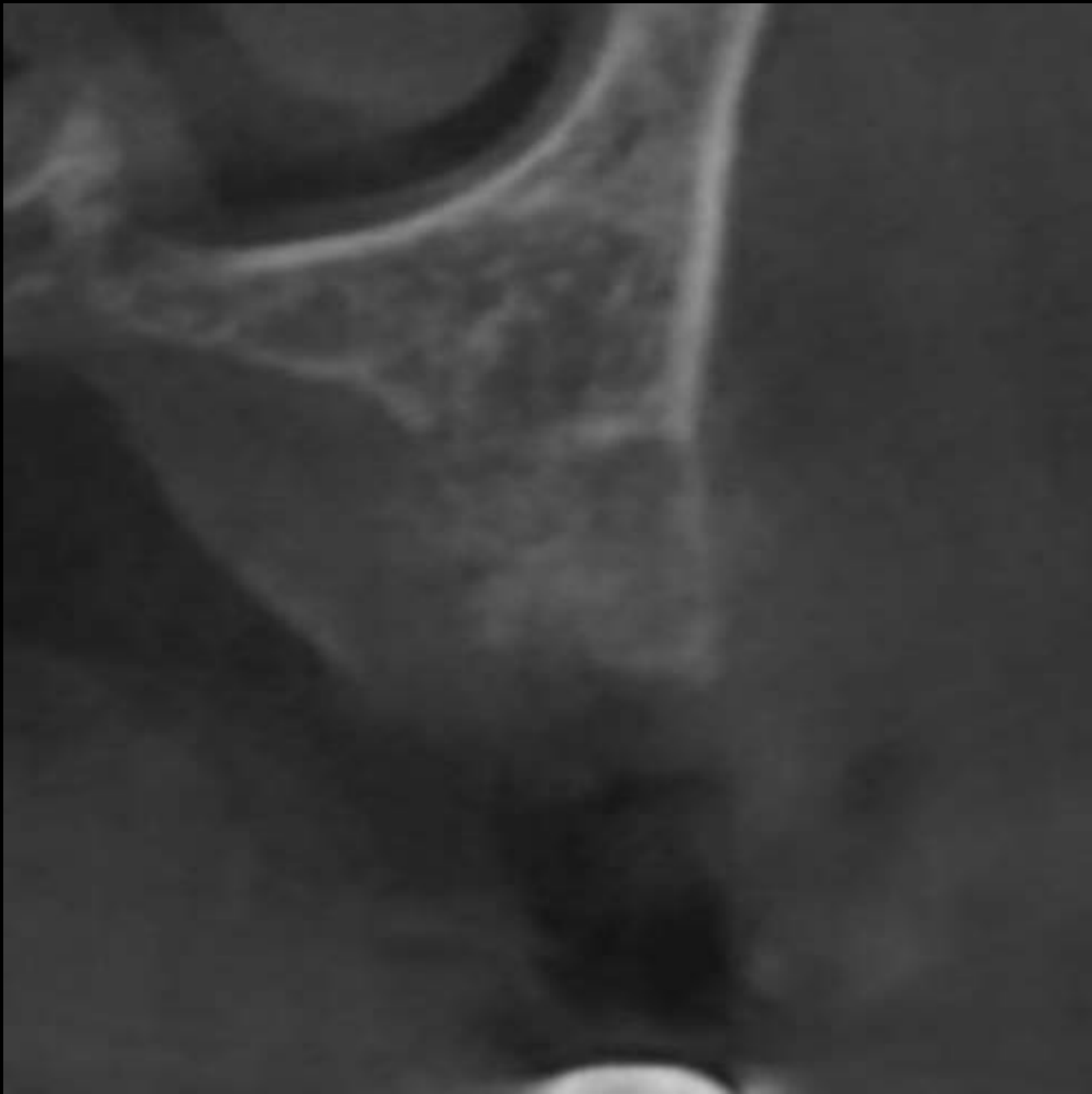Oral exam (2024-11-15)



Final prosthesis (2025-04-02)

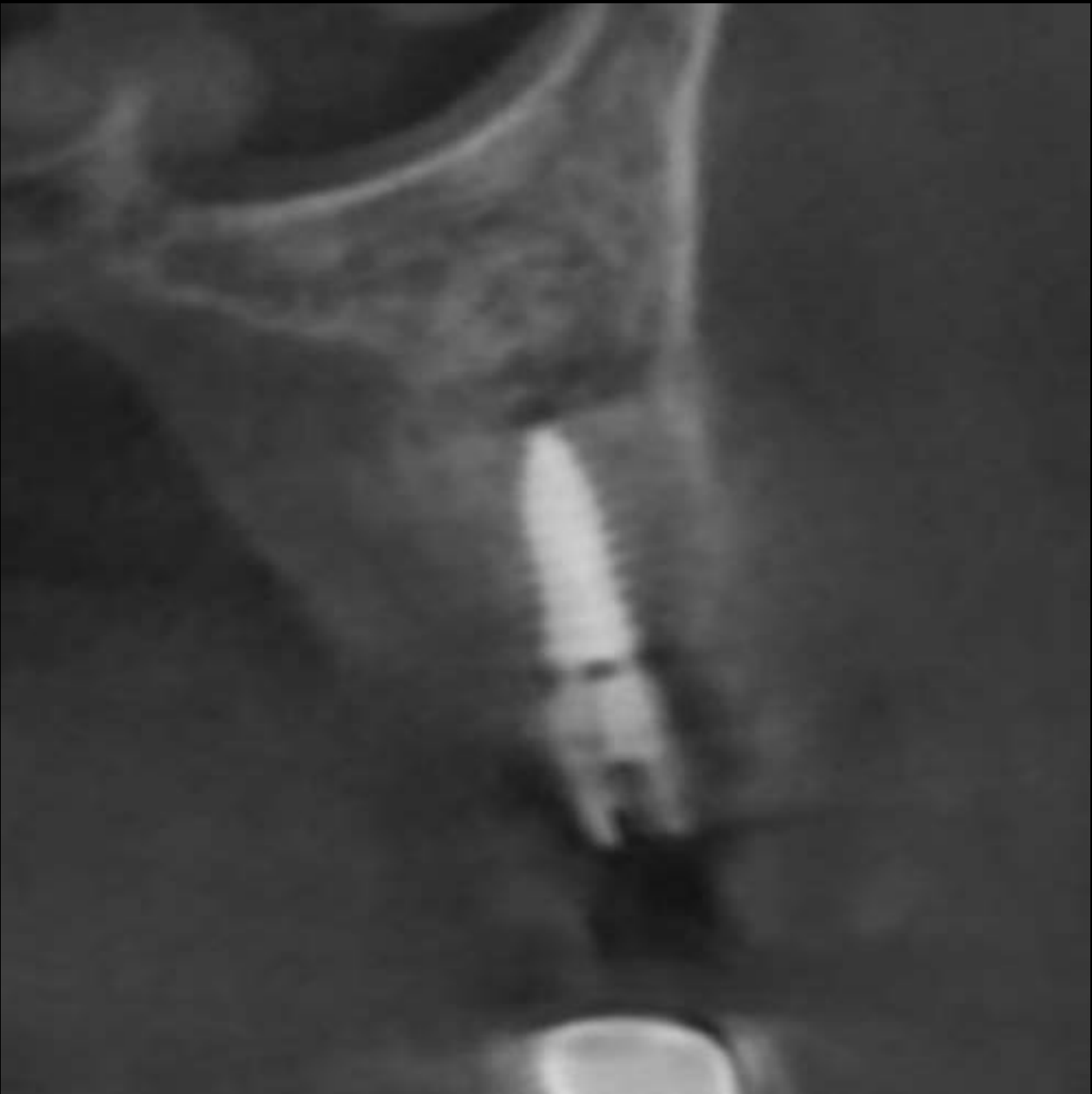

Pre-op CT (2025-03-10)



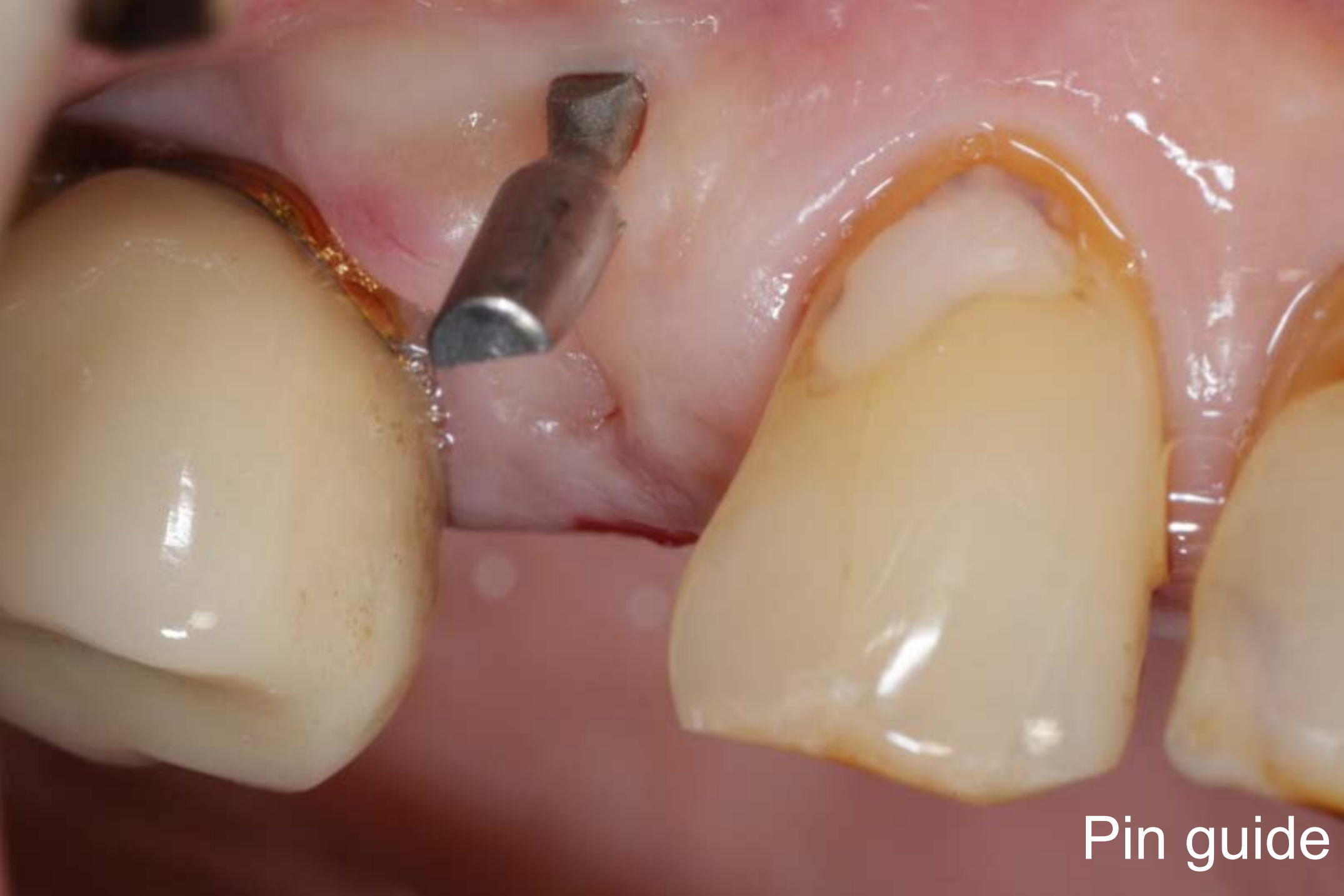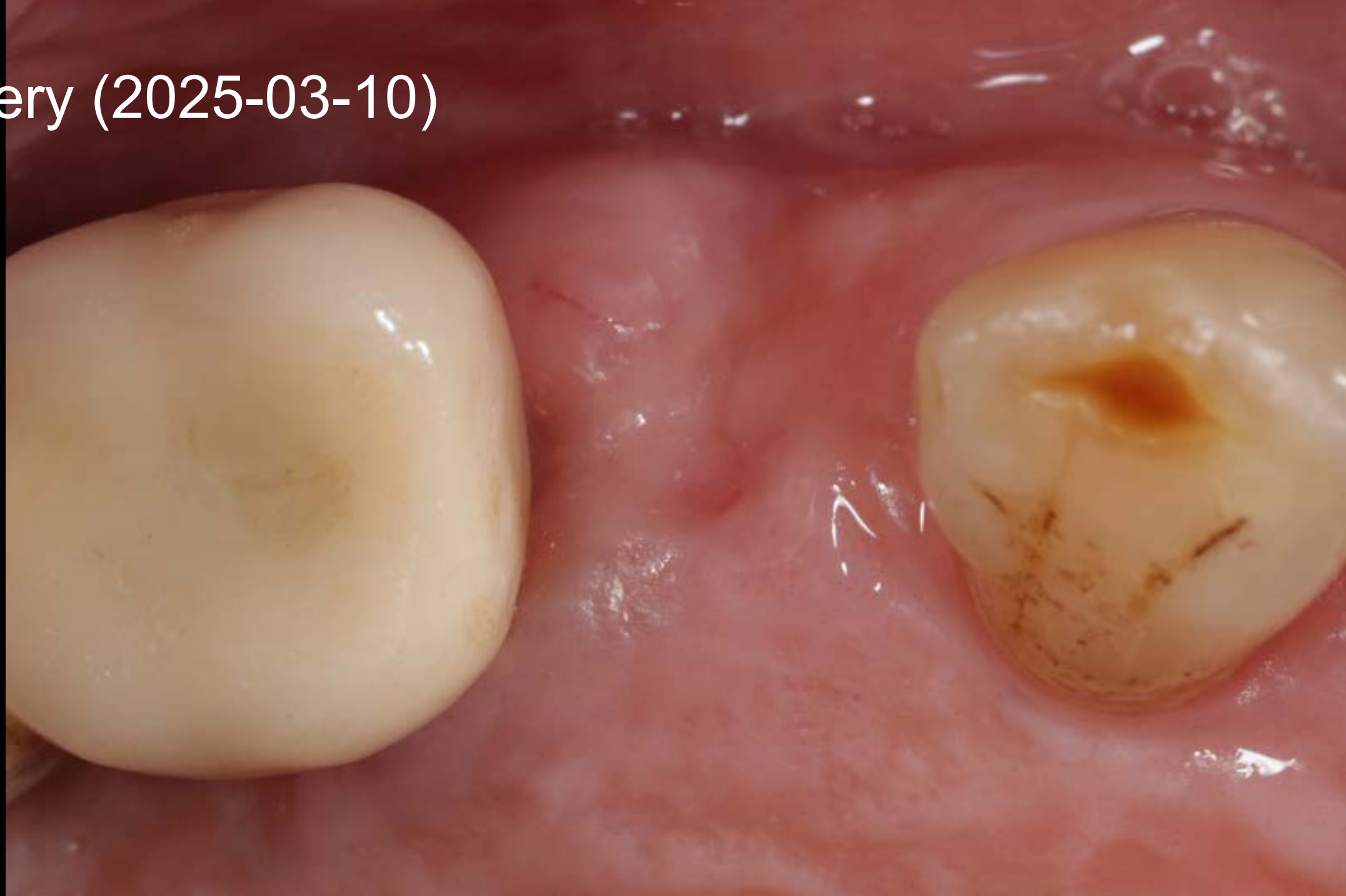#14

Post-op CT (2025-03-10)

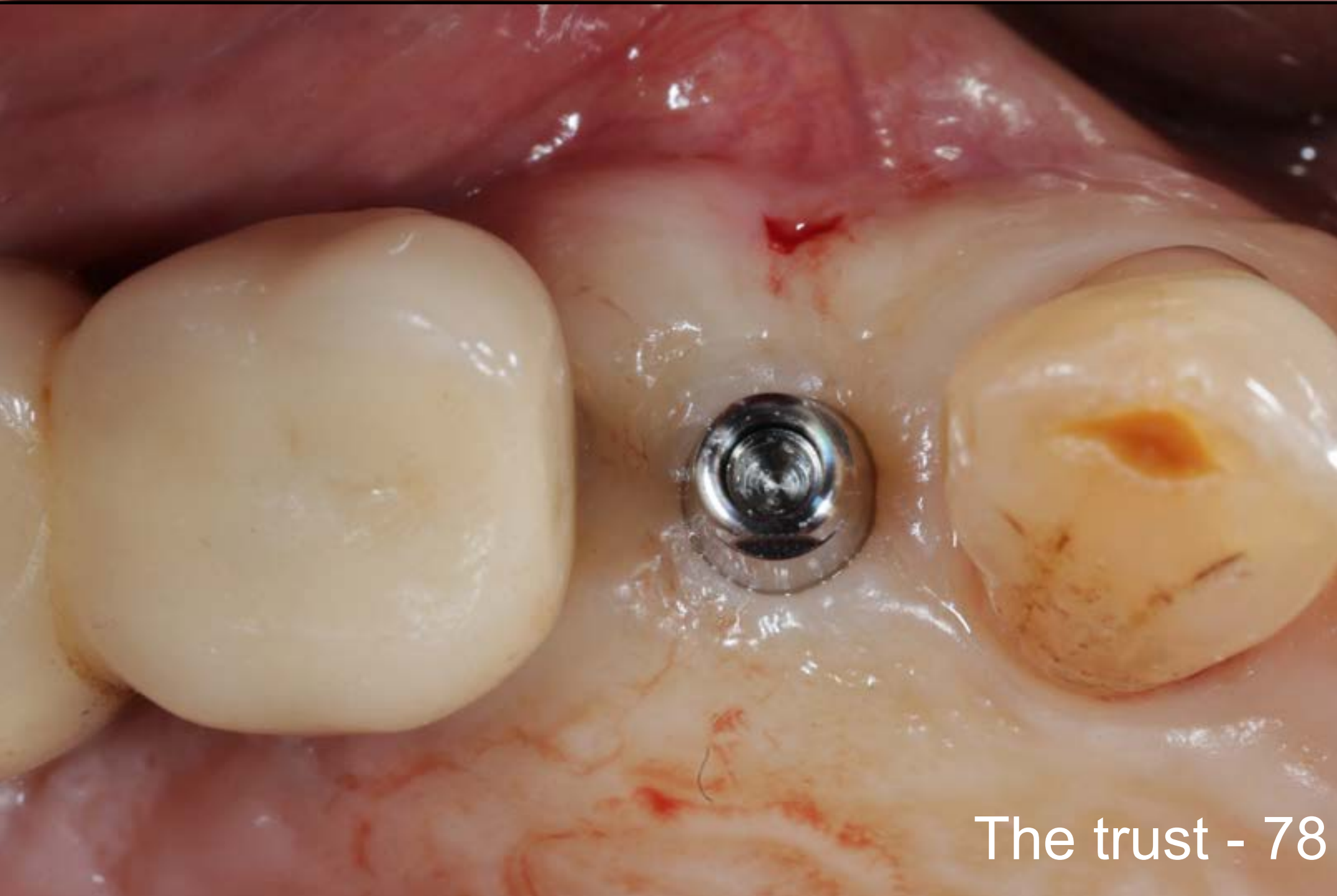
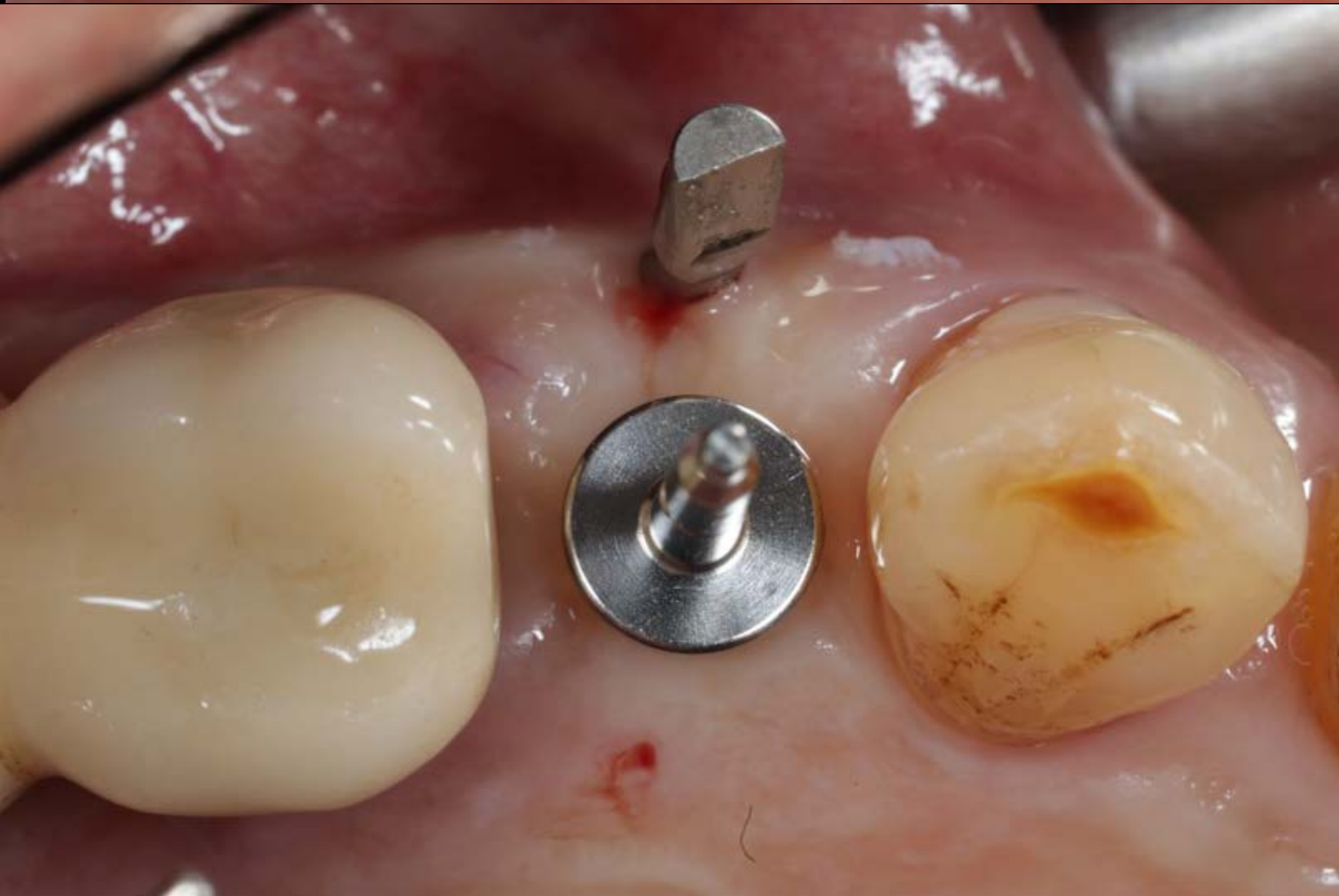


#14

Surgery (2025-03-10)

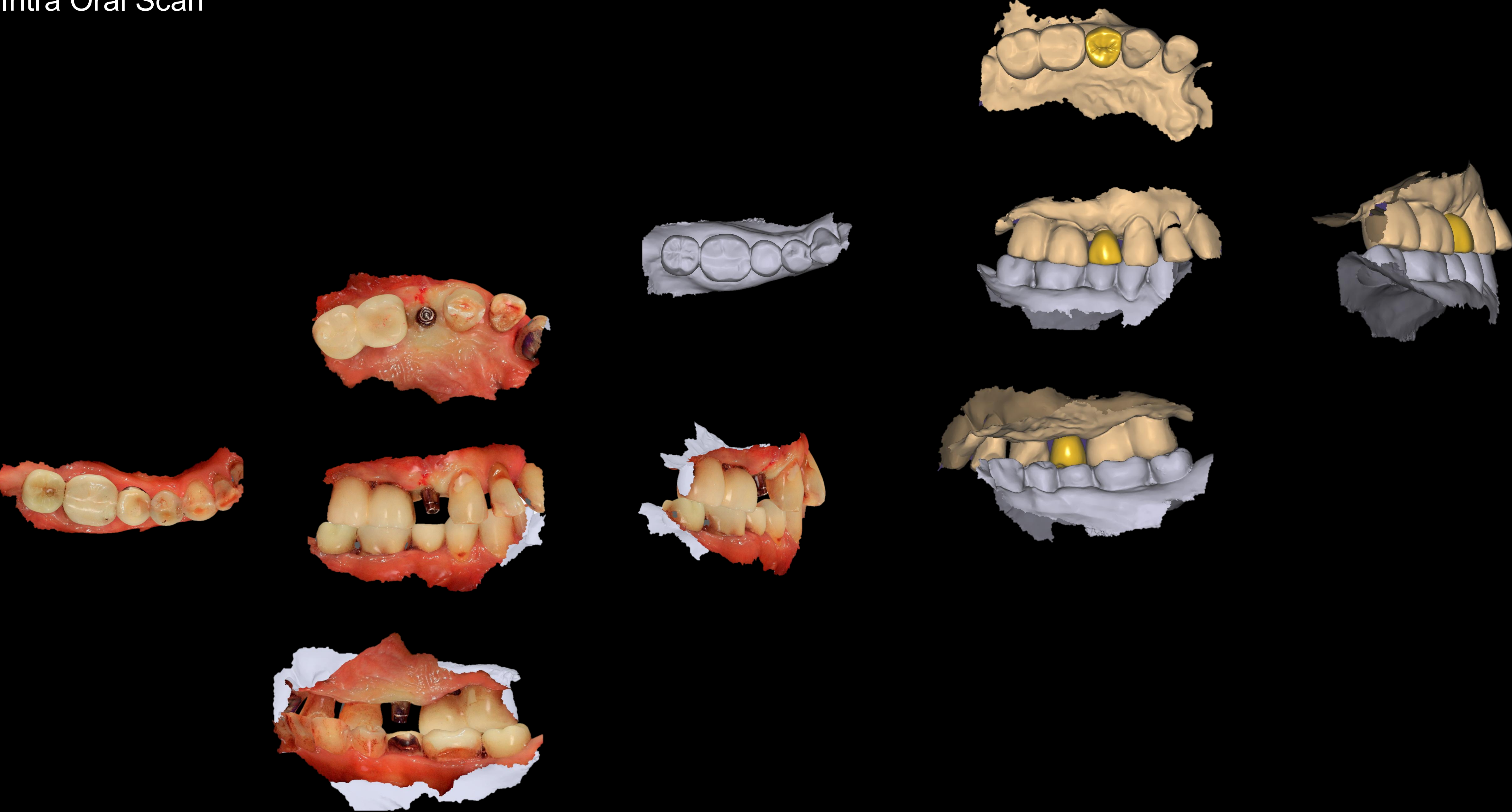


Pin guide

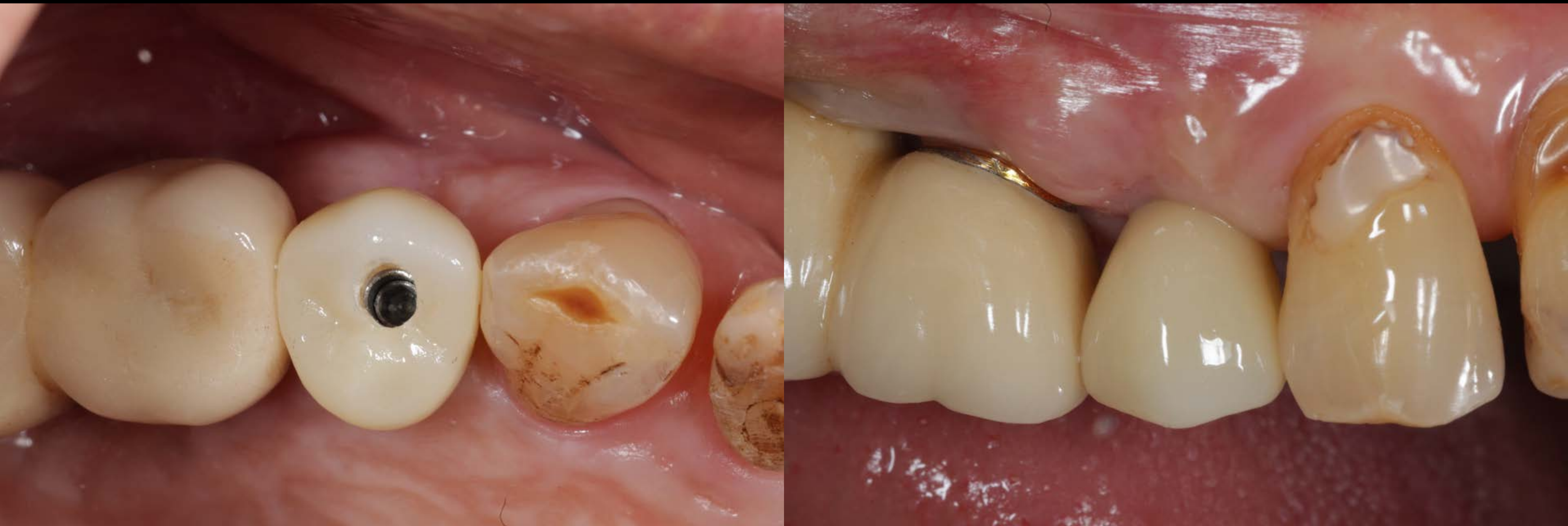

The trust - 78

Intra Oral Scan



Final prosthesis (2025-04-02)



Contents

Bright implant

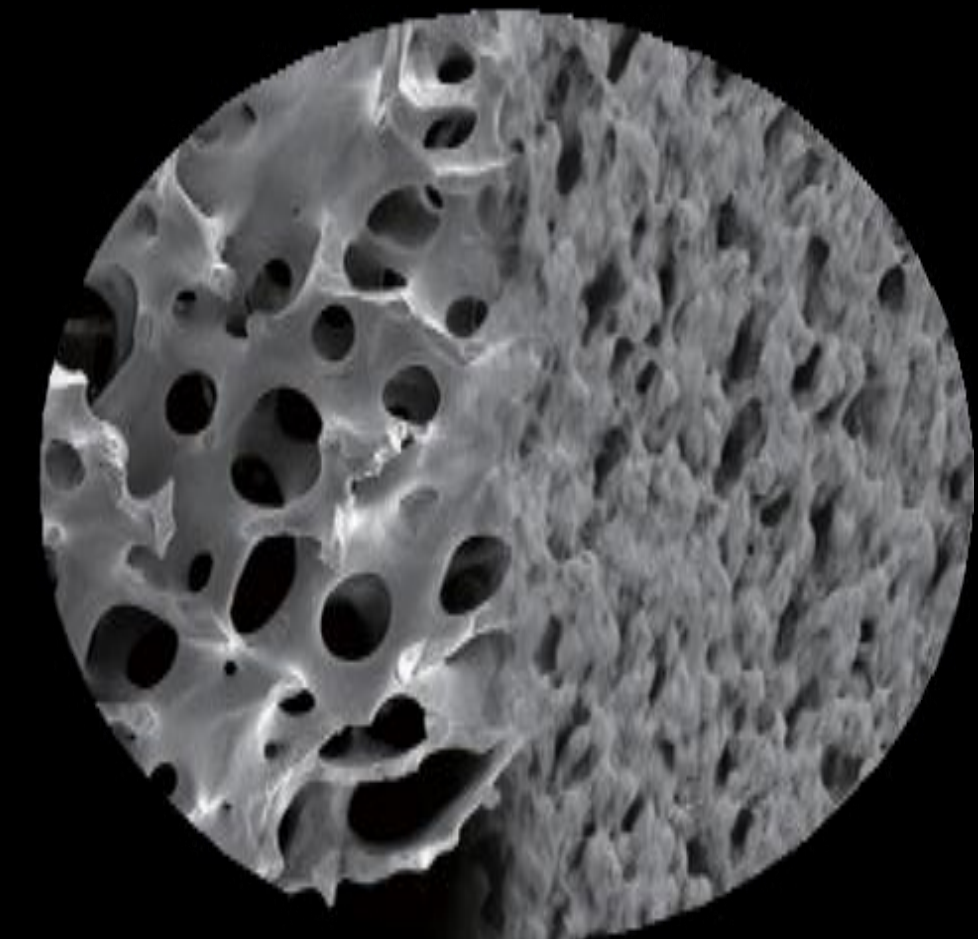
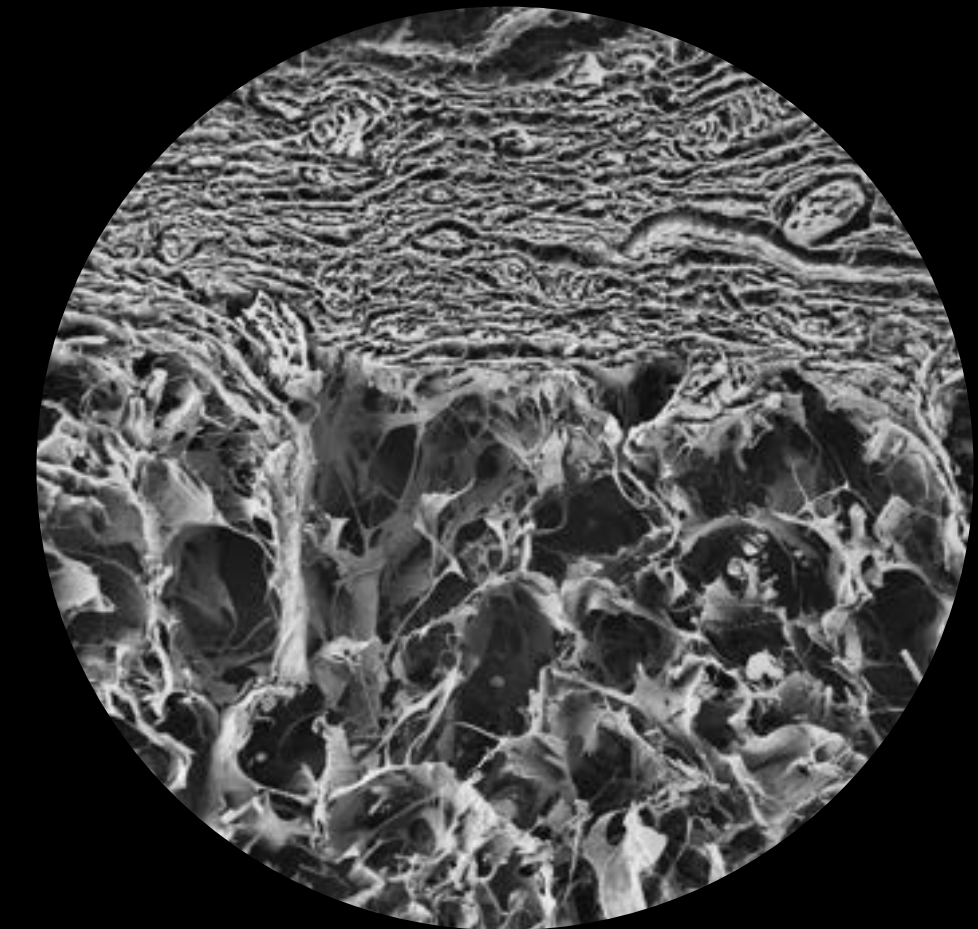

Narrow and short implants

Bone regeneration materials

Simple and exact digital concepts

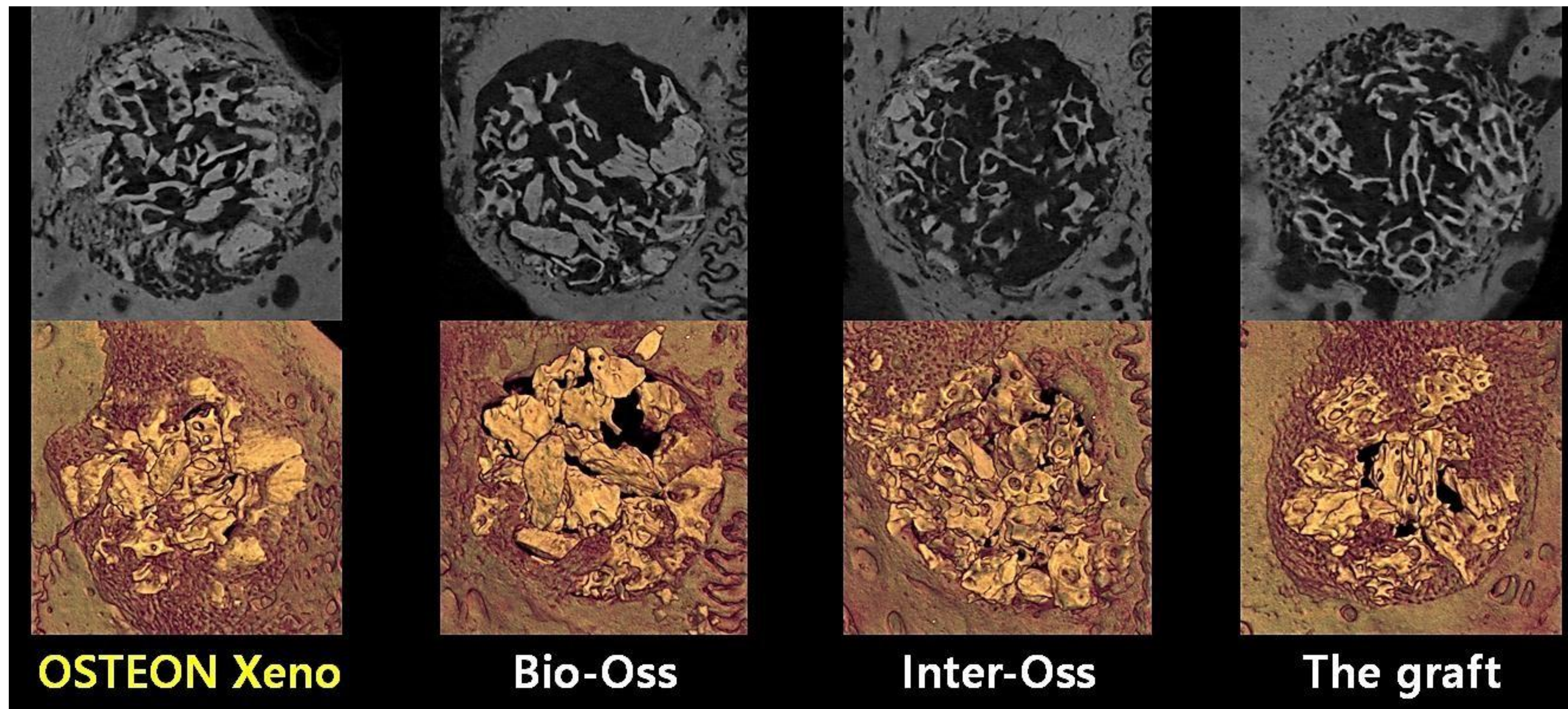
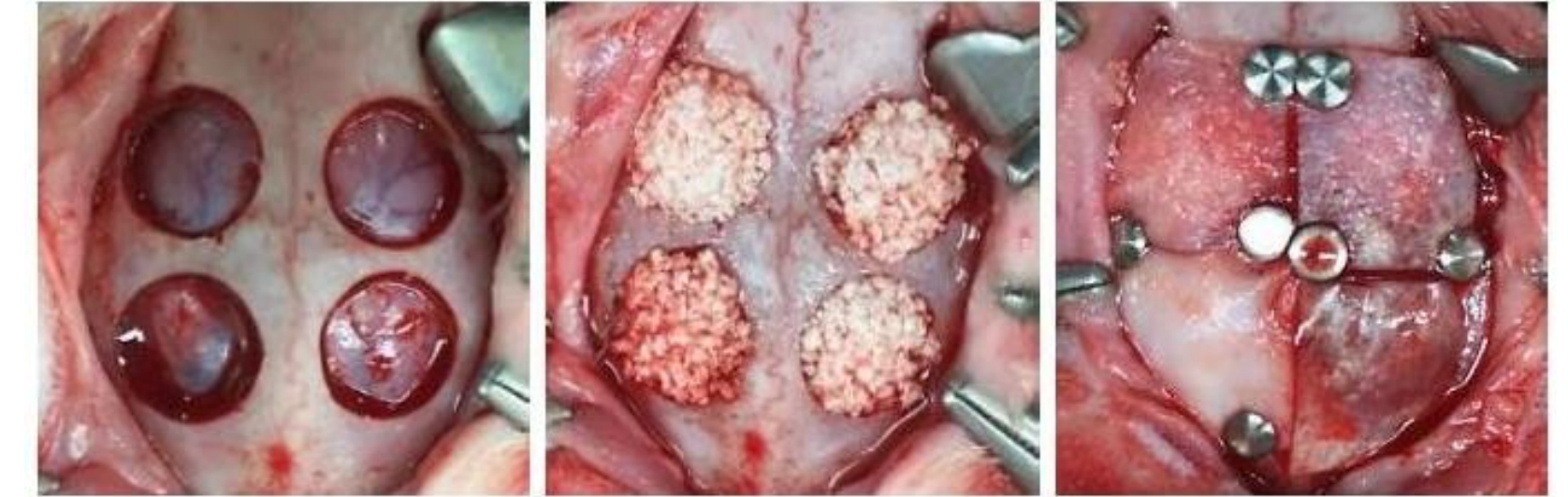Filler and toxin in dental field

Correlation between industrialization and clinical applications



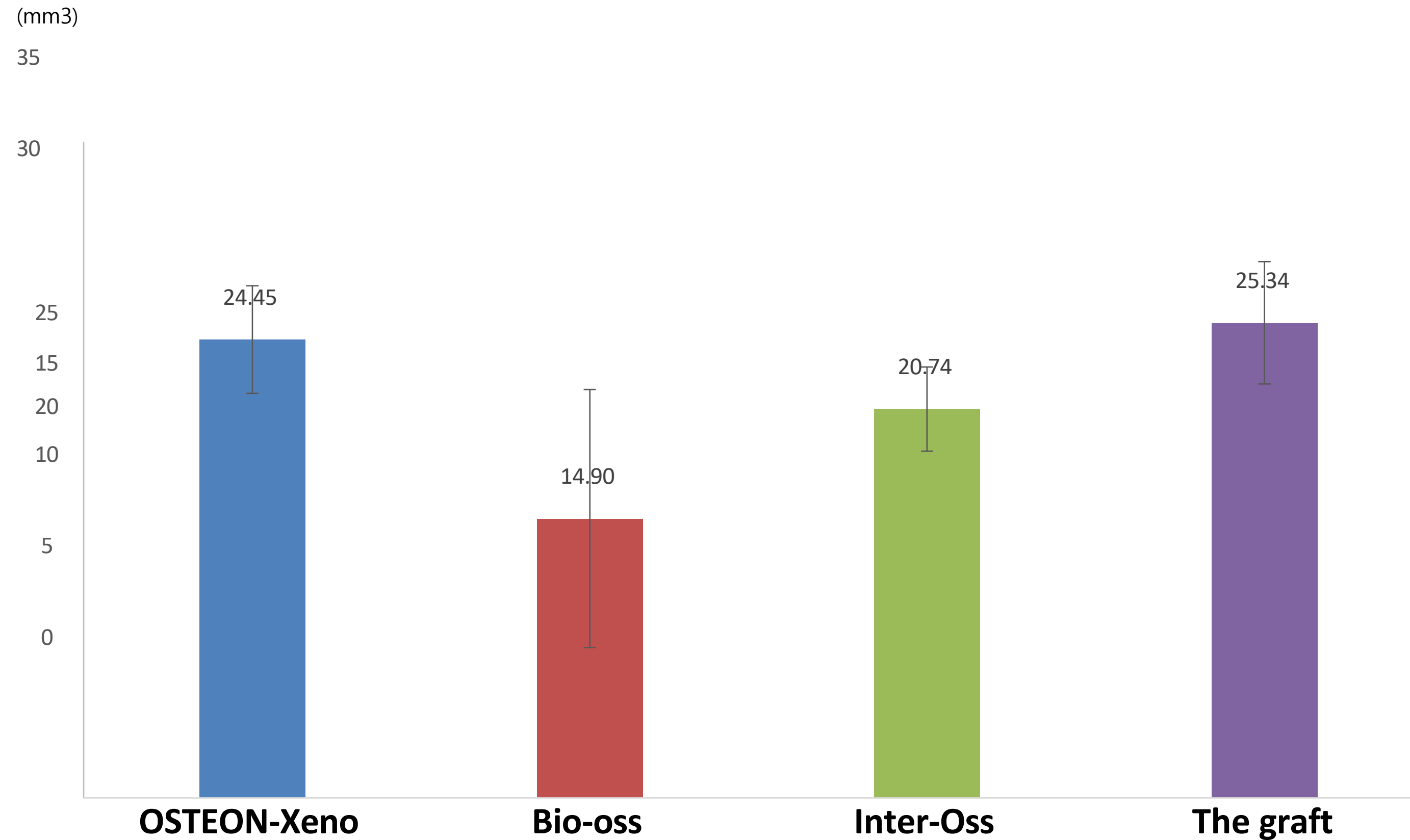
OSTEON Xeno : Preliminary evaluation of bone formation (4W)

1. Objective : Comparative evaluation of three commercial bone grafts (Bio-Oss, Inter-Oss, The Graft)
2. Conclusion : **OSTEON Xeno** $\hat{=}$ The graft > Inter-Oss > Bio-Oss
3. Action plan : Prepare a report and share data with relevant departments



Micro-CT quantitative analysis


New bone volume in Rabbit calvaria (4w)



OSTEON Xeno, Xeno collagen

- 1 What: **Comparison between OSTEON Xeno and Bio-Oss (8, 16, 24 weeks)**
- 2 How : **Comparable osteogenic potential to Bio-Oss**


No.	위치	분류	골이식재
1	토끼 두개골	대조군	Bio-Oss
2			Bio-Oss Collagen
3		실험군	OSTEON Xeno
4			OSTEON Xeno Collagen



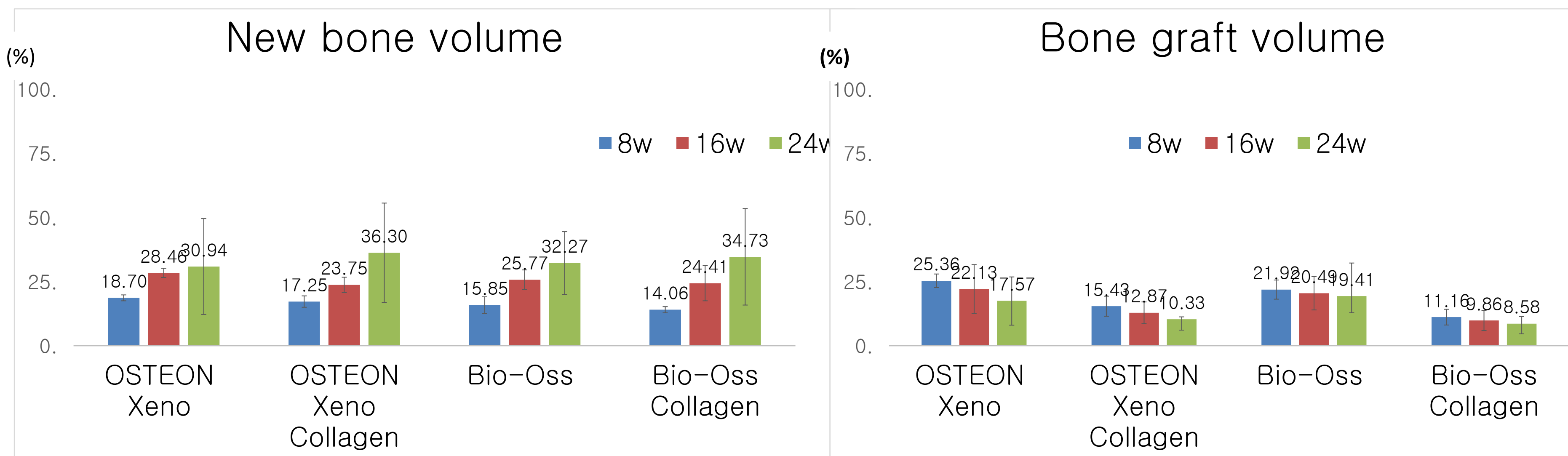
OSTEON Xeno (8주)

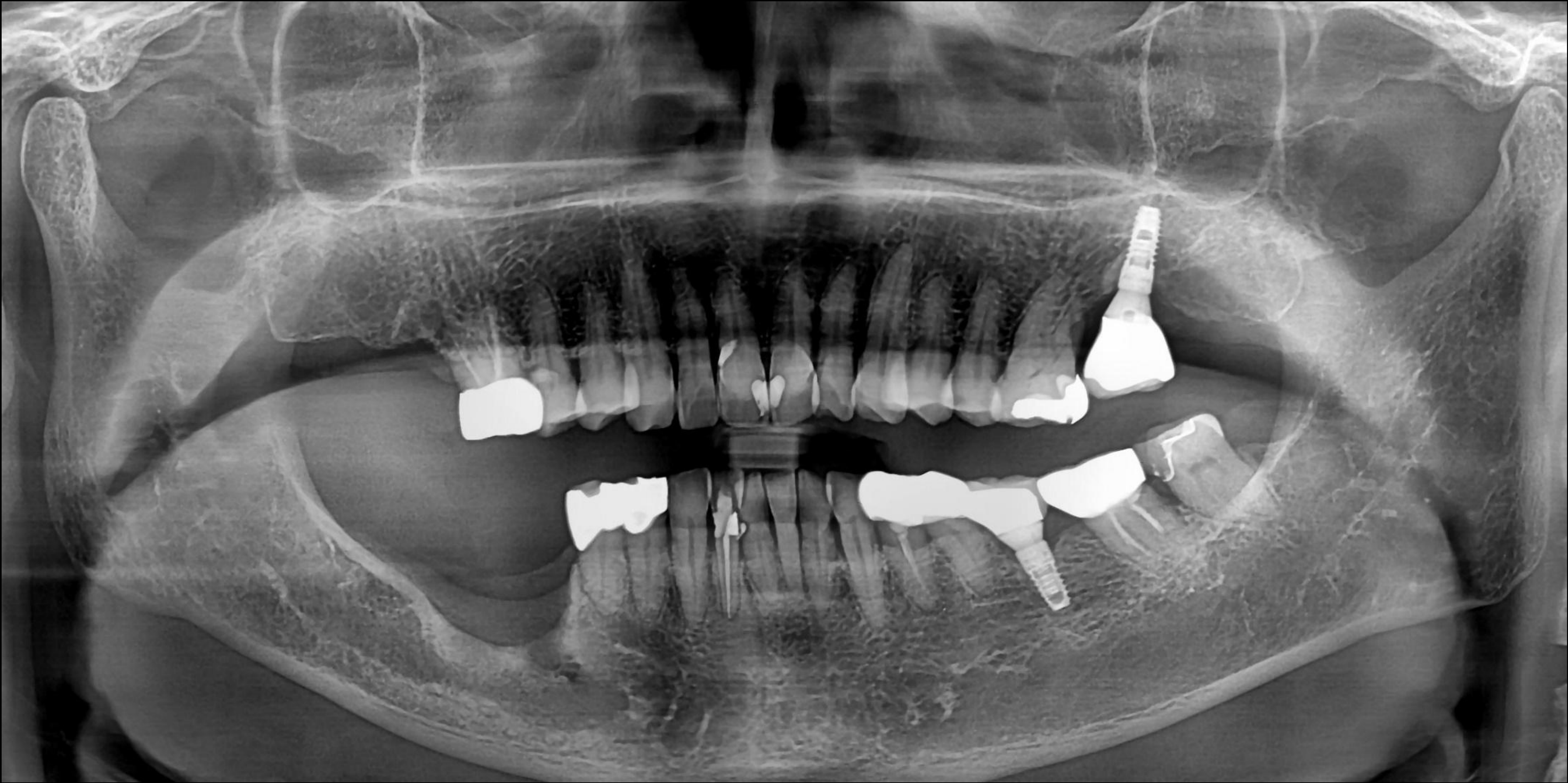

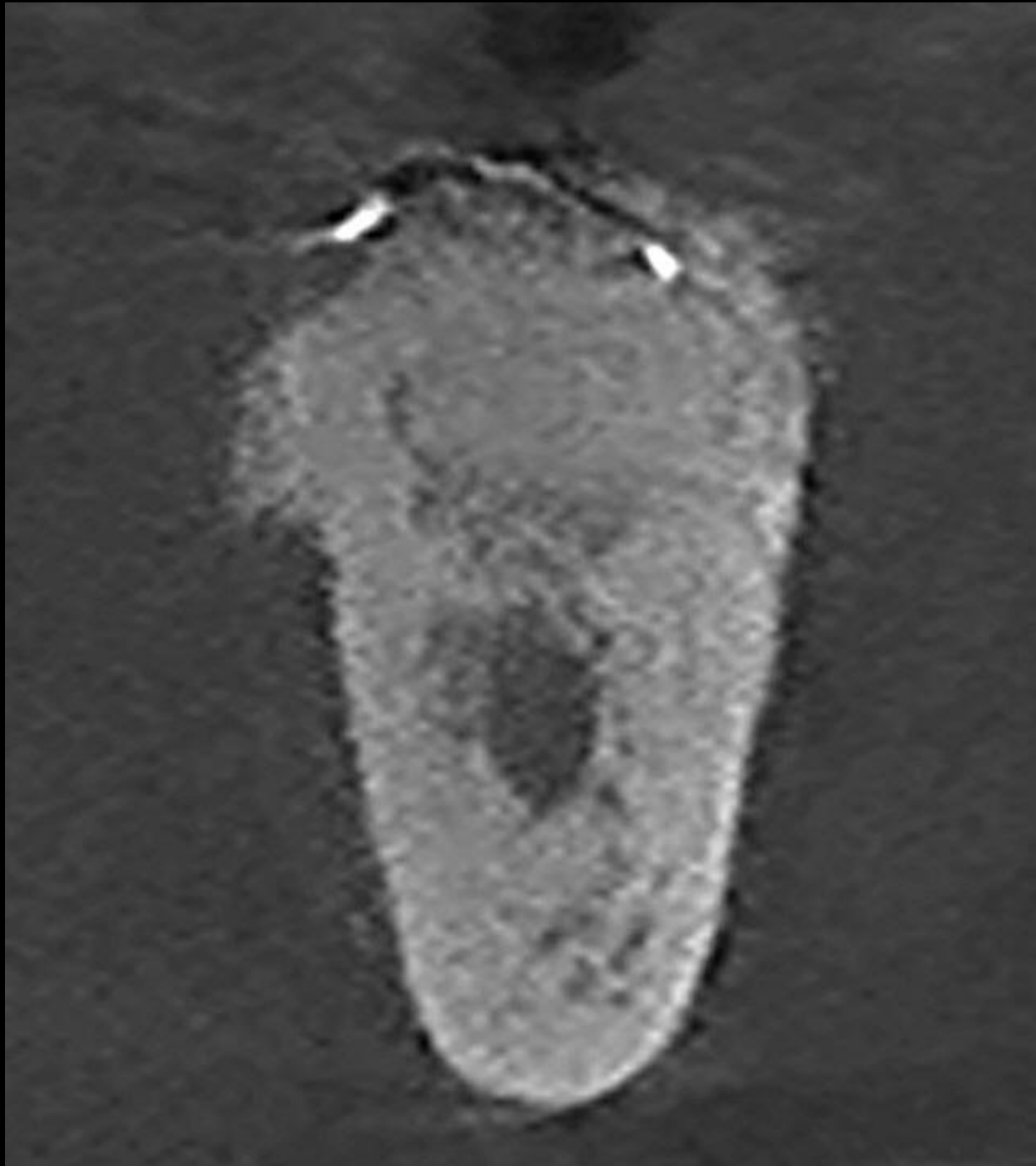
OSTEON Xeno (16주)



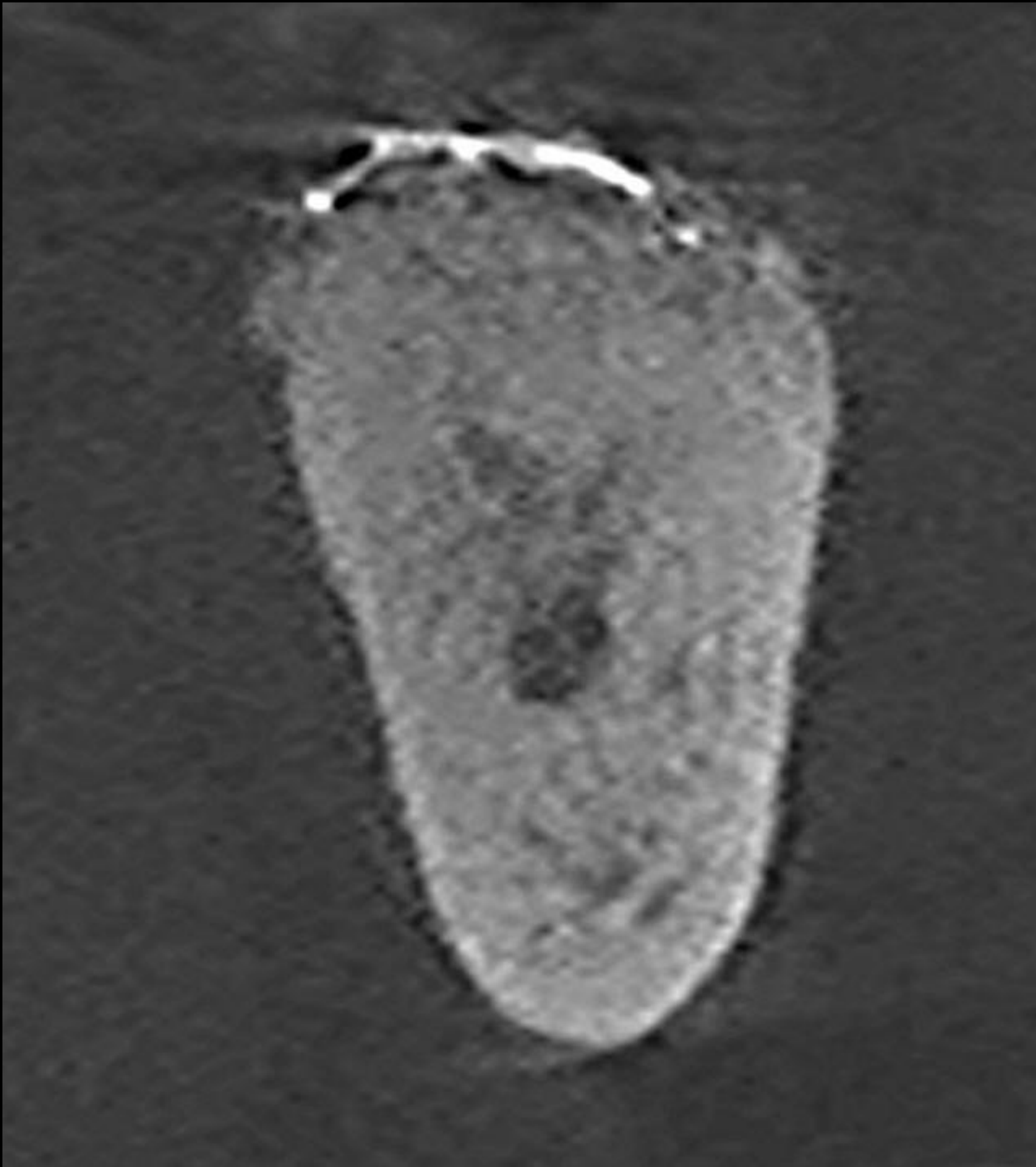
Micro-CT quantitative analysis





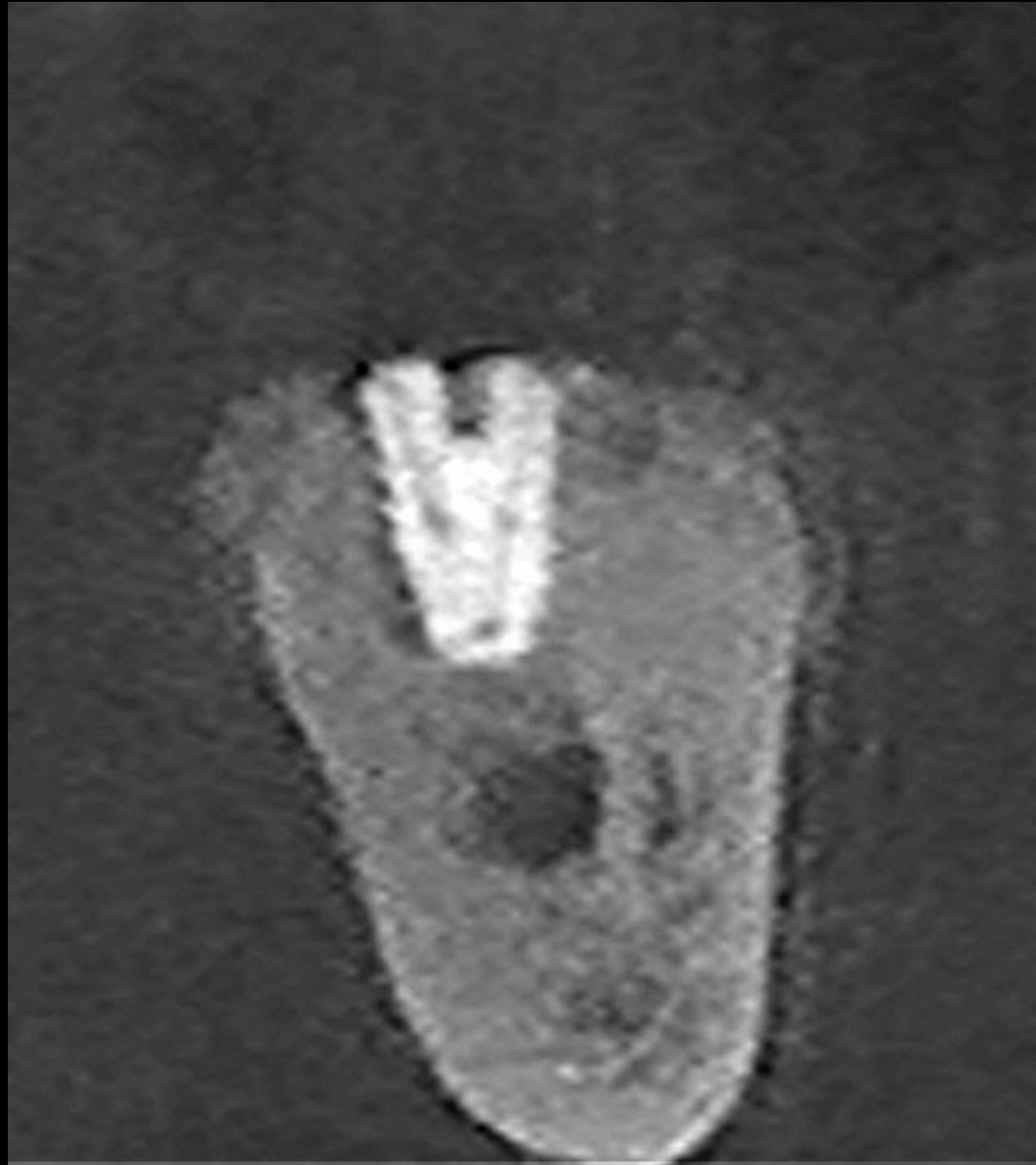

#47

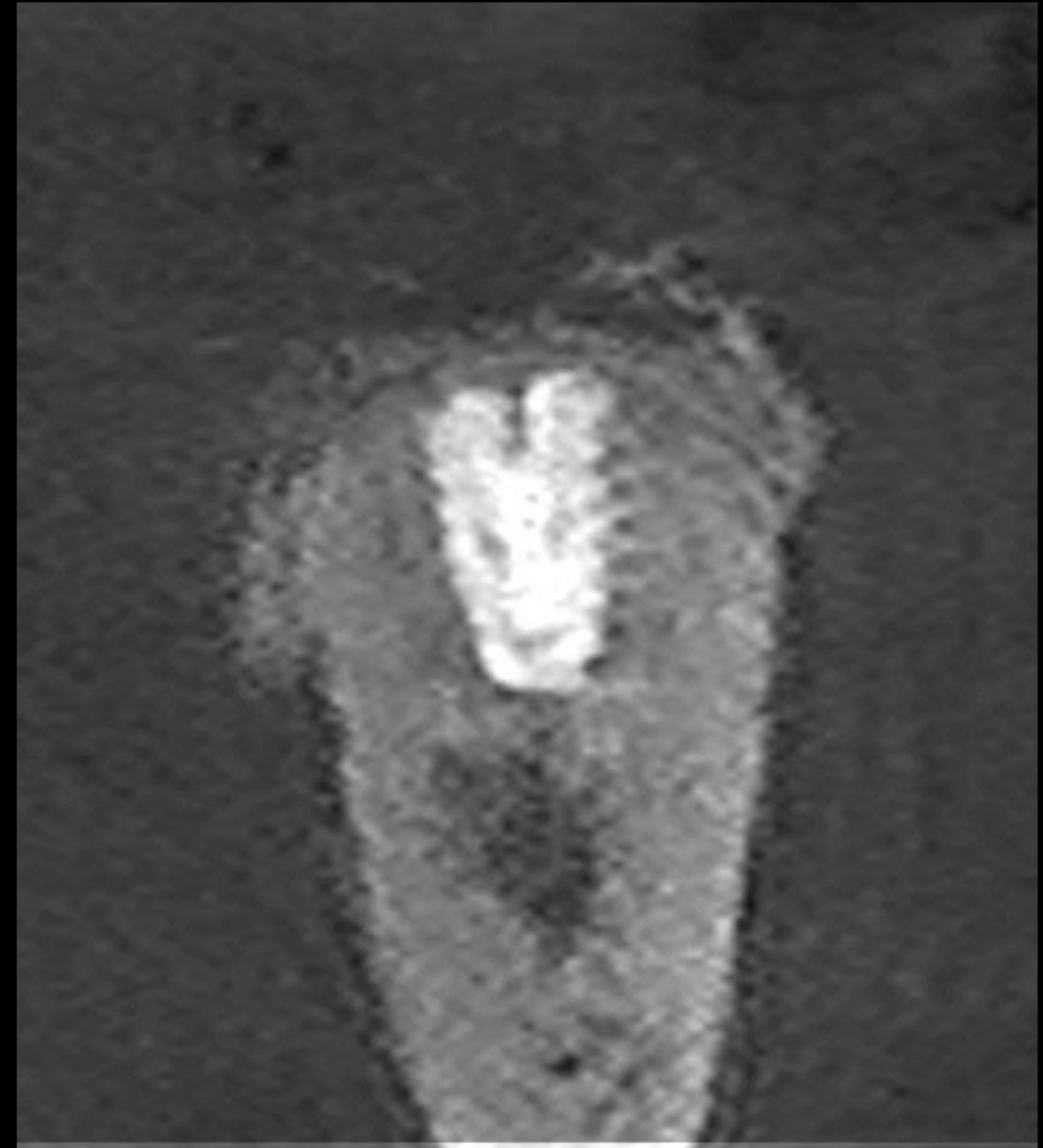


#46

Post-op CT (2023-04-10)

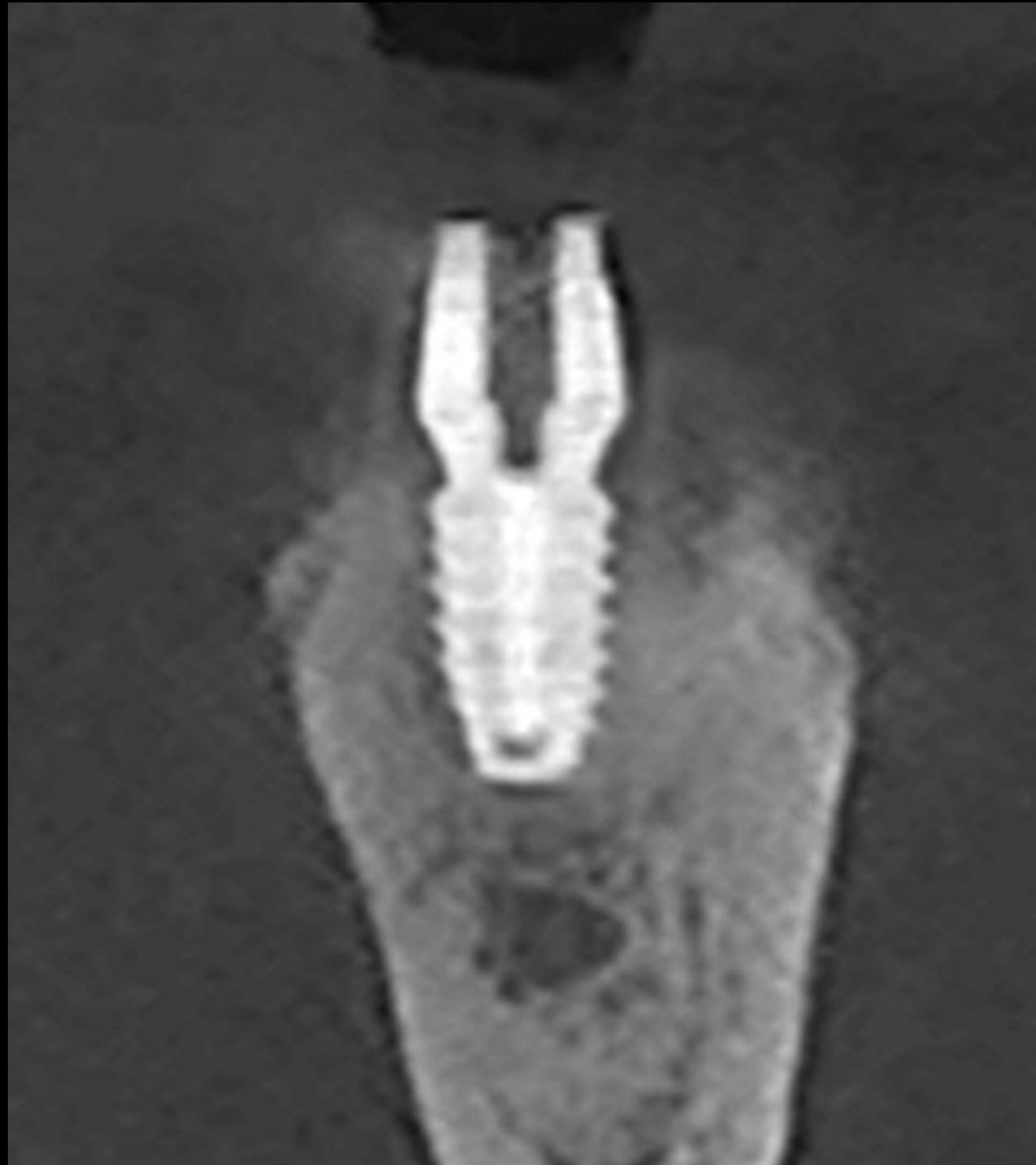


#47

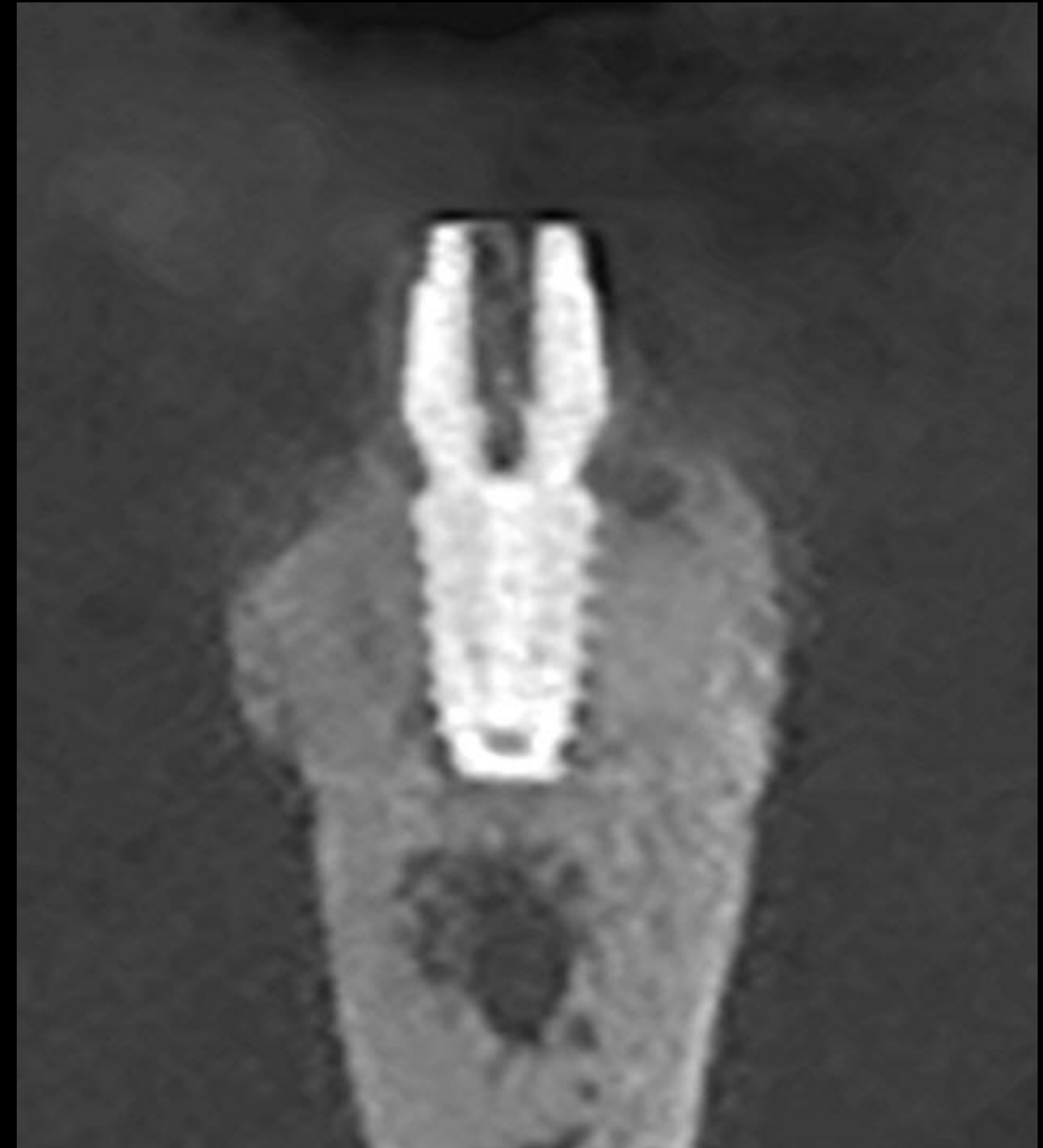

#46

Healing : 3 months (2023-07-13)

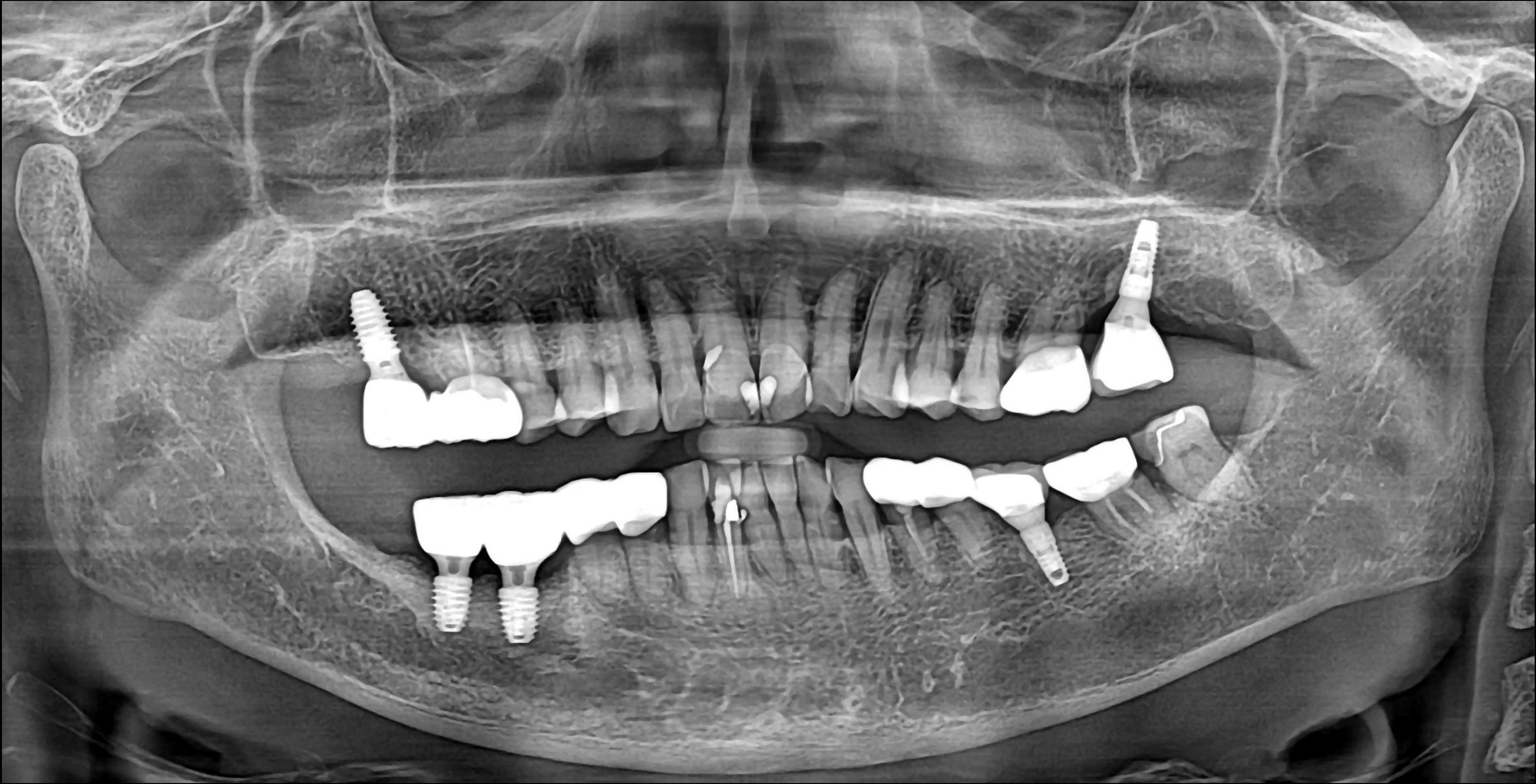

#47

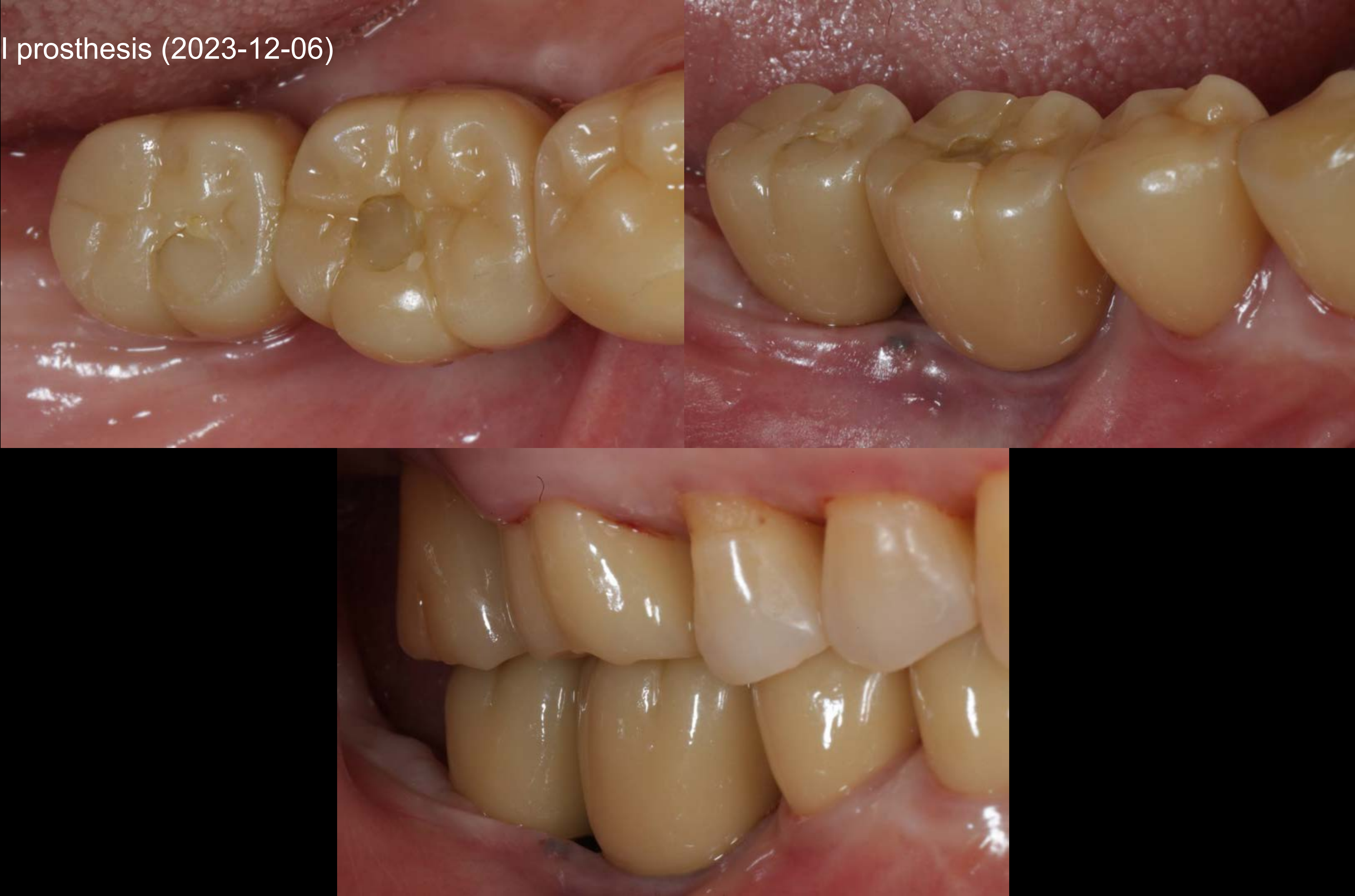

#46

Follow up : 3 months (2024-04-03)



Final prosthesis (2023-12-06)



Description

PN vs. PDRN

- Genetic material extracted from the testes and semen of salmon (*Oncorhynchus keta*)
- DNA polymer that exhibits tissue regeneration activity and anti-inflammatory effects



PN
(Polynucleotide)

Extracted from **salmon testes**

Polymer
500 ~ 3,000 kDa

Medical device material
Concentration used : 20 mg/mL
Average MW : 1,000 kDa

Physical restoration, hydration and tissue elasticity

PDRN
(Polydeoxyribonucleotide)

Extracted from **salmon semen**

Small molecules
50 ~ 1,500 kDa

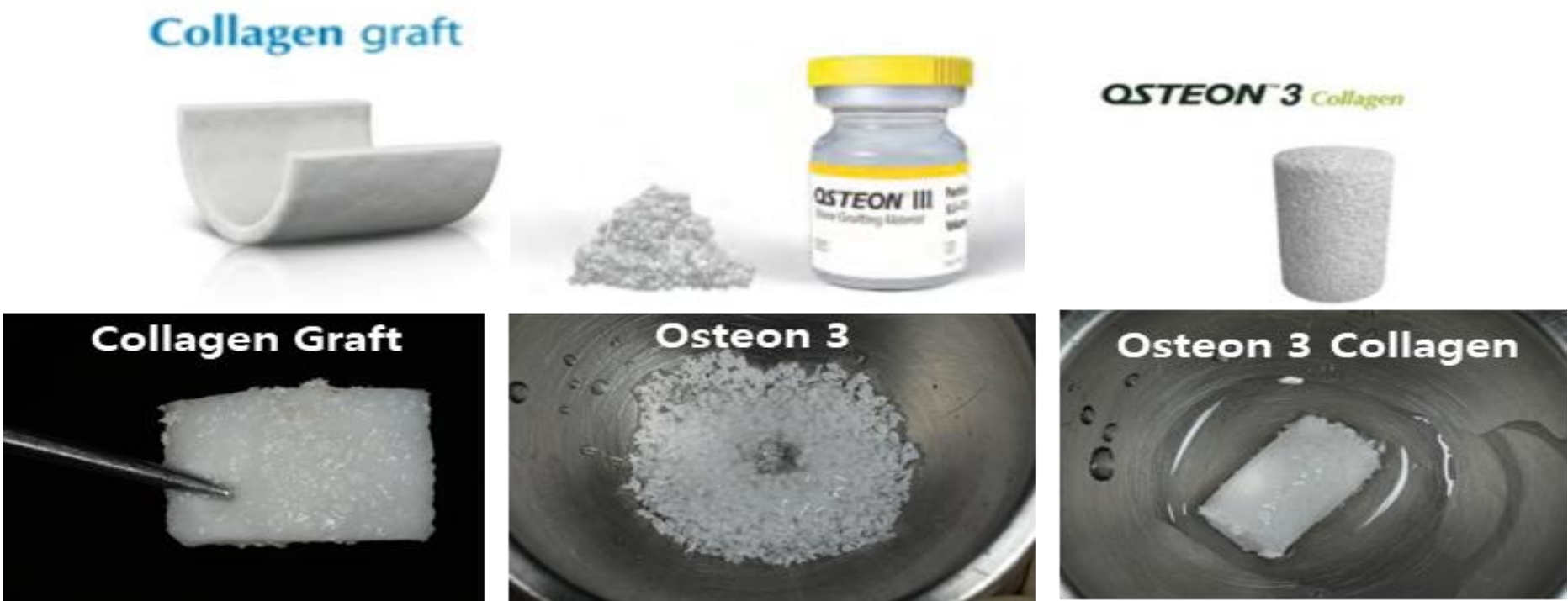Pharmaceutical material
Concentration used : 1.875 mg/mL
Average MW : 350 kDa

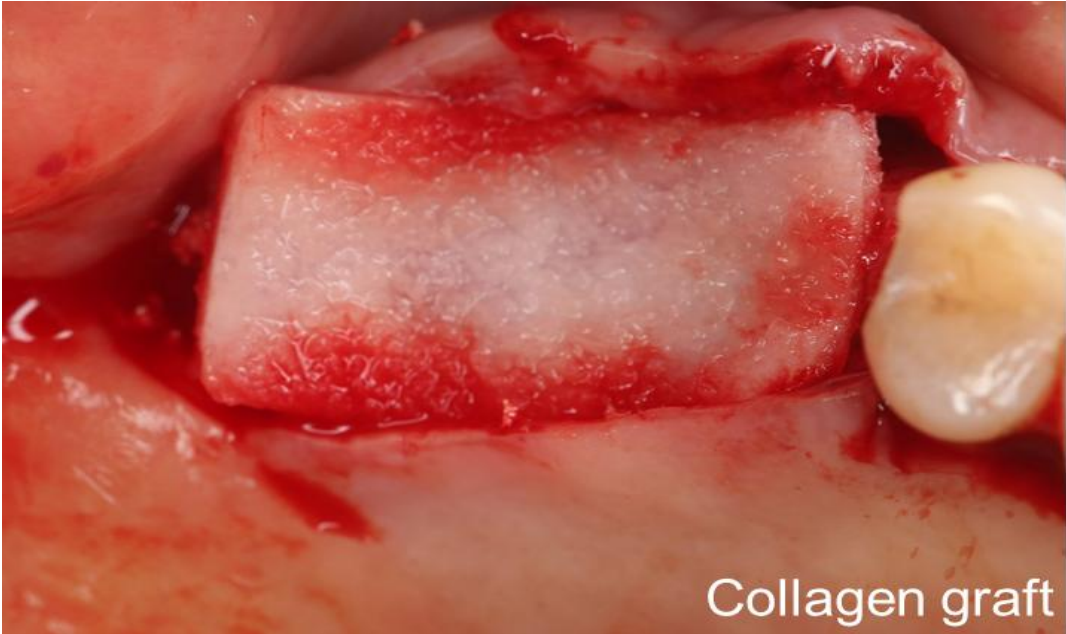
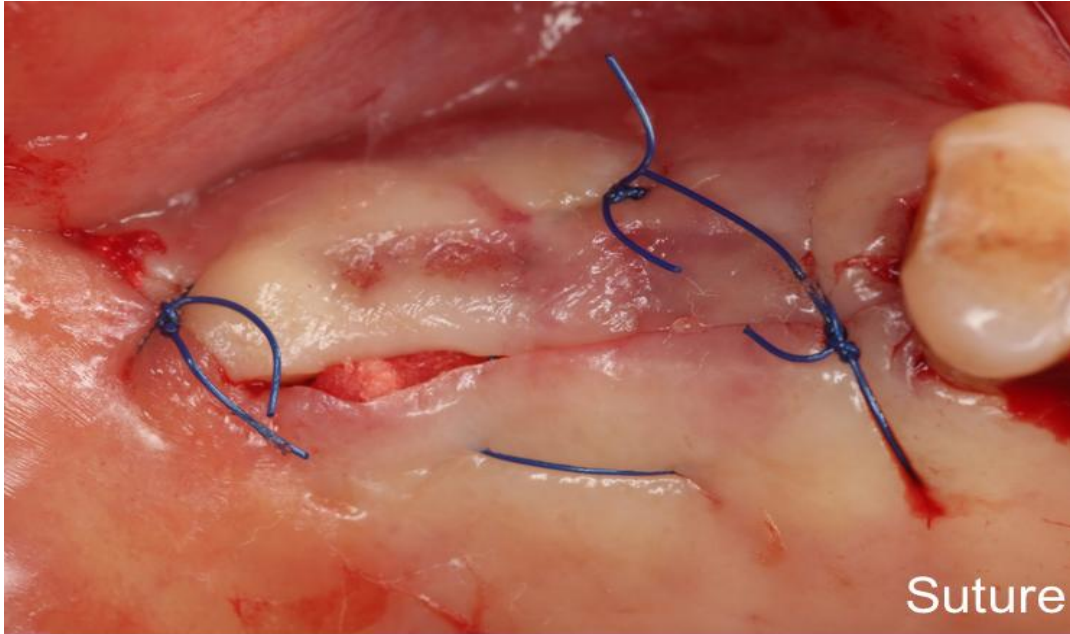
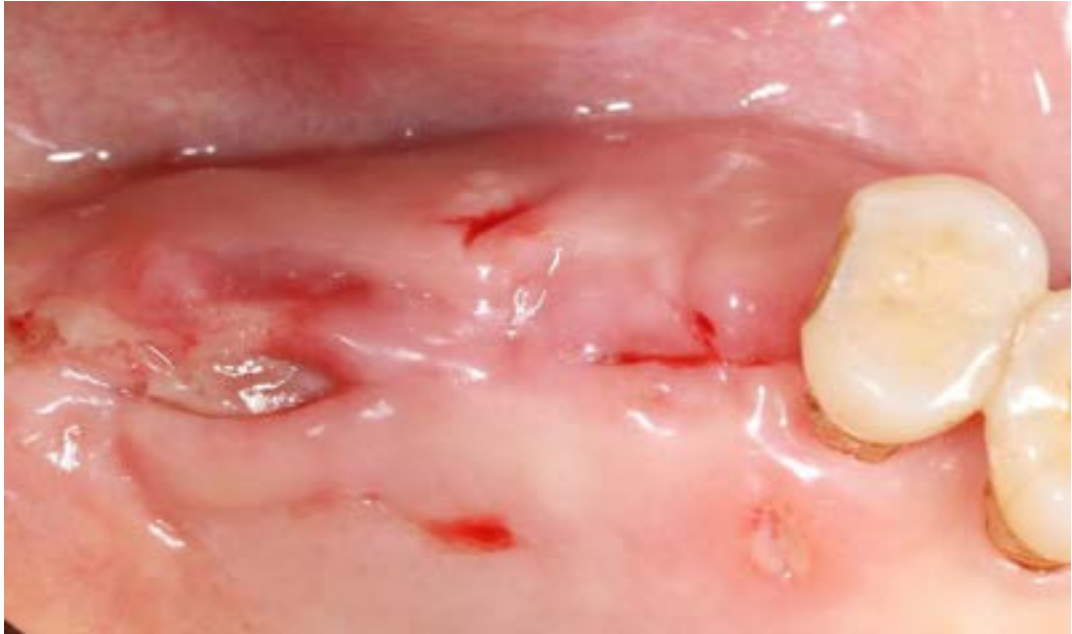

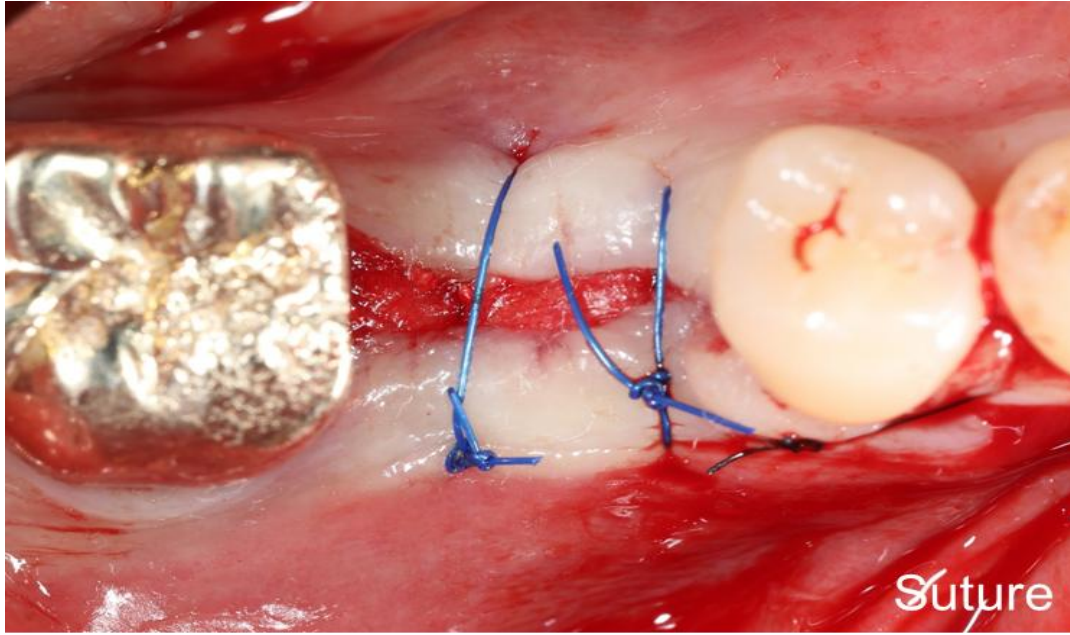

Wound healing, anti-inflammation, angiogenesis

Examples of PDRN

@ Dentium Dental Clinic

- Soaking Collagen Graft and Bone graft material in PDRN injection before grafting
- The remaining PDRN is injected into the surgical site (after suture)



	Surgery		Healing : 1 week
Case 1 Collagen Graft	 Collagen graft	 Suture	
Case 2 OSTEON™ 3, OSTEON™ 3 Collagen	 OSTEON™ 3 + OSTEON™ 3 Collagen	 Suture	

Indication of PDRN or PN

Fast soft and hard tissue healing

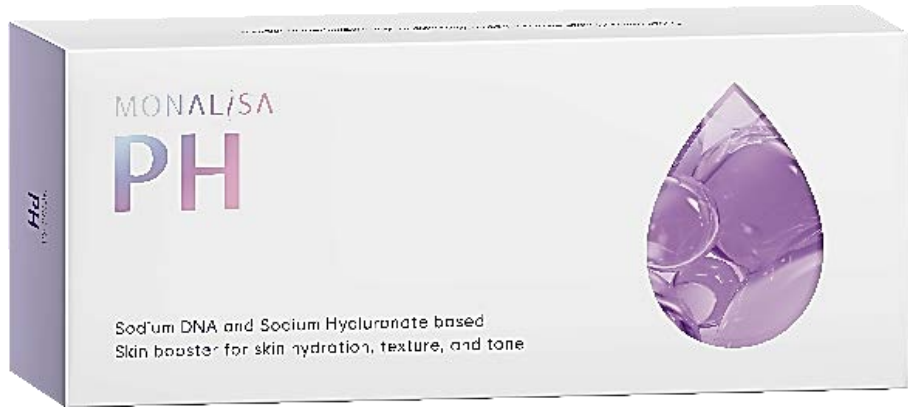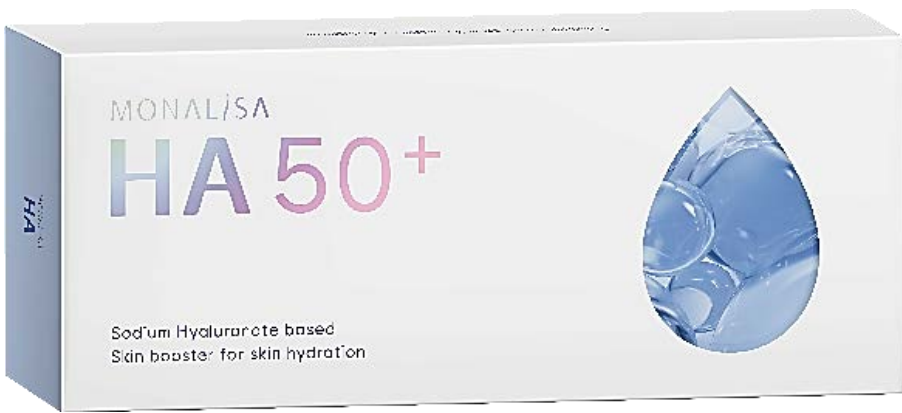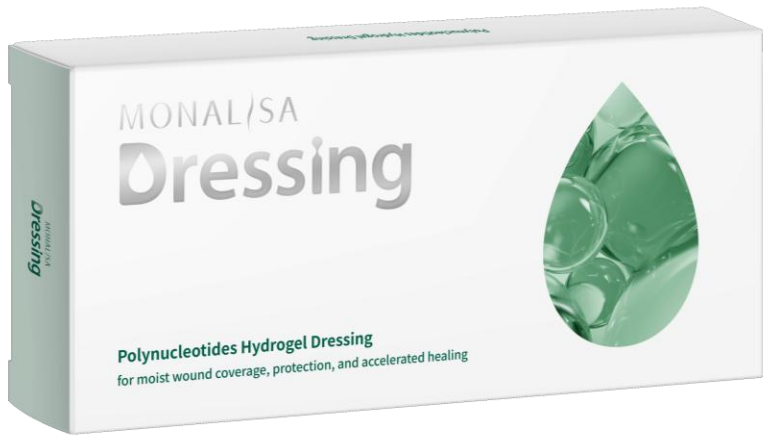White lesions

TMJ pain and inflammation relieve

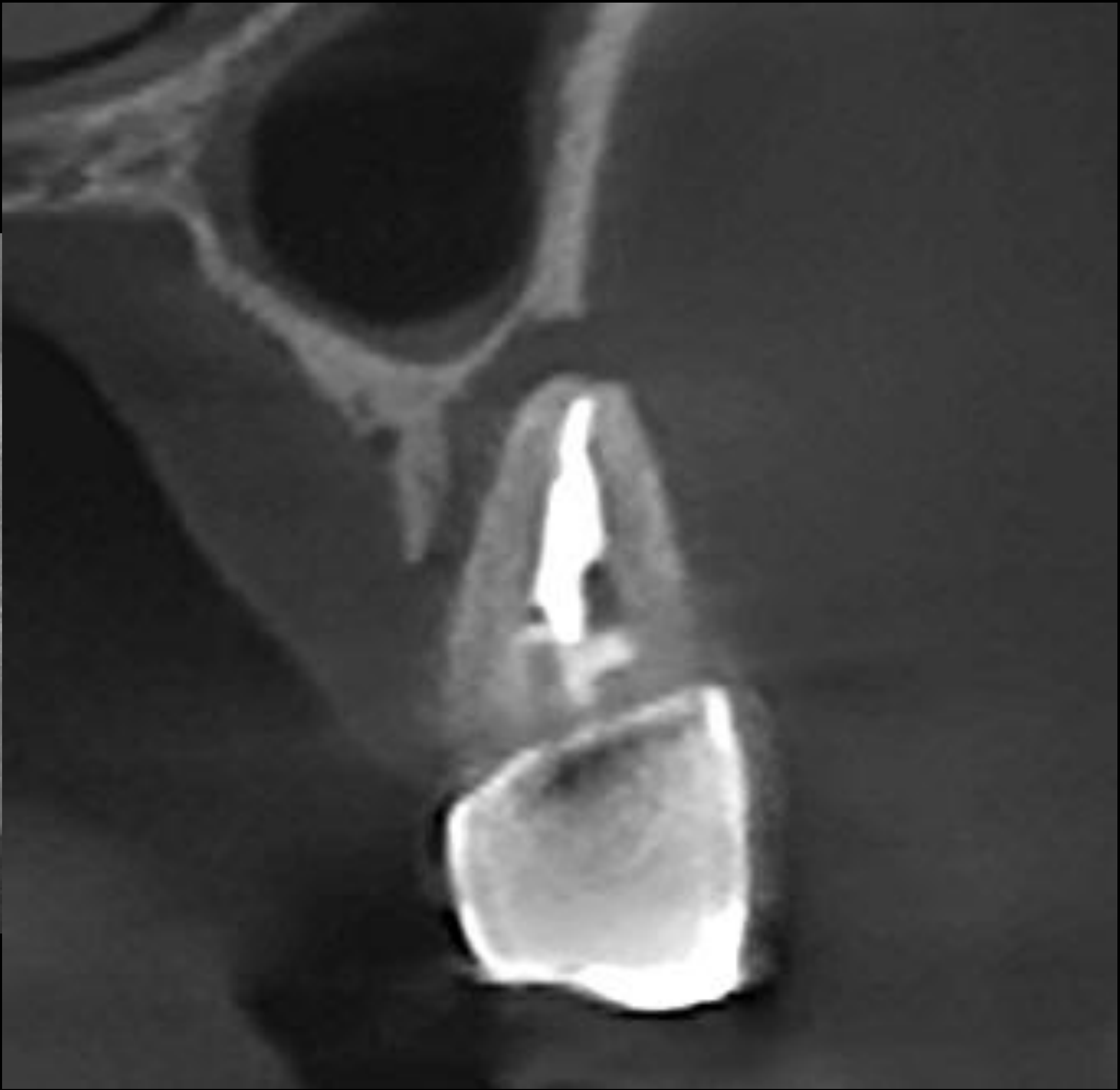
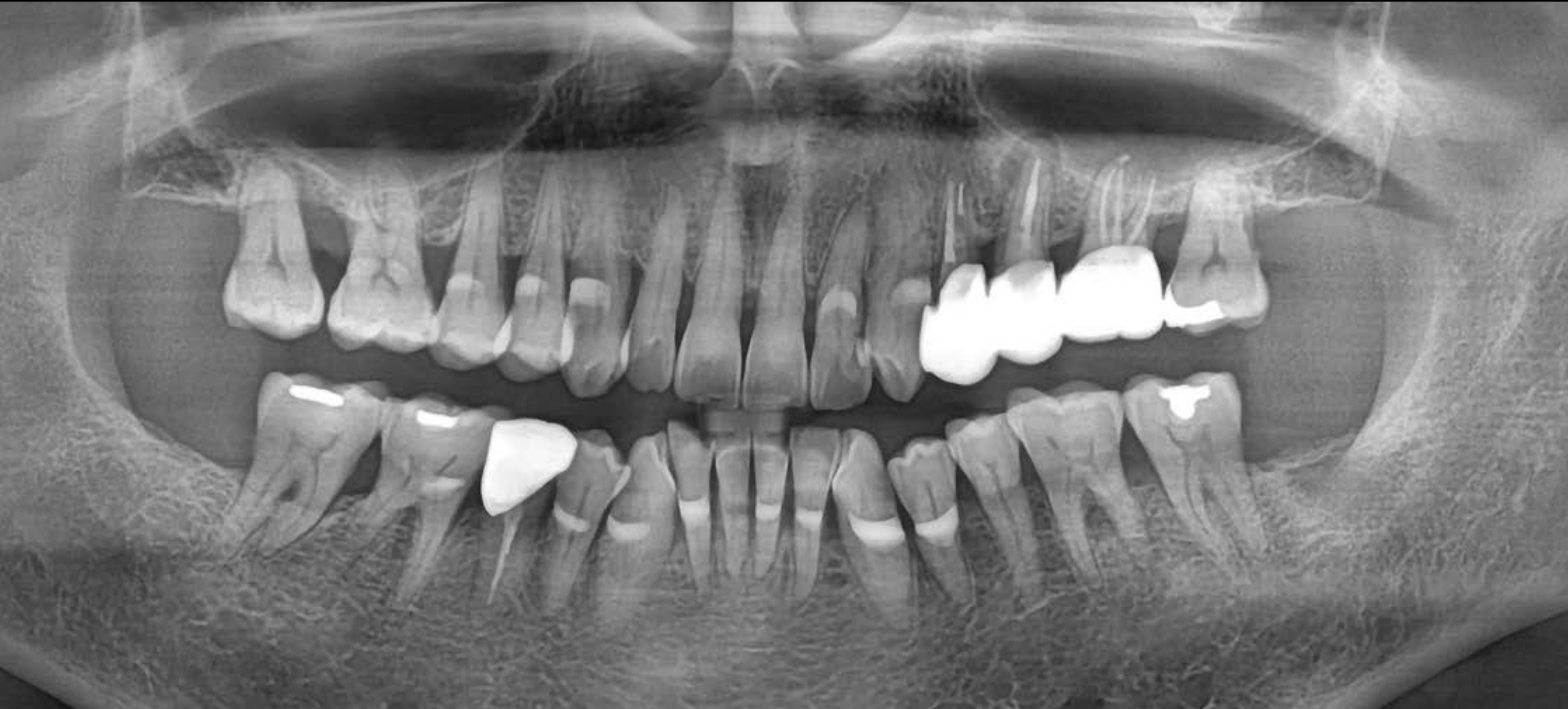Cellulitis

Product Introduction – Monalisa Skinboosters, Dressing

Category	Medical Device (II)	Cosmetics		
Product	MONALISA Dressing	MONALISA HA 50+	MONALISA PN30	MONALISA PH
Shape	No impurities, transparent and colorless gel			
Ingredient	Polynucleotide (PN)	Hyaluronic Acid (HA)	Polynucleotide (PN)	Polynucleotide (PN) + Hyaluronic Acid (HA)
Conc.	30 mg/mL	50 mg/mL (High : low-molecular ratio = 1:4)	30 mg/mL	PN 20 mg/mL non-crosslinked HA 10 mg/mL
Volume	1.0 mL	2.0 mL		
Storage Temp.	2 ~ 25℃			

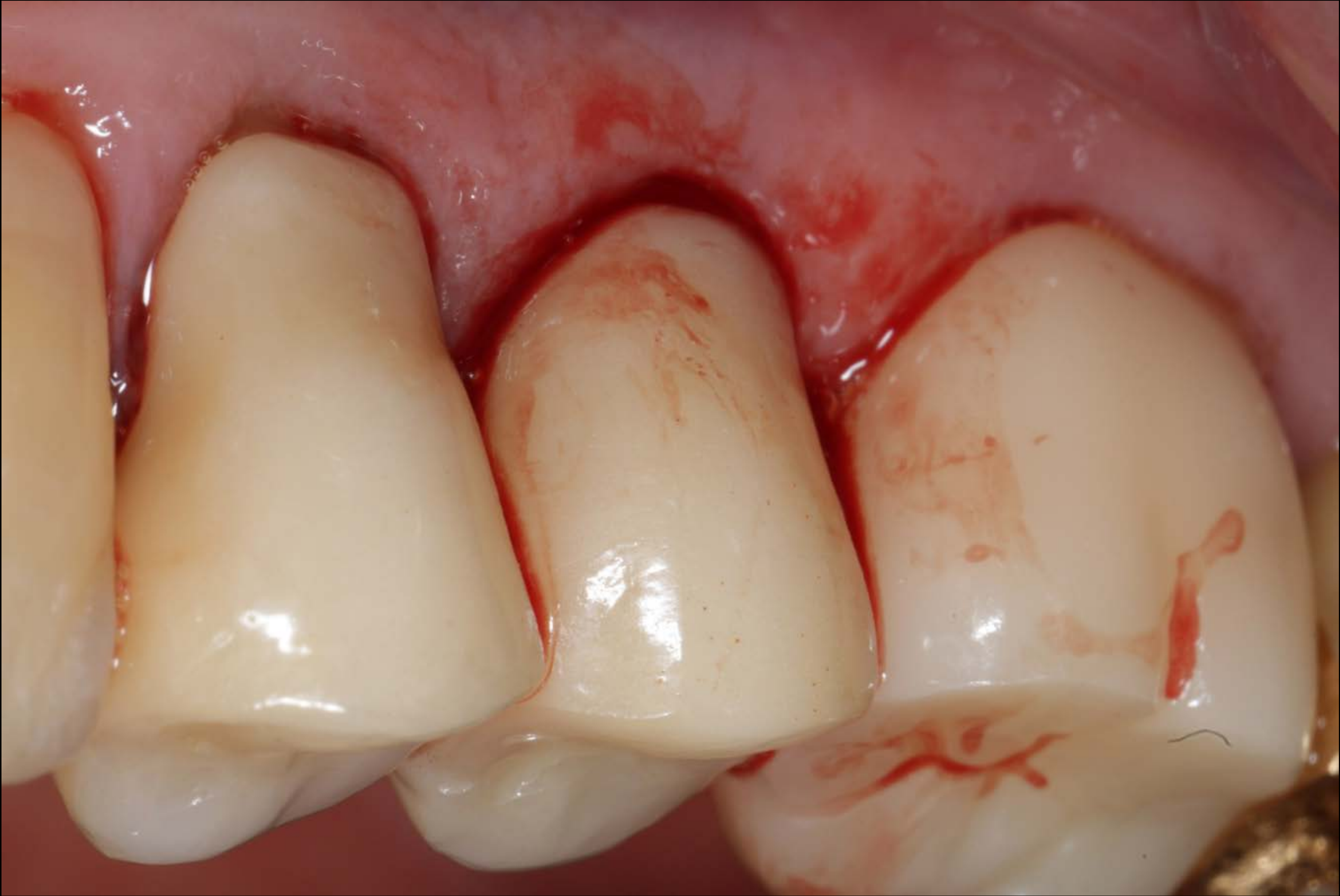

Oral exam (2024-10-30)

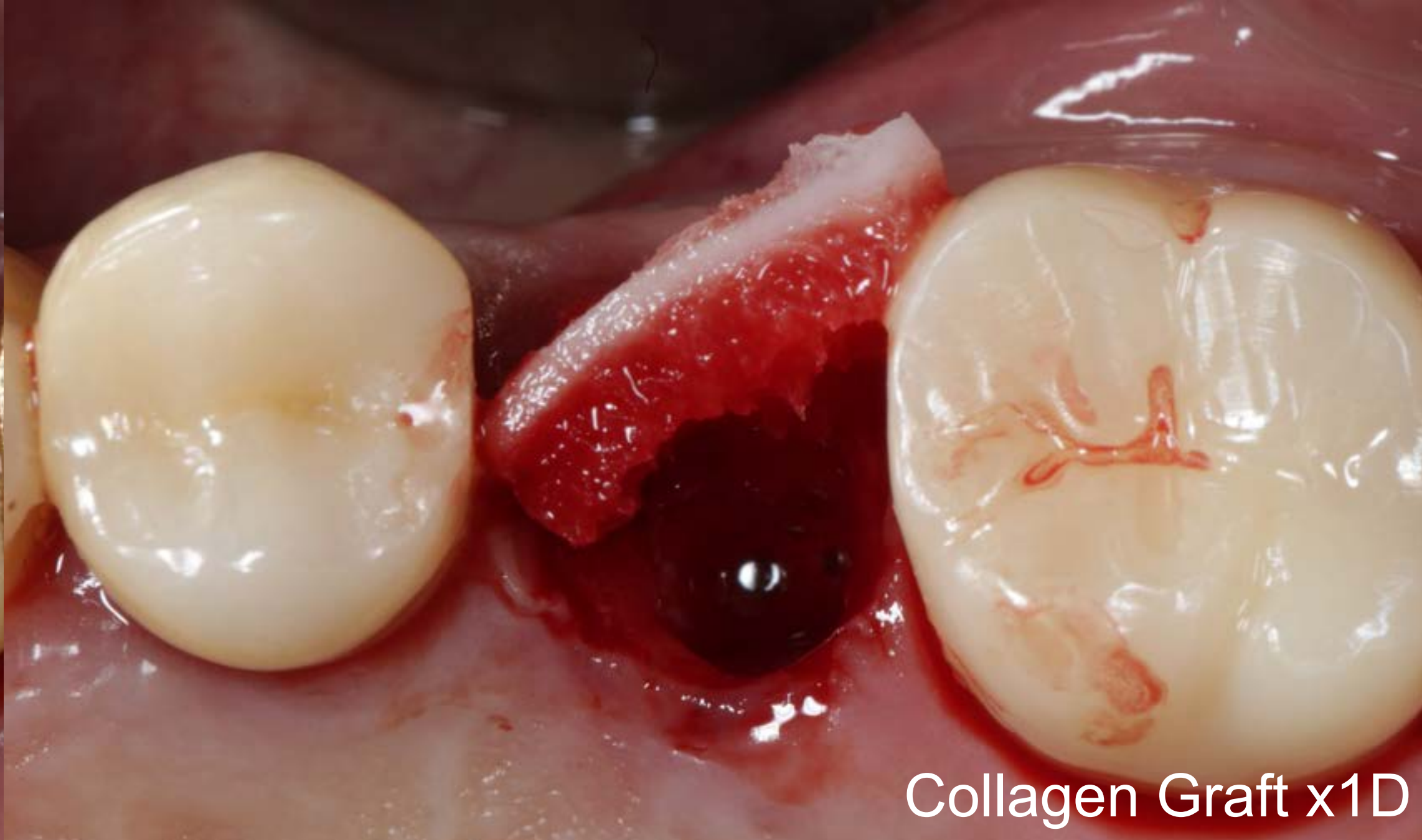
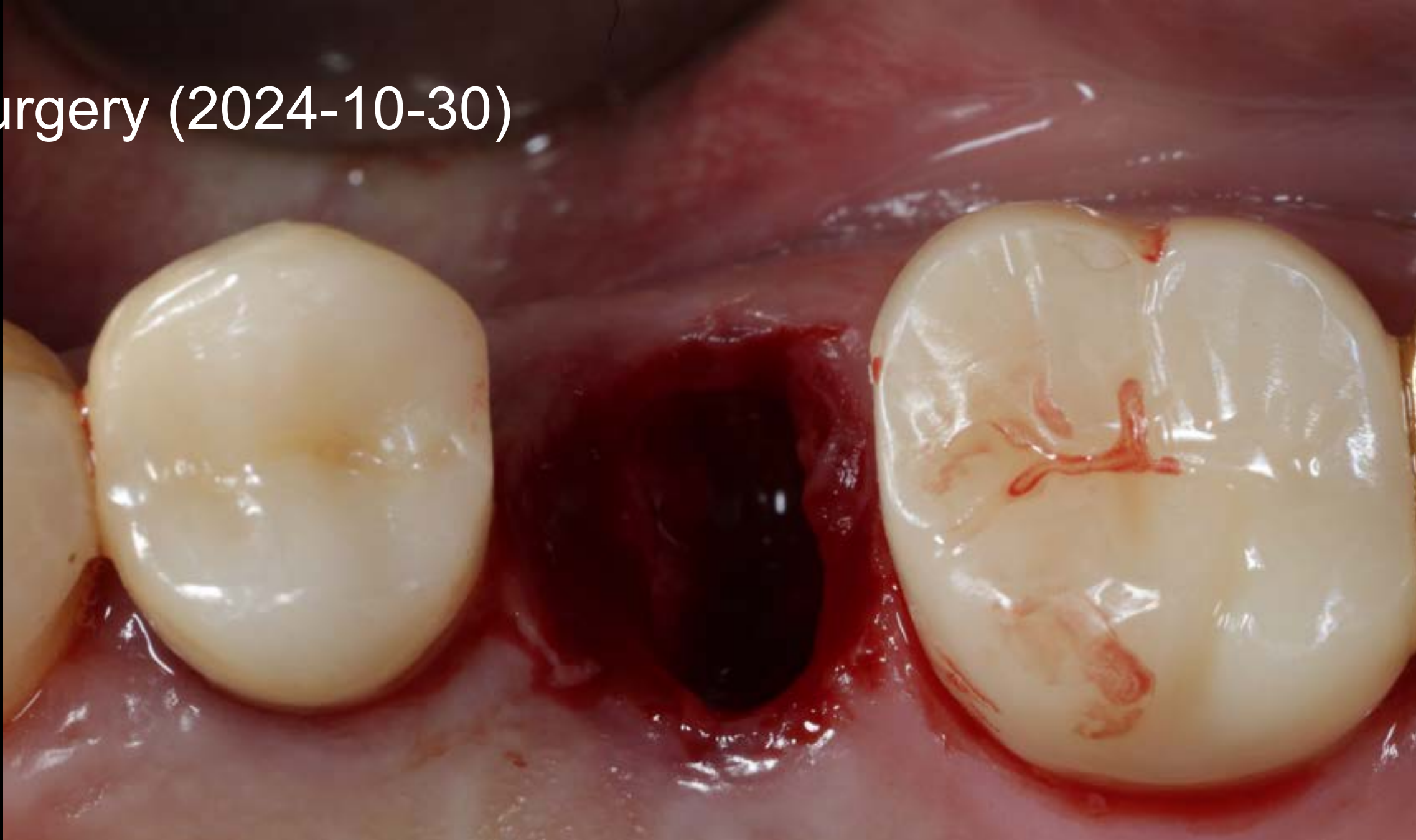


#25

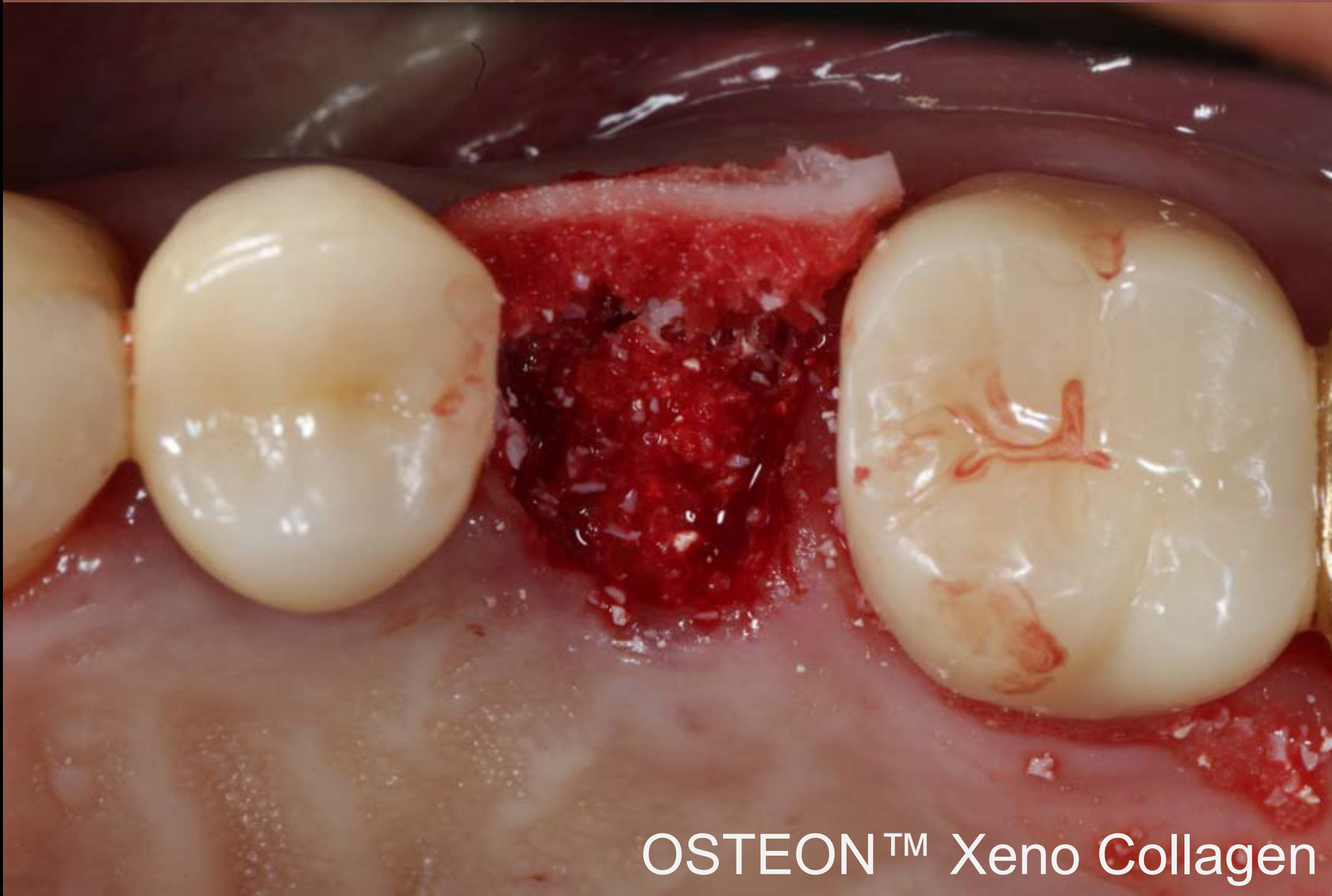Pre-op (2024-10-30)



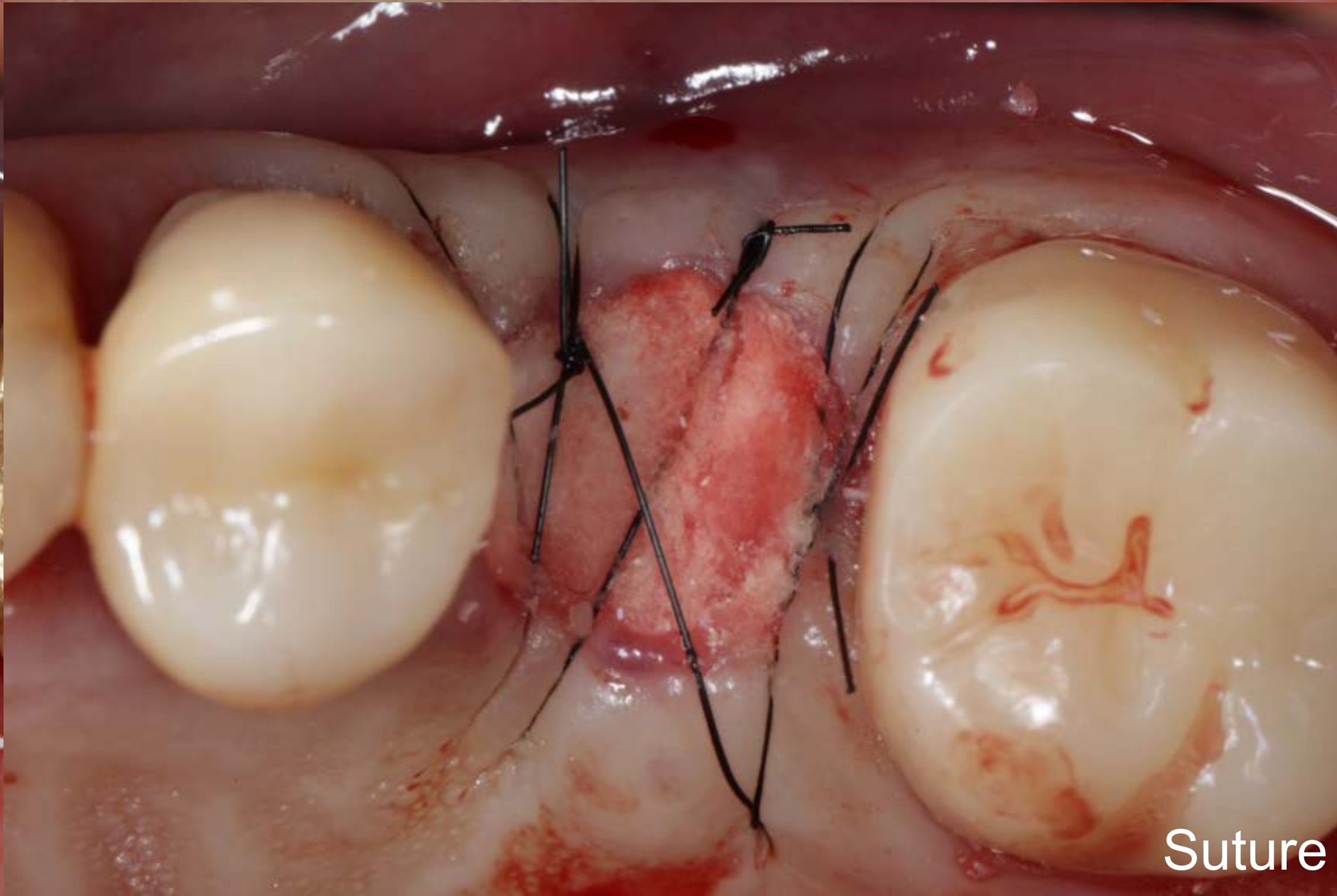
Surgery (2024-10-30)



Collagen Graft x1D

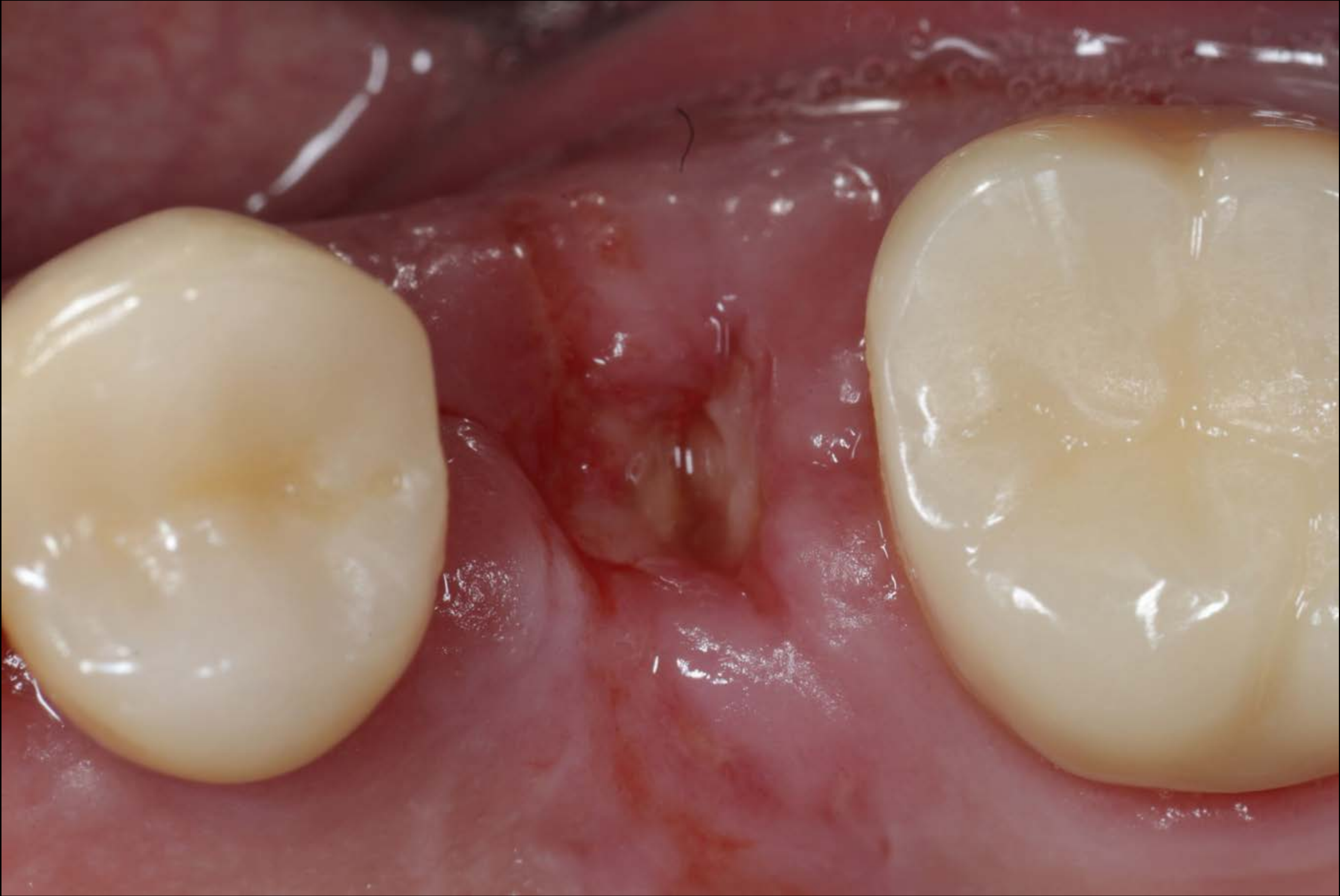

OSTEON™ Xeno Collagen

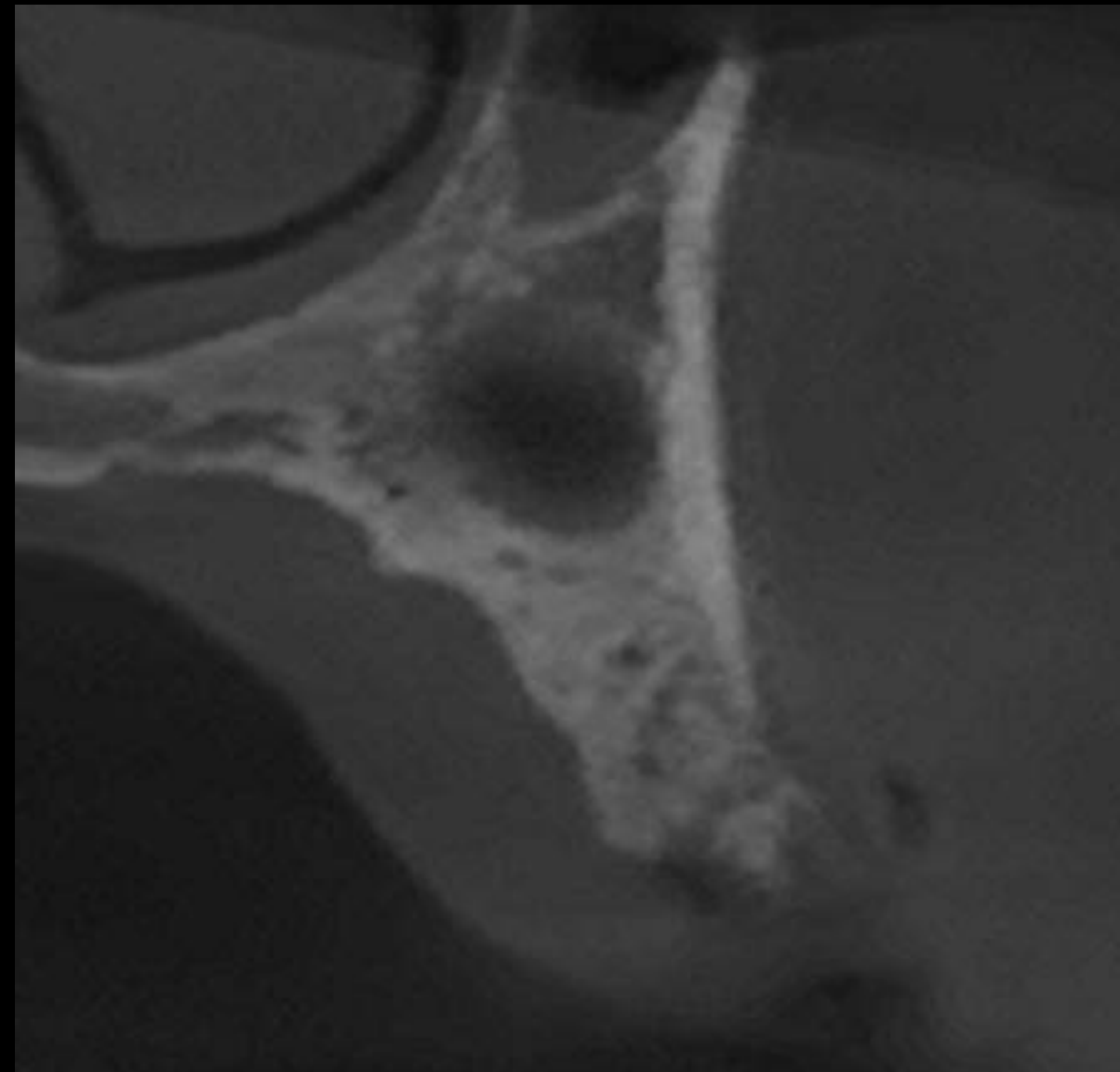


Suture

Healing : 1 week (2024-11-06)

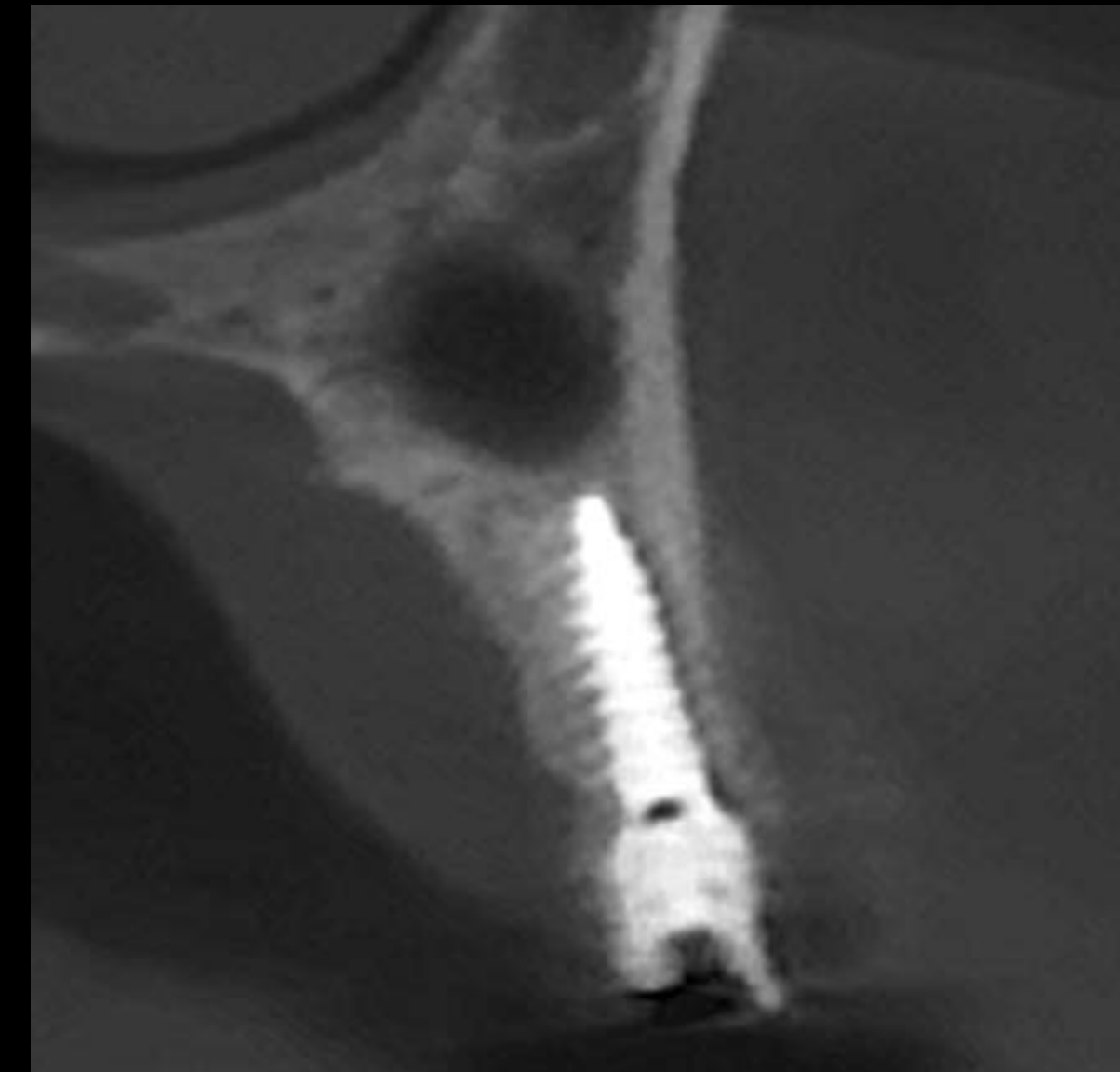


Pre-op CT (2025-06-25)



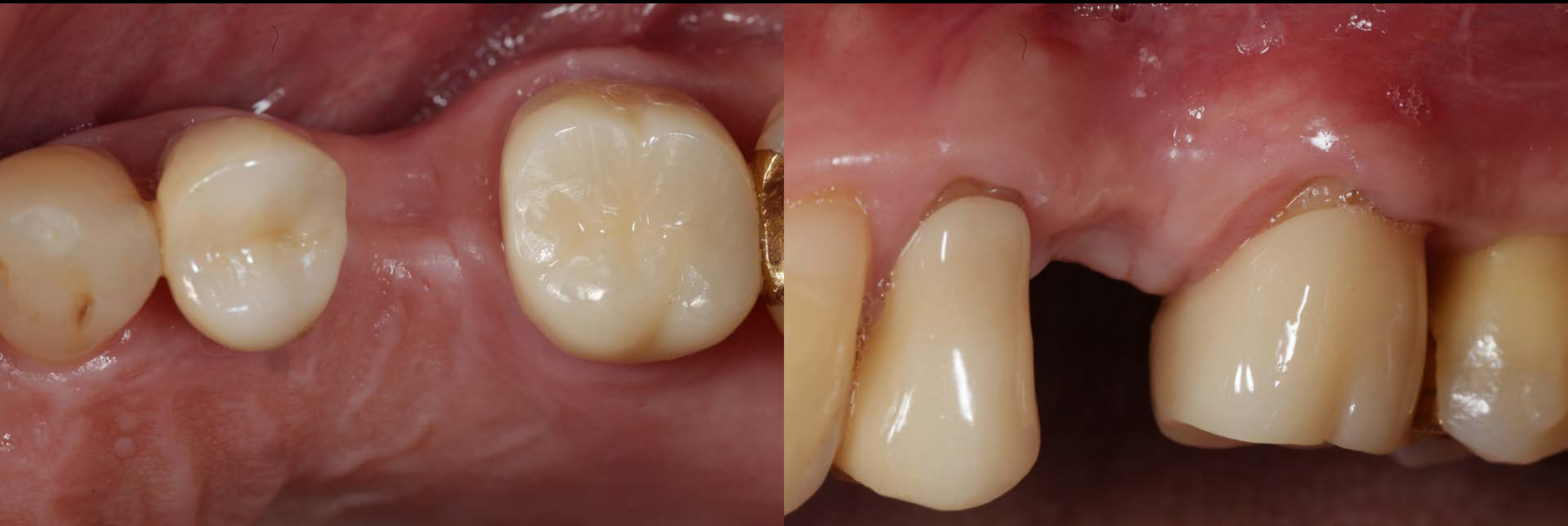#25

Post-op CT (2025-06-25)

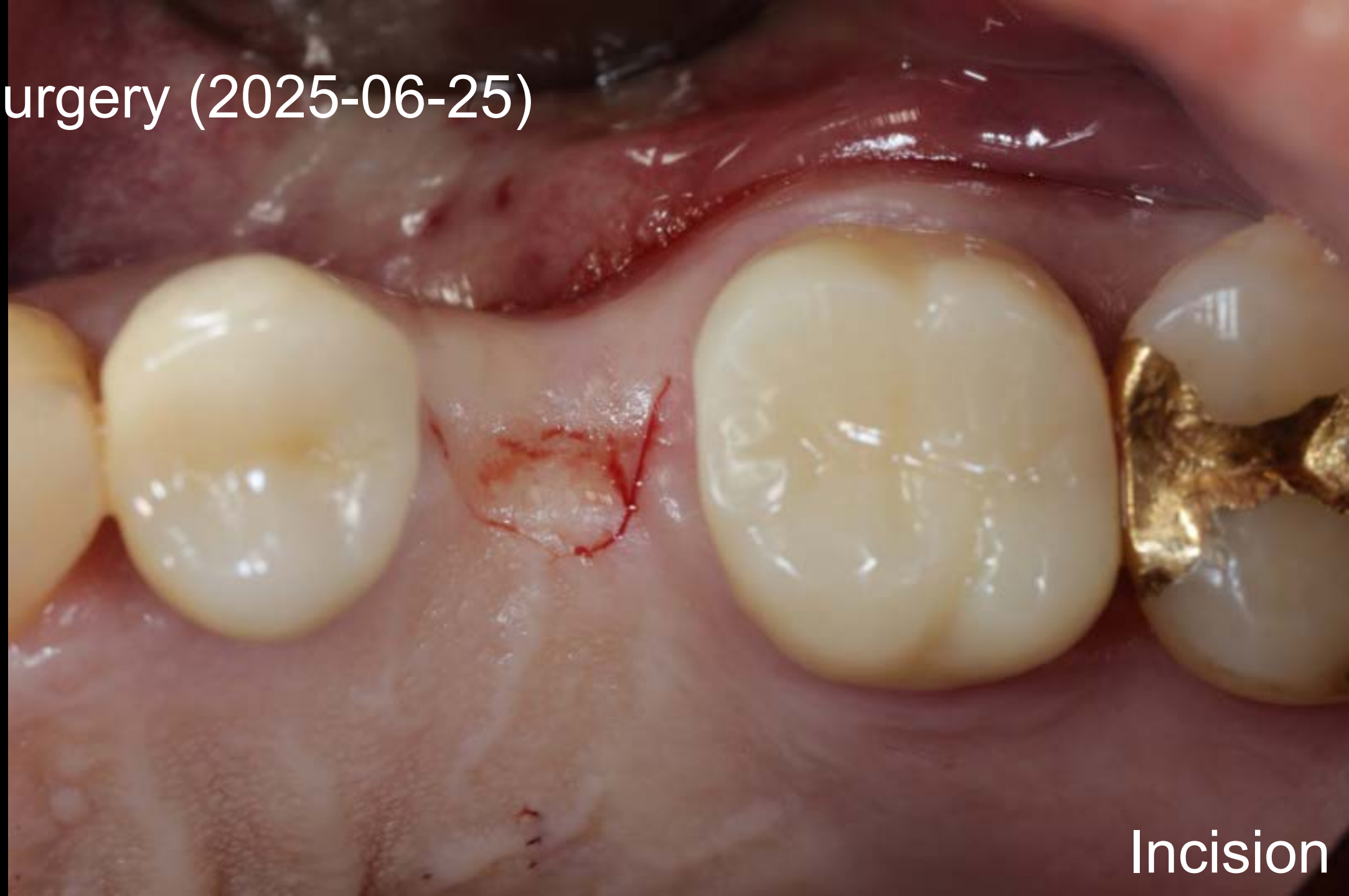

#25

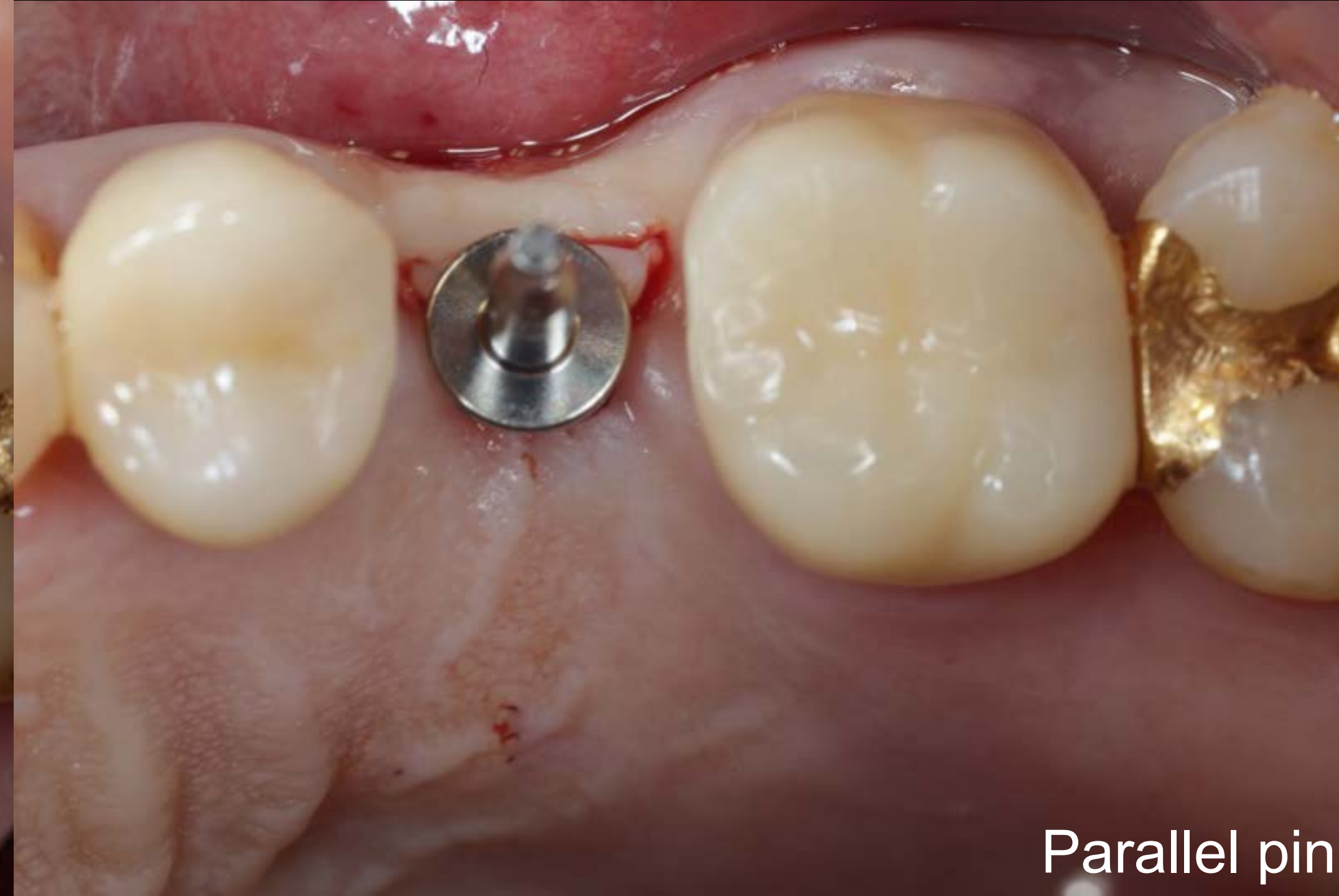Pre-op 2nd Surgery (2025-06-25)



2nd Surgery (2025-06-25)



Incision

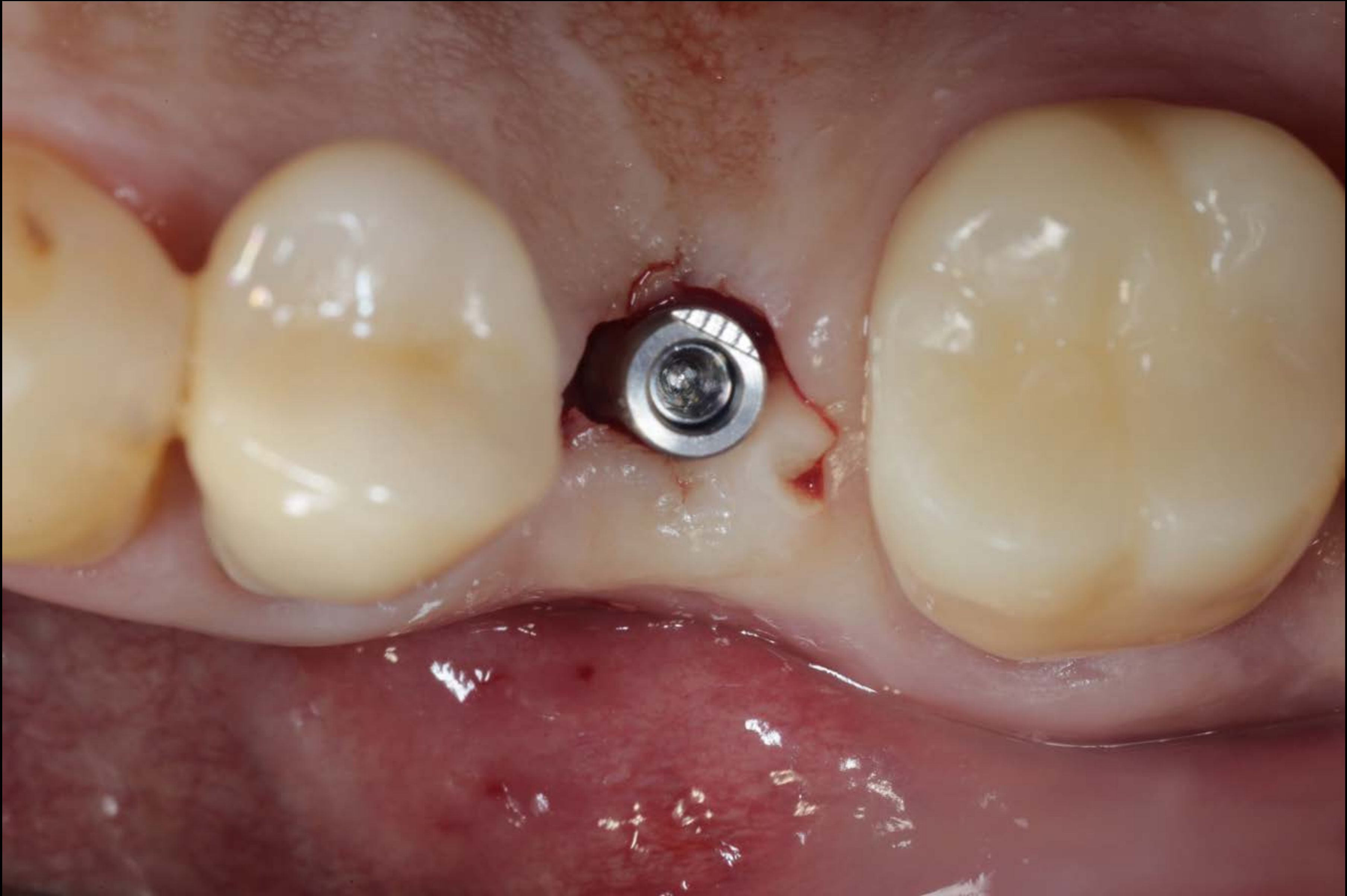


Parallel pin

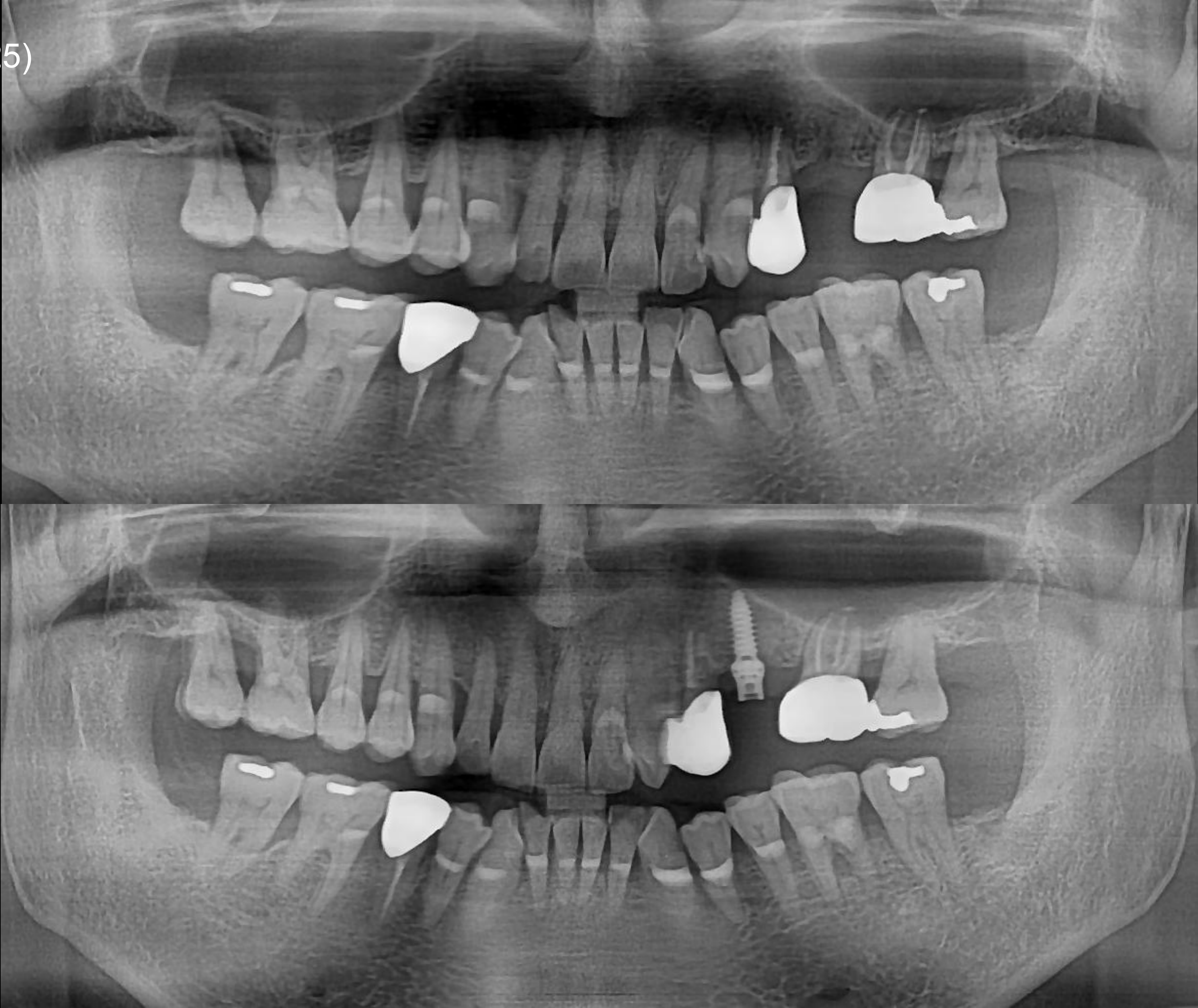


bright TL (Ø3.0 X 9.0)

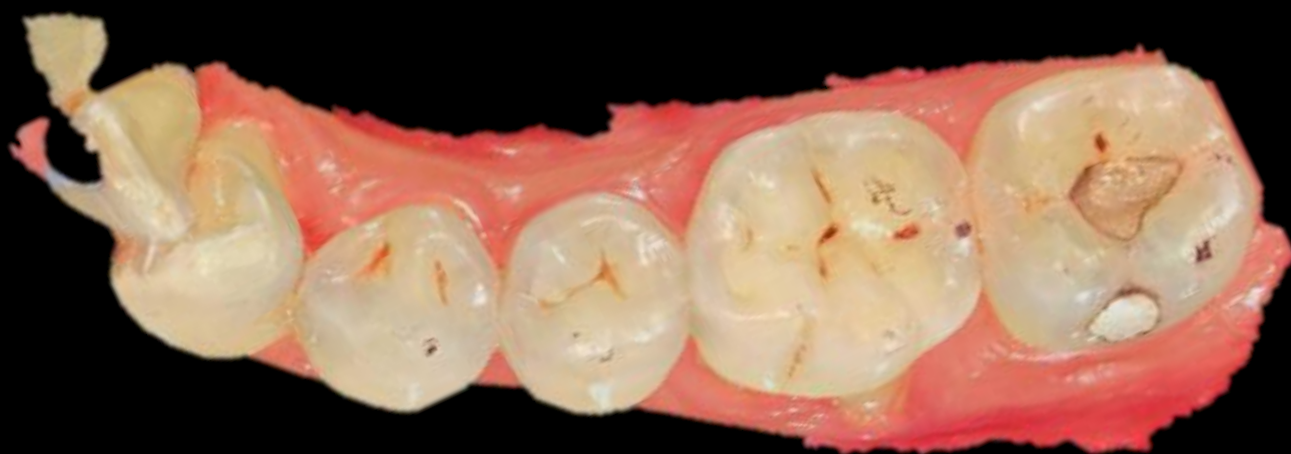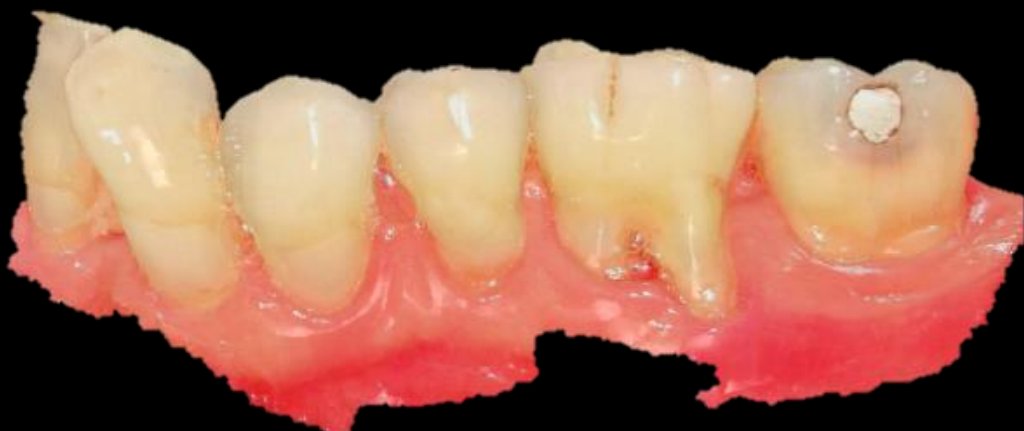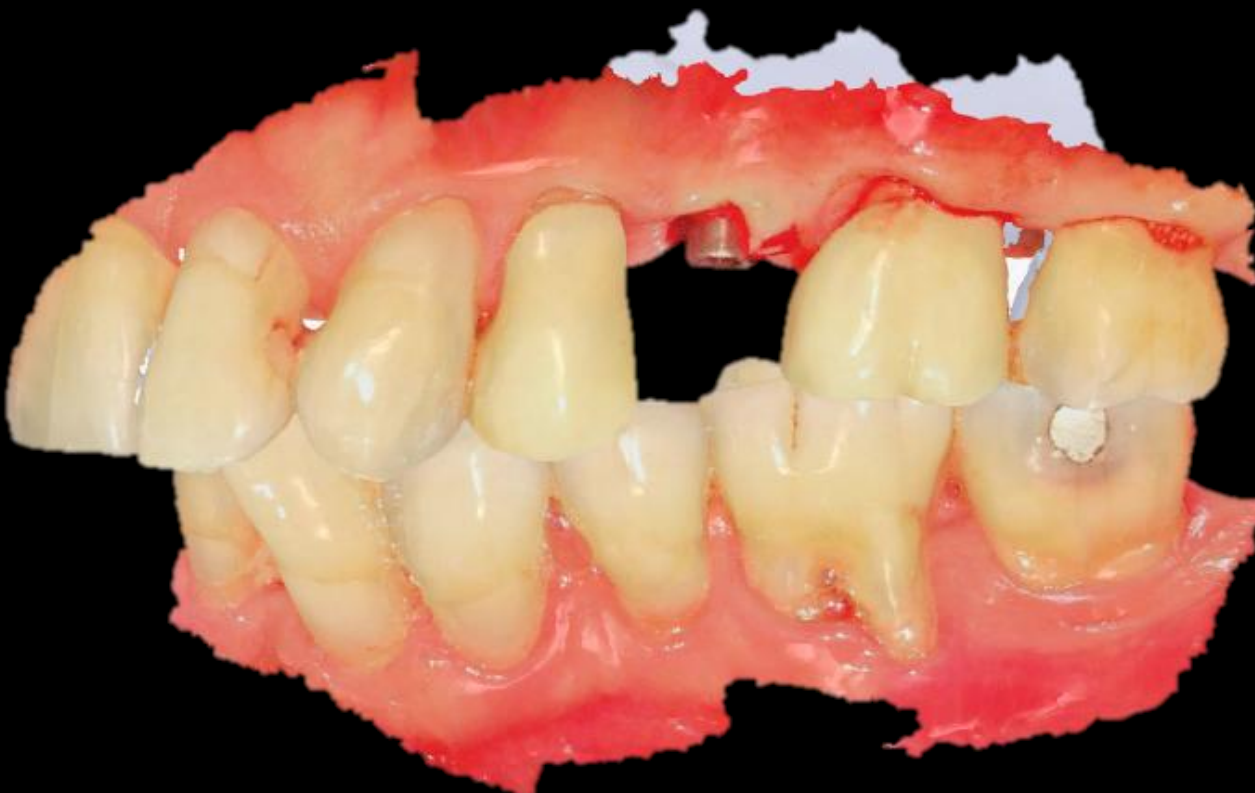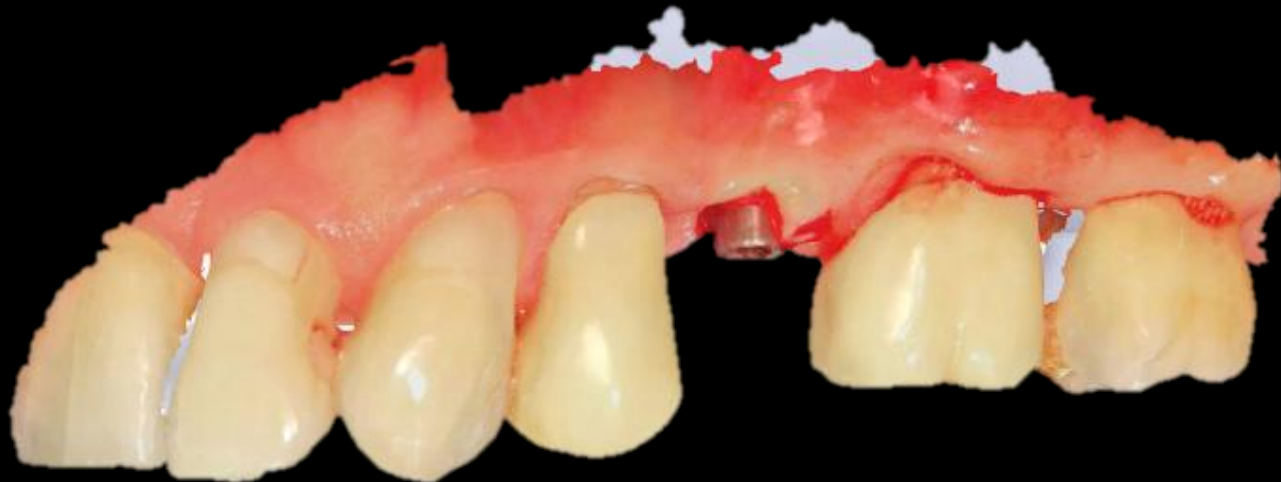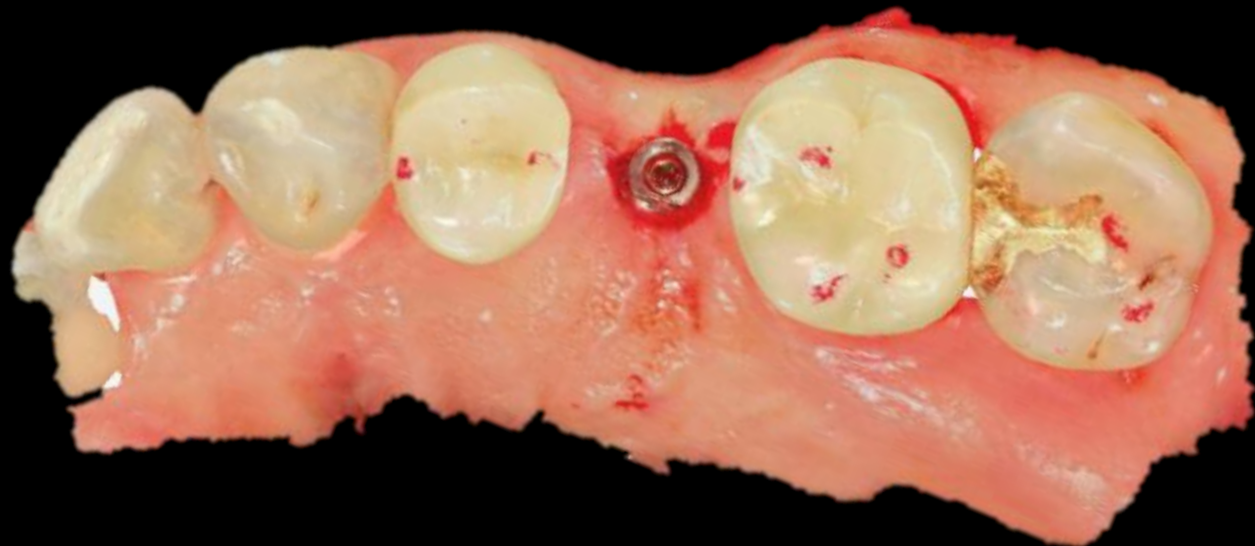
Post-op (2025-06-25)



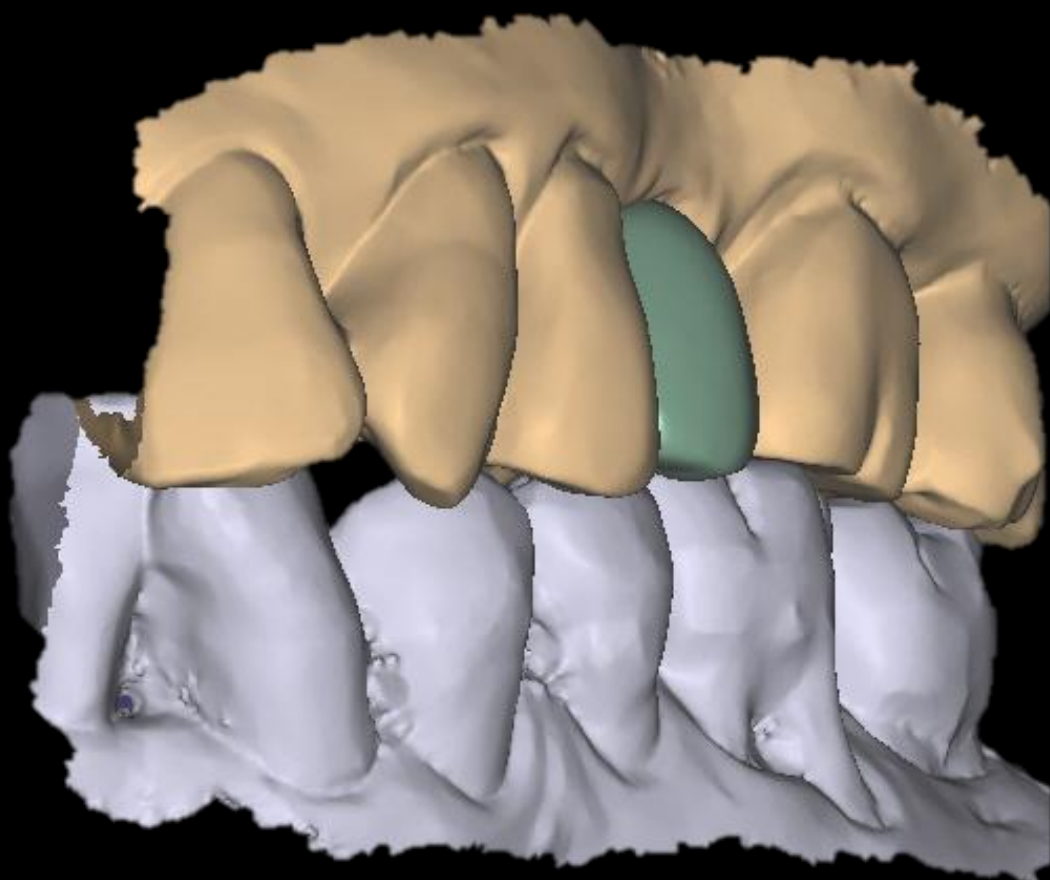
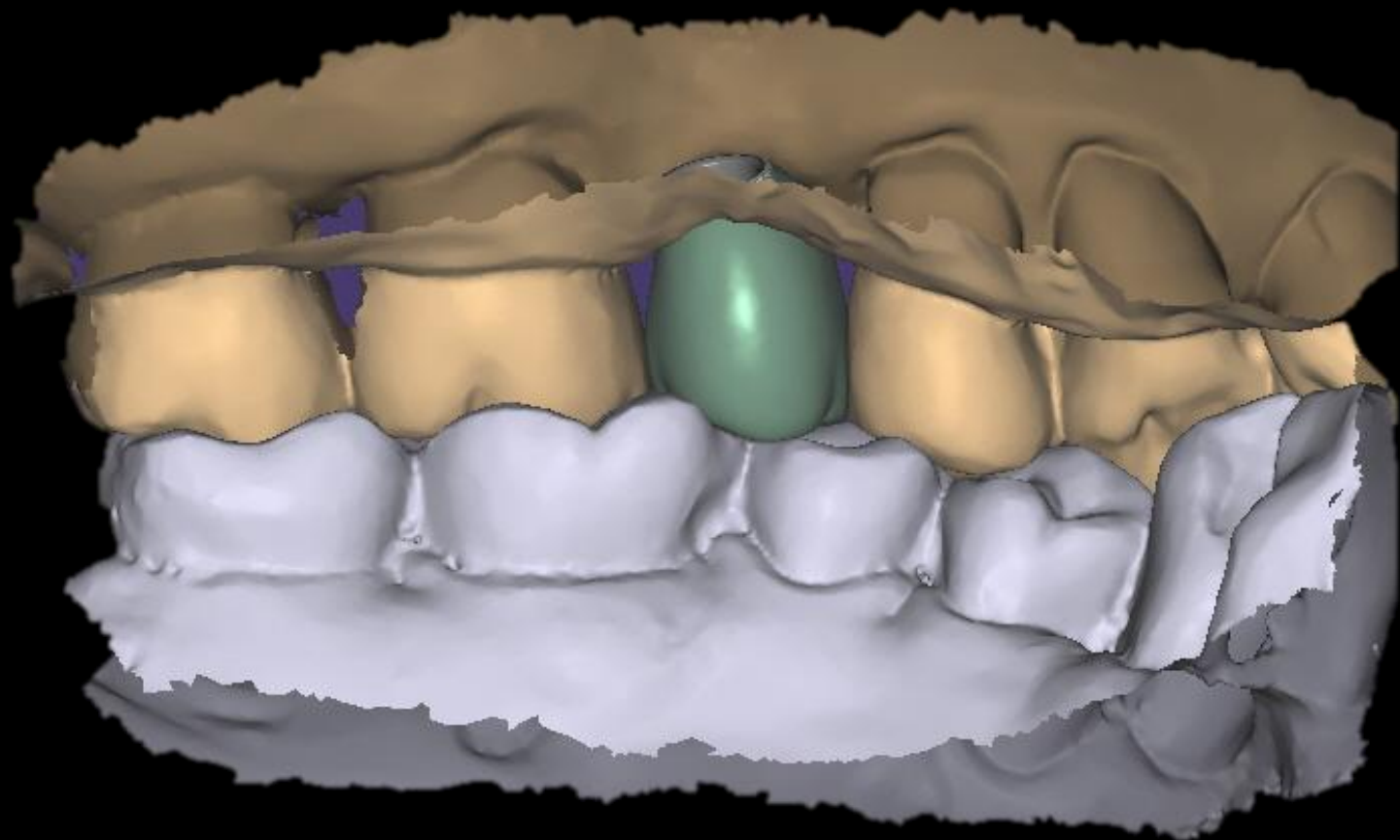
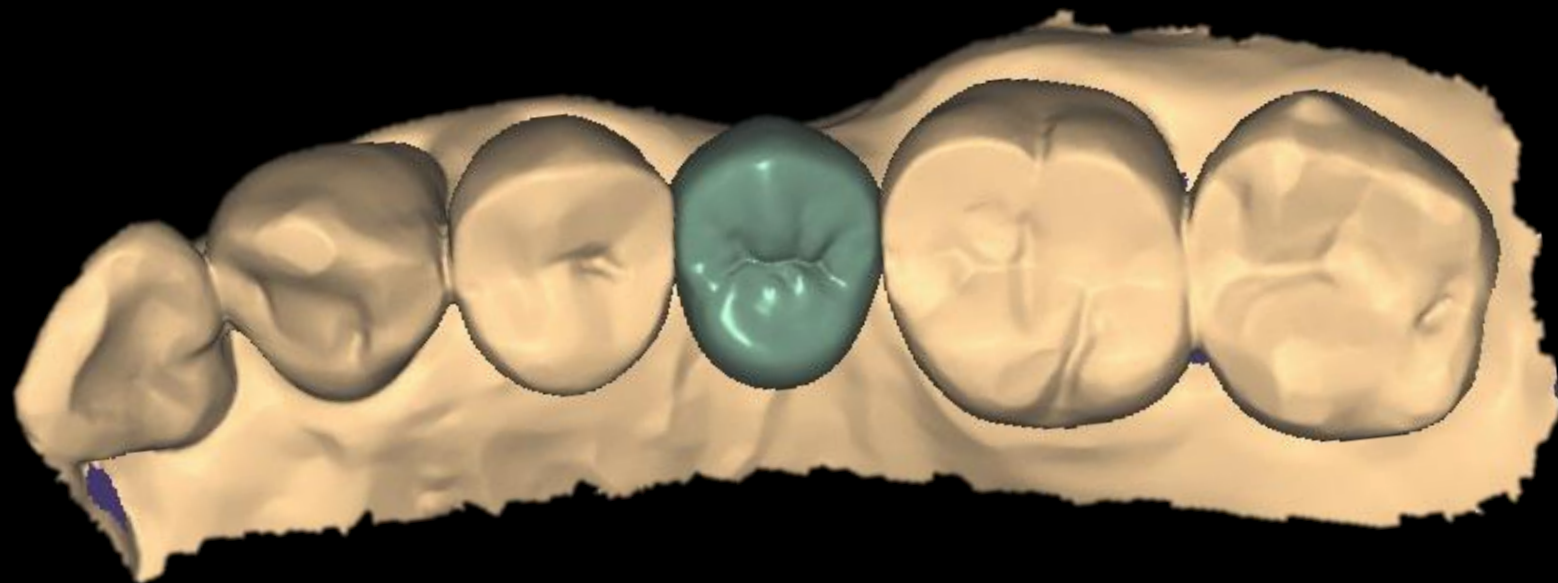
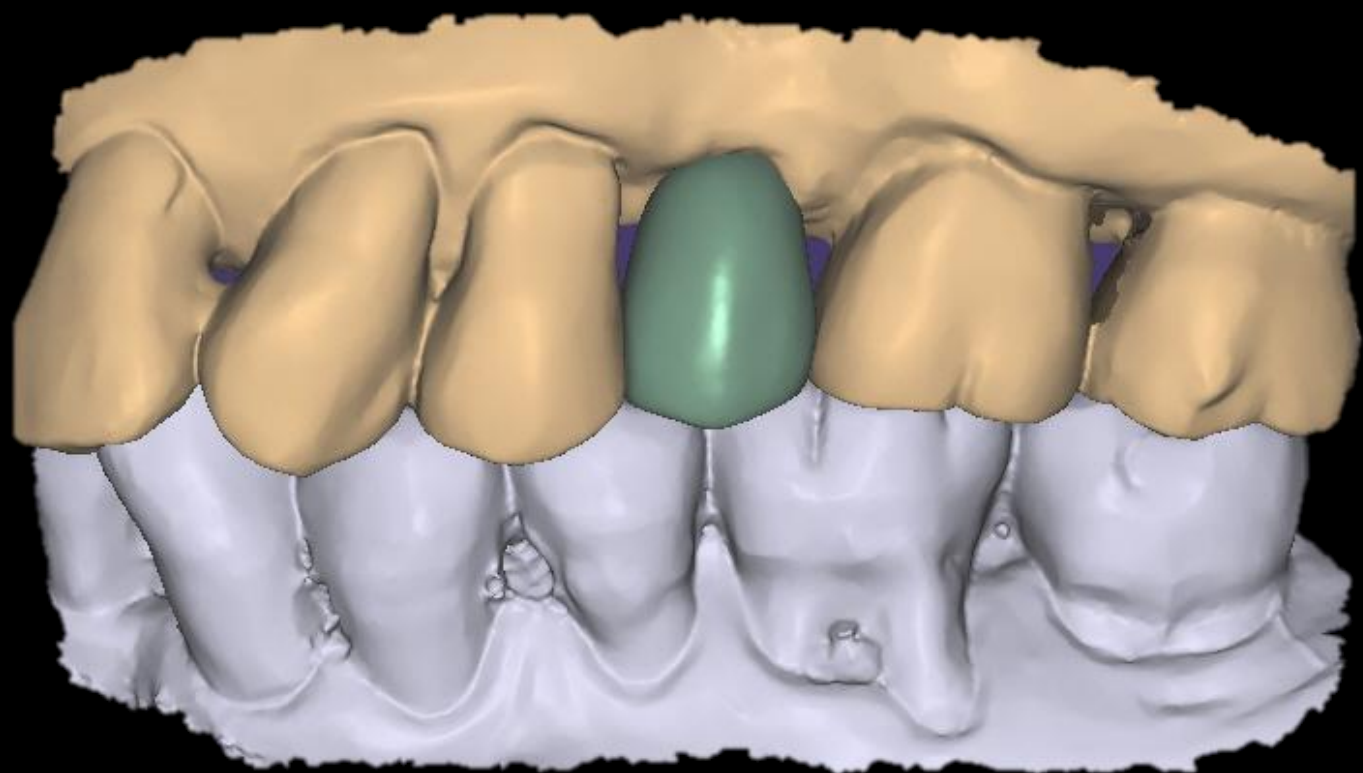
Pre-op (2025-06-25)



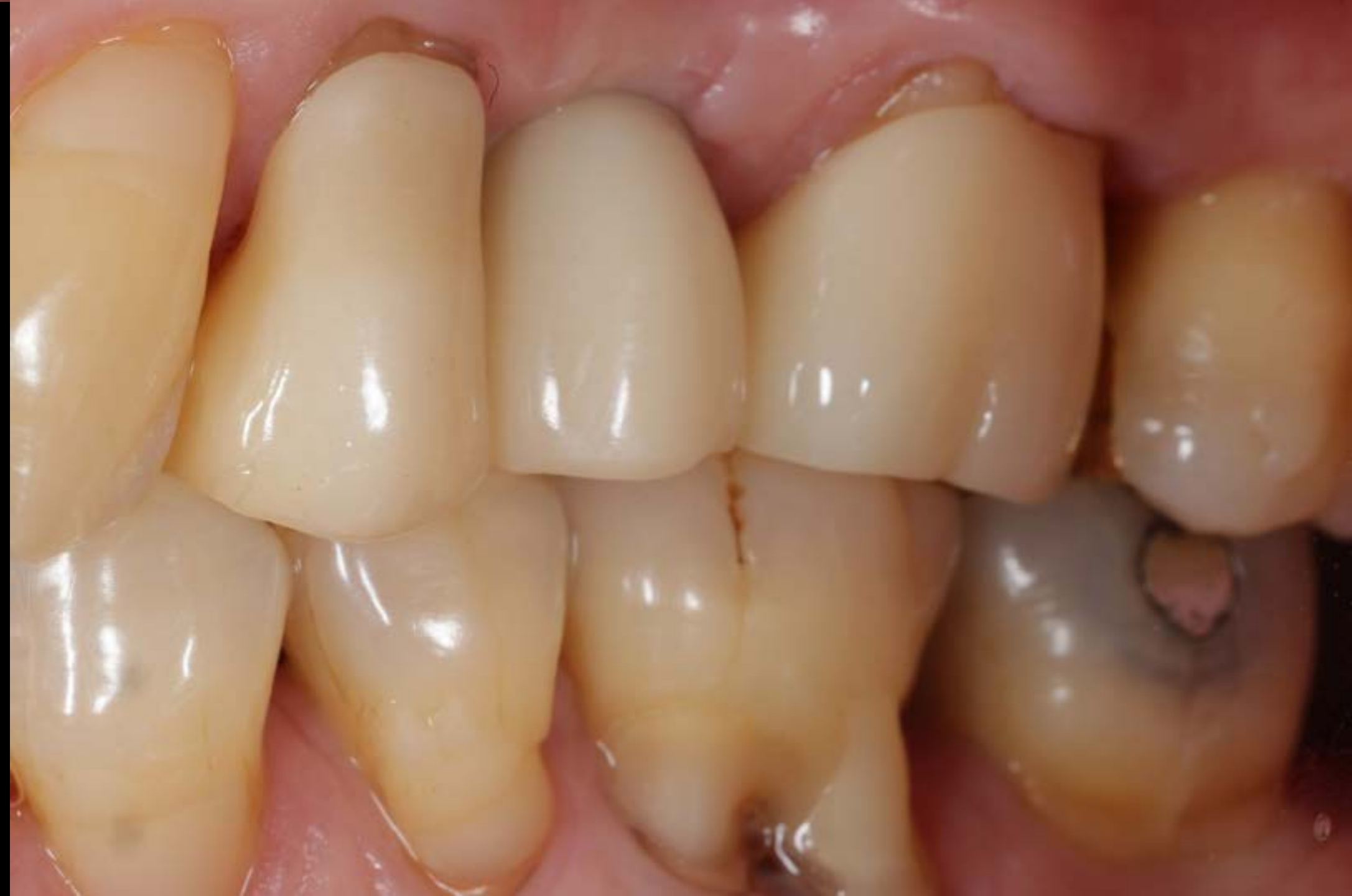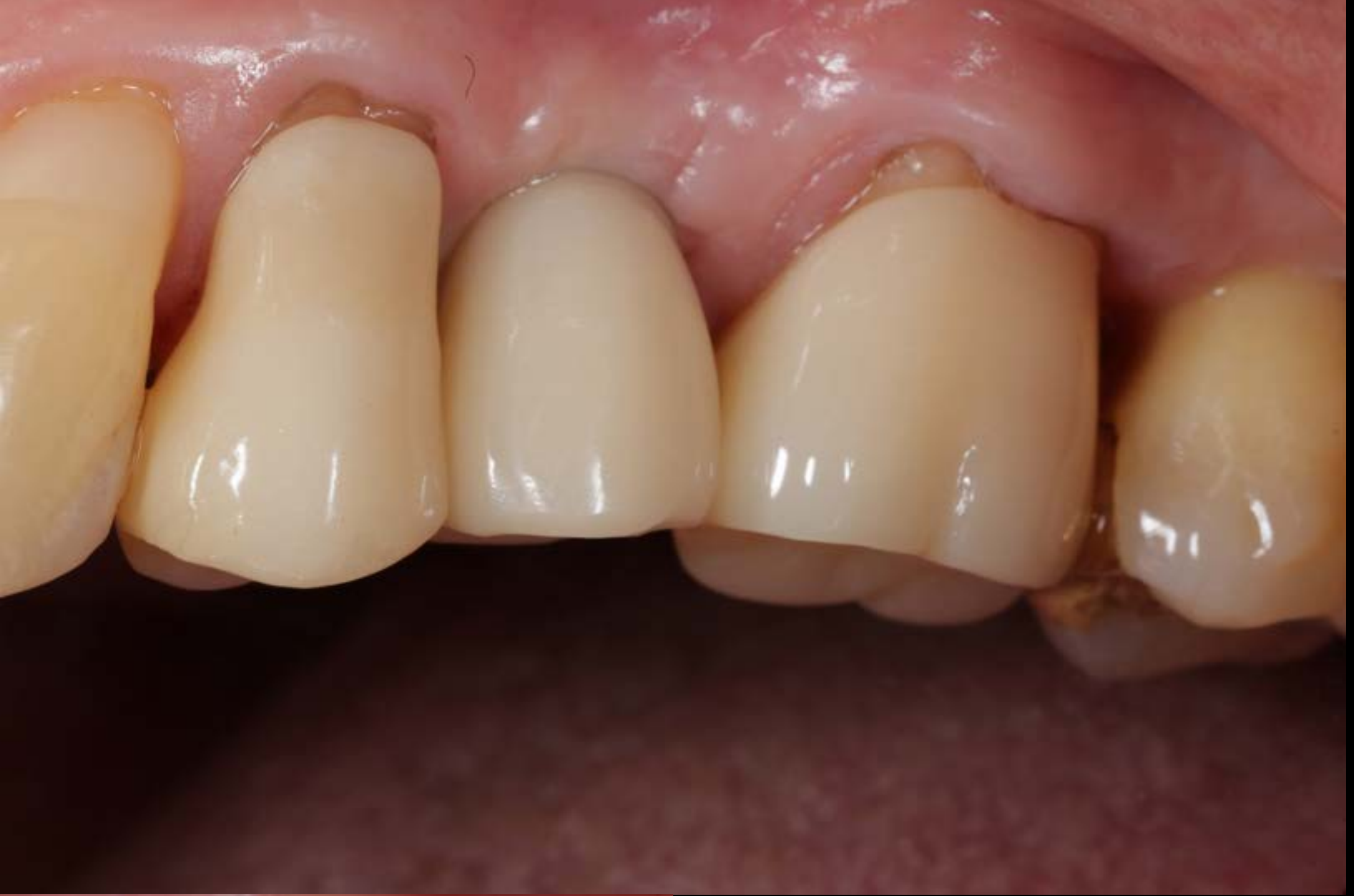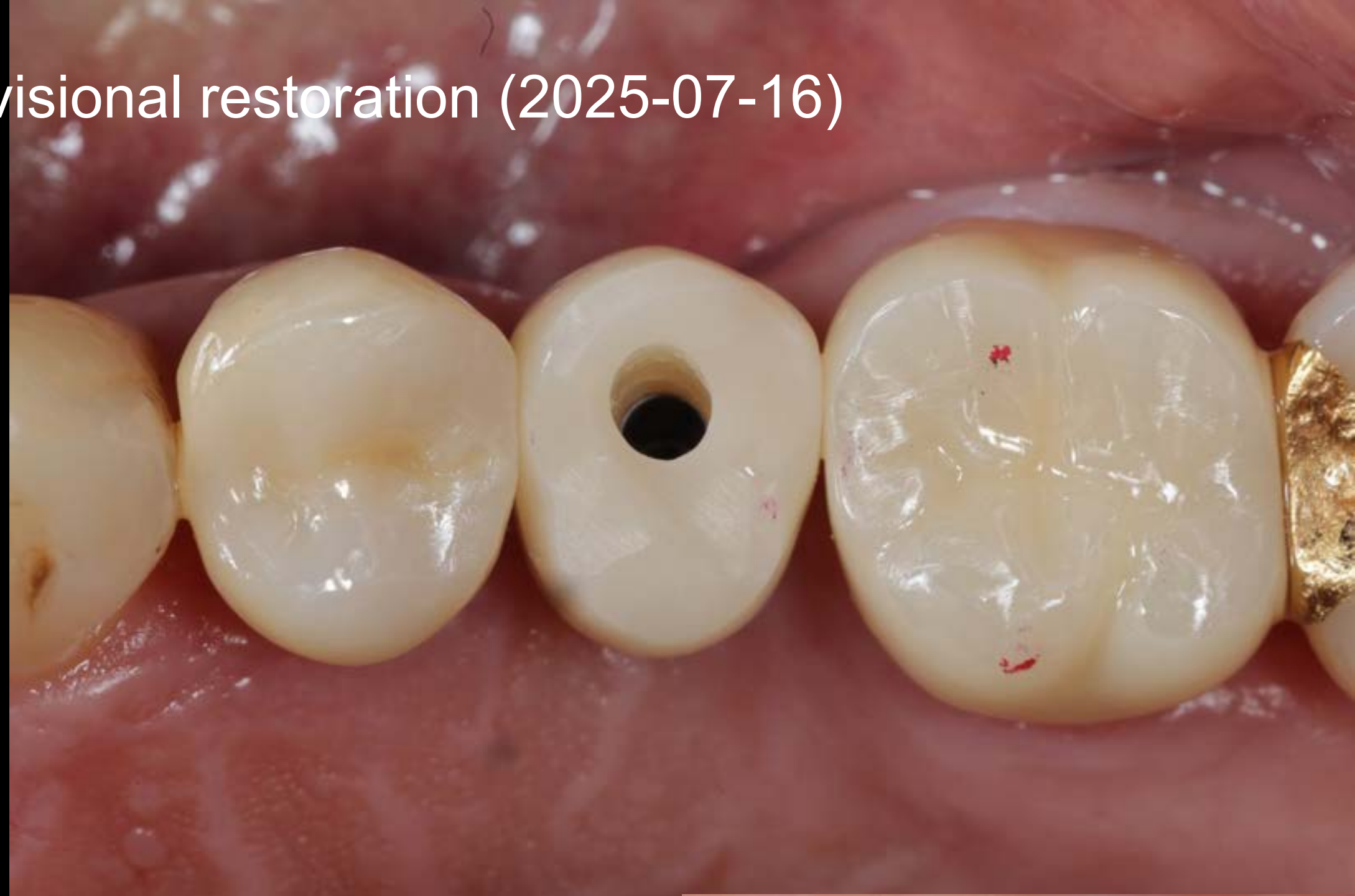Intra Oral Scan

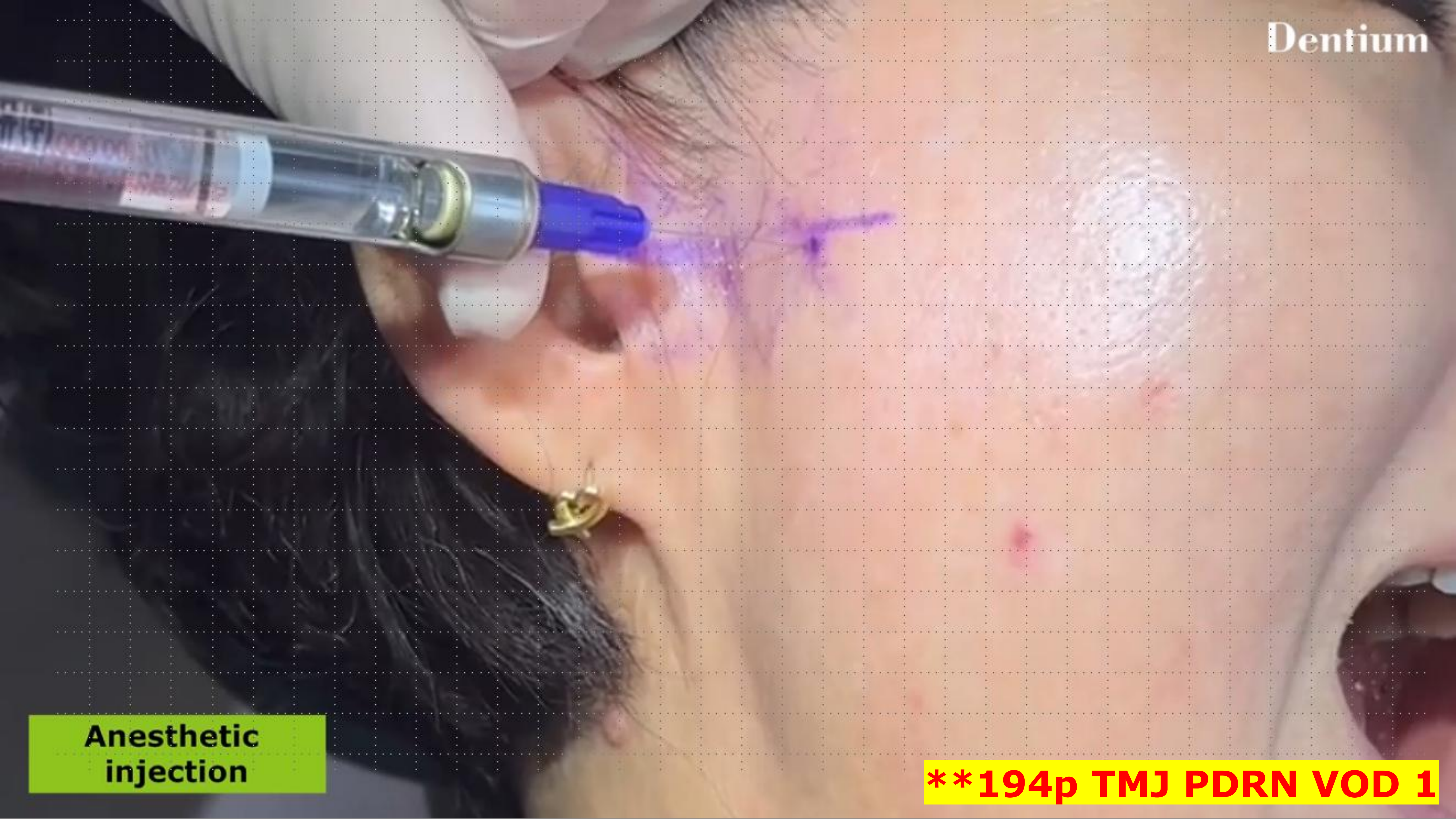

CAD (Temporary)



Provisional restoration (2025-07-16)





**Anesthetic
injection**

****194p TMJ PDRN VOD 1**

Crestal approach

bright

7mm

Short Implant

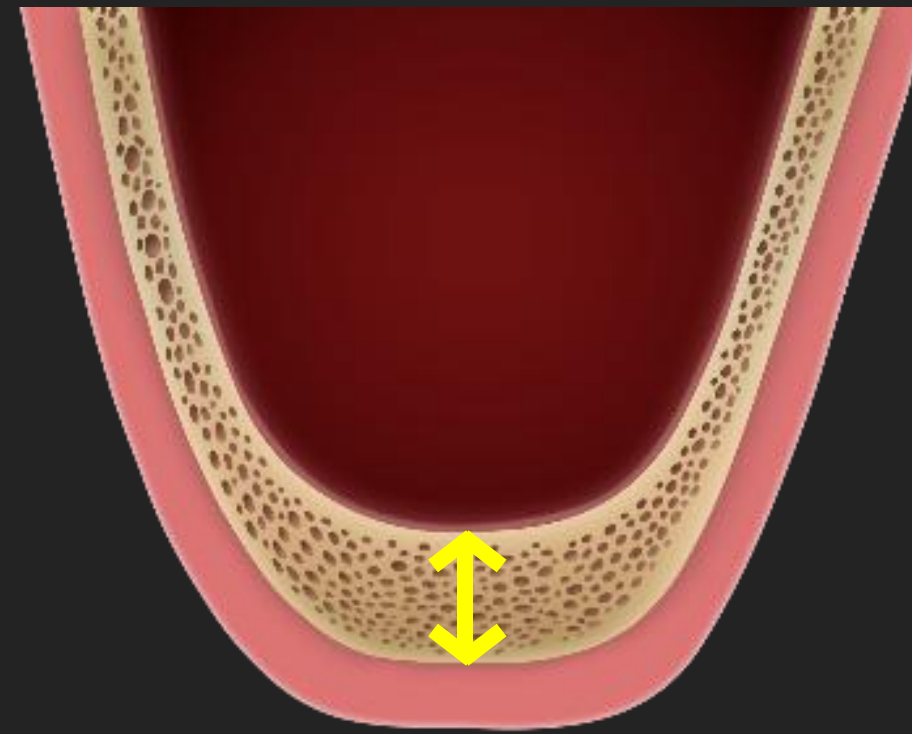


Tissue Level



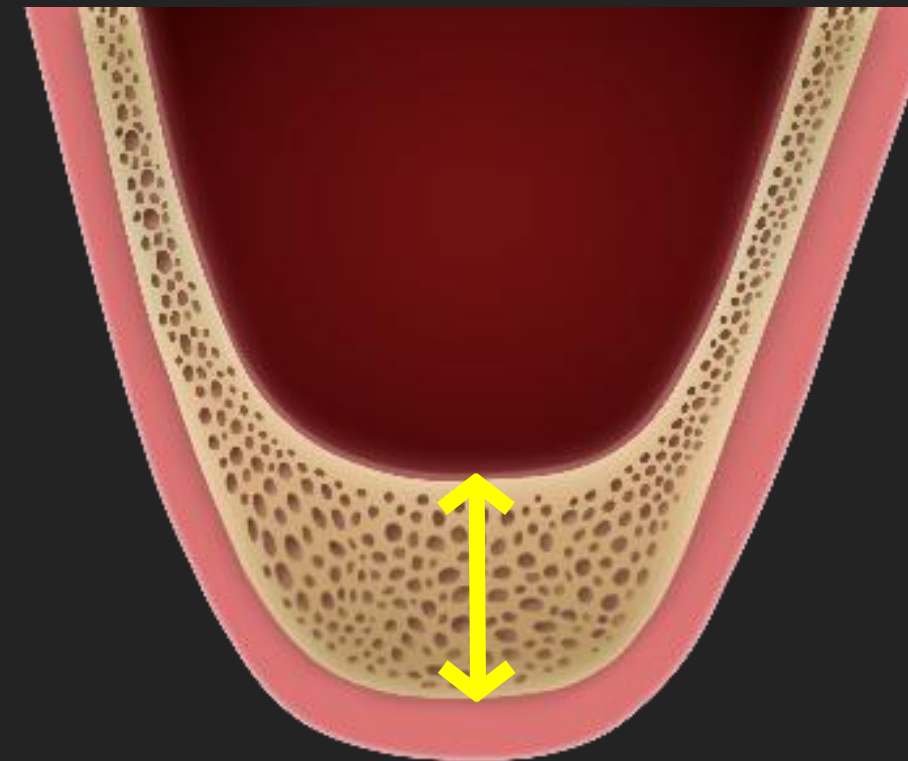
Bone Level

1 – 3 mm



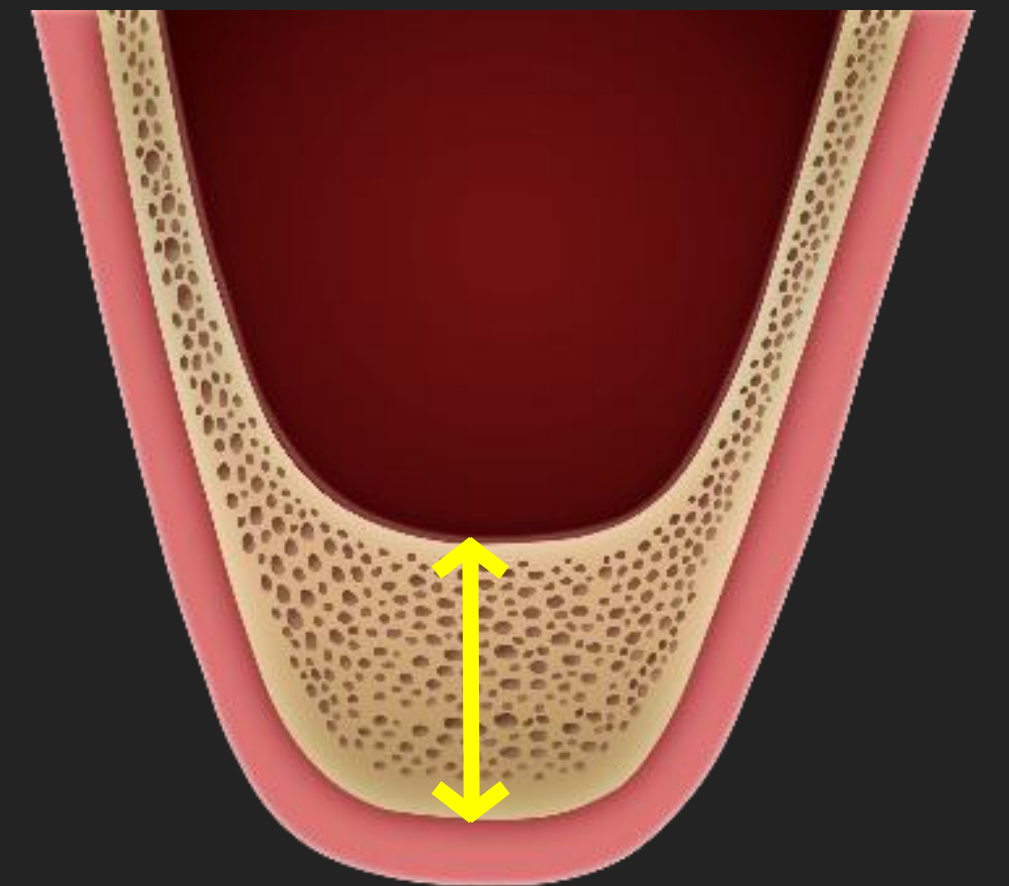
Lateral approach

3 – 5 mm



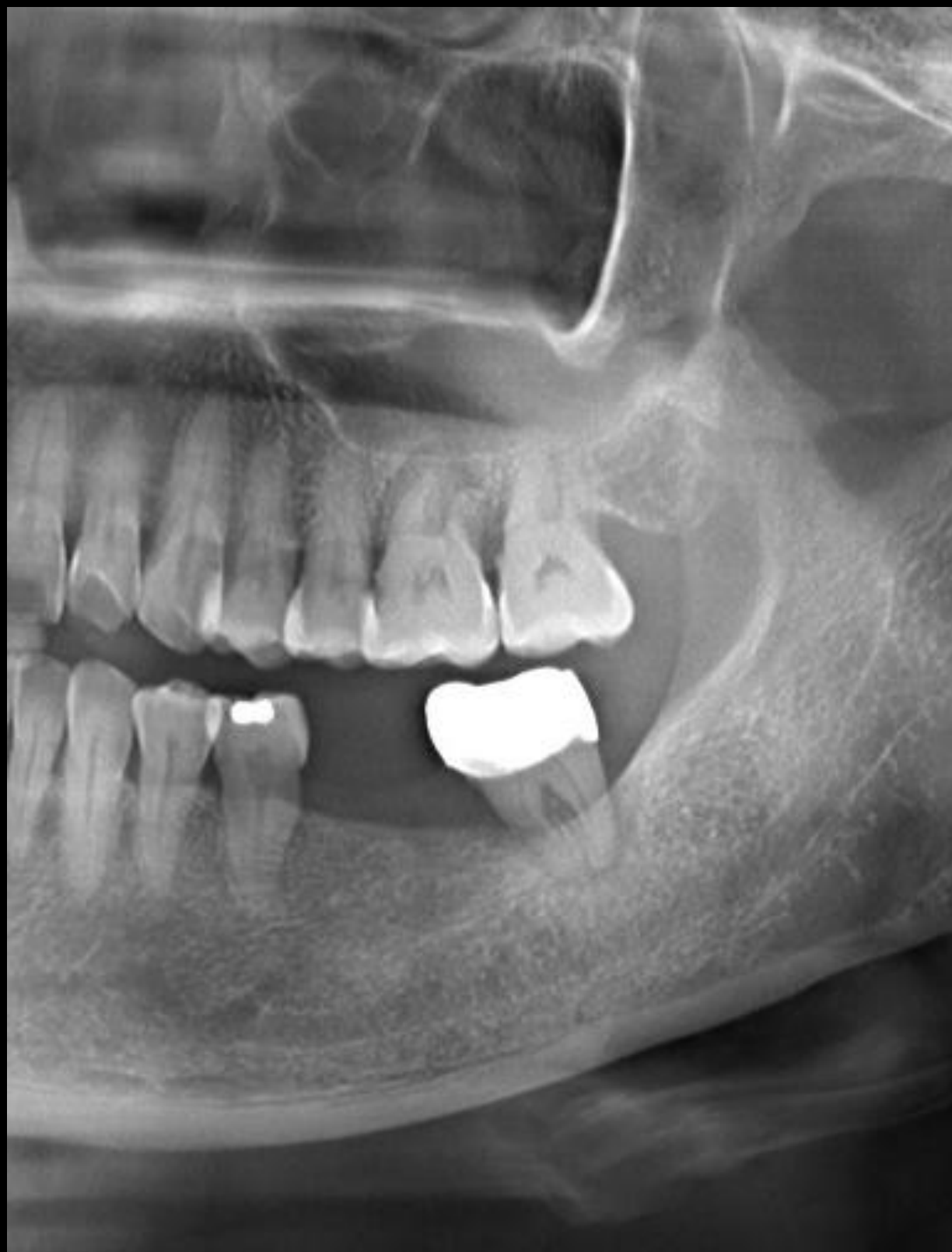Crestal approach

5 mm over

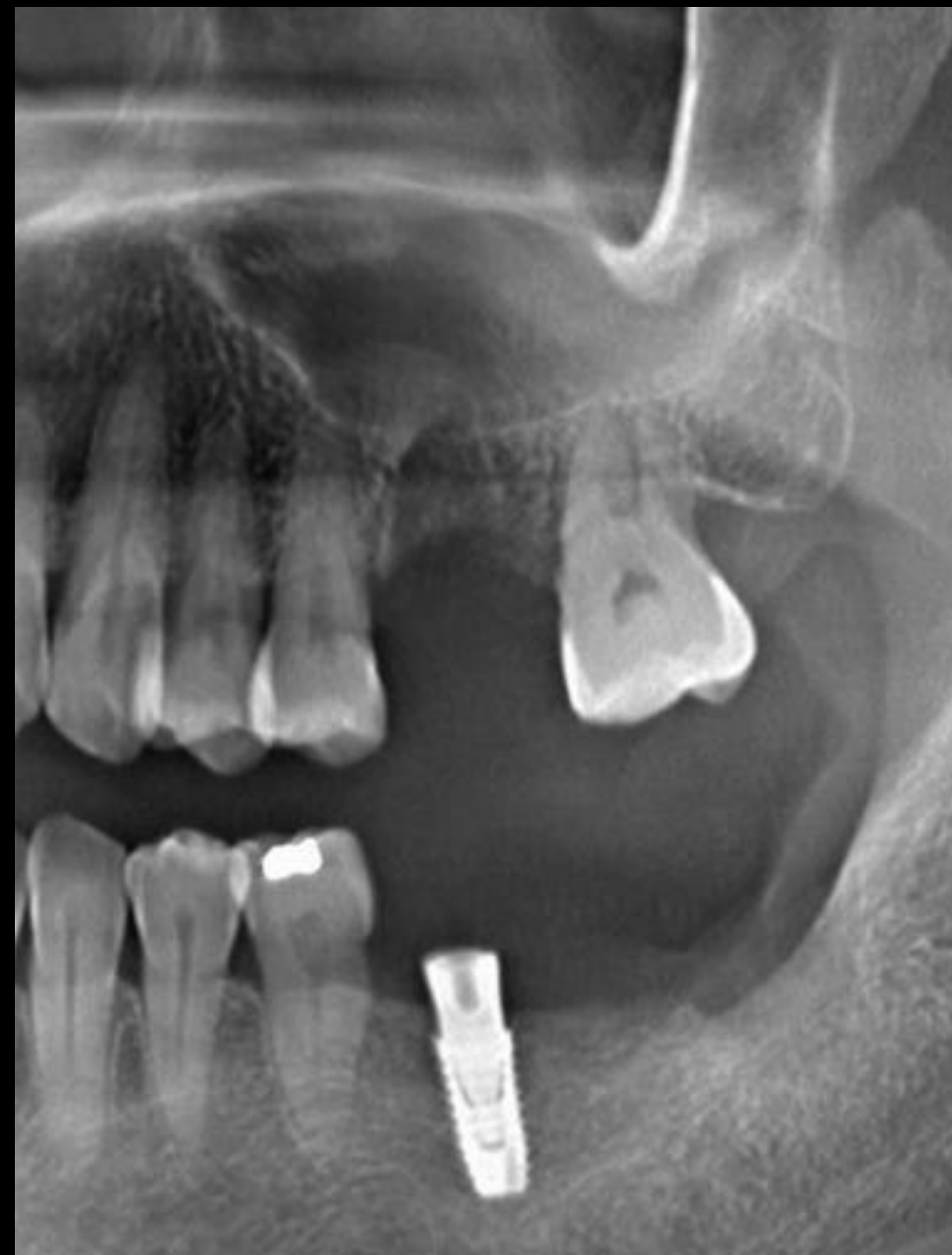

Bicortical Fixation

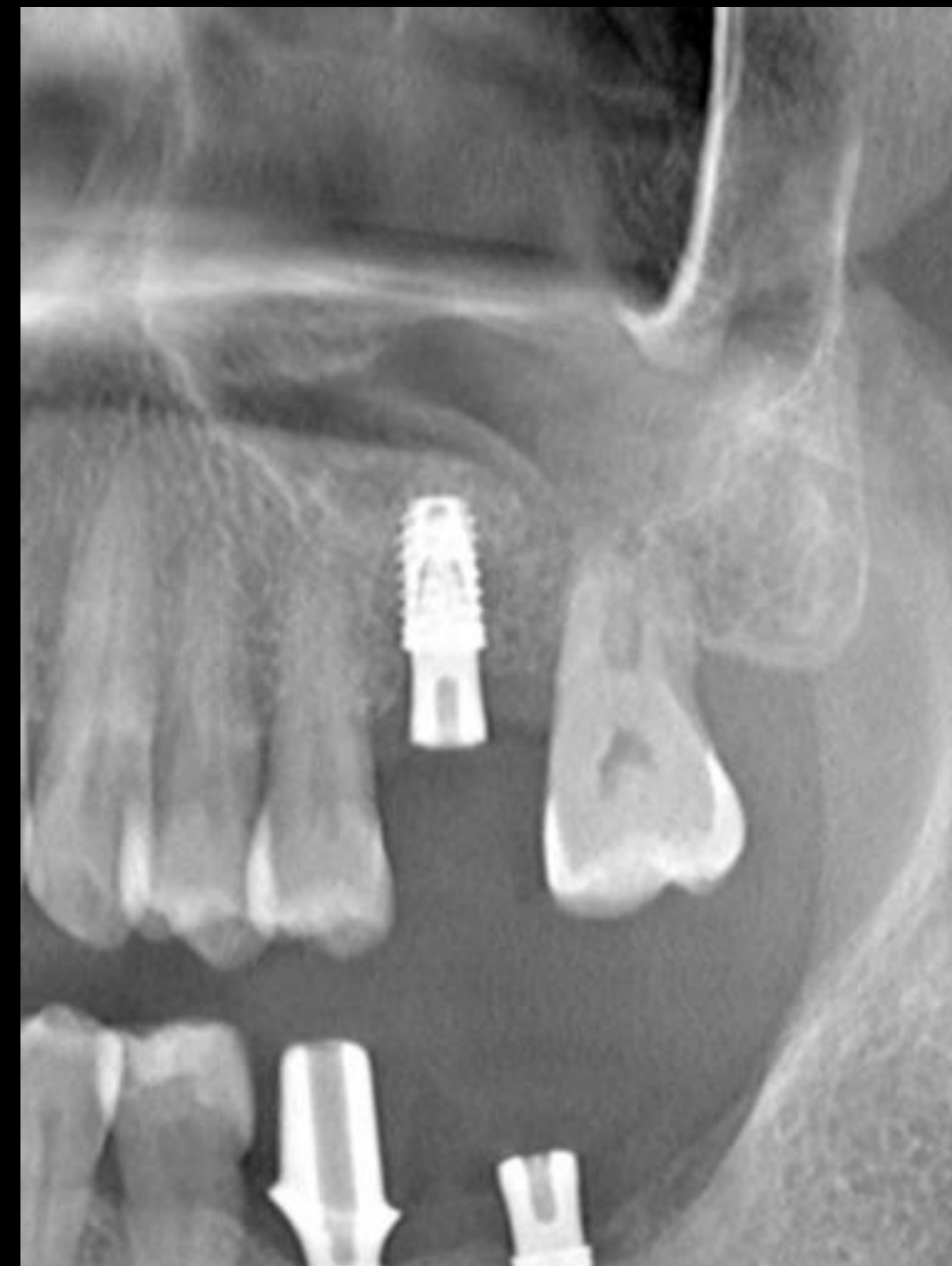Oral exam



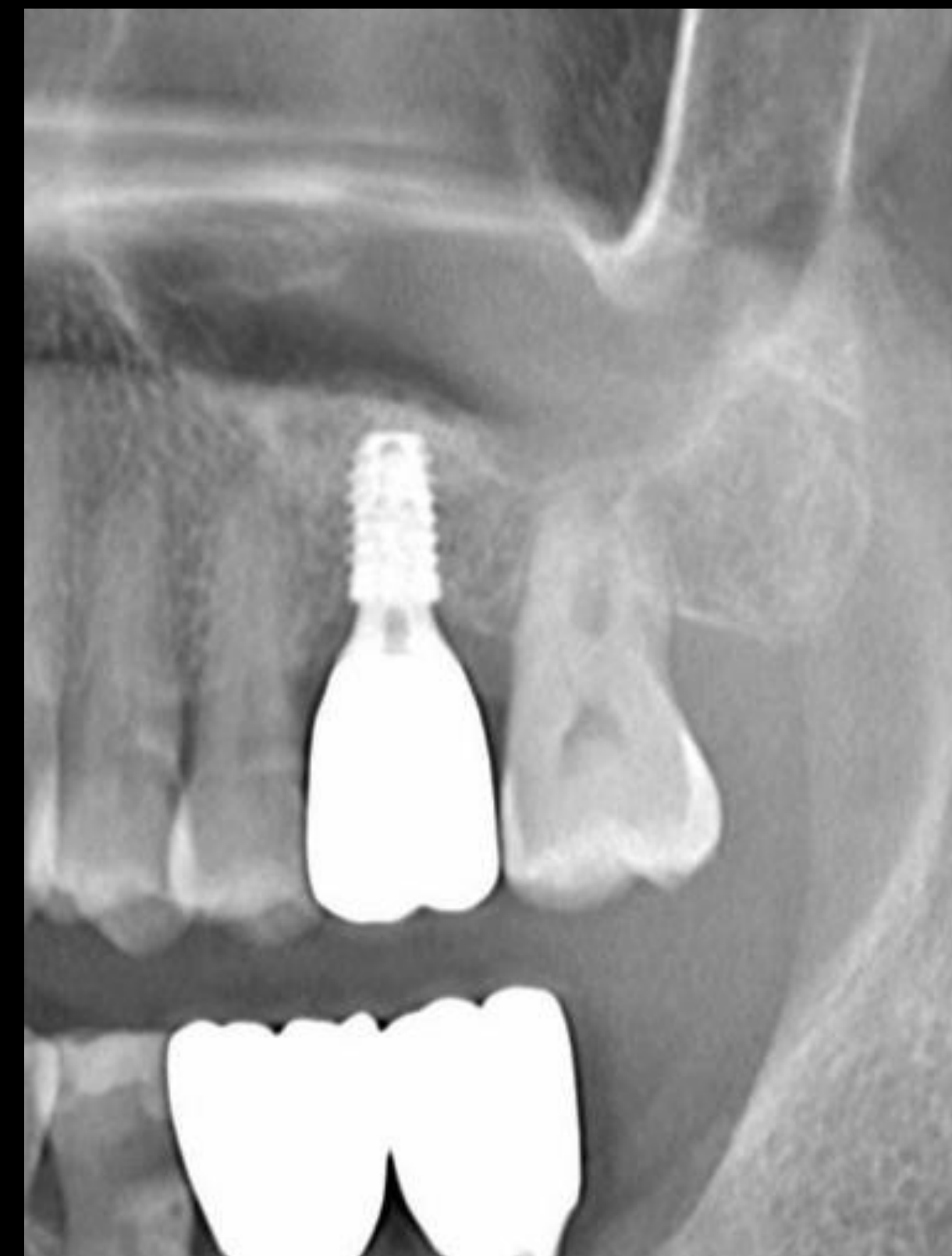
Pre-op



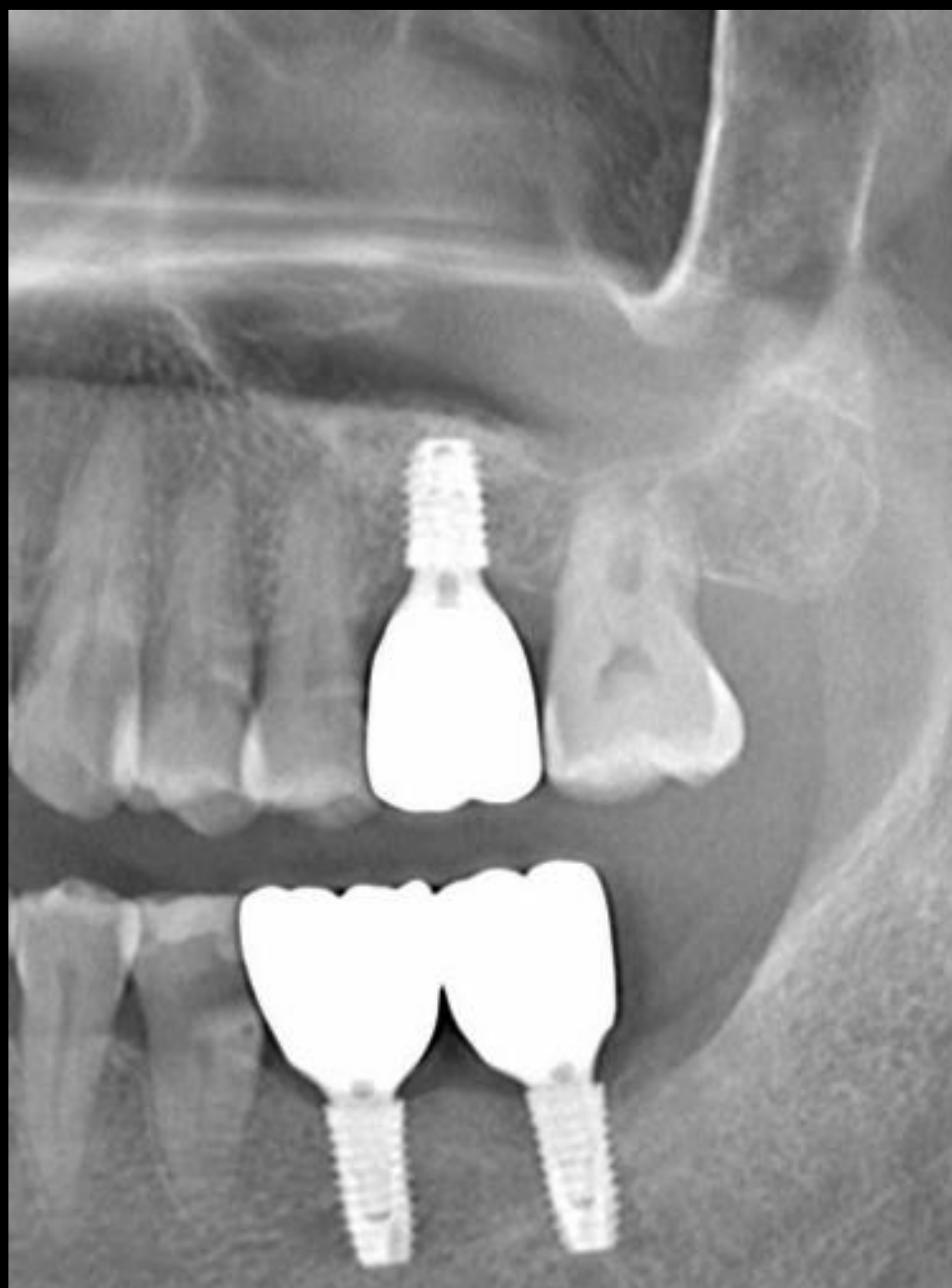
Post-op



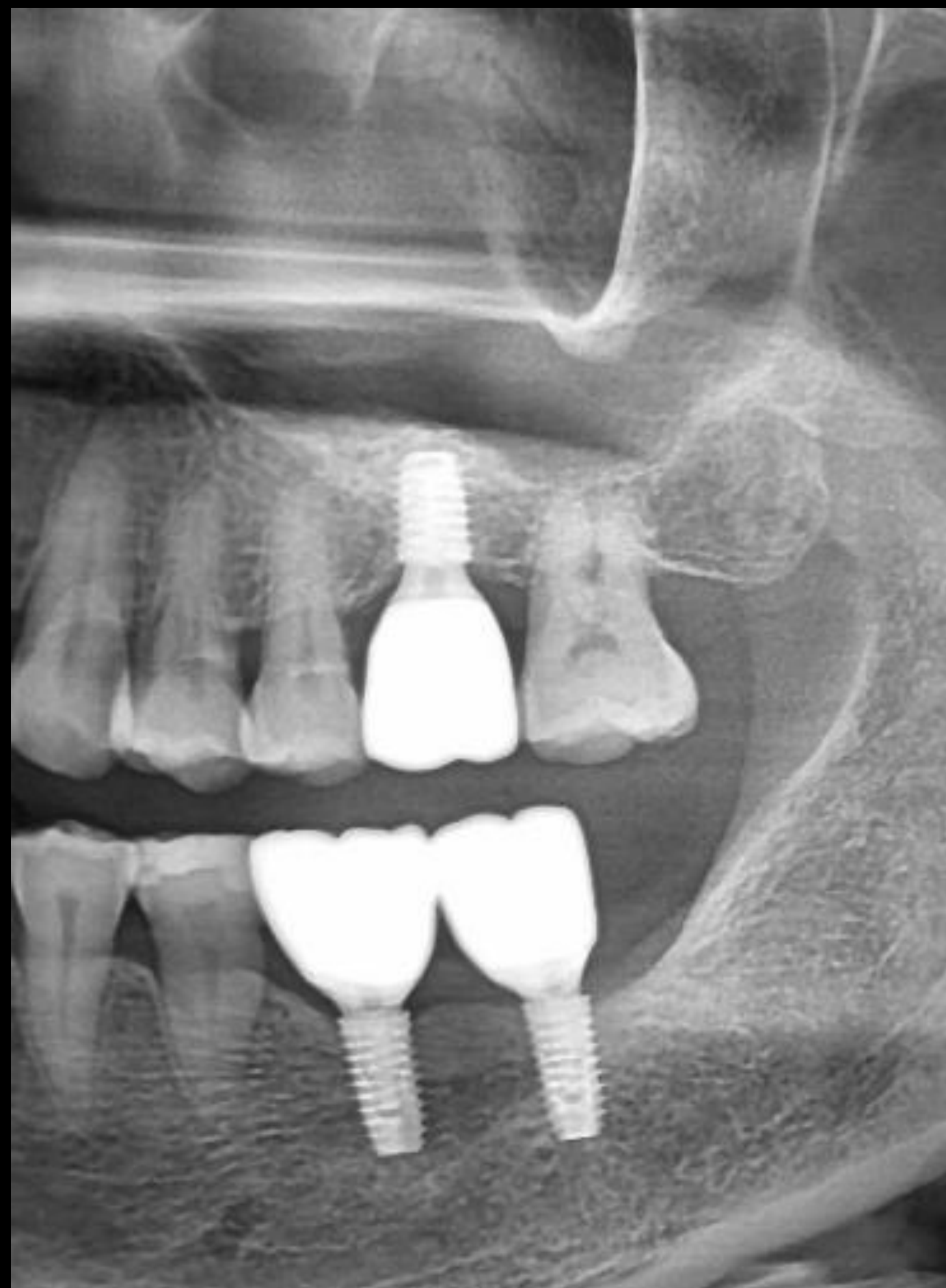Final



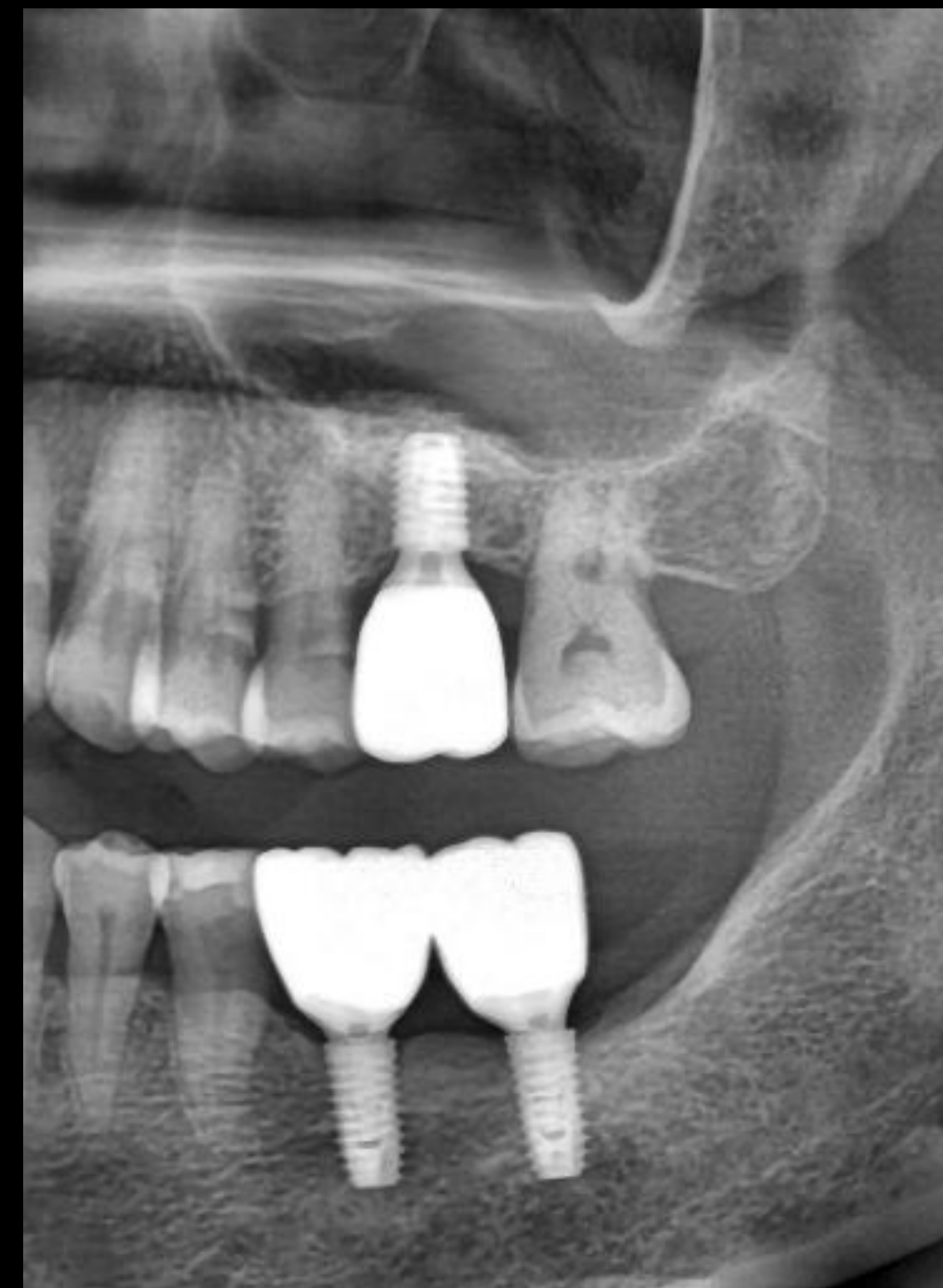4 M



1Y 4M




2Y 5M




bright BL (Ø4.5 X 7.0)

DASK *Simple*




Compaction Drill



Lateral Drill



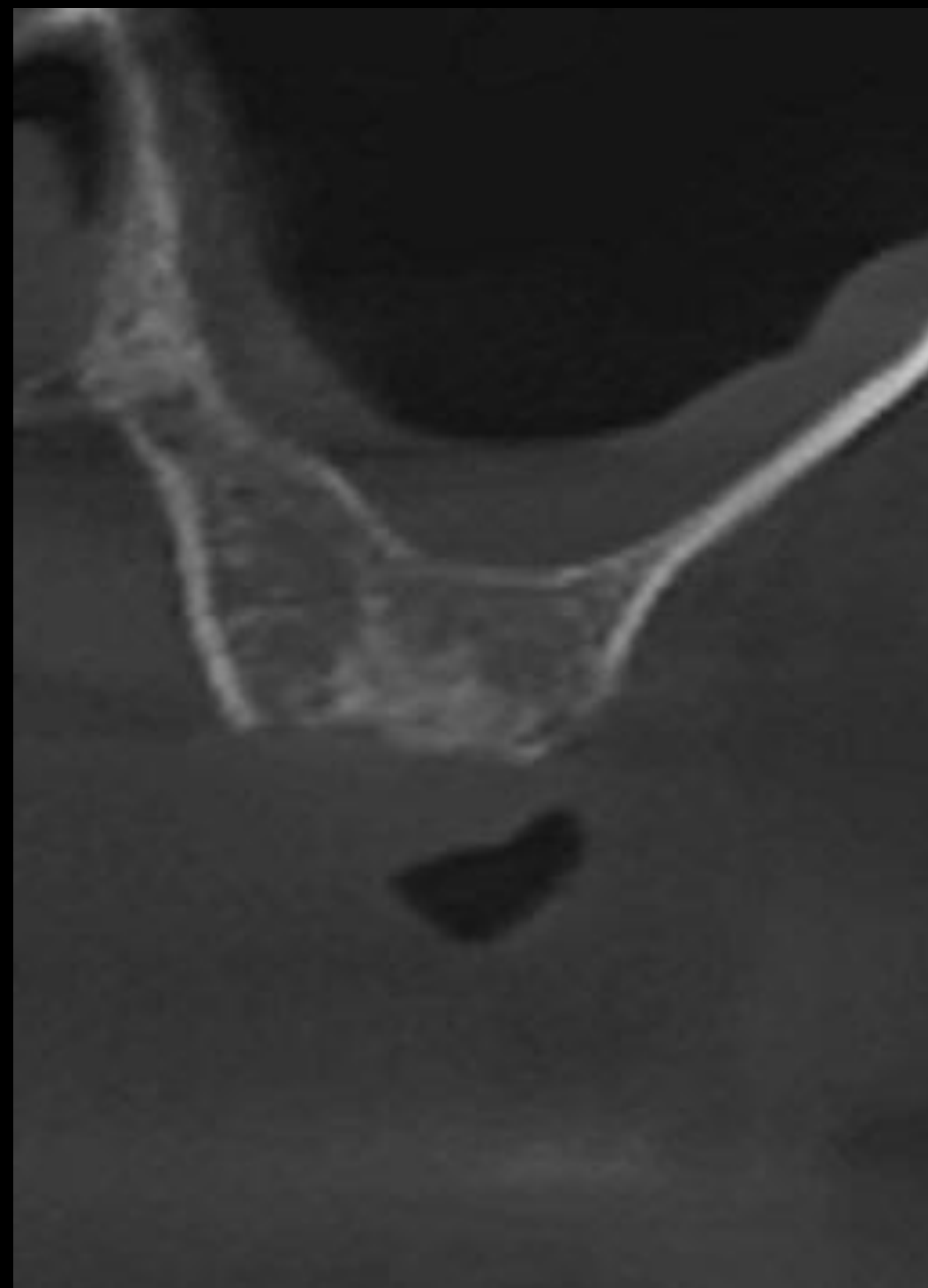
Bone Spreader



Hand Instruments

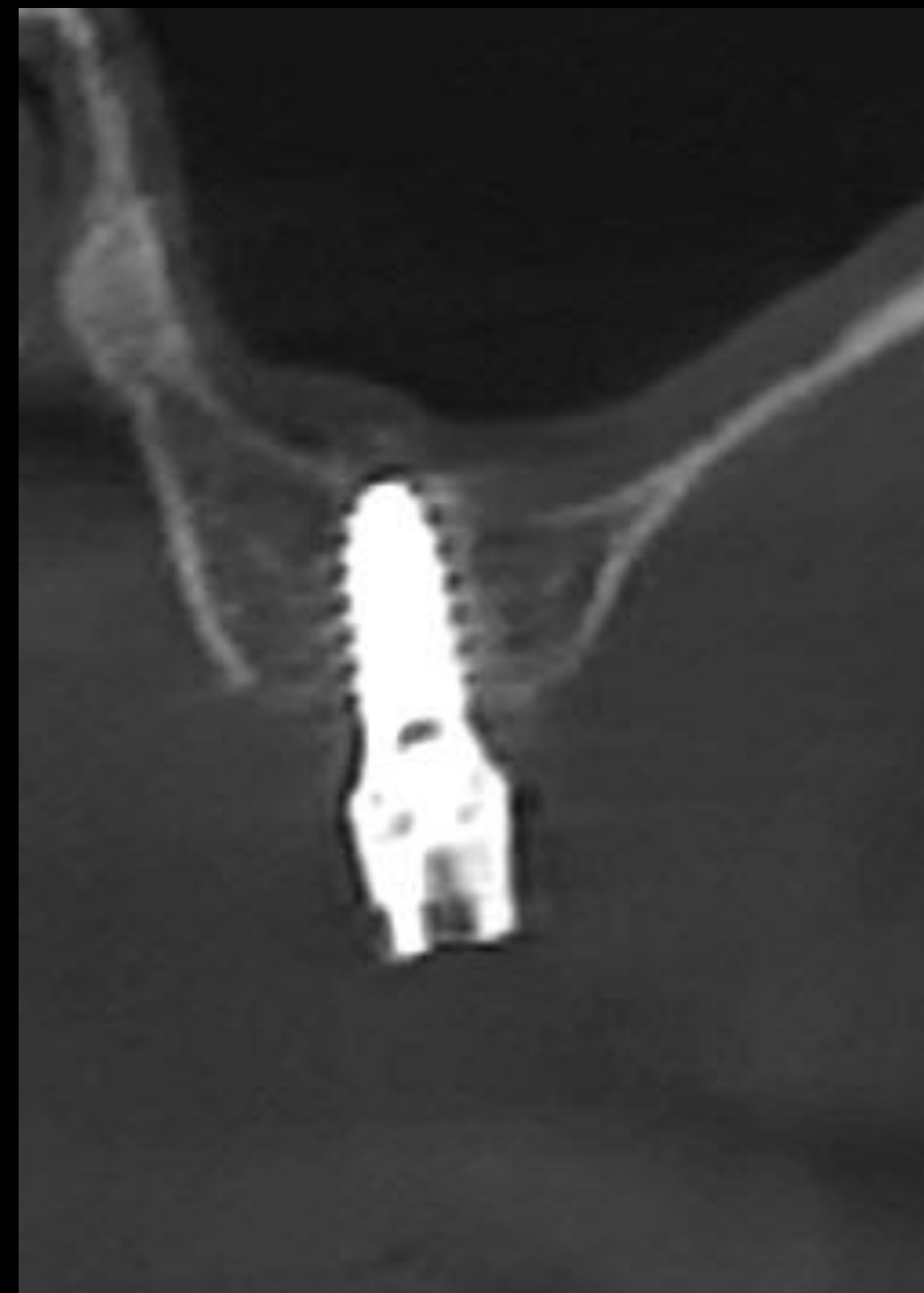DASK Simple is designed to facilitate safe, efficient and minimally invasive **Sinus Lift** procedures

Pre-op CT (2024-10-31)

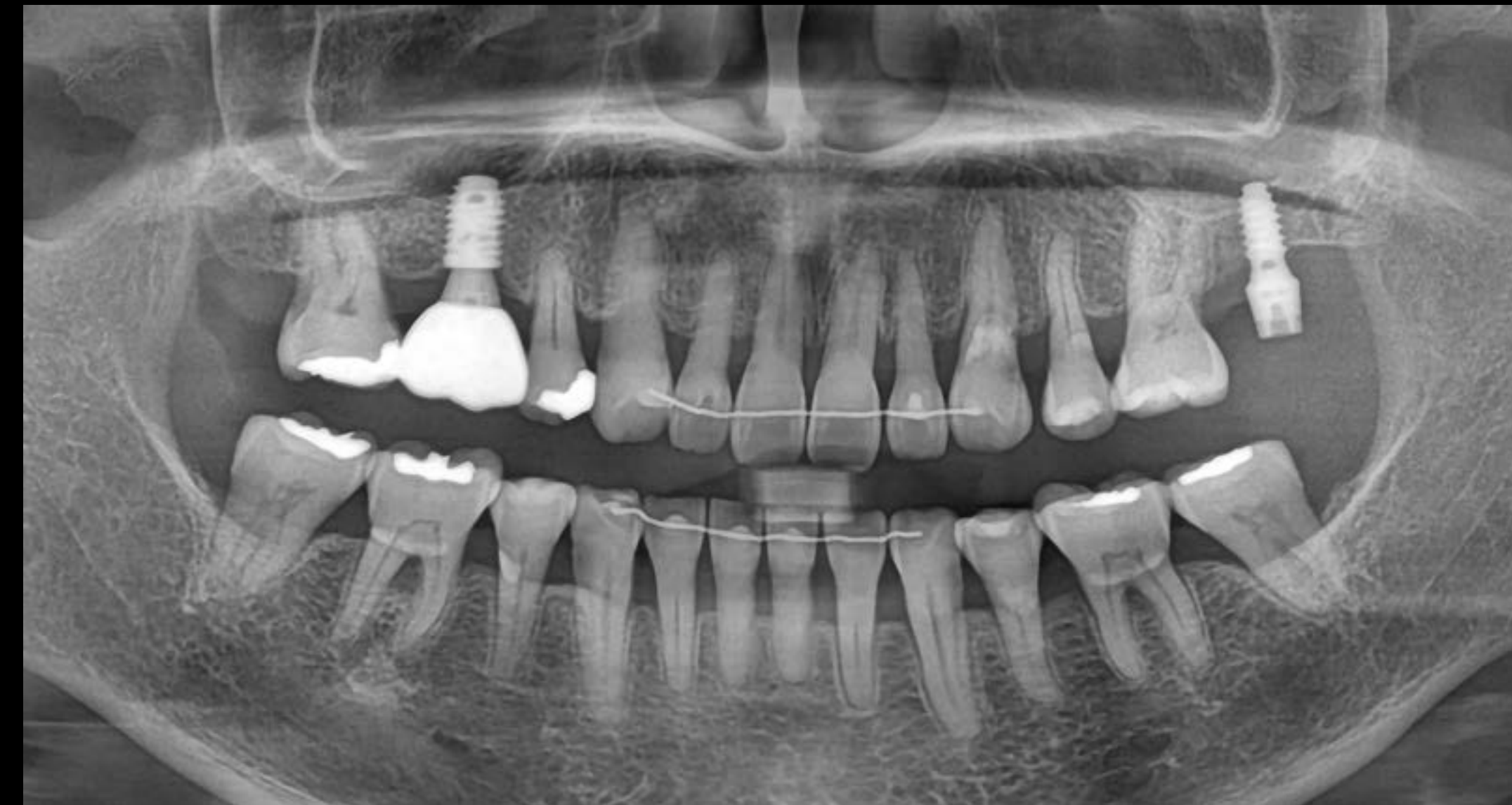


#27

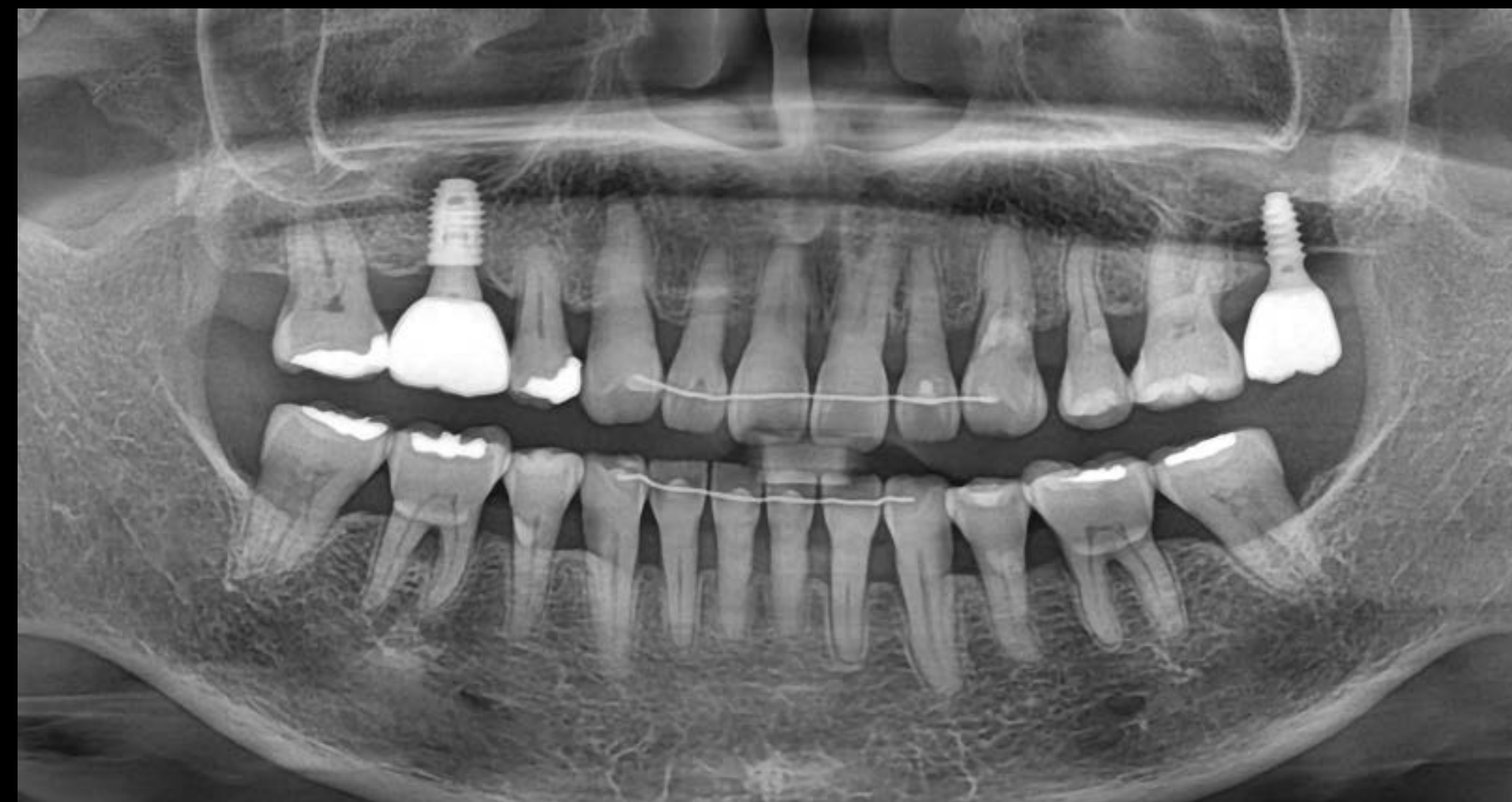
Post-op CT (2024-10-31)



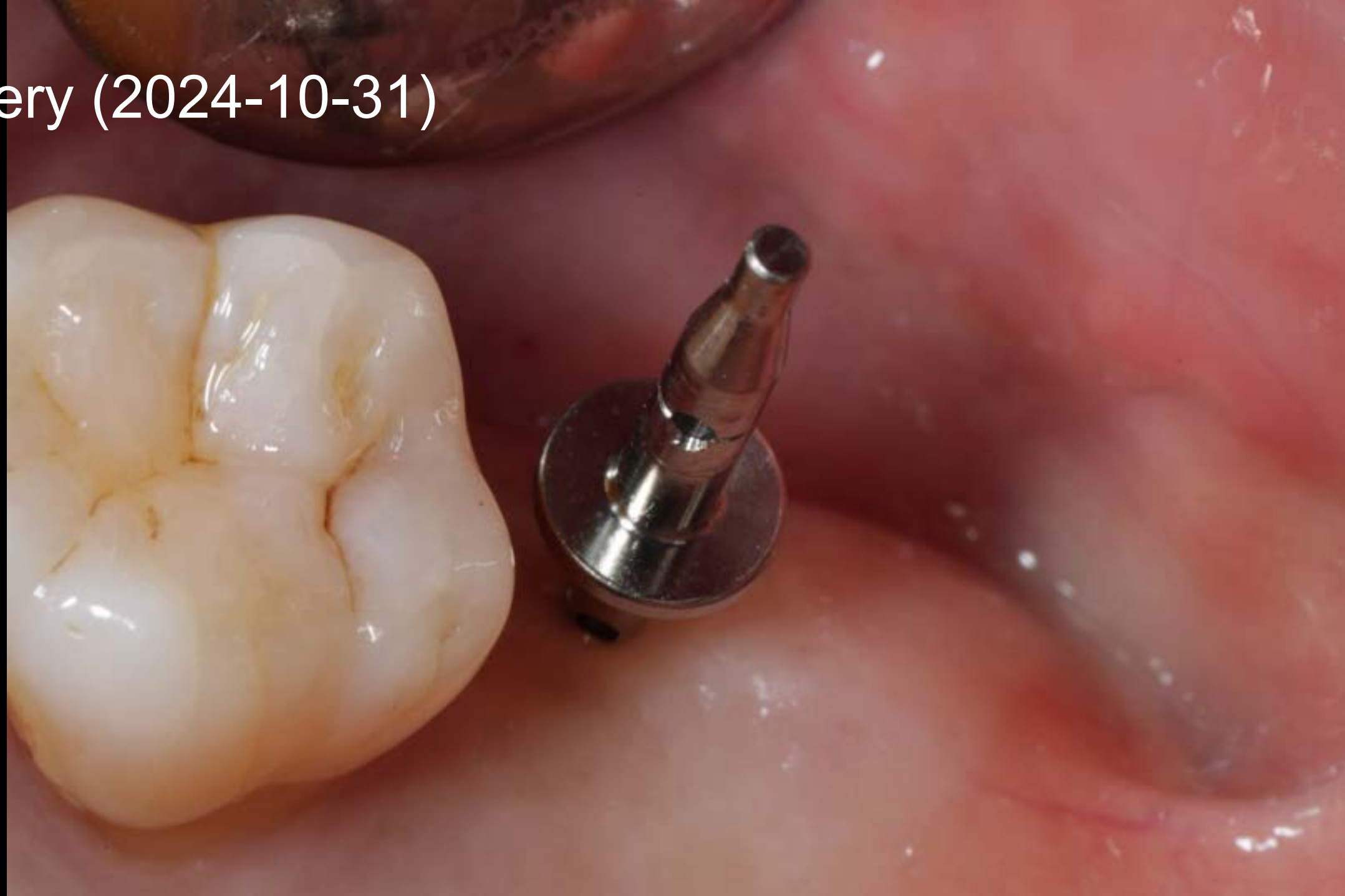#27



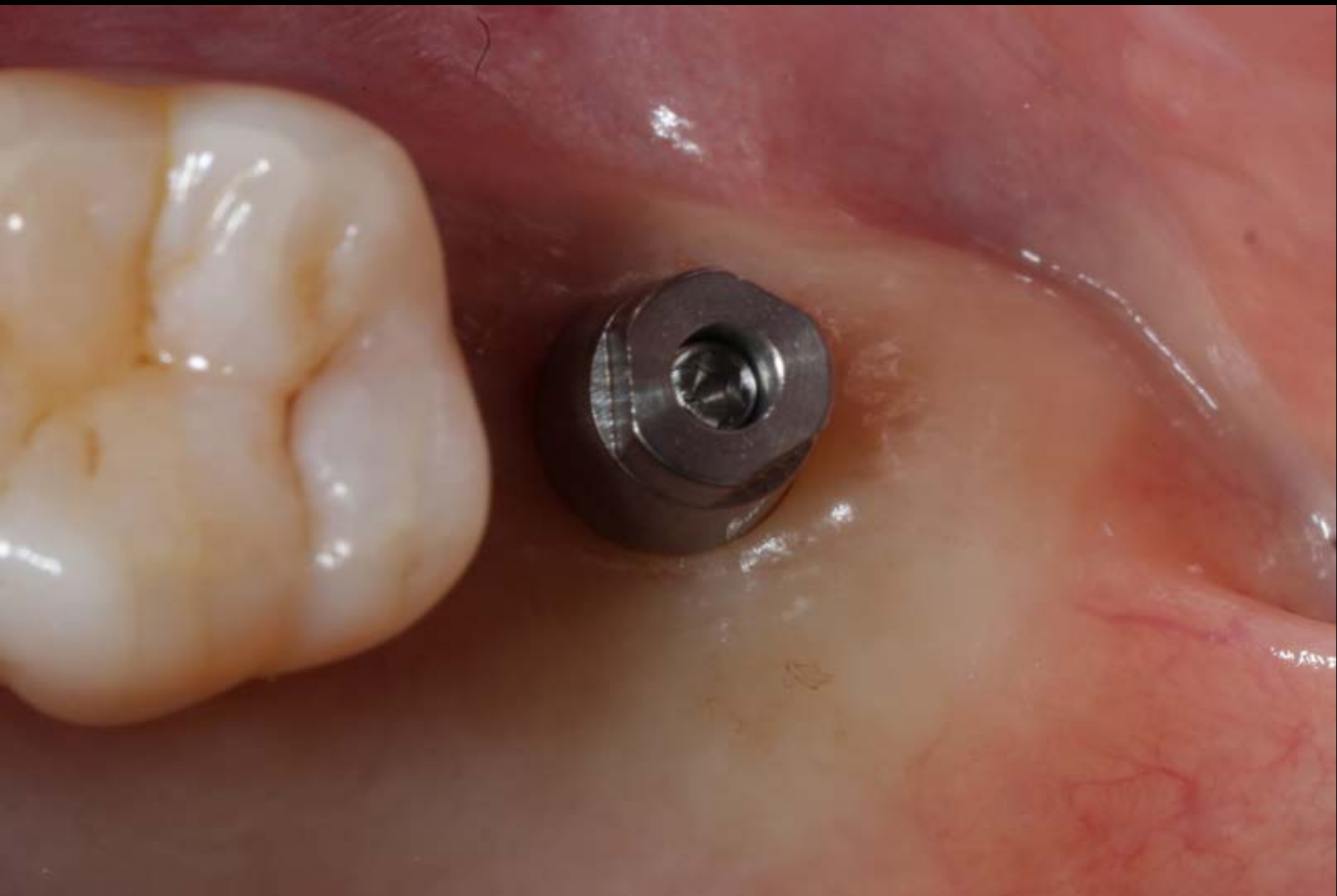
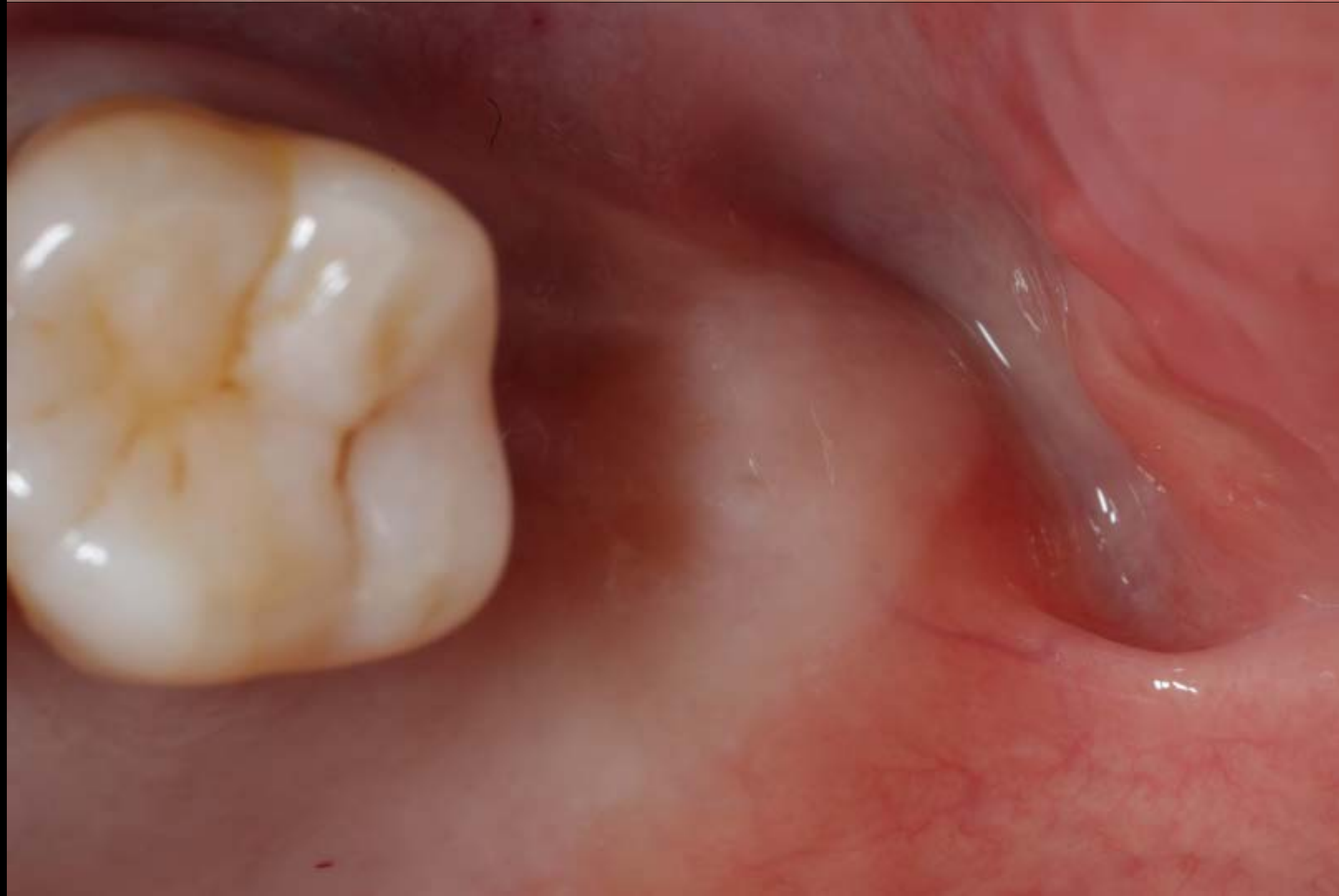3weeks later final prosthesis

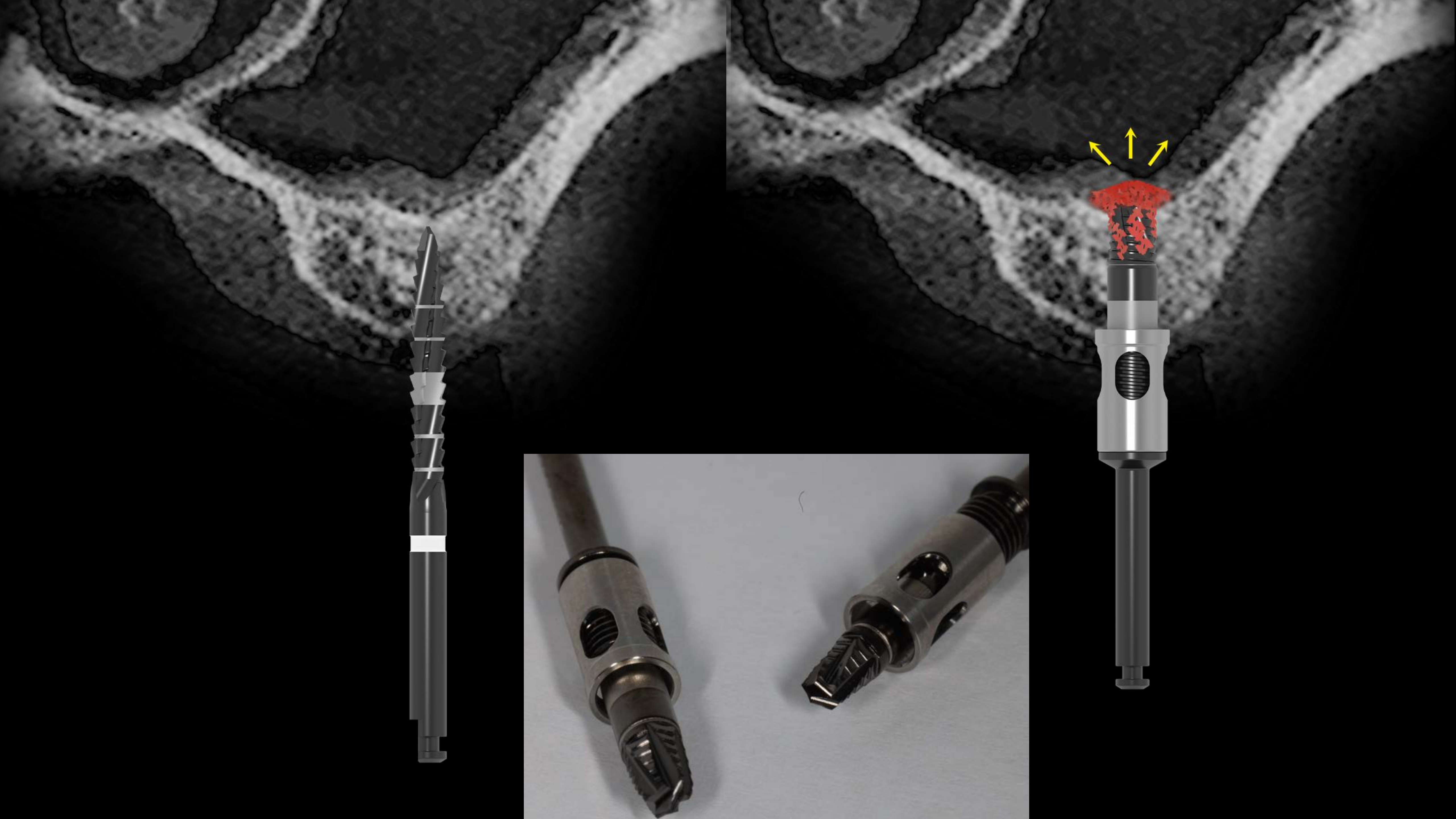


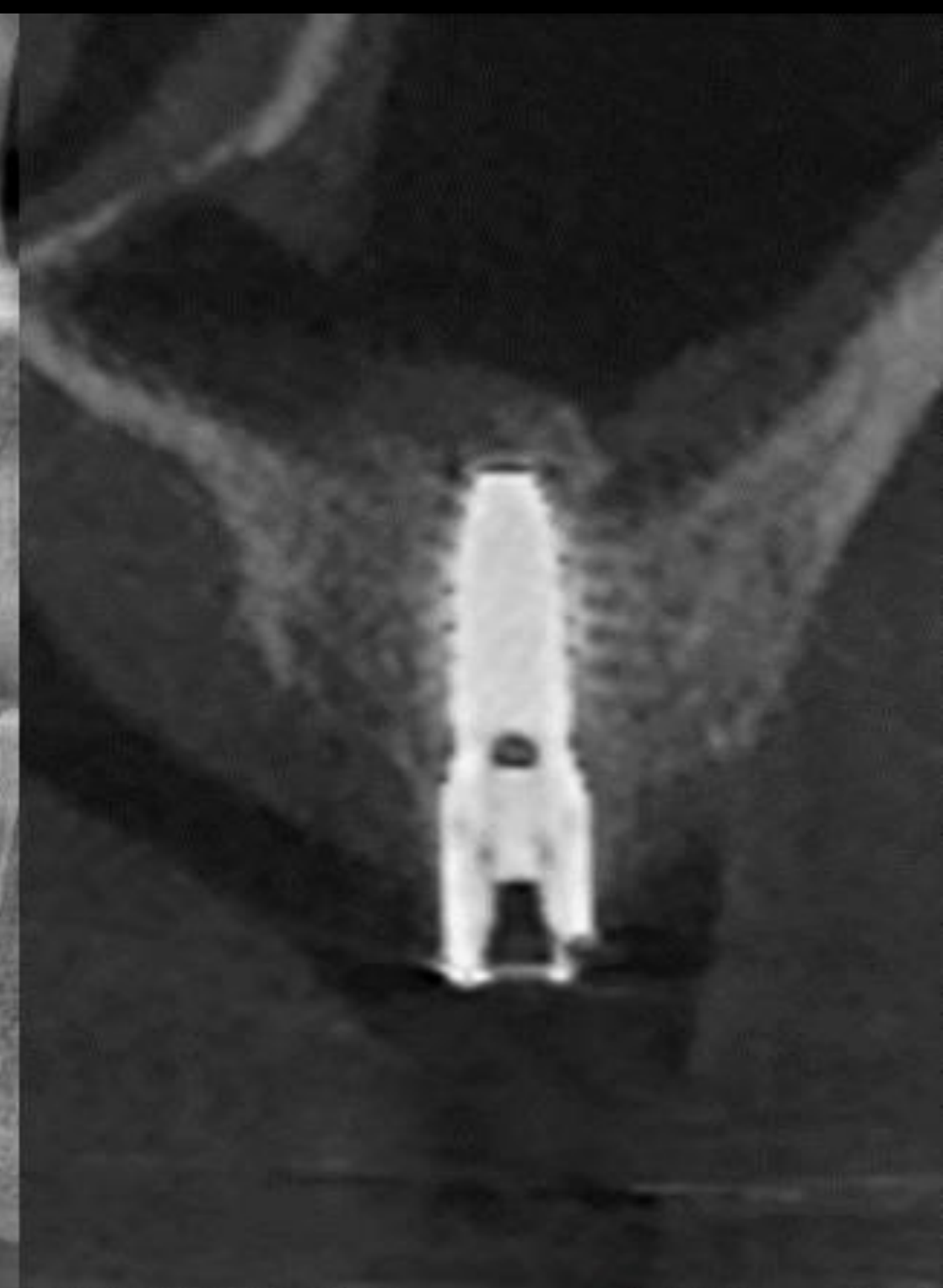
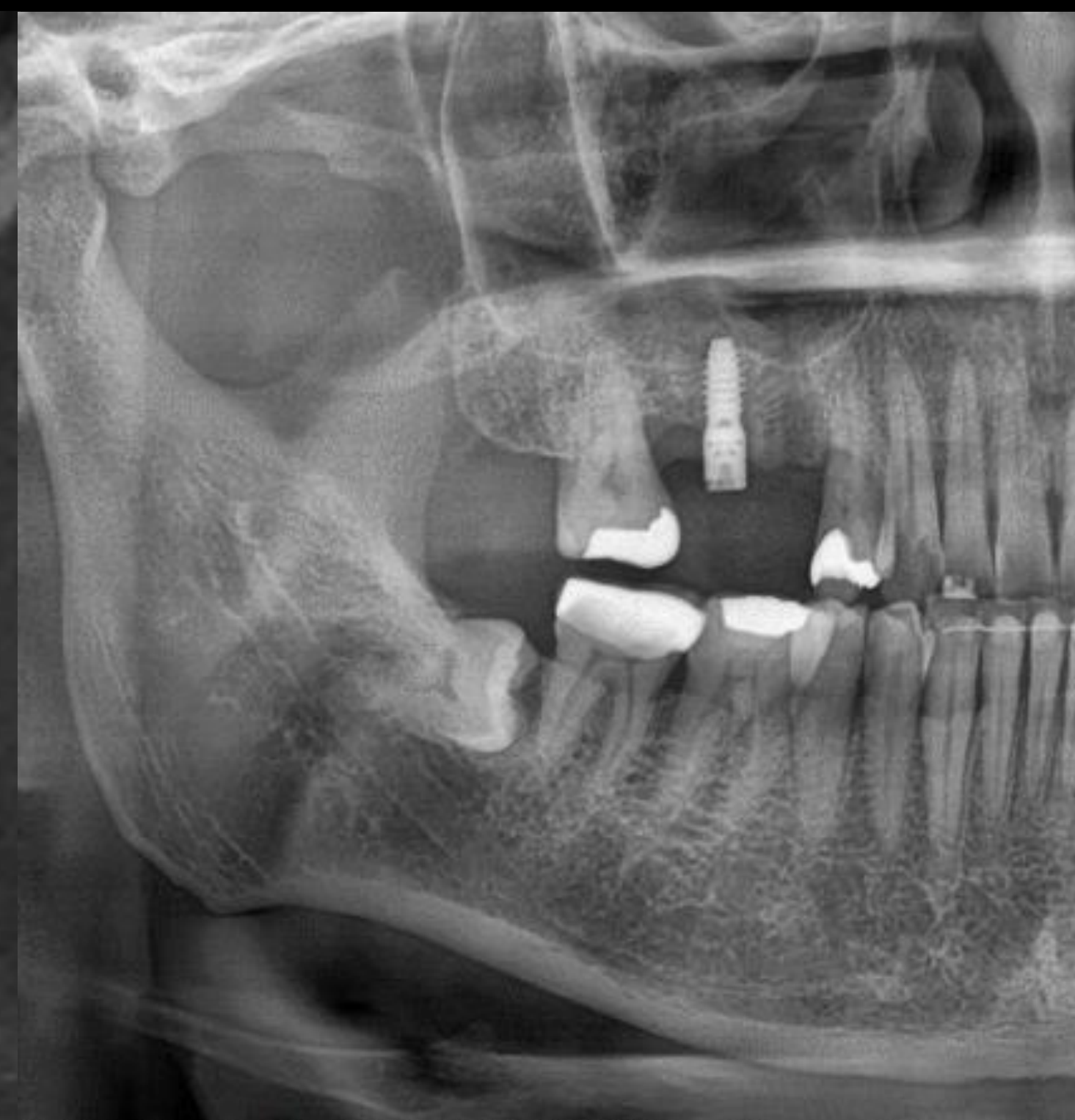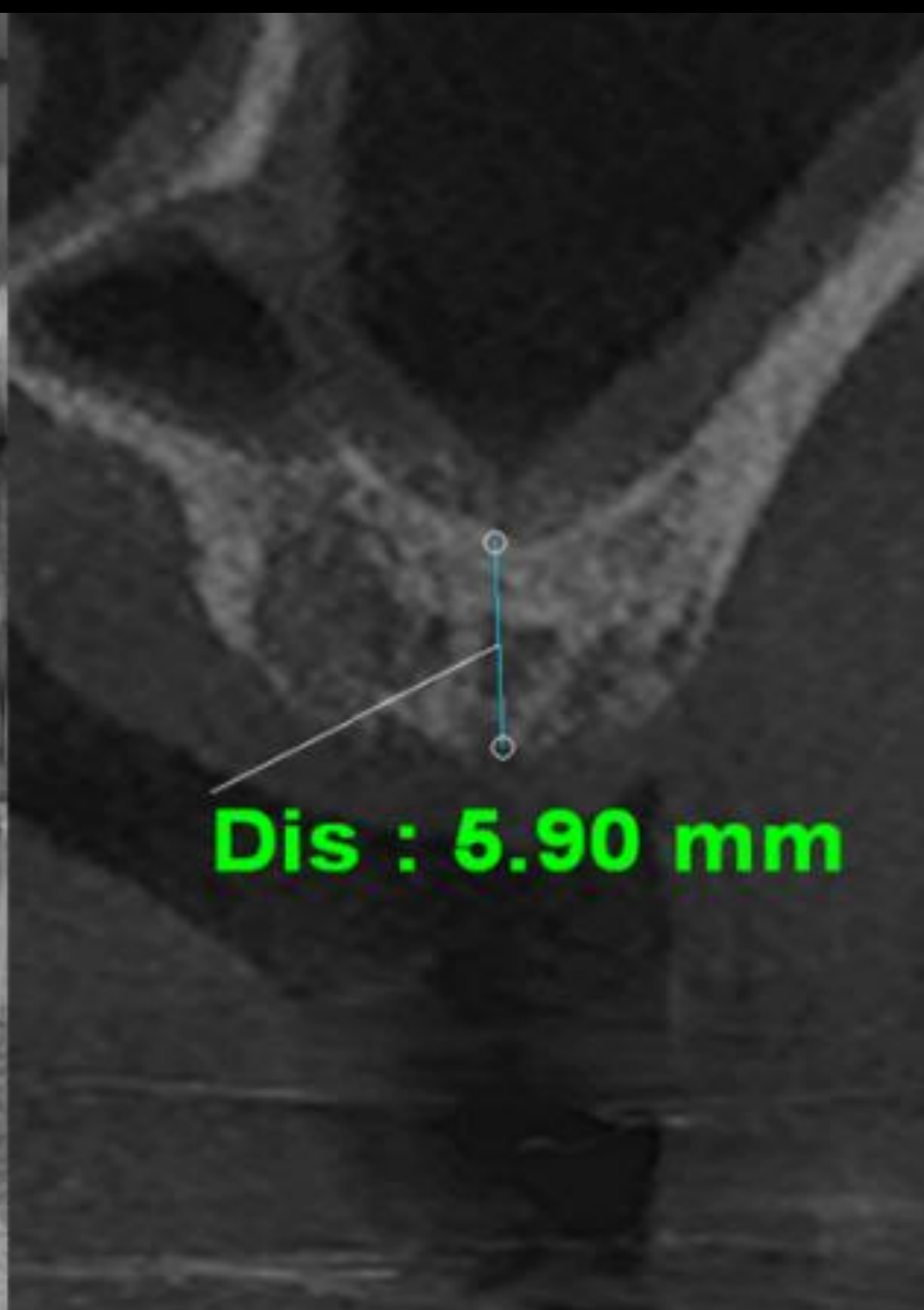
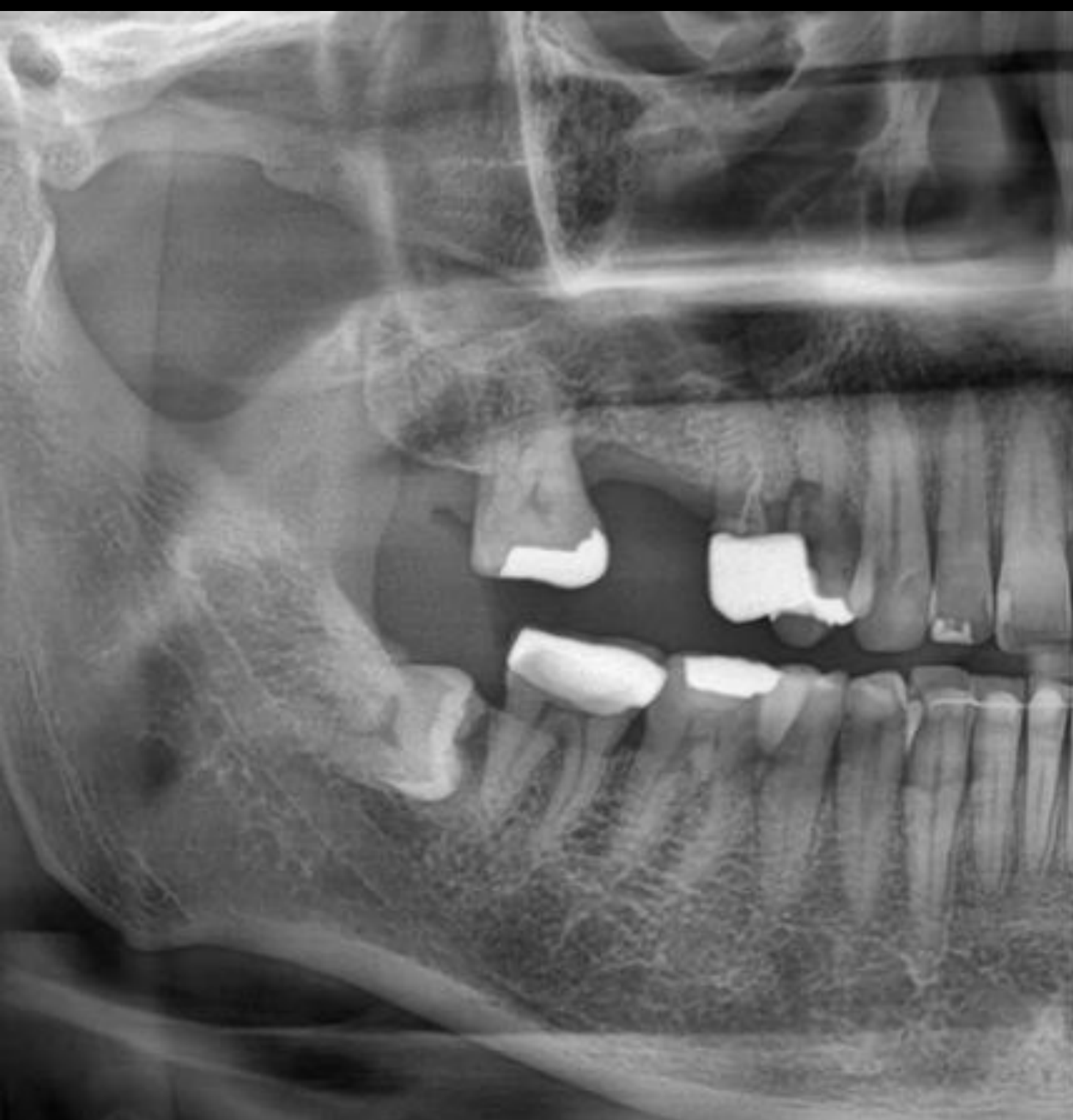Surgery (2024-10-31)



bright premier TL (Ø4.0 X 7.0)










Auto bone chip lifting



Crestal drill Ø 3.0

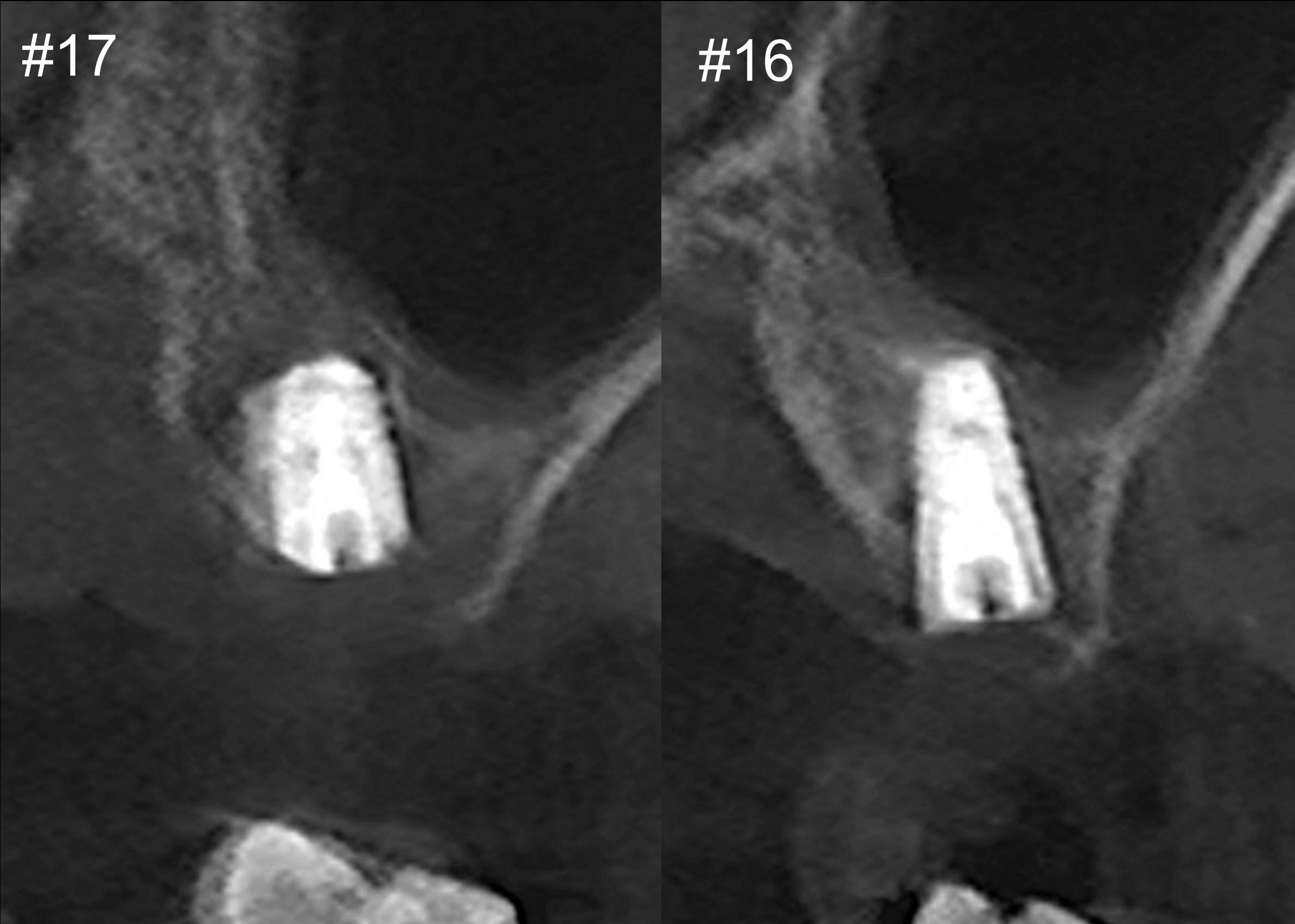
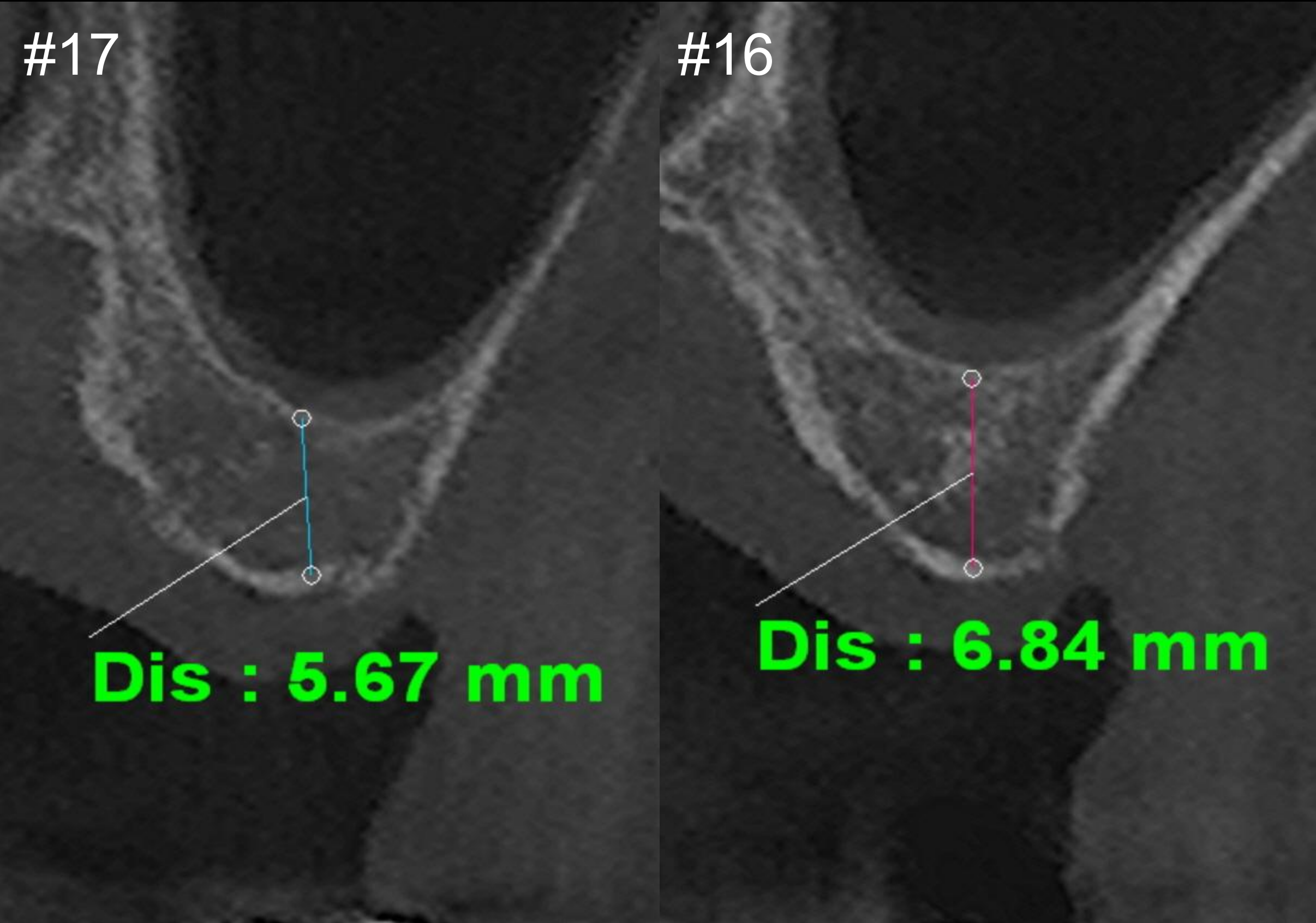
50 rpm / 70 Ncm² without irrigation



**** 203p DASK Simple Hands-on VOD**

Pre-op (2022-03-20)

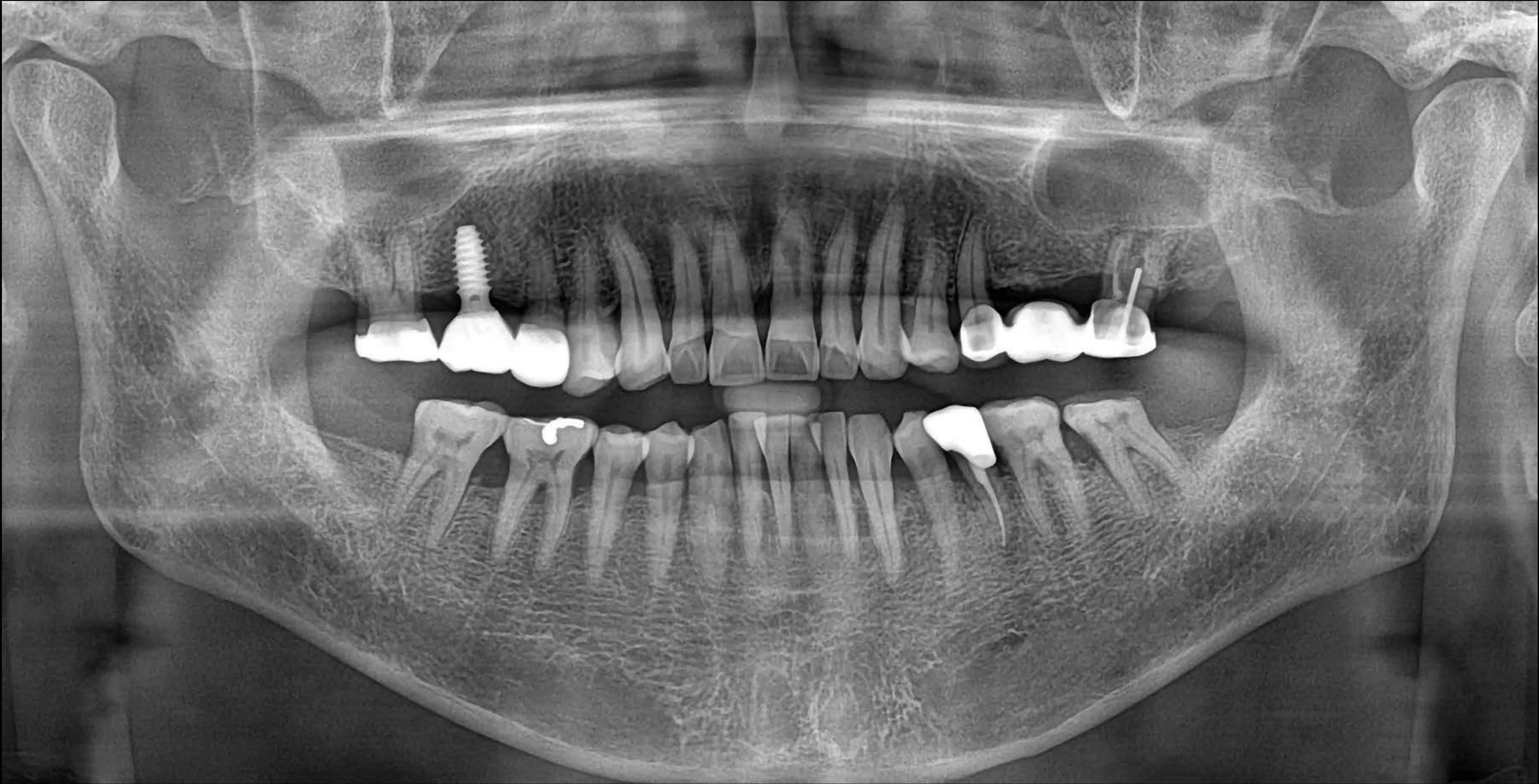Post-op (2022-03-20)

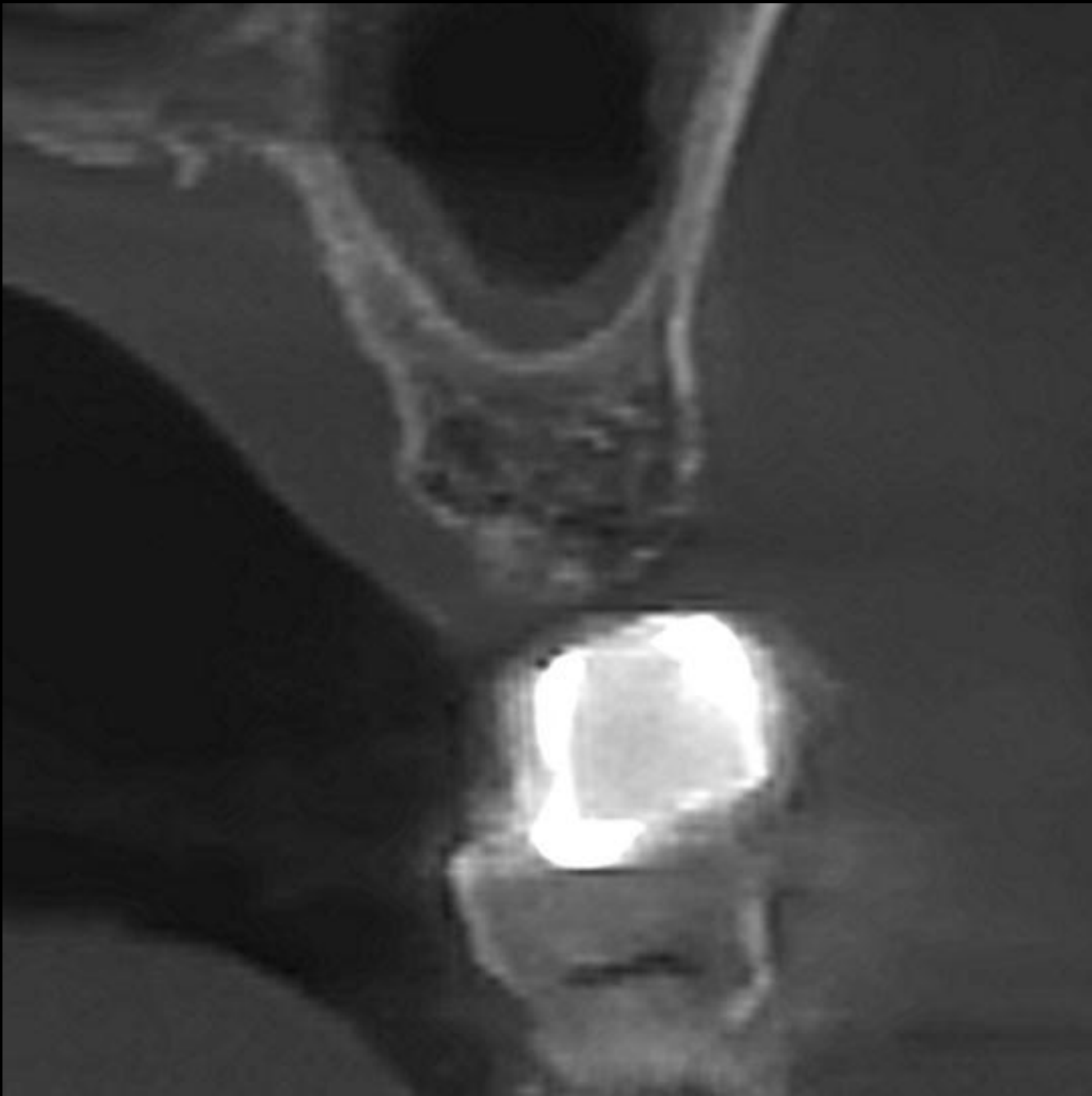


bright BL (Ø5.0 X 7.0)

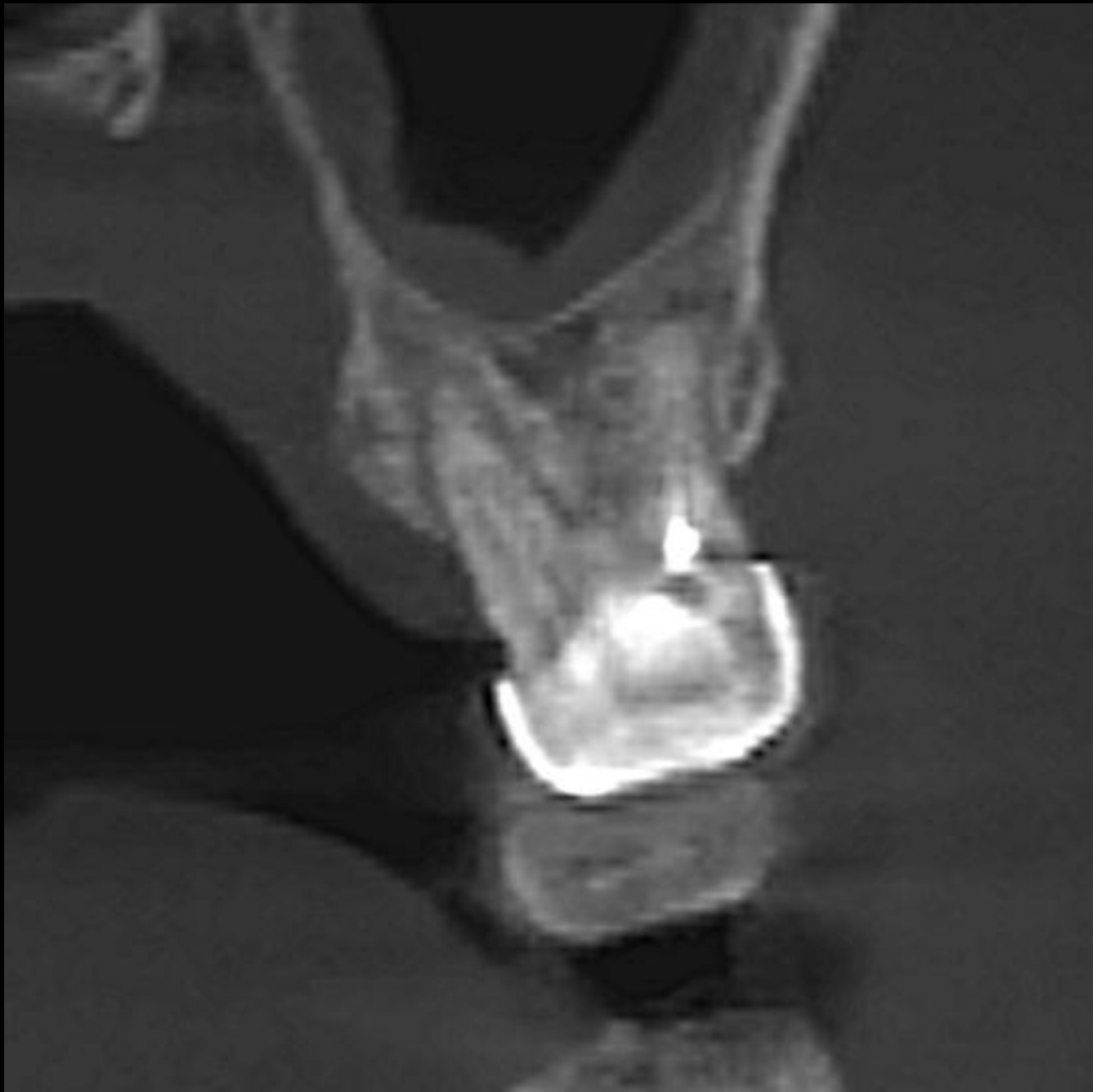bright BL (Ø4.0 X 9.0)

Oral exam (2024-07-31)

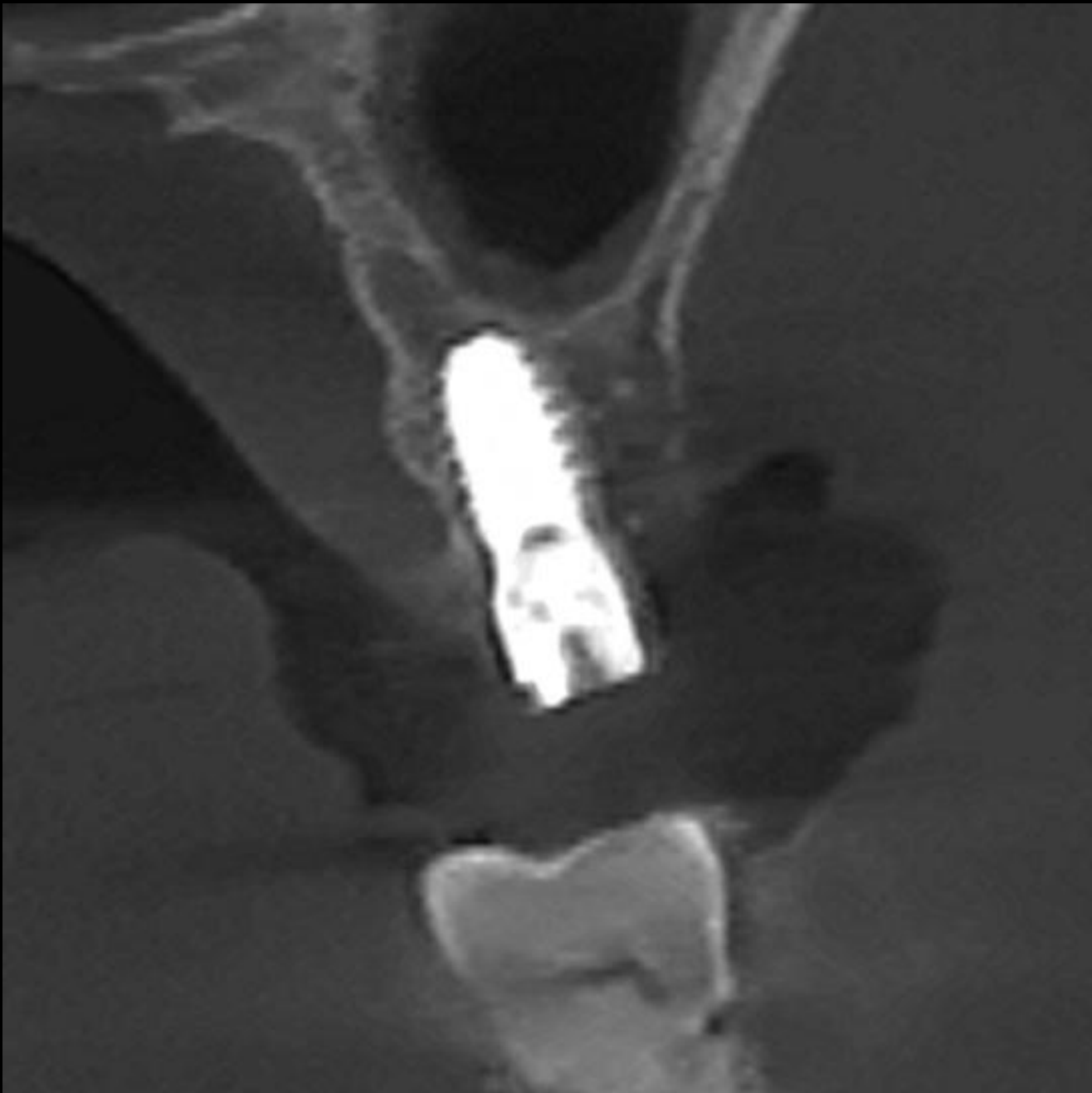




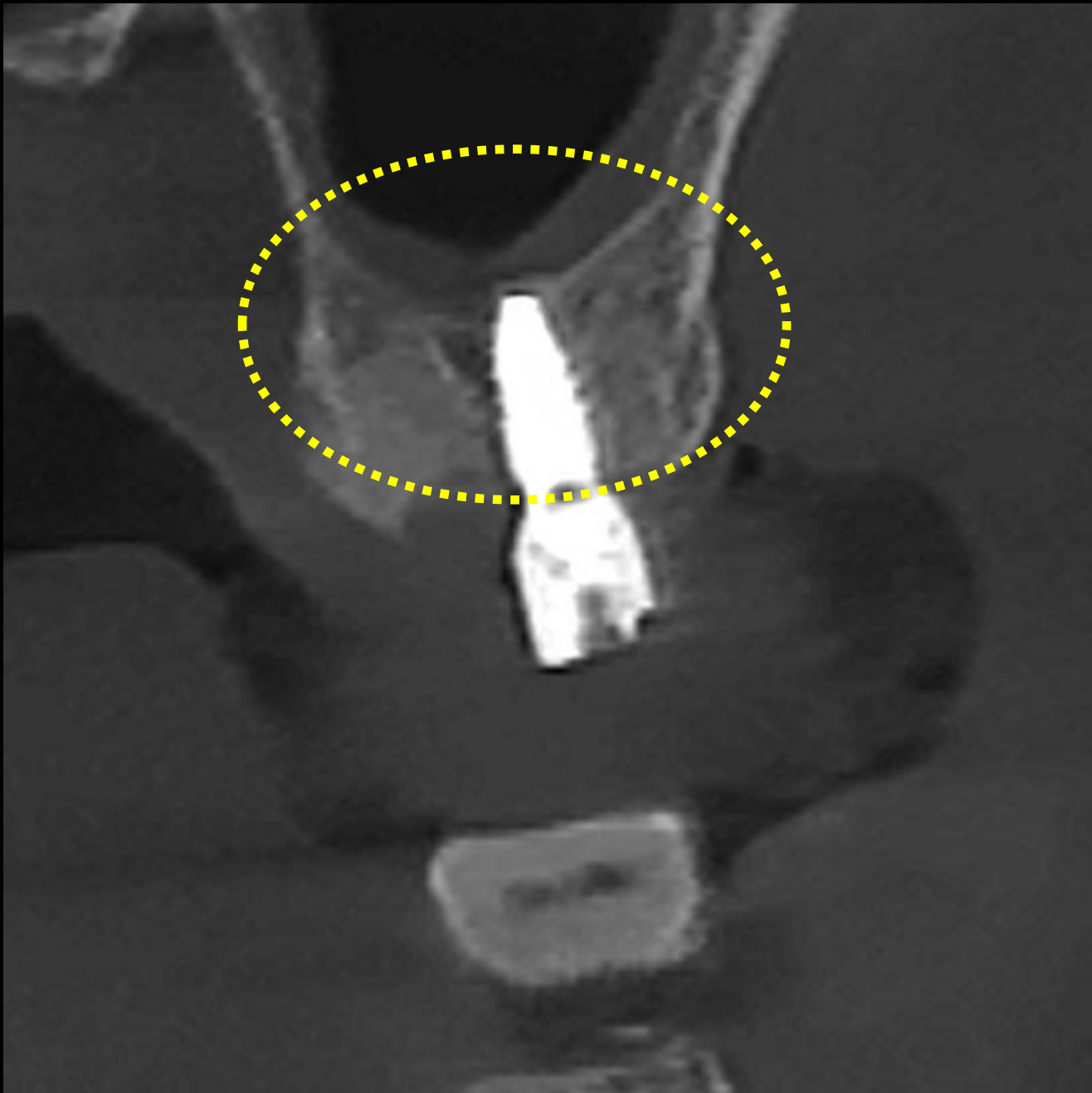
#26



#27

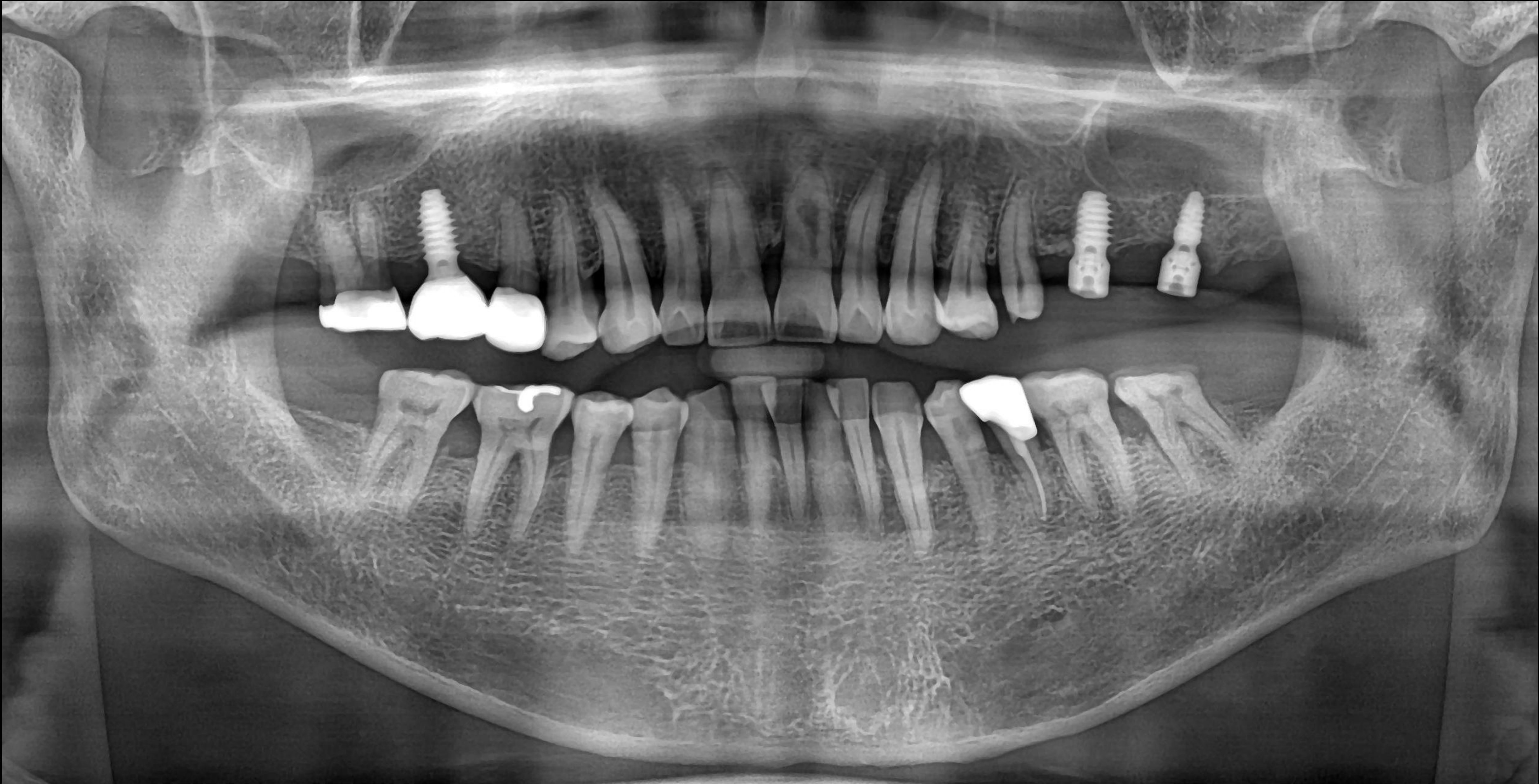


#26

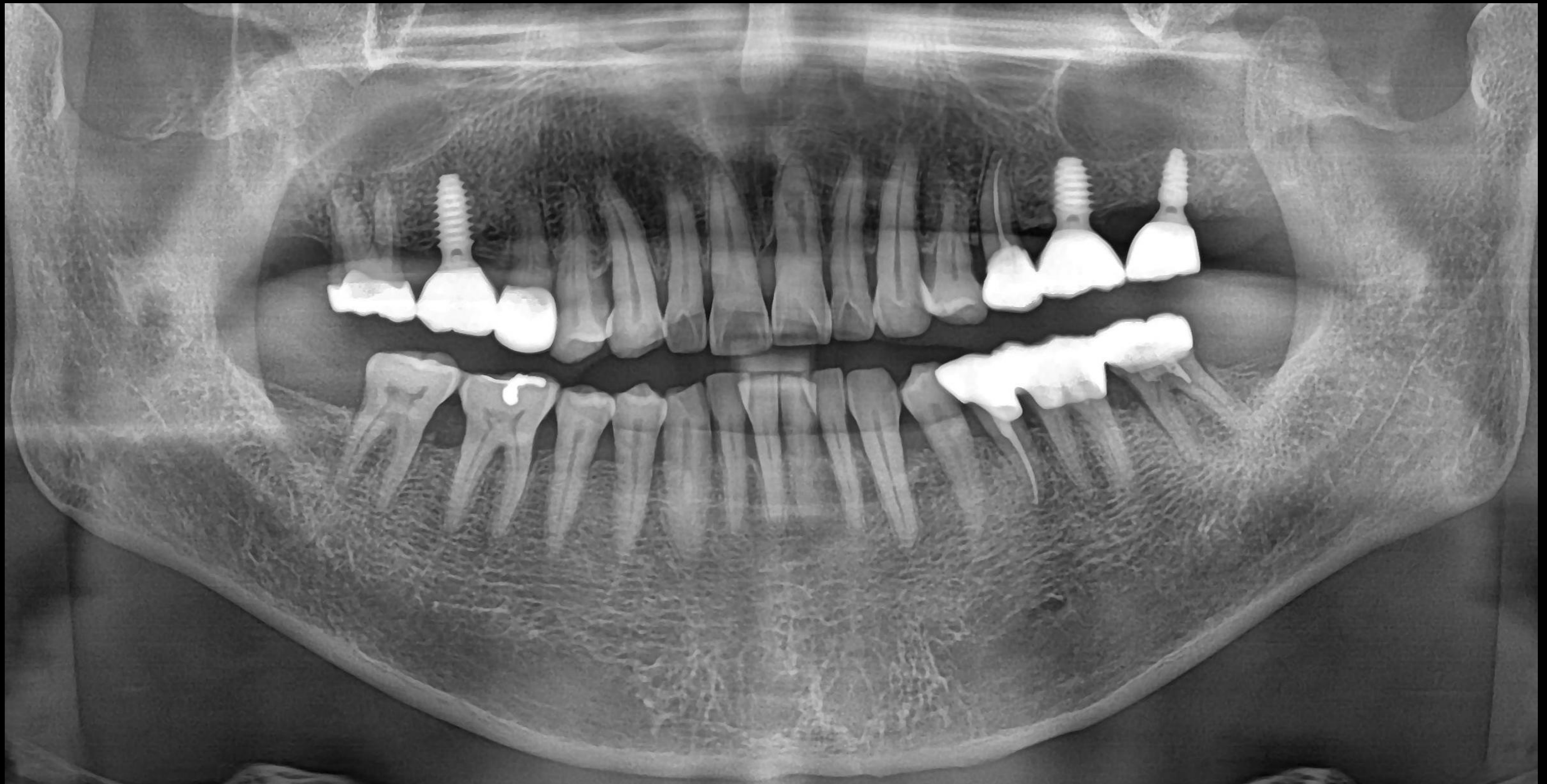

#27

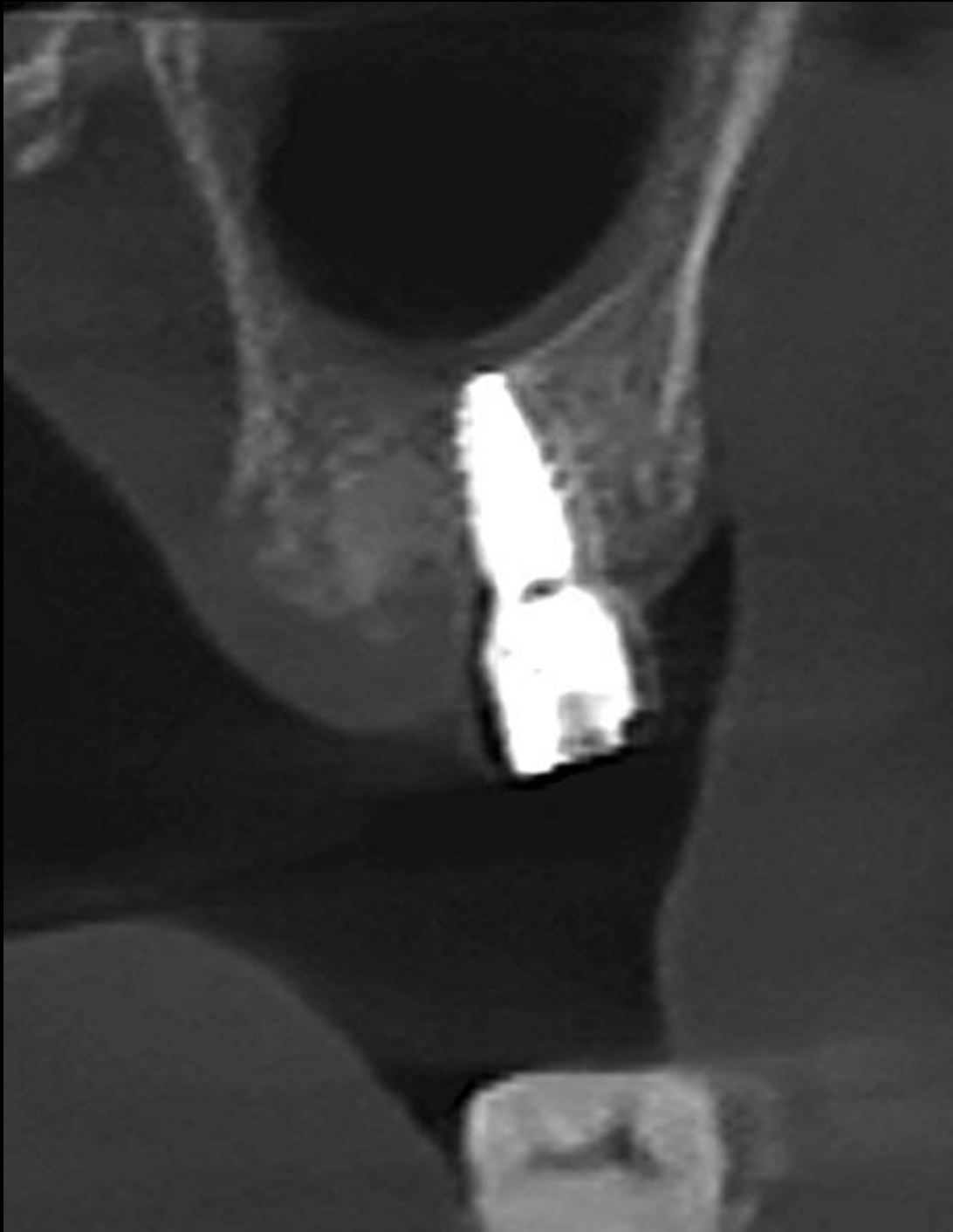
Post-op (2024-10-08)



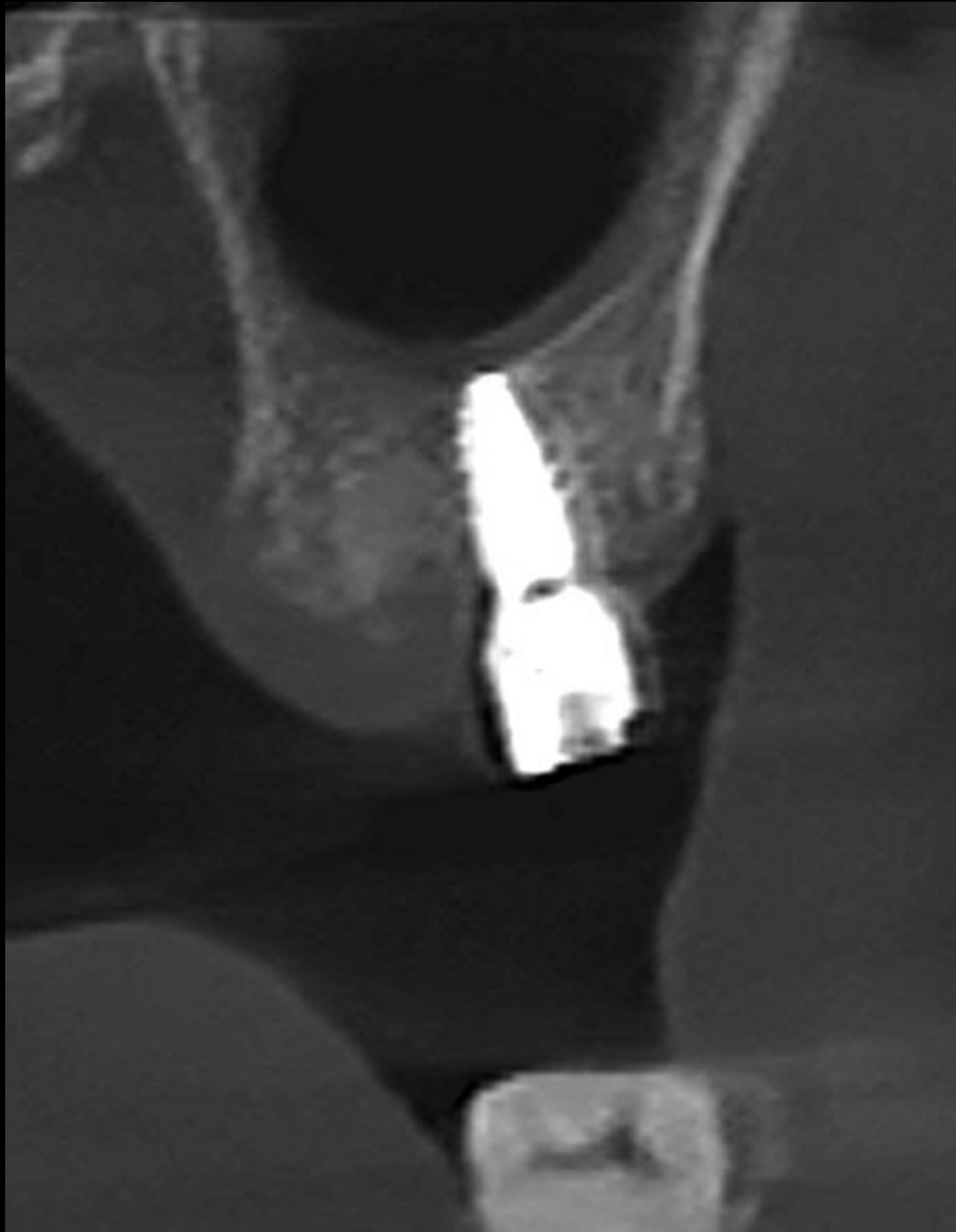
Final prosthesis (2025-01-08)



Follow up CT : 4 weeks (2024-10-30)

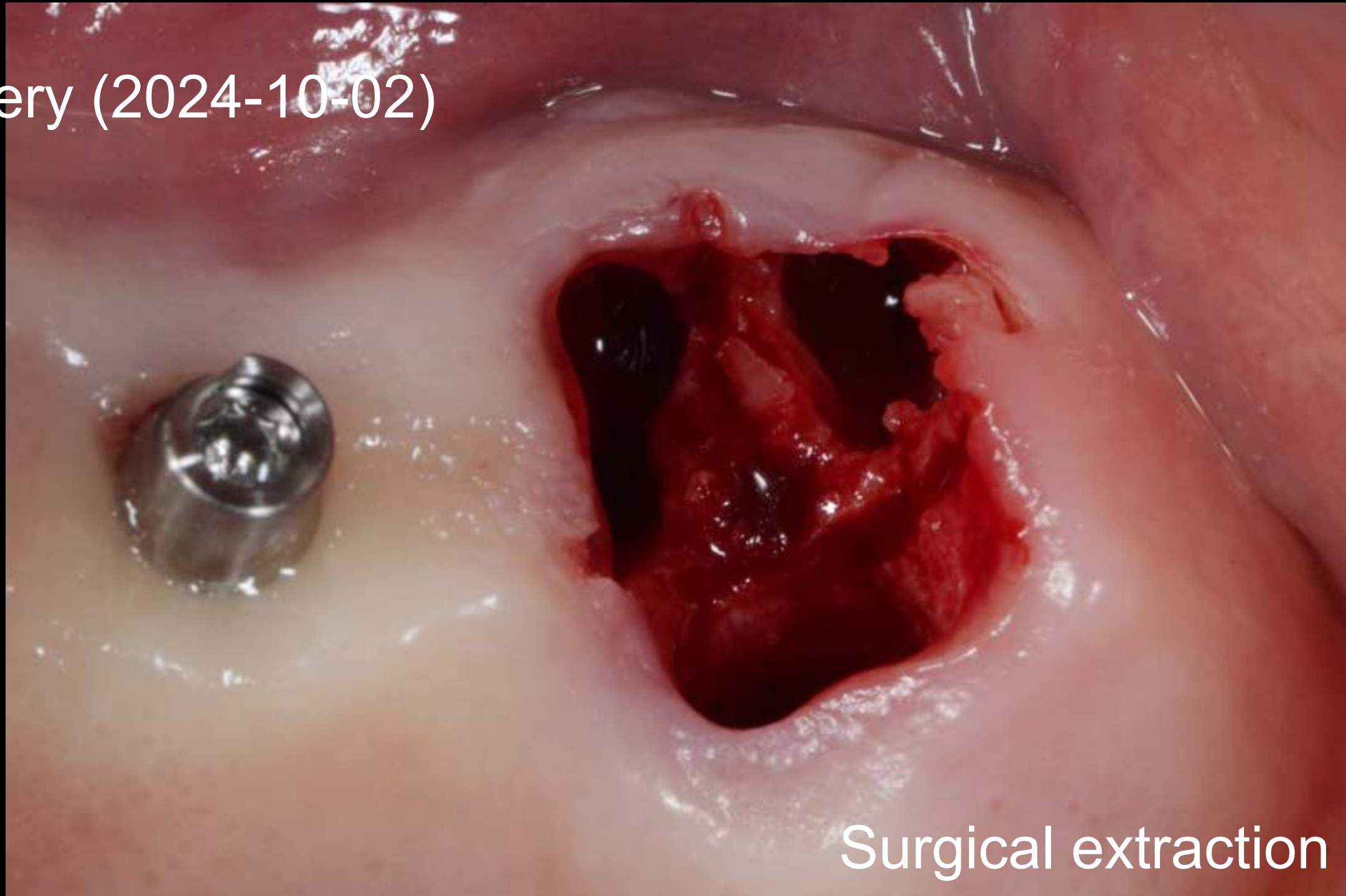


#26

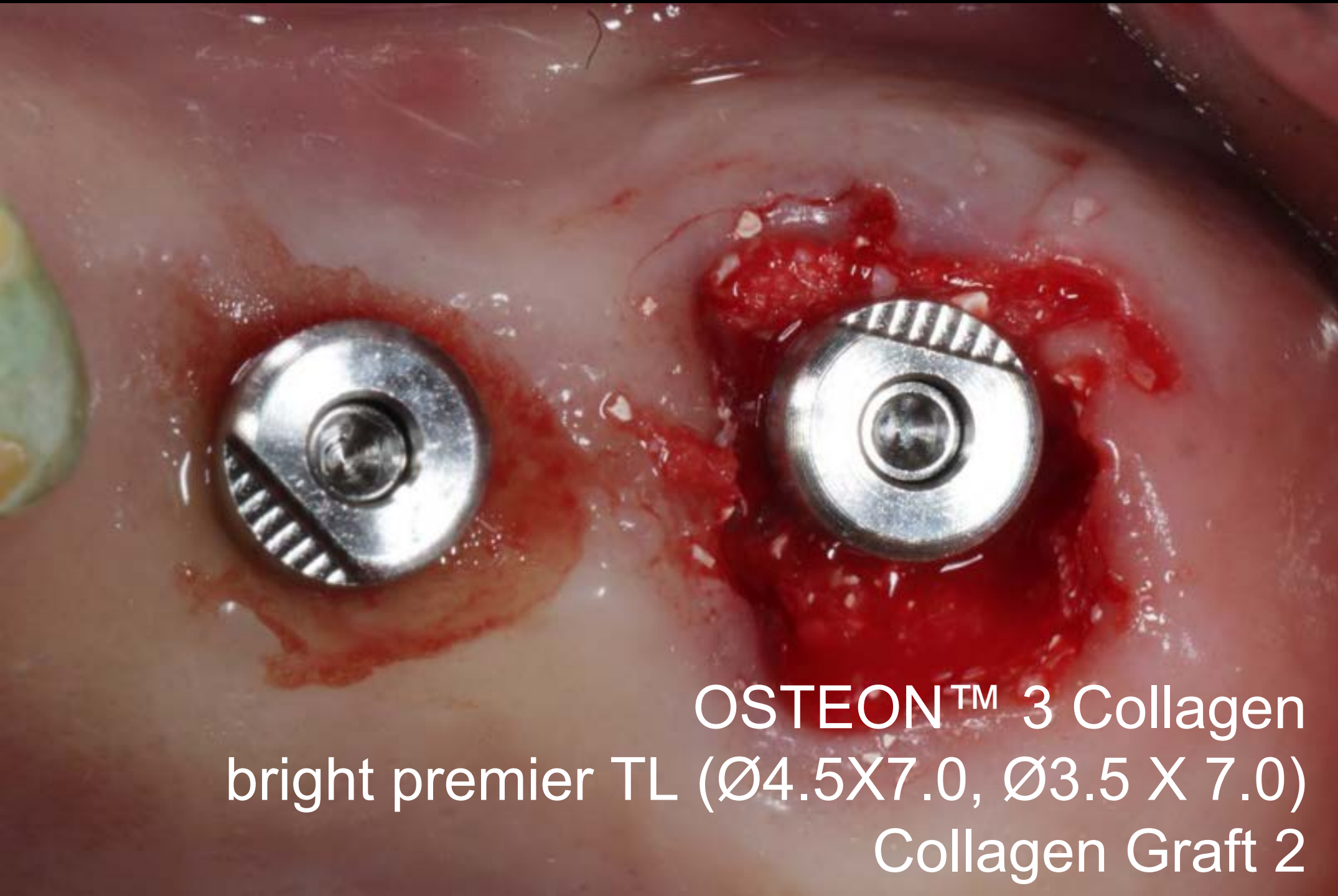

#27

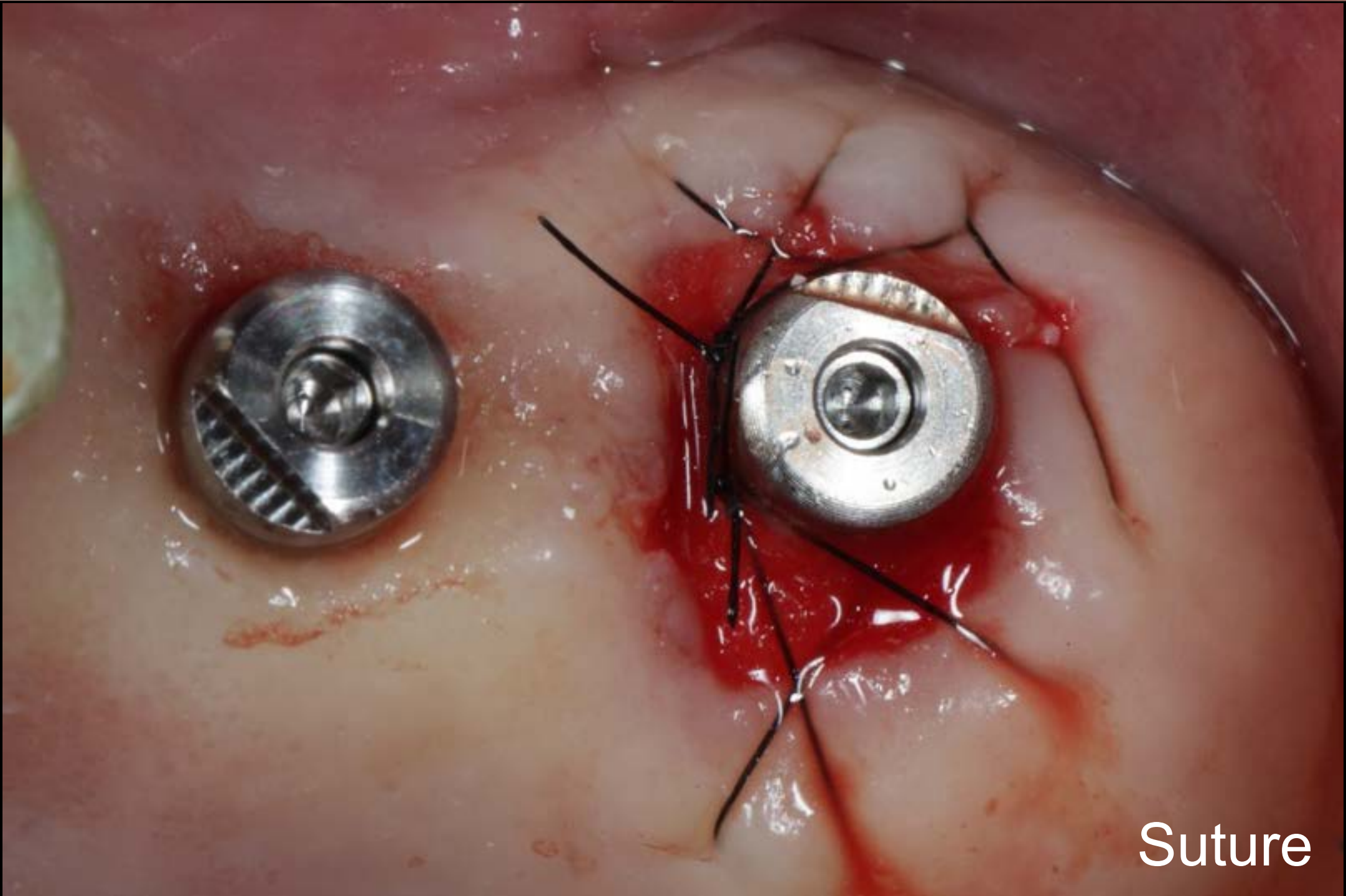
Surgery (2024-10-02)



Surgical extraction

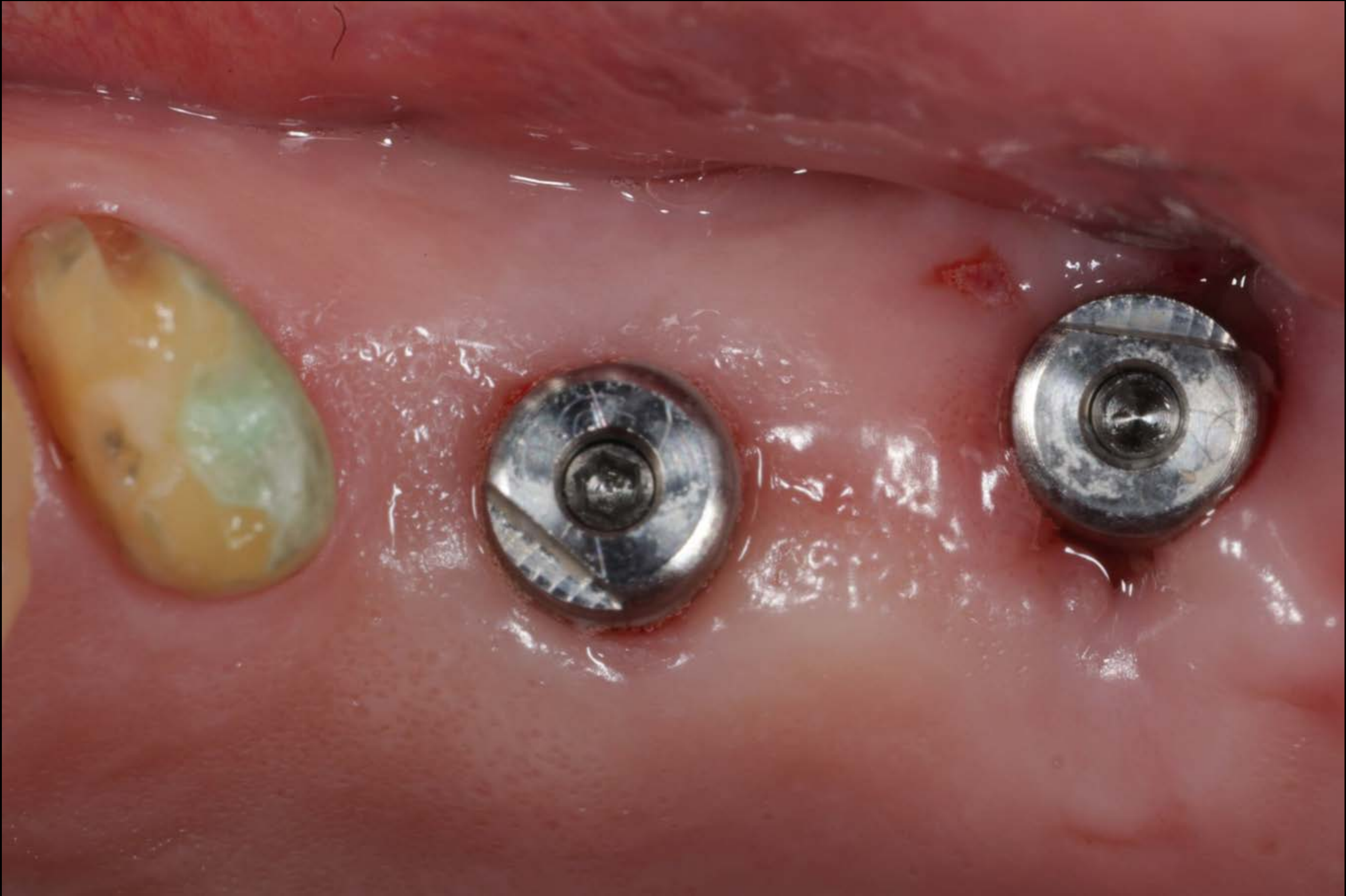

OSTEON™ 3 Collagen
bright premier TL (Ø4.5X7.0, Ø3.5 X 7.0)
Collagen Graft 2

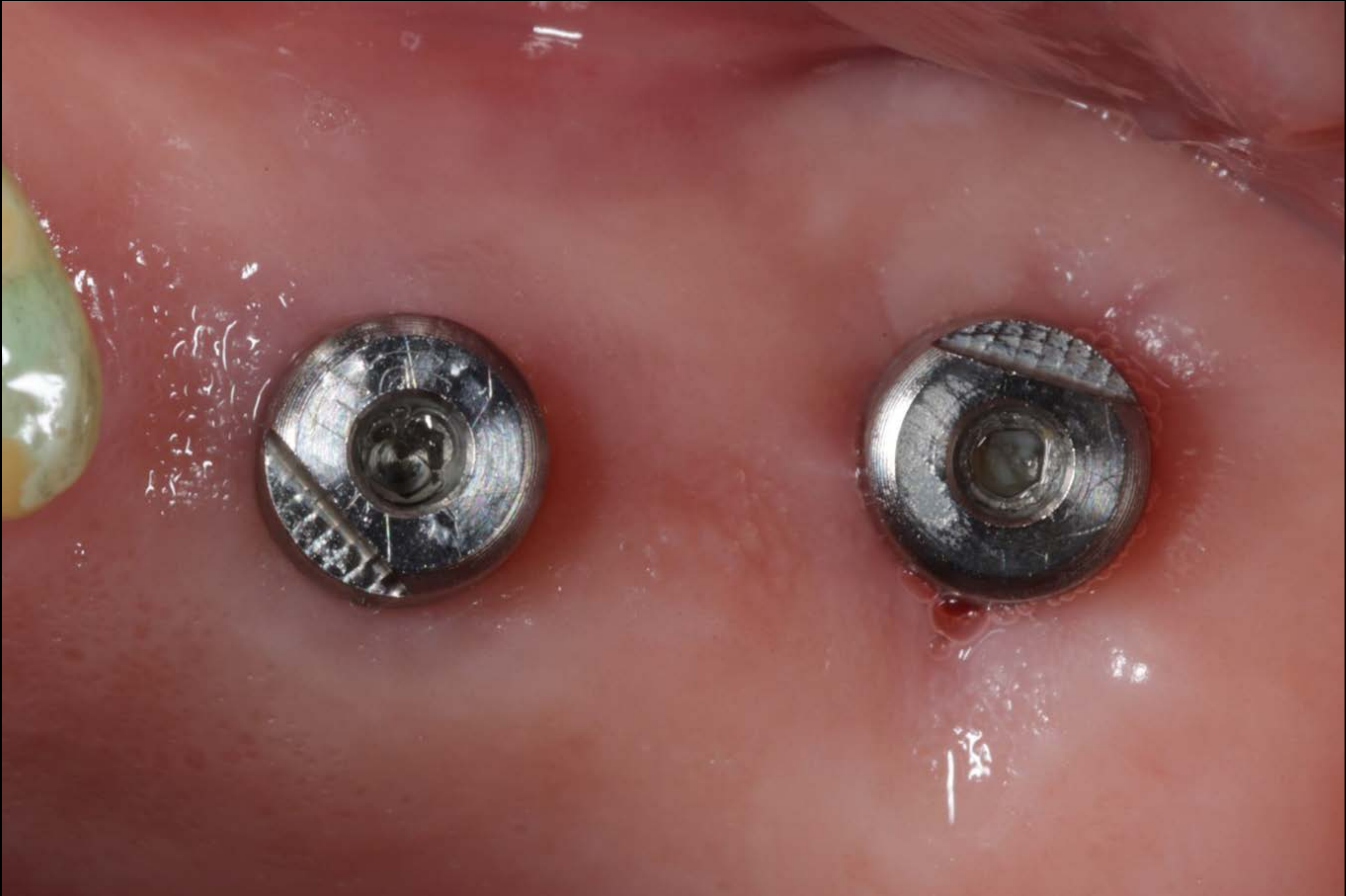

Suture

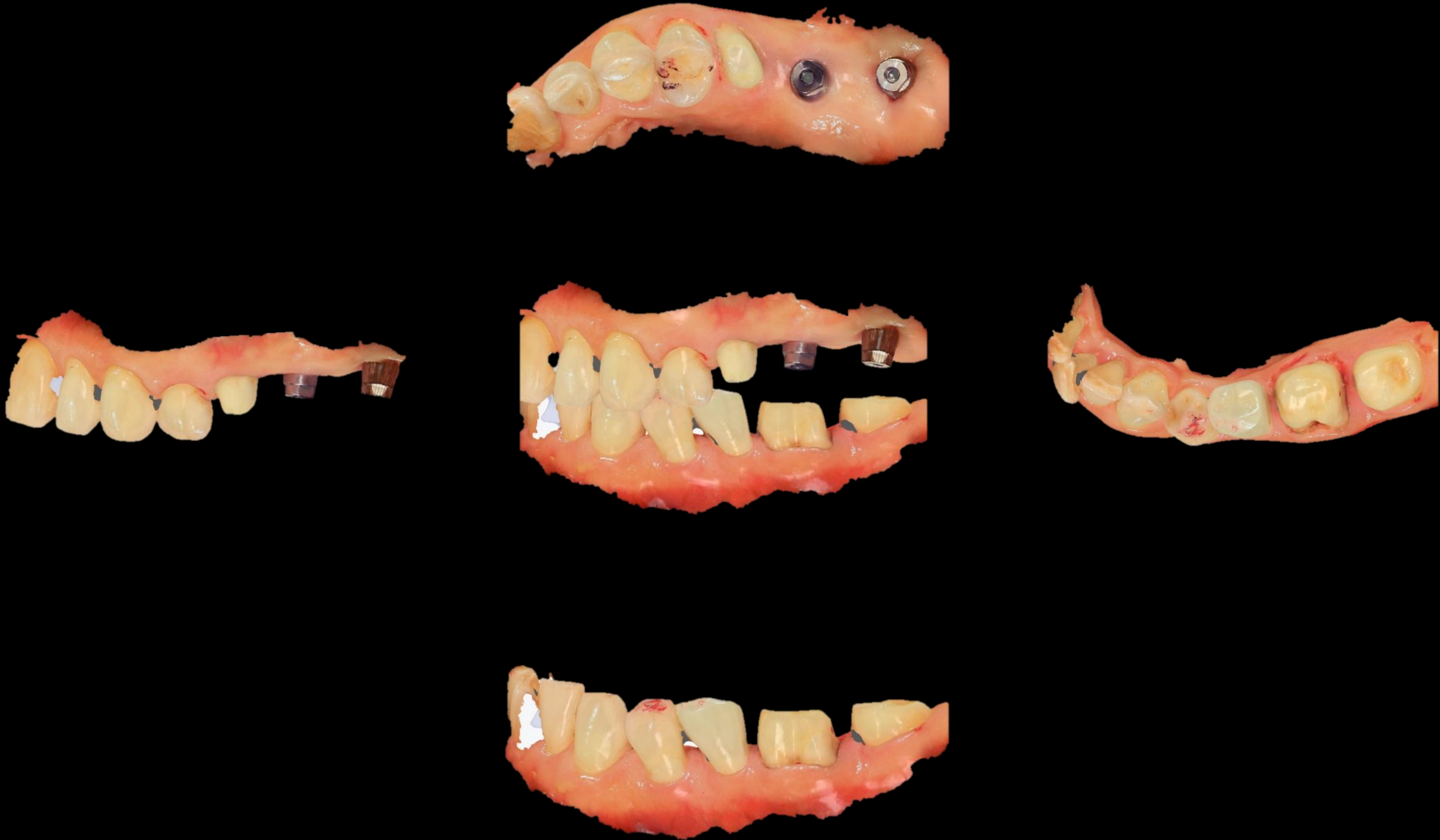Healing : 1 week (2024-10-08)



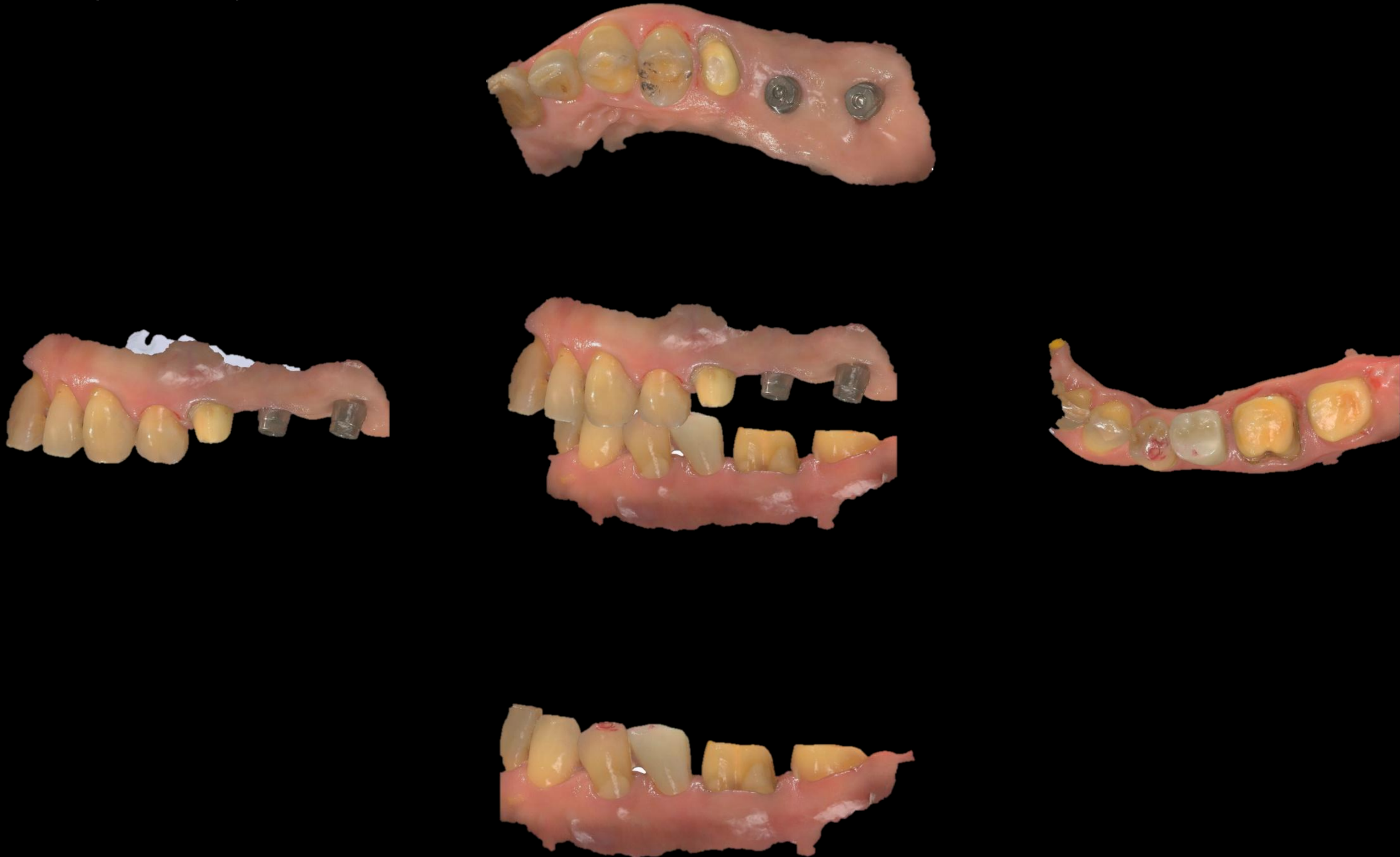
Healing : 1 month (2024-10-30)



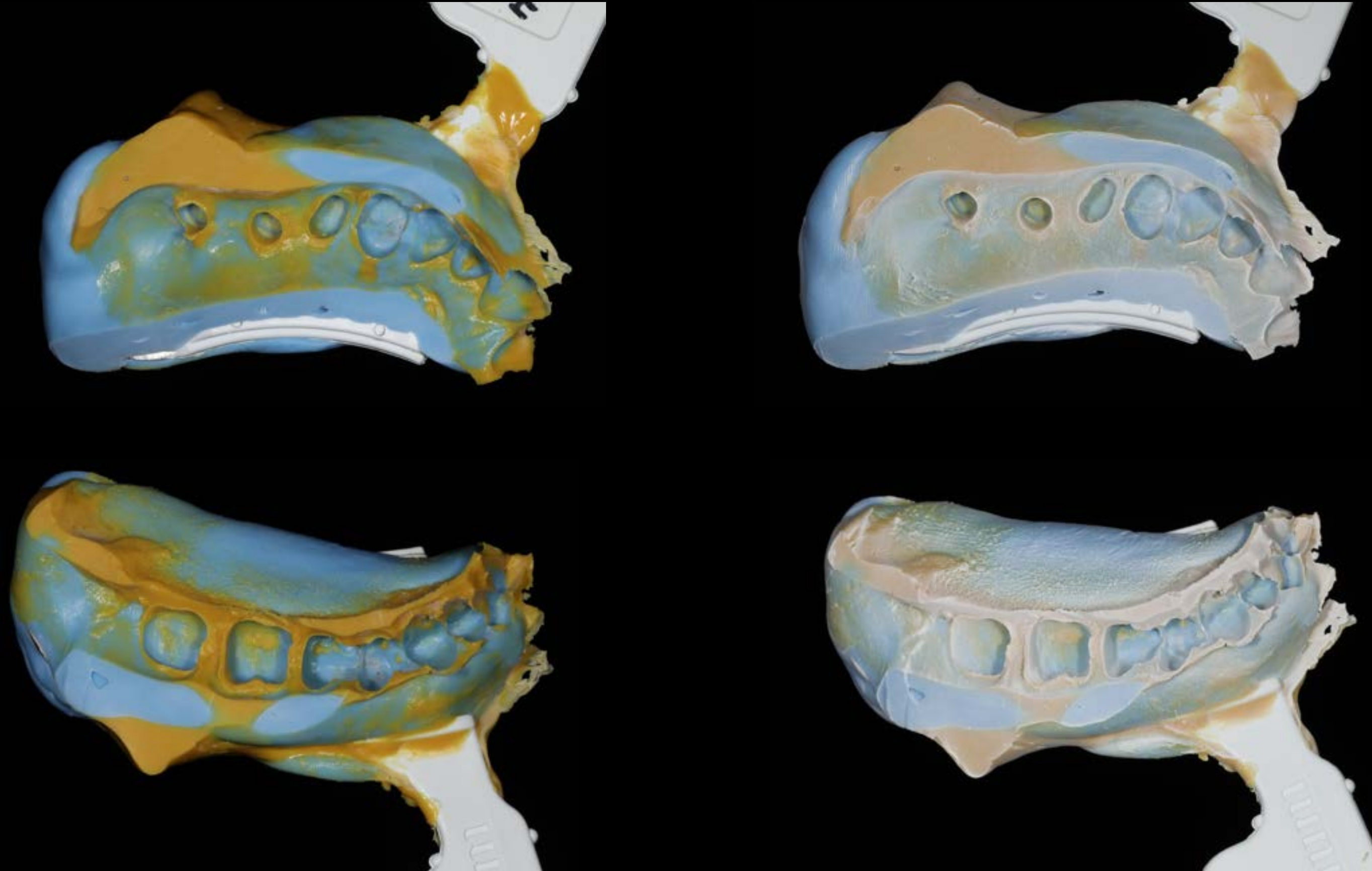
Intra Oral Scan (Elite)



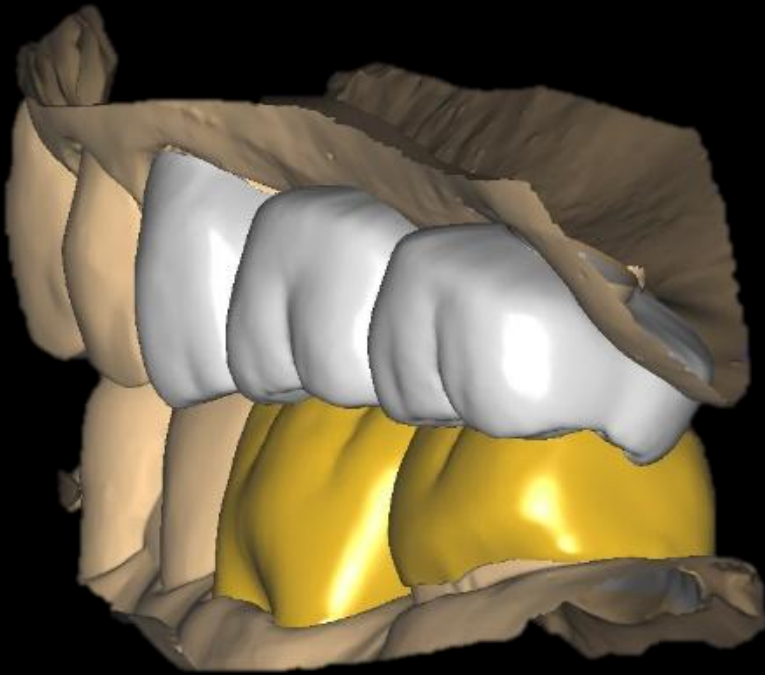
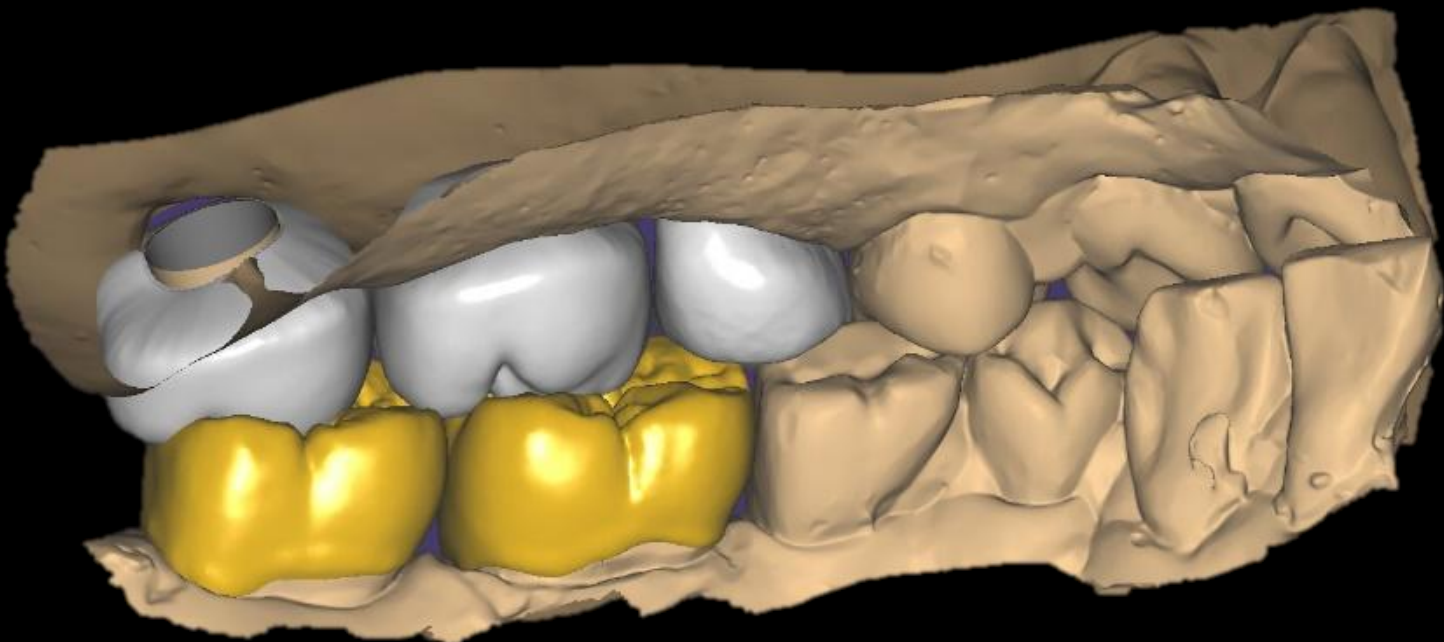
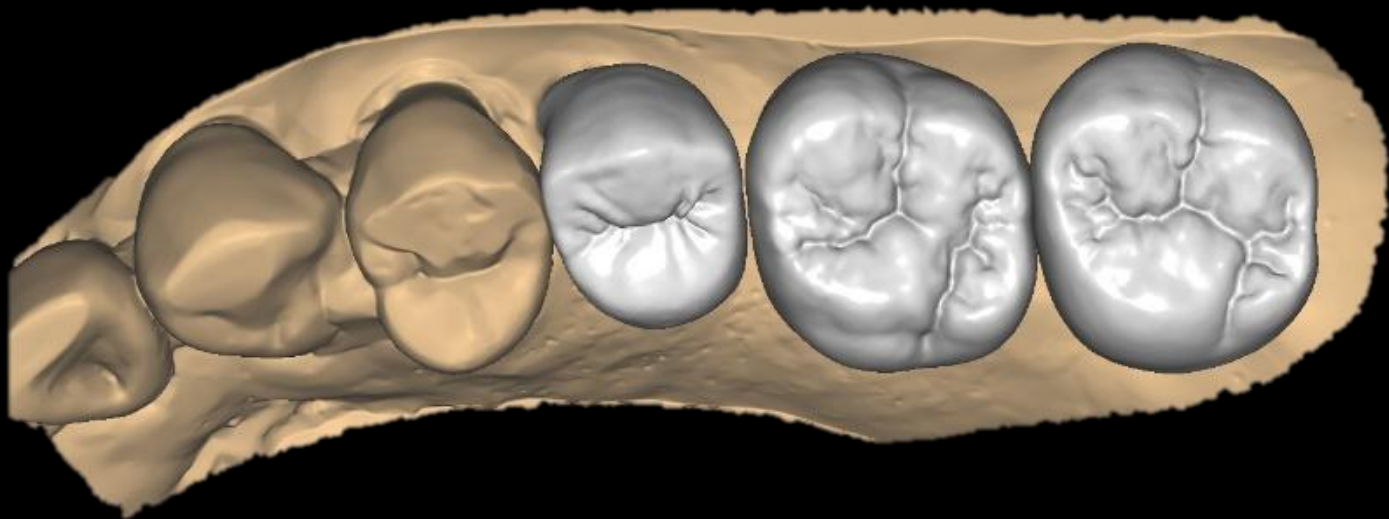
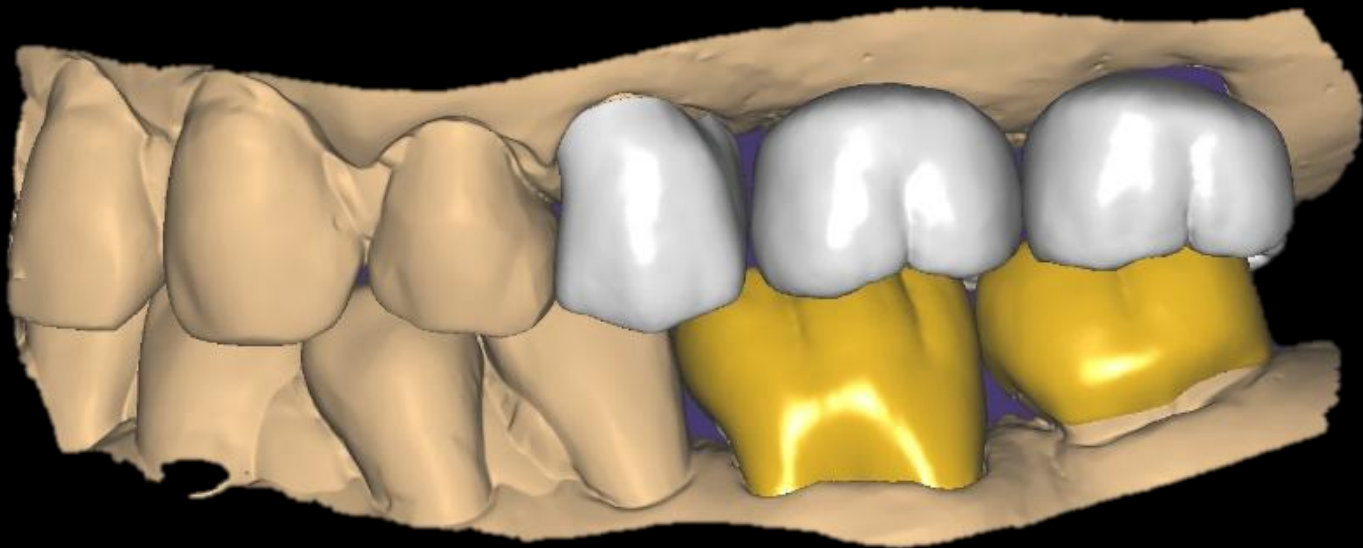
Intra Oral Scan (Wireless)



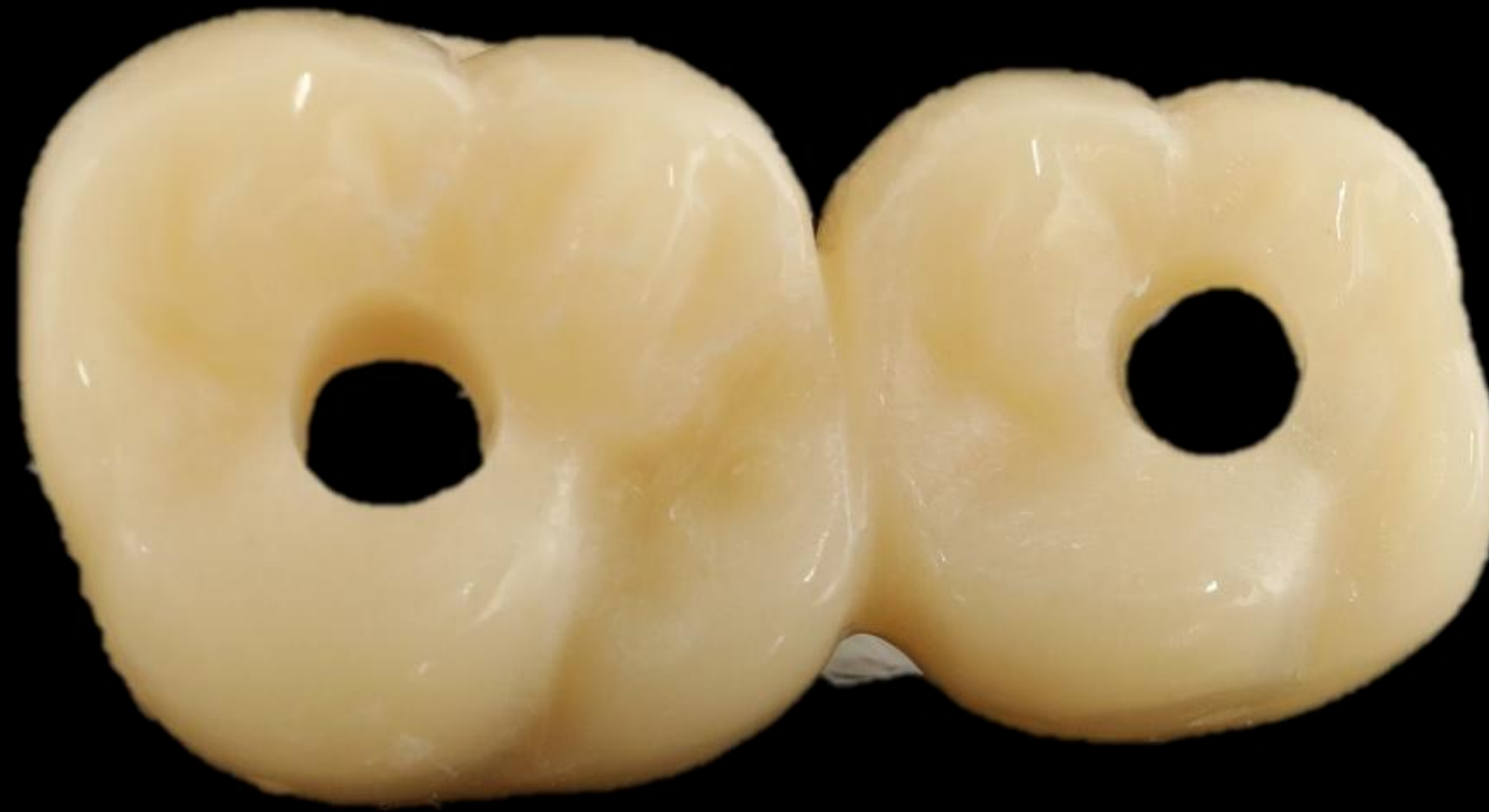Impression / Trimming / Scan Spray



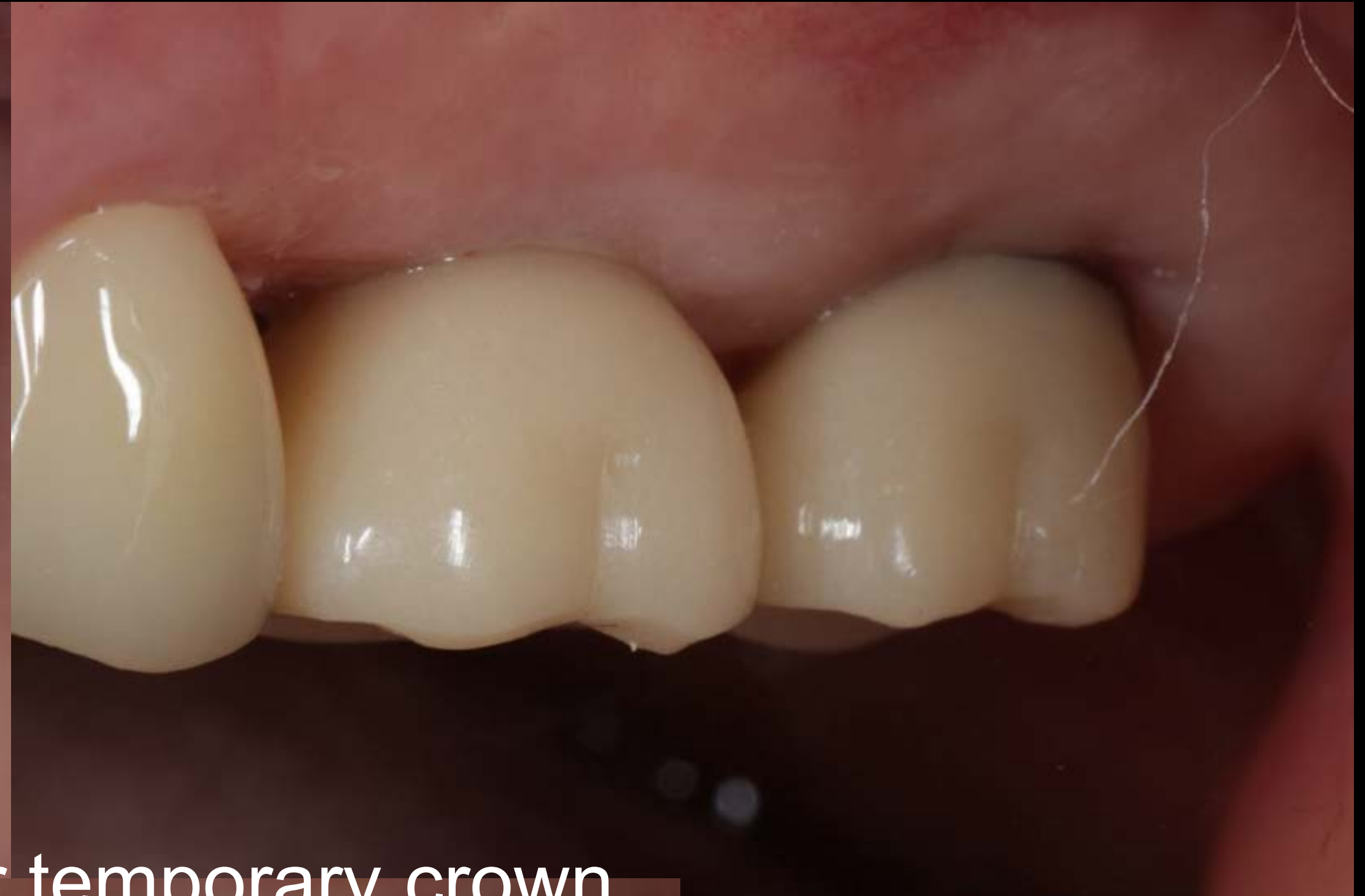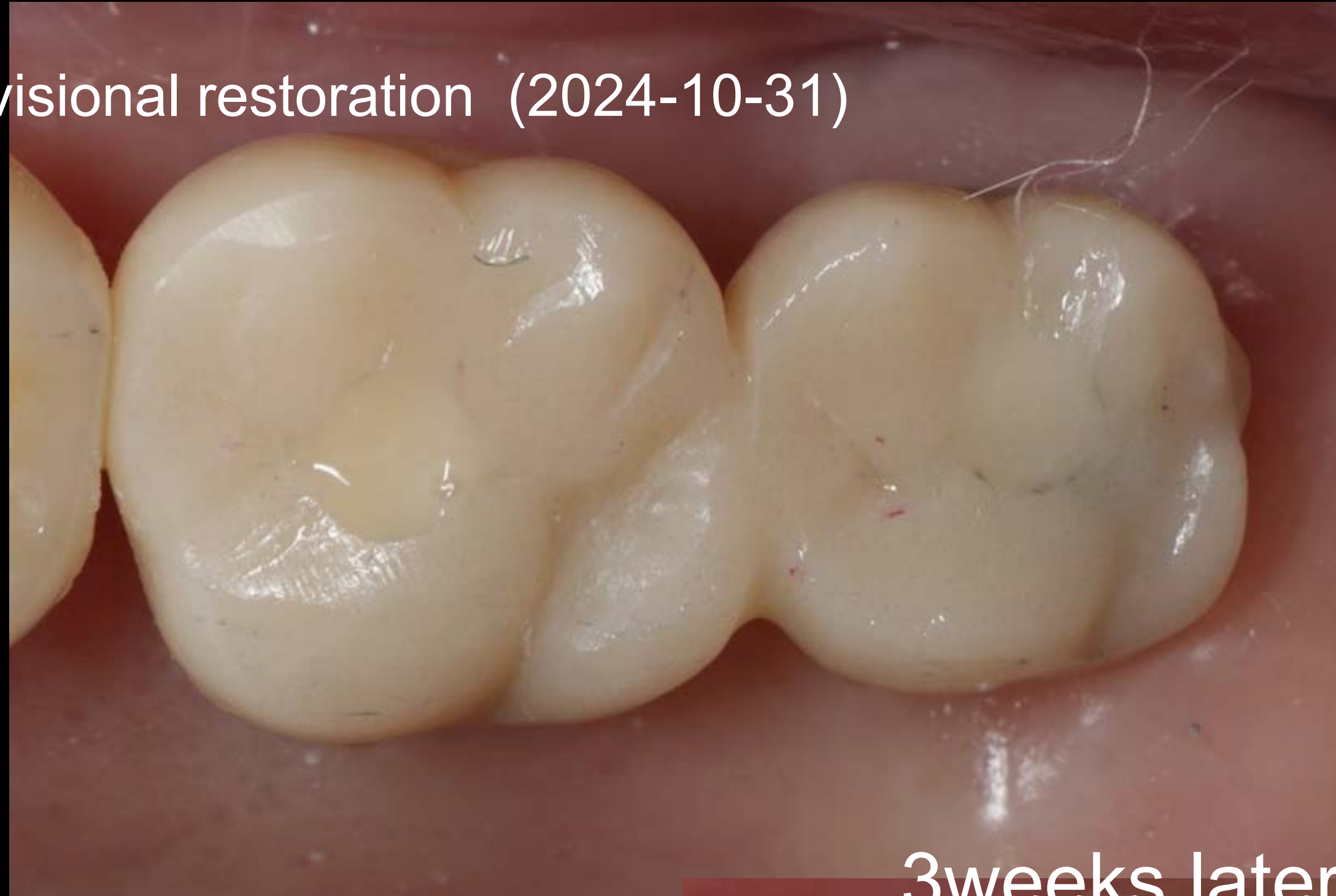CAD (Temporary)



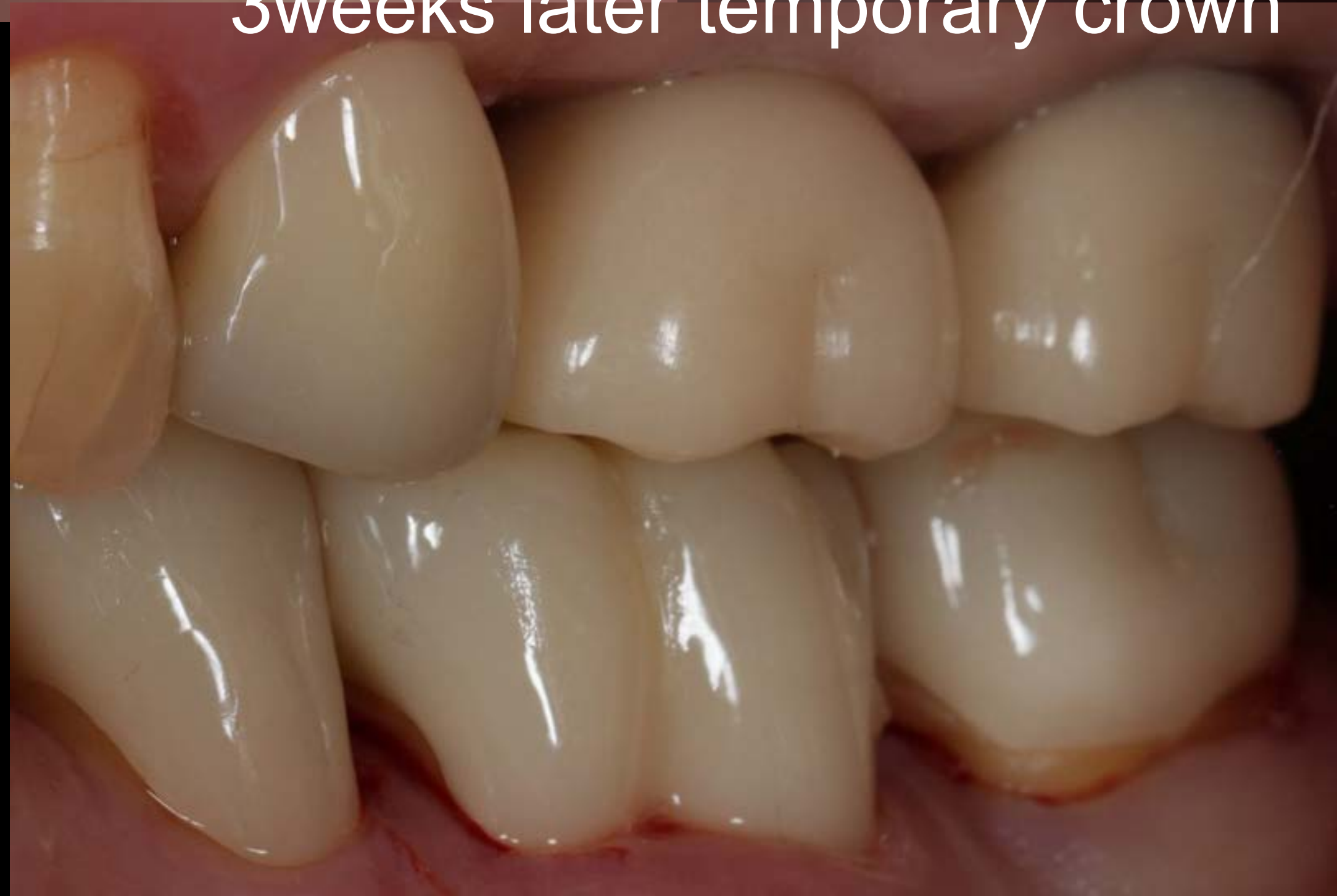Temporary Crown



Provisional restoration (2024-10-31)



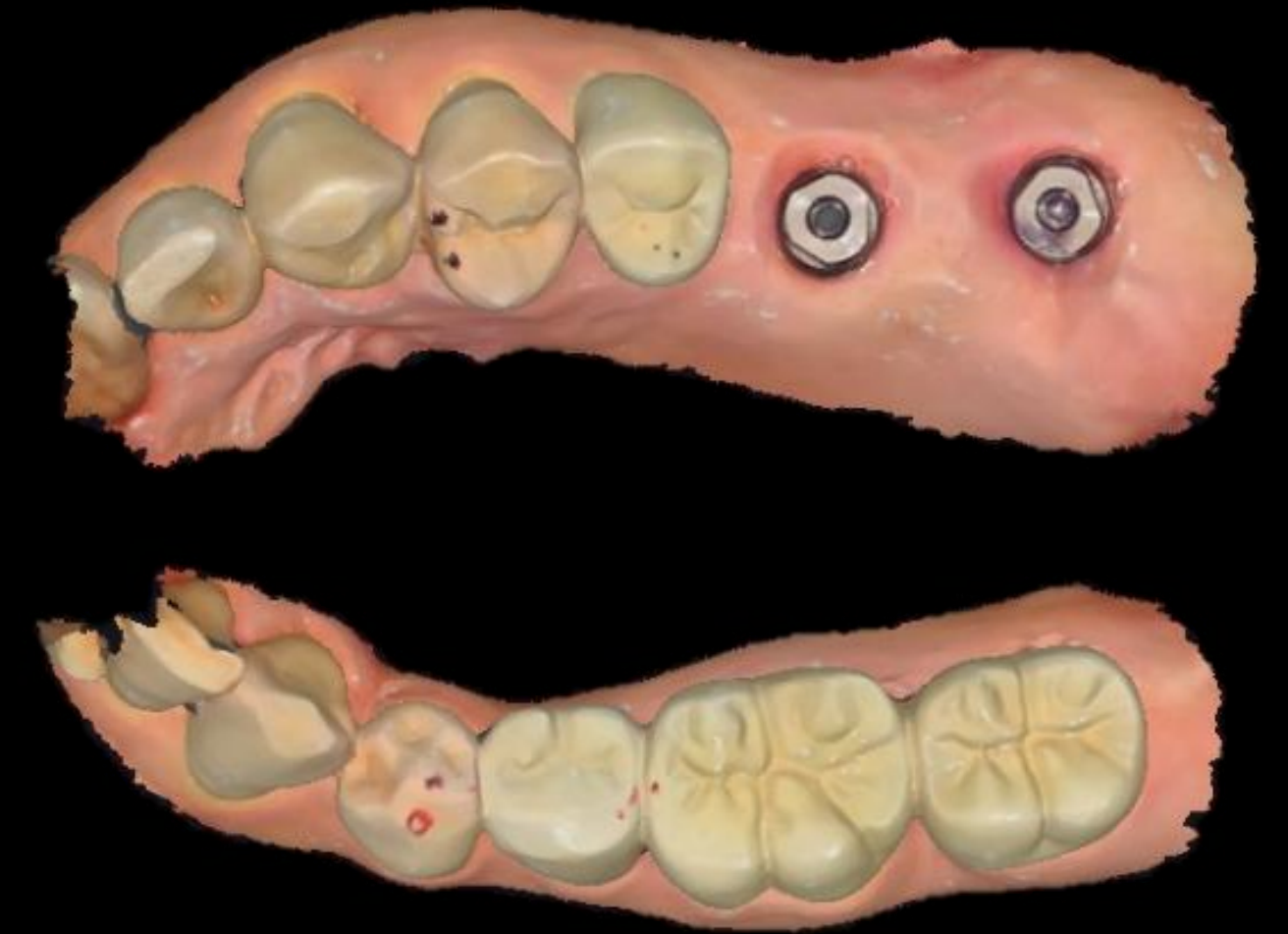
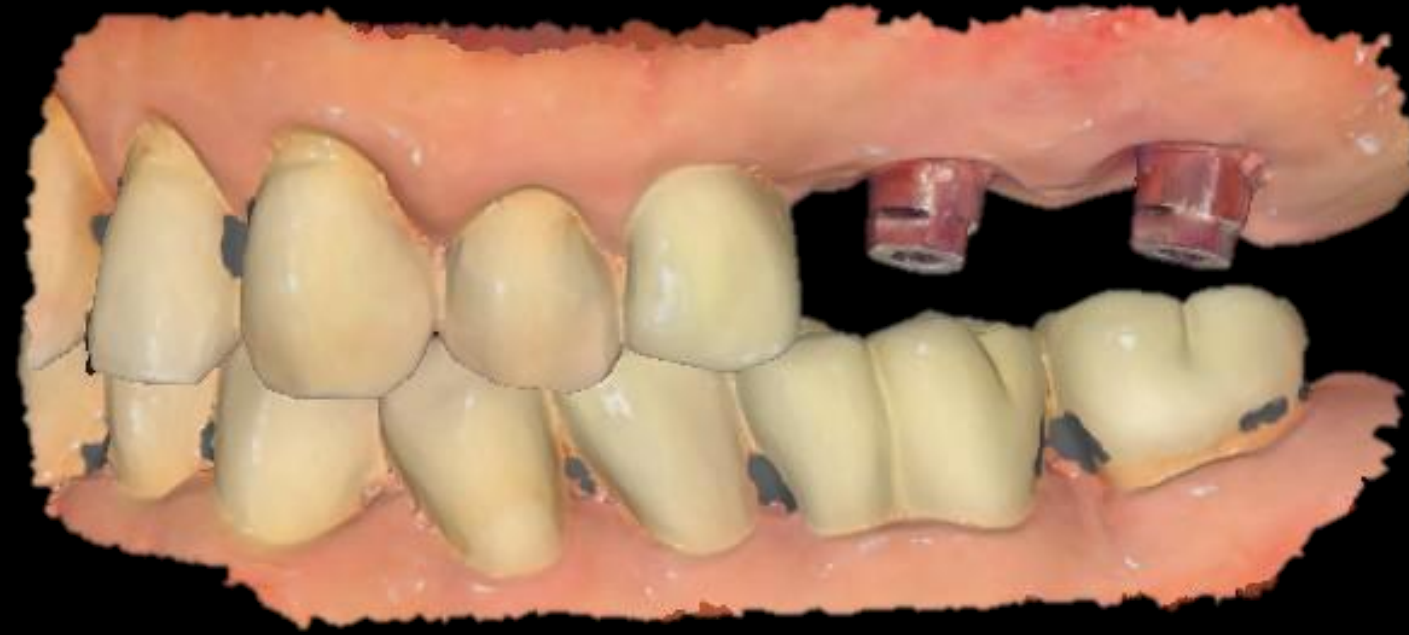3 weeks later temporary crown



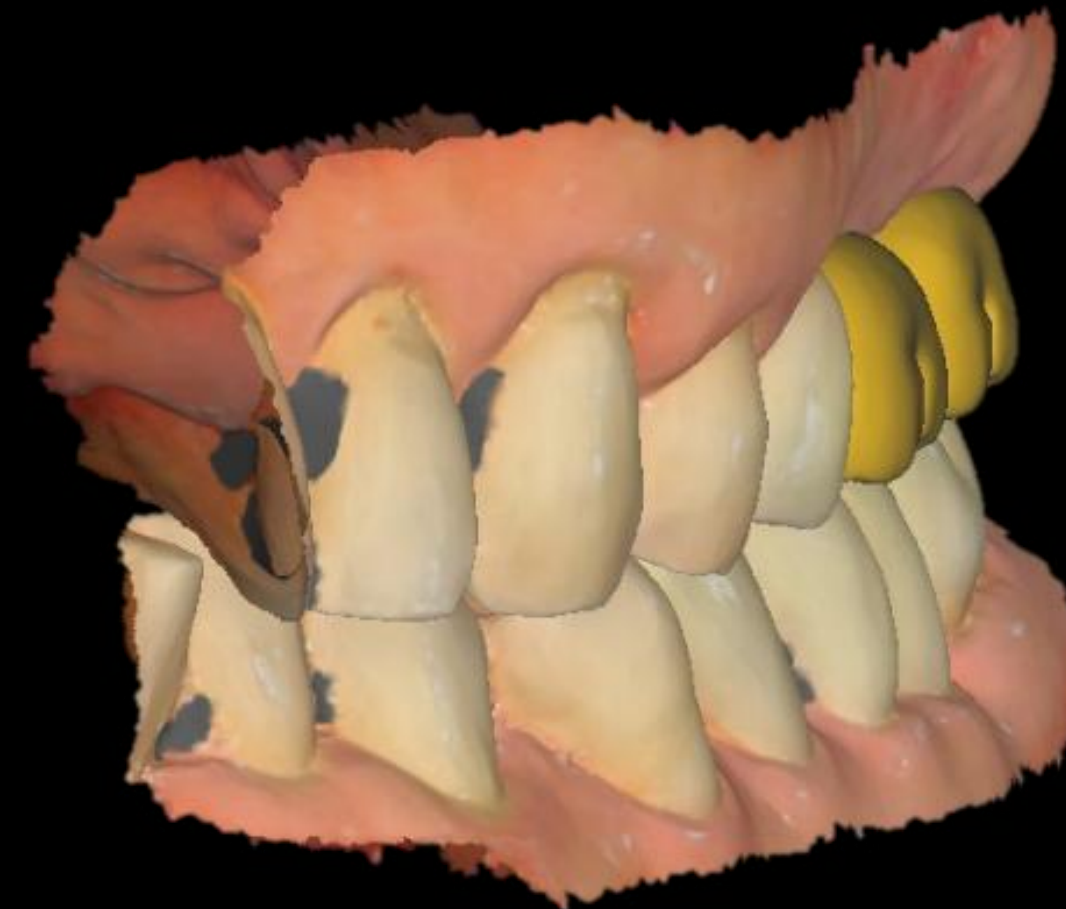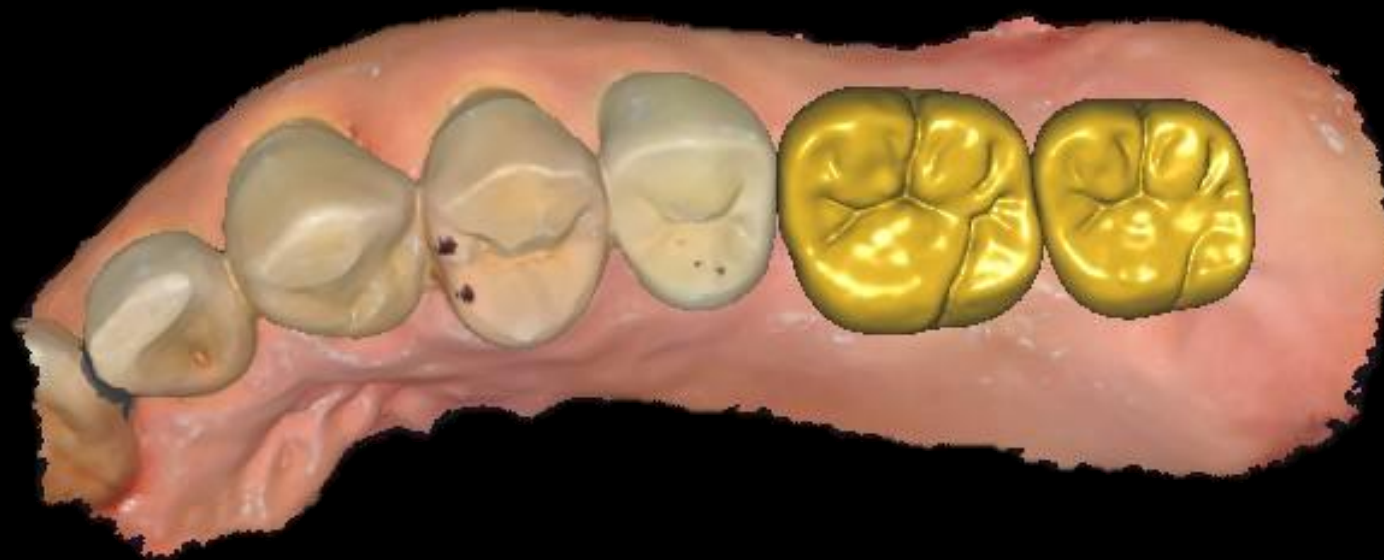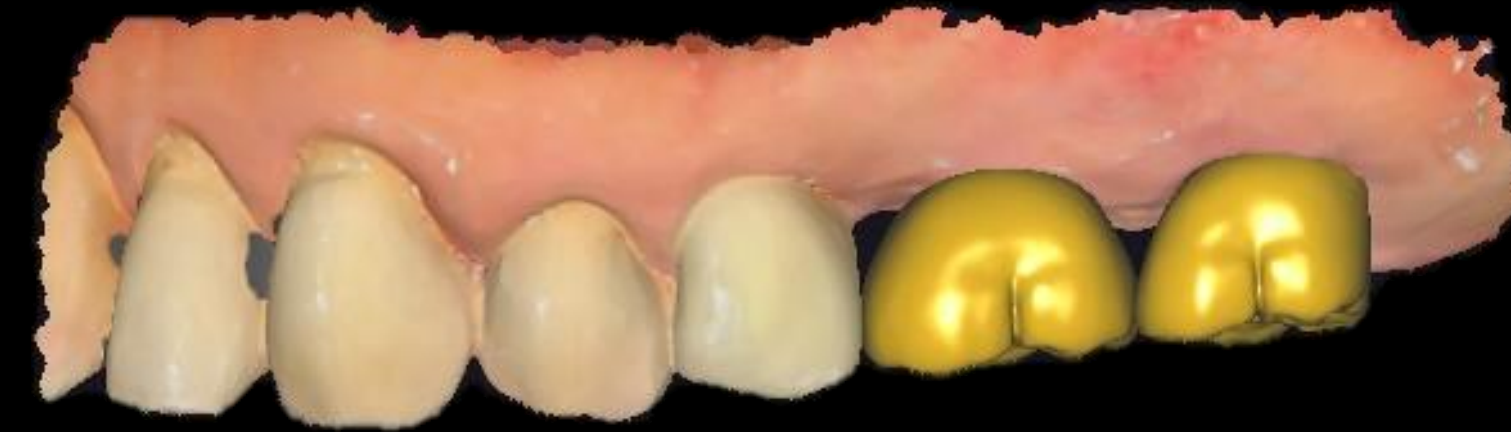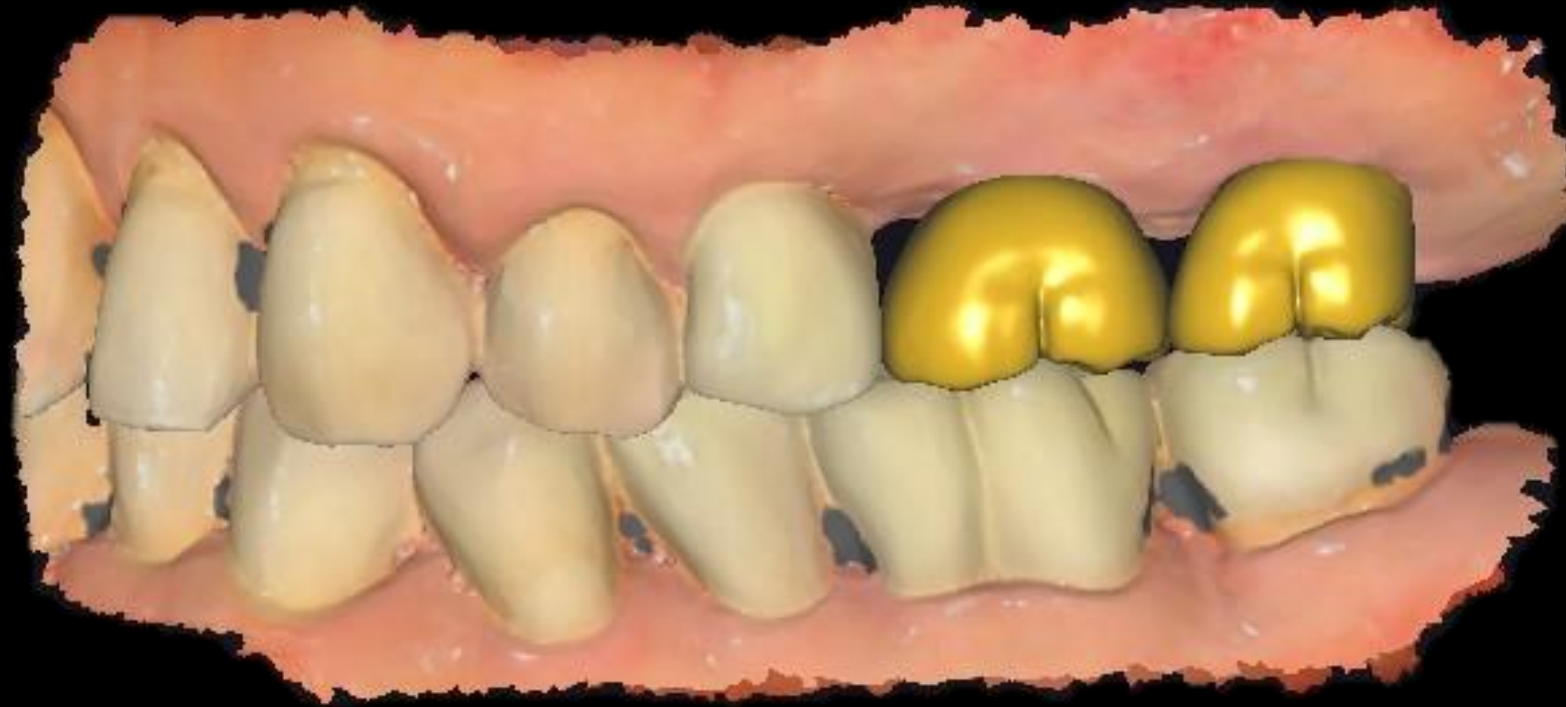Working model



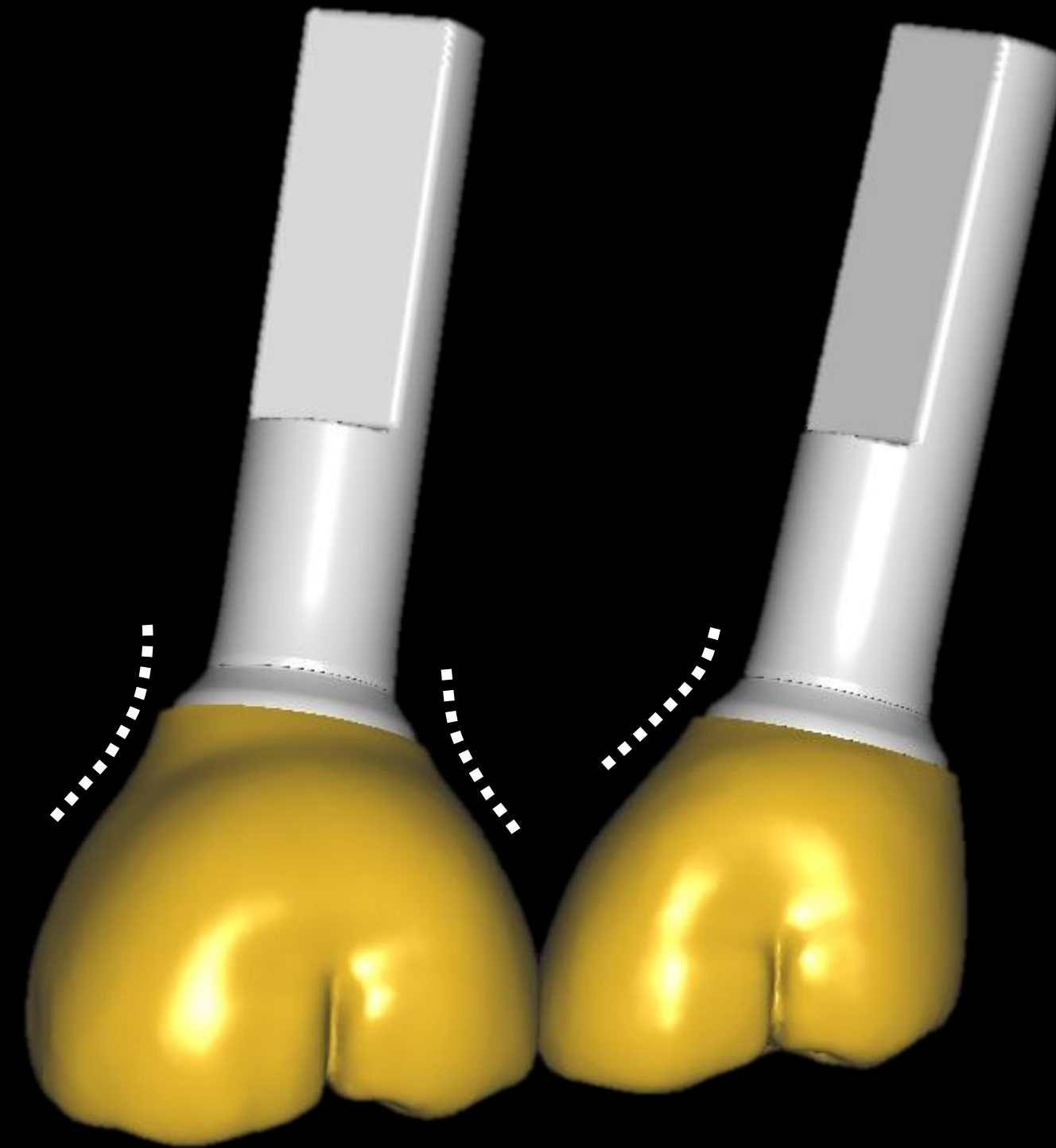
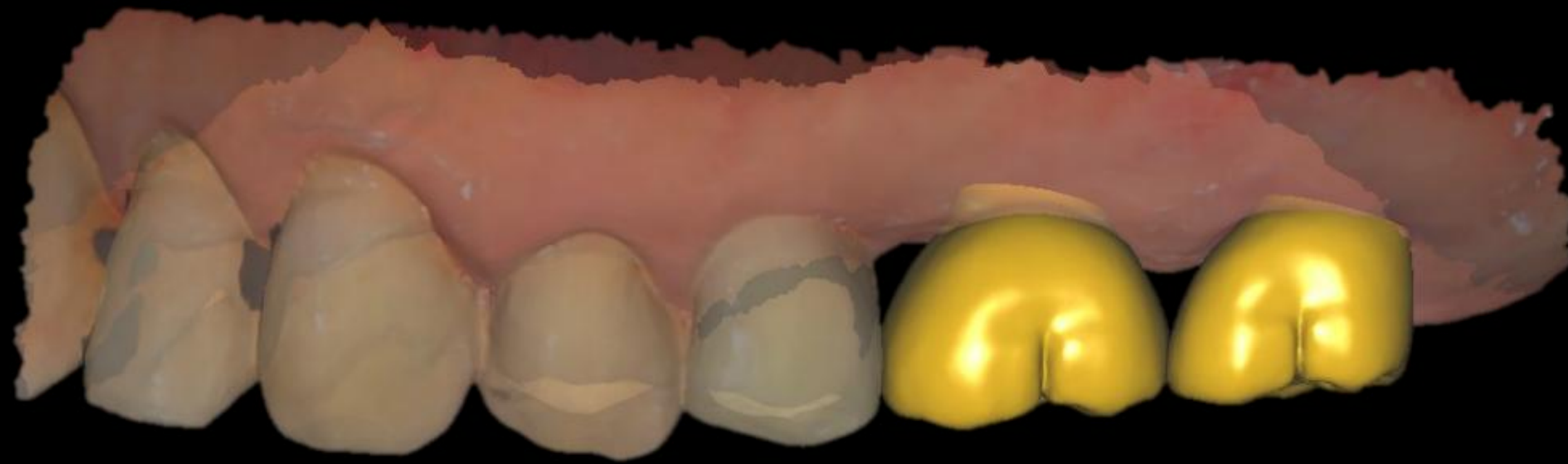
Shining3D Aoralscan
Elite



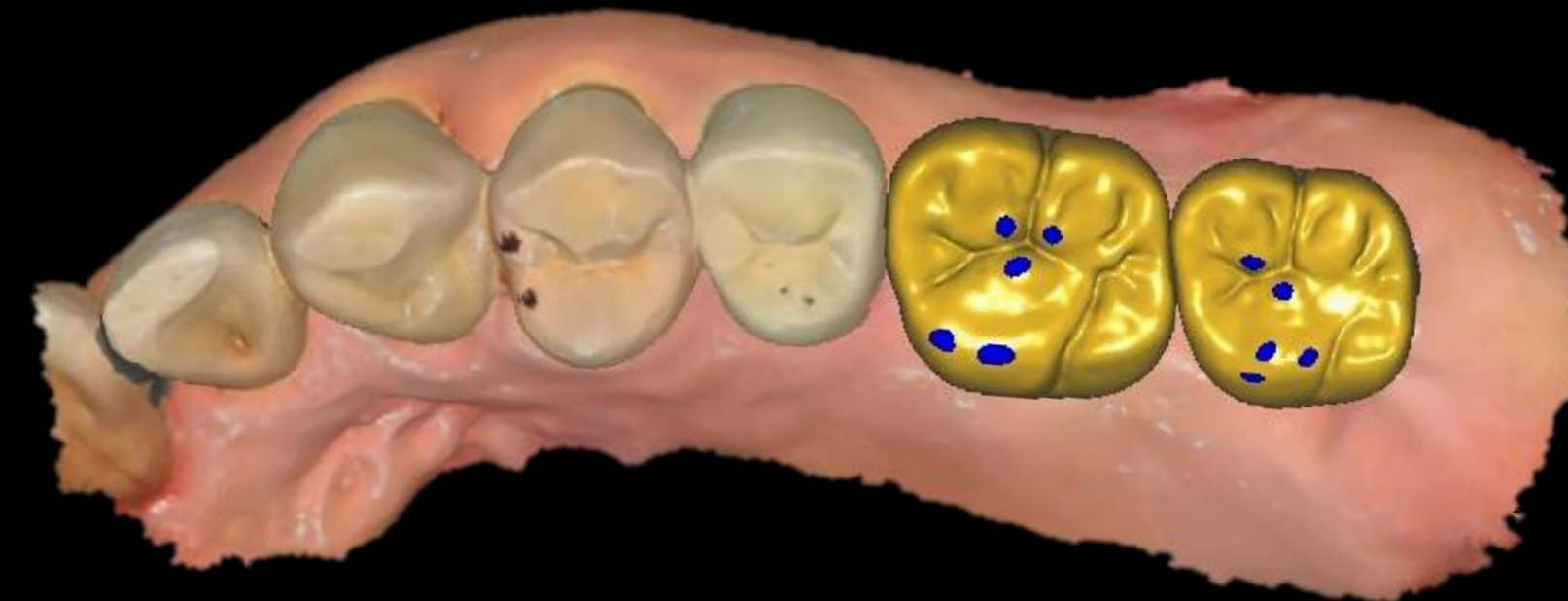
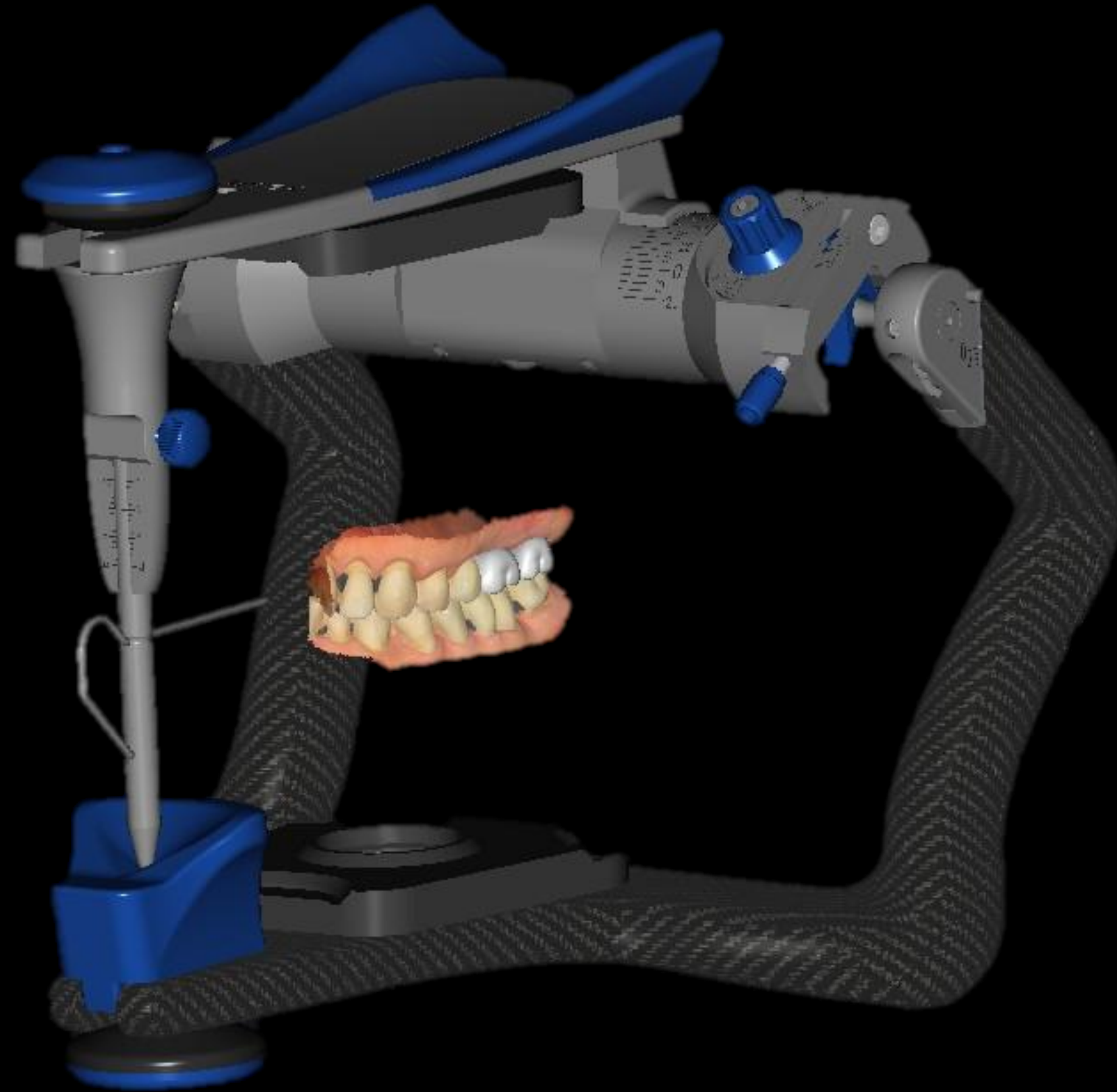Cad Design



Cad Design

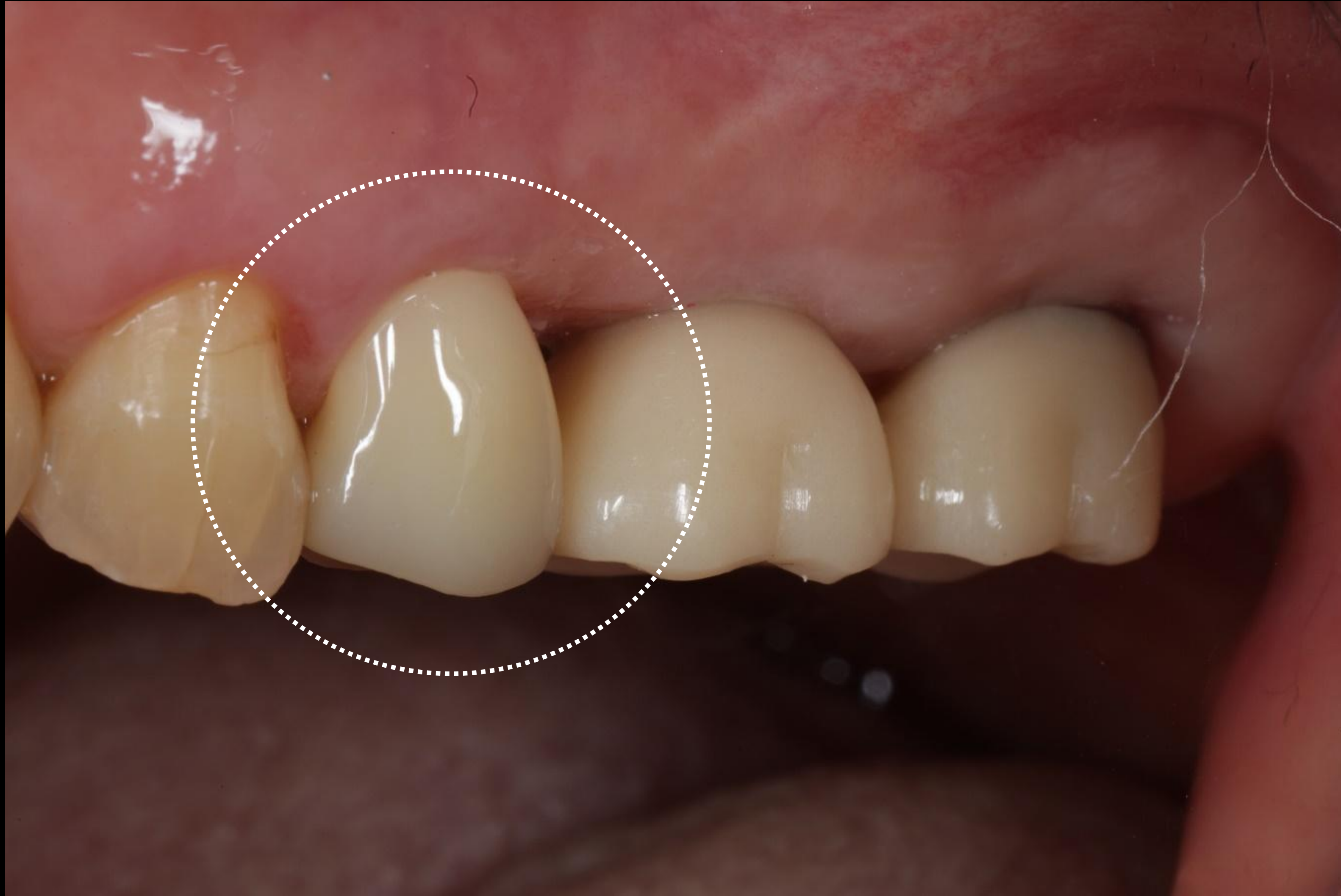


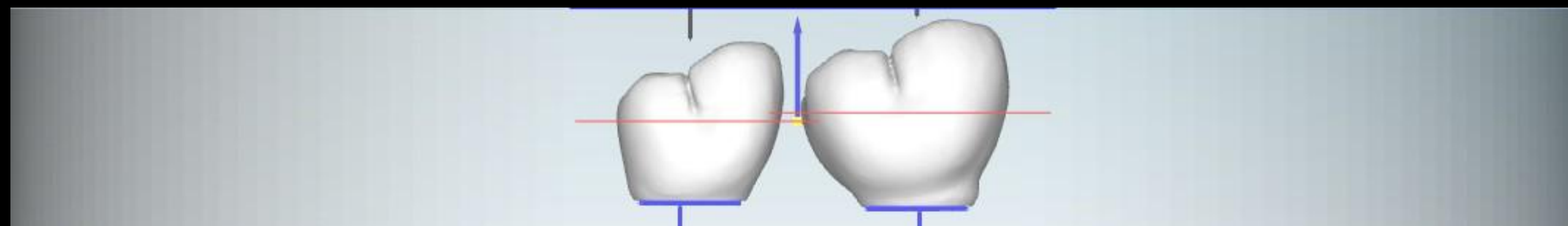
Cad Design



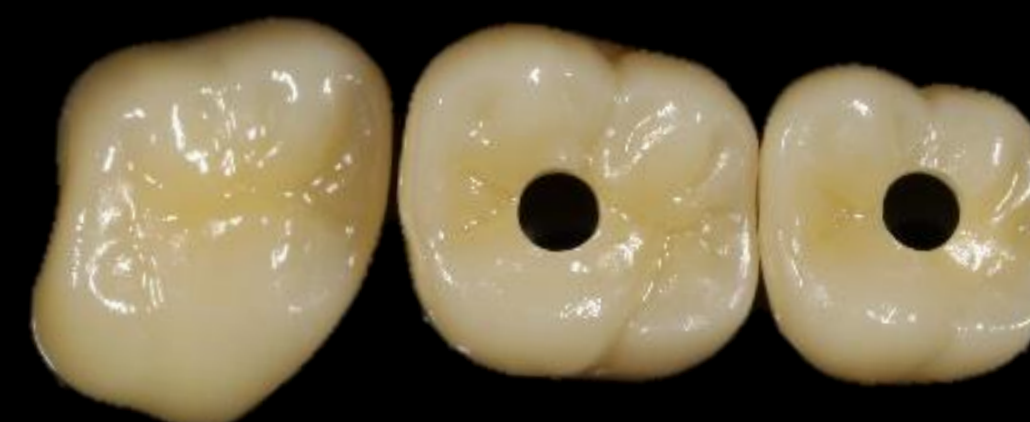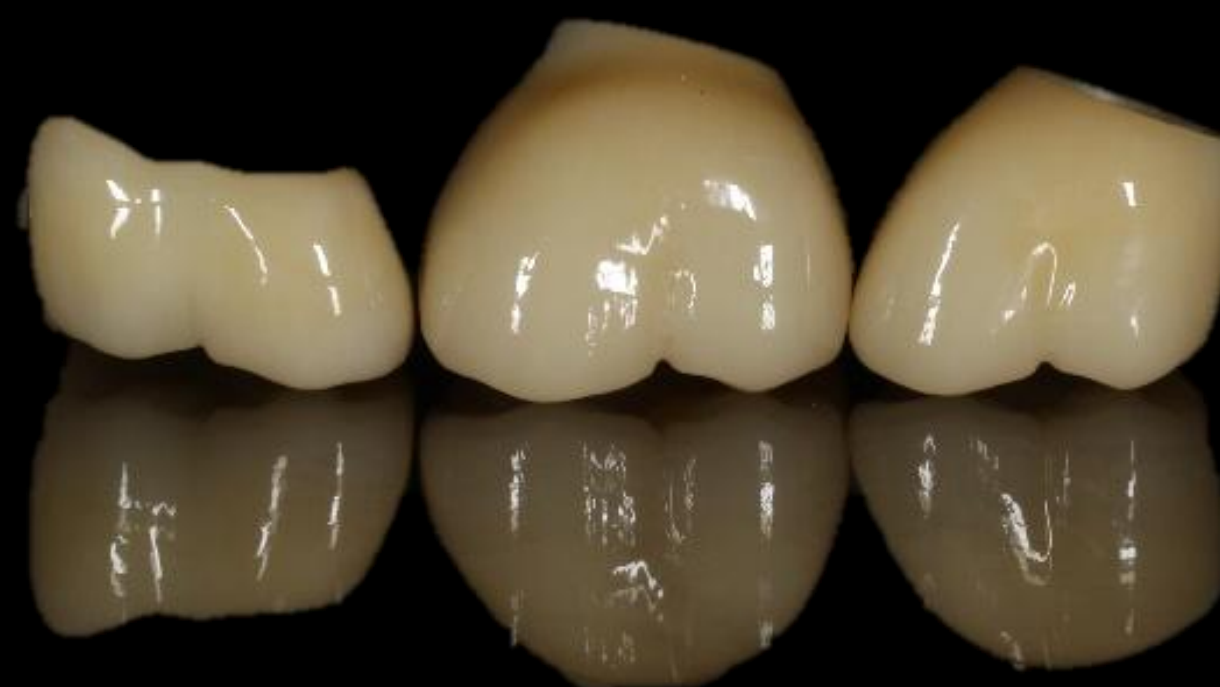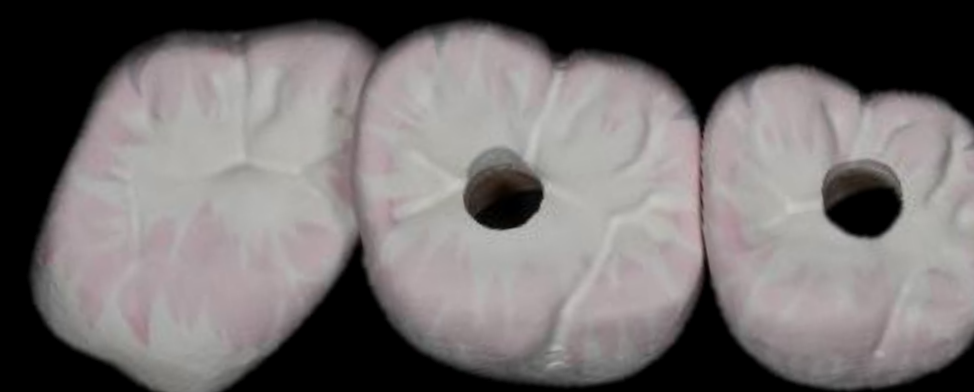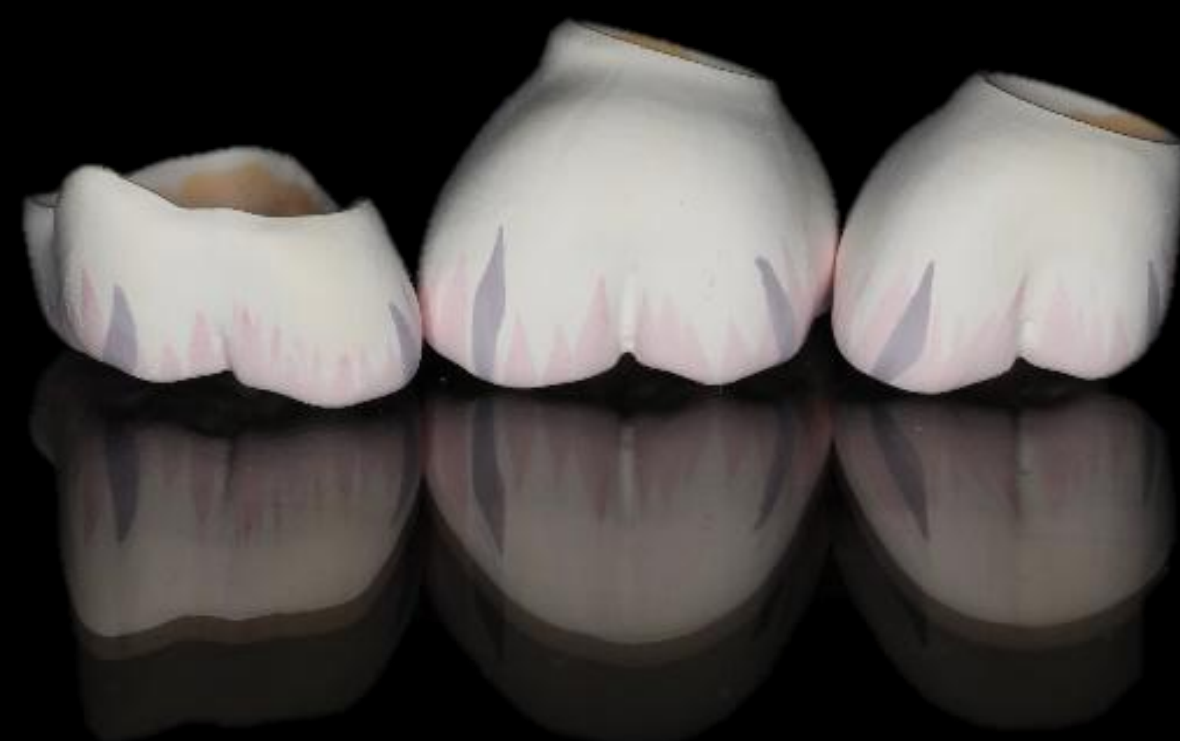Virtual articulator

Shade Taking

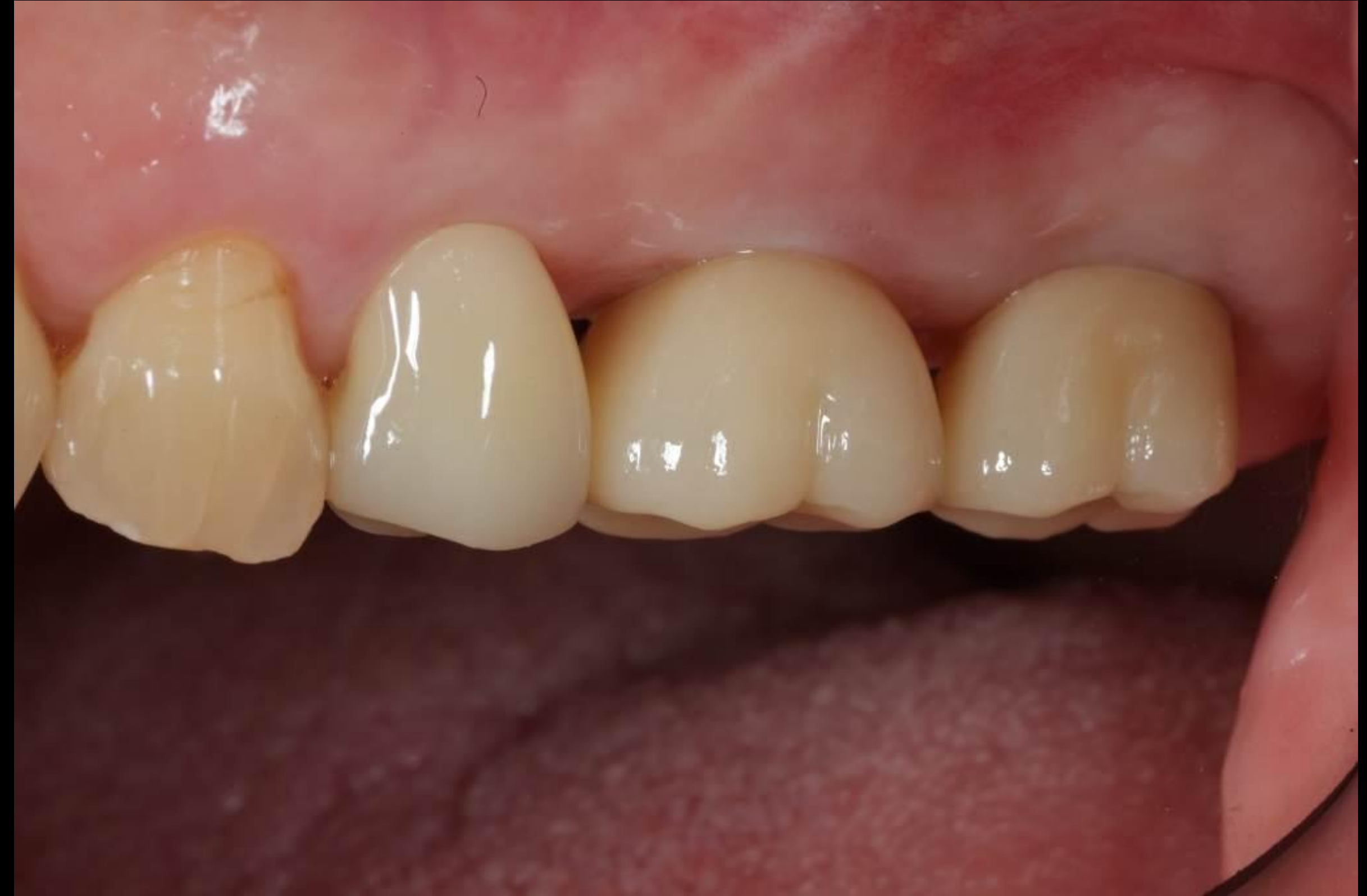
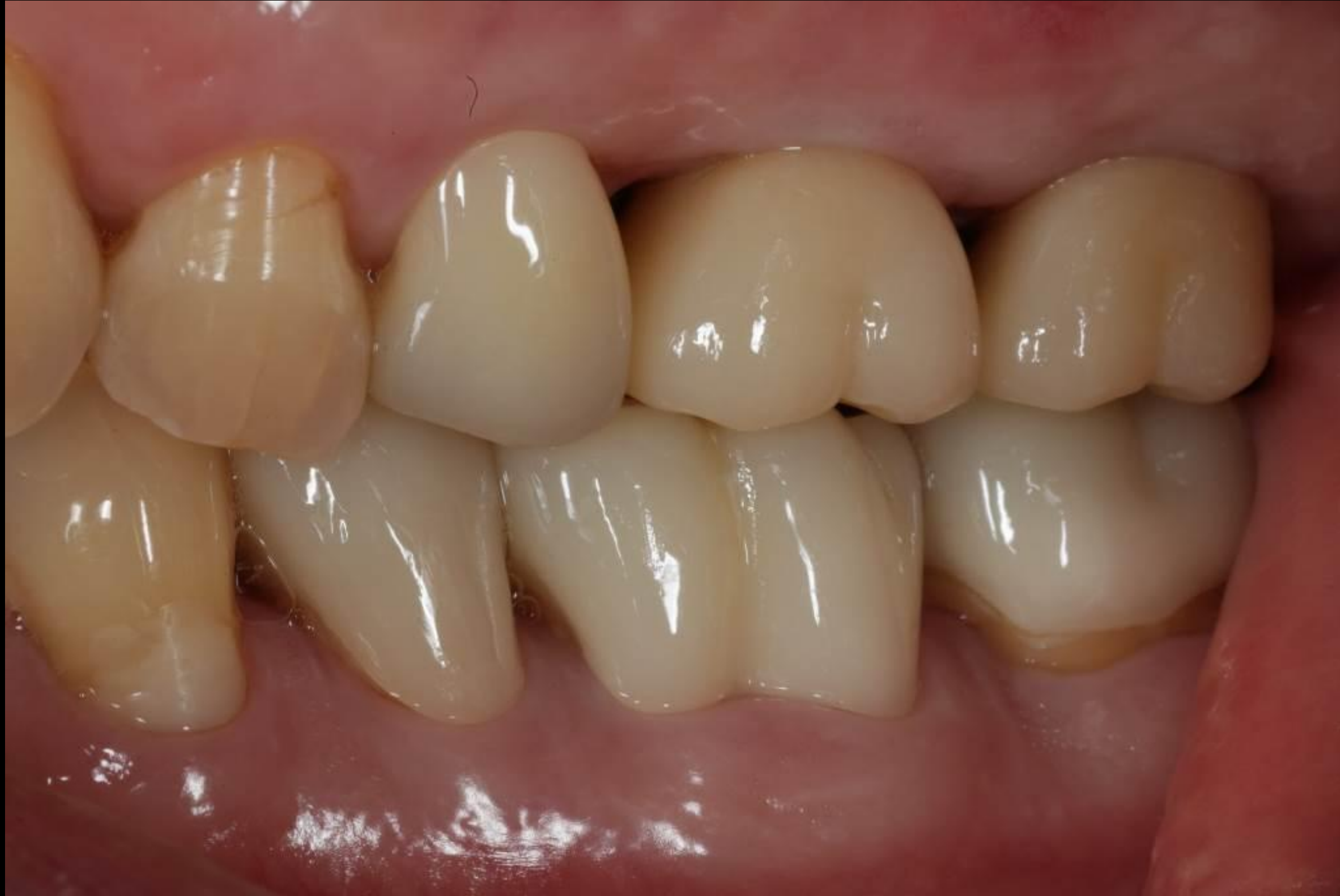


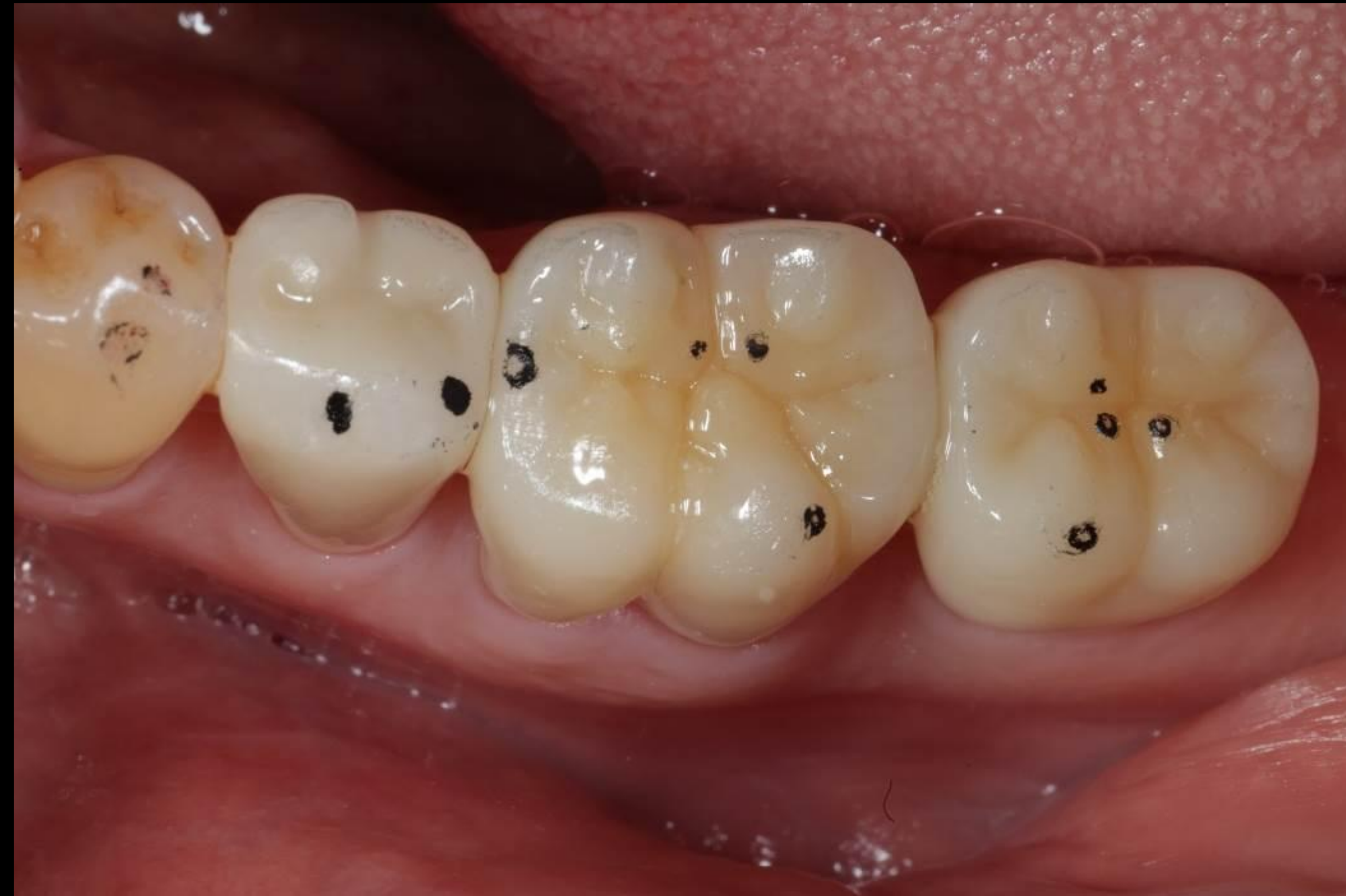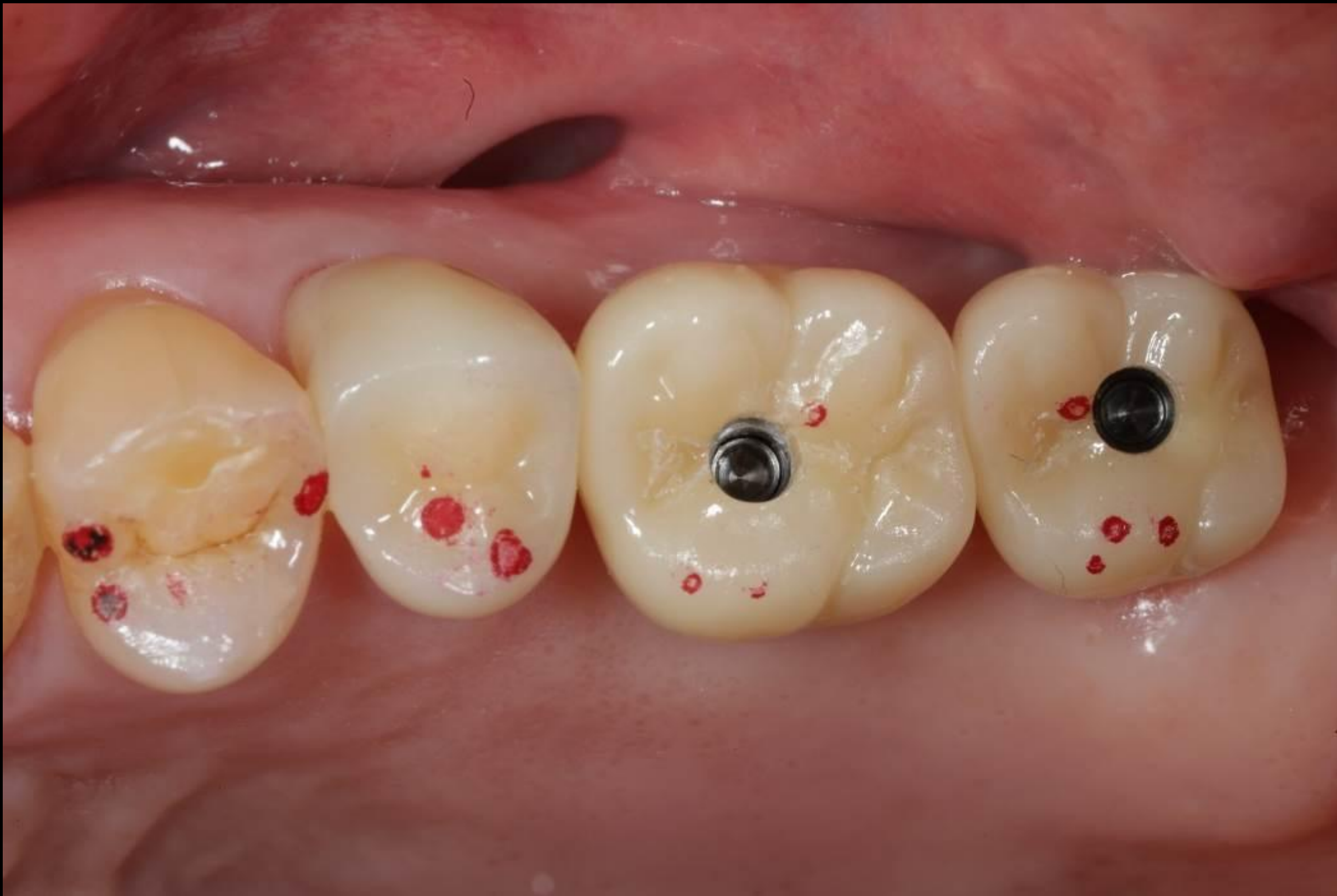bright Mono Block A3

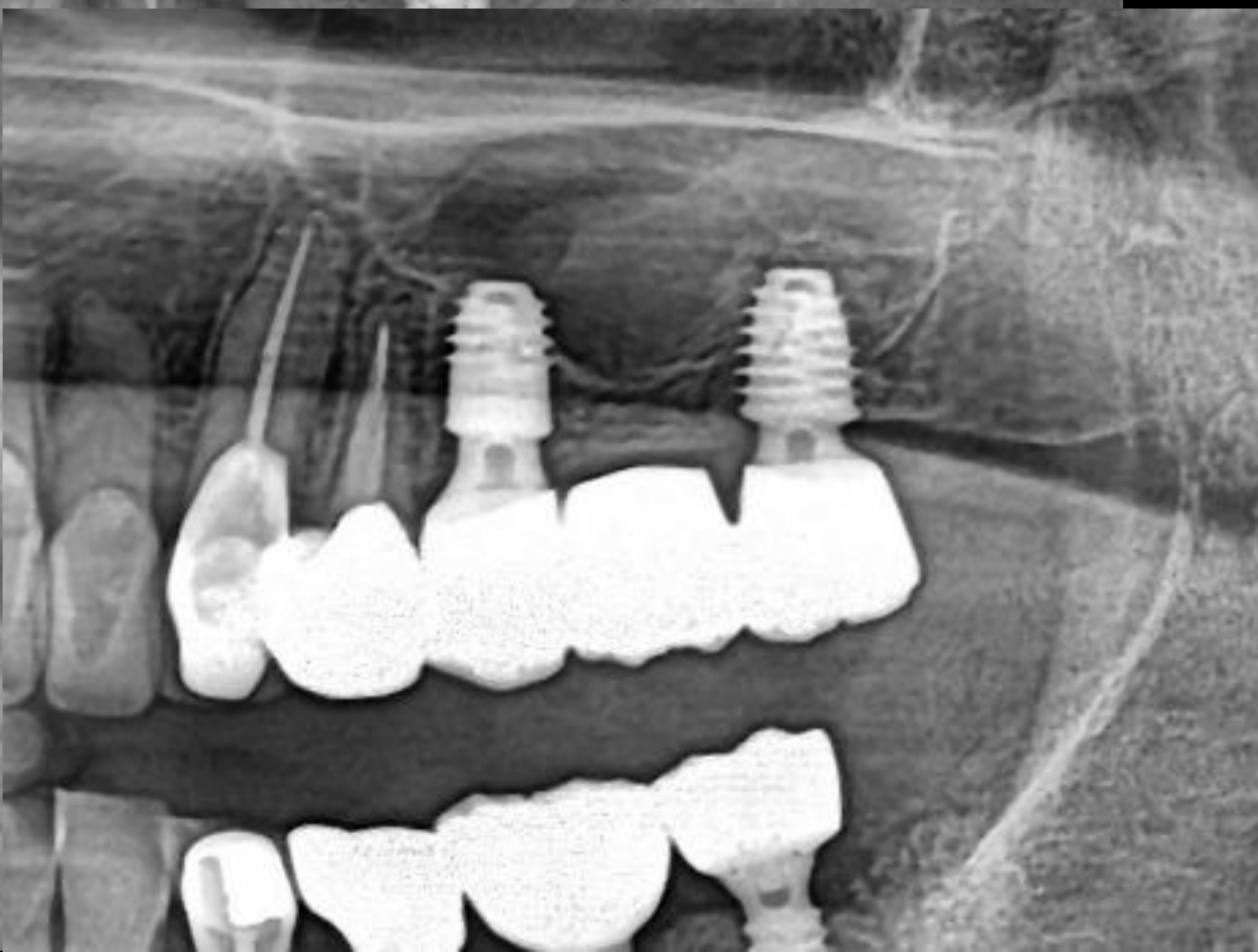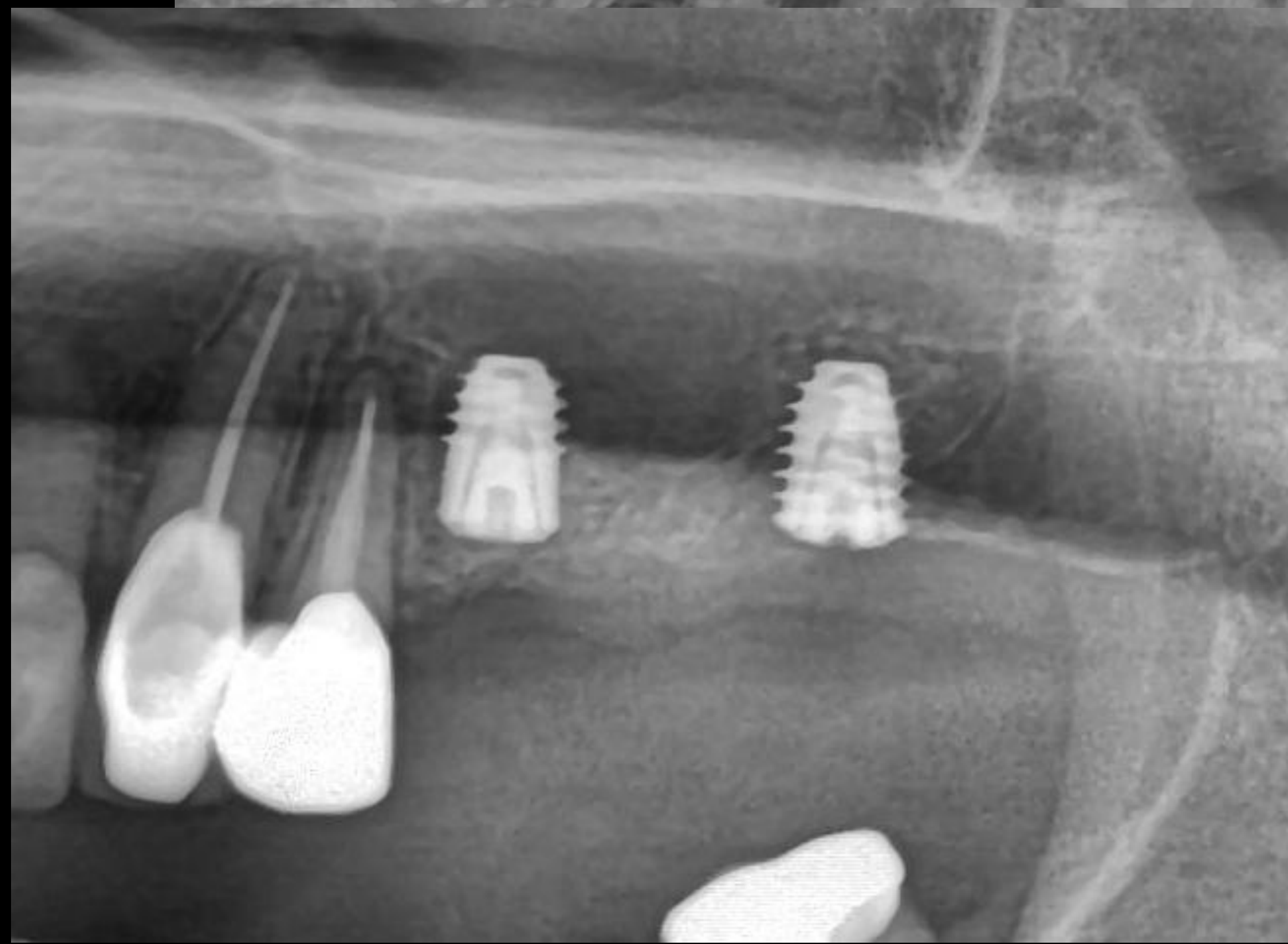

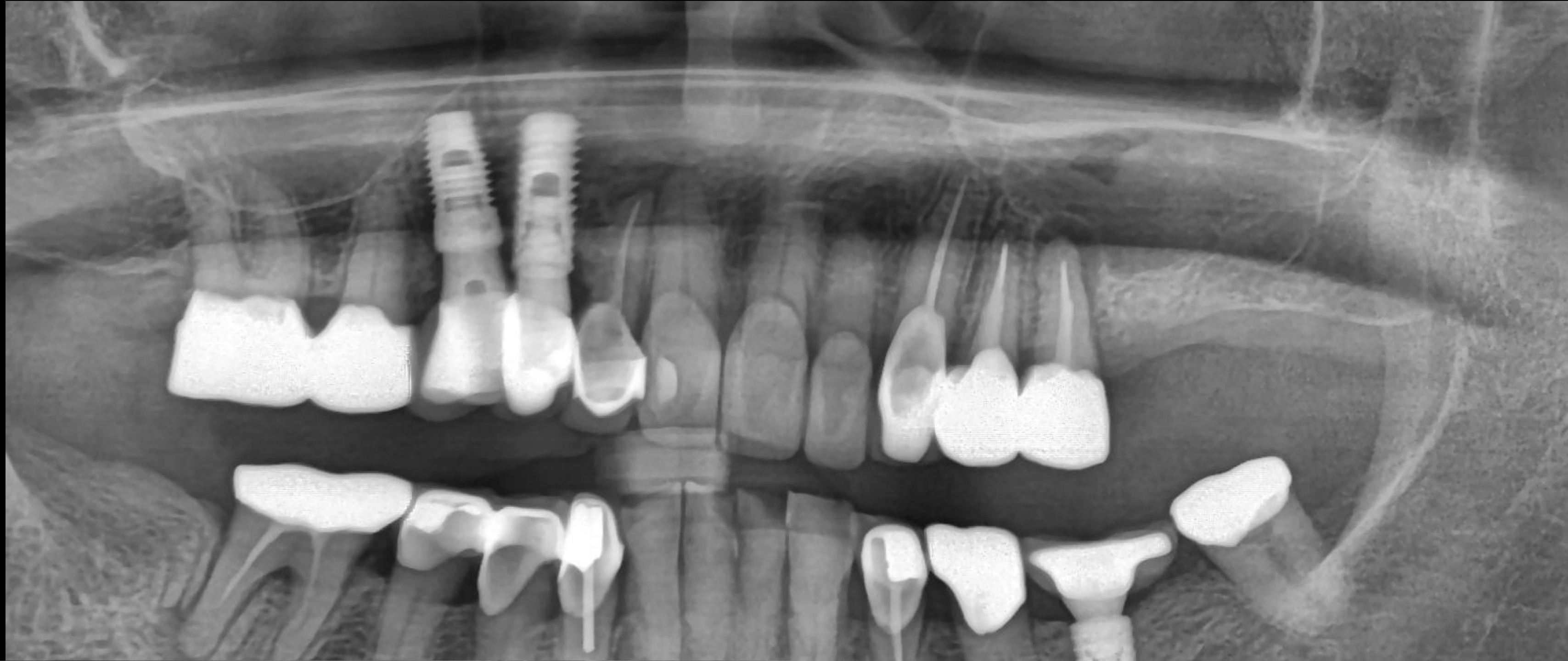
Final Prosthesis

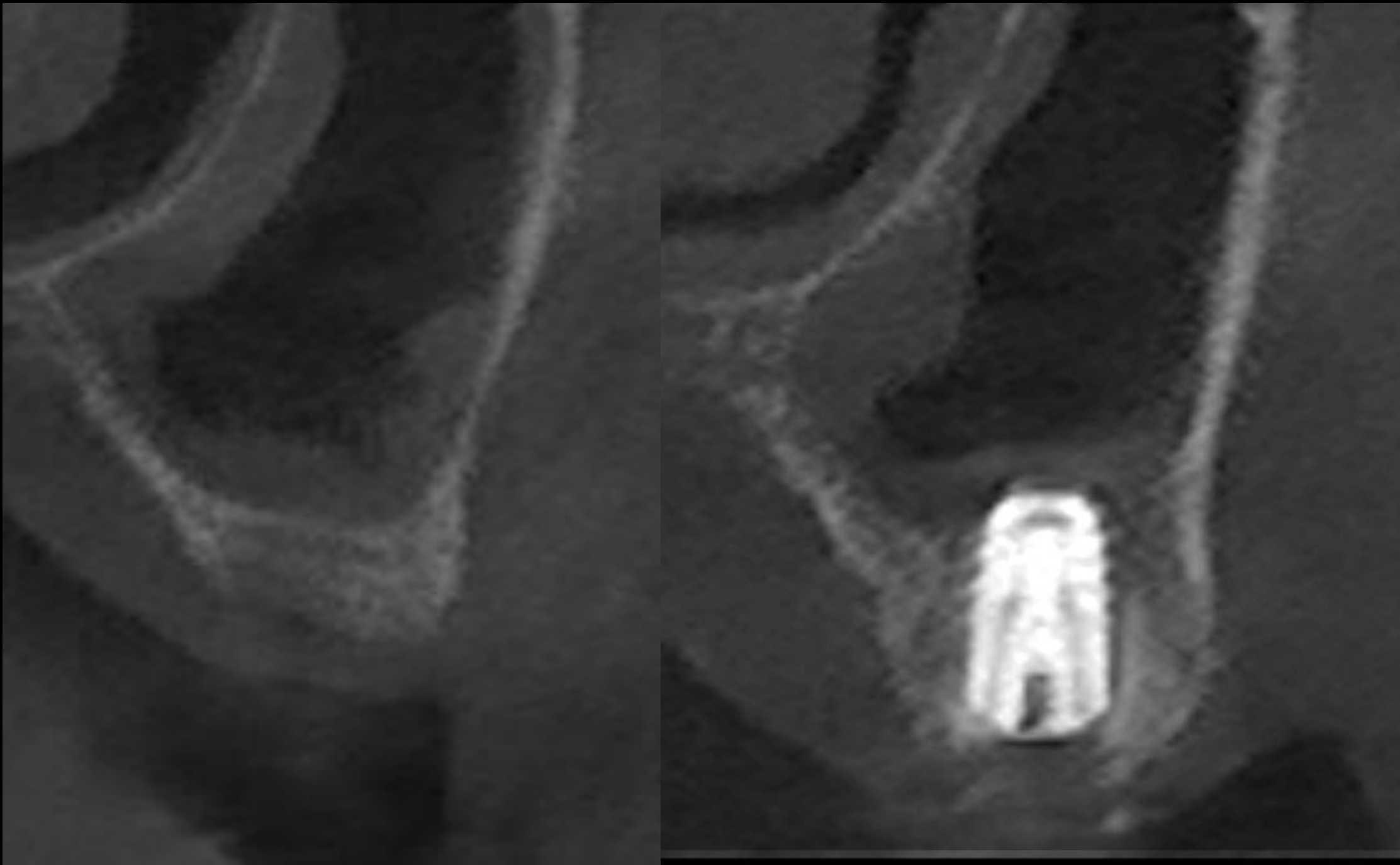

Final Prosthesis

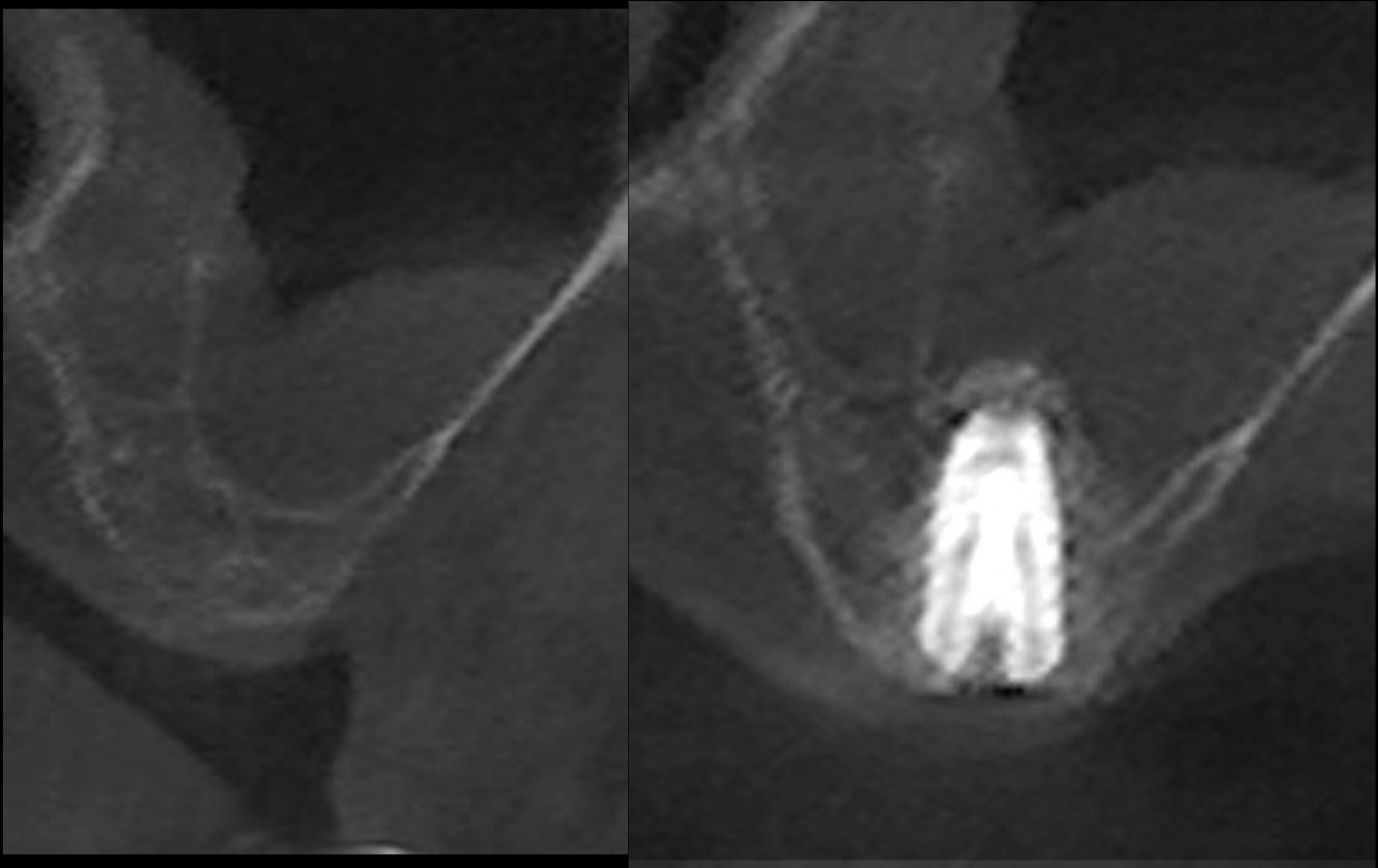




Pre-op (2023-03-09)

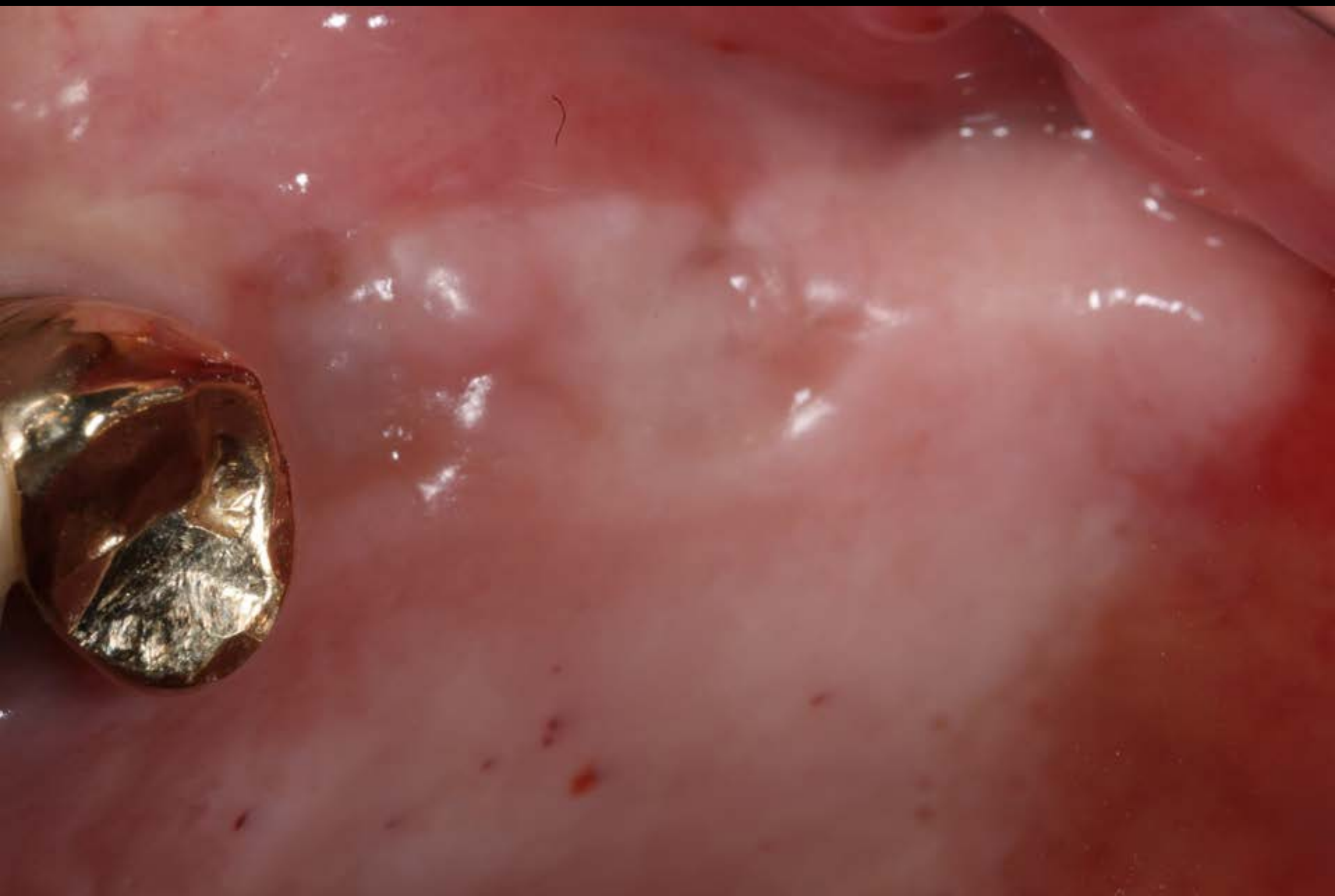

#25

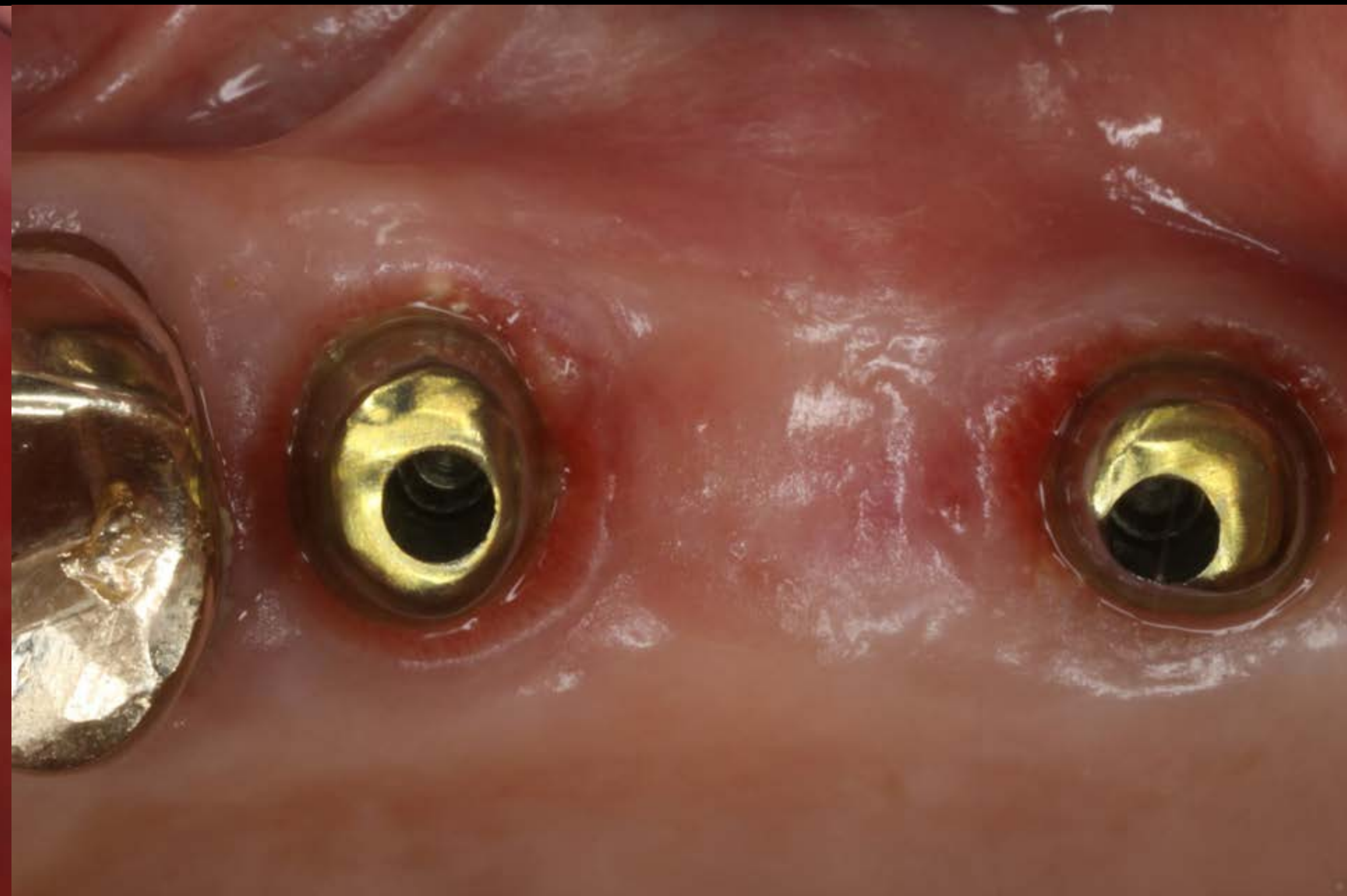

#27

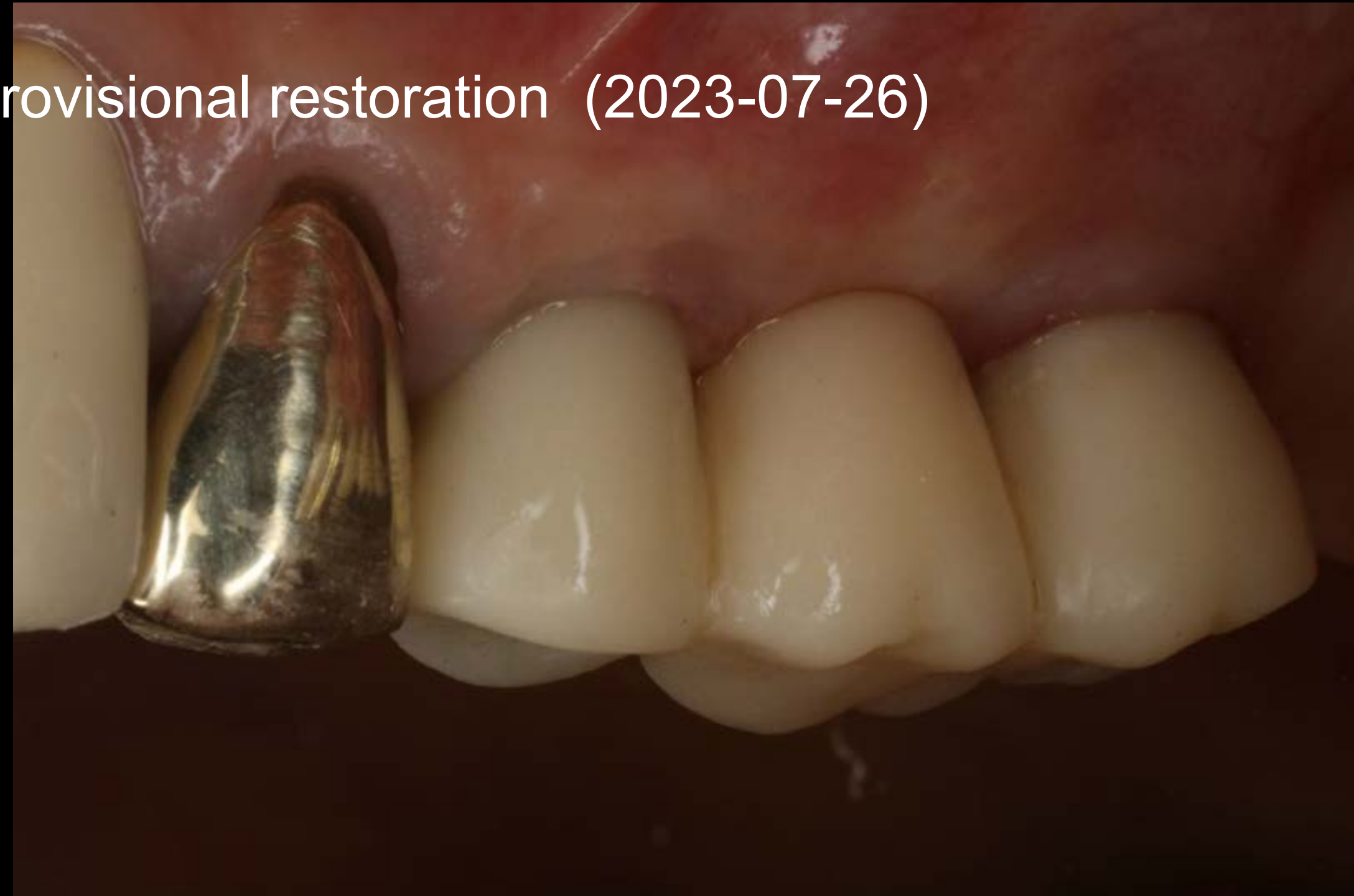Pre-op (2022-03-09)



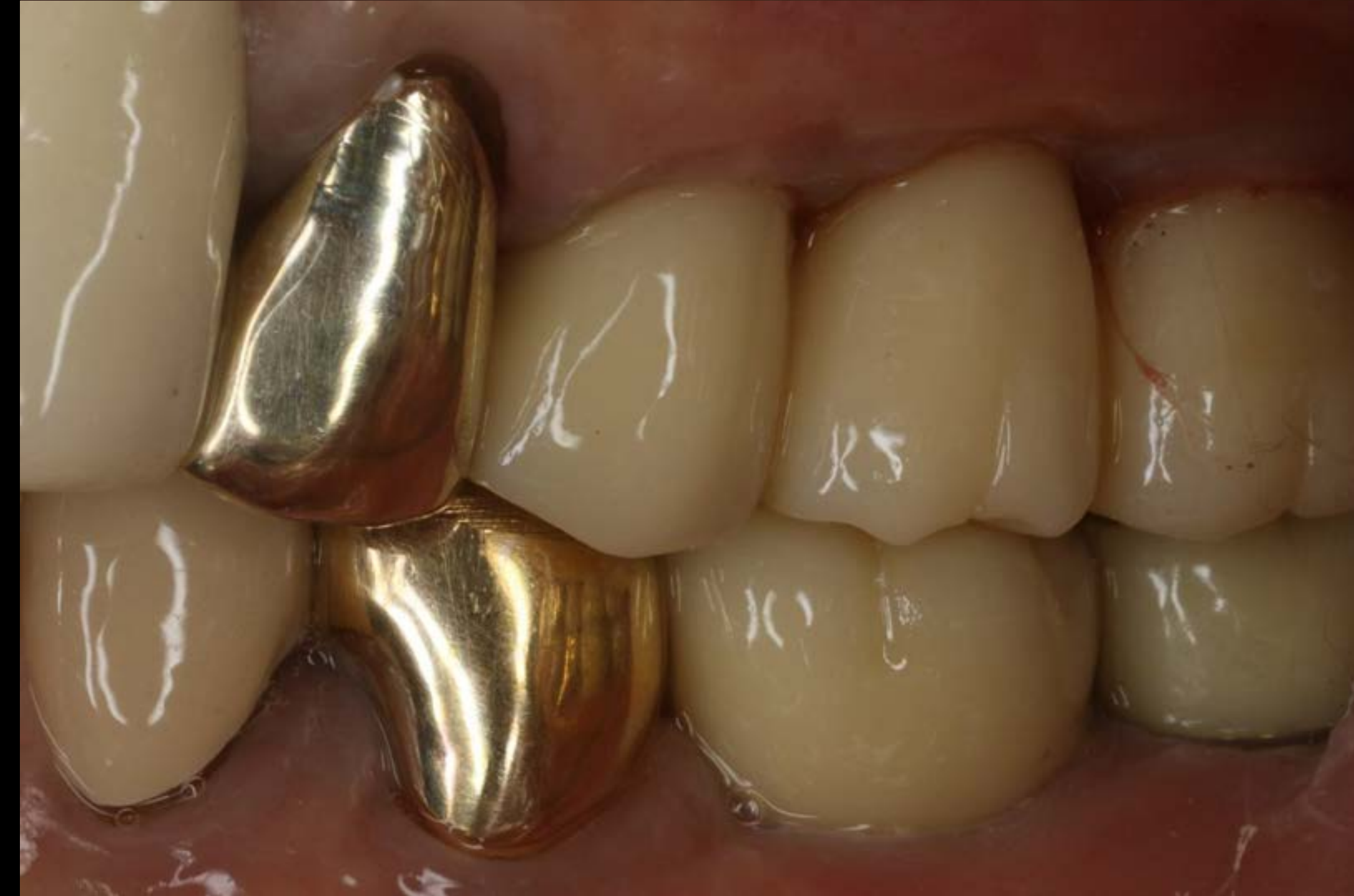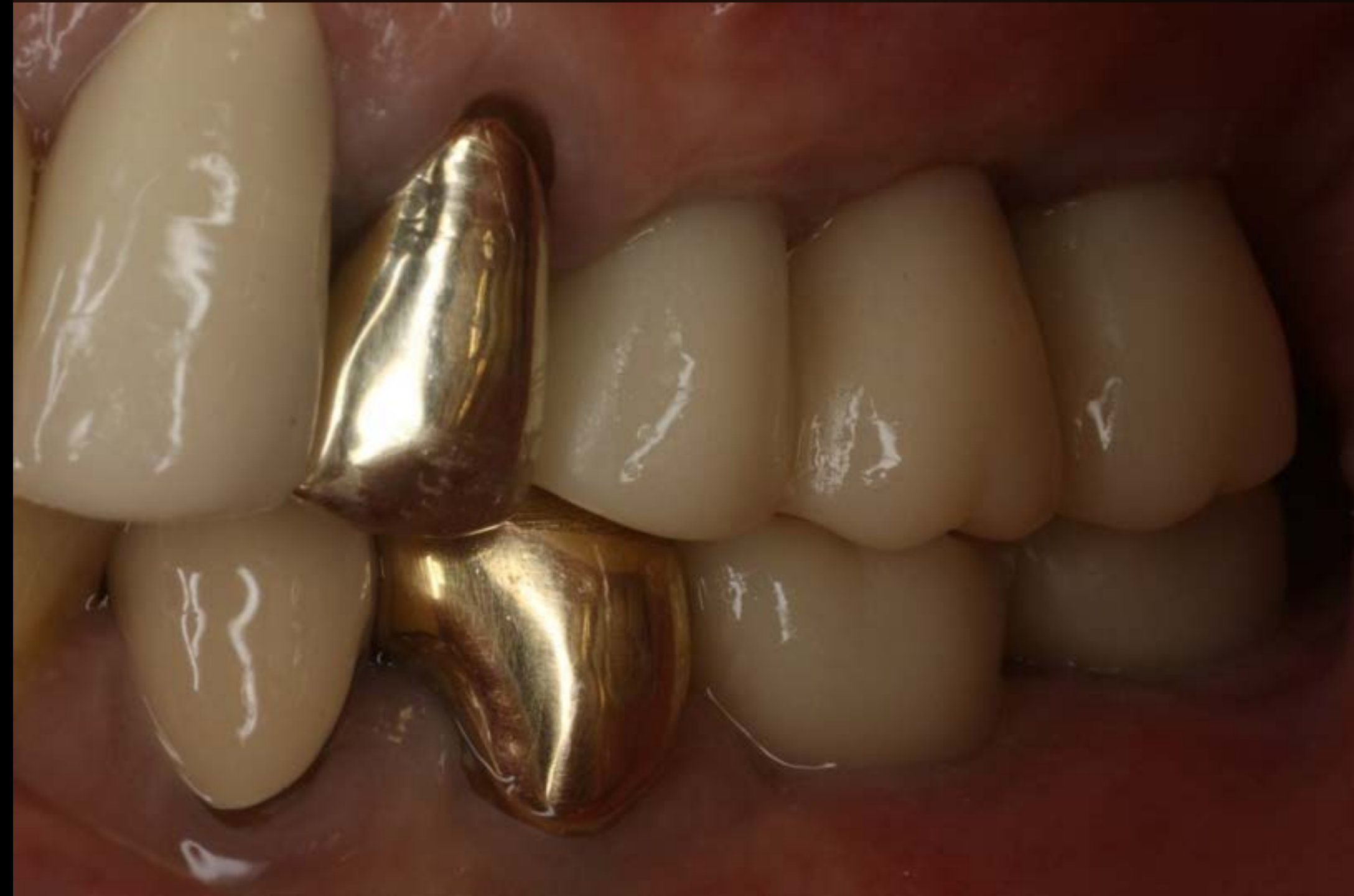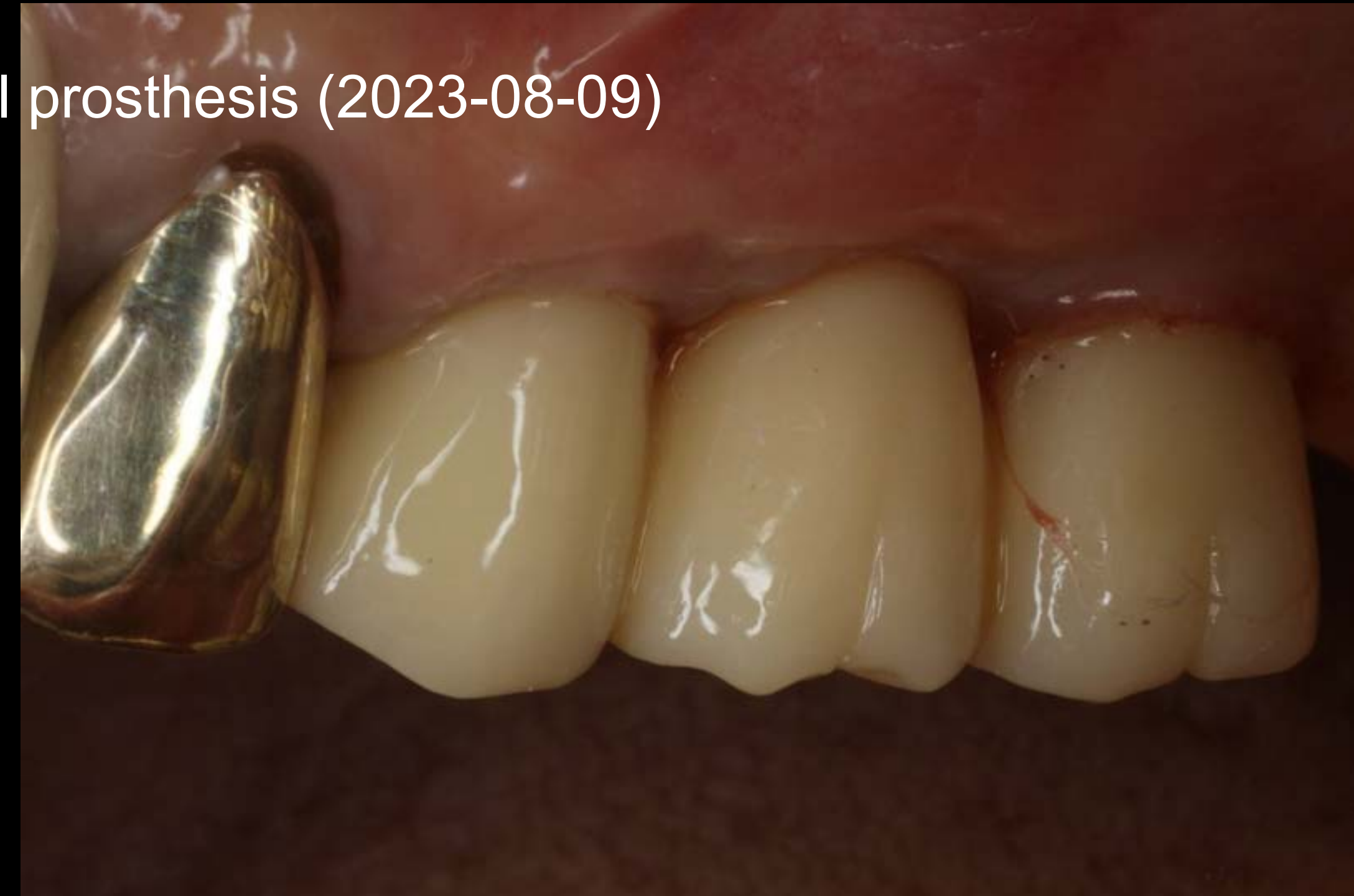Abutment delivery (2023-07-26)



Provisional restoration (2023-07-26)



Final prosthesis (2023-08-09)



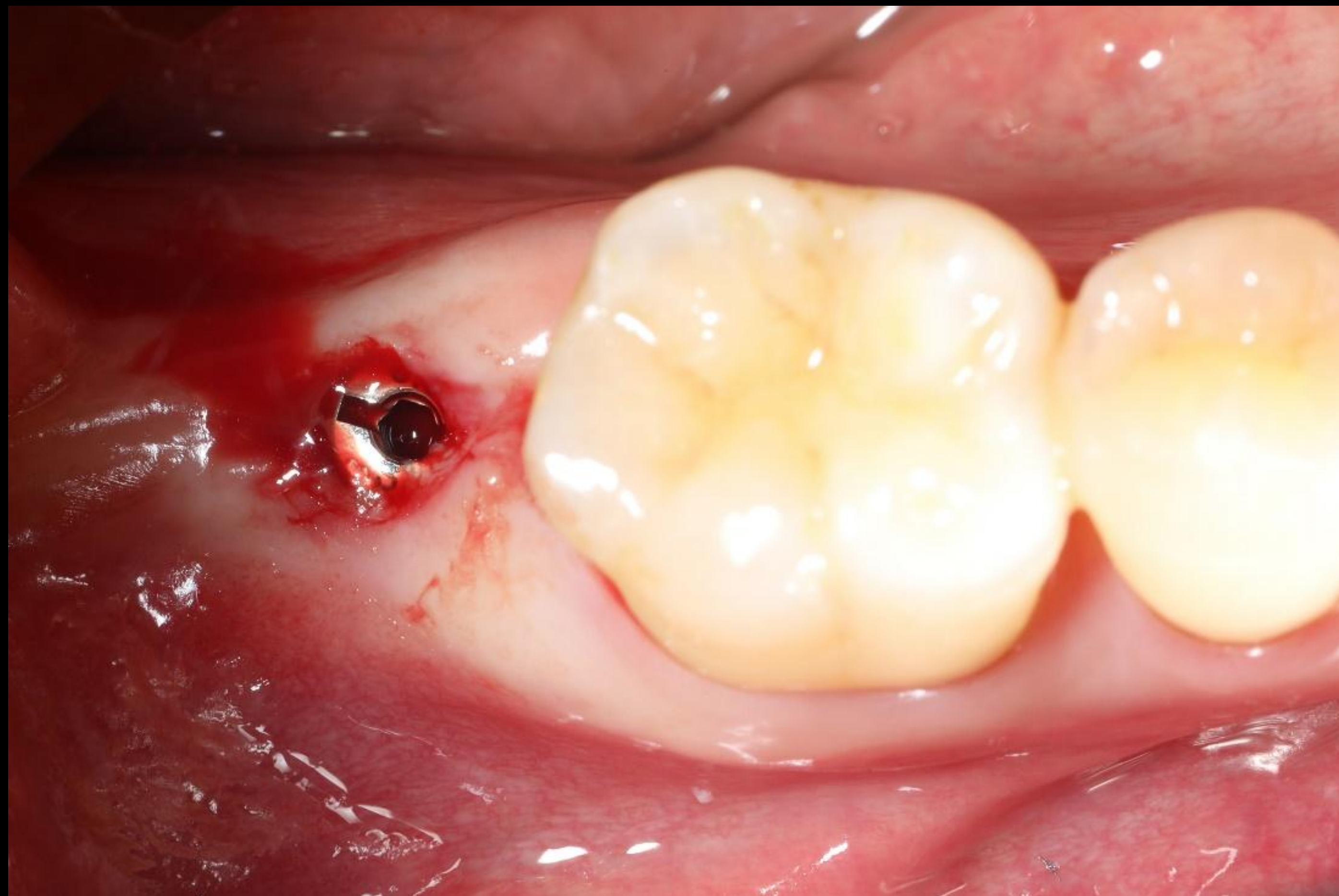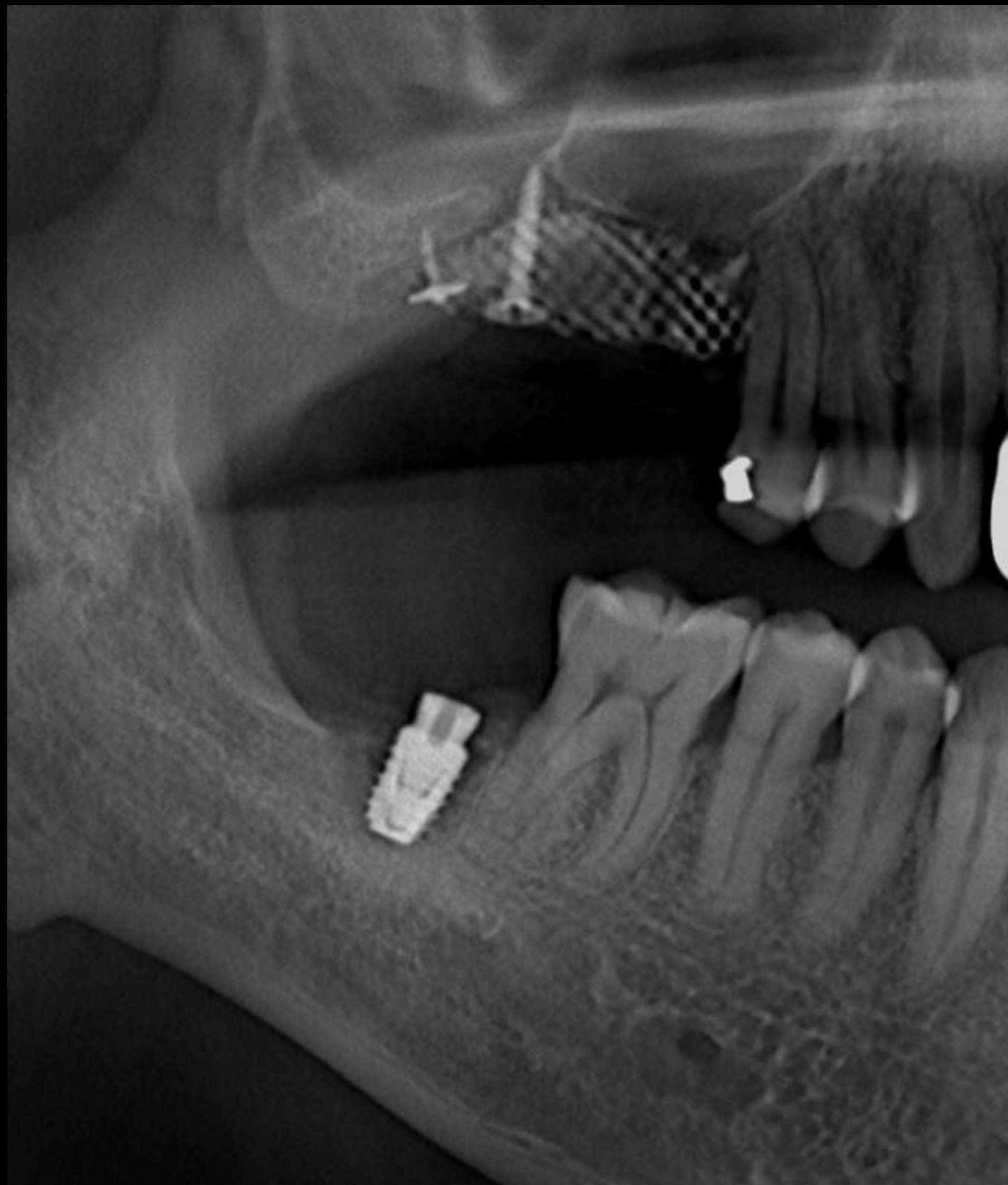
**Overcoming Sinus perforation
in Sinus Septum case**

**** 232p Surgery VOD 3**

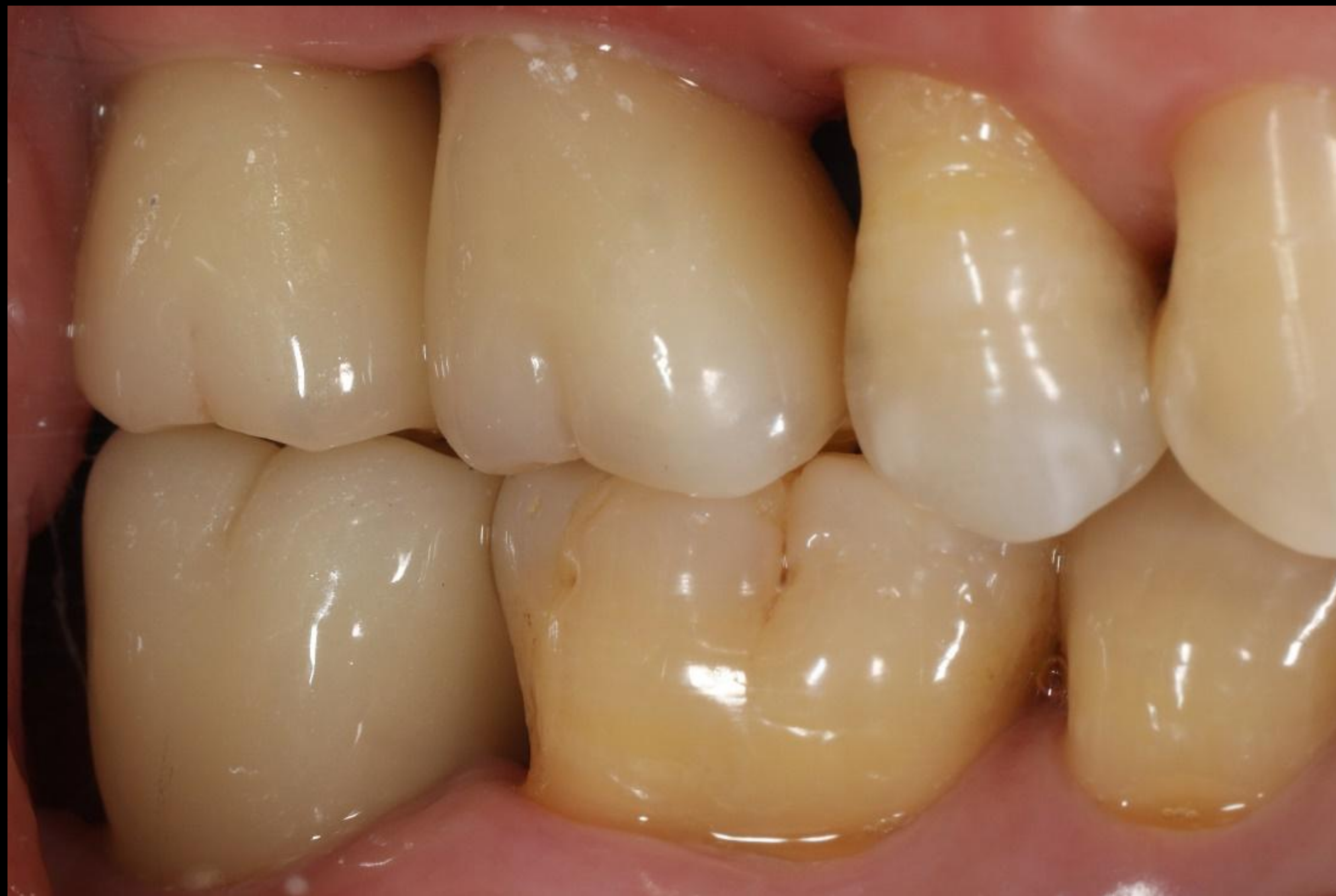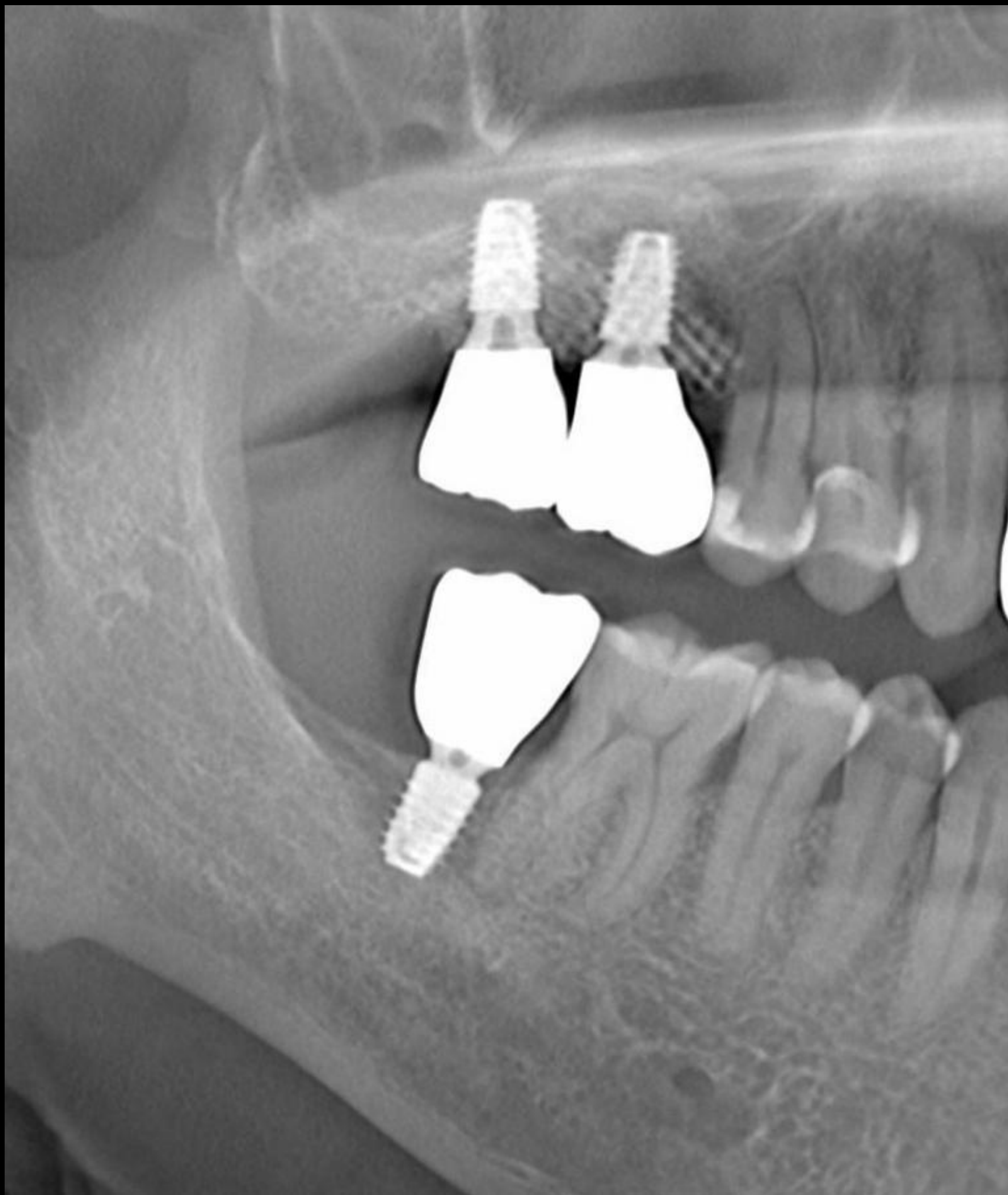
**Simple & Clear Lateral approach
with DASK Simple**

**** 232p Surgery VOD 4**

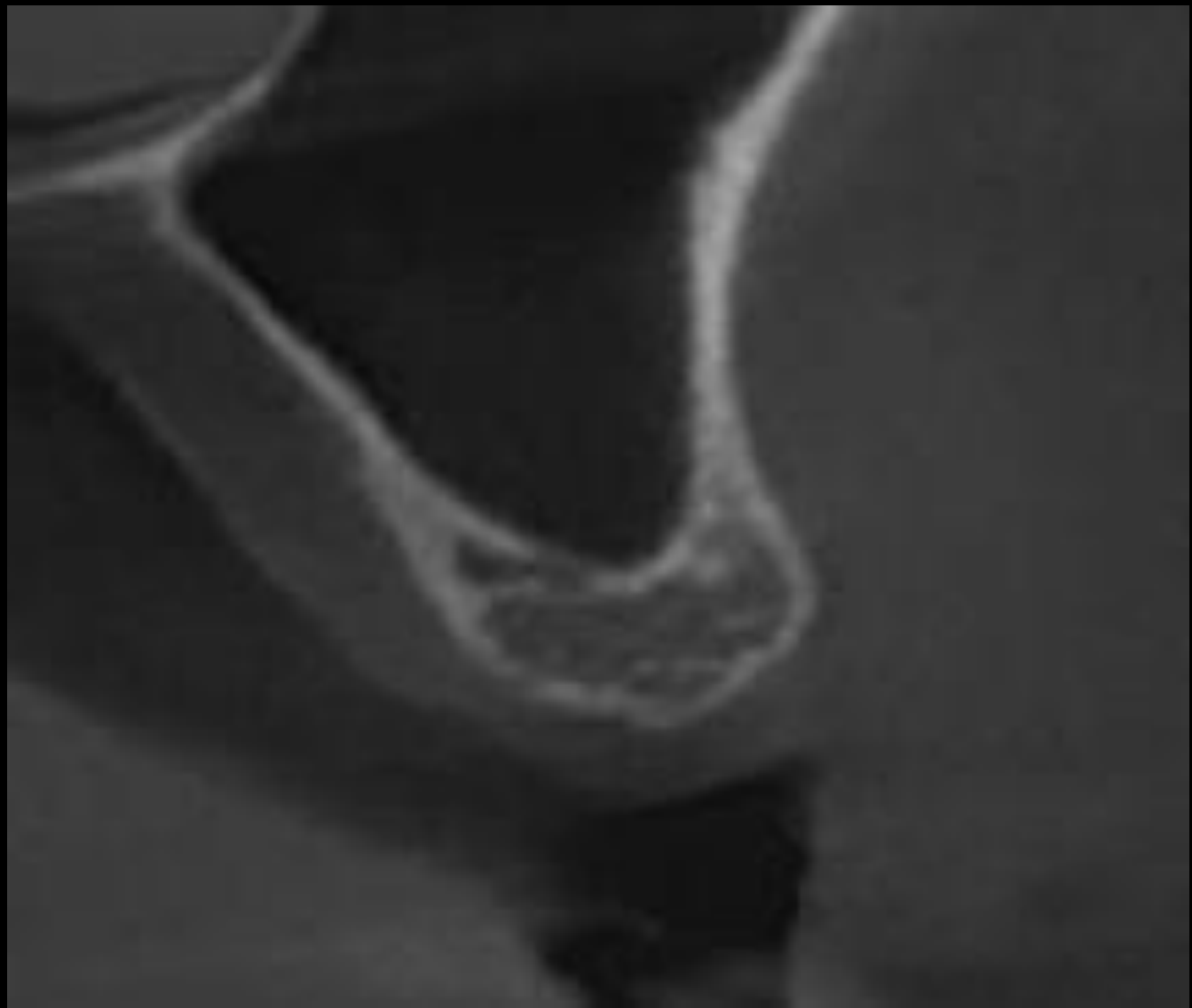
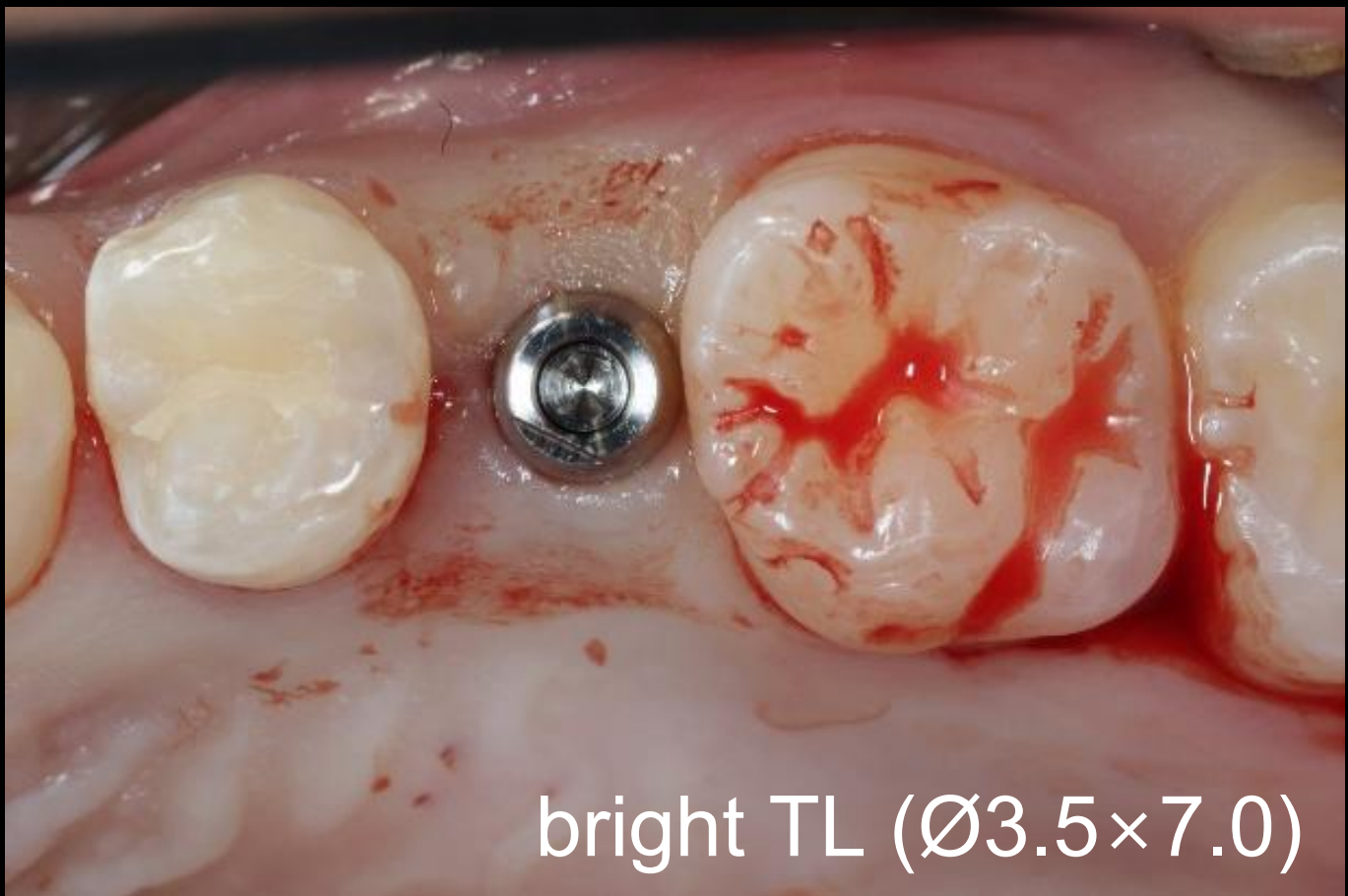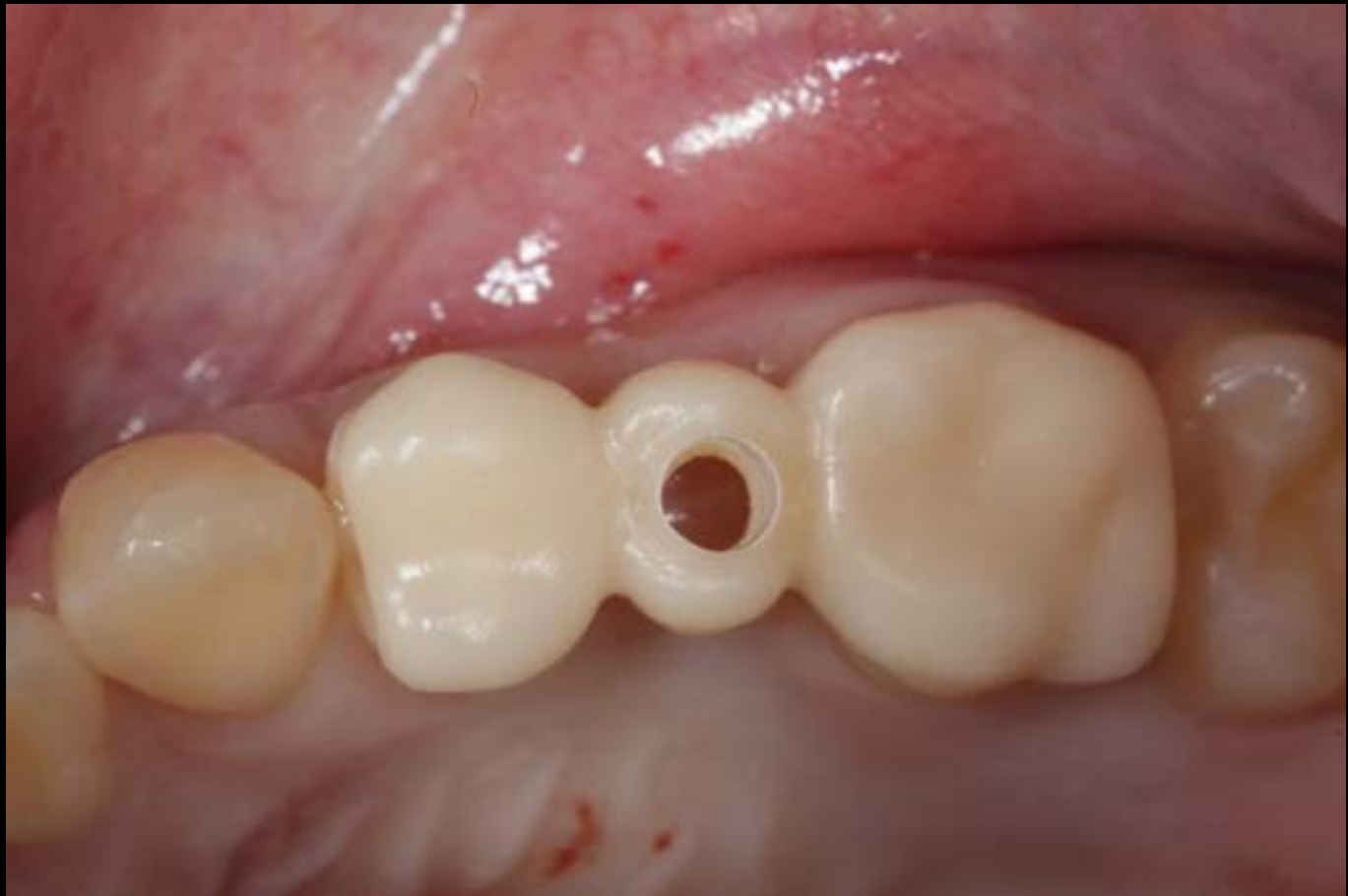
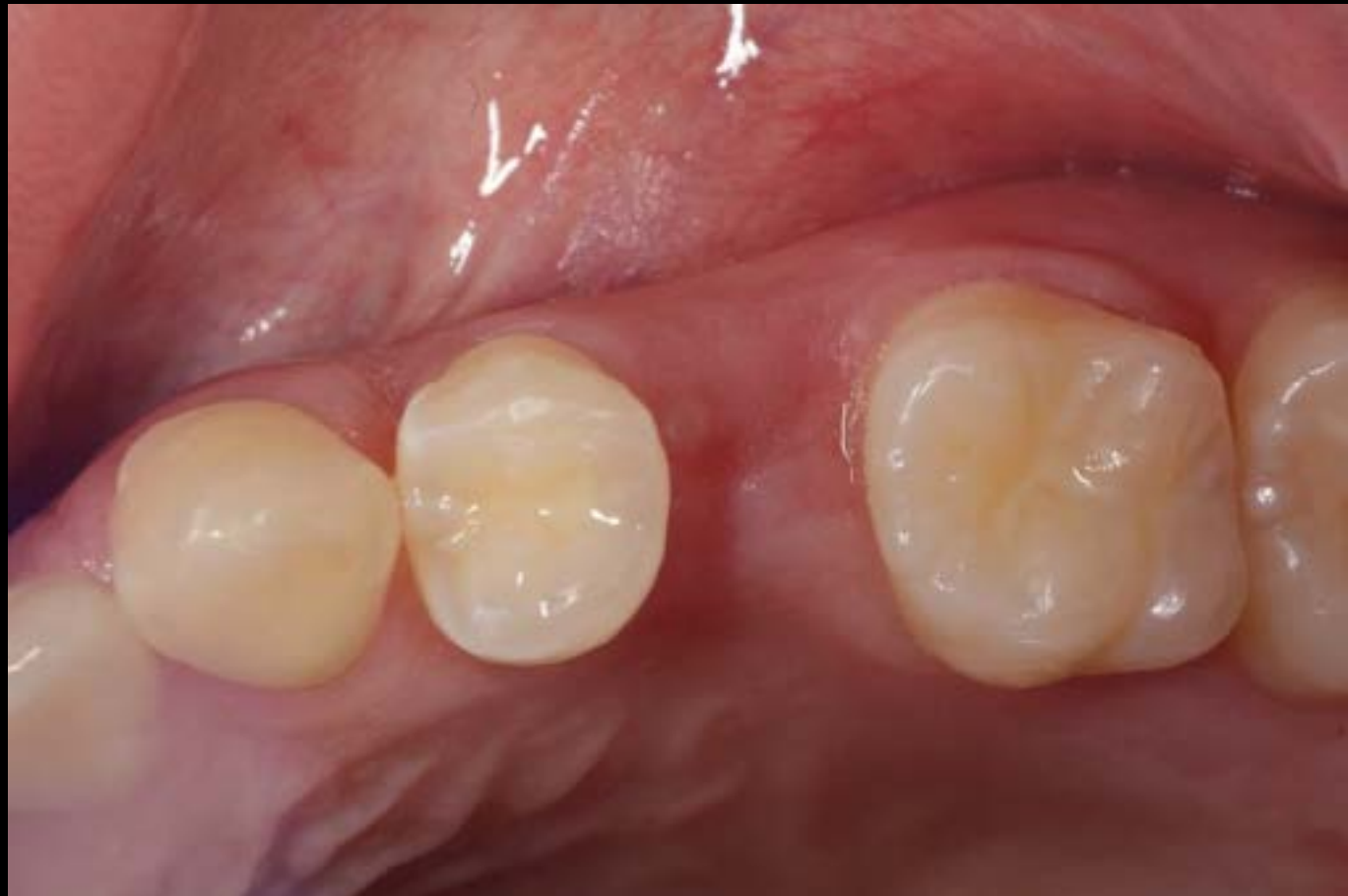Post-op (2018-11-19)



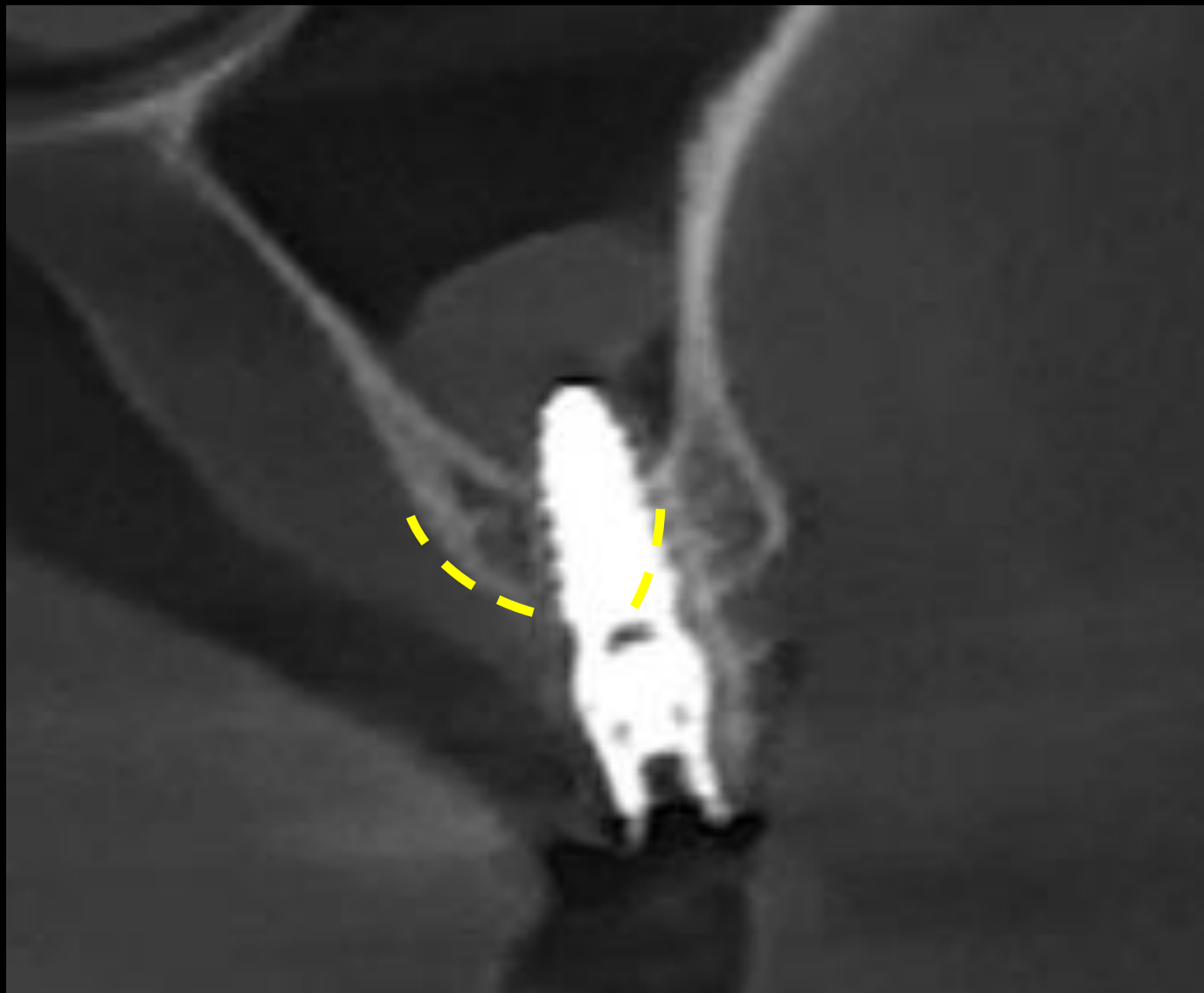Final prosthesis (2020-07-23)



#15 I.S & bicortical (collagen graft2)



Pre-OP

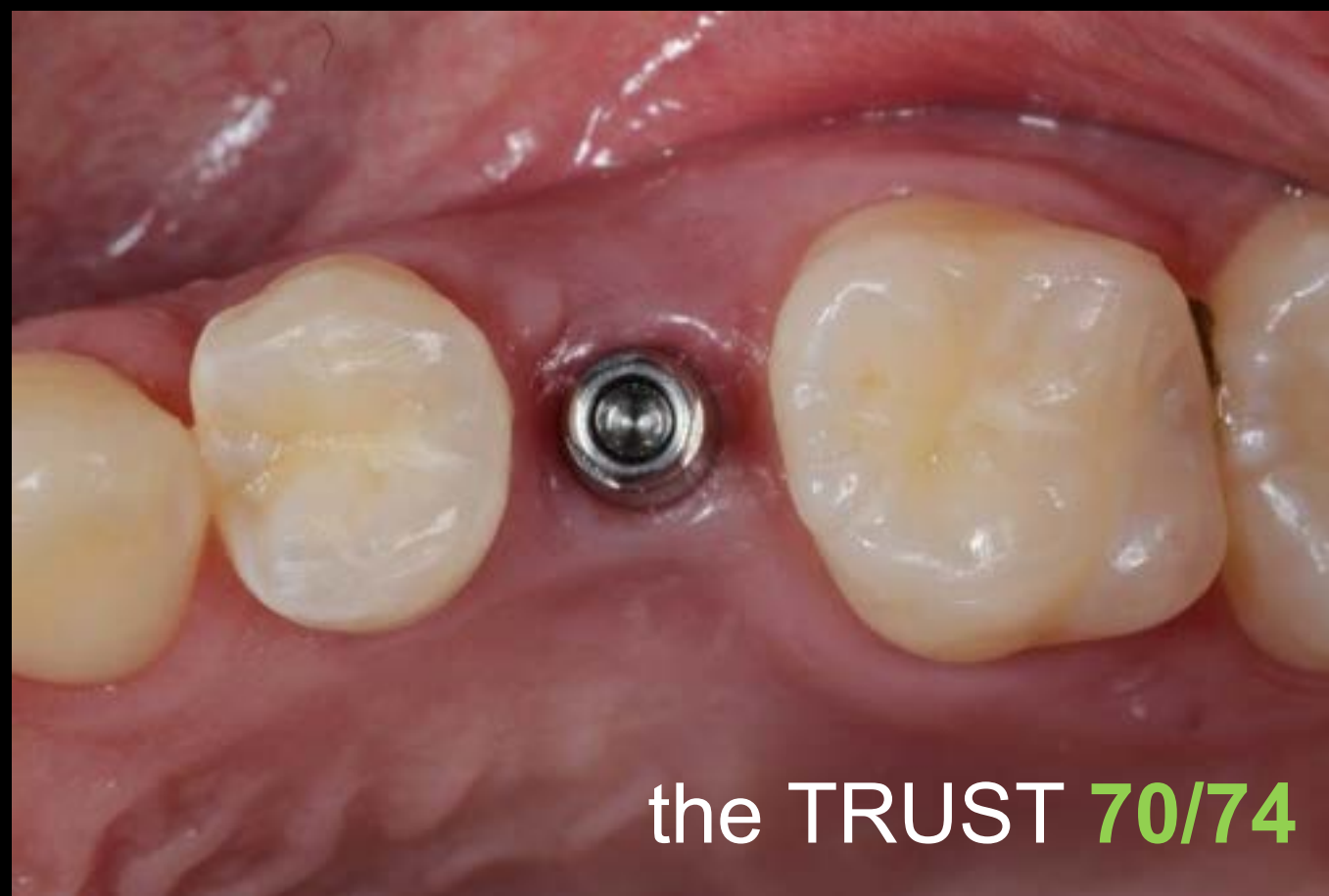
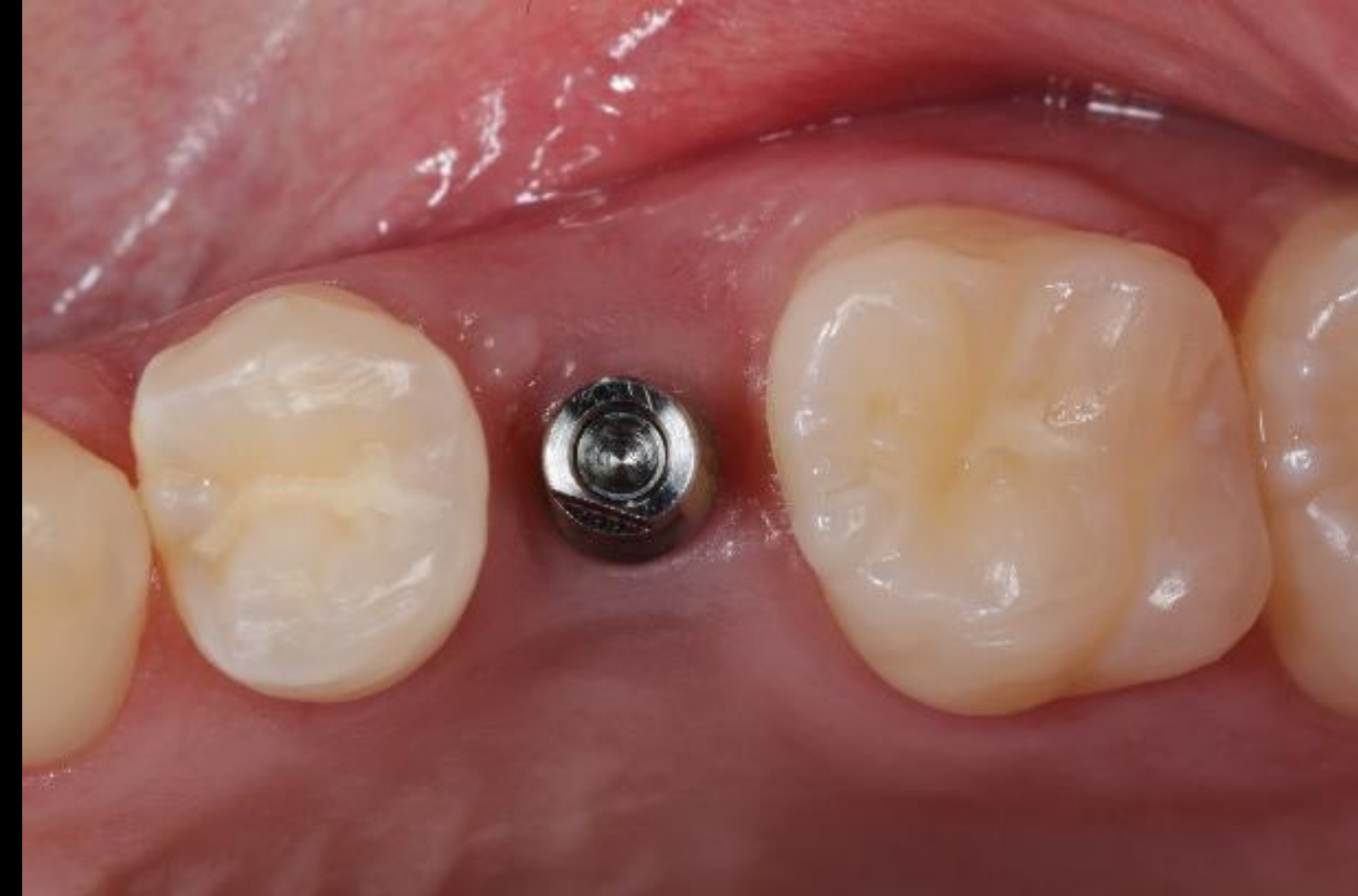
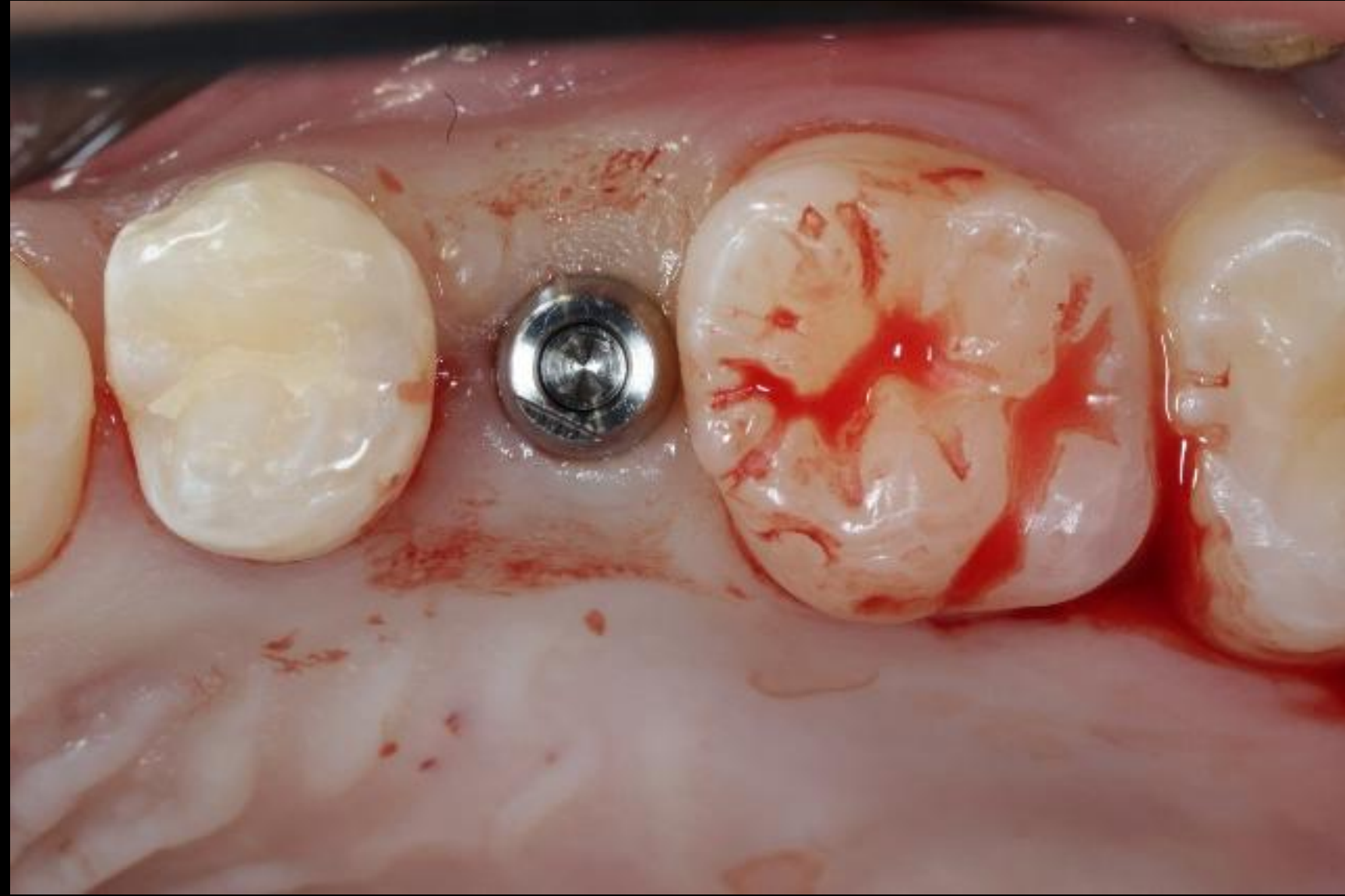Post-OP

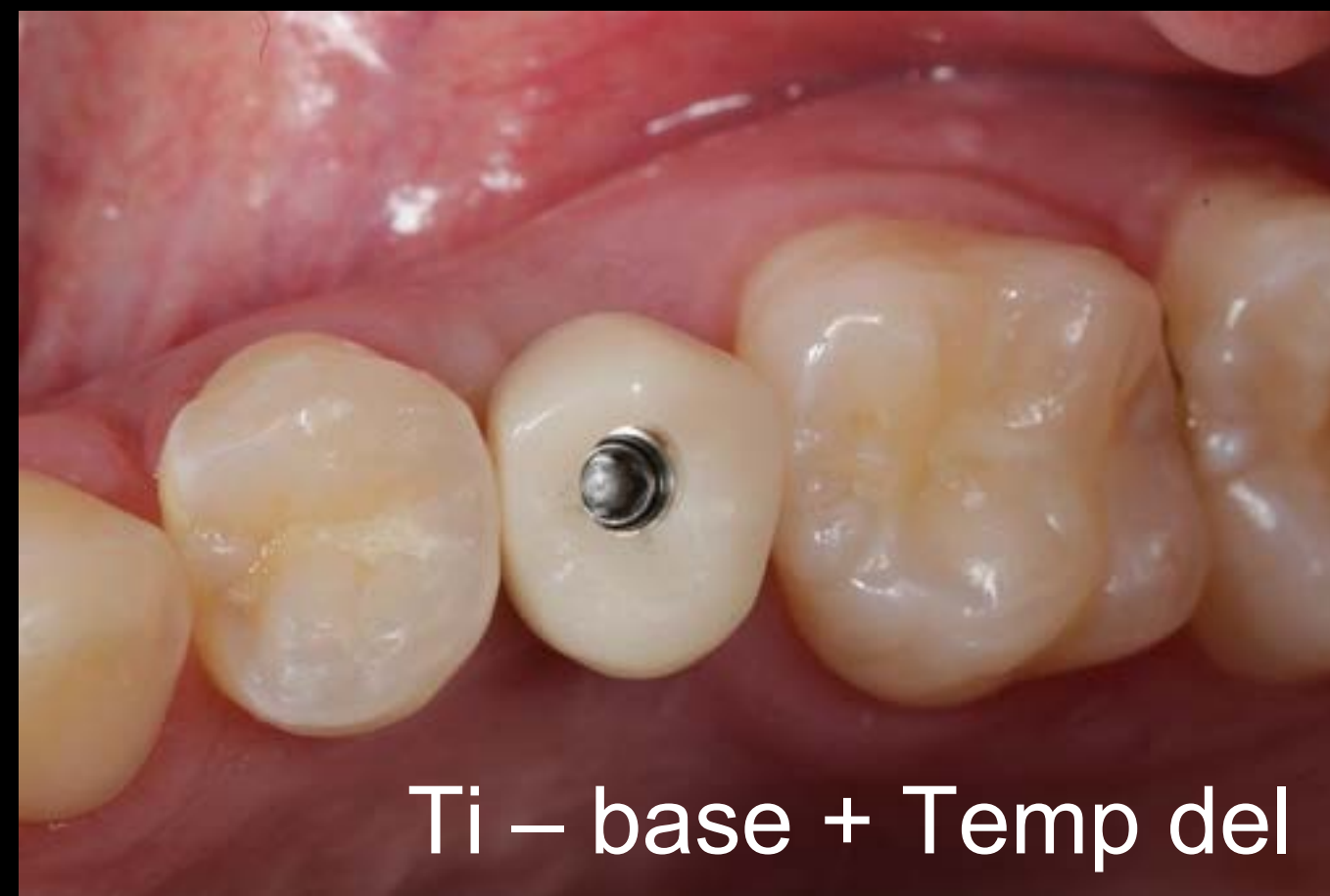

I.S 후 6M 뒤 CT

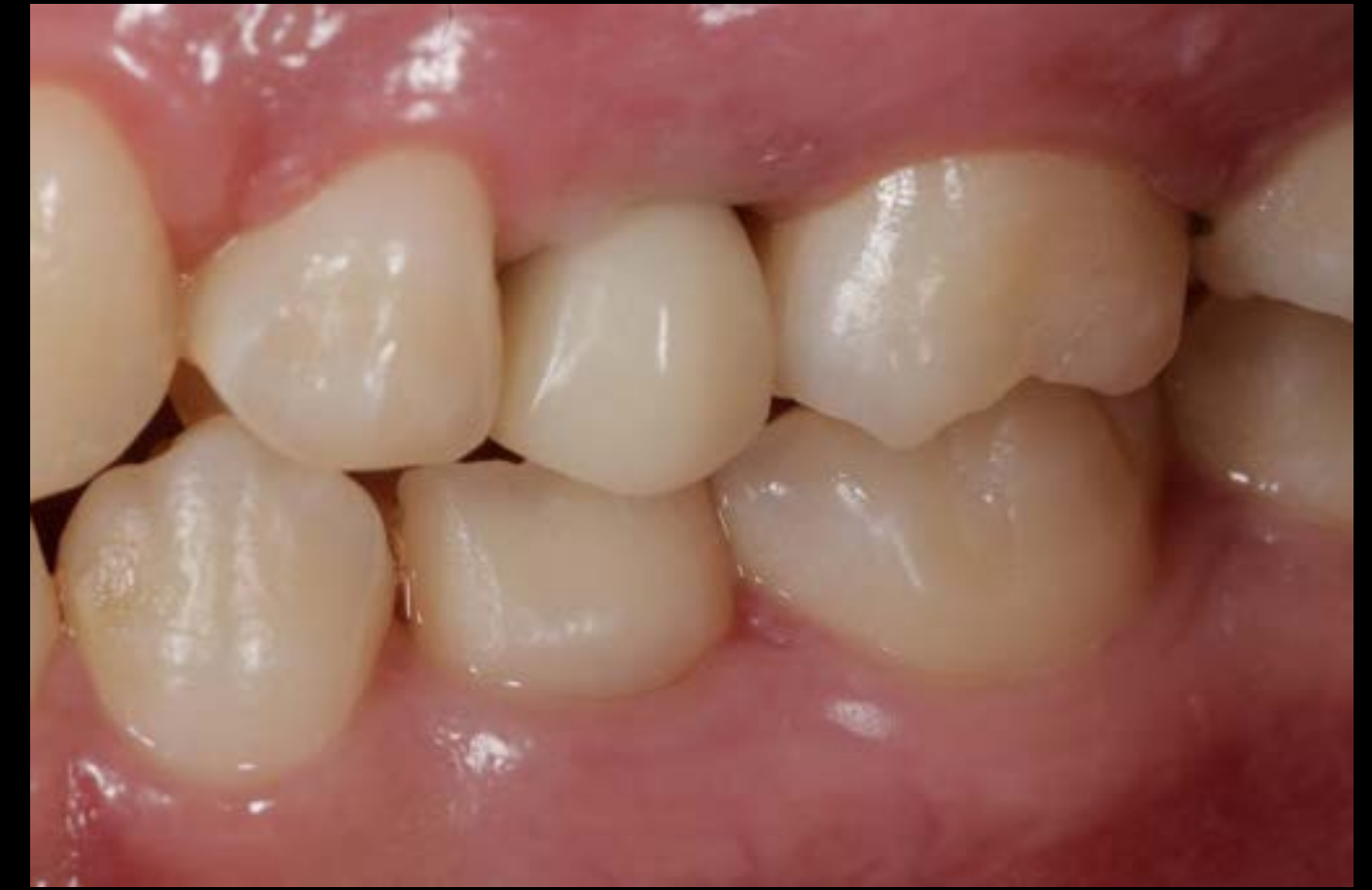Clear slinger for 26 distal driving with the implant anchor

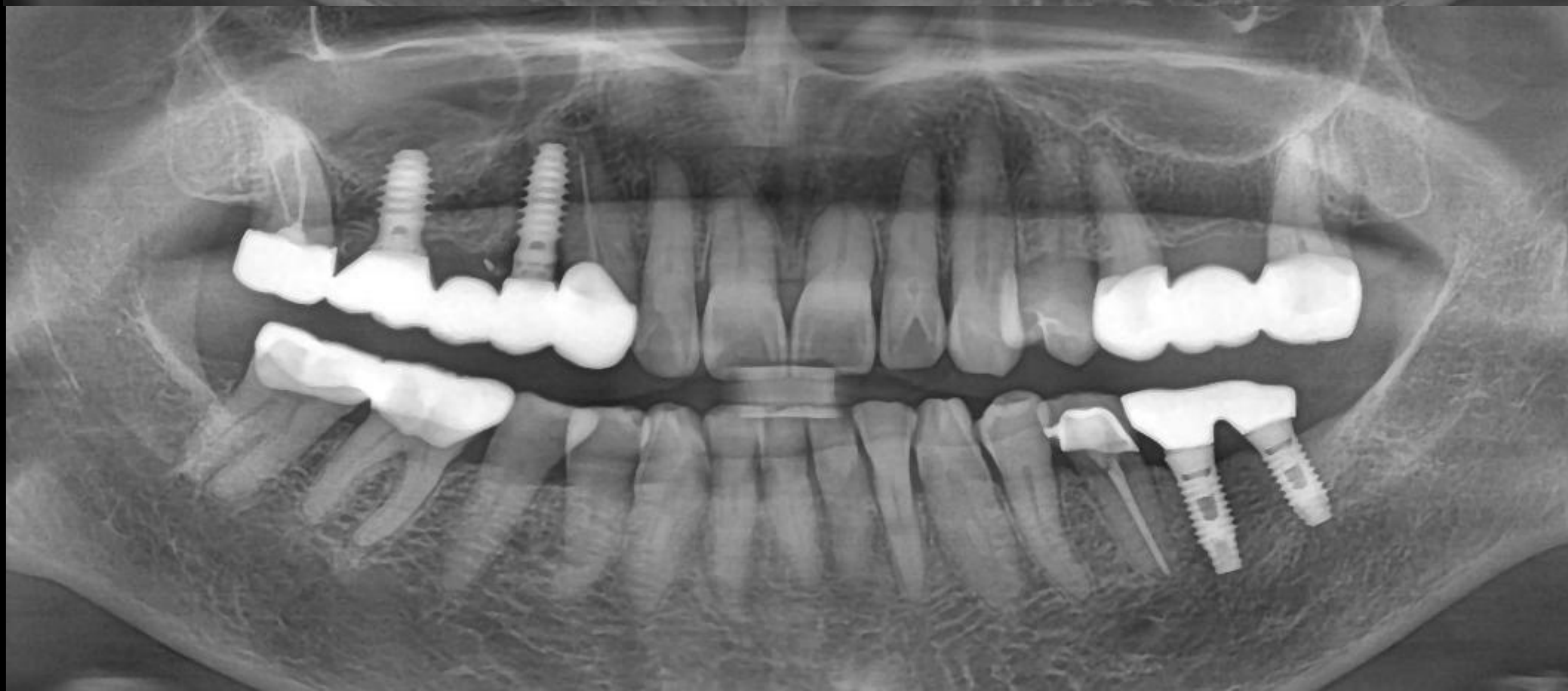
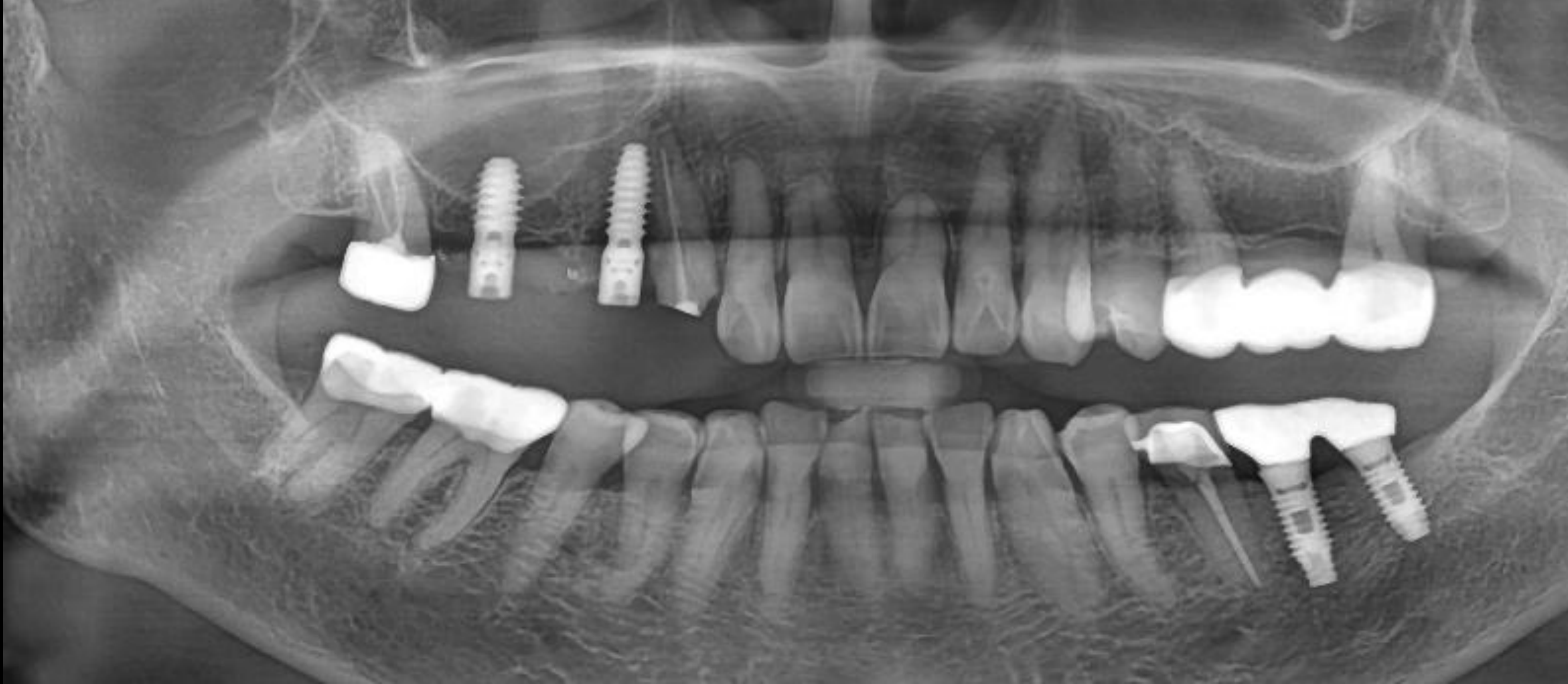
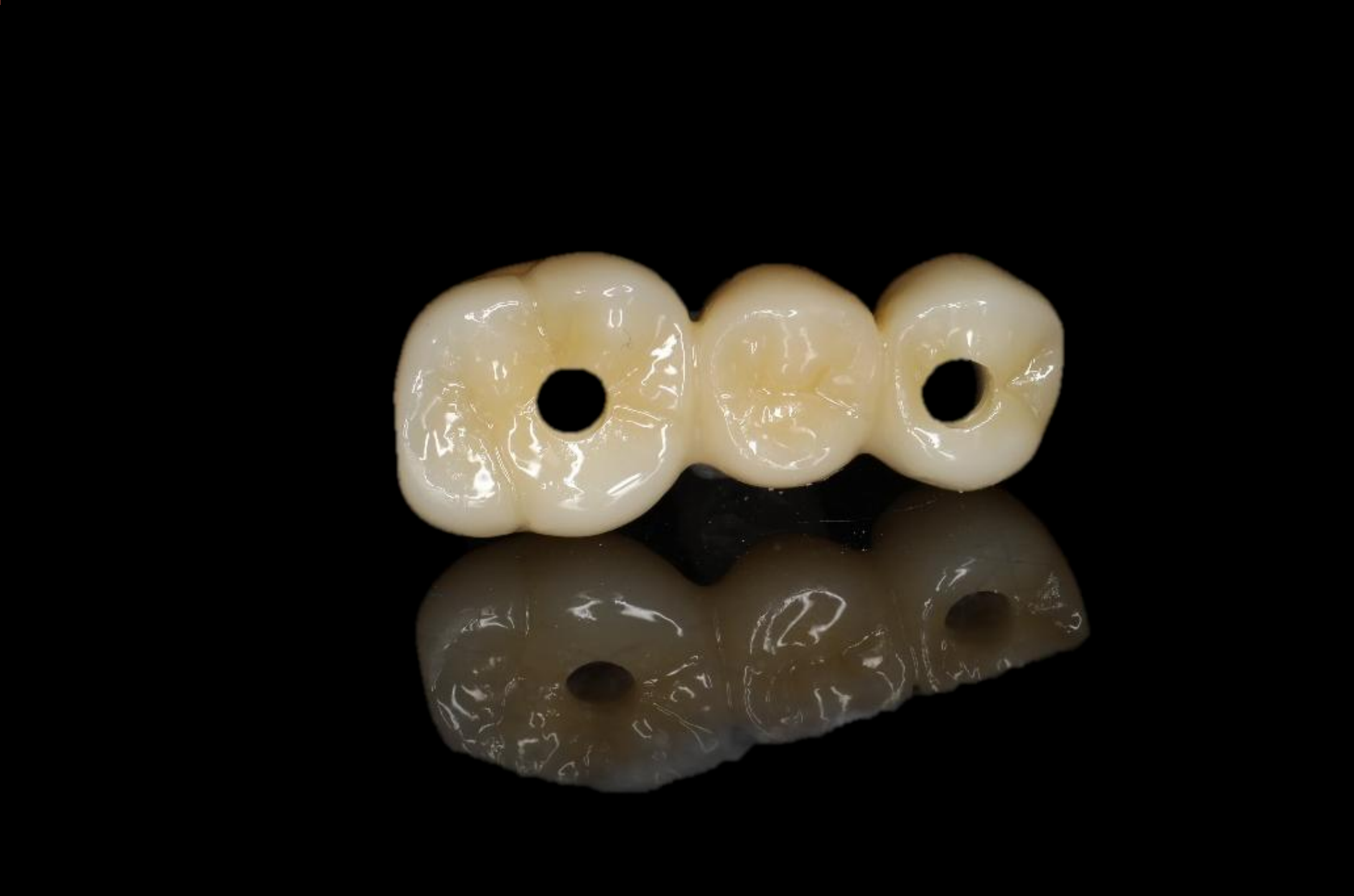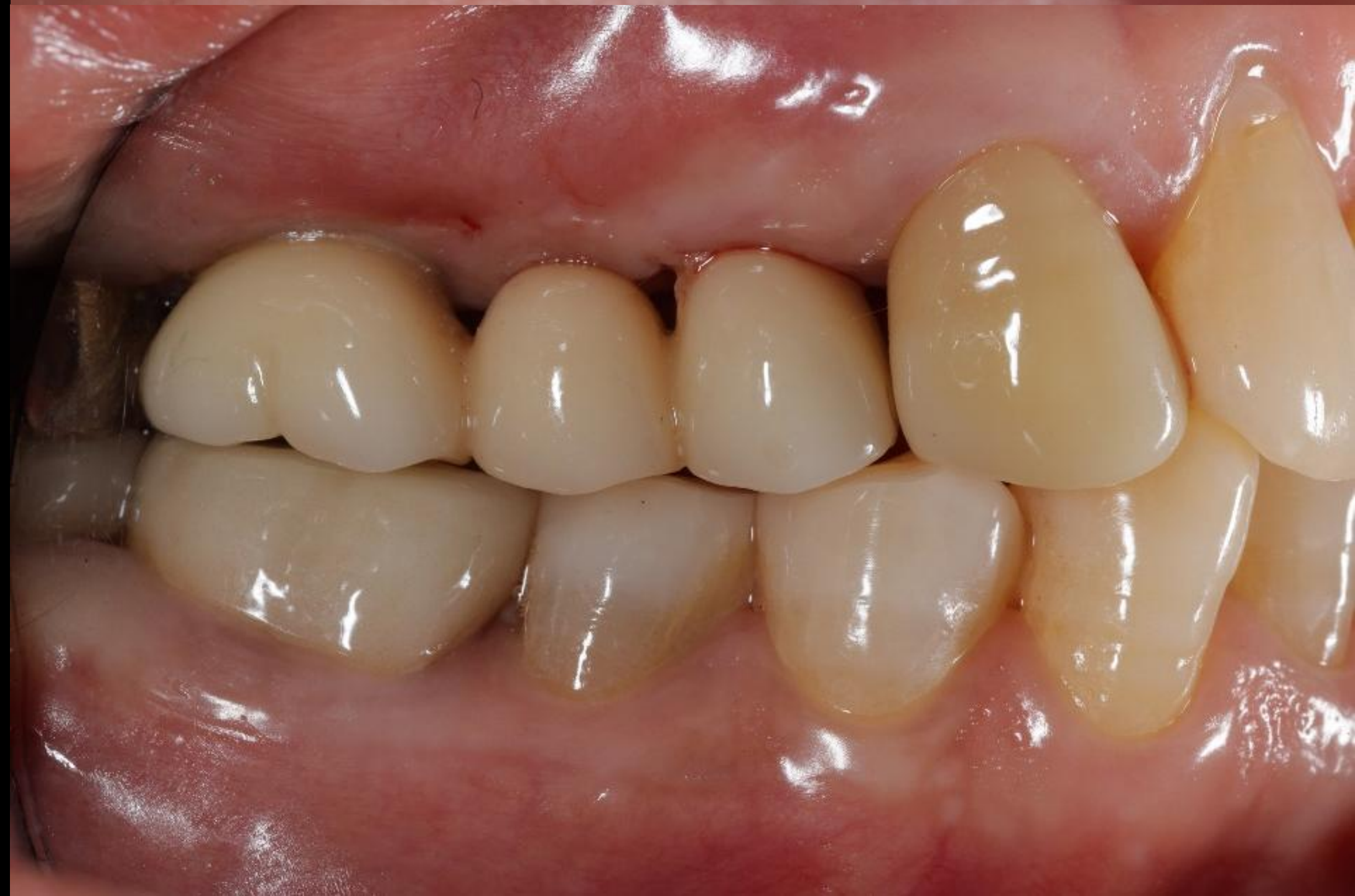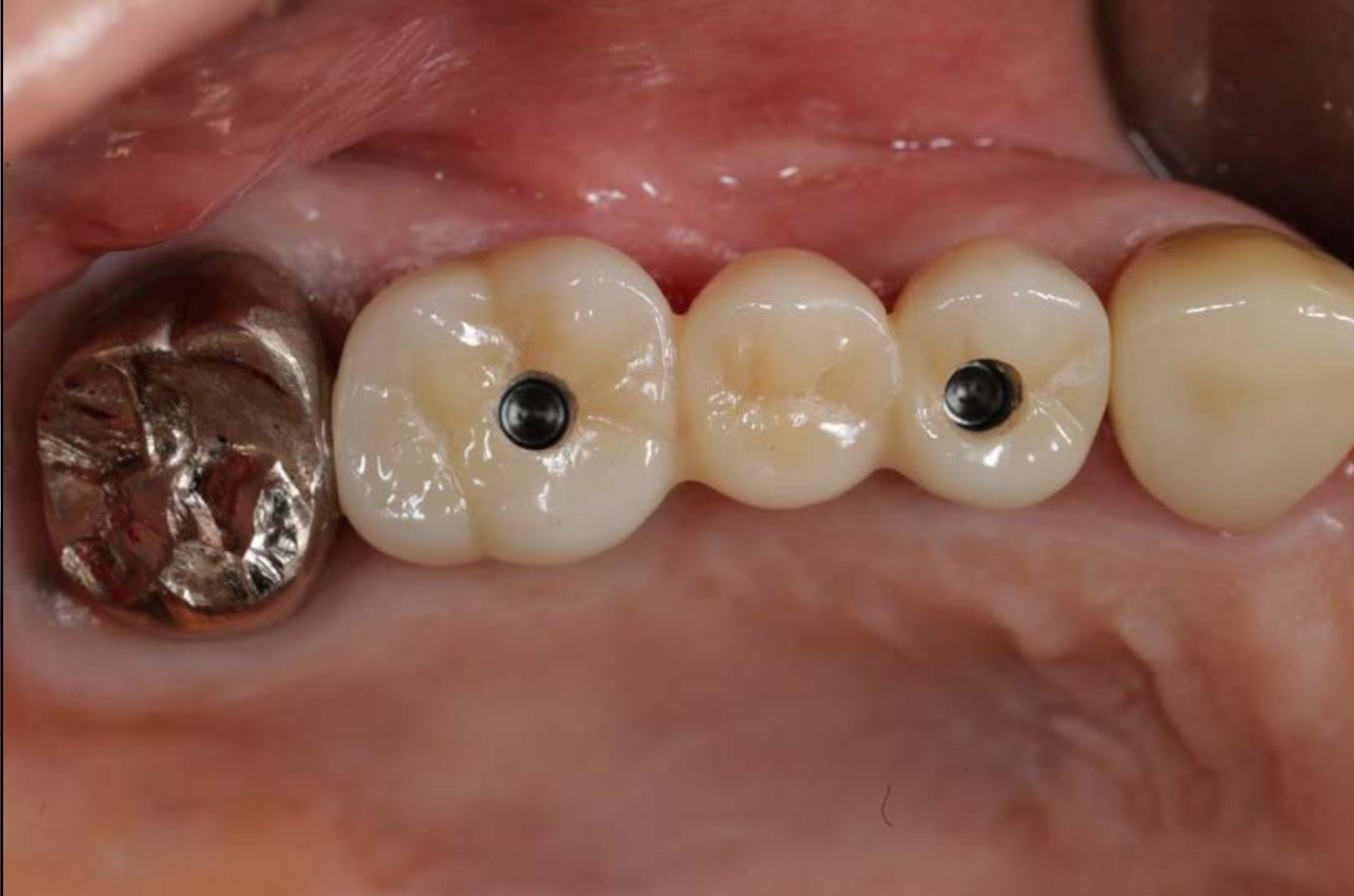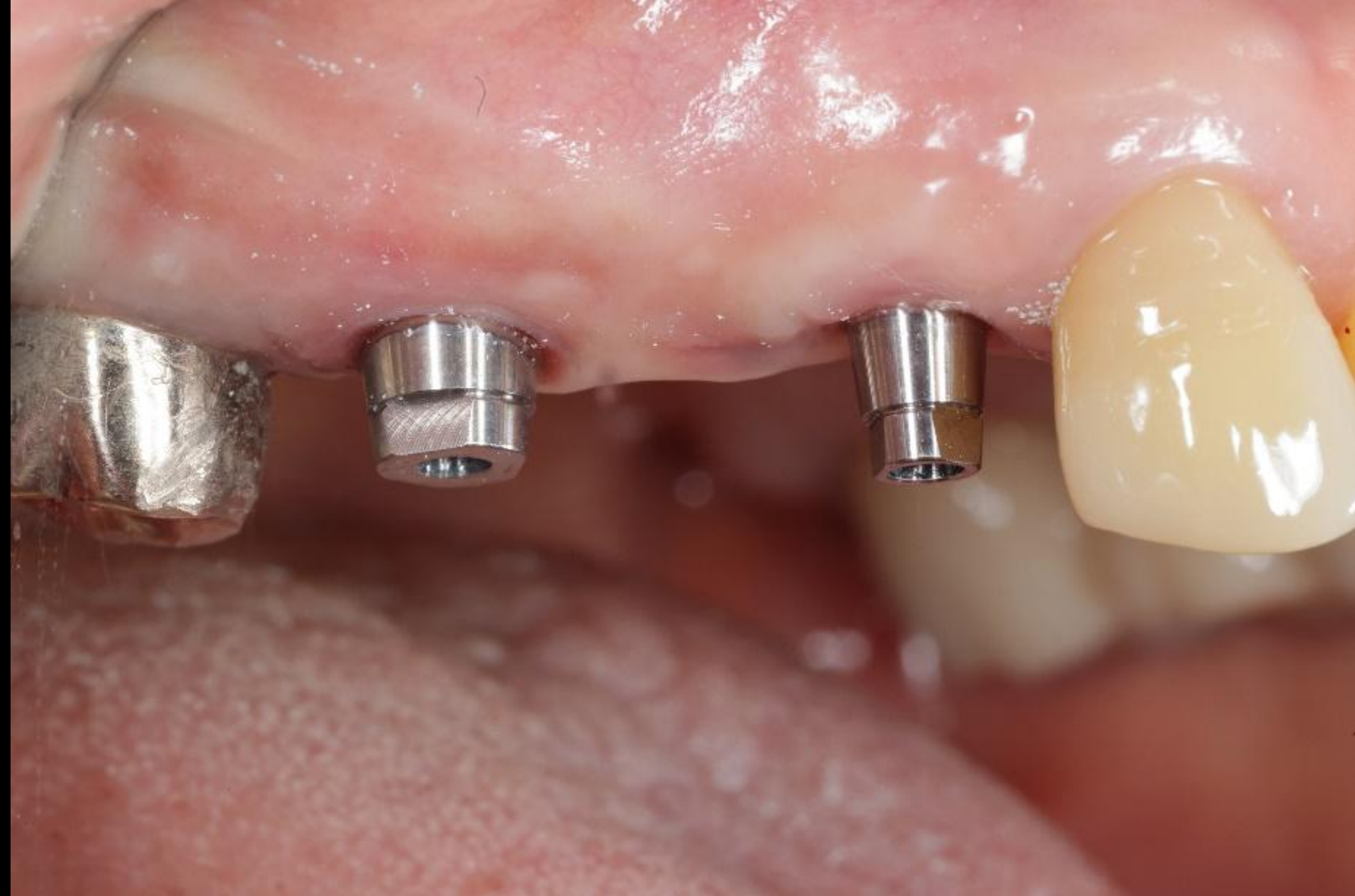the TRUST 70/74



Ti – base + Temp del







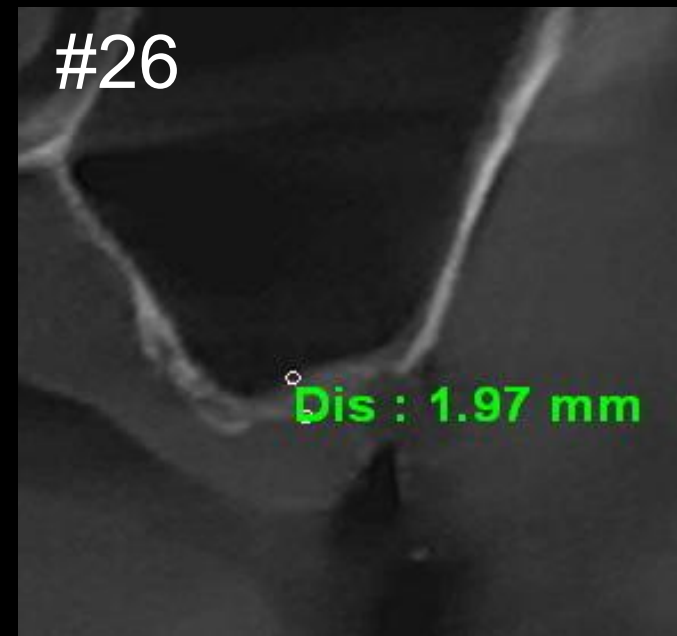
An intraoperative photograph showing a dental procedure. A white, textured implant (DASK Simple) is visible, partially covered by a translucent, reddish membrane. The surrounding tissue is pink and moist. A surgical instrument is visible in the lower left corner.

Crestal Approach with DASK Simple

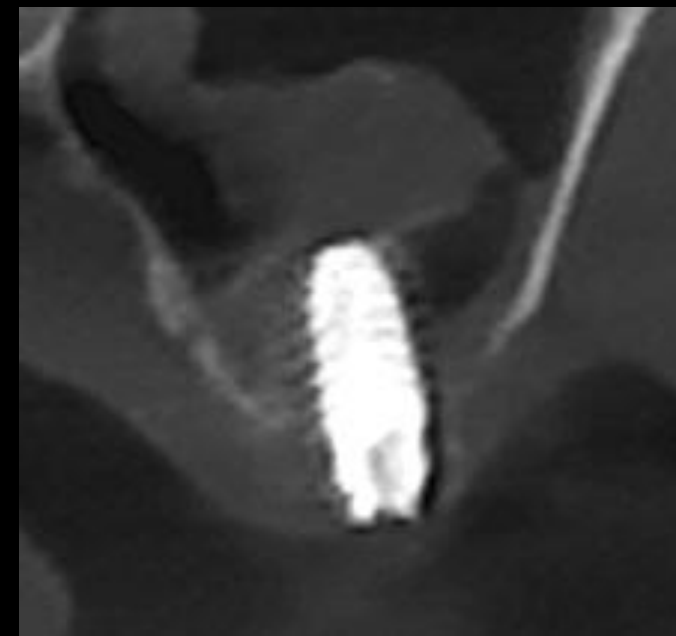
Dentium Dental Clinic
Dr. SM Chung

**** 239p Surgery VOD 5**

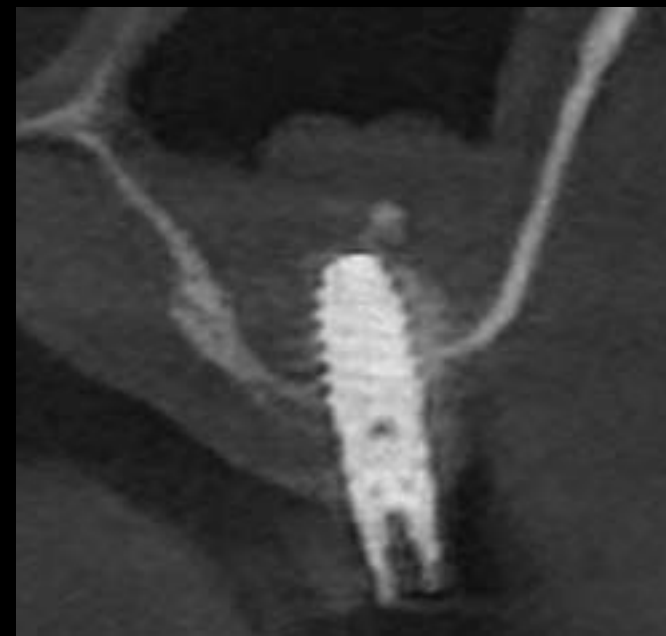
Crestal Approach Clinical CASE



Pre-op CT

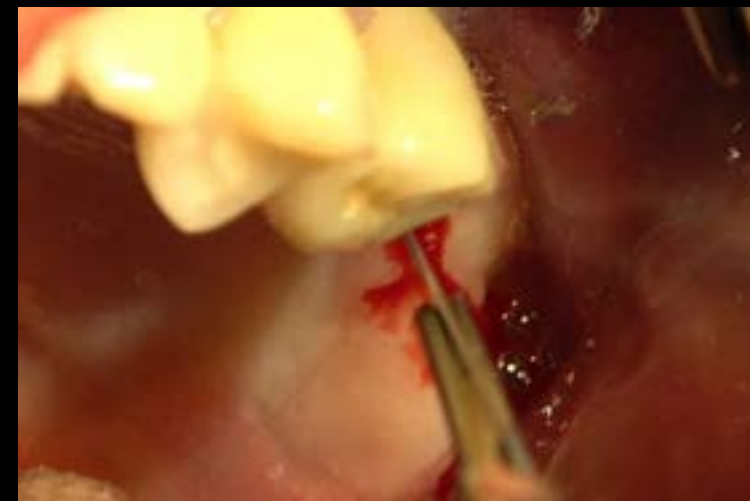

Post-op CT

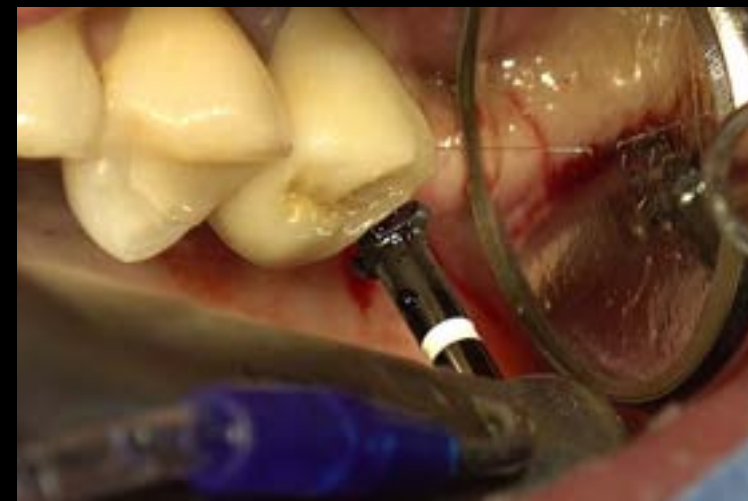

Healing CT : 4M

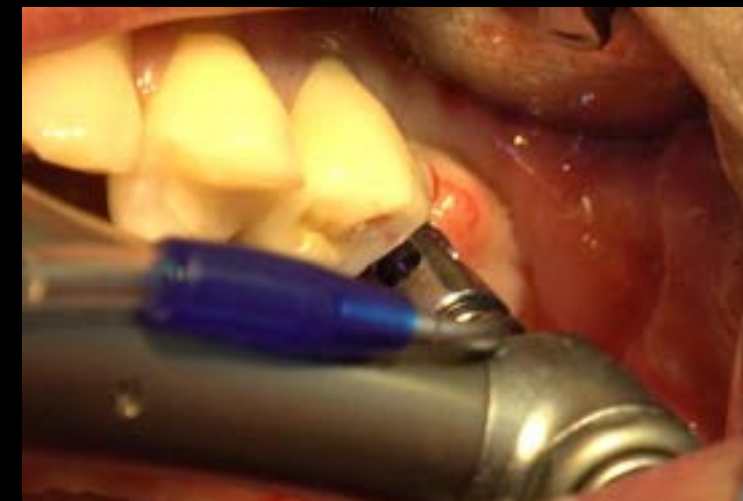- “Does **Collagen Graft** first layering enhance the performance of **OSTEON Xeno** or **OSTEON 3**?
- Can the **Crestal approach** be used in cases with 1–3 mm residual bone height?



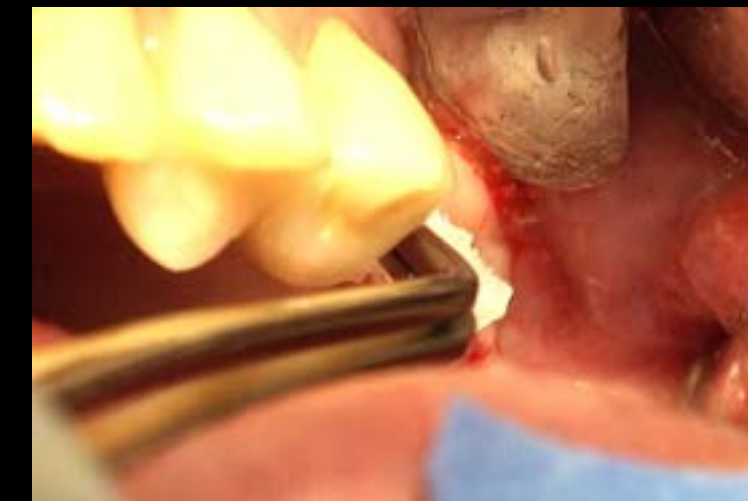Minimal invasive



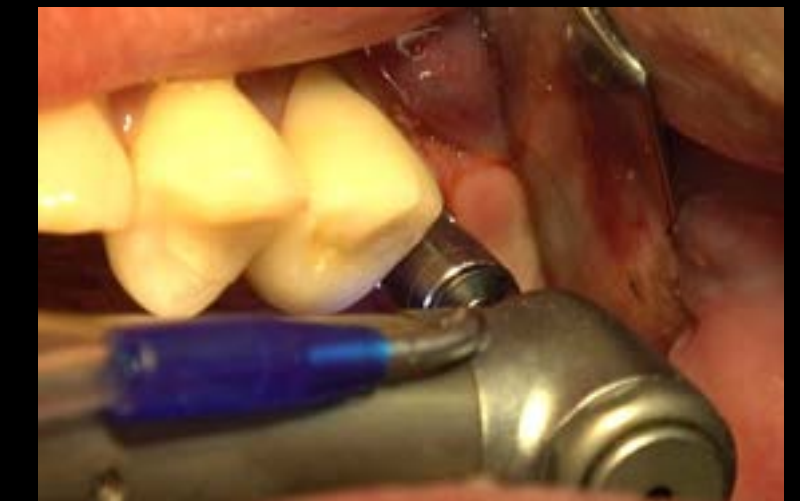Guide drilling



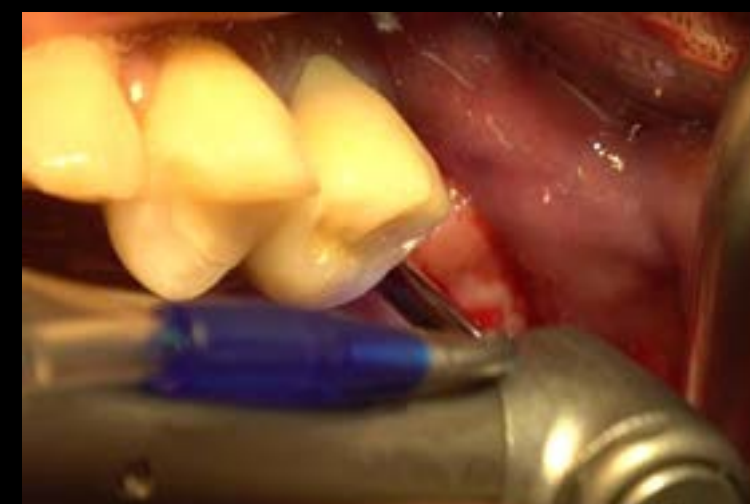
Sinus elevation



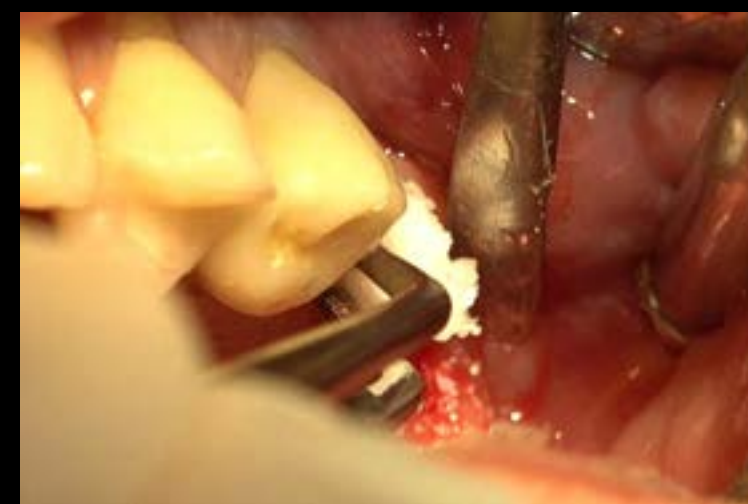
Collagen Graft x1D



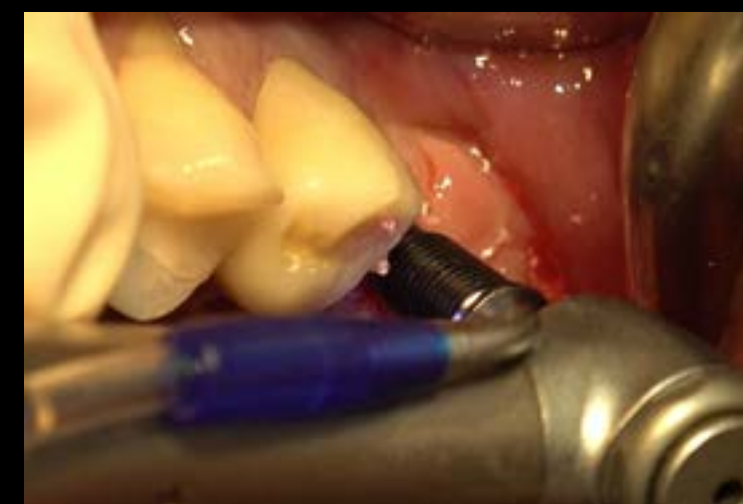Bone graft lifting



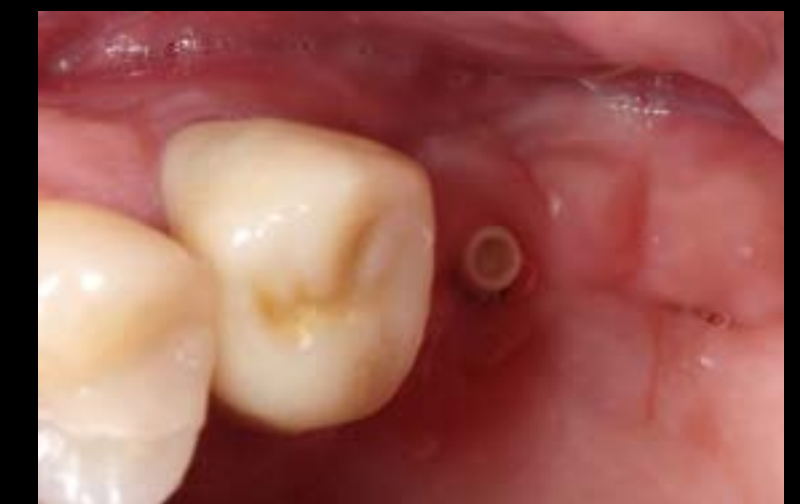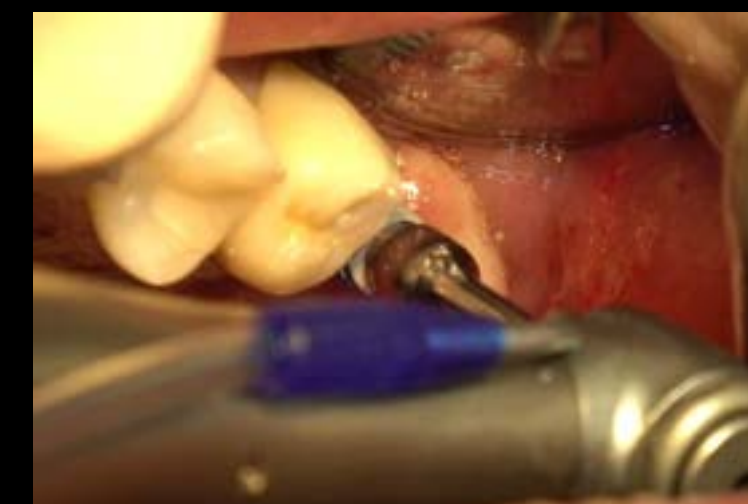Bone graft spreading OSTEON™ Xeno Collagen



Bone graft lifting



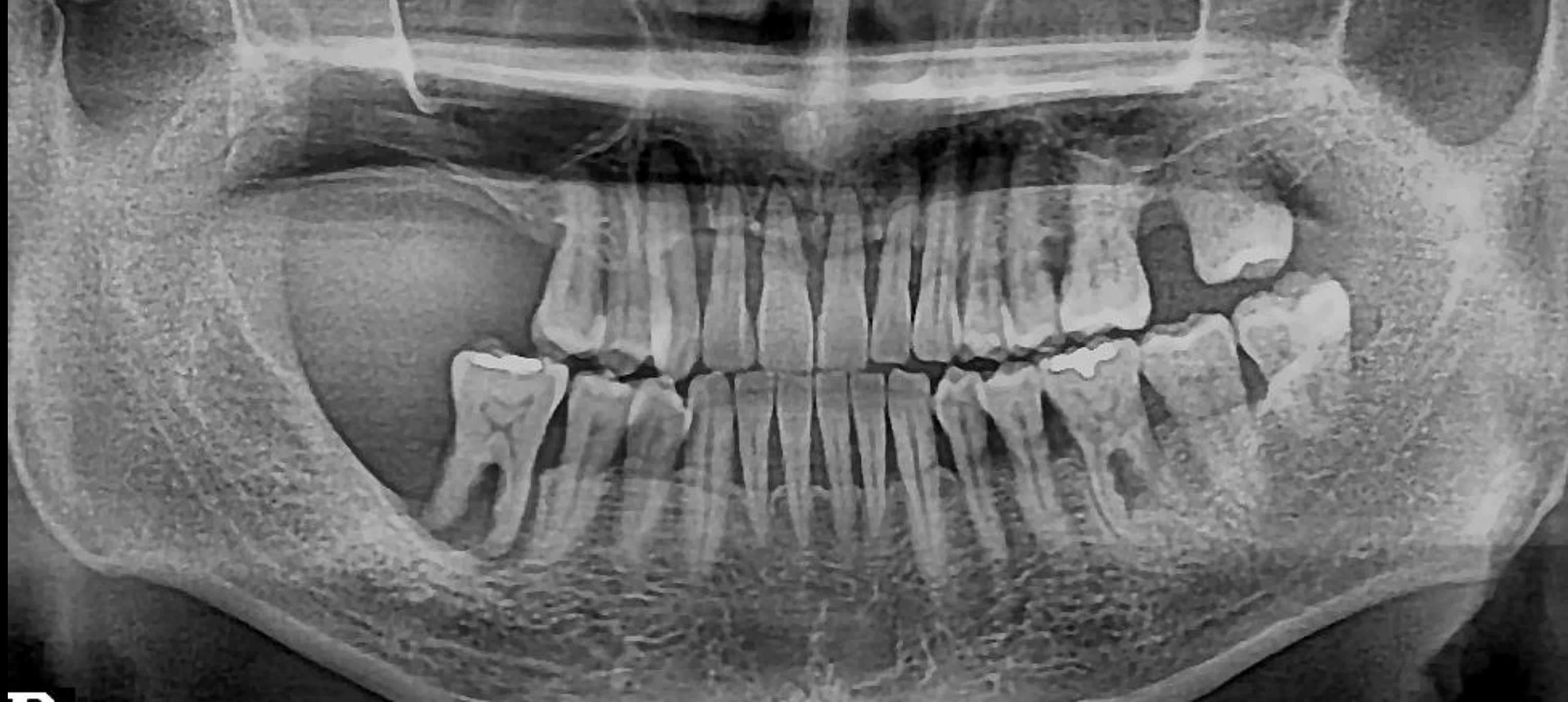bright TL (Ø4.5 X 7.0)



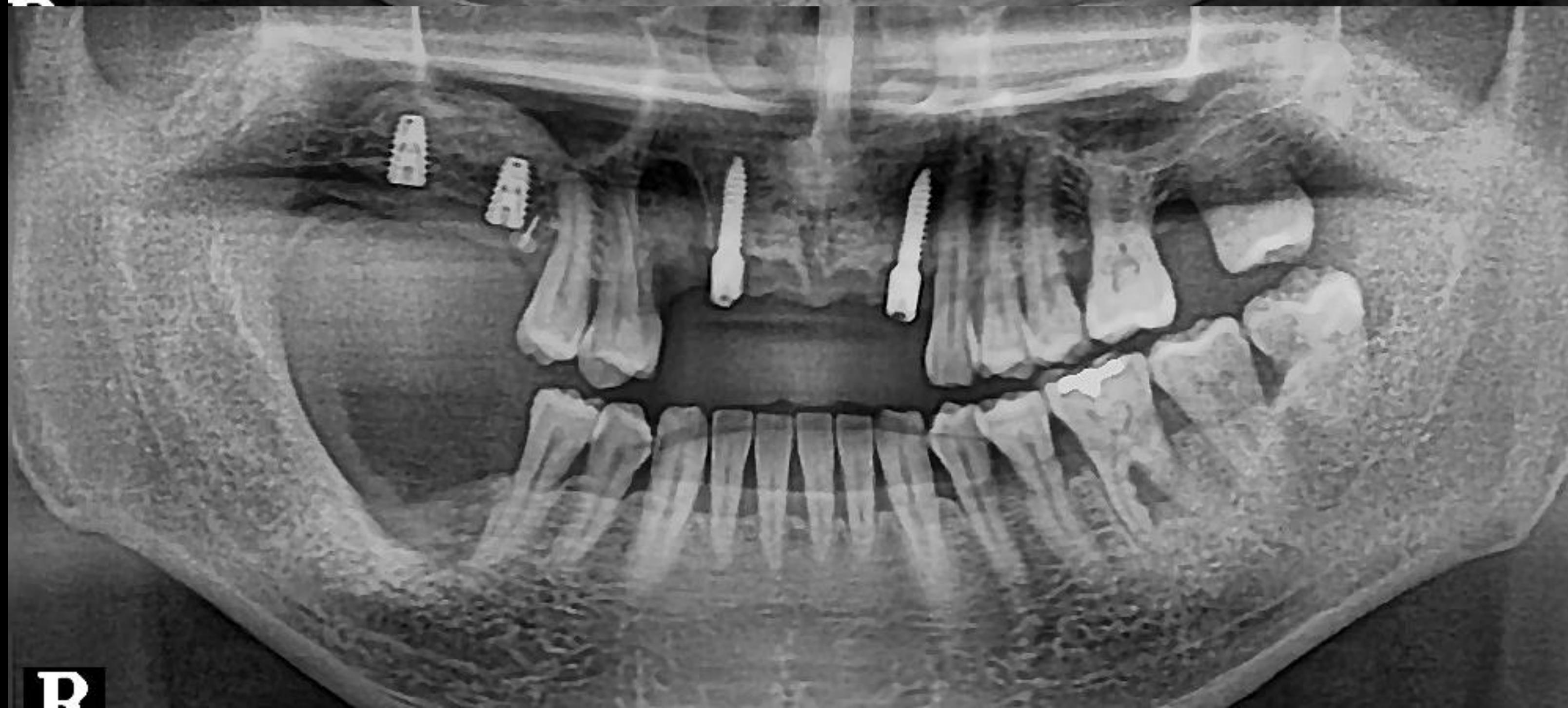
Healing : 1 month

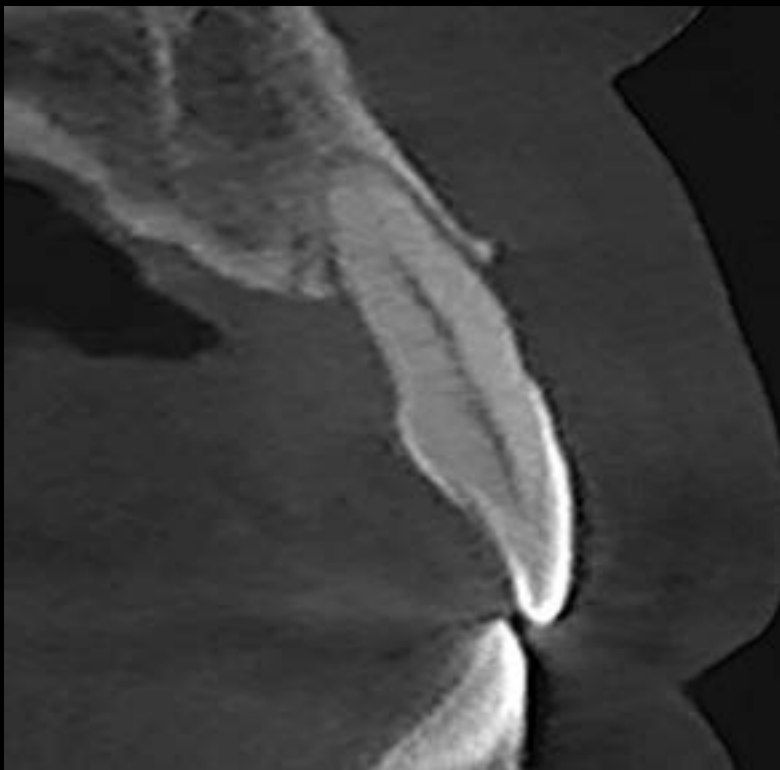
Sinus lifting with **Collagen Graft** & Bone grafting with **OSTEON Xeno Collagen**

Pre-op (2025-08-08)

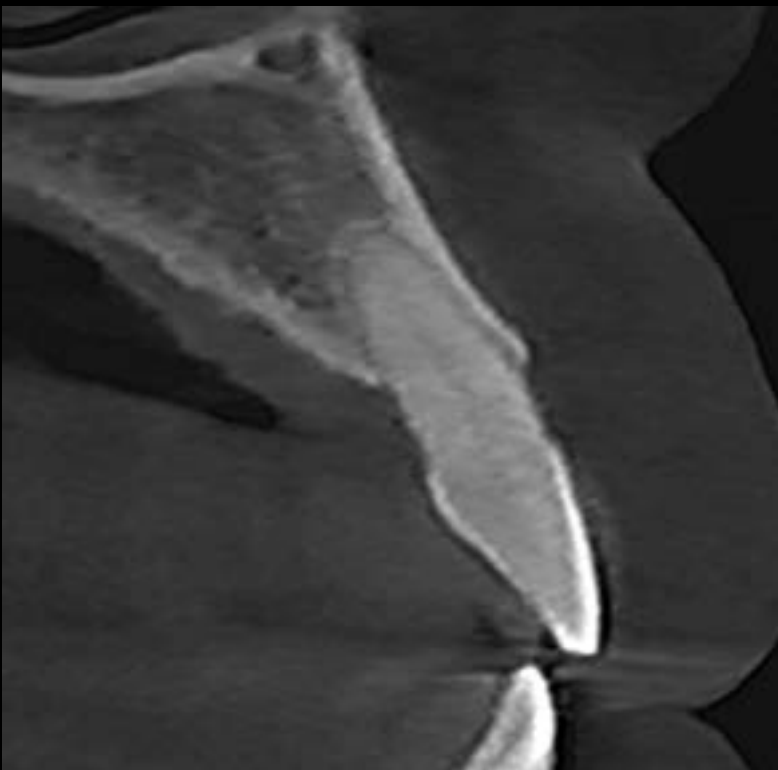


Post-op (2025-08-08)

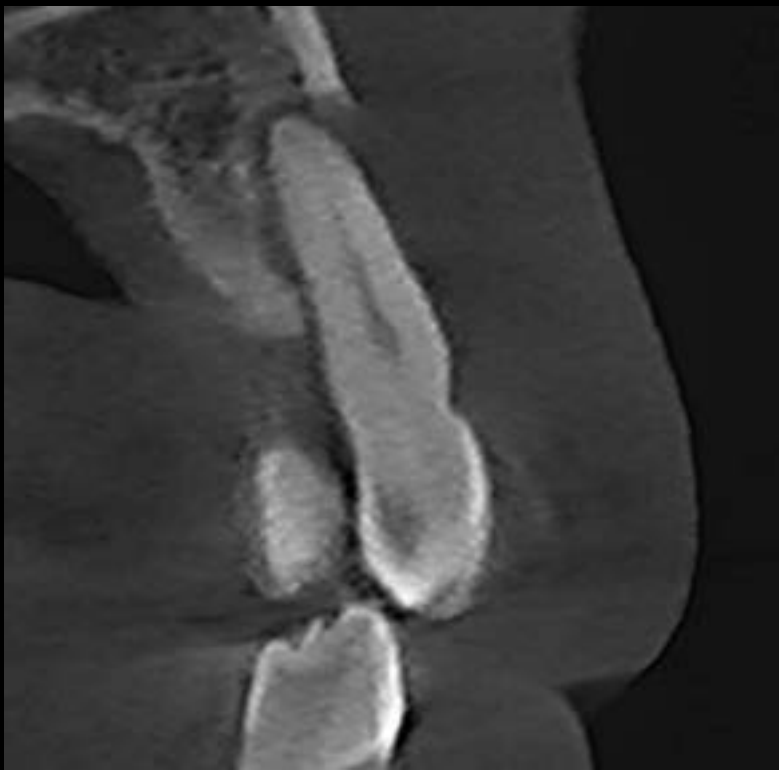



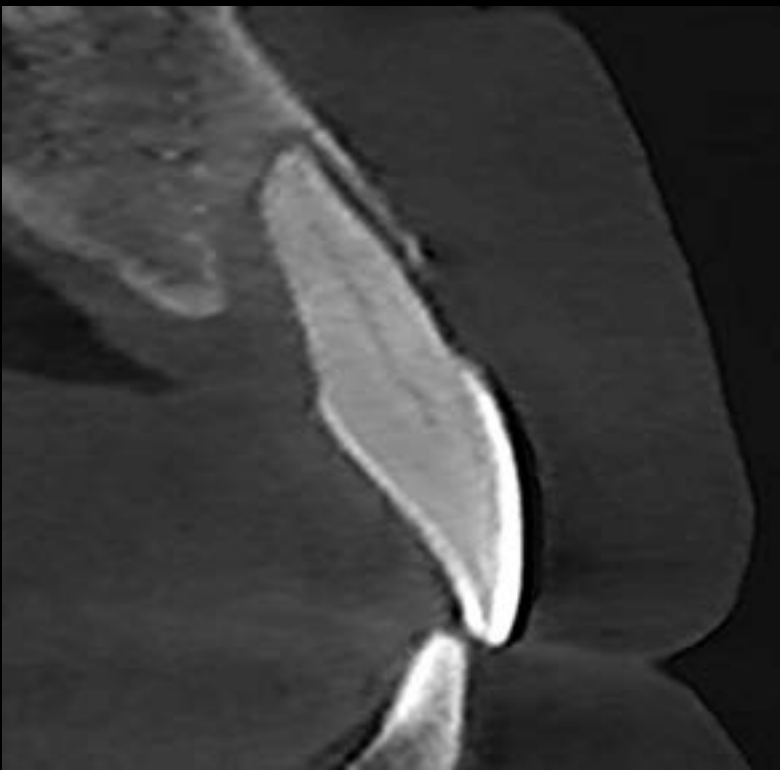
#12



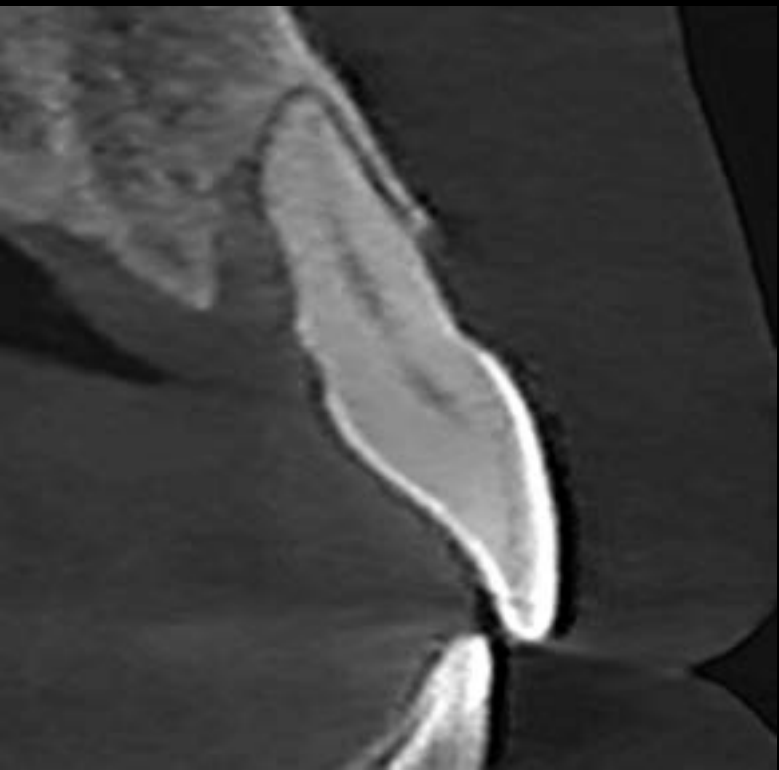
#22



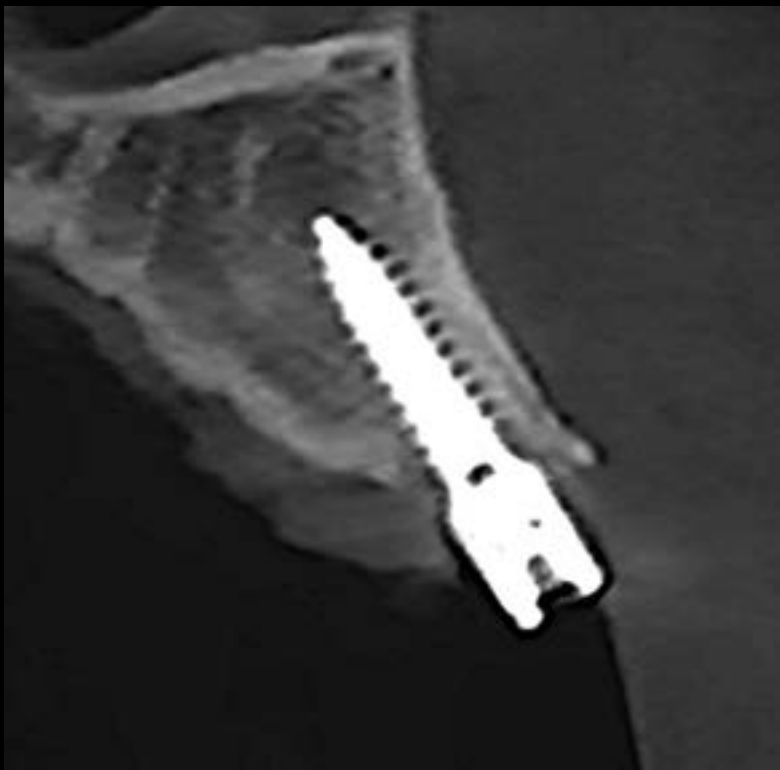#13



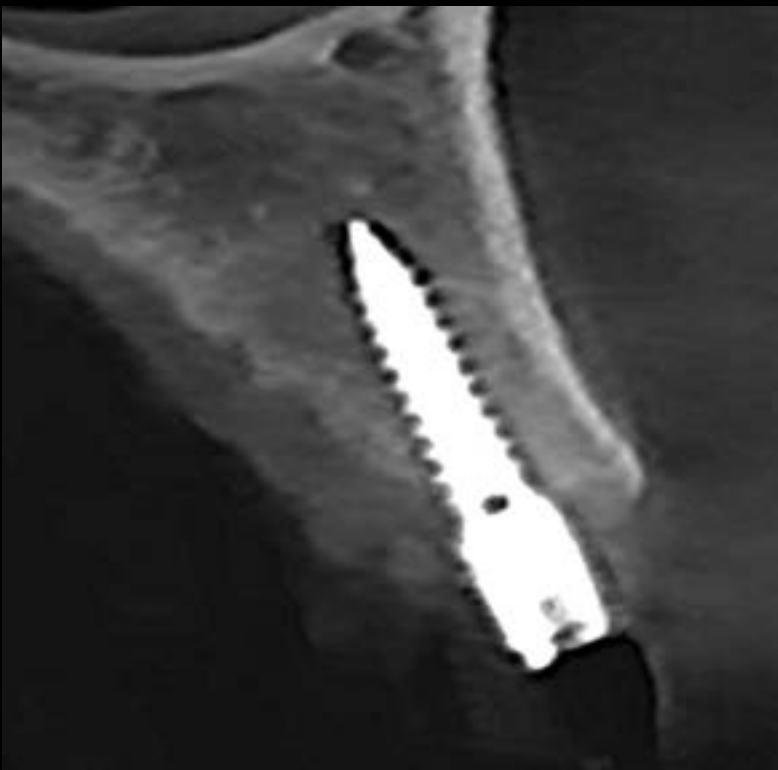#11



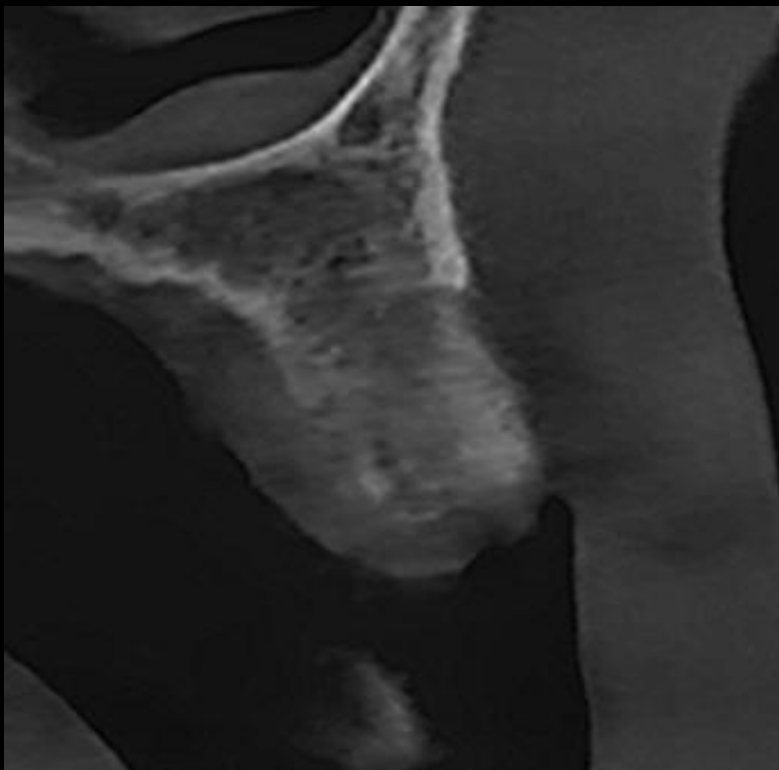
#21




#12



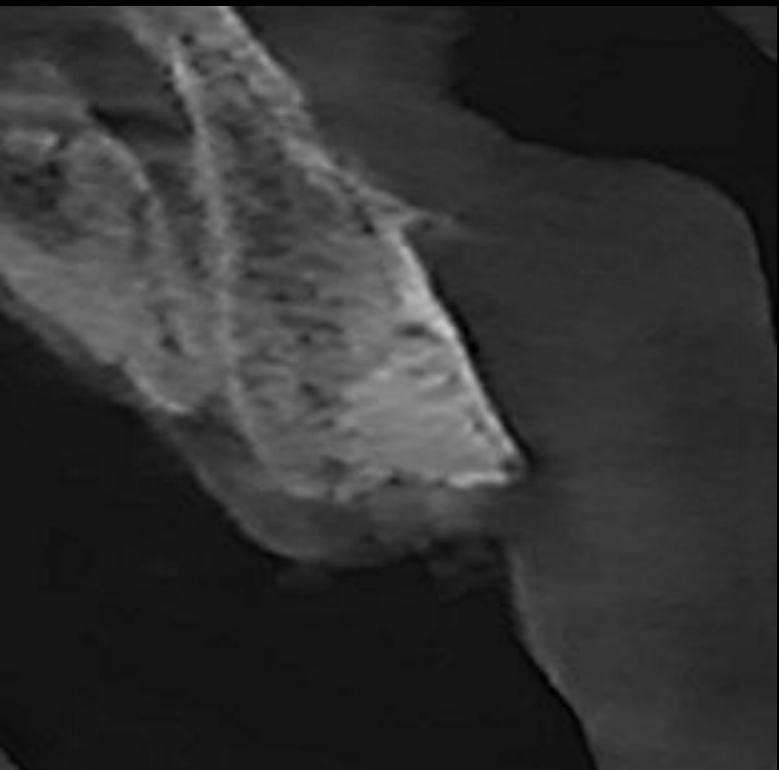
#22



#13

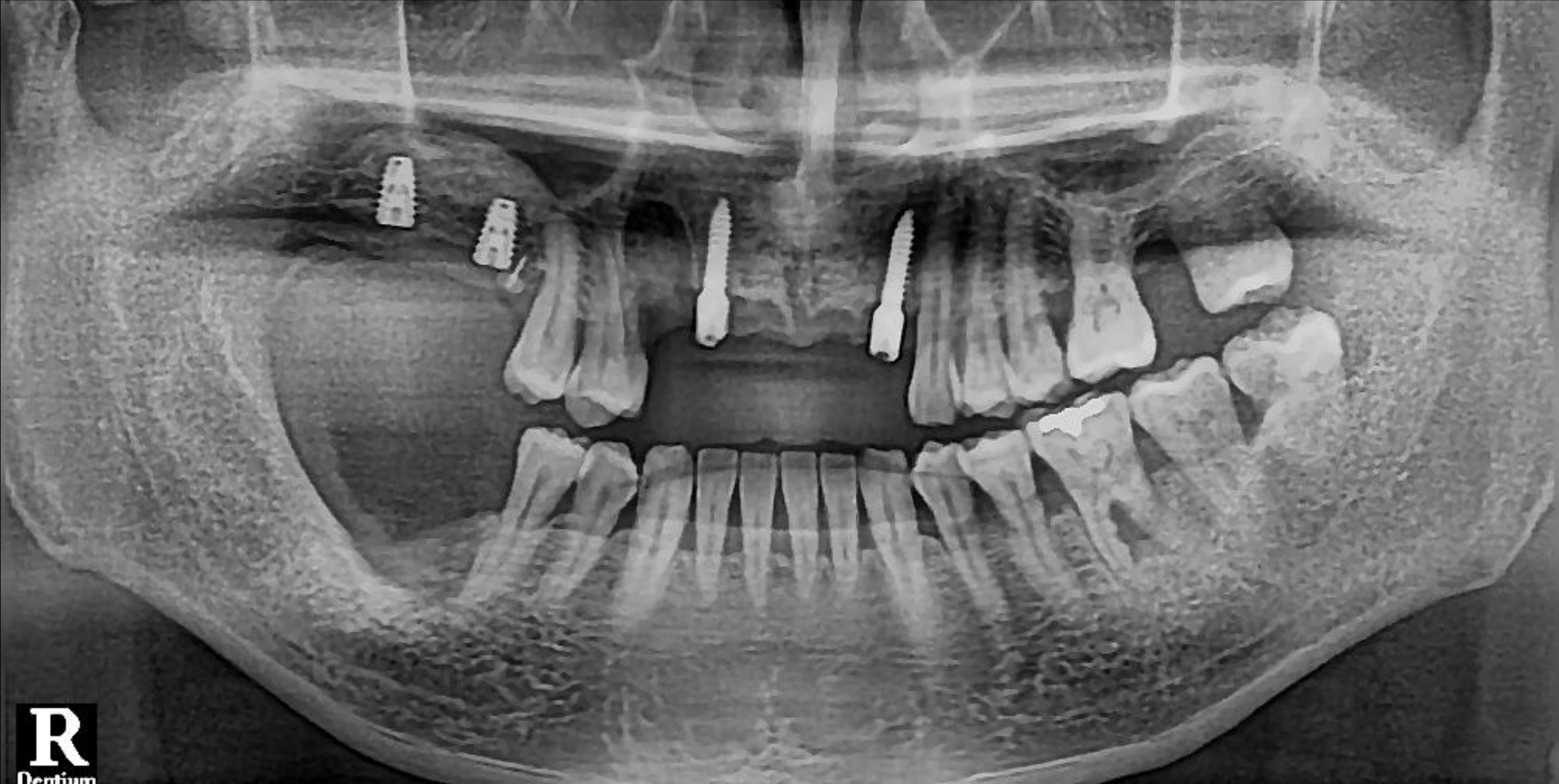

#11

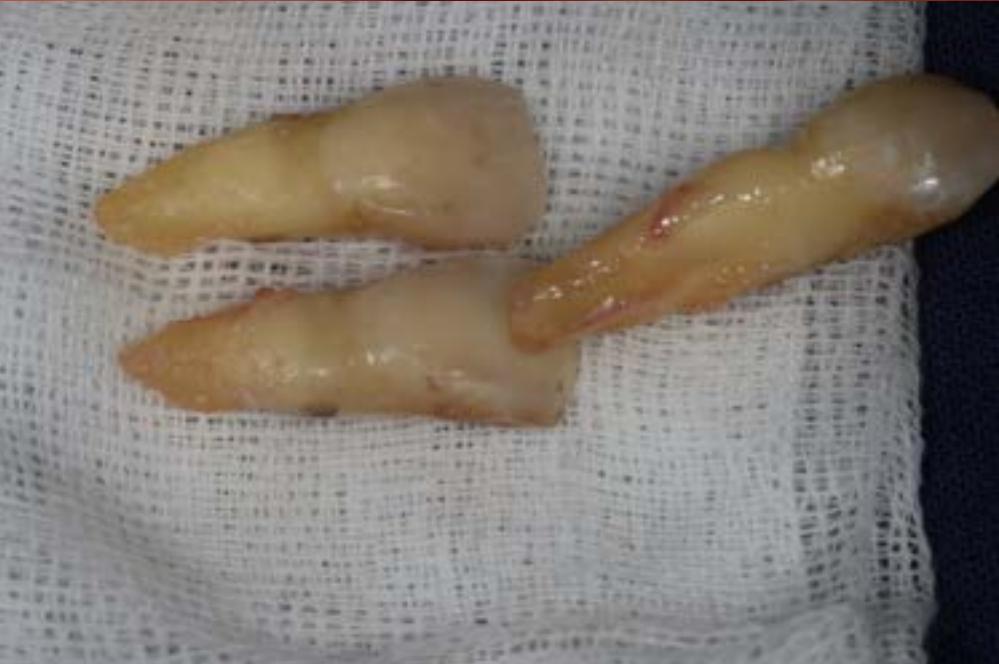
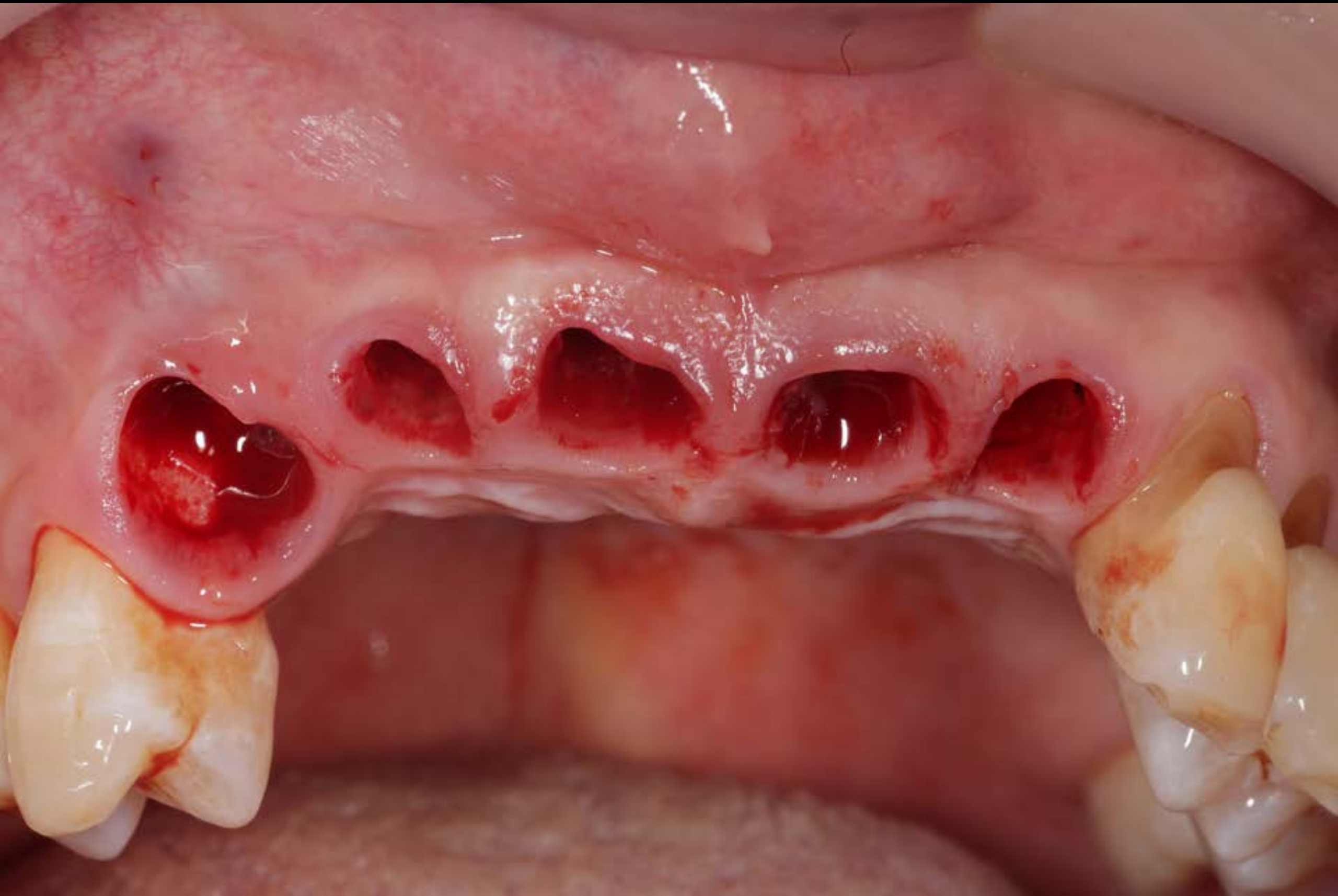
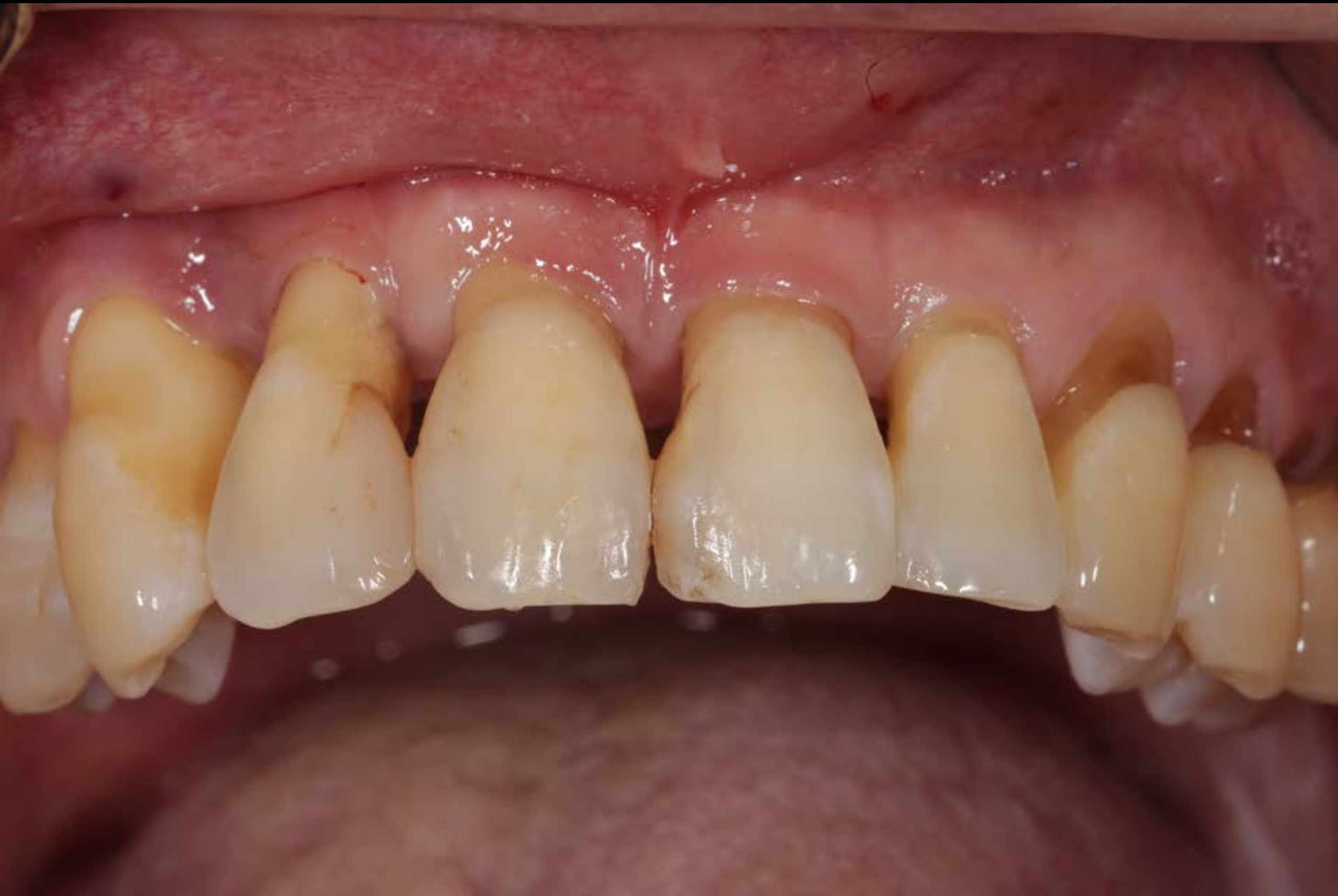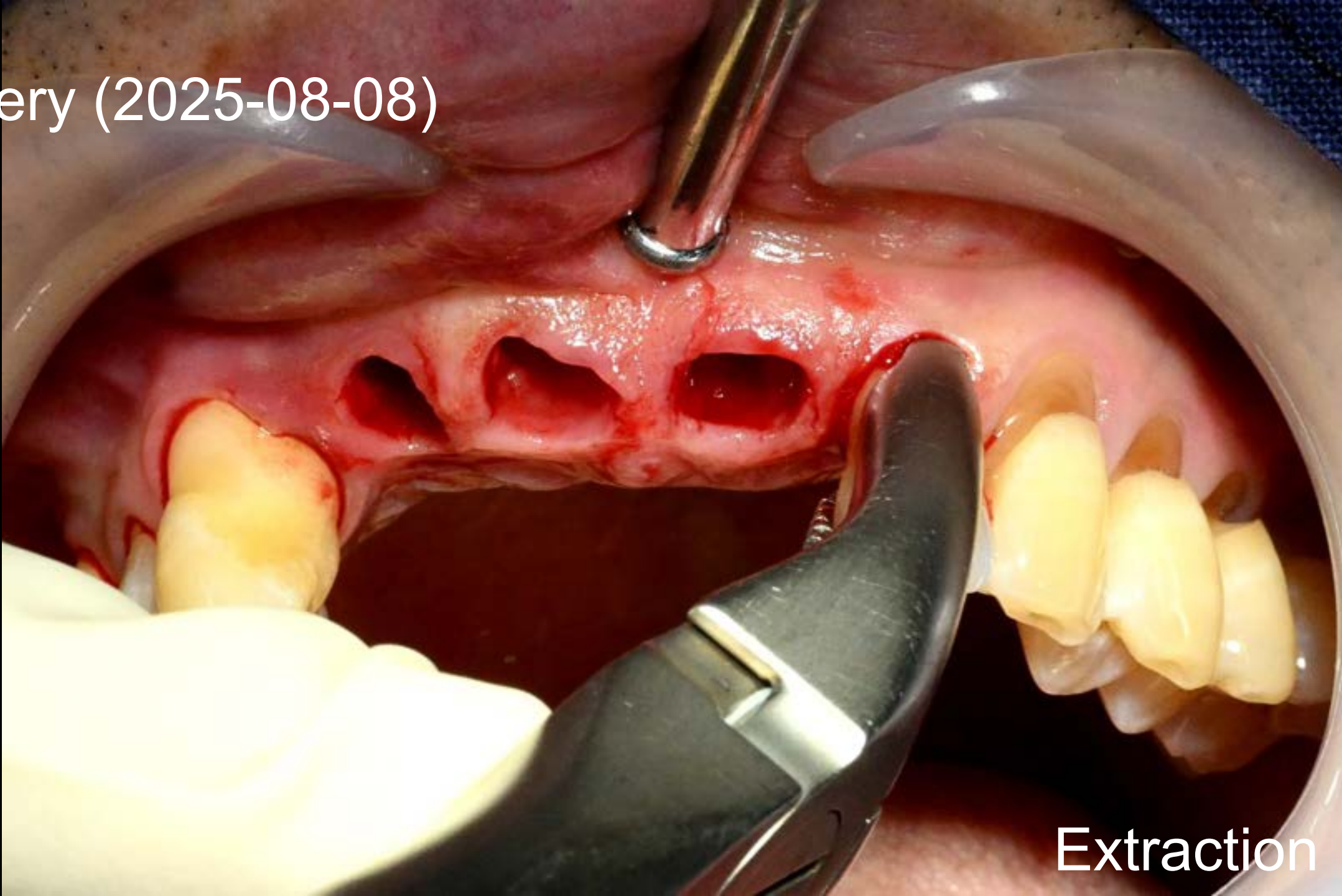
#21

Post-op (2025-08-08)

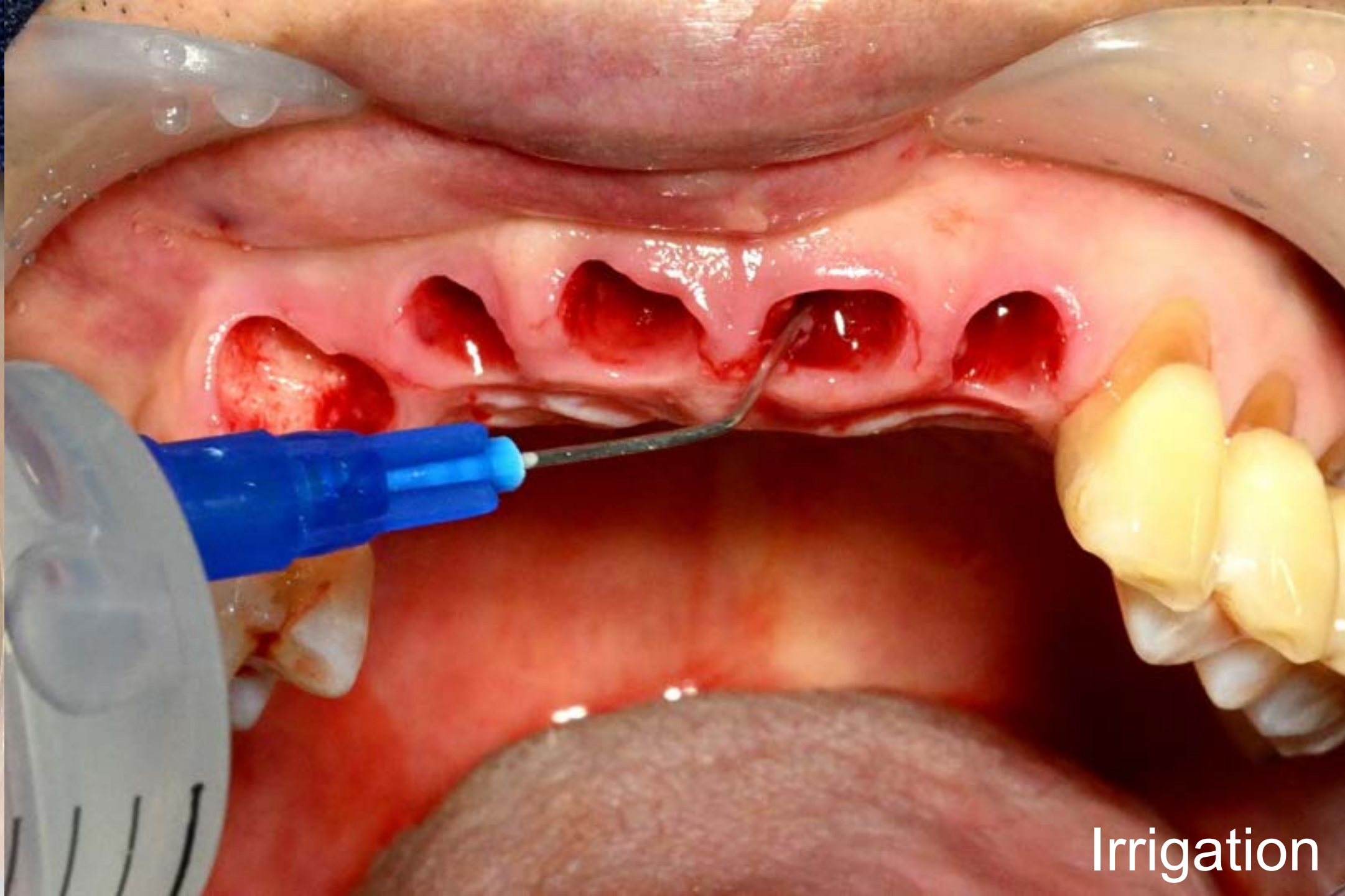


Pre-op (2025-08-08)

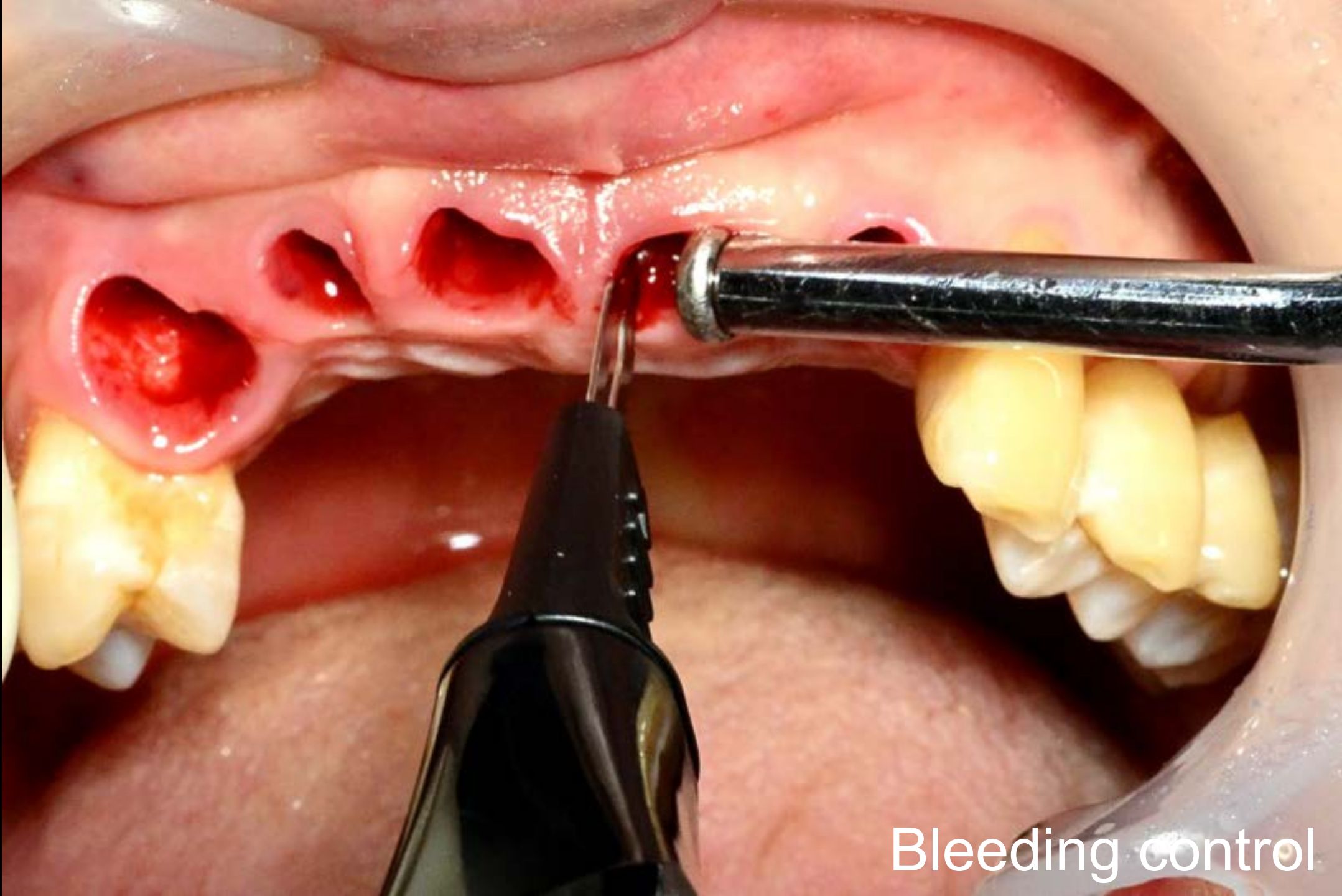




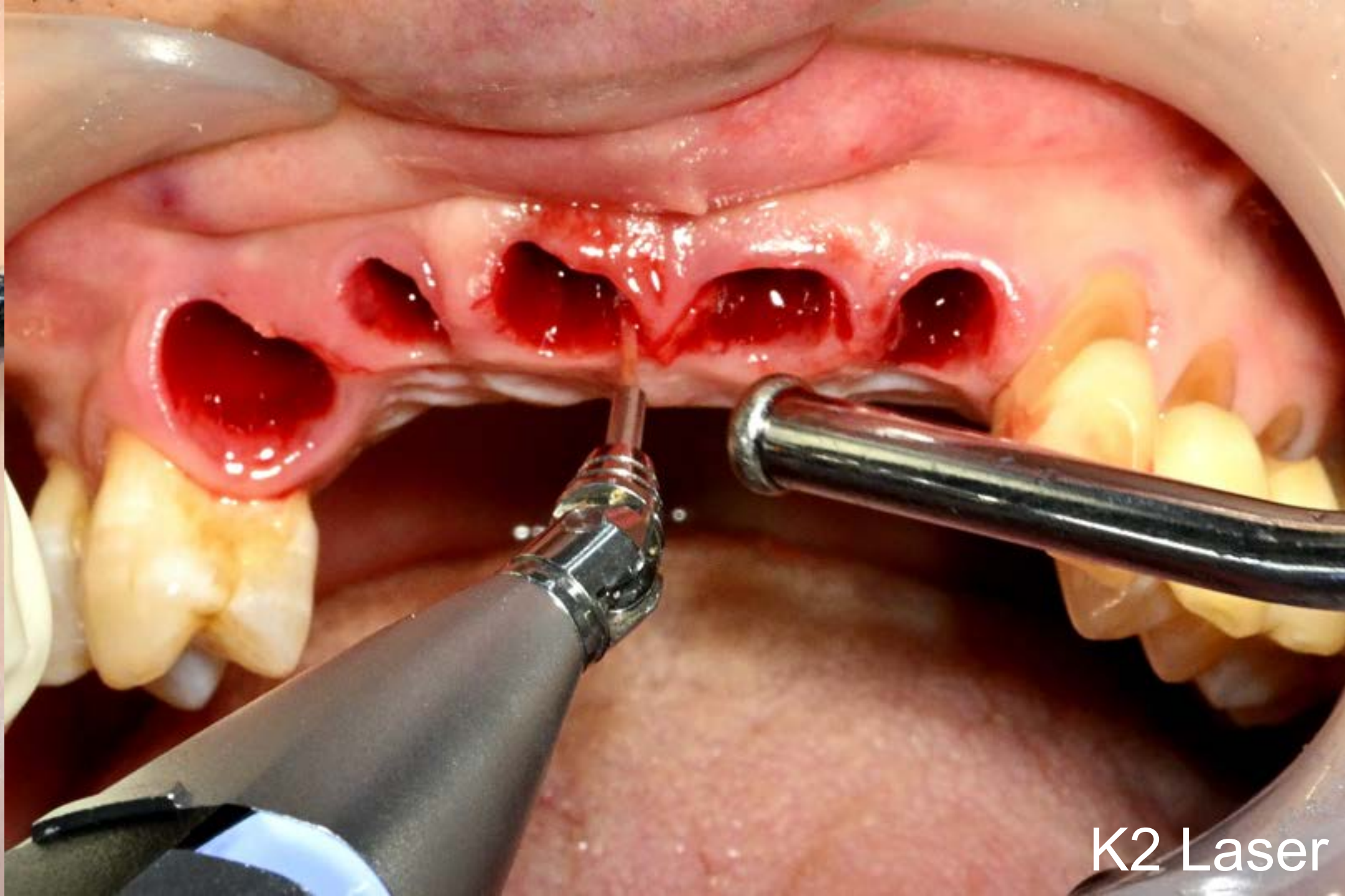
Extraction



Irrigation

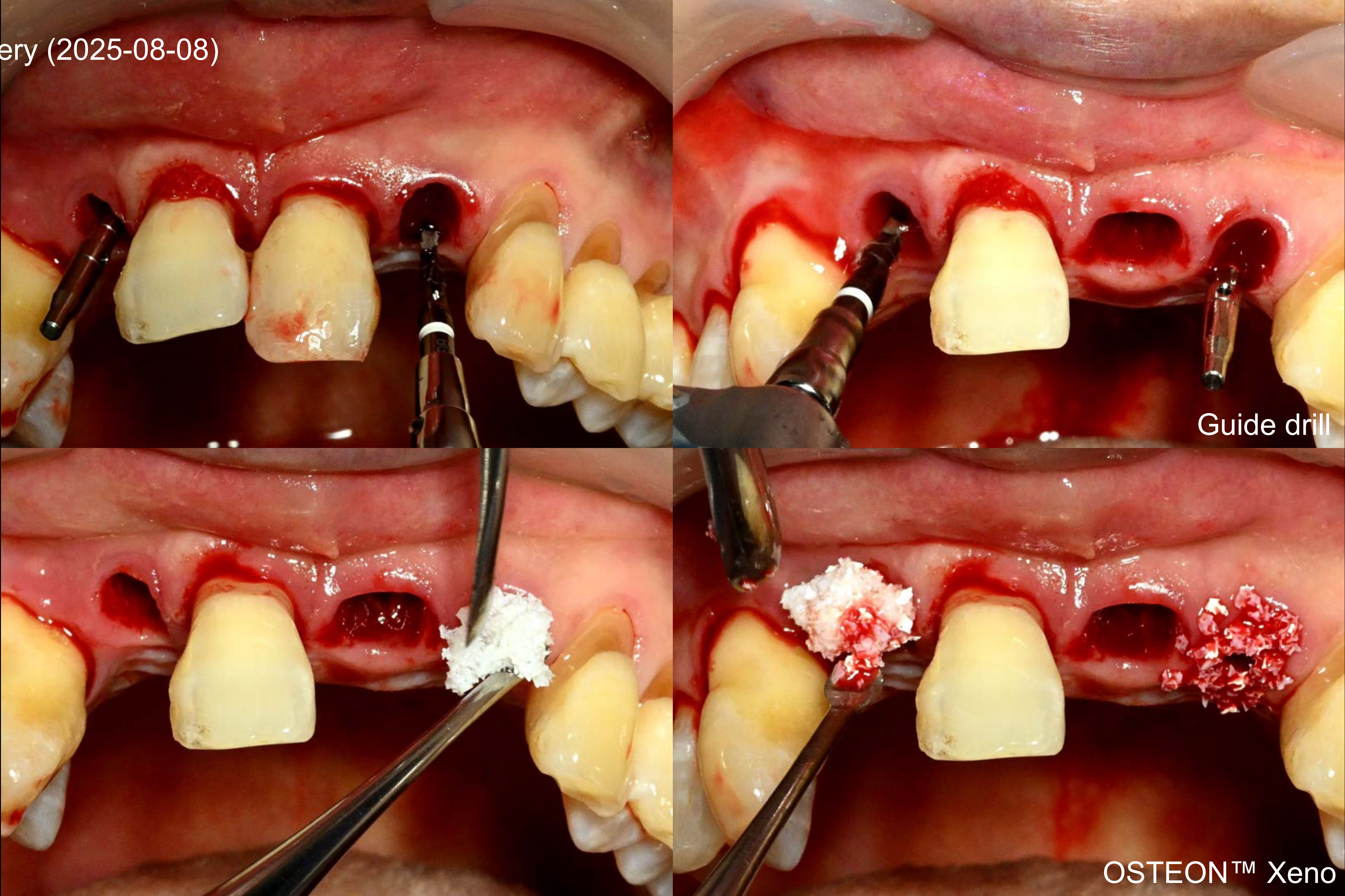


Bleeding control

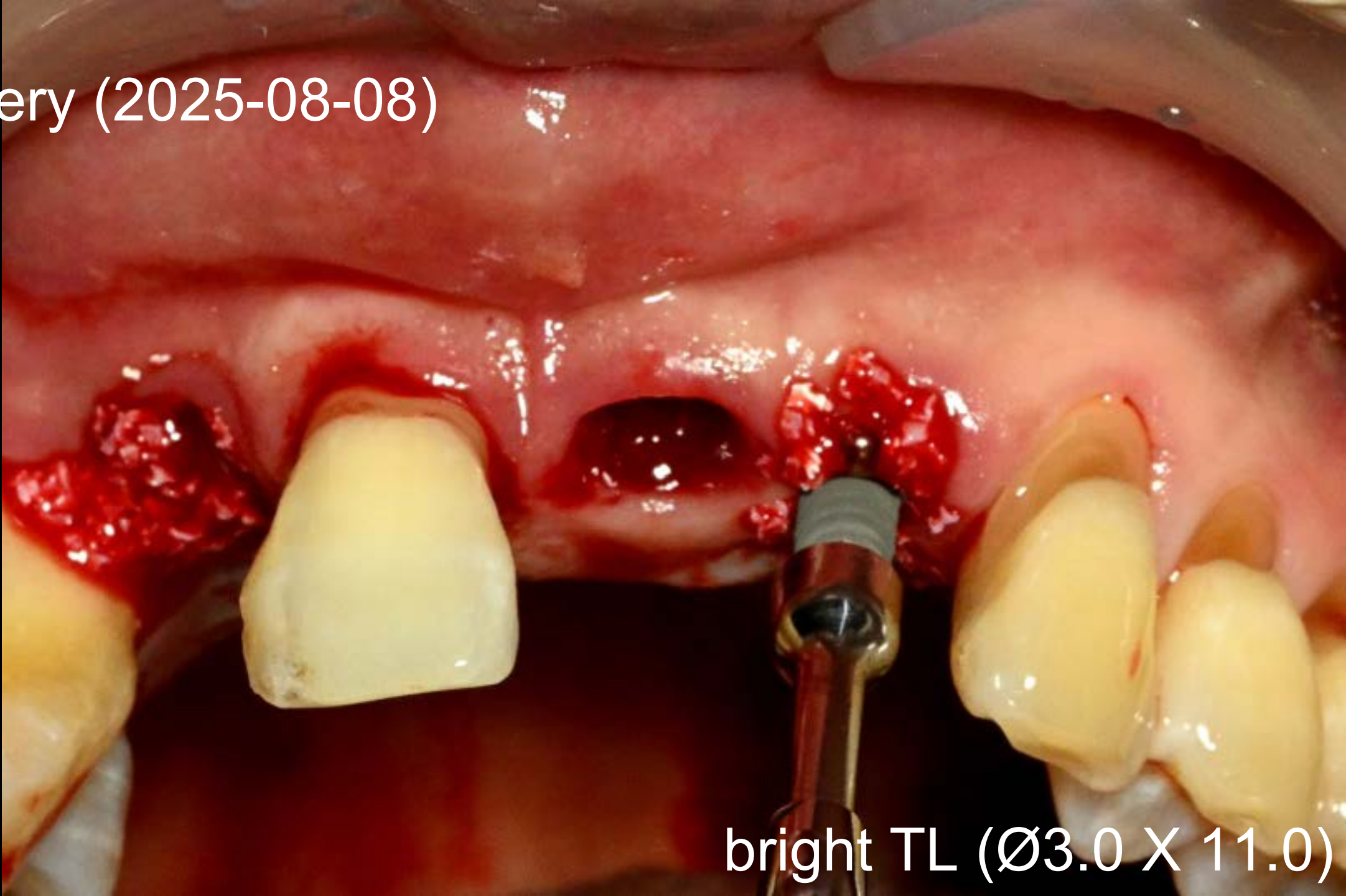


K2 Laser

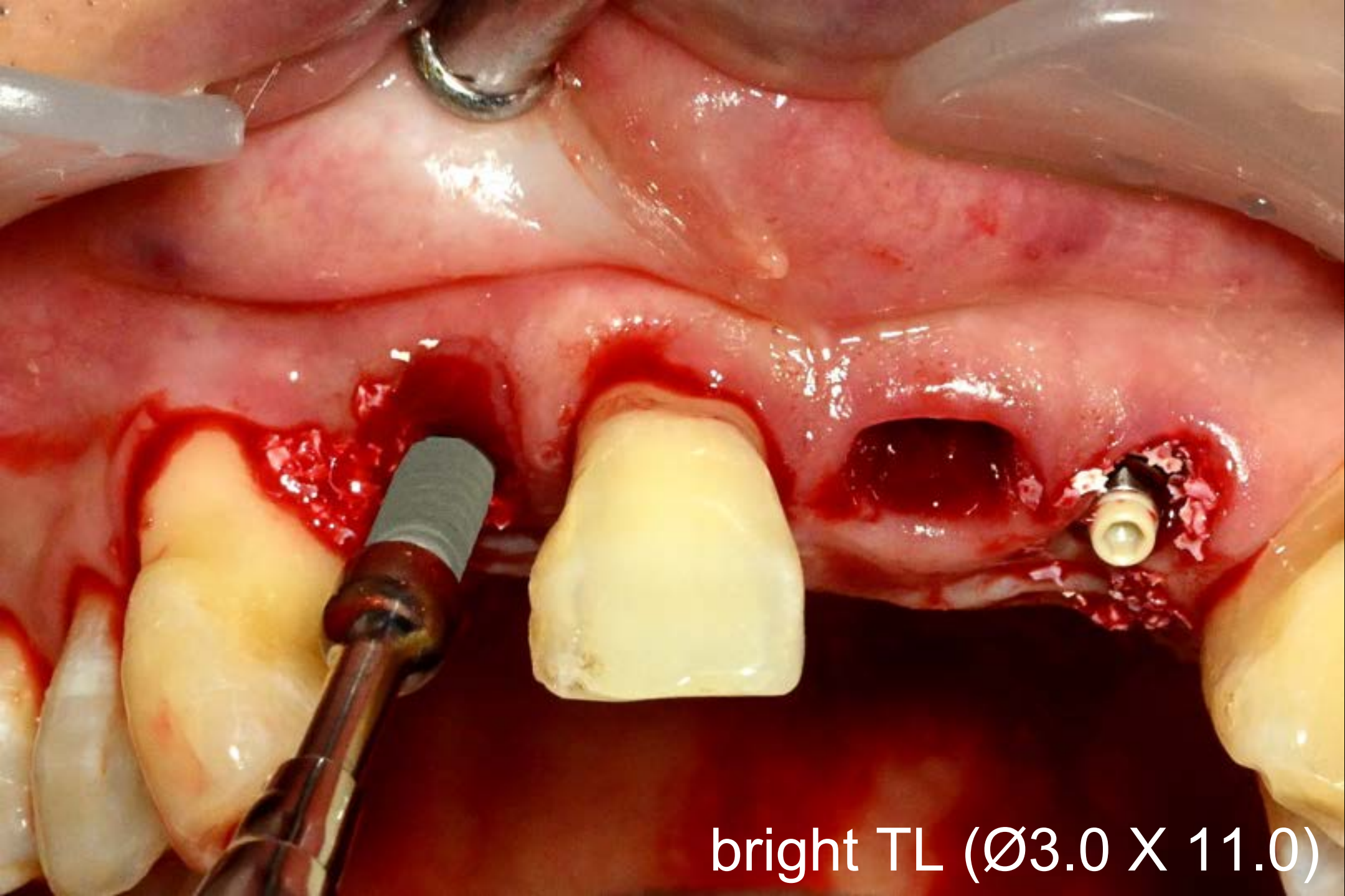
Surgery (2025-08-08)



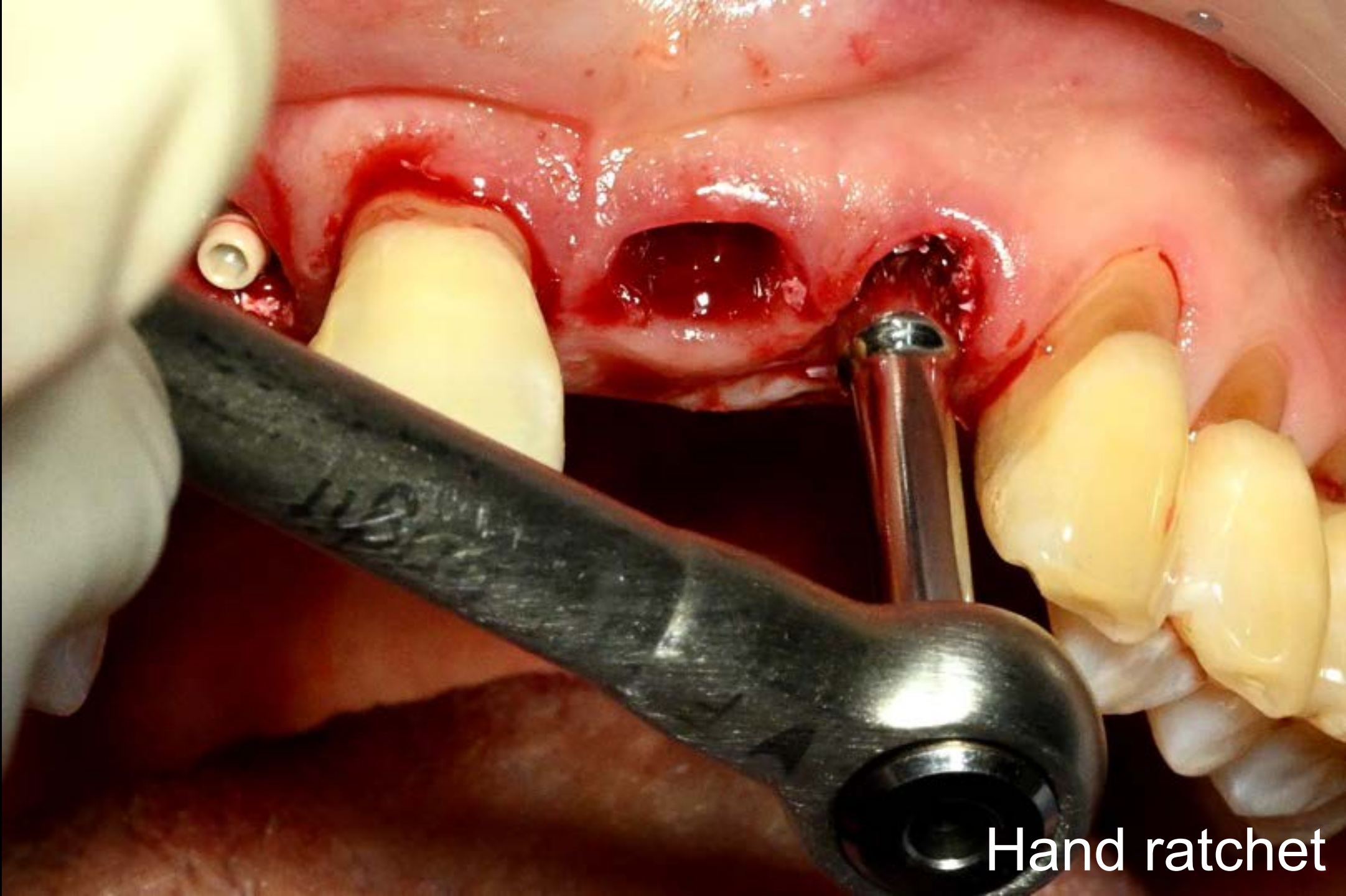Surgery (2025-08-08)



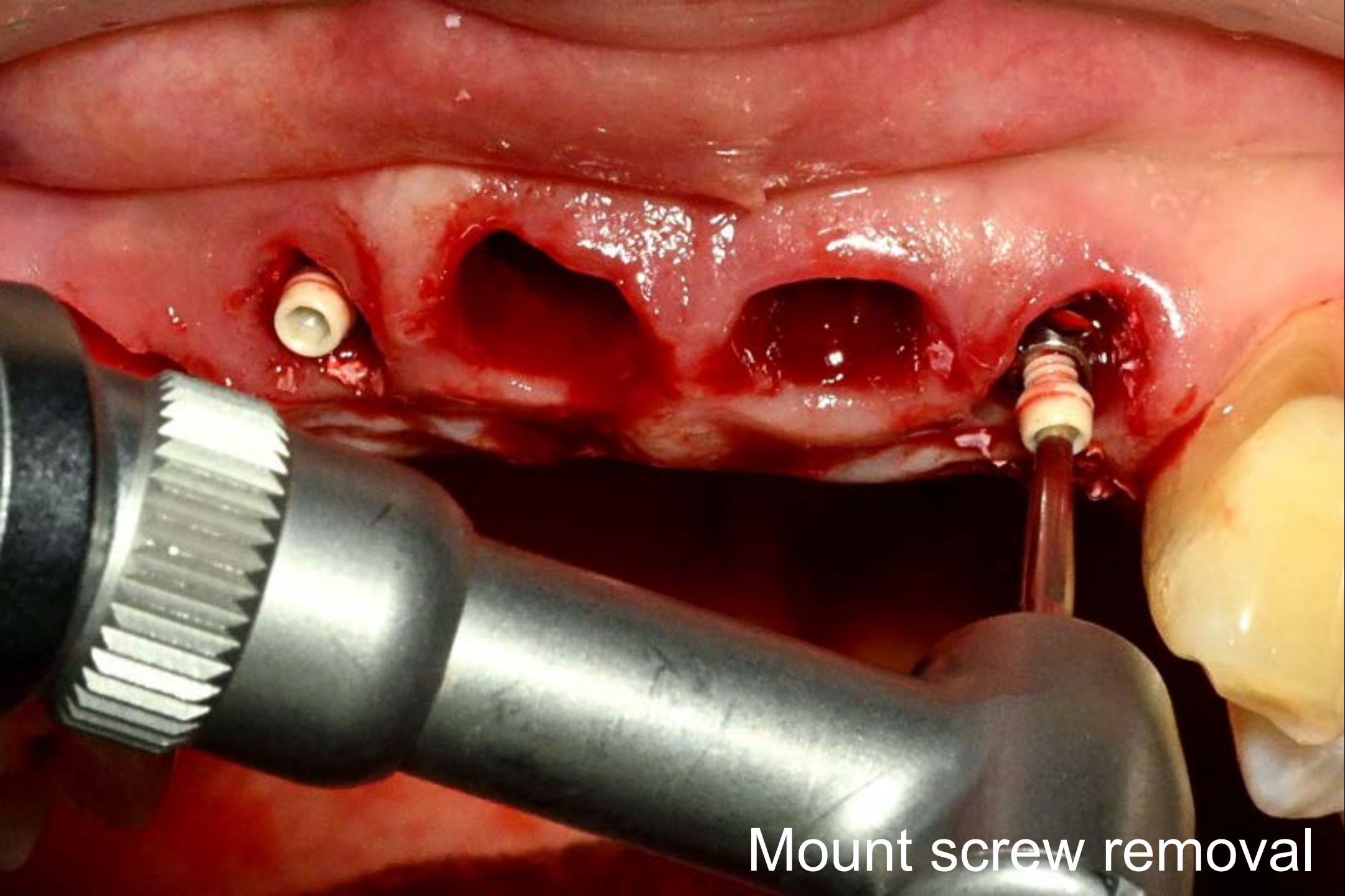
bright TL (Ø3.0 X 11.0)



bright TL (Ø3.0 X 11.0)

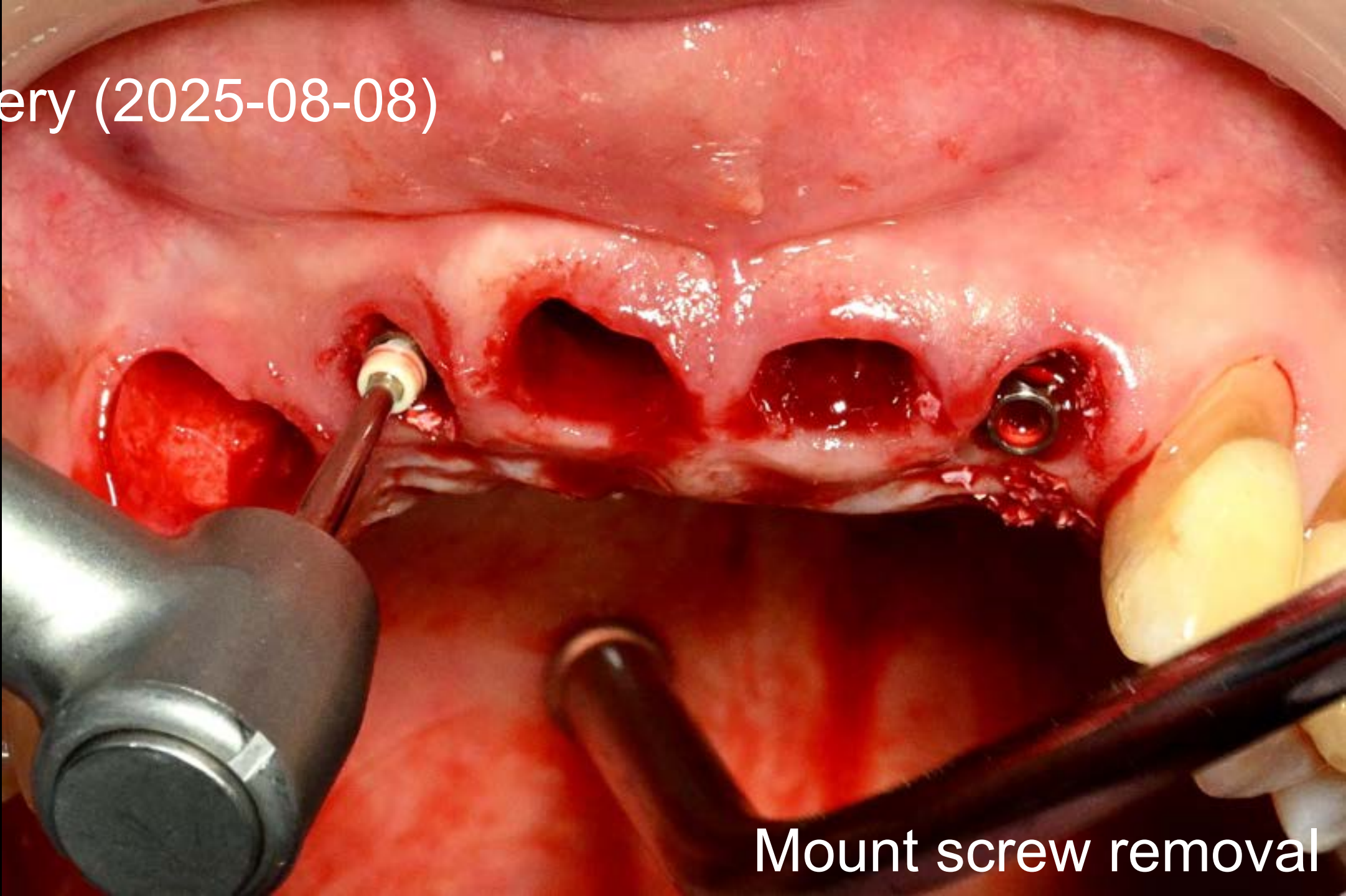

Hand ratchet

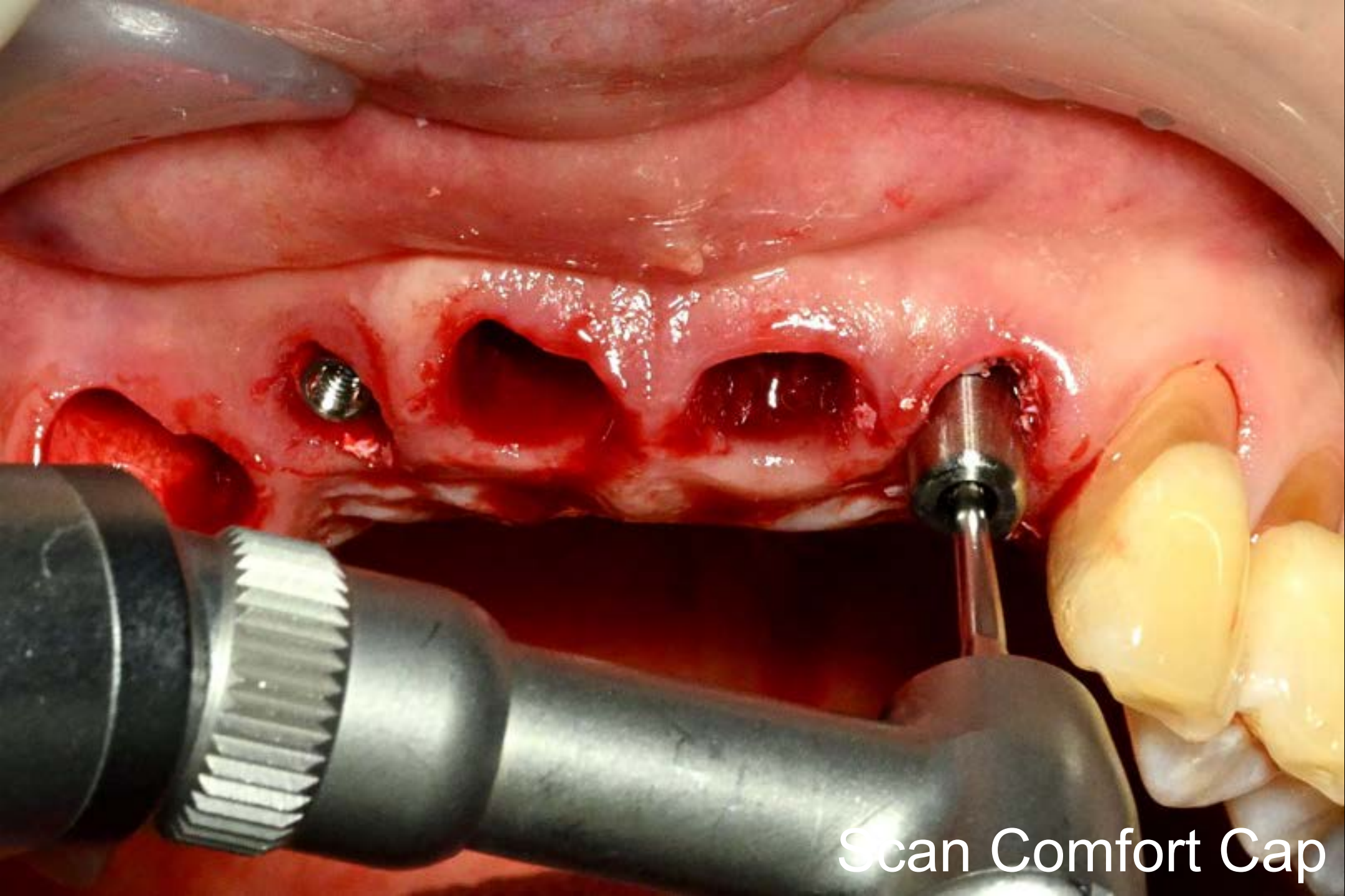


Mount screw removal

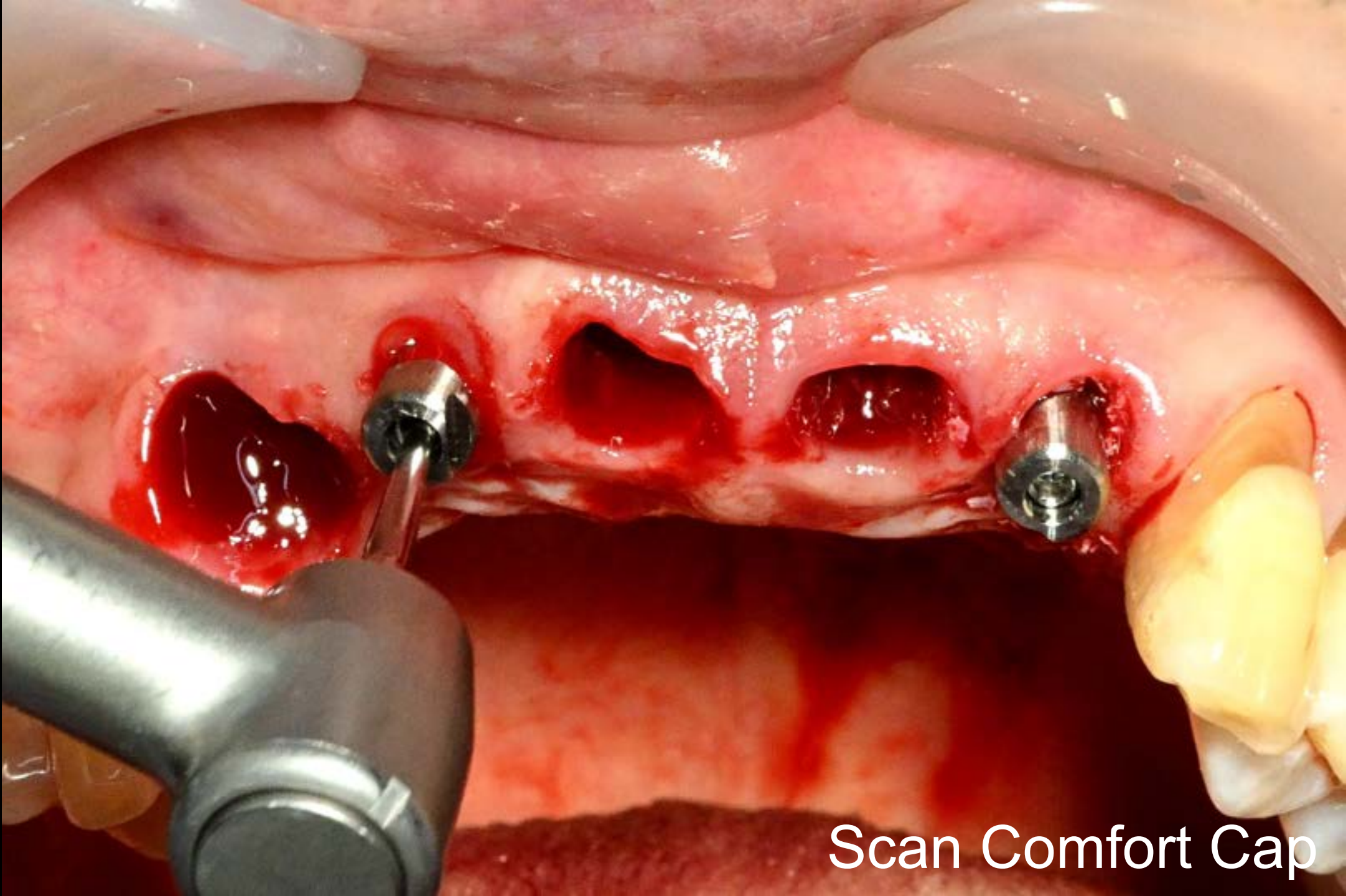
Surgery (2025-08-08)



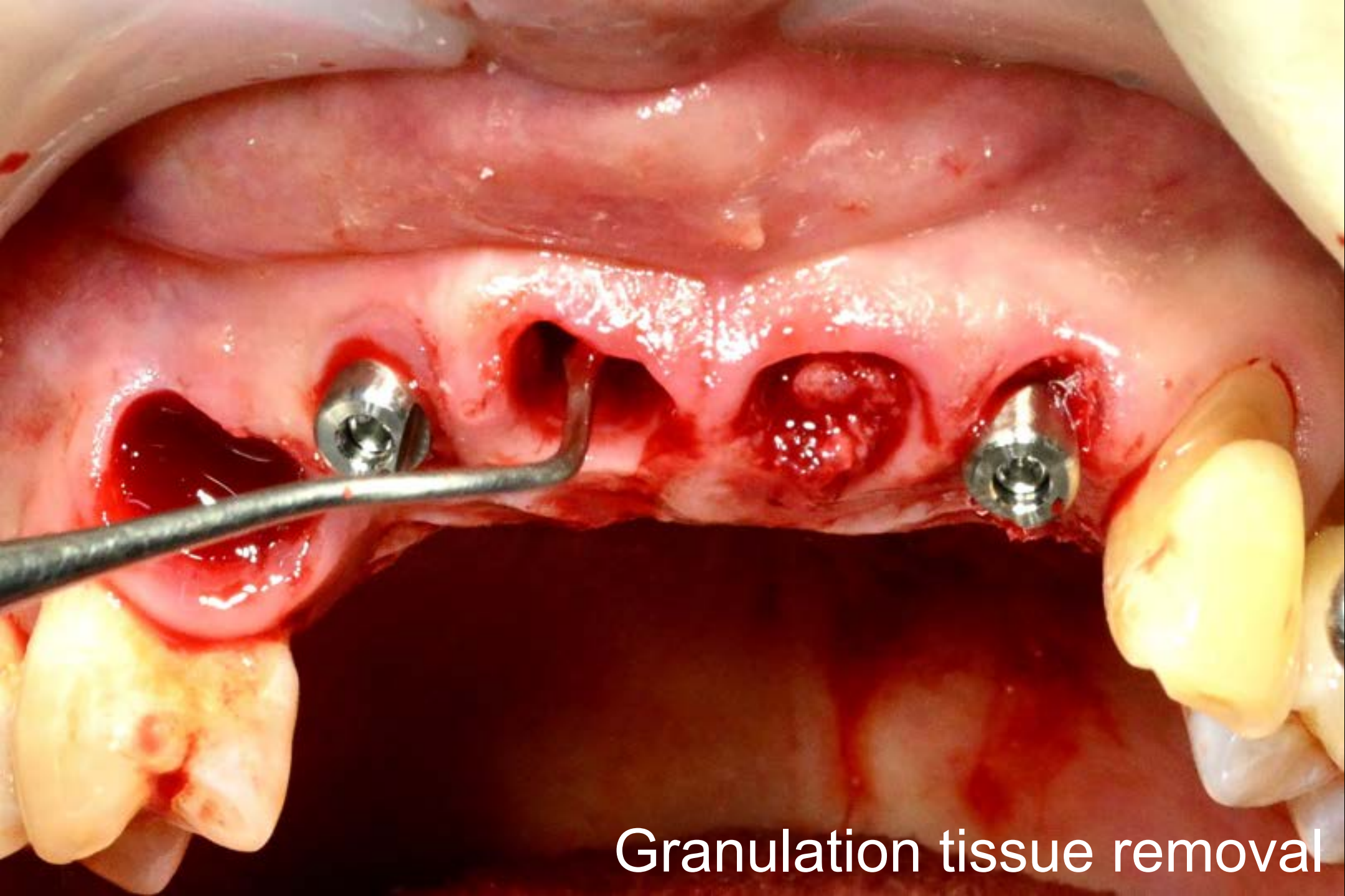
Mount screw removal



Scan Comfort Cap

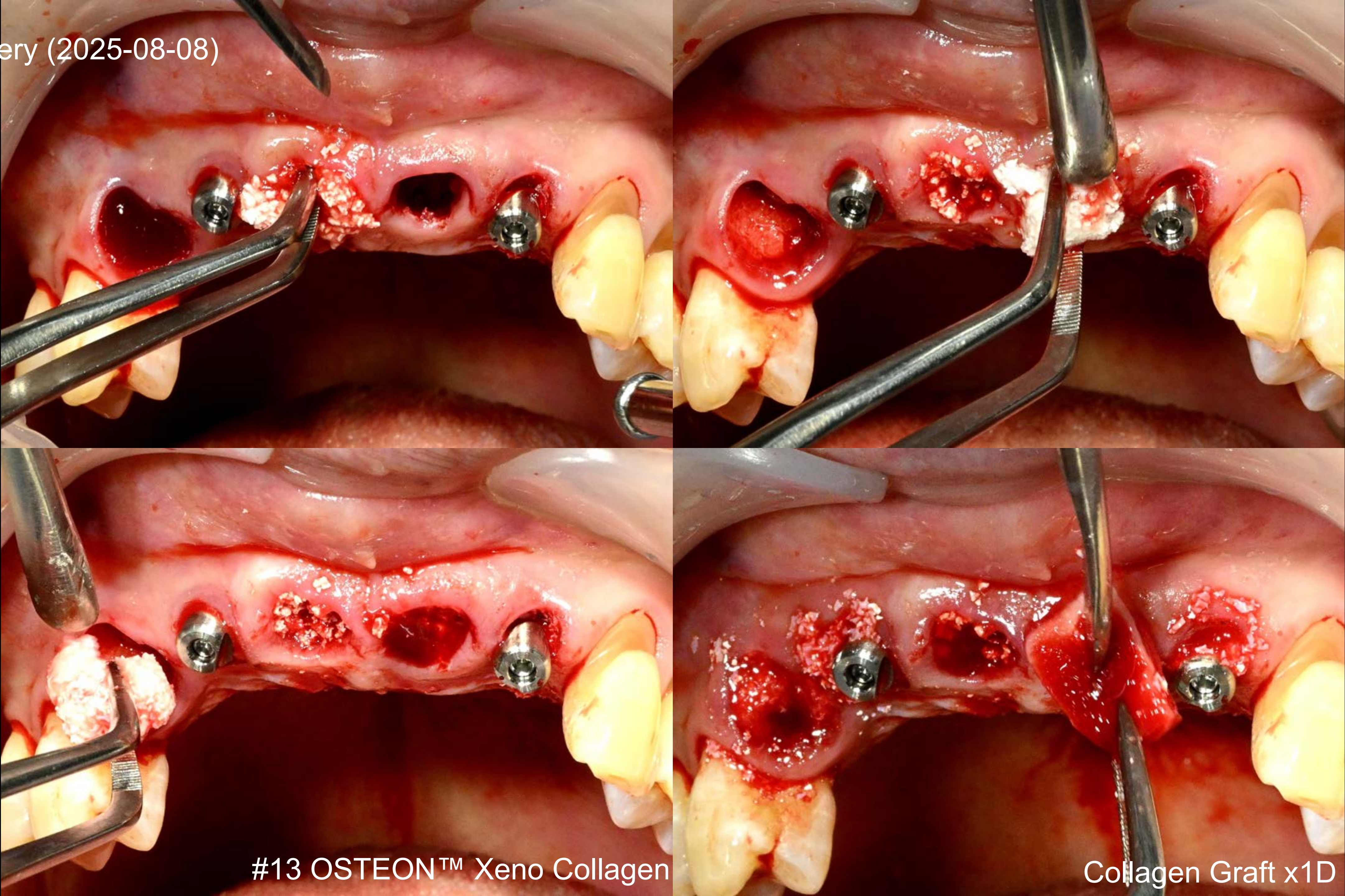


Scan Comfort Cap



Granulation tissue removal

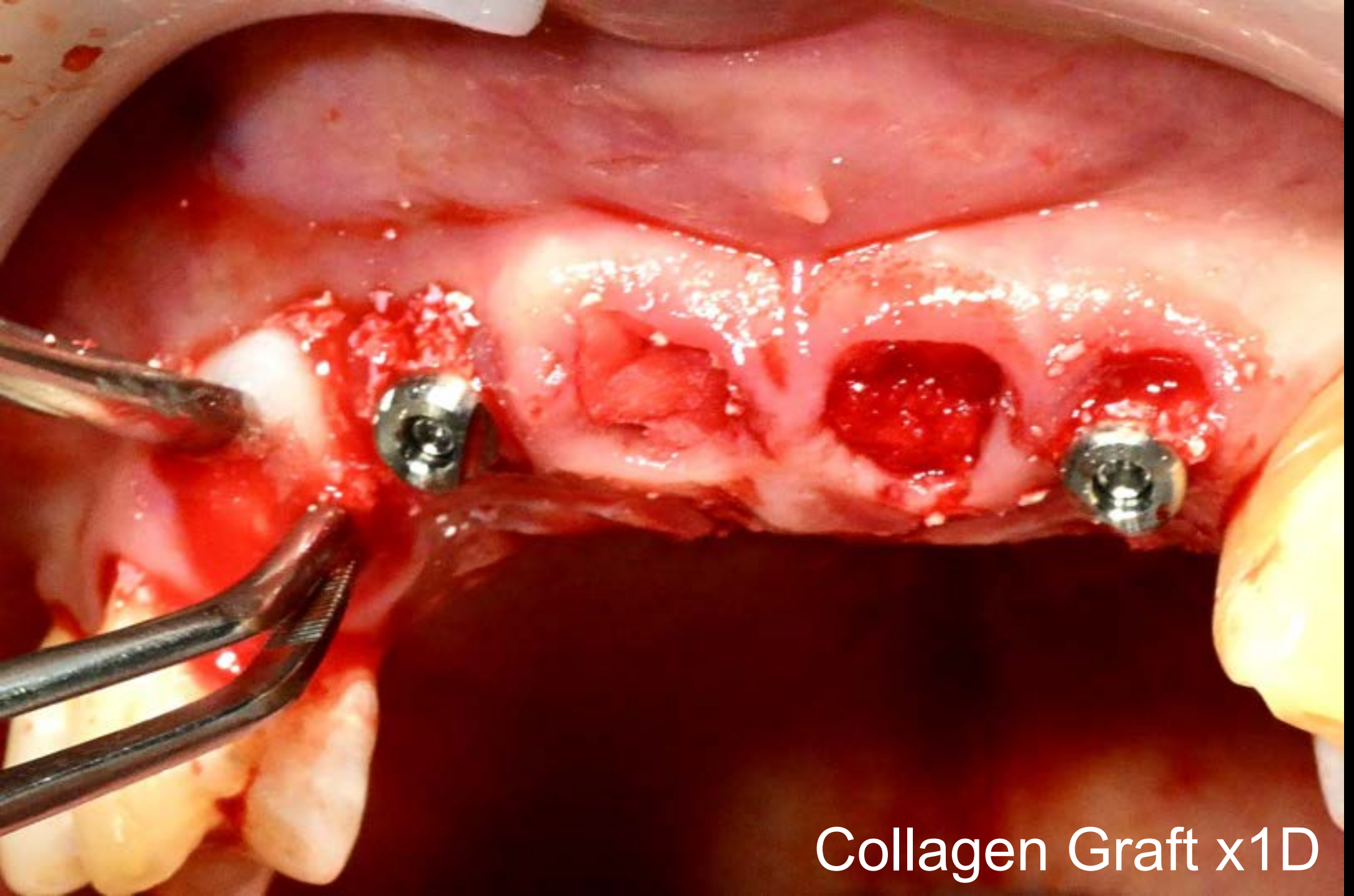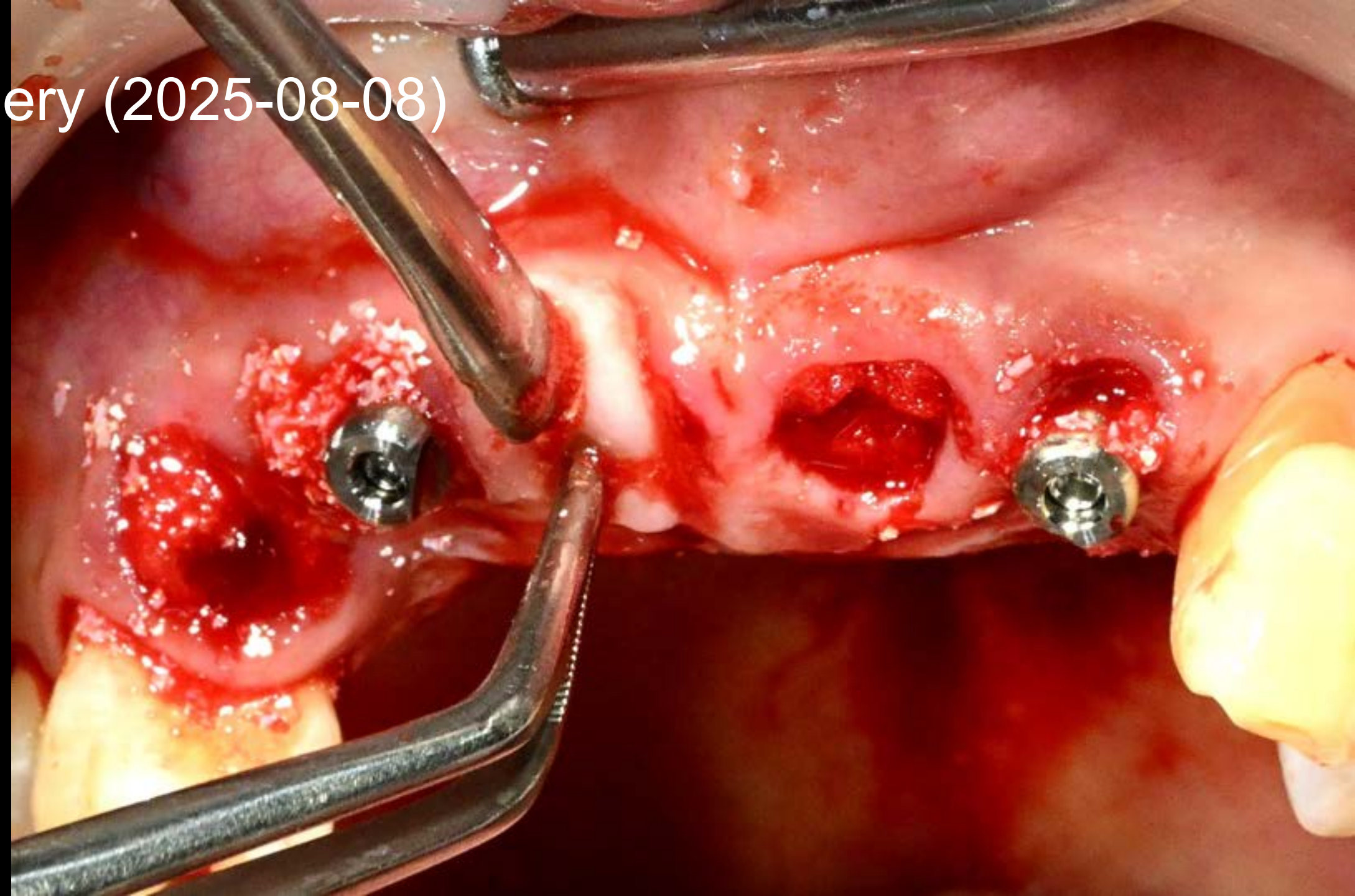
Surgery (2025-08-08)



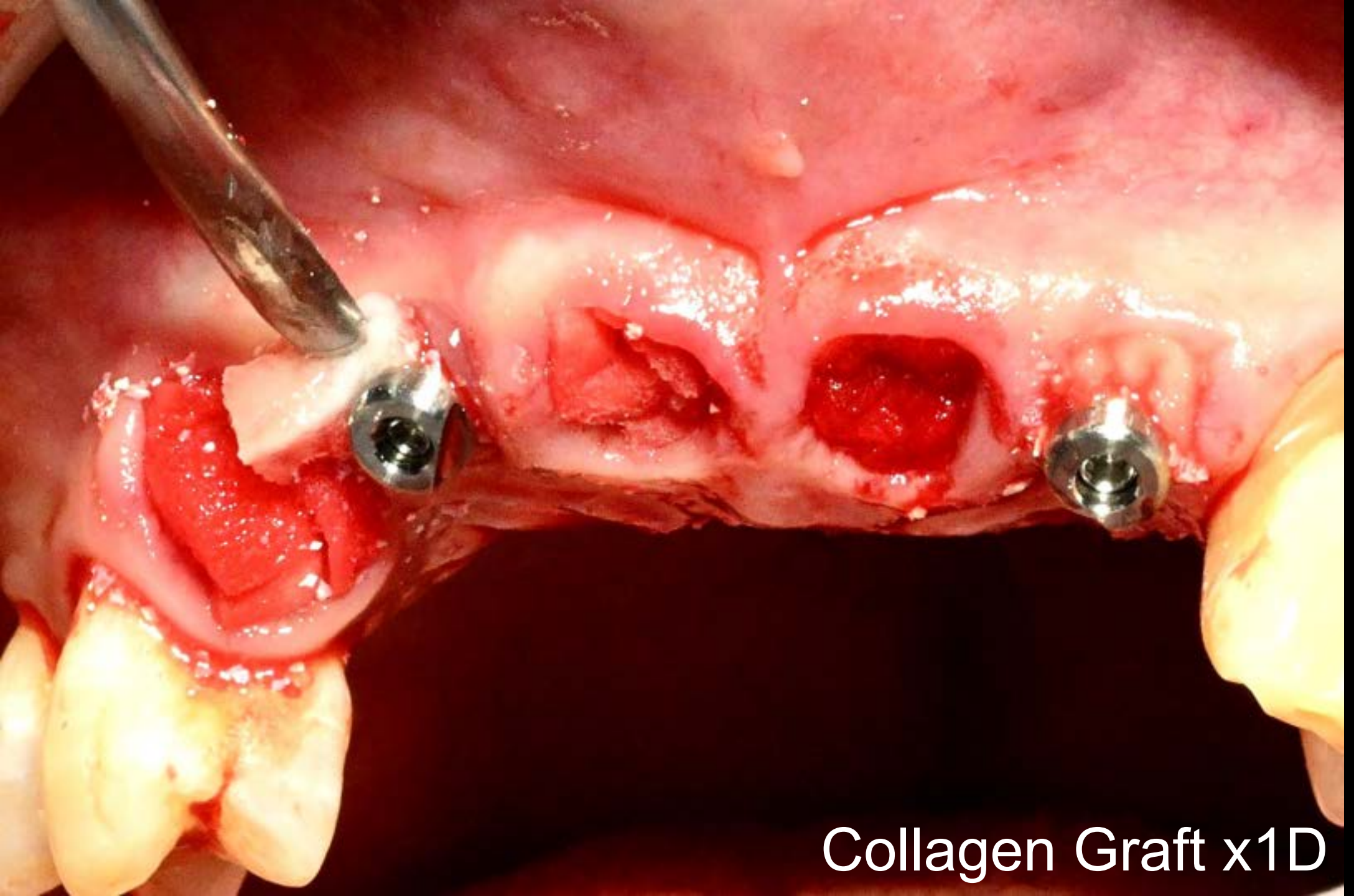
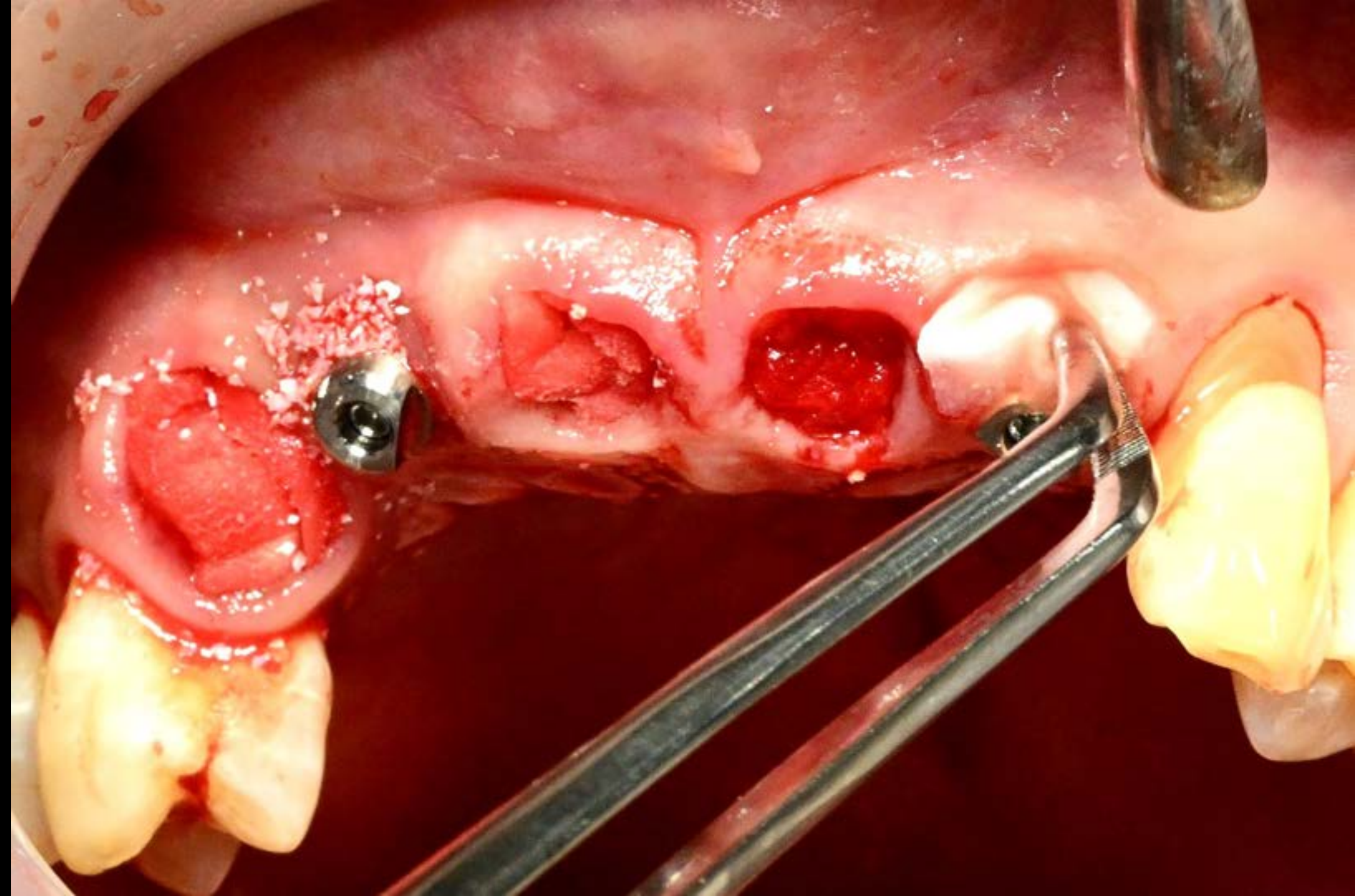
#13 OSTEON™ Xeno Collagen

Collagen Graft x1D

Surgery (2025-08-08)

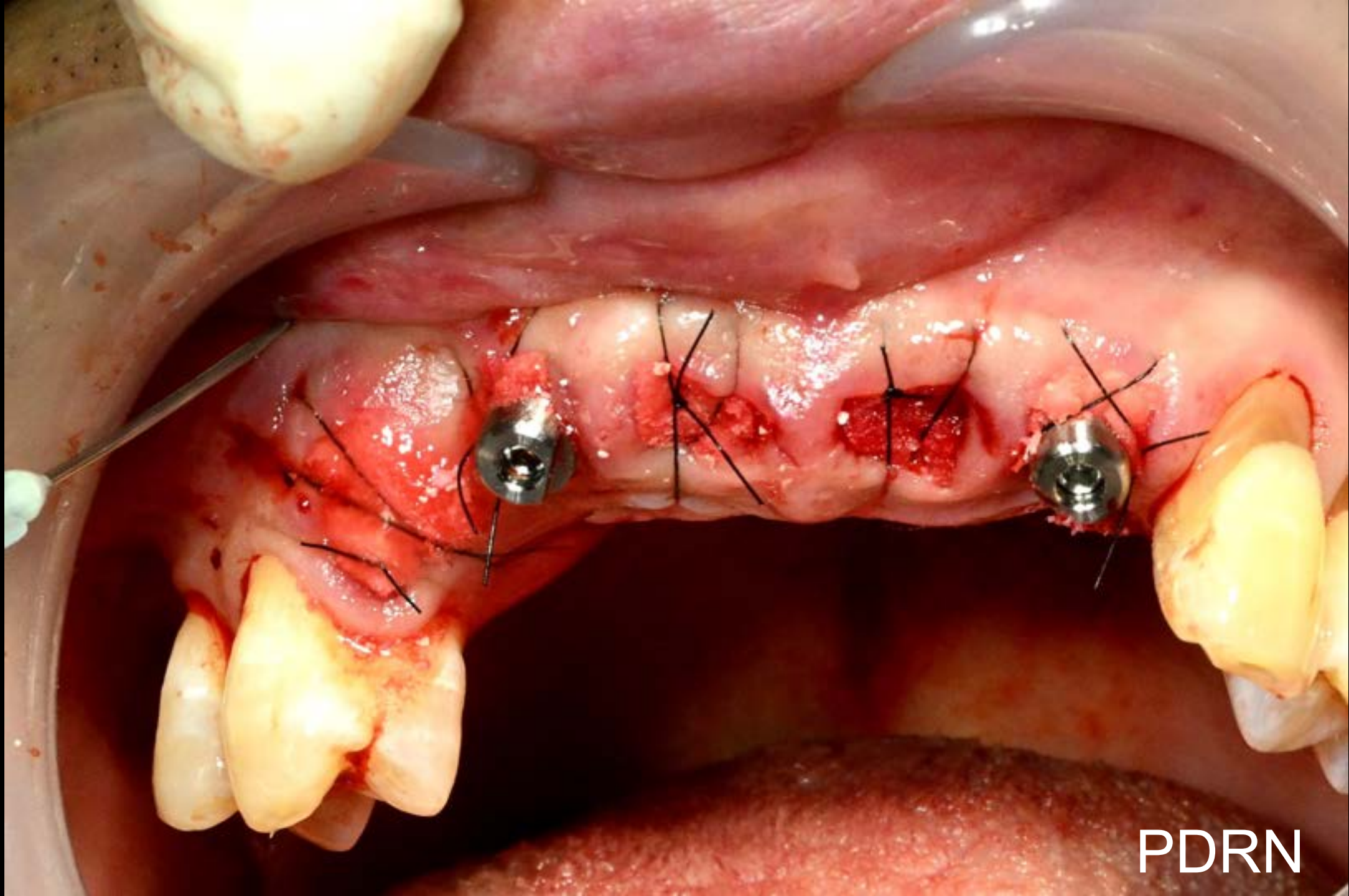
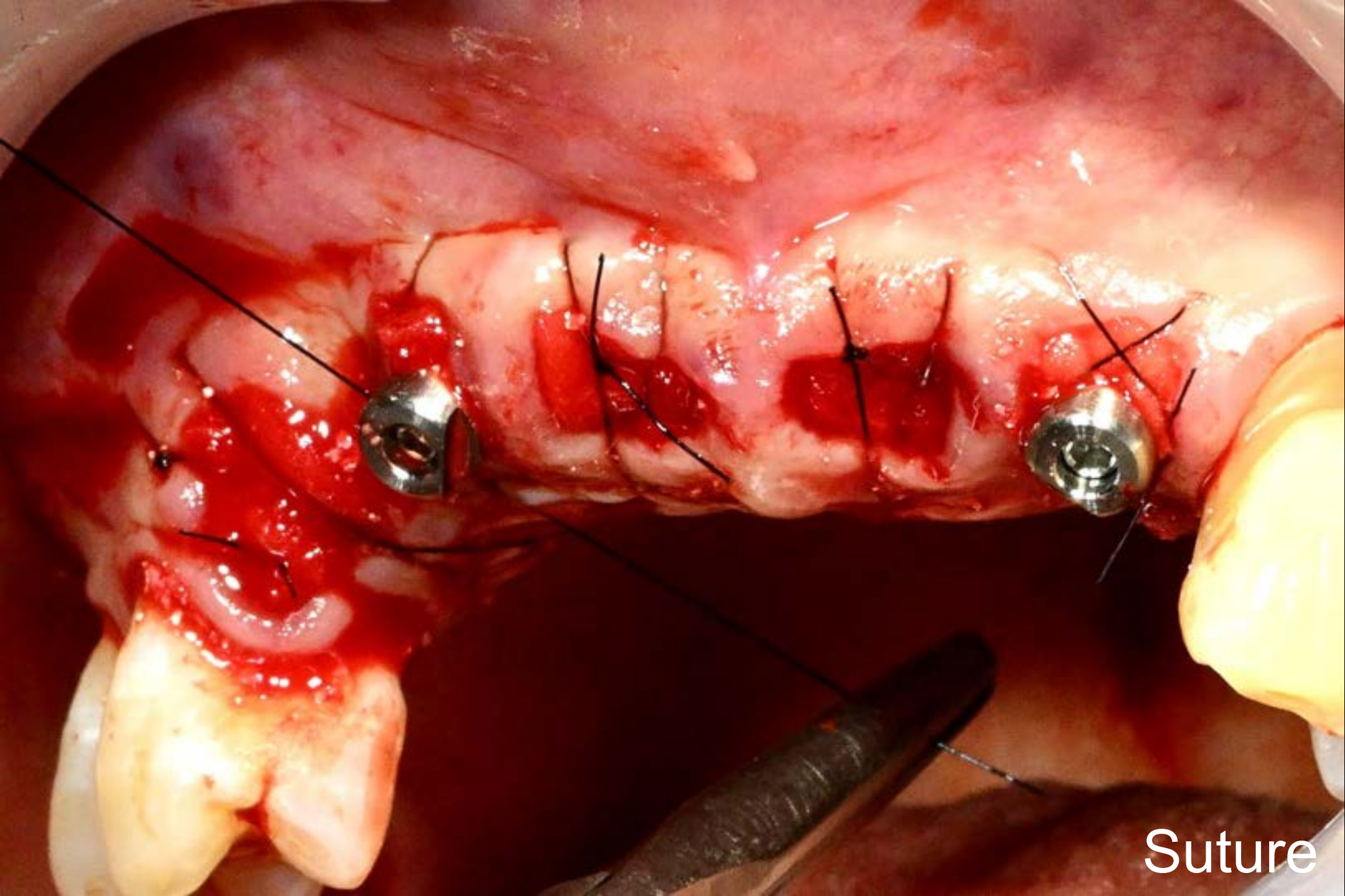
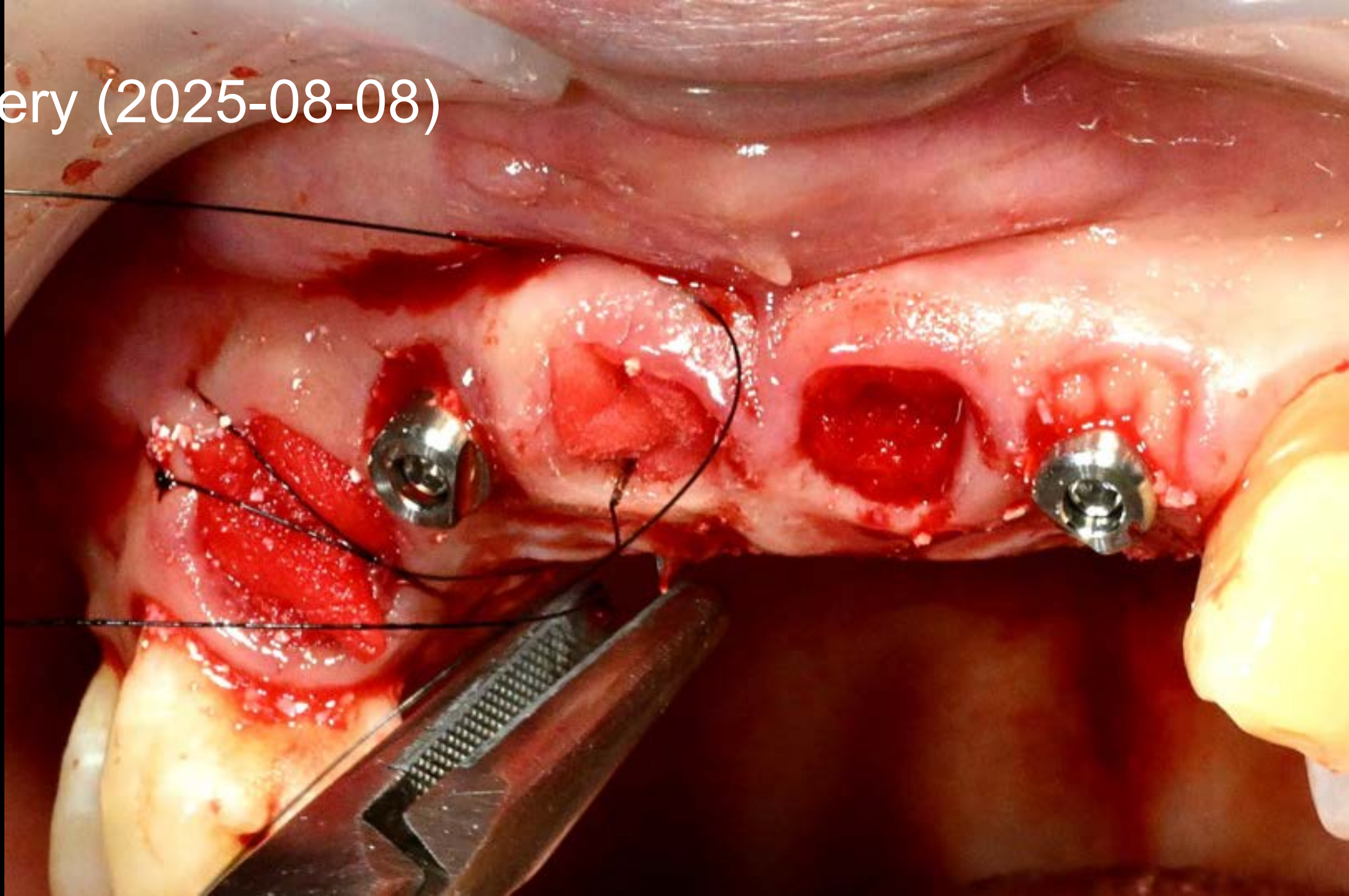


Collagen Graft x1D

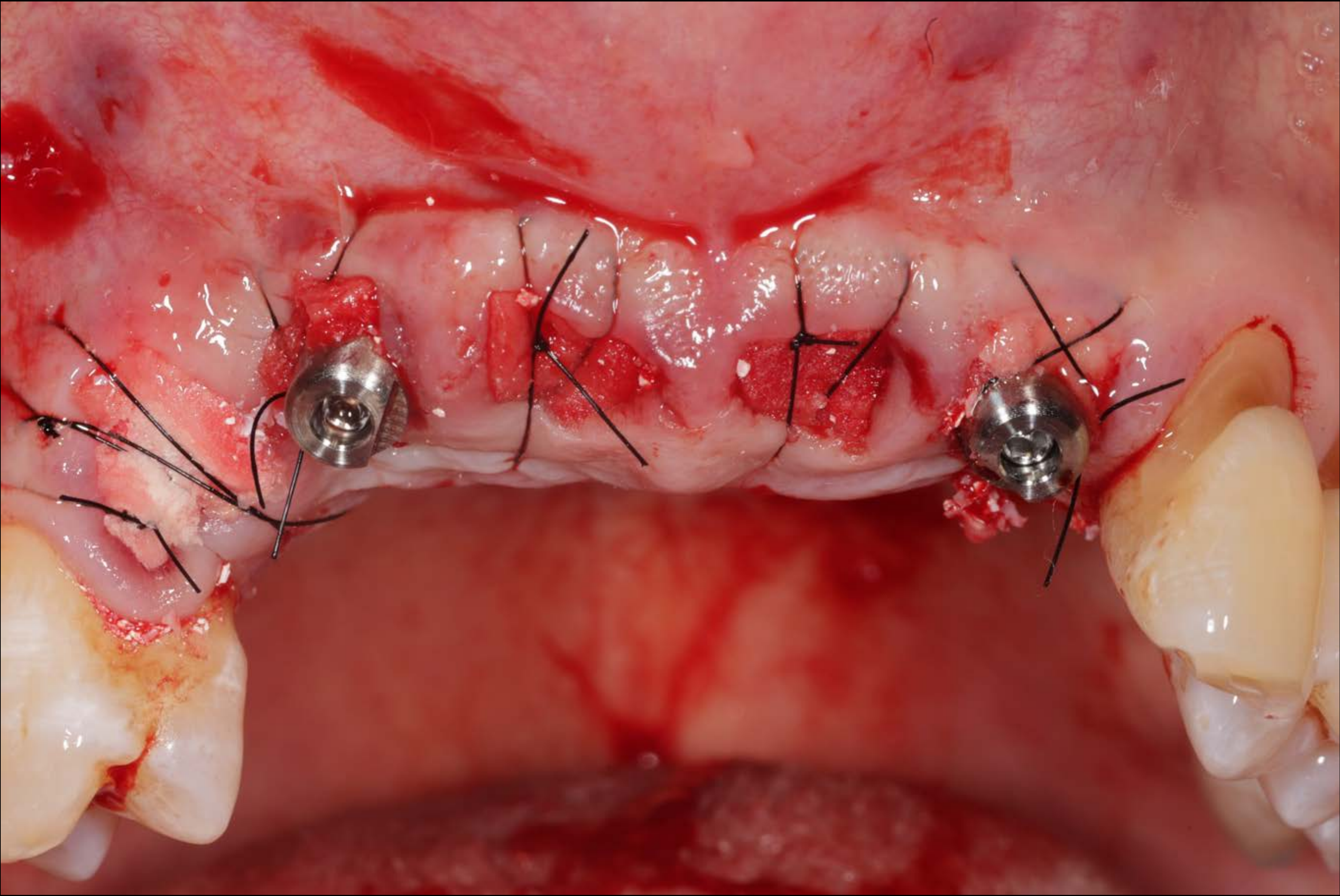


Collagen Graft x1D

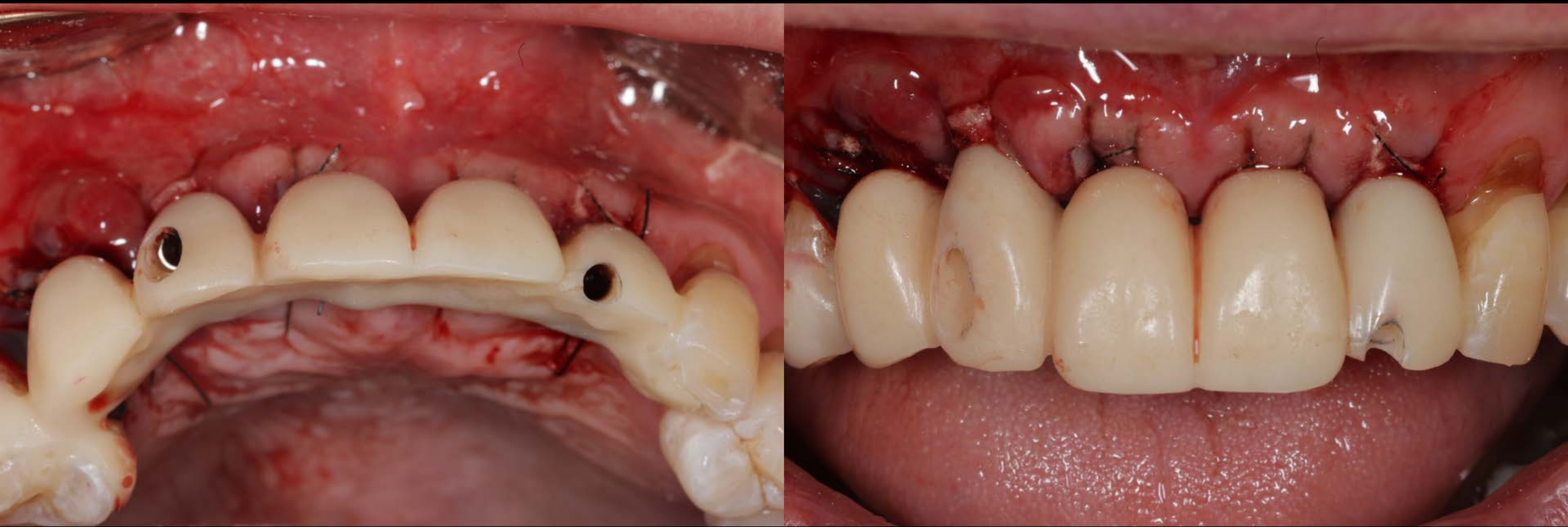
Surgery (2025-08-08)



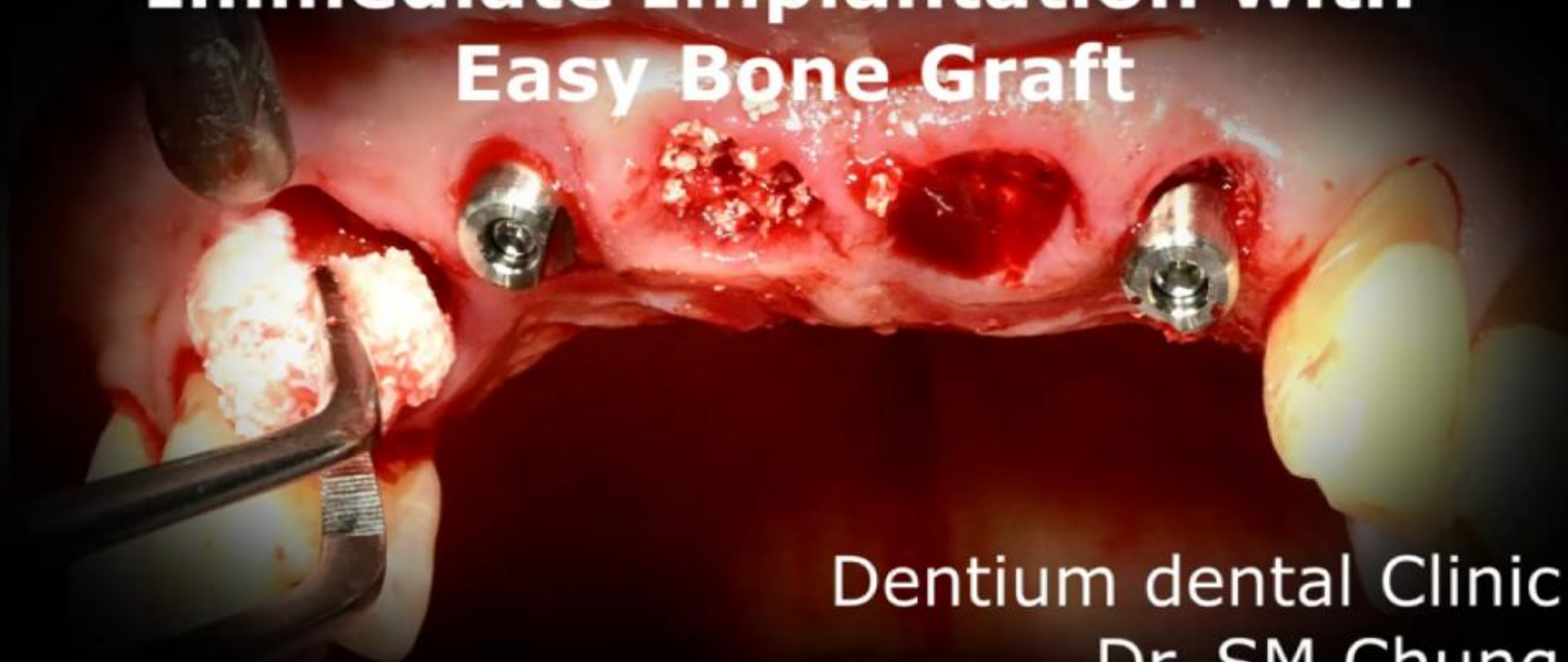Post-op (2025-08-08)



Provisional restoration (2025-08-08)

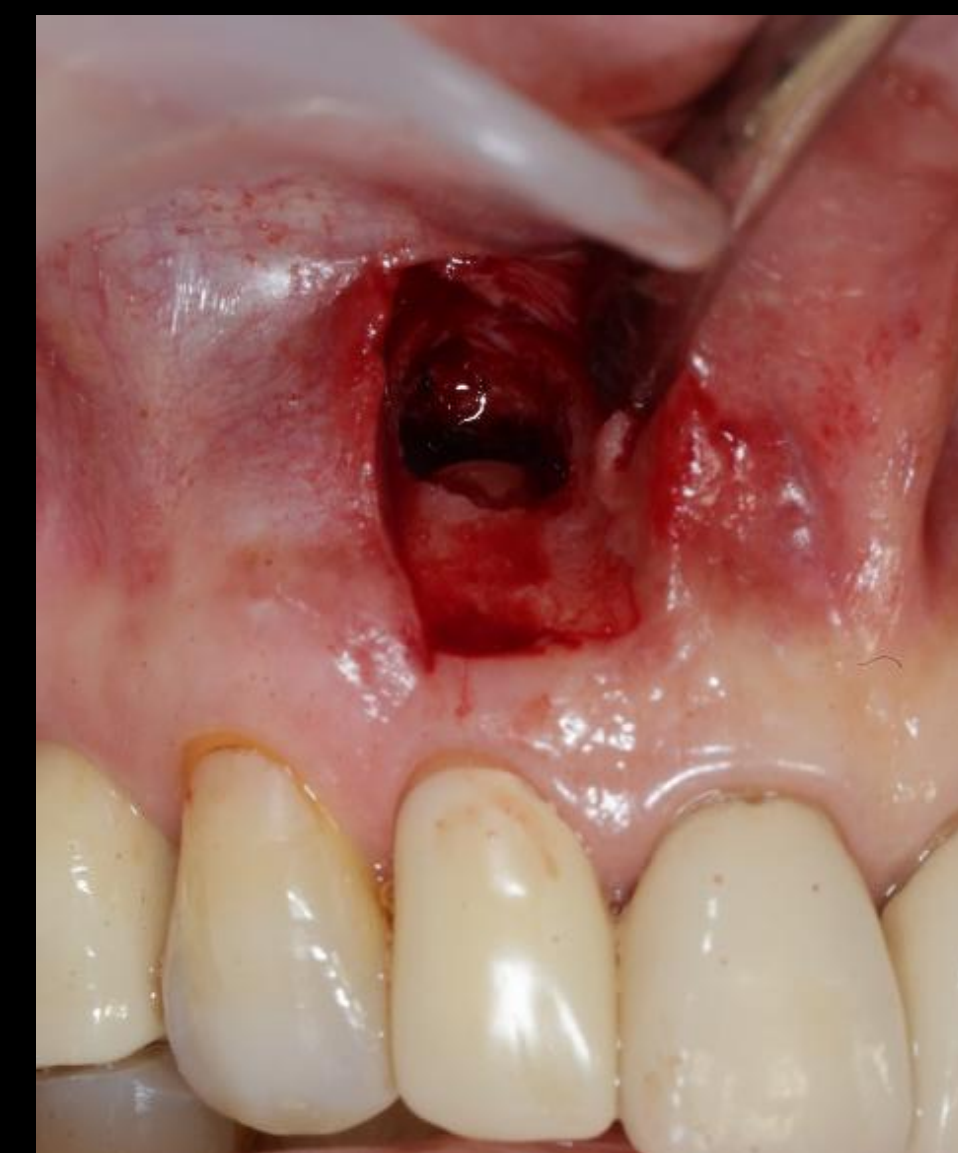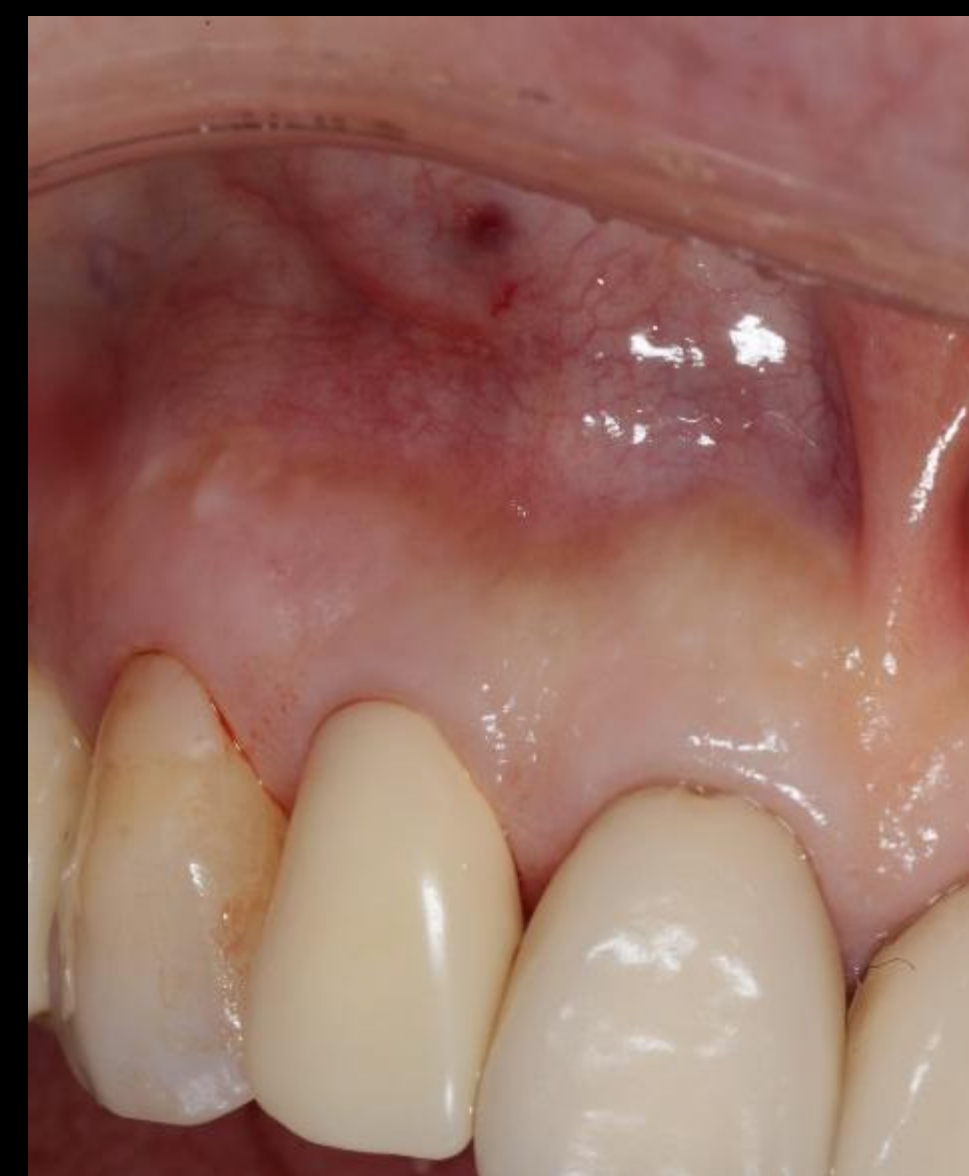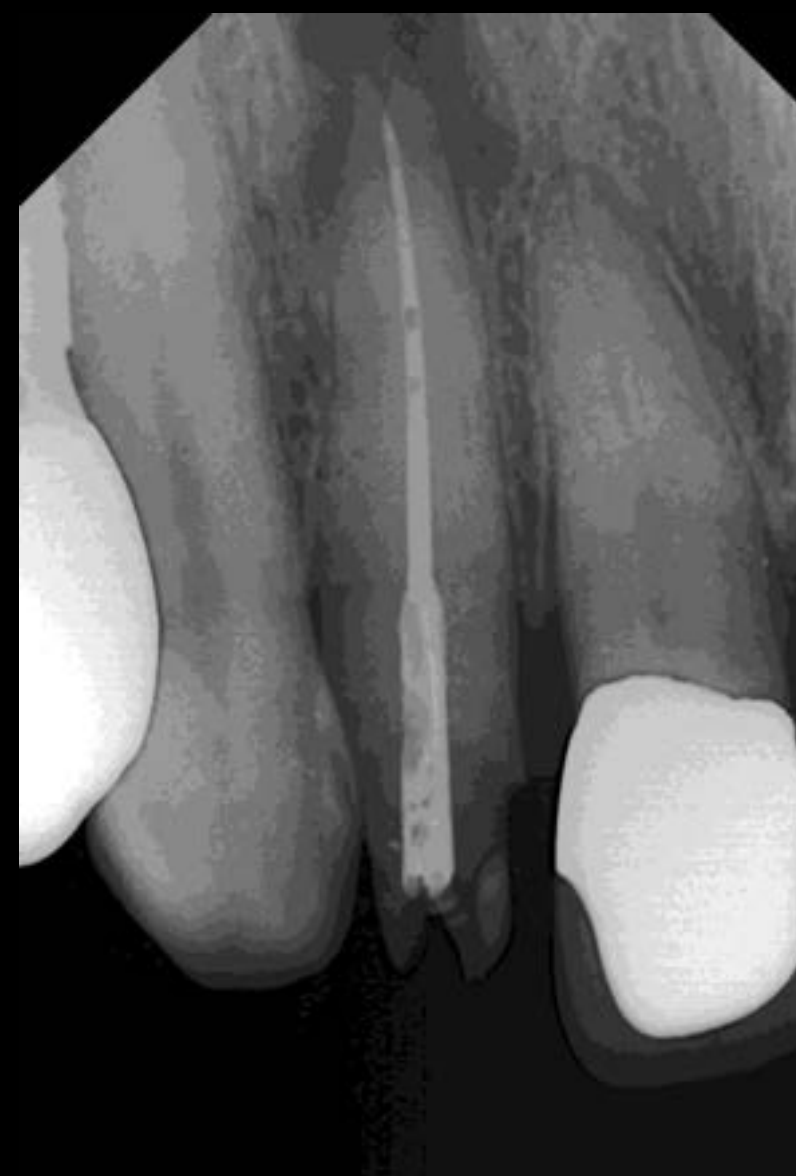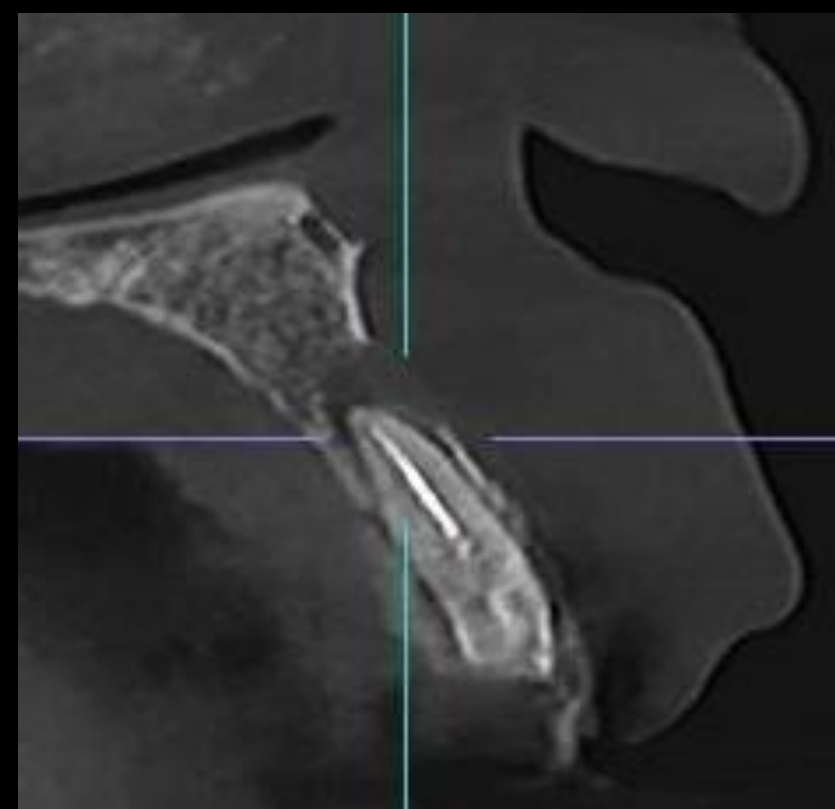


Immediate Implantation with Easy Bone Graft

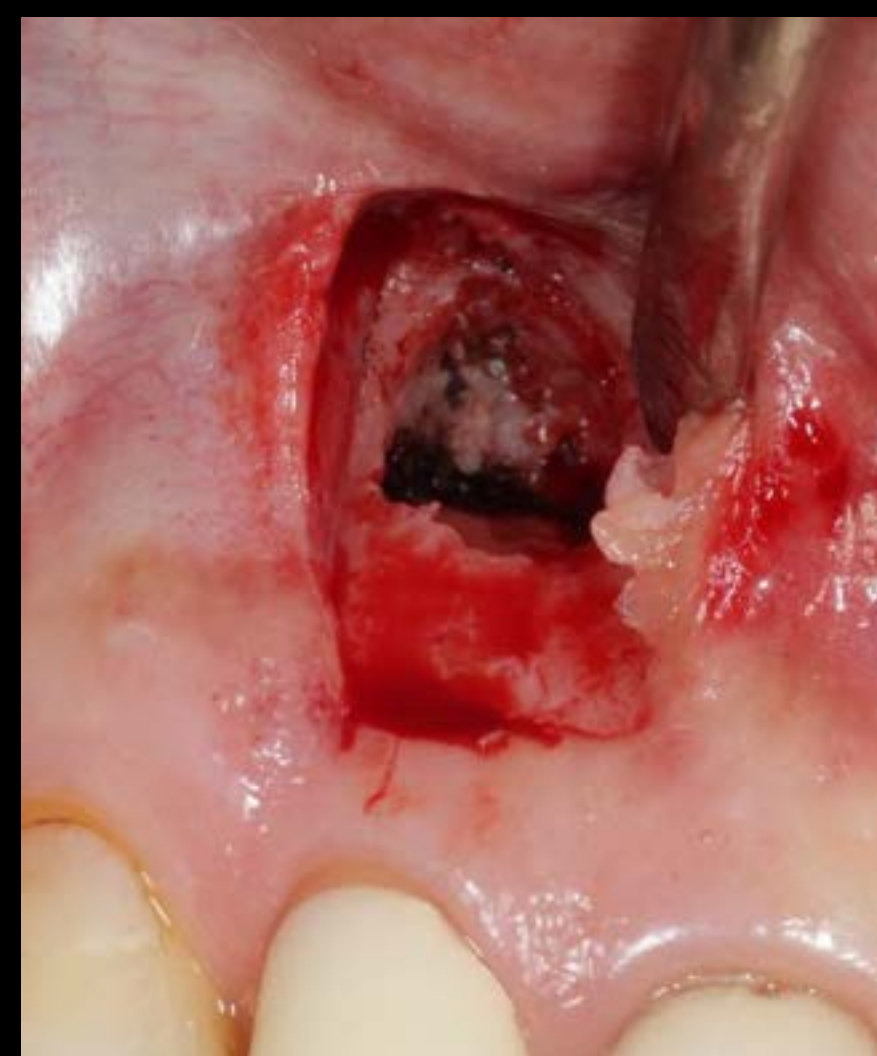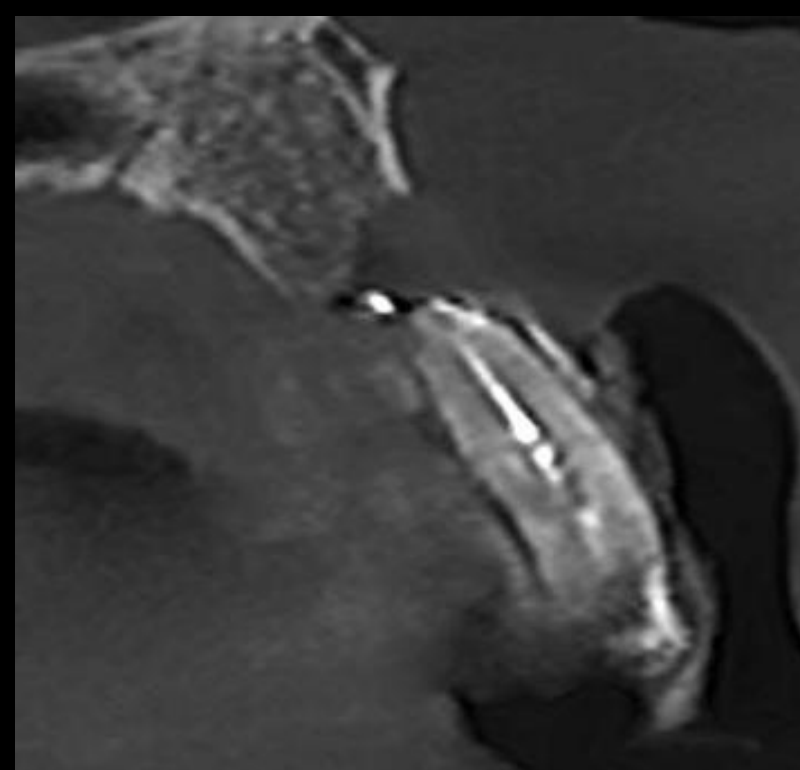


Dentium dental Clinic
Dr. SM Chung

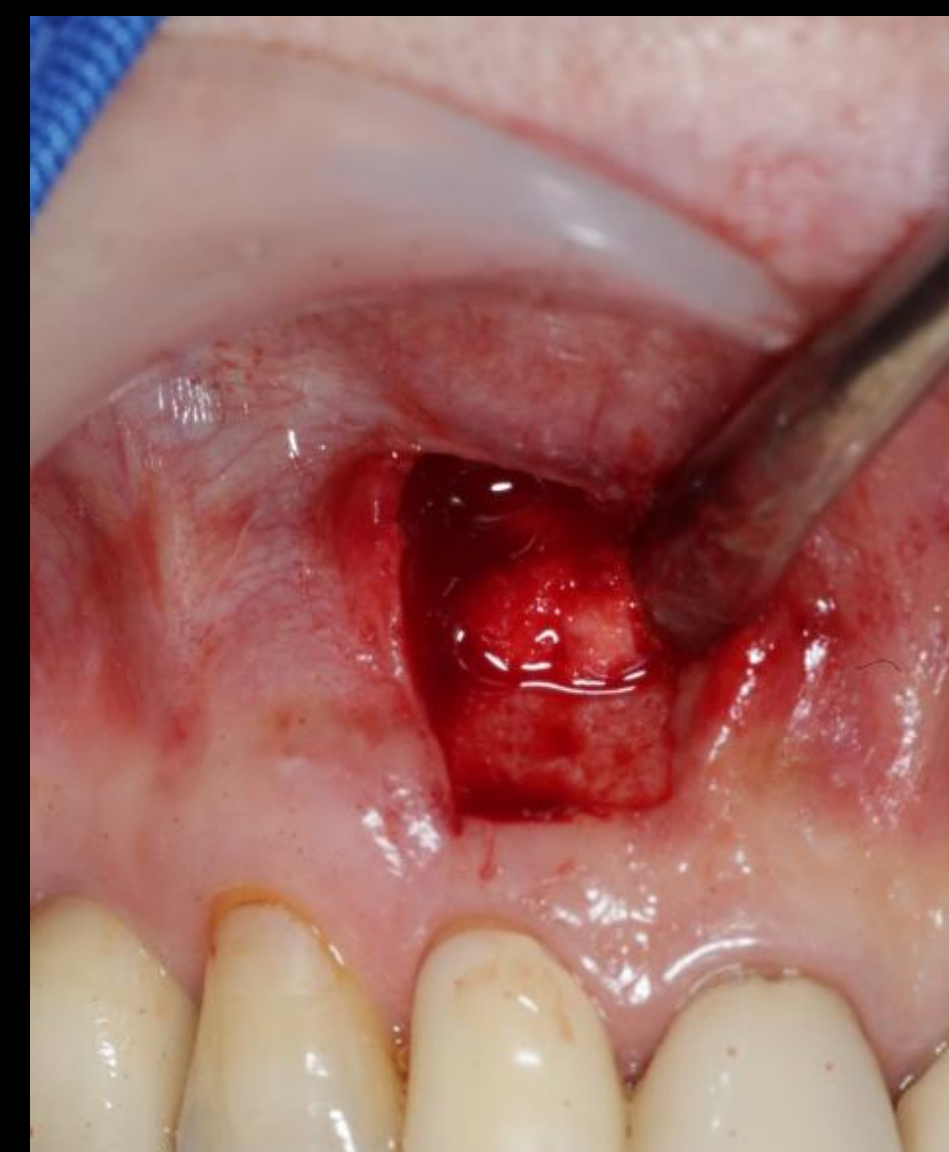Pre-OP CT



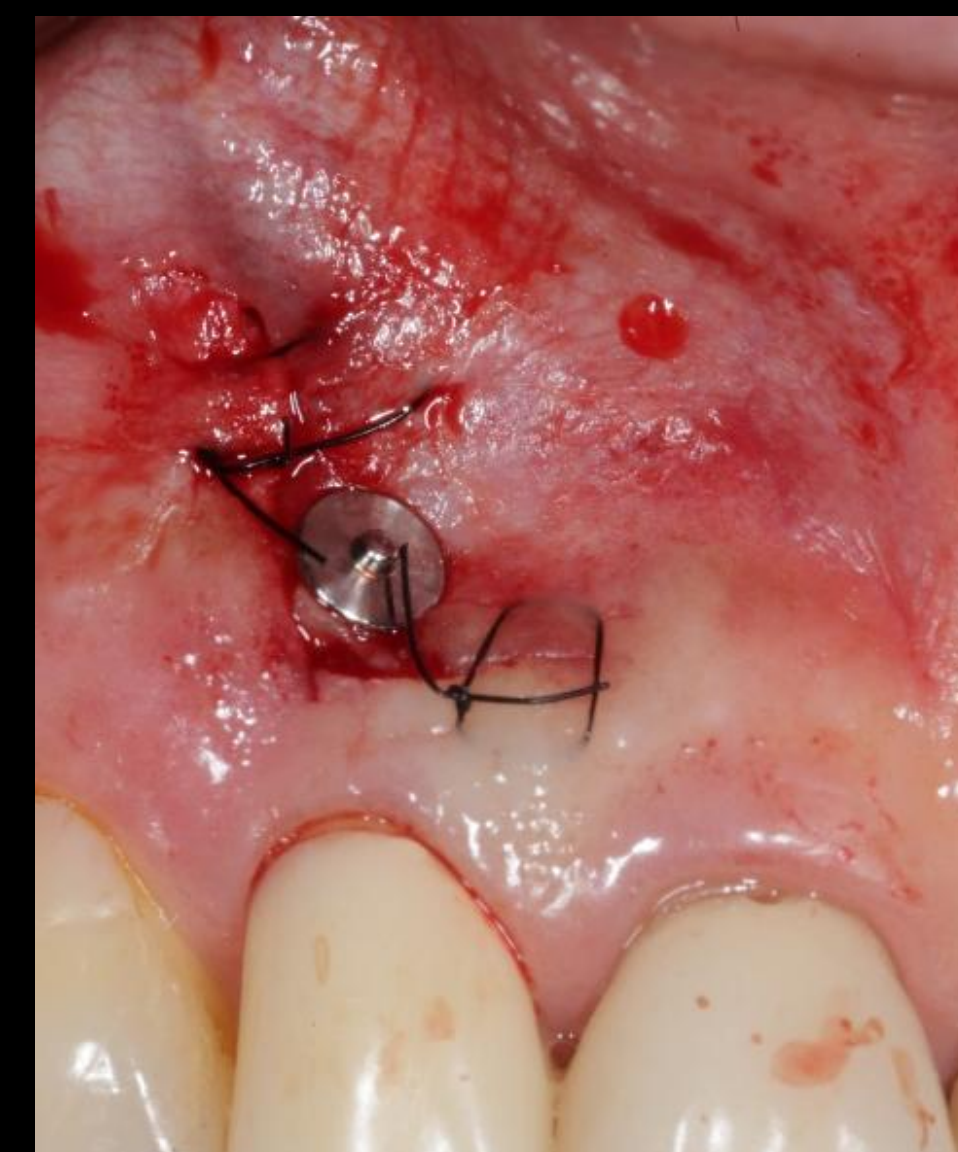
Post-OP CT

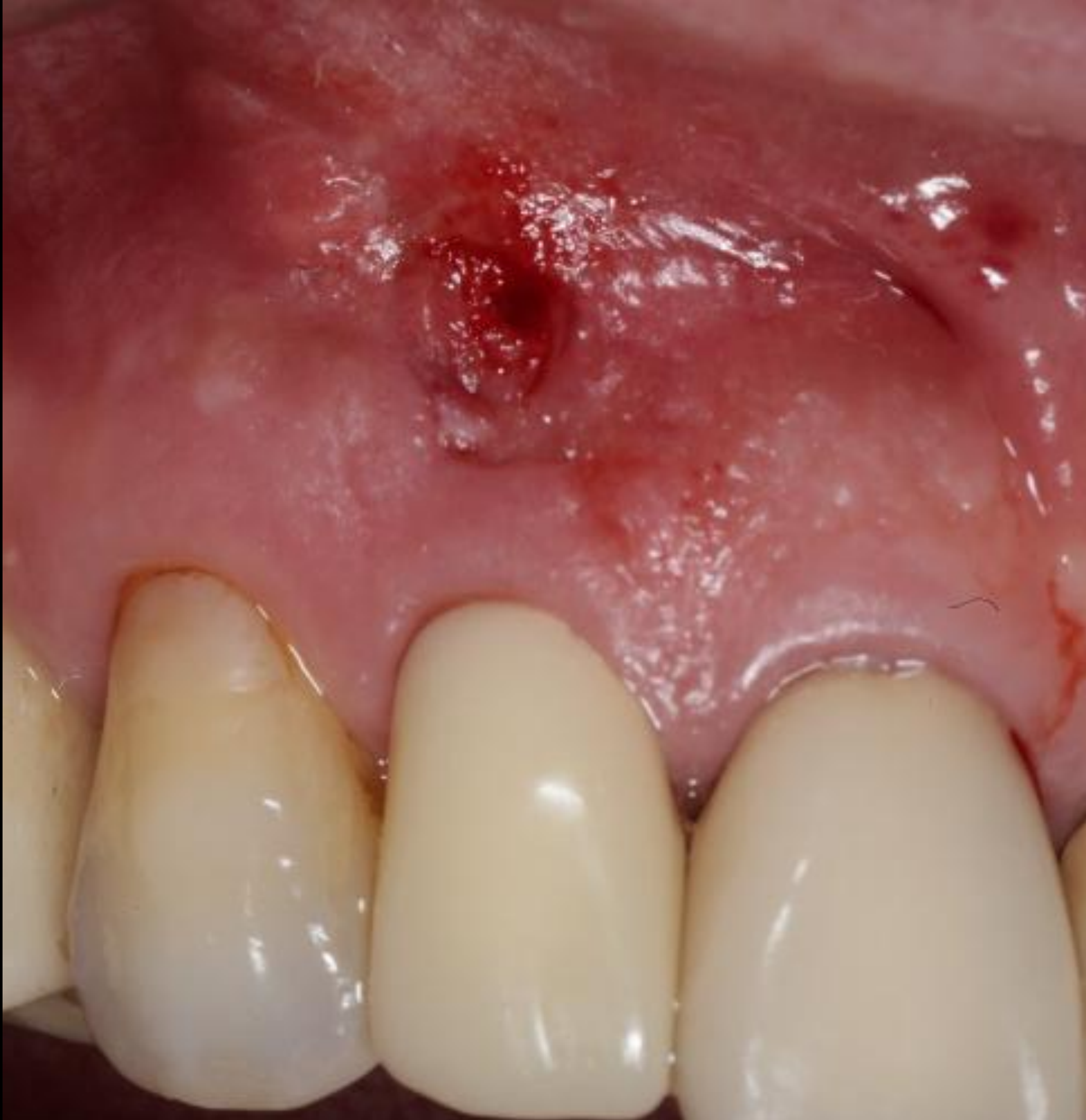

Collagen Graft x1D

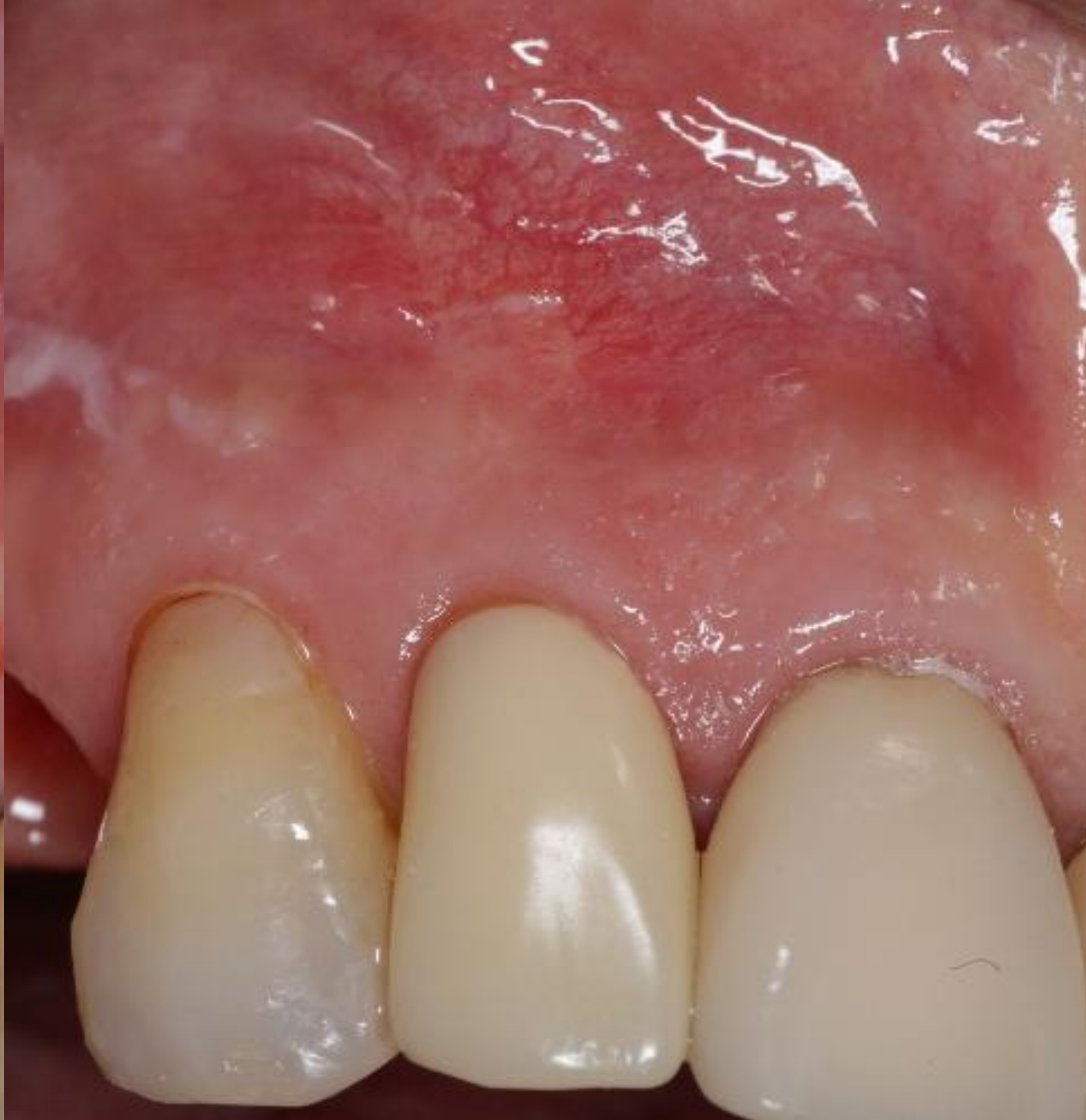

Suture & PIN





1 week



4 weeks later

An intraoperative photograph showing a surgical site in the mouth. A dental handpiece is visible on the left, and a surgical instrument is being used to perform a procedure on the tissue. The text "Apicoectomy to preserve natural teeth" is overlaid in white.

Apicoectomy to preserve natural teeth

Dentium Dental Clinic
Dr. SM Chung

**** 258p Surgery VOD 7**

Contents

Bright implant

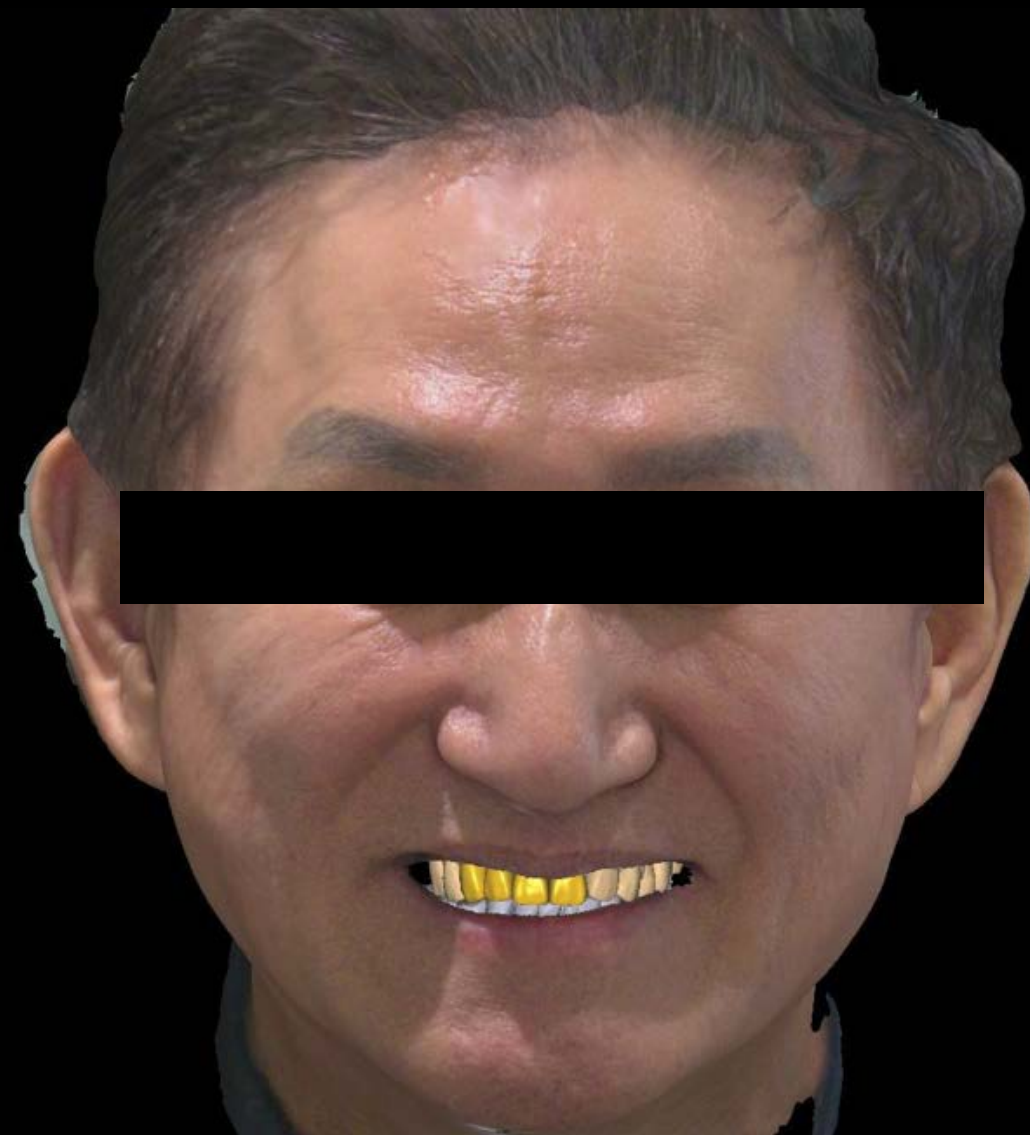Narrow and short implants

Bone regeneration materials

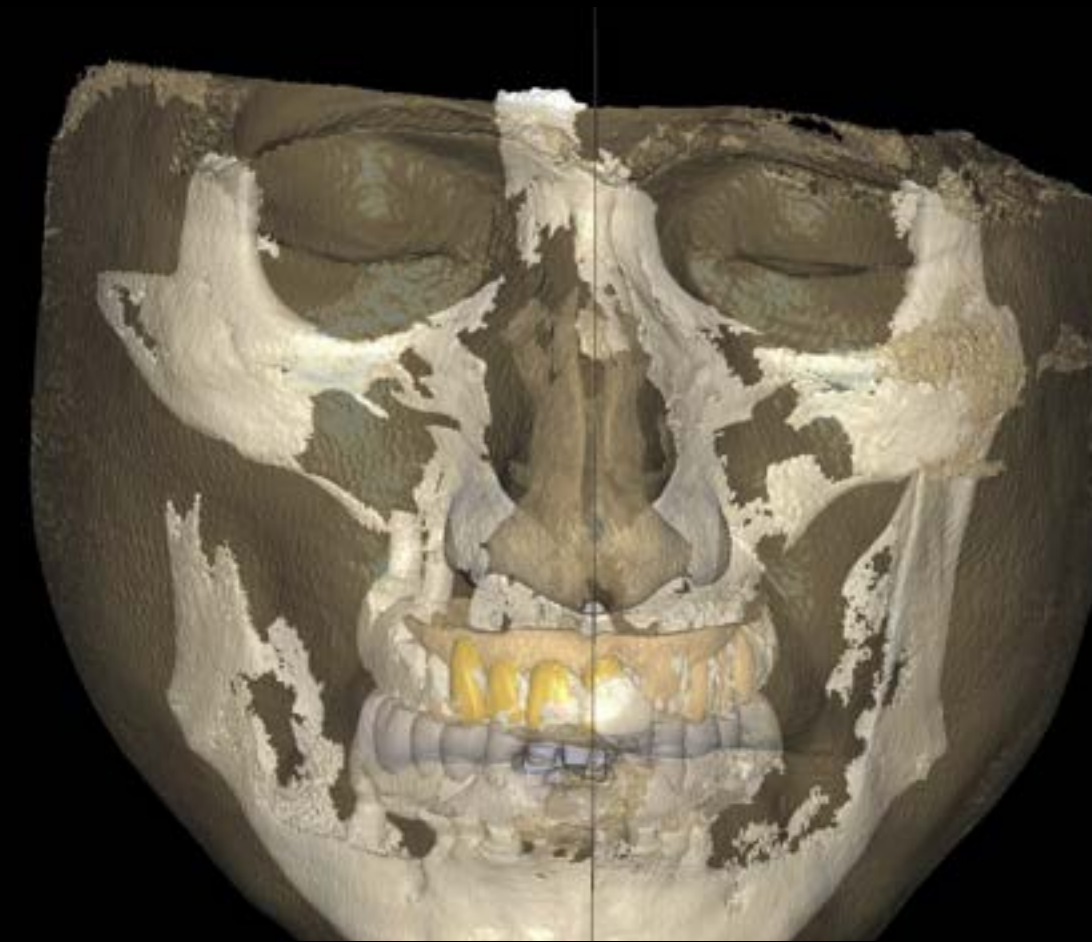Simple and exact digital concepts

Filler and toxin in dental field

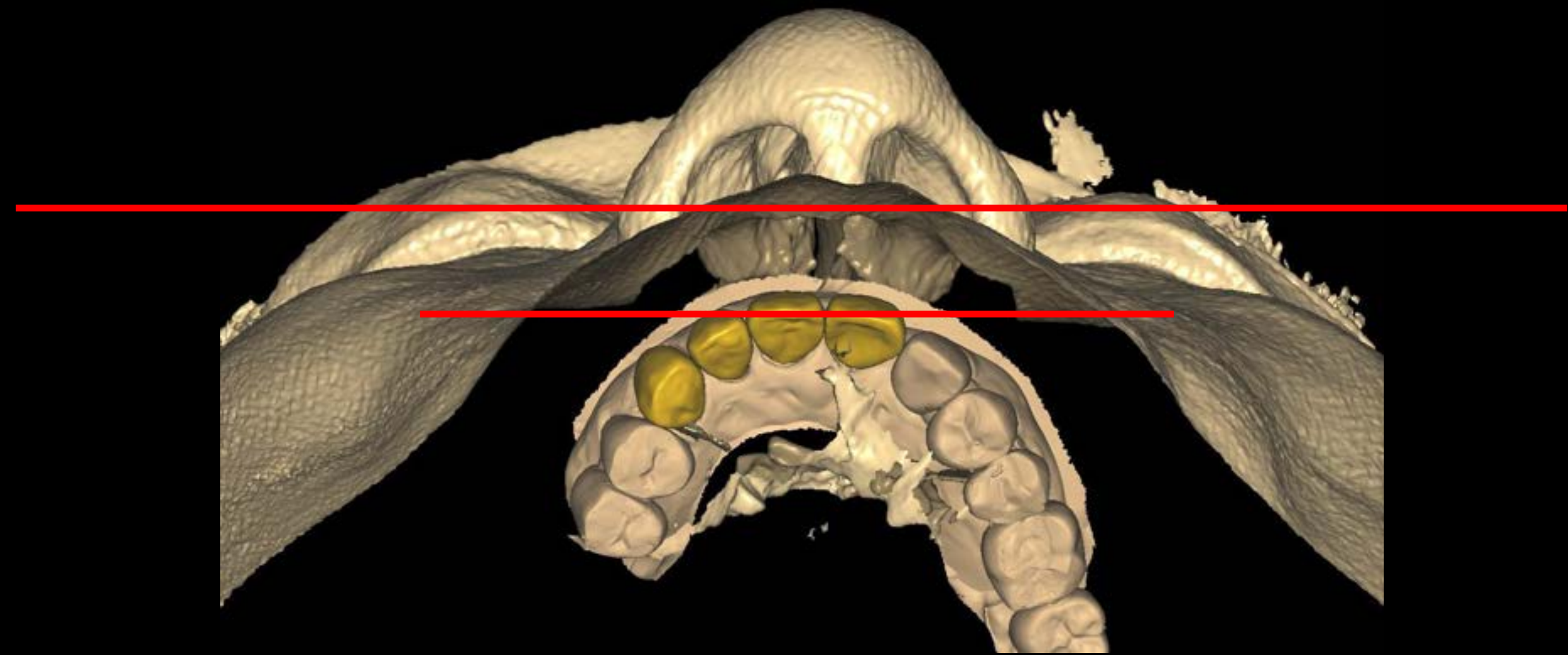
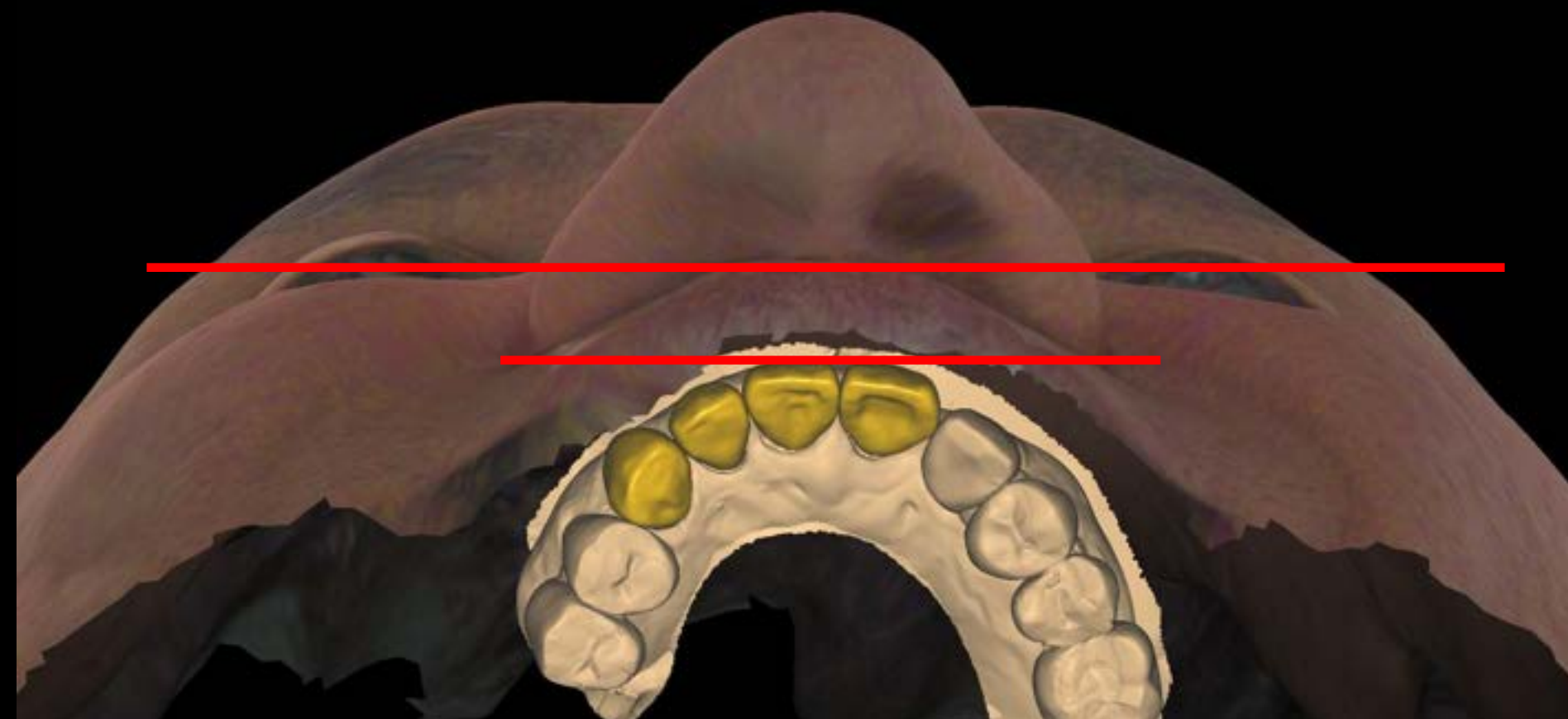
Facial scanner vs CT data application



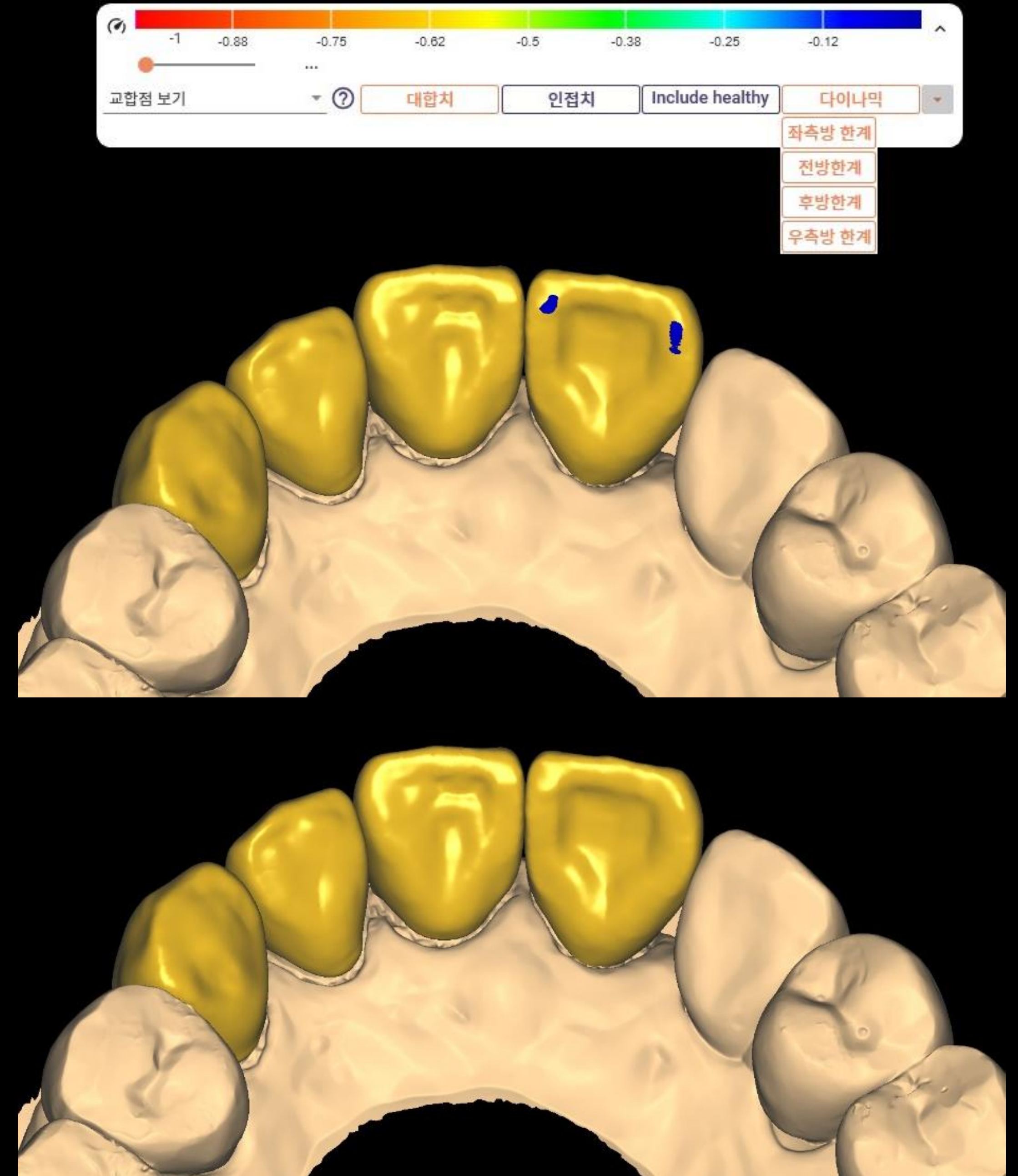
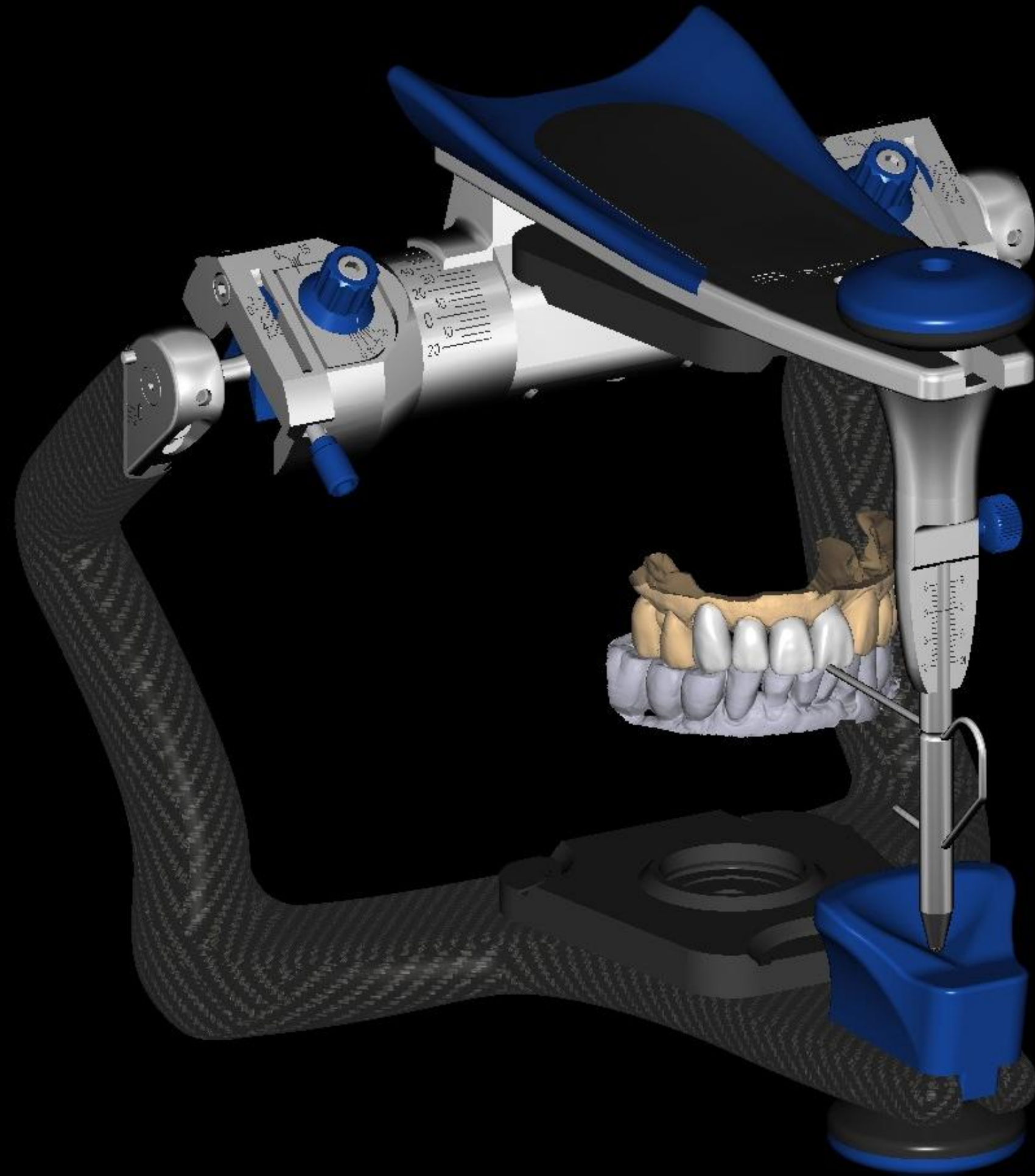
Facial scanner
Good for pts consulting



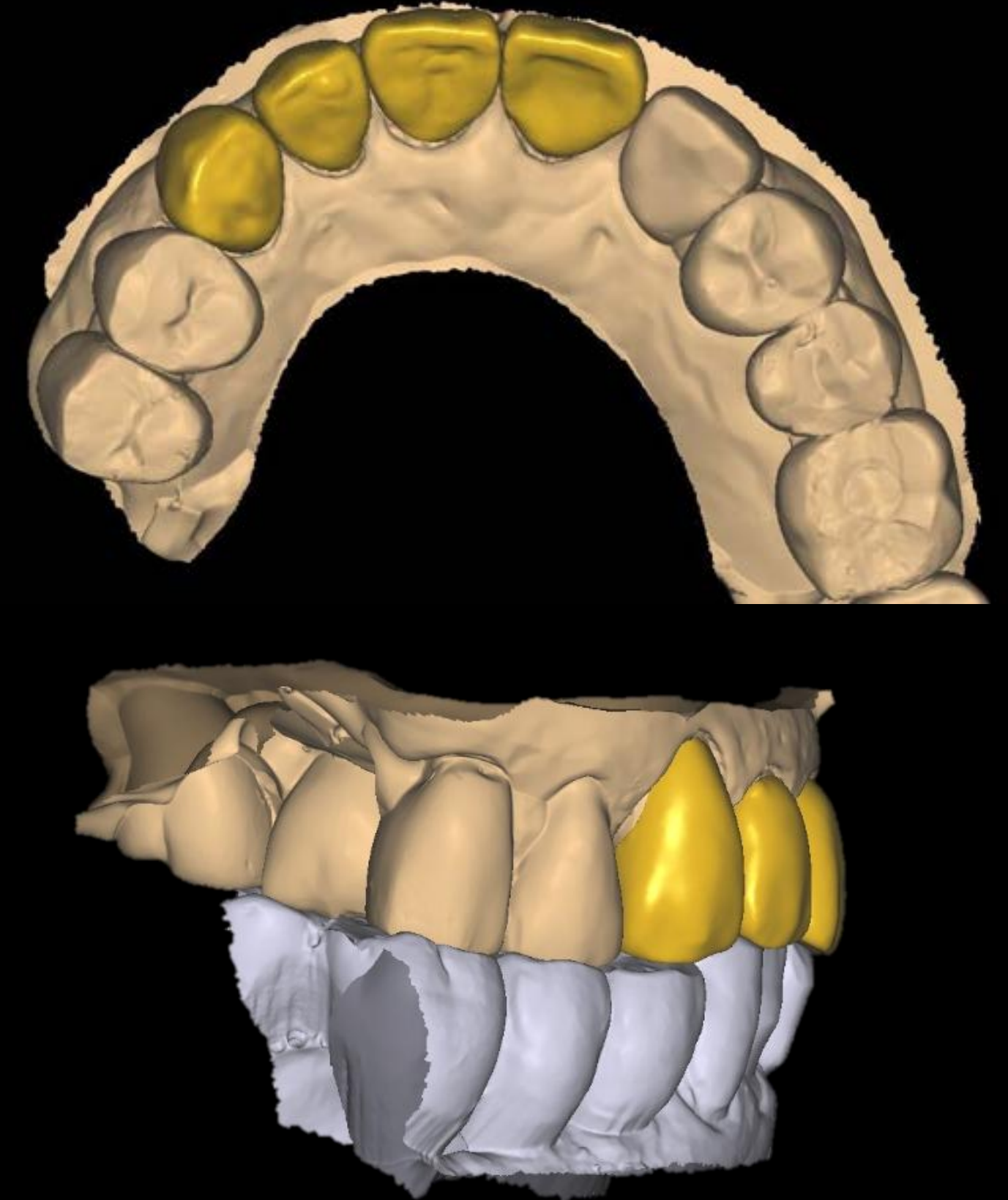
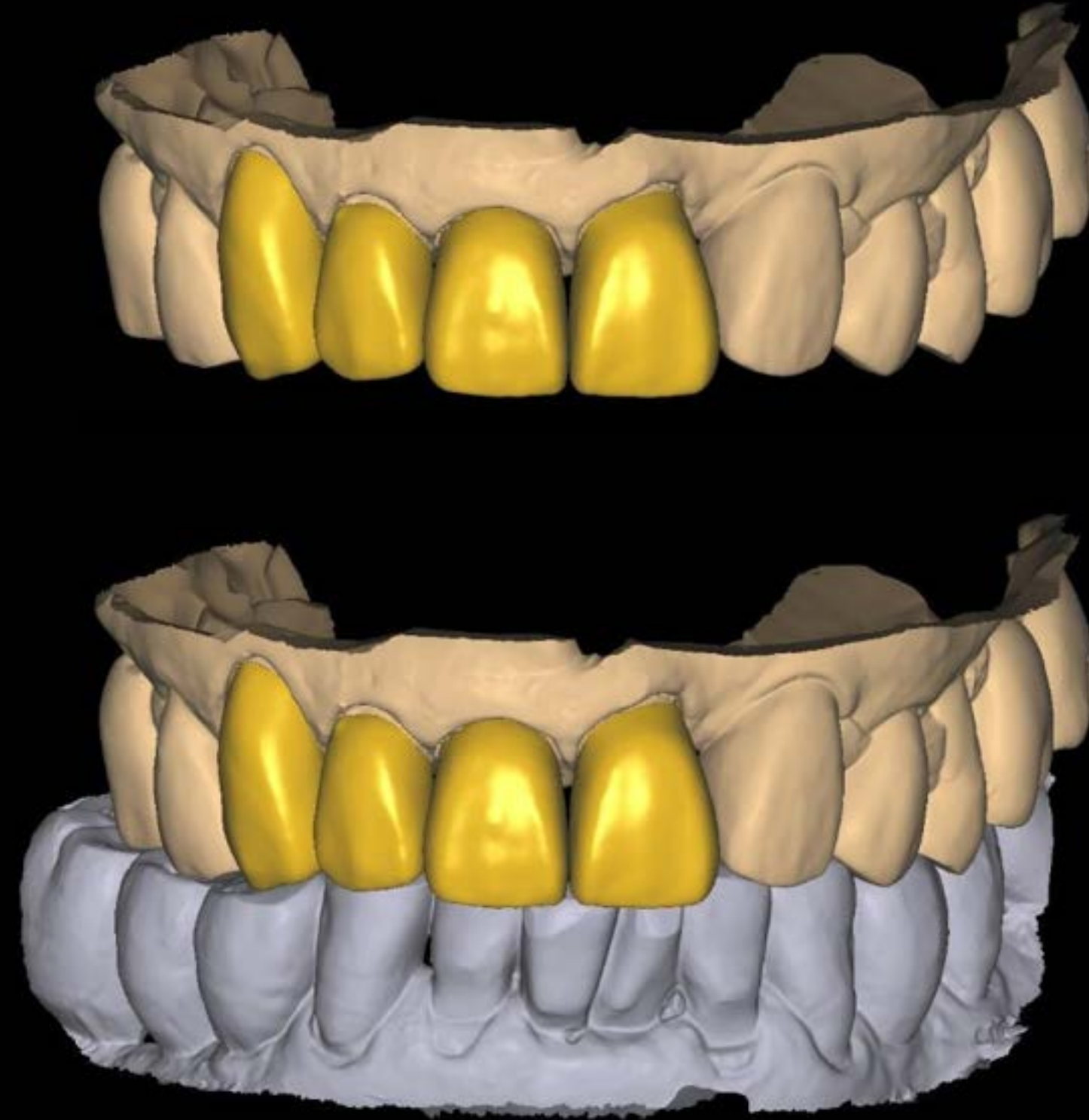
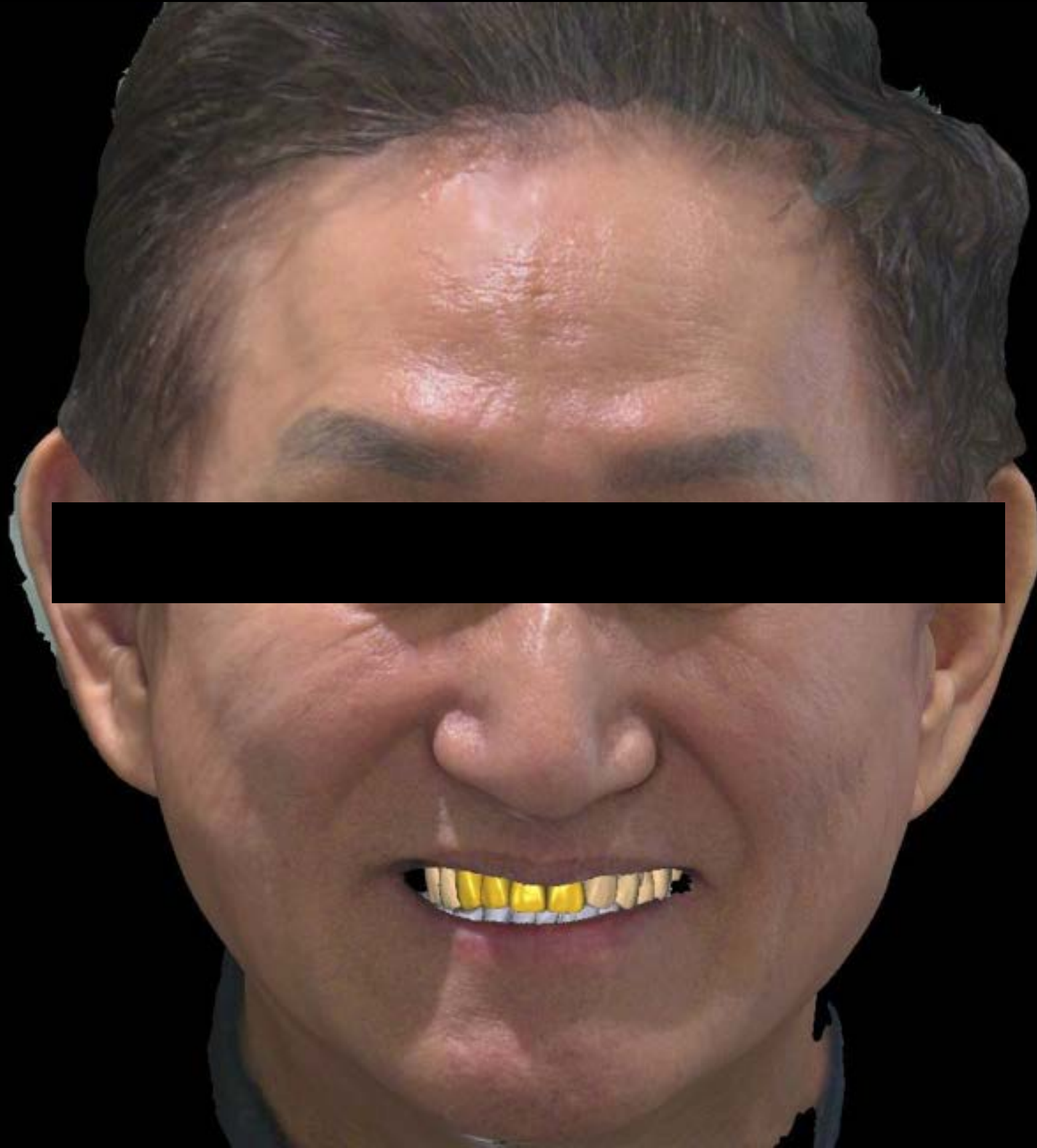CT STL
more precise for lab



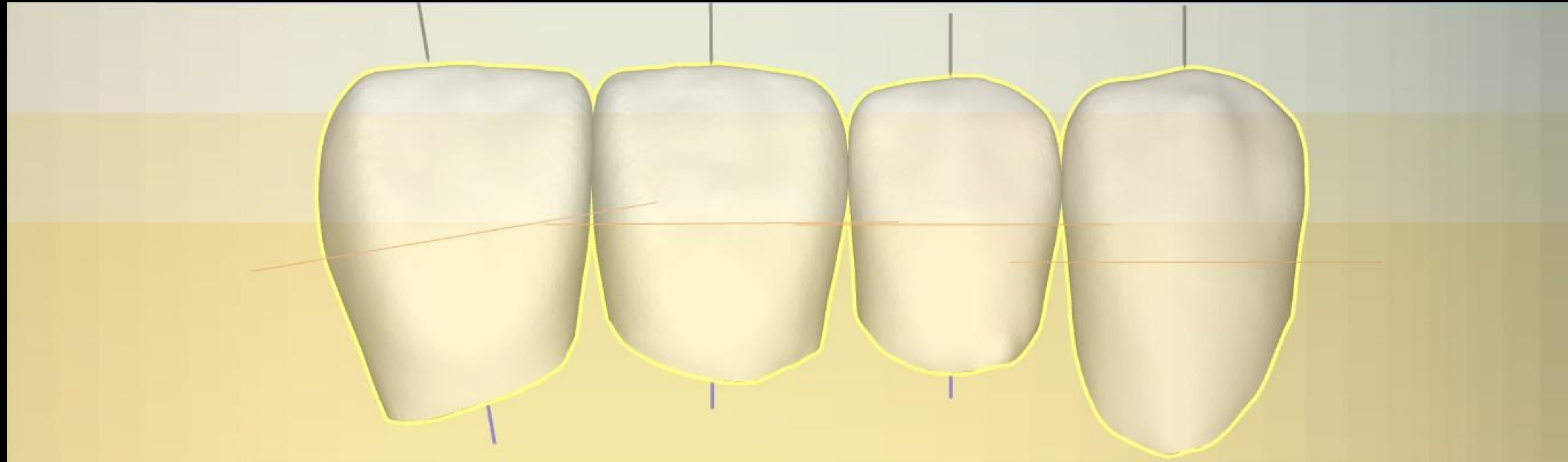
Prosthesis design



Prosthesis design

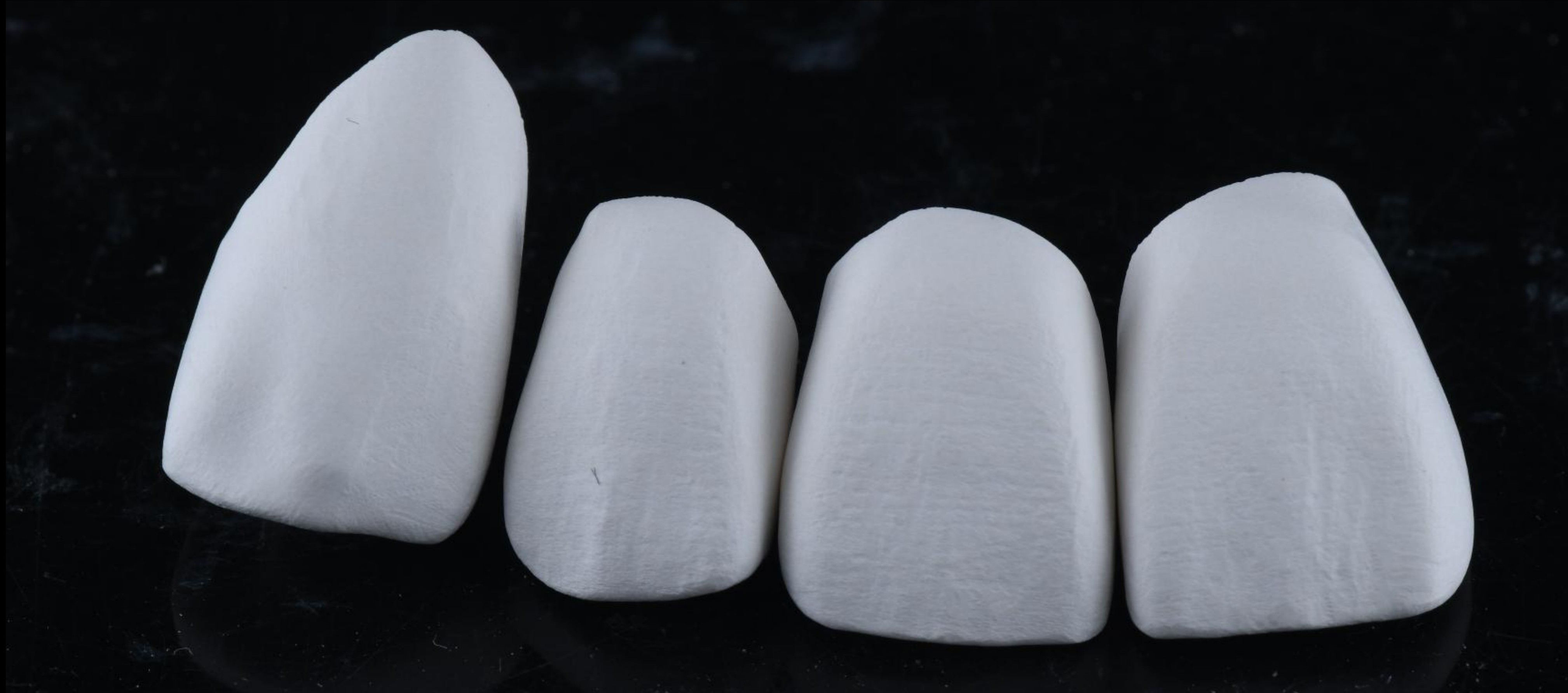

Hyper Dent



A3 18T 3 Layer Block

Coloring



Inner – White Opaque

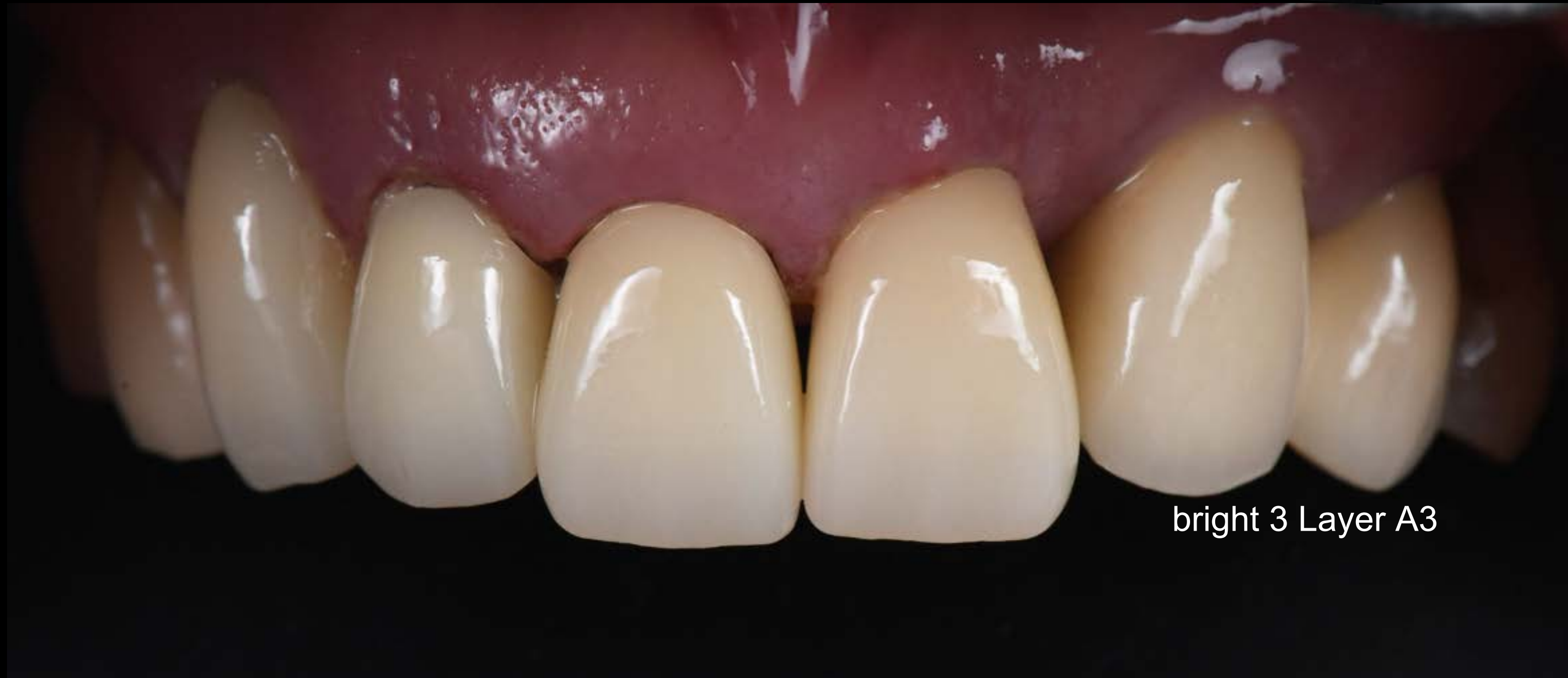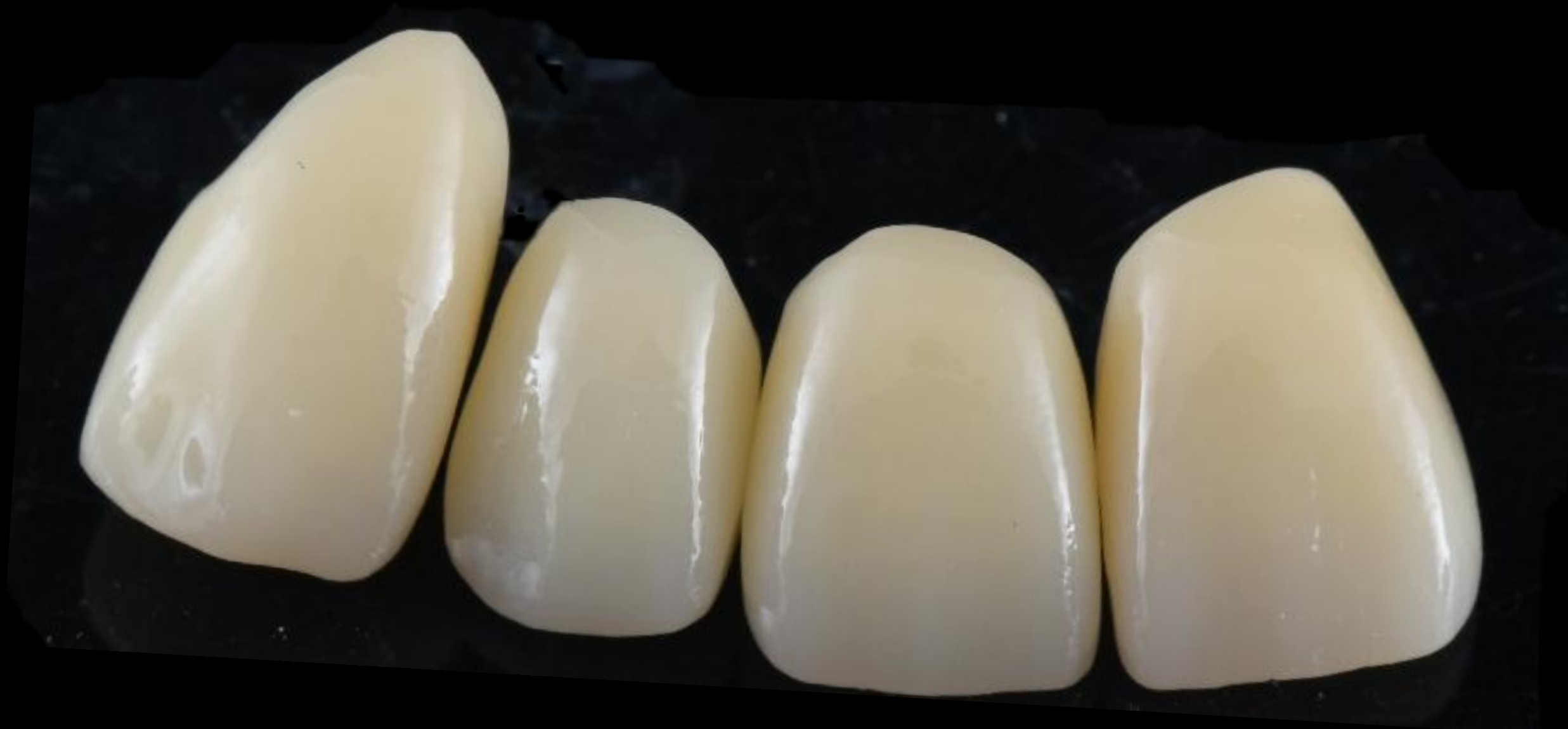Safe approach based on evidence

Dynamic approach based on inspiration

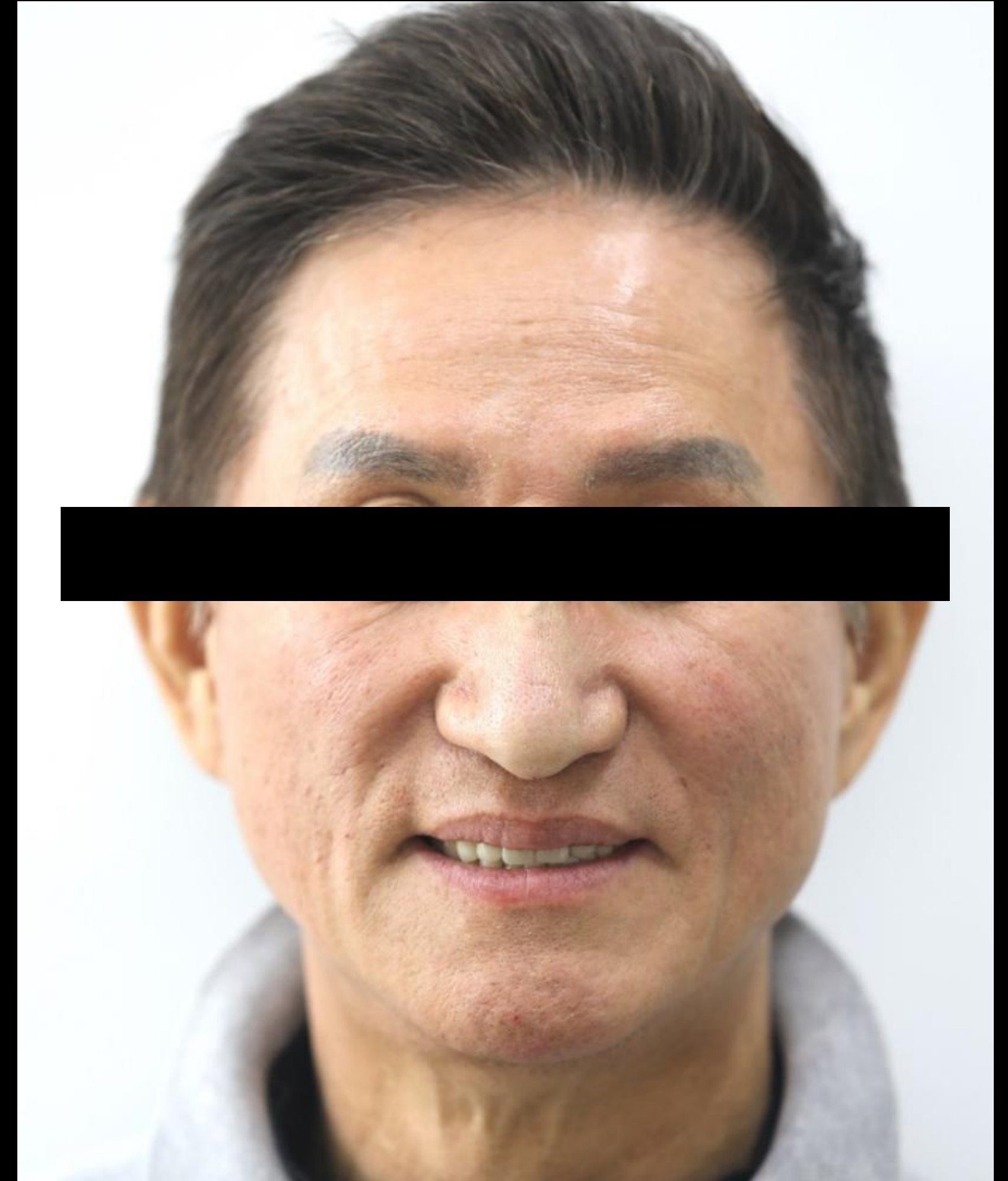
New field over dentistry

Toxin and filler, PDRN

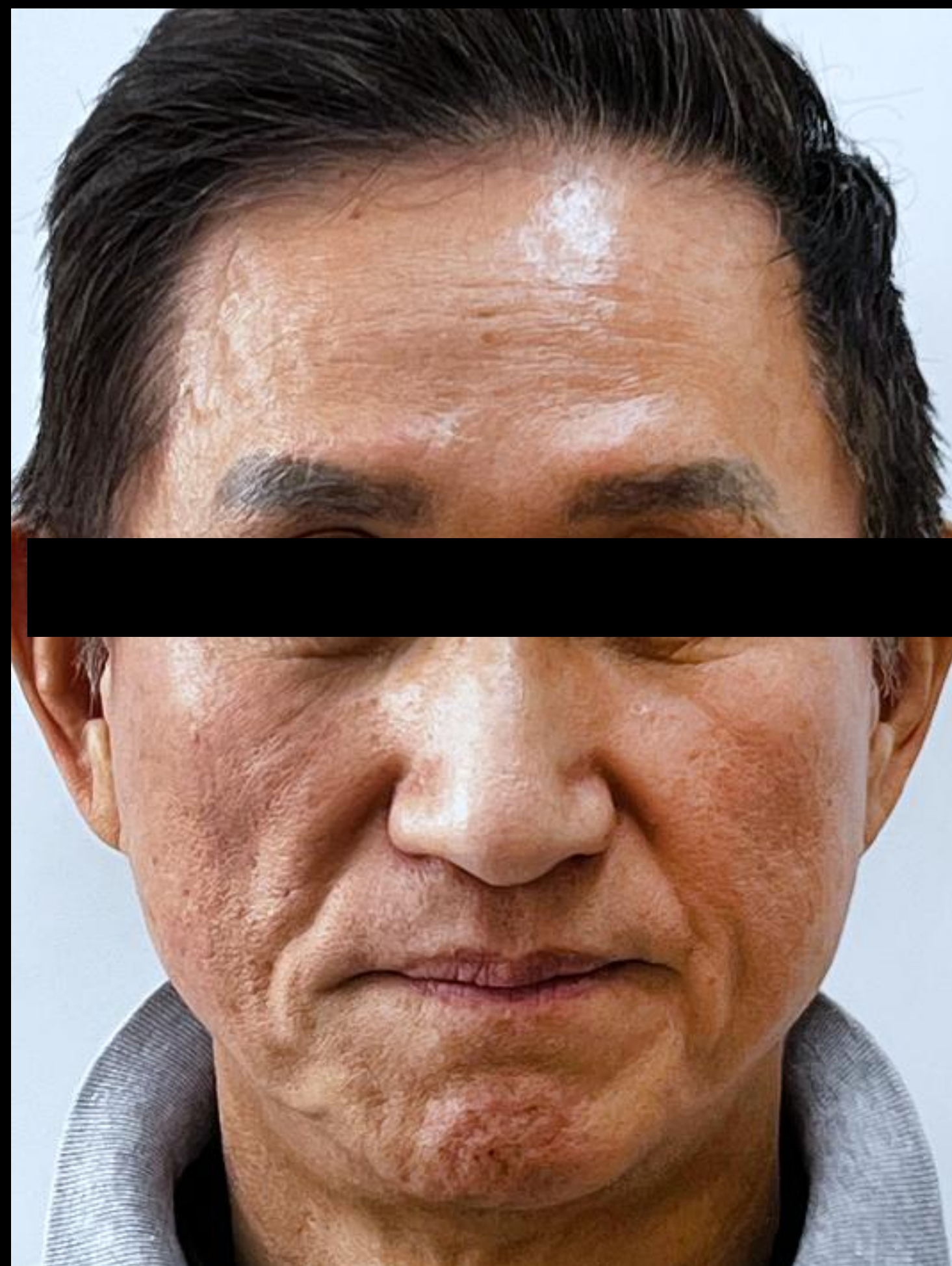
Prosthesis design



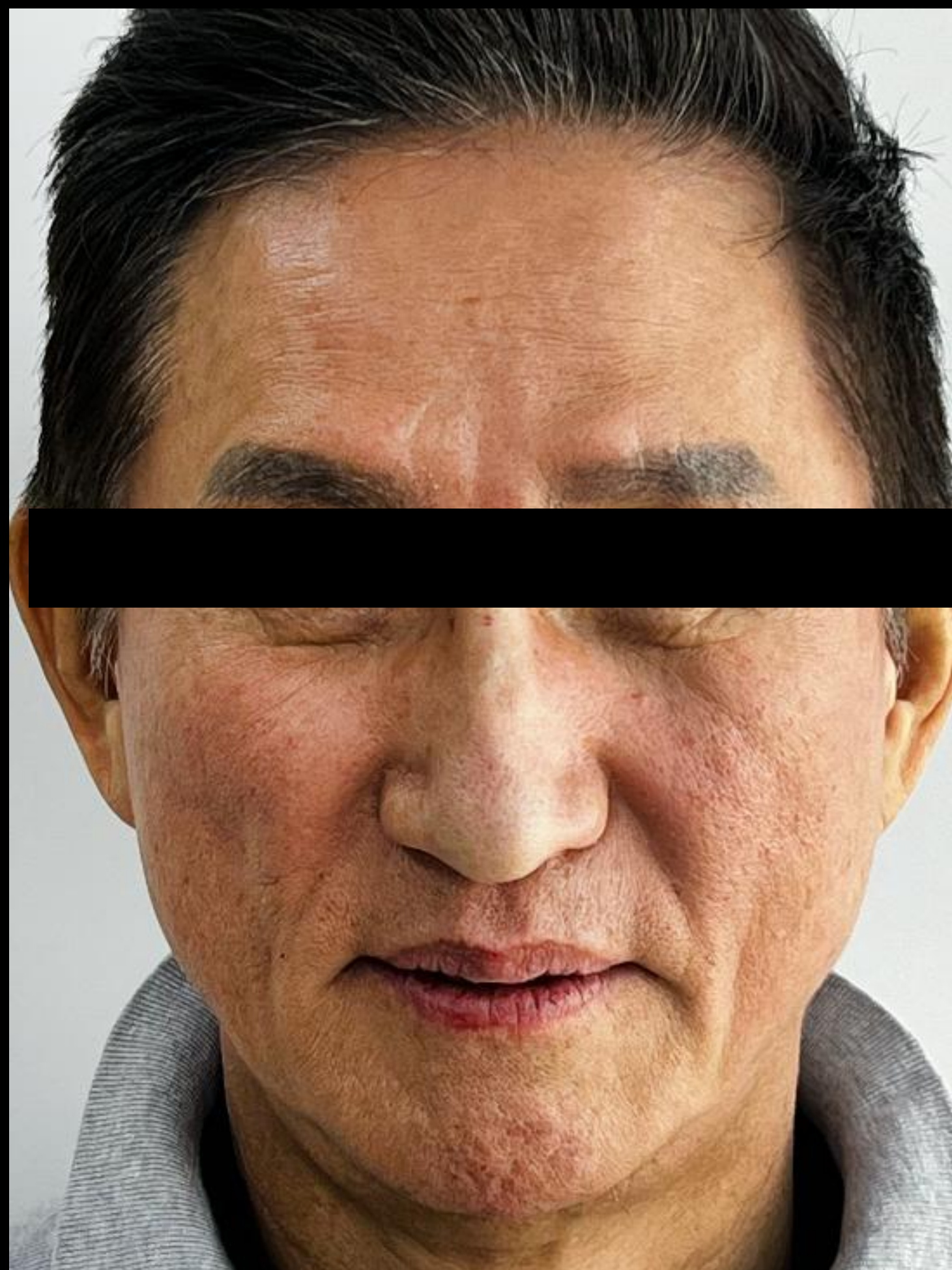
bright 3 Layer A3



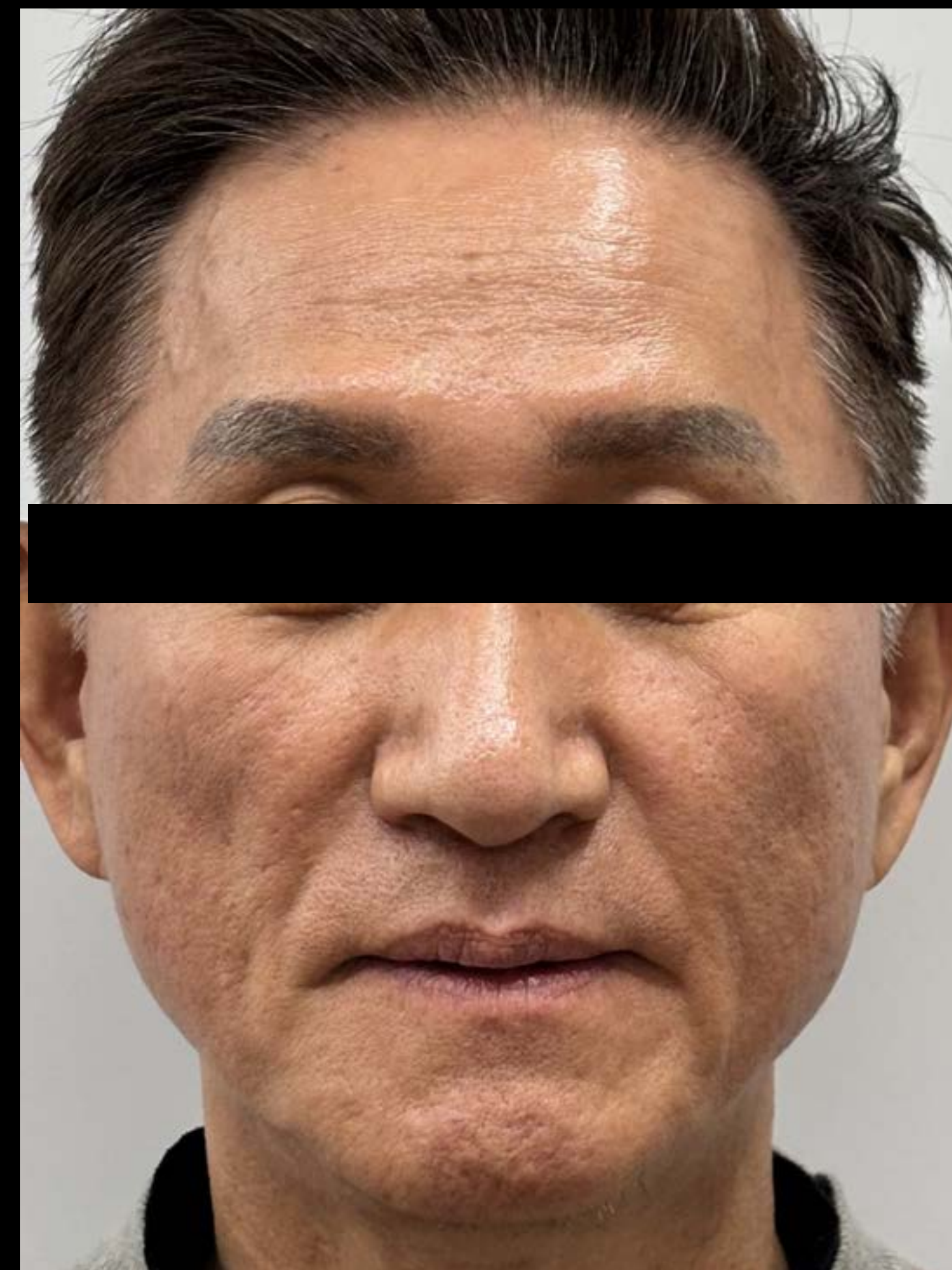
Before



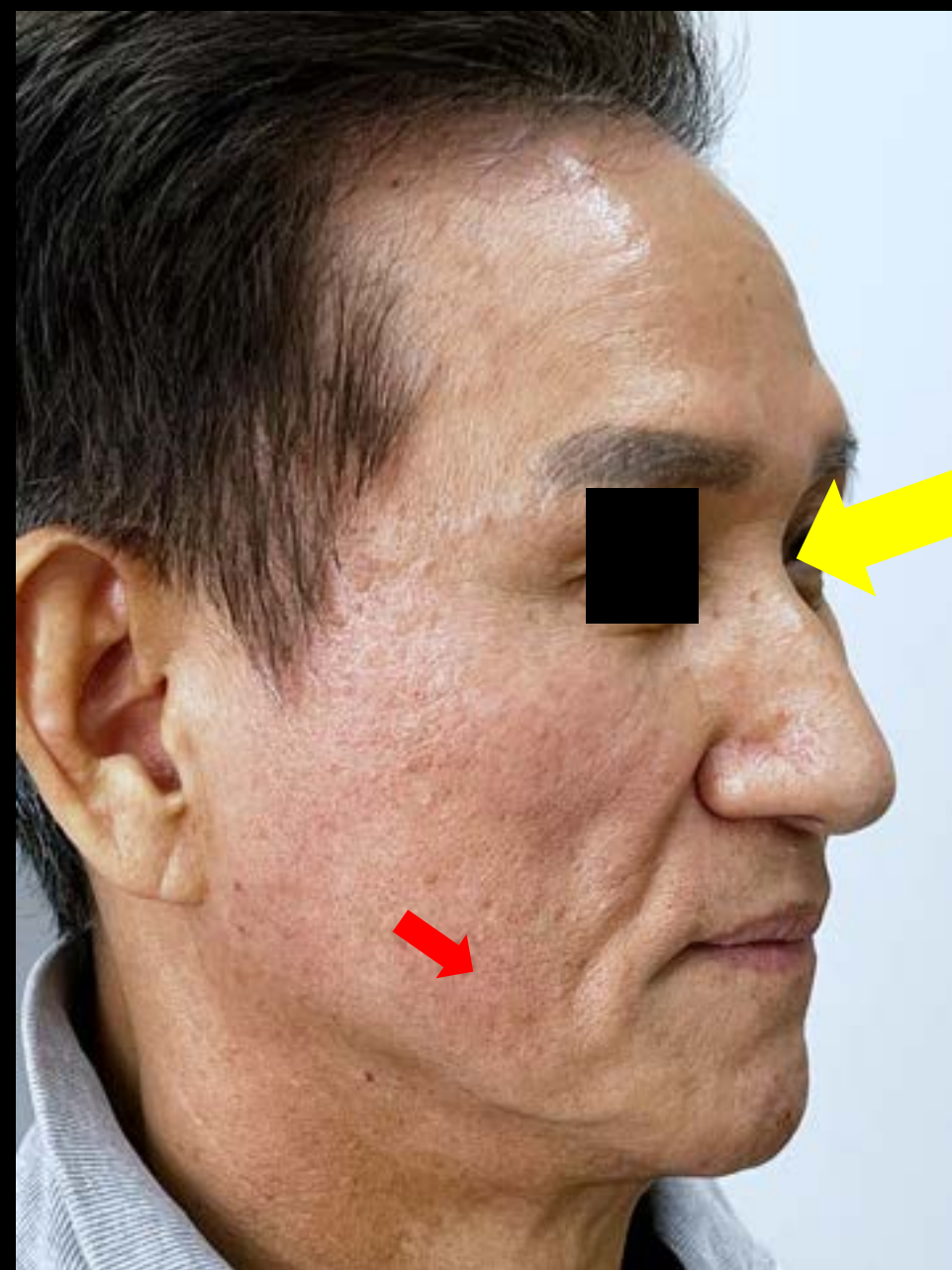
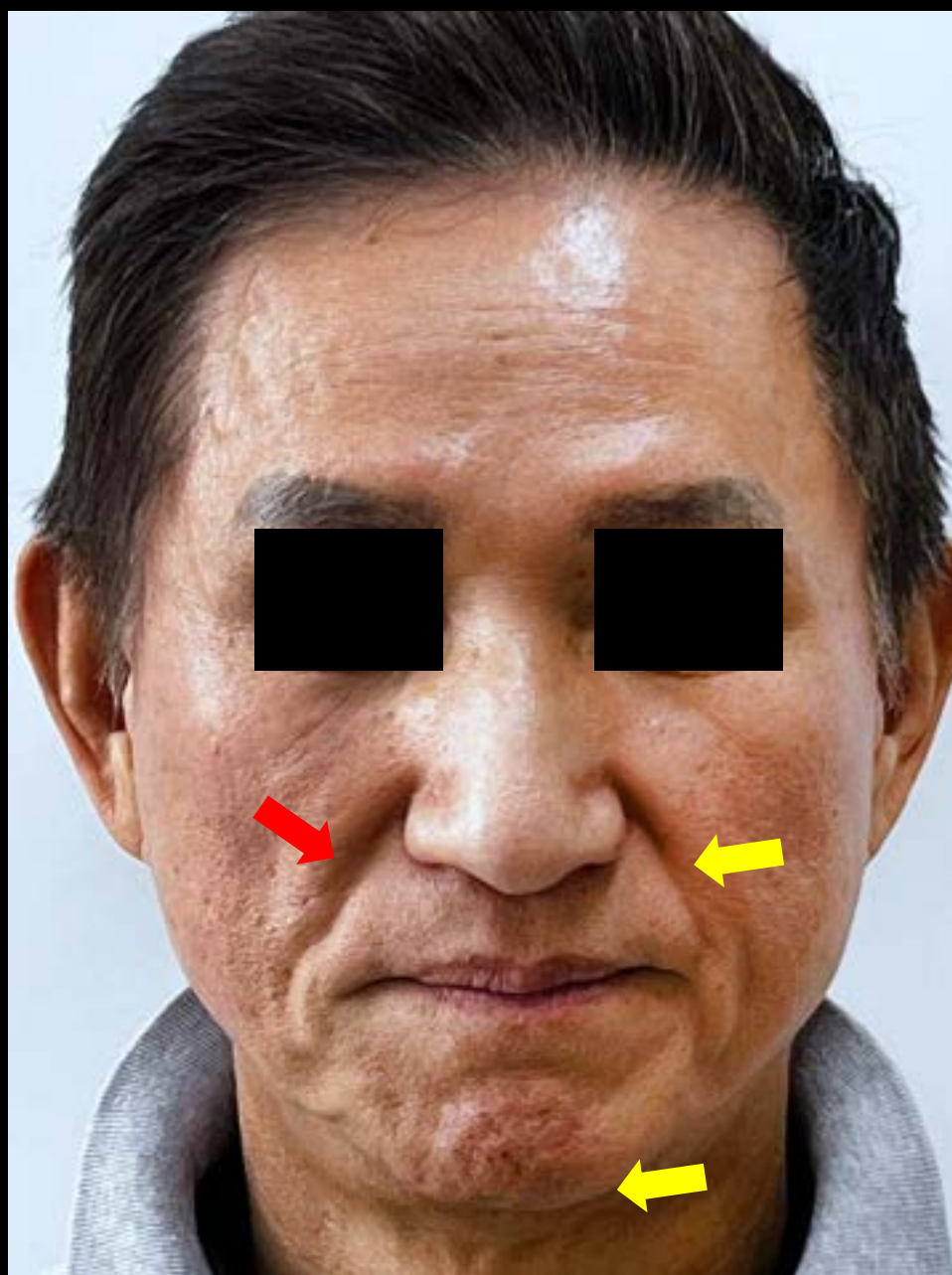
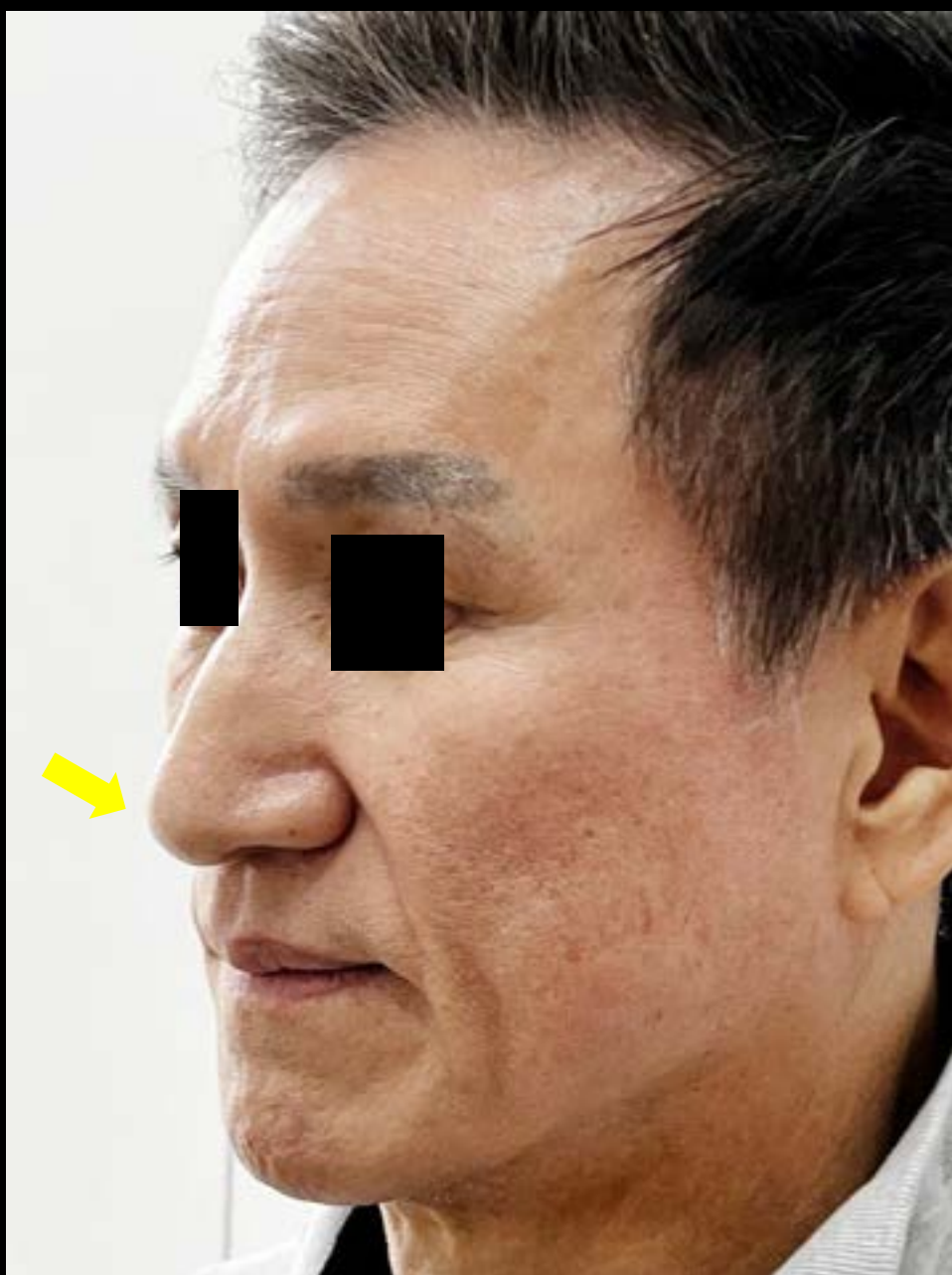
After



1 Month Later



before

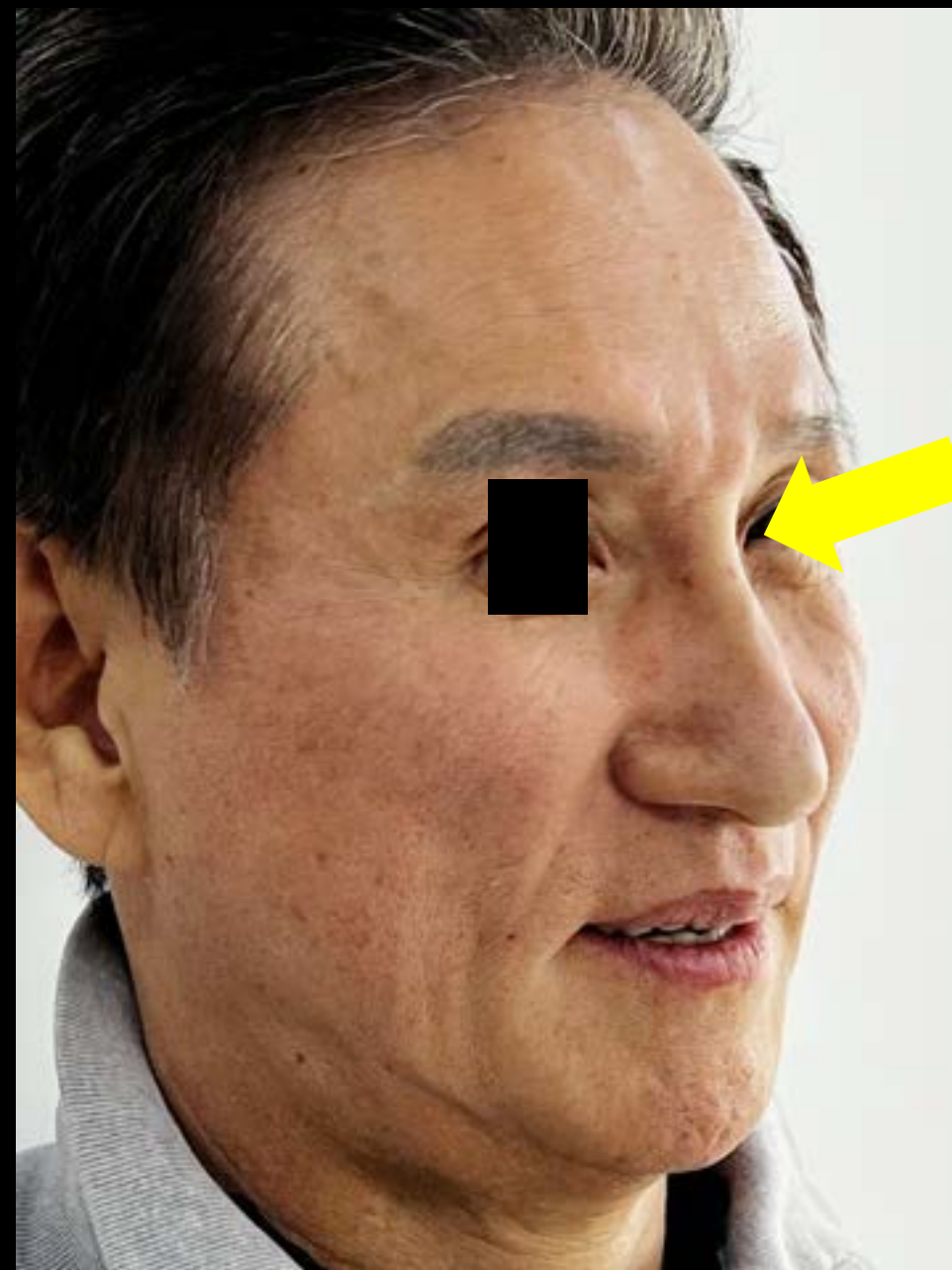
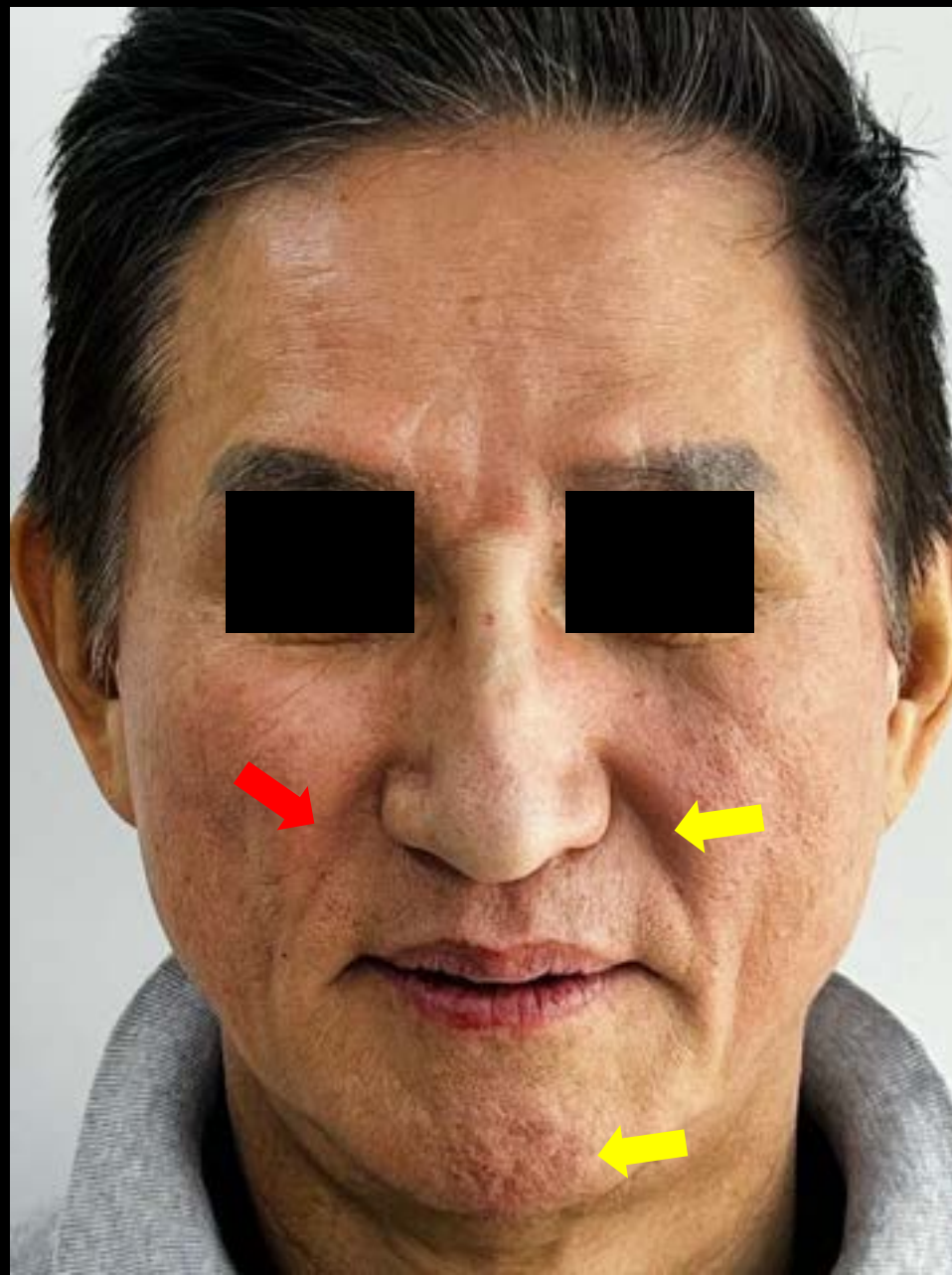
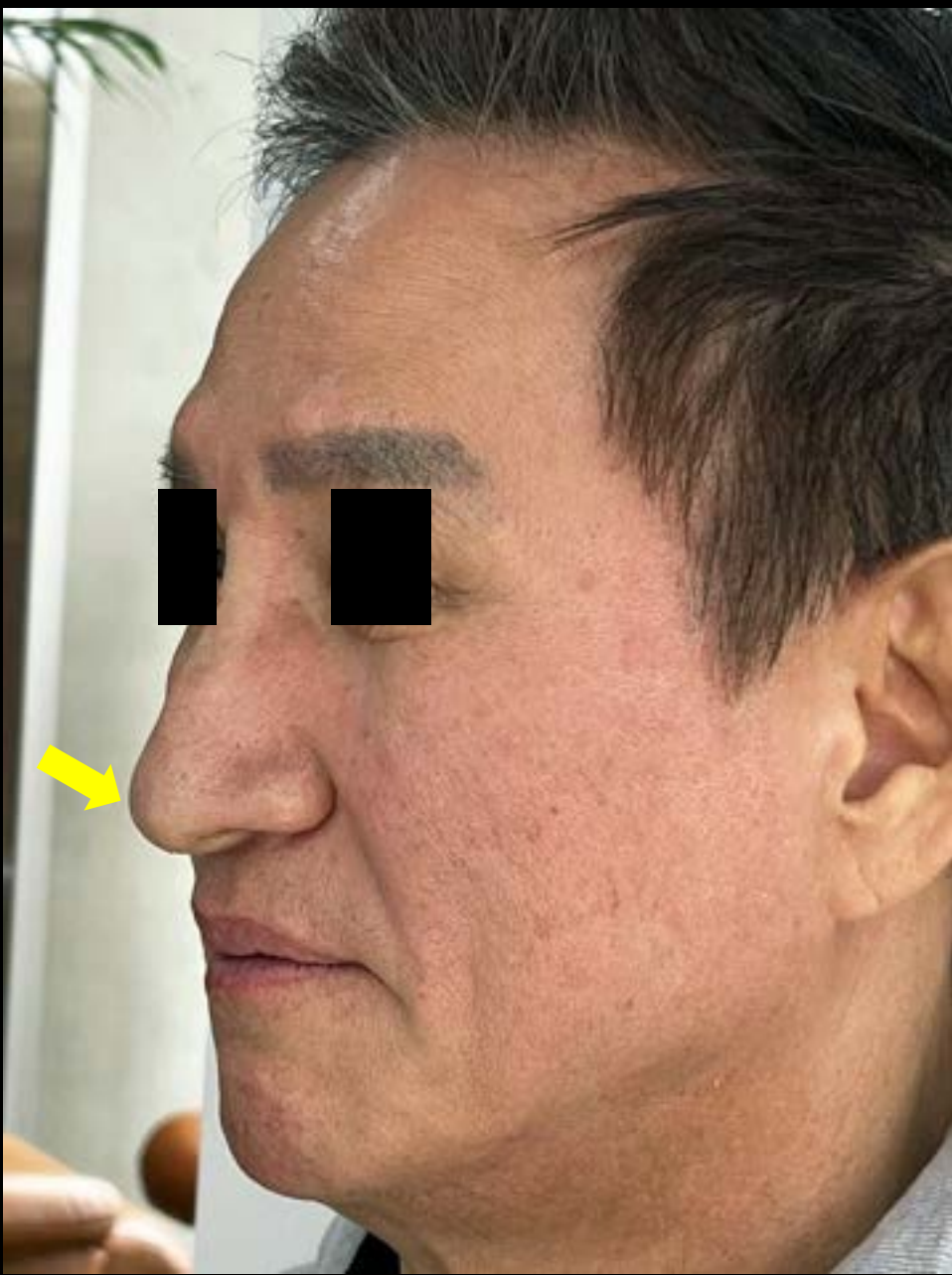


application site

- High ✓
- Nose
 - Nasolabial folds
 - Chin

- Smile ✓
- Nasolabial folds
 - Marionette lines

after



High elastic hyaluronic acid filler

A close-up, low-angle shot of a white CT scanner gantry. The gantry is curved and has the text 'brightCT' printed on it in a grey, sans-serif font. A black circular opening is visible on the left side of the gantry. In the foreground, a white, curved structure with a yellow stripe is partially visible. The background is slightly blurred, showing some green light streaks.

brightCT

More diverse images from one CT scan

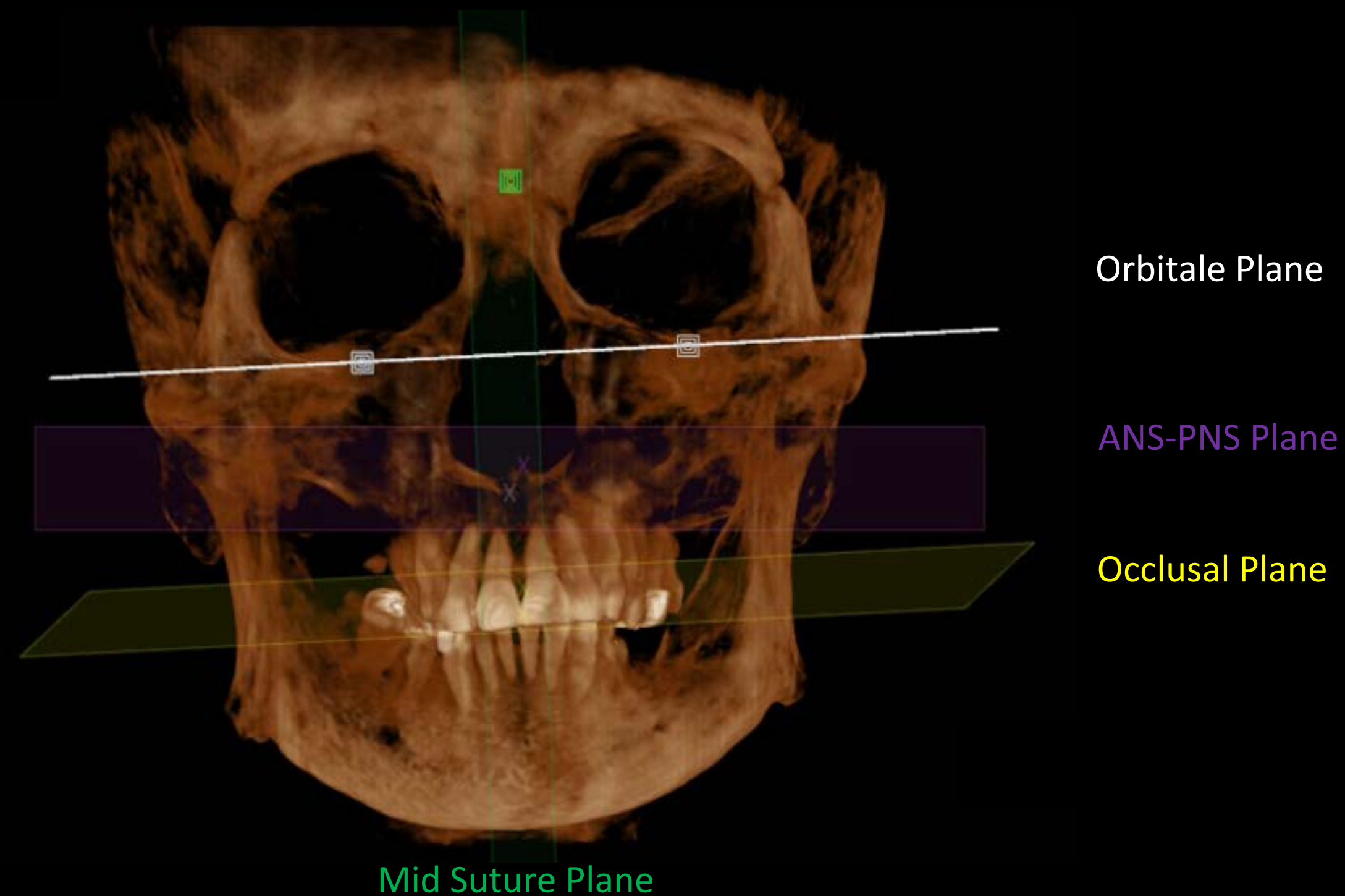
**** 269p Dentium CT Viewer VOD 1**

Clinical Case Applications

Implant Cases

2. Advanced Case : AI Occlusal Plane

Defines ideal occlusal and midline planes using ANS–PNS, Orbitale, and Mid-suture line, helping clinicians establish precise prosthetic and orthodontic references.



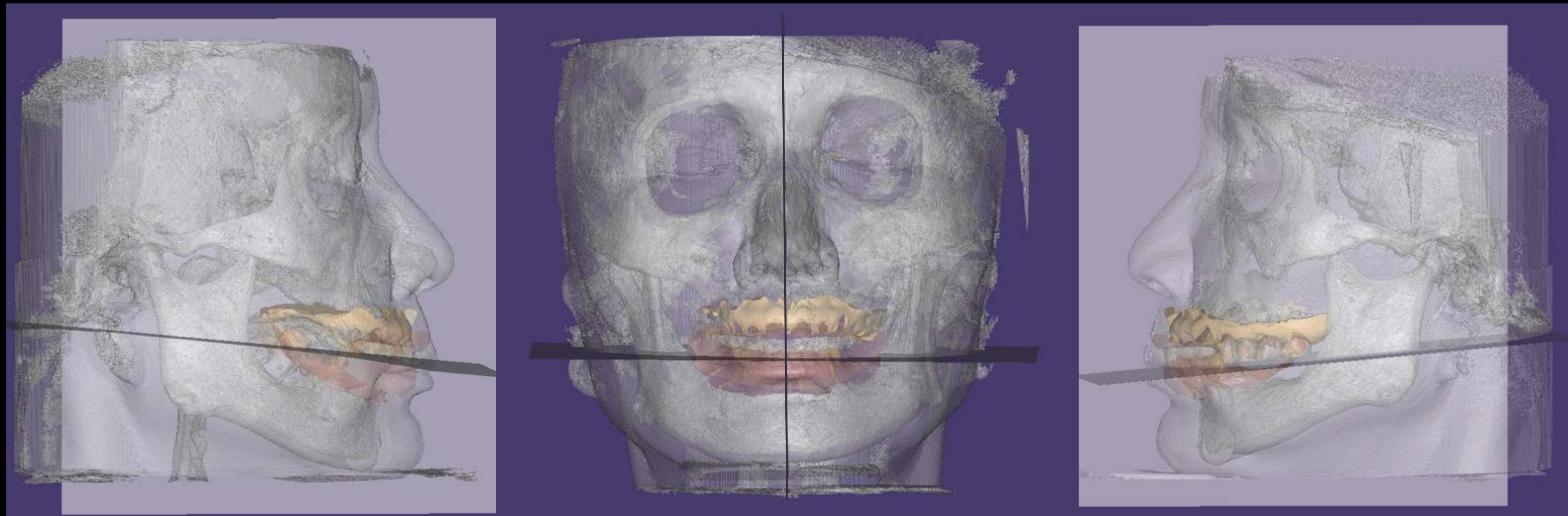
Clinical Case Applications

Implant Cases

2. Advanced Case : AI Occlusal Plane

2

Export occlusal plane, midline, and tissue data from the viewer as STL files to CAD for alignment with working models.



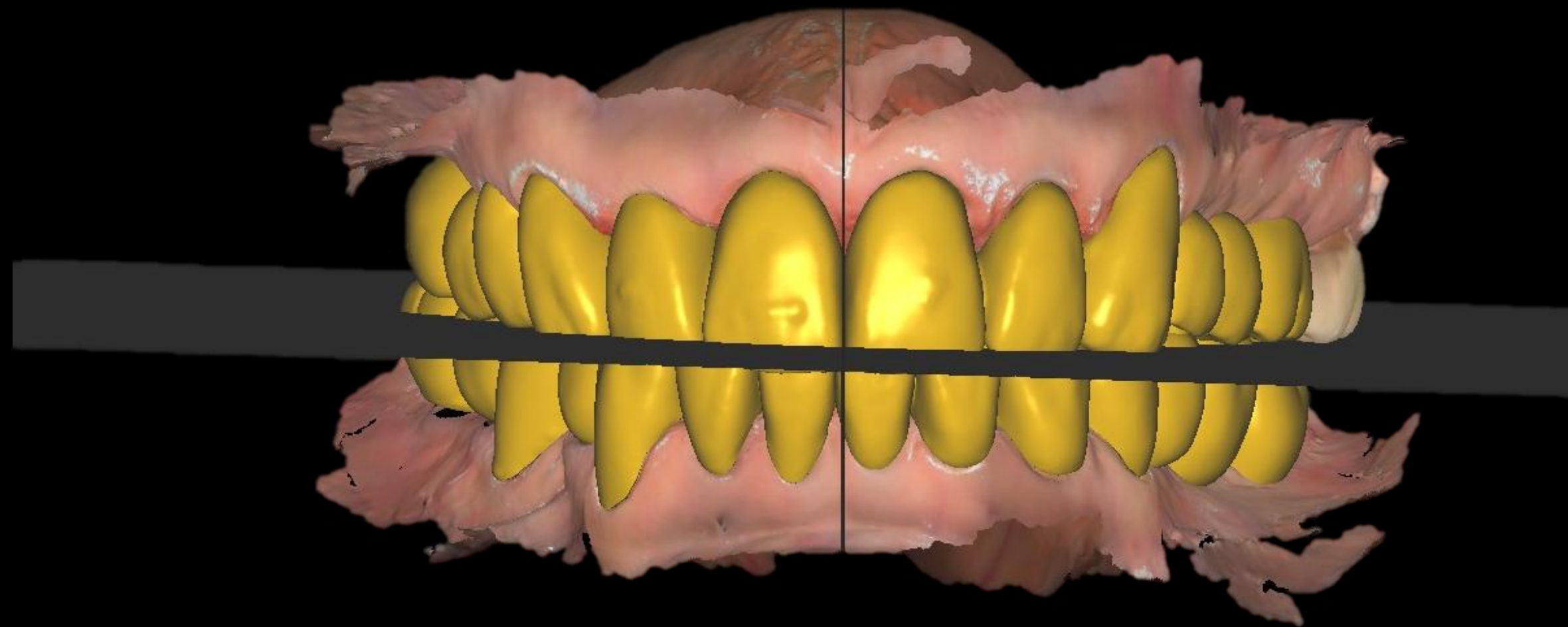
Clinical Case Applications

Implant Cases

2. Advanced Case : AI Occlusal Plane

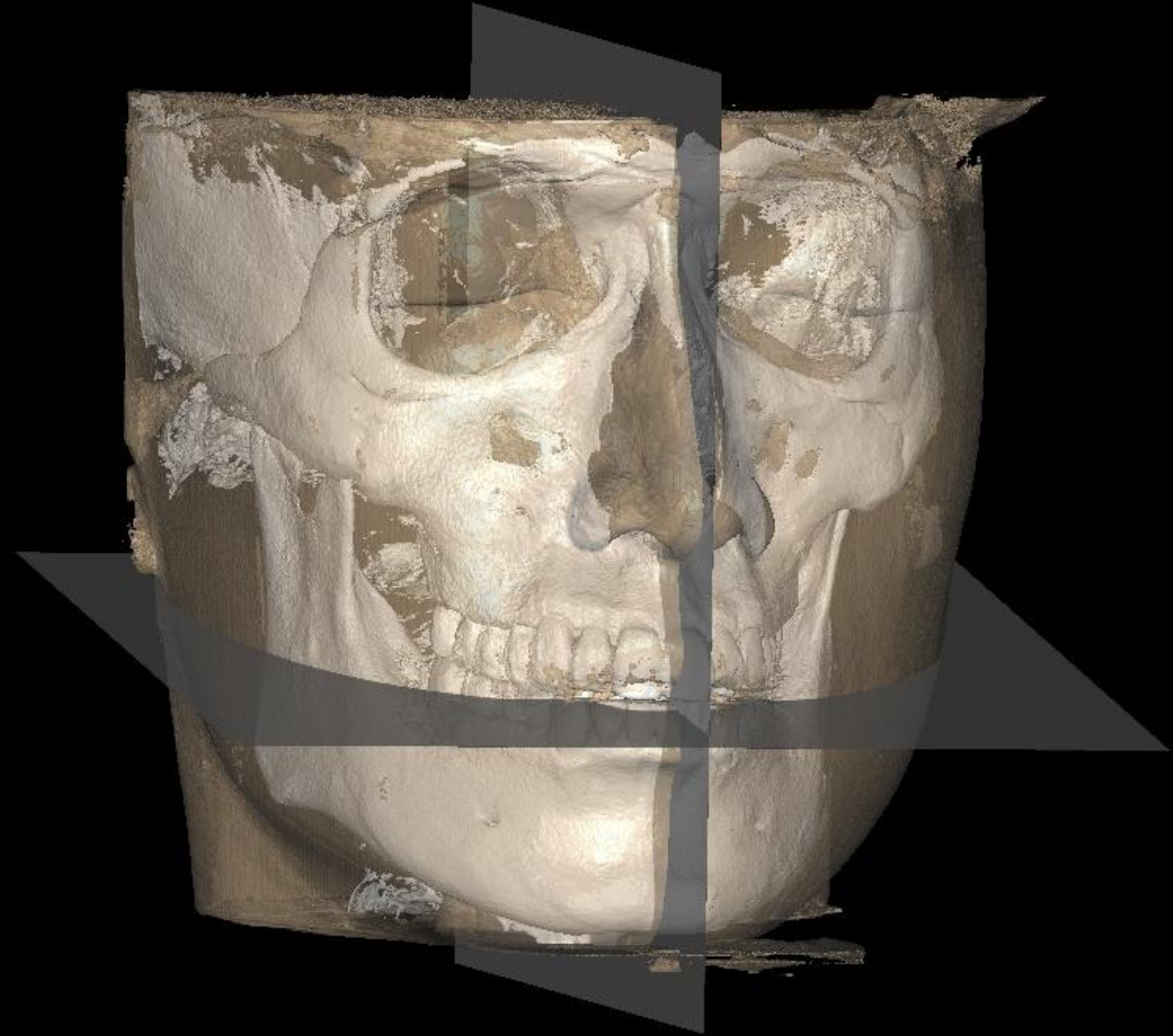
4

AI-generated midline and occlusal plane provide exact guidelines for tooth alignment in edentulous cases, especially in upper anterior esthetics.



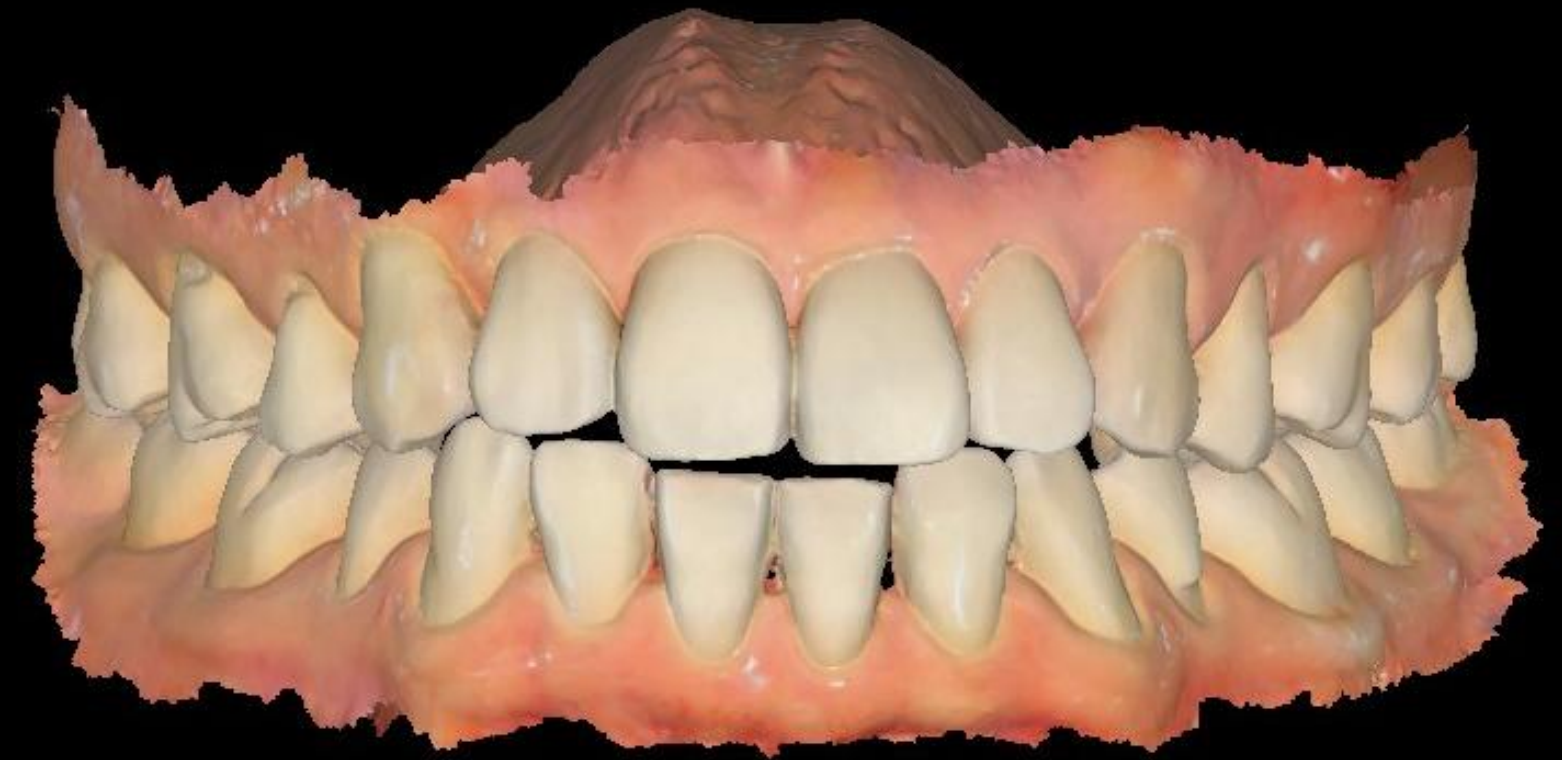CAD

CT data with Orthodontics diagnose



CT data

(AI occlusal plane, Hard & Soft Tissue data)

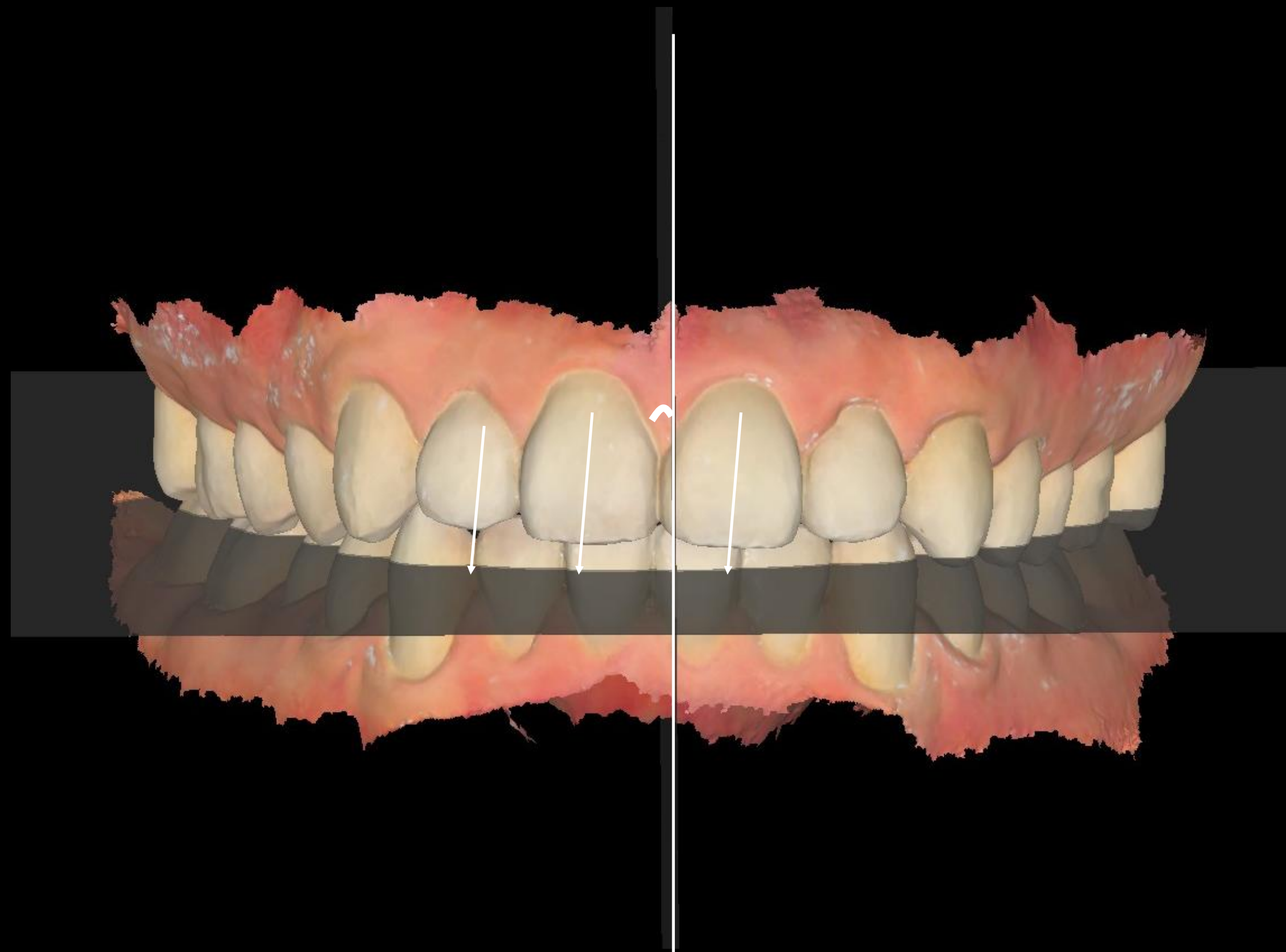


Shining 3d Elite Ios scan data



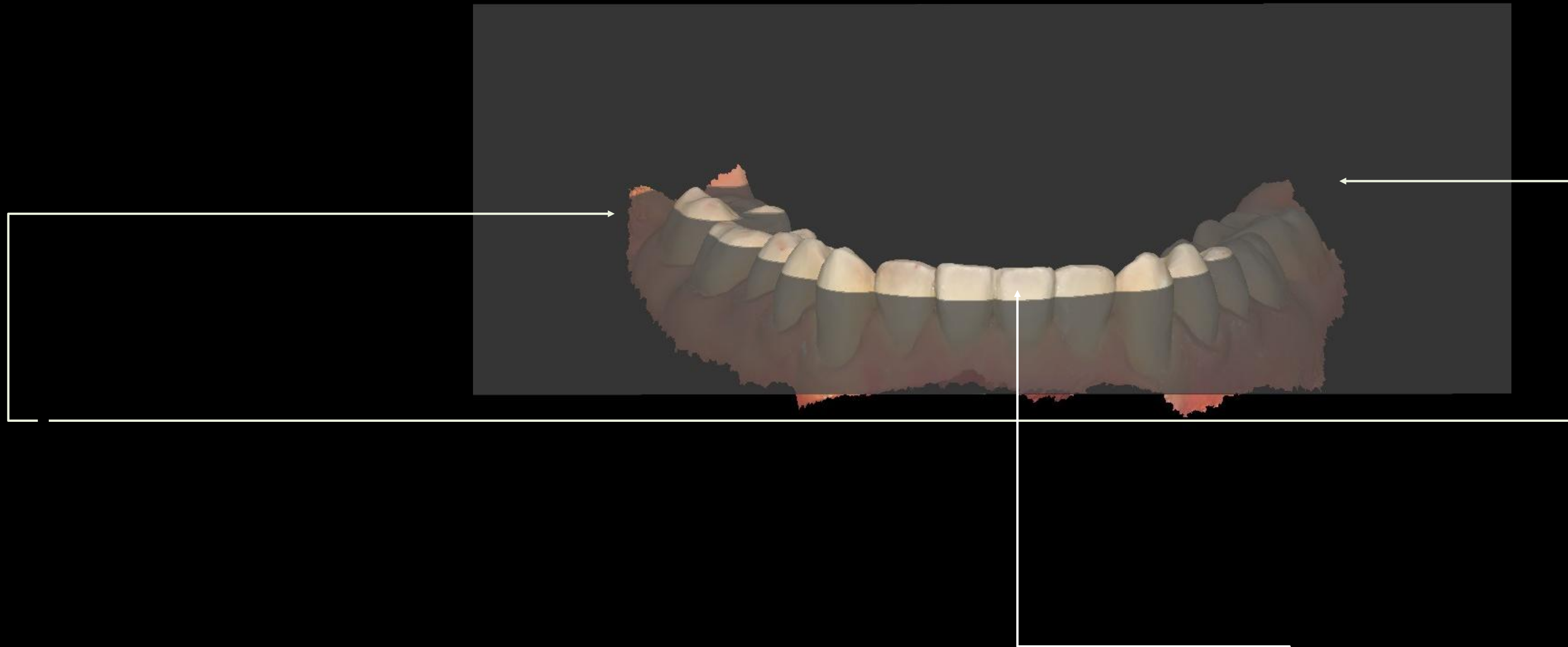Shining 3d MetiSmile

CT data with Orthodontics diagnose



****Assessment of Deviated Anterior Maxillary Tooth Axis & Midline****

CT data with Orthodontics diagnose



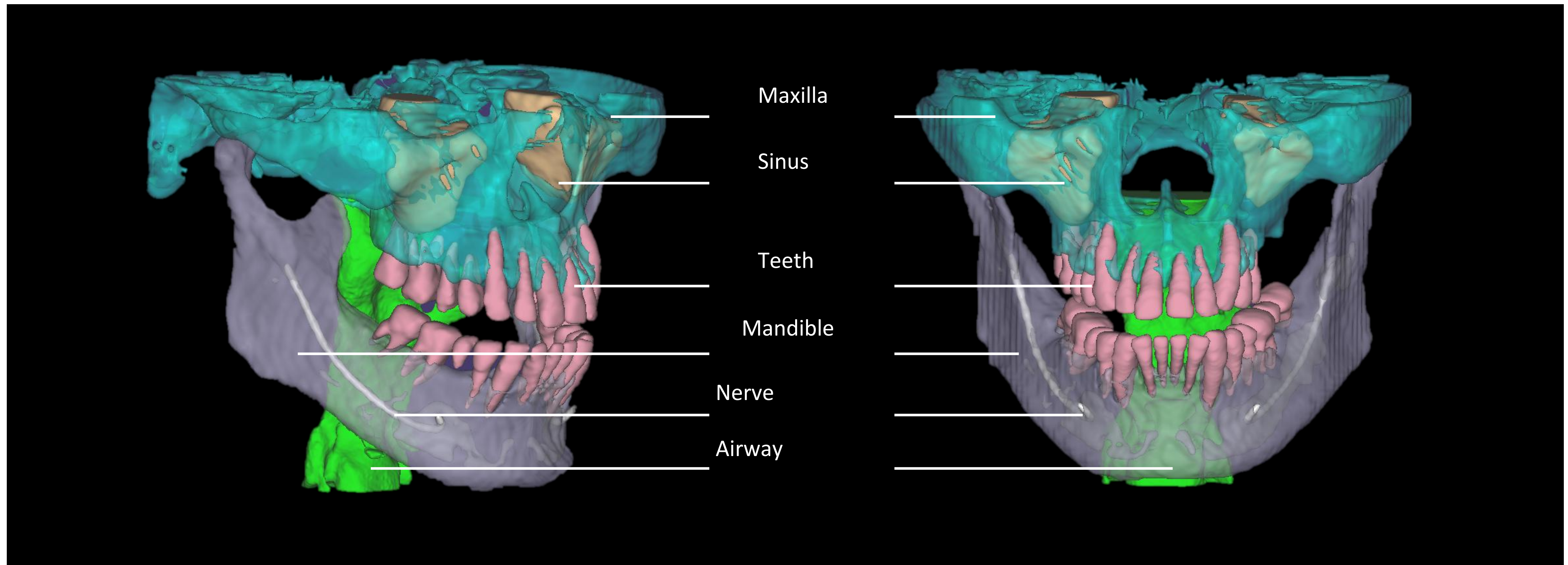
****Diagnosis of the occlusal plane in the left and right molars and mandibular anterior teeth****

Clinical Value

NEW

AI Segmentation

Automatically segments teeth, nerves, bones, sinus and airway clearly — very helpful for intuitive diagnosis and patient consultation.

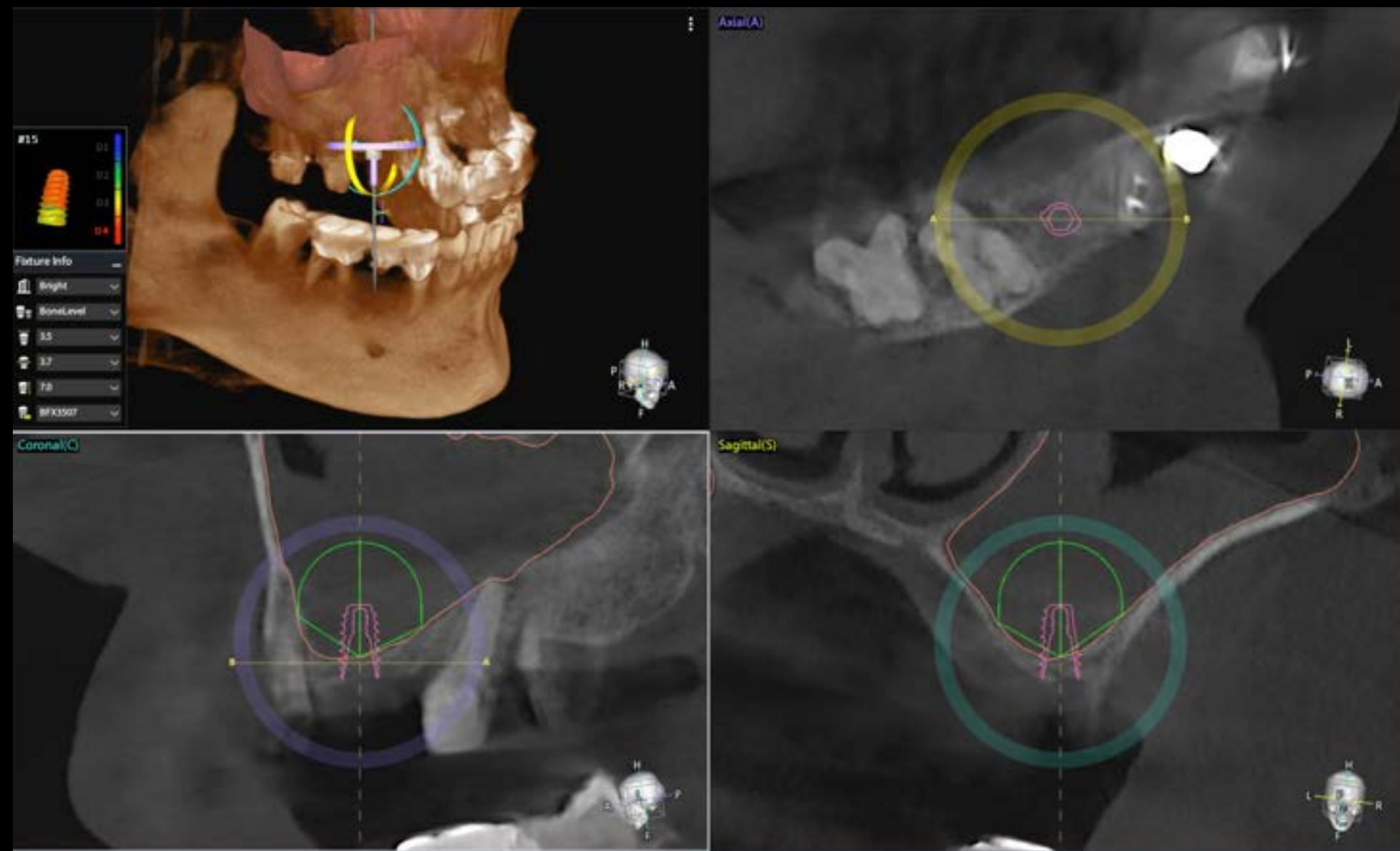


Clinical Value

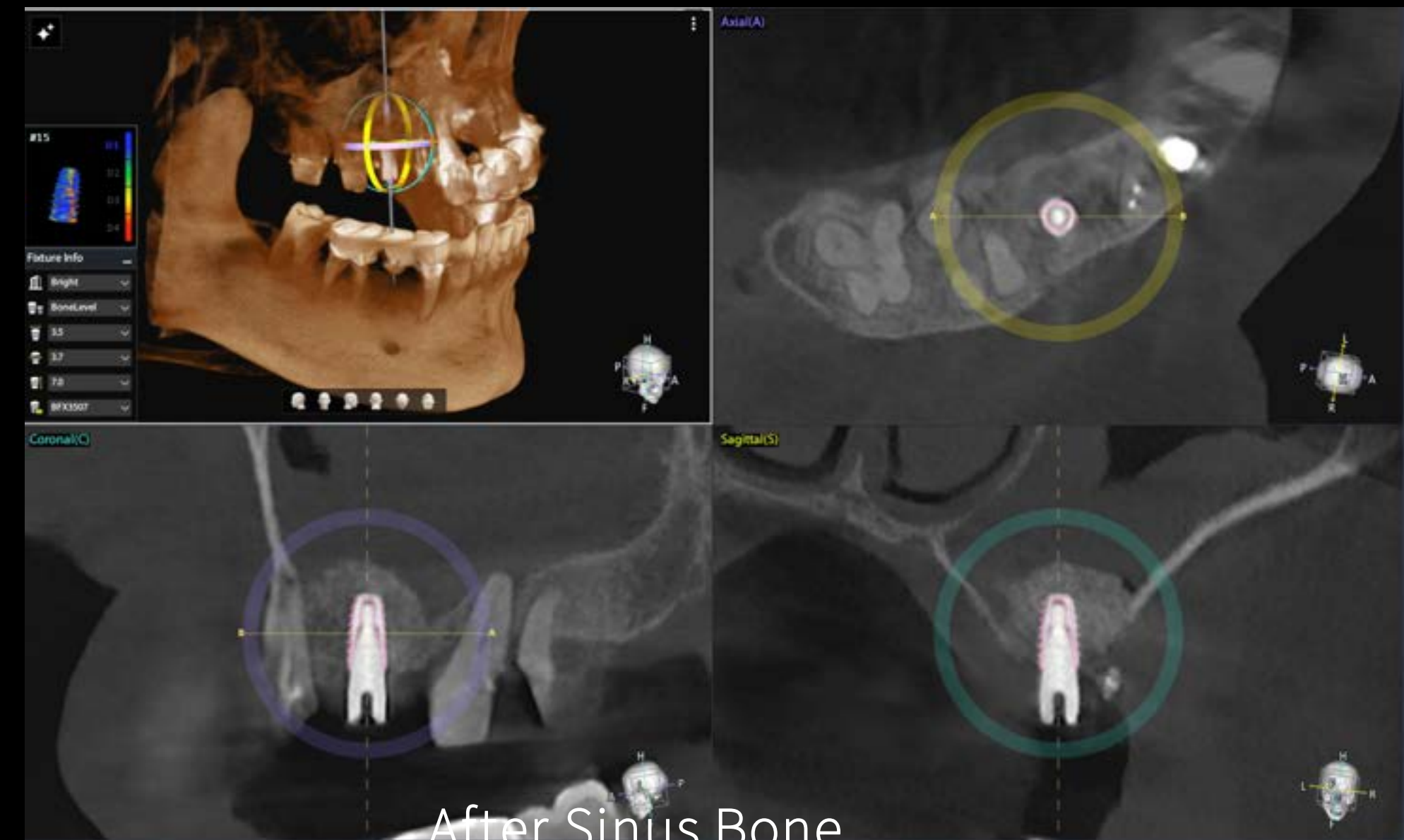
NEW

AI Sinus Bone Graft

Based on segmented maxillary sinus data, the AI feature provides a visualization of the expected augmented volume in areas requiring sinus grafting.



Bone Graft Simulation



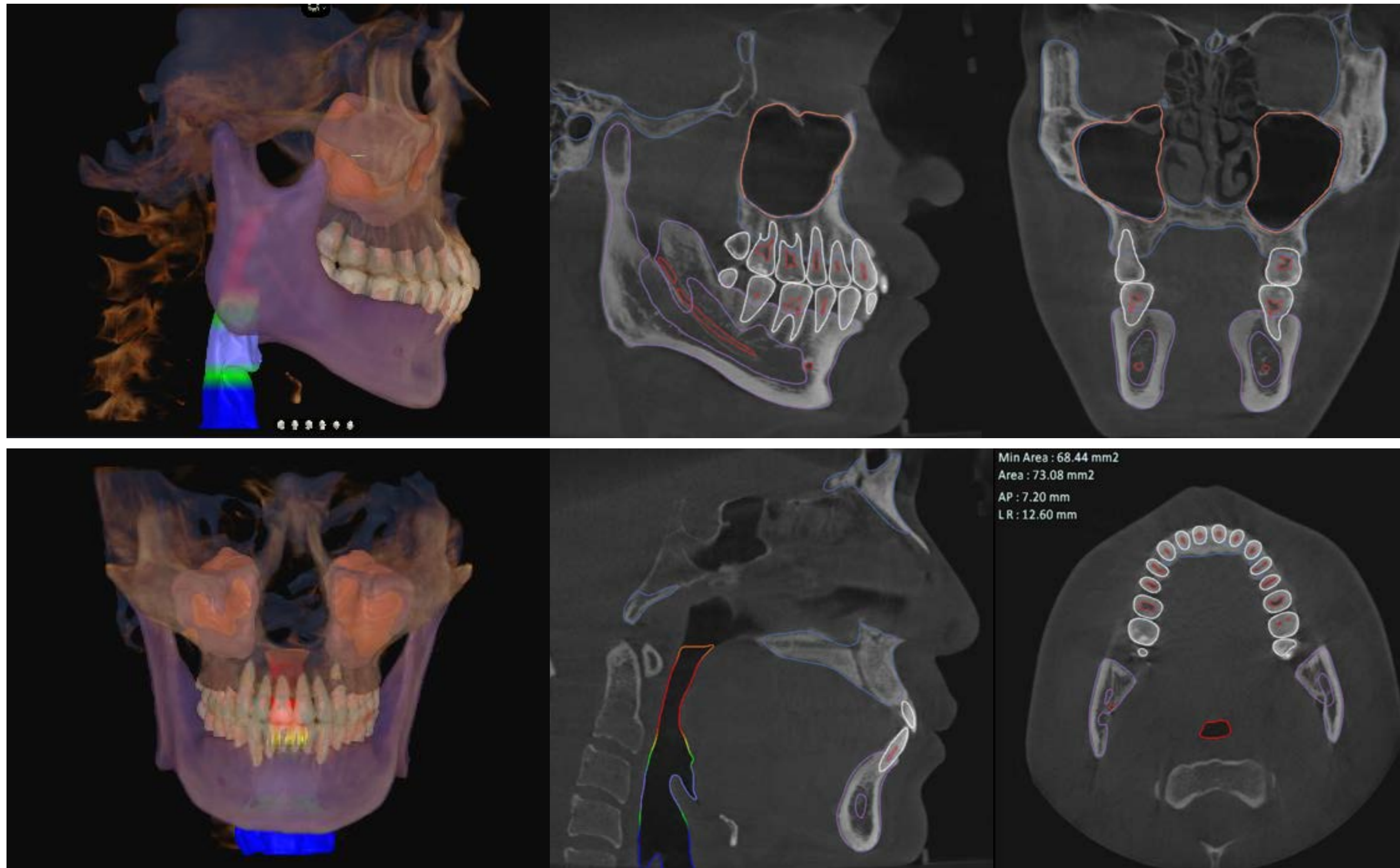
After Sinus Bone
Graft

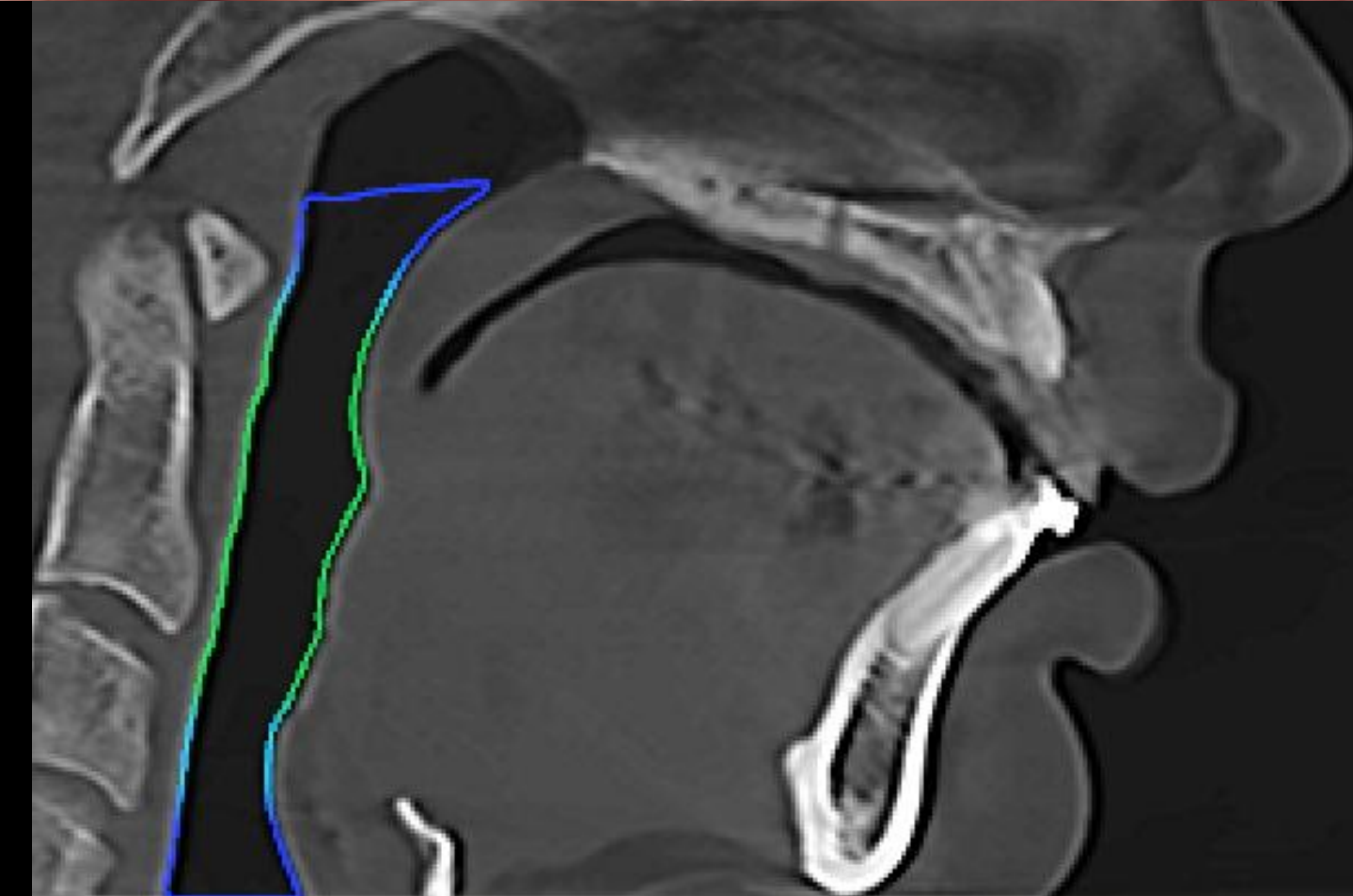
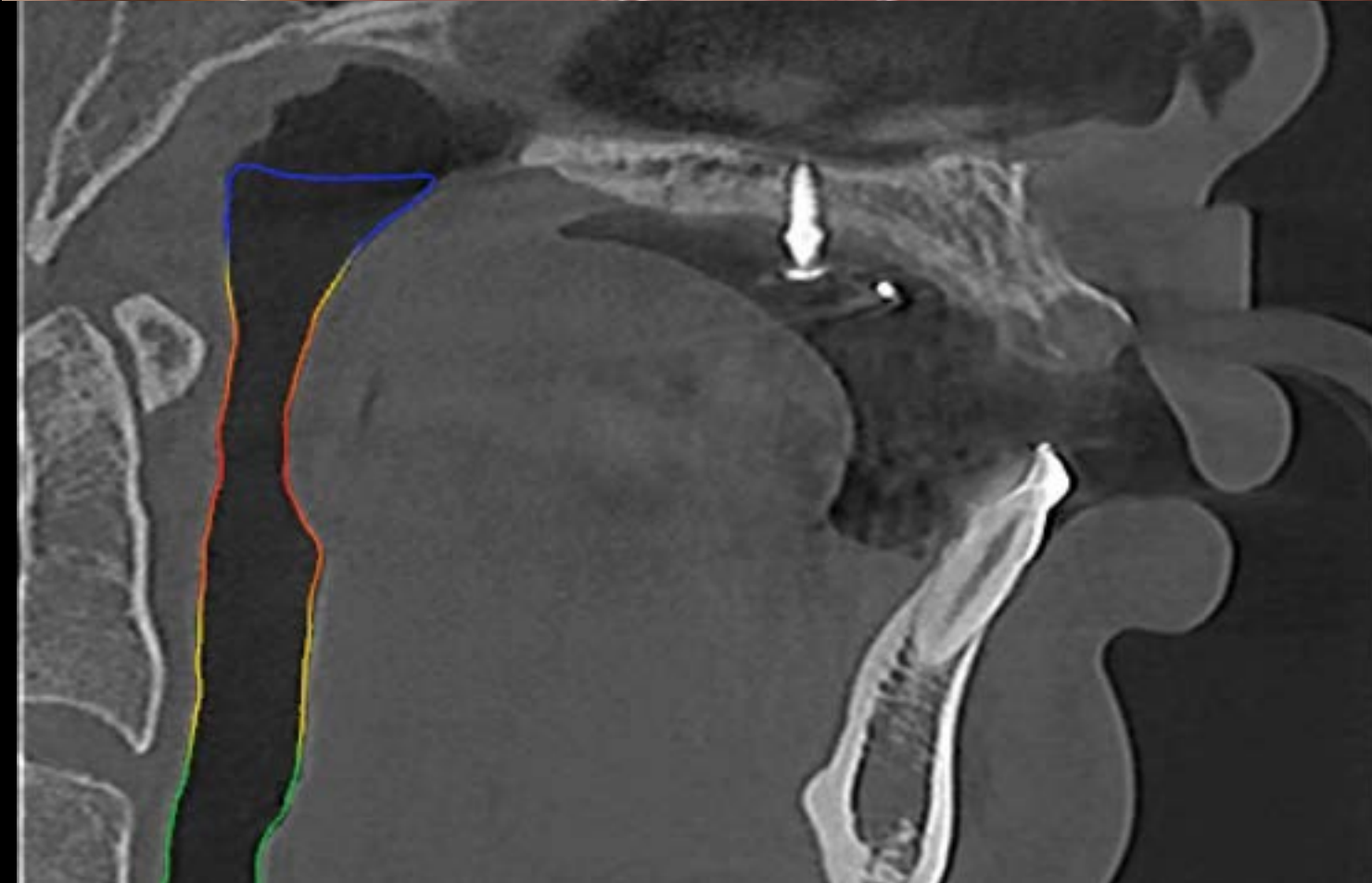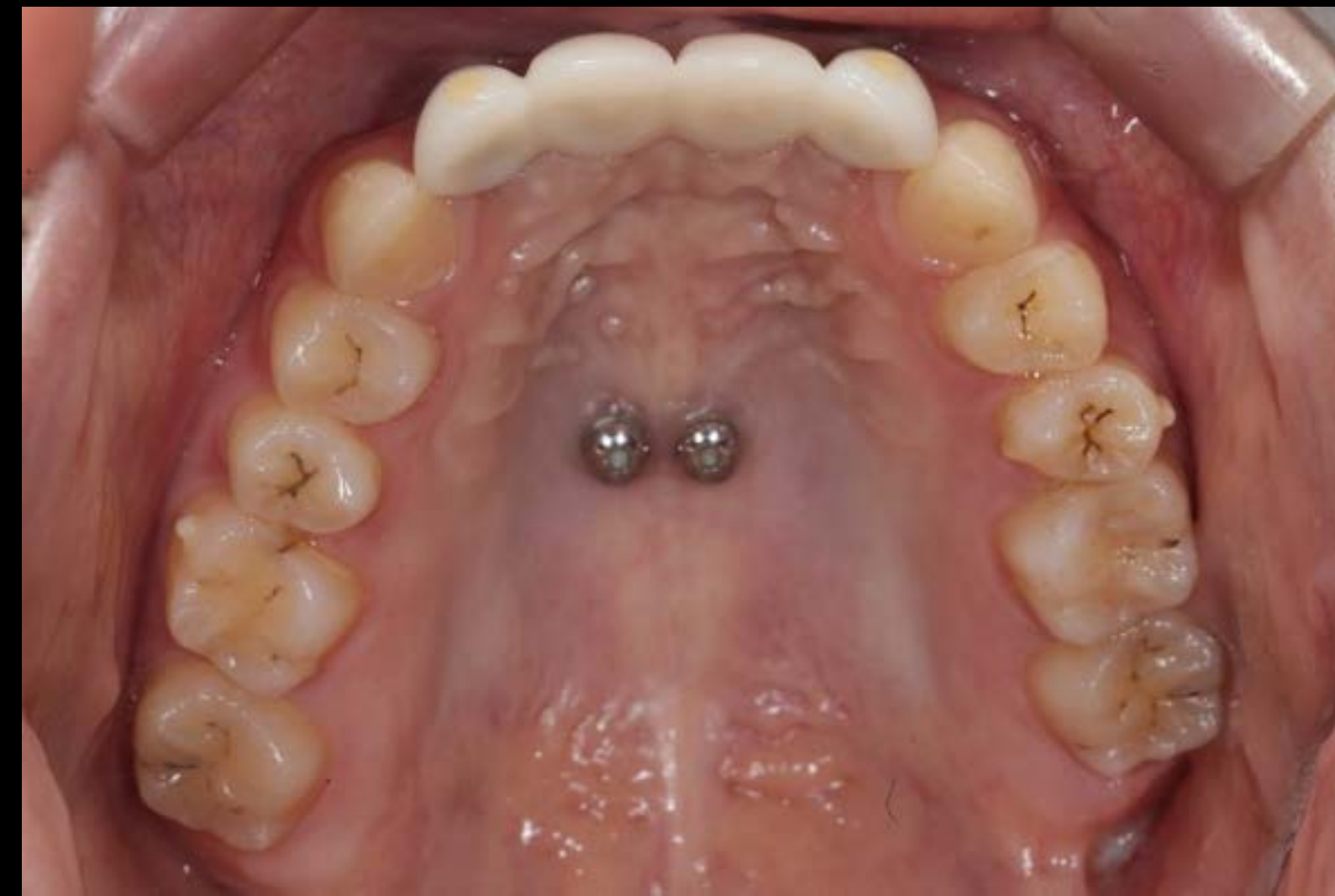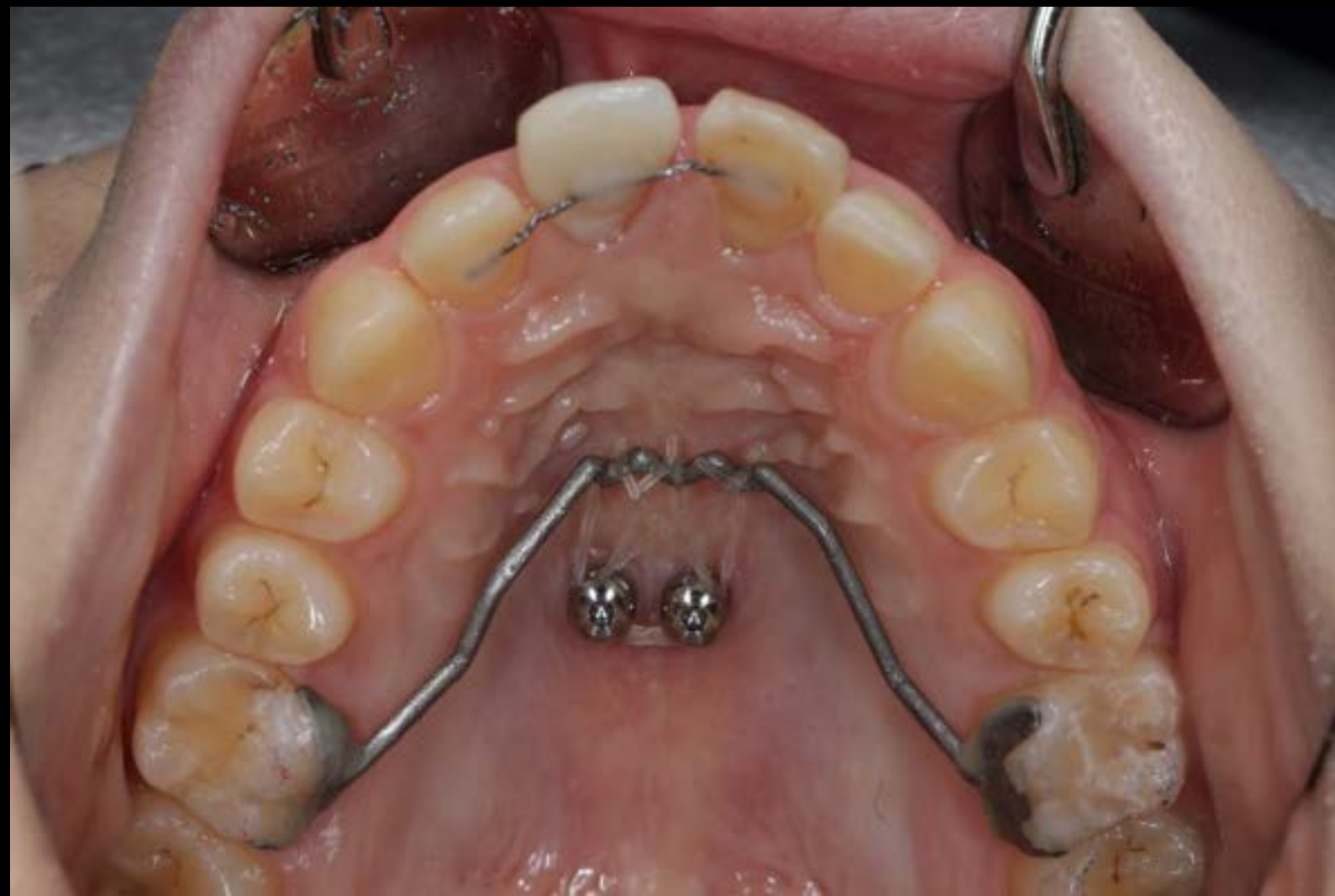Clinical Value

NEW

AI Segmentation

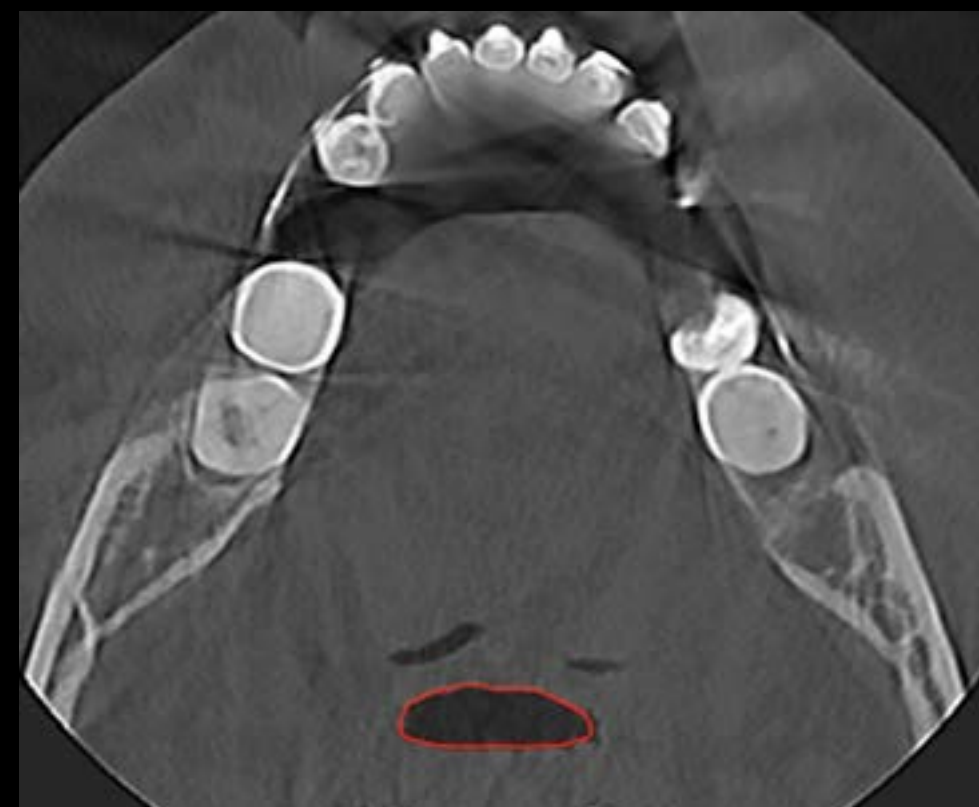Automatically segments teeth, nerves, bones, sinus and airway clearly — very helpful for intuitive diagnosis and patient consultation.



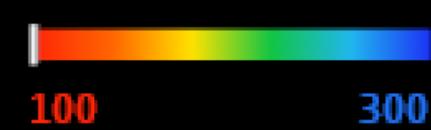


Before
2023.12

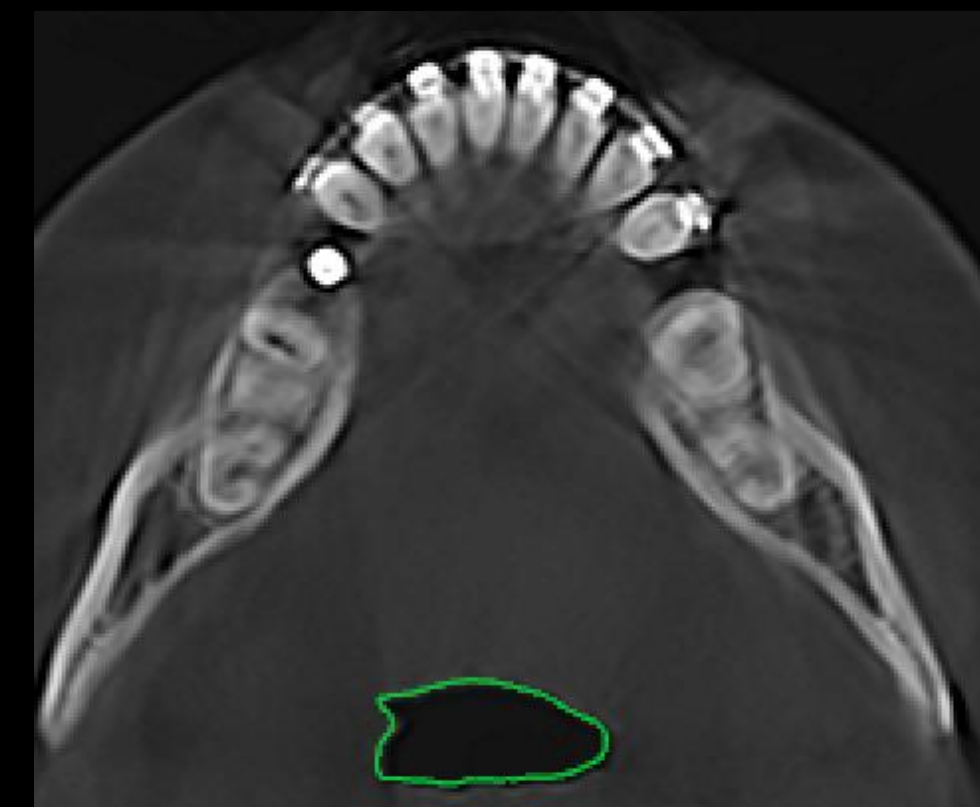
After
2025.08



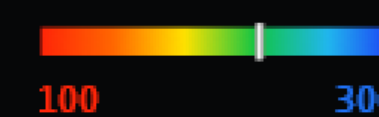Total Volume : 11.13 cc
Min Area : 0.00 mm2
Area : 96.12 mm2
AP : 6.20 mm
LR : 19.00 mm



96.12

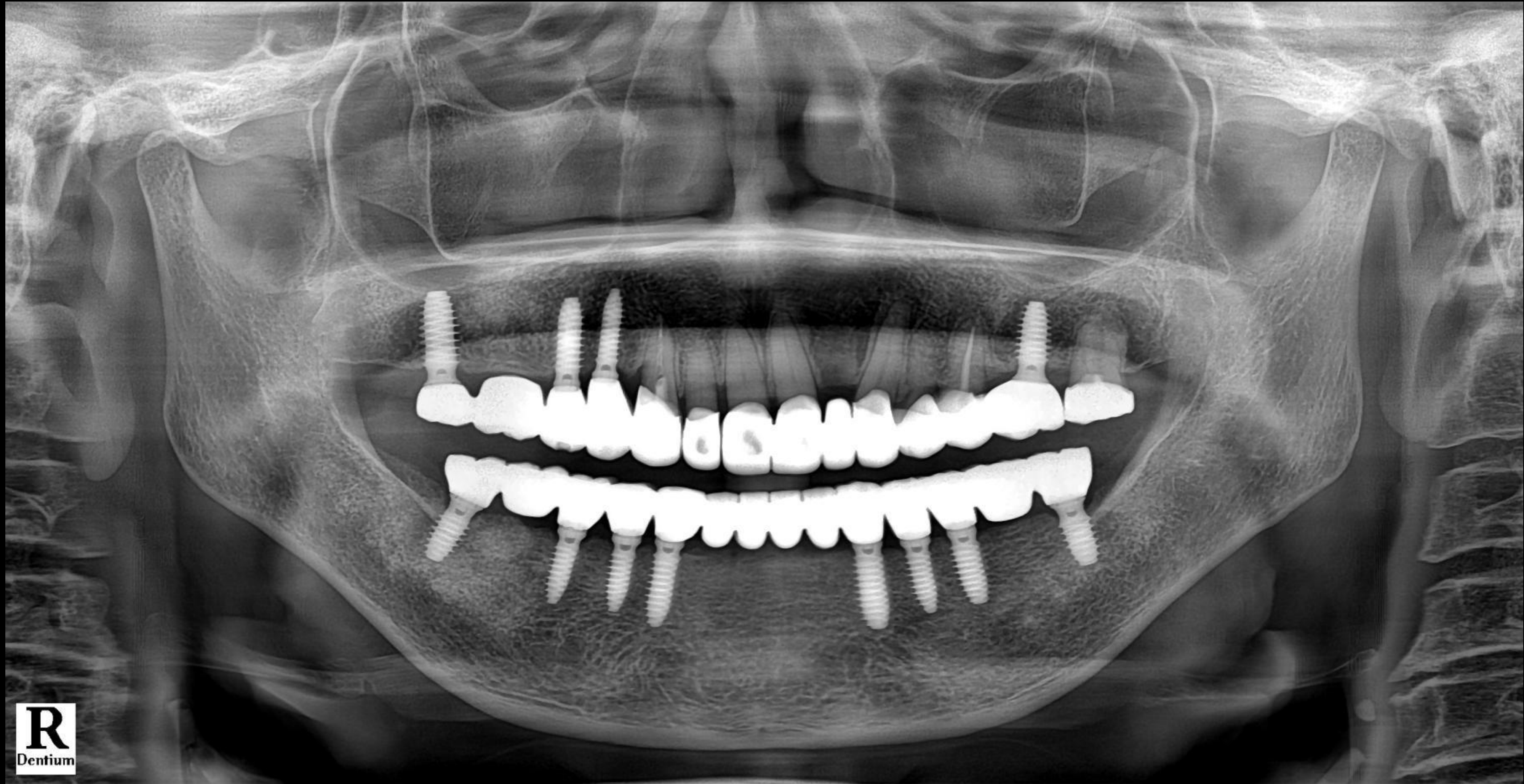

Total Volume : 15.80 cc
Min Area : 196.72 mm2
Area : 221.80 mm2
AP : 10.80 mm
LR : 24.20 mm

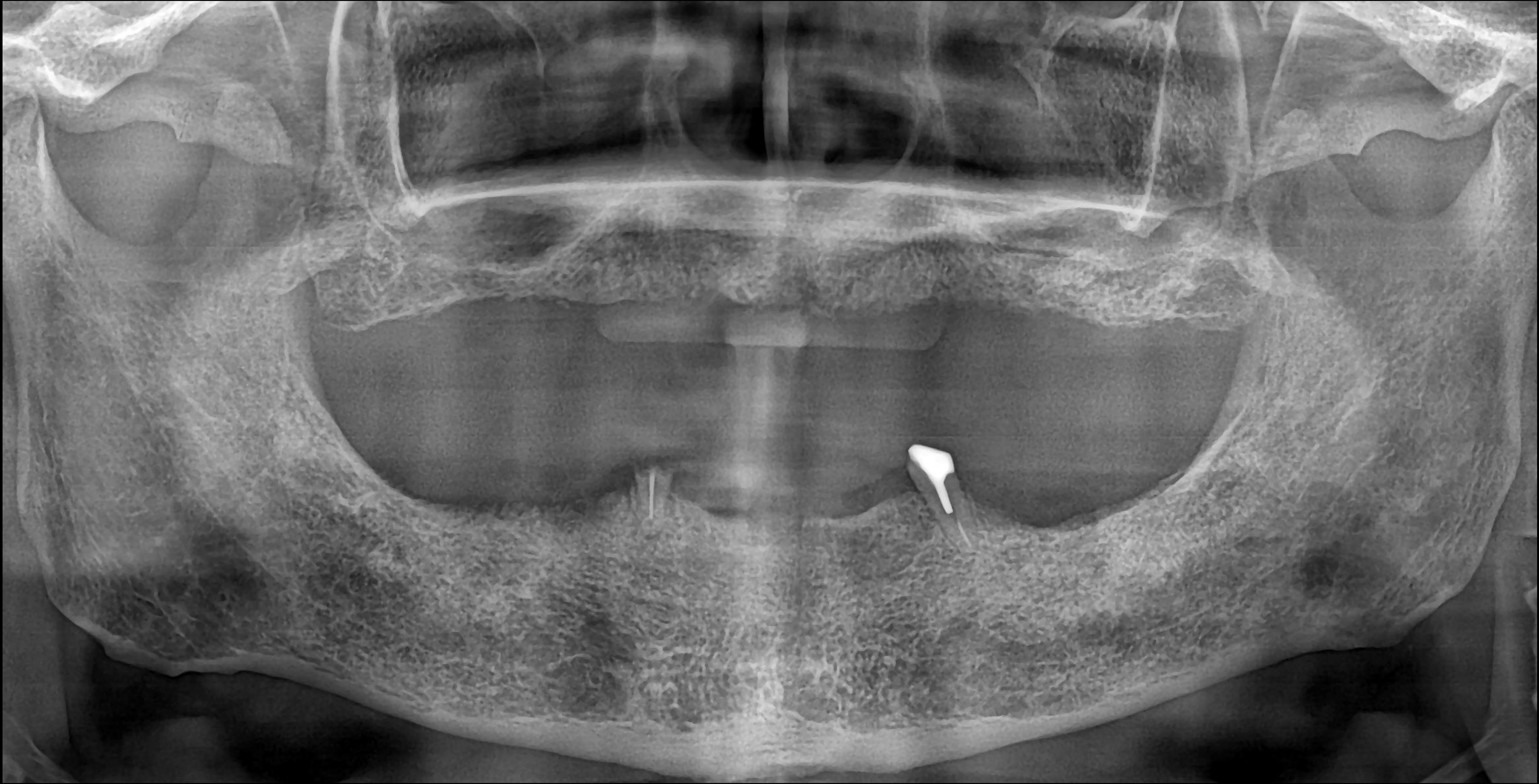


221.80

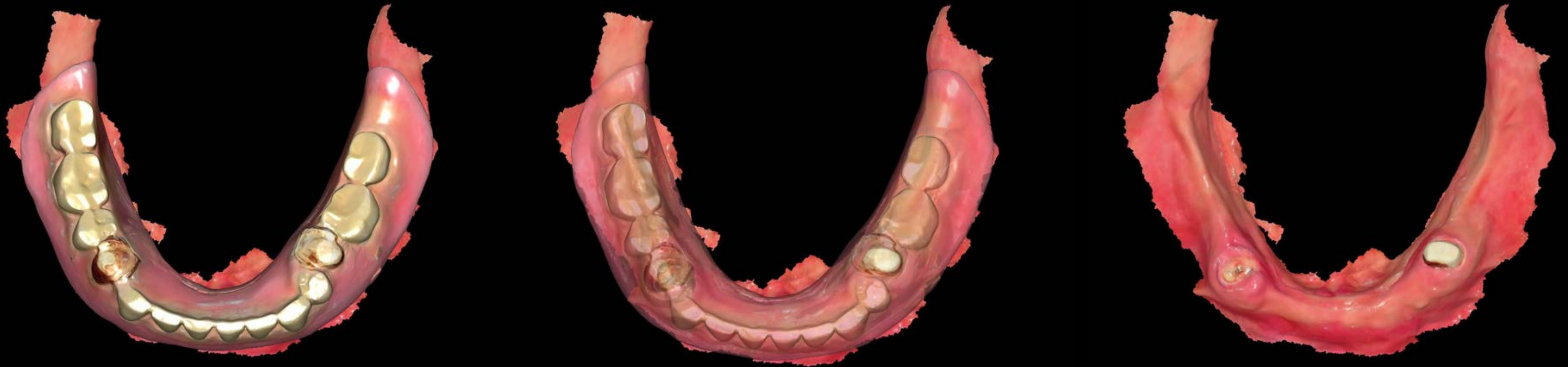Mandibular orthodontic
treatment in progress
→ Continuous F/U required



Pre-op (2025-07-08)



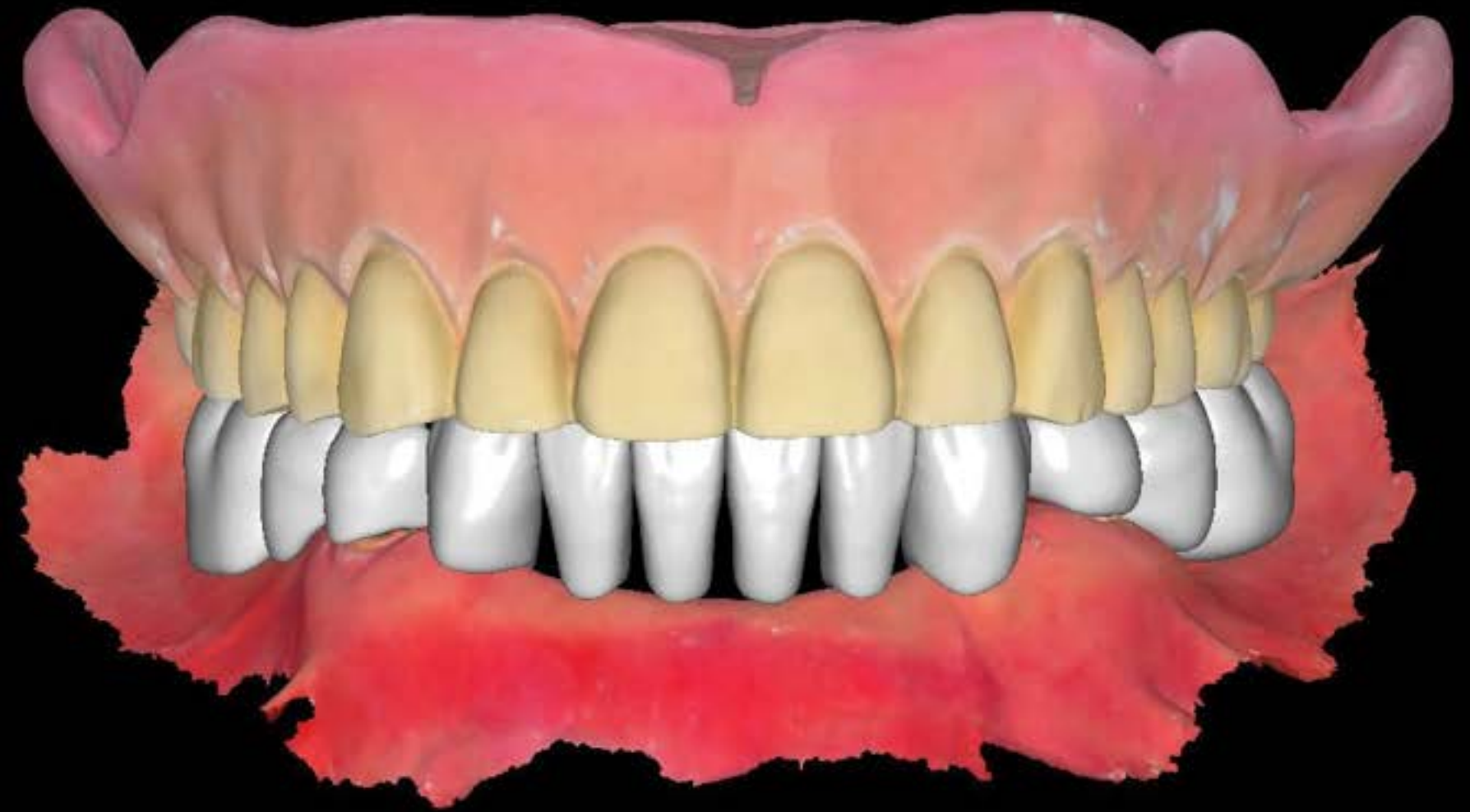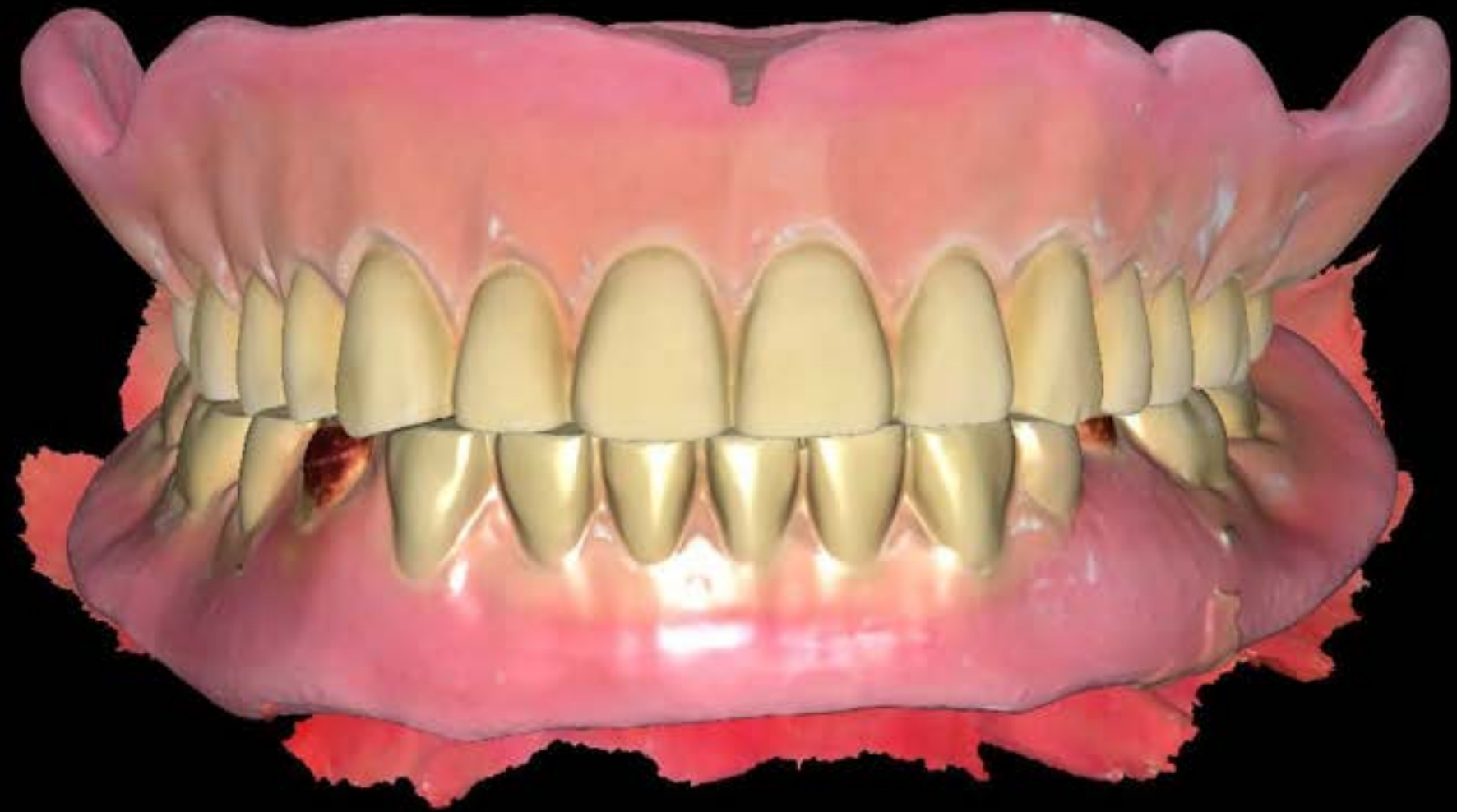All on x Denture Stent



Duplicating an existing denture and using it as a stent

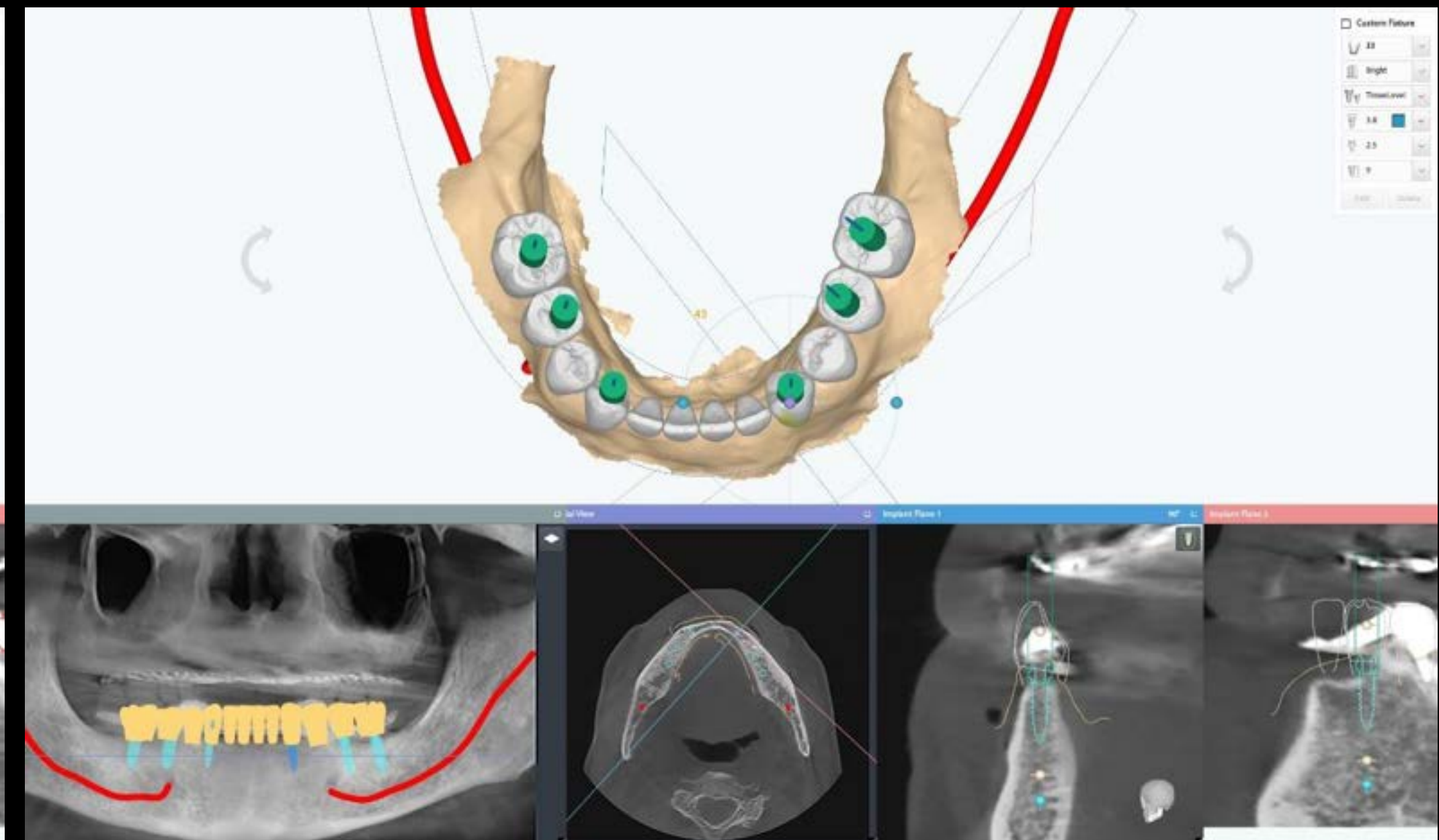
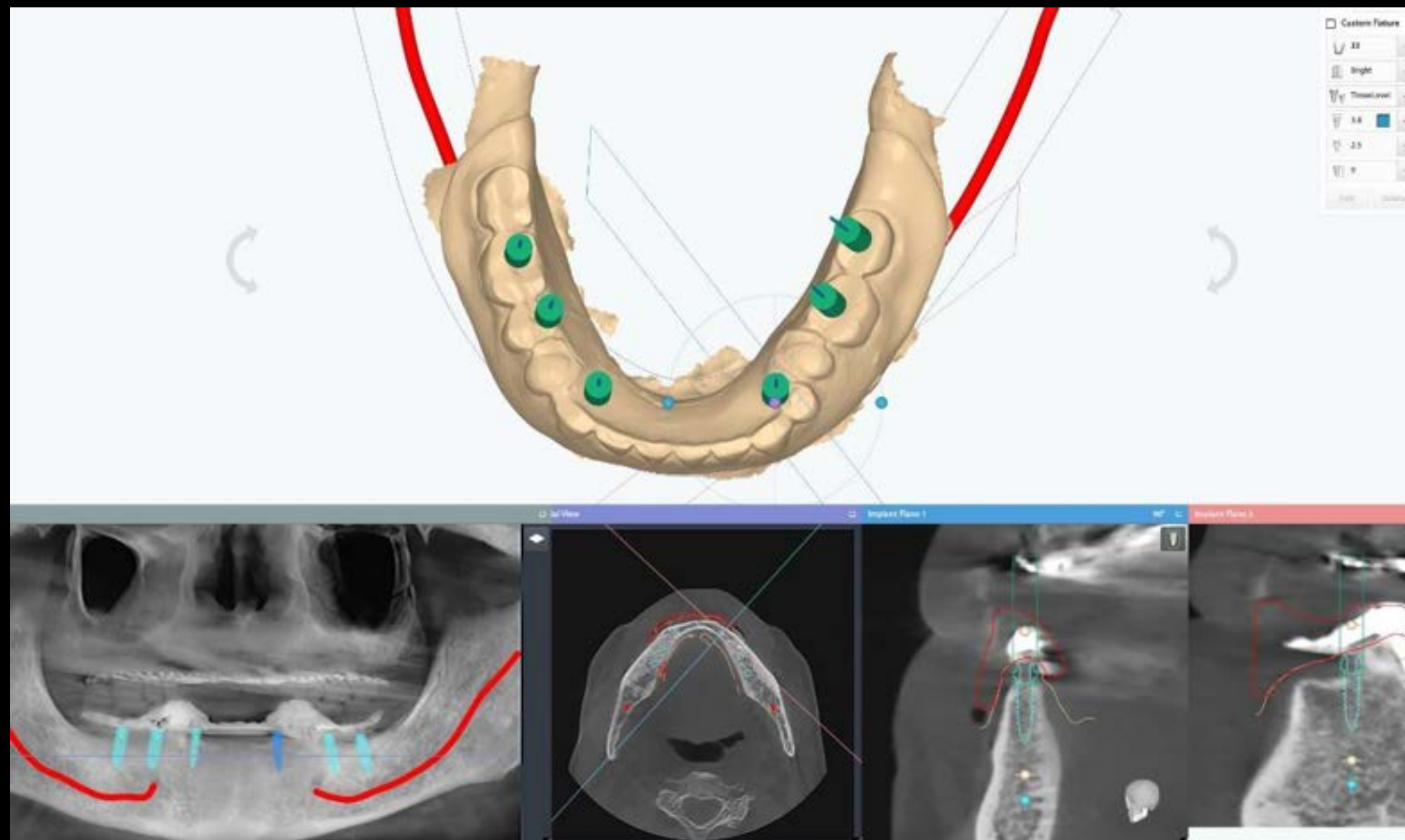
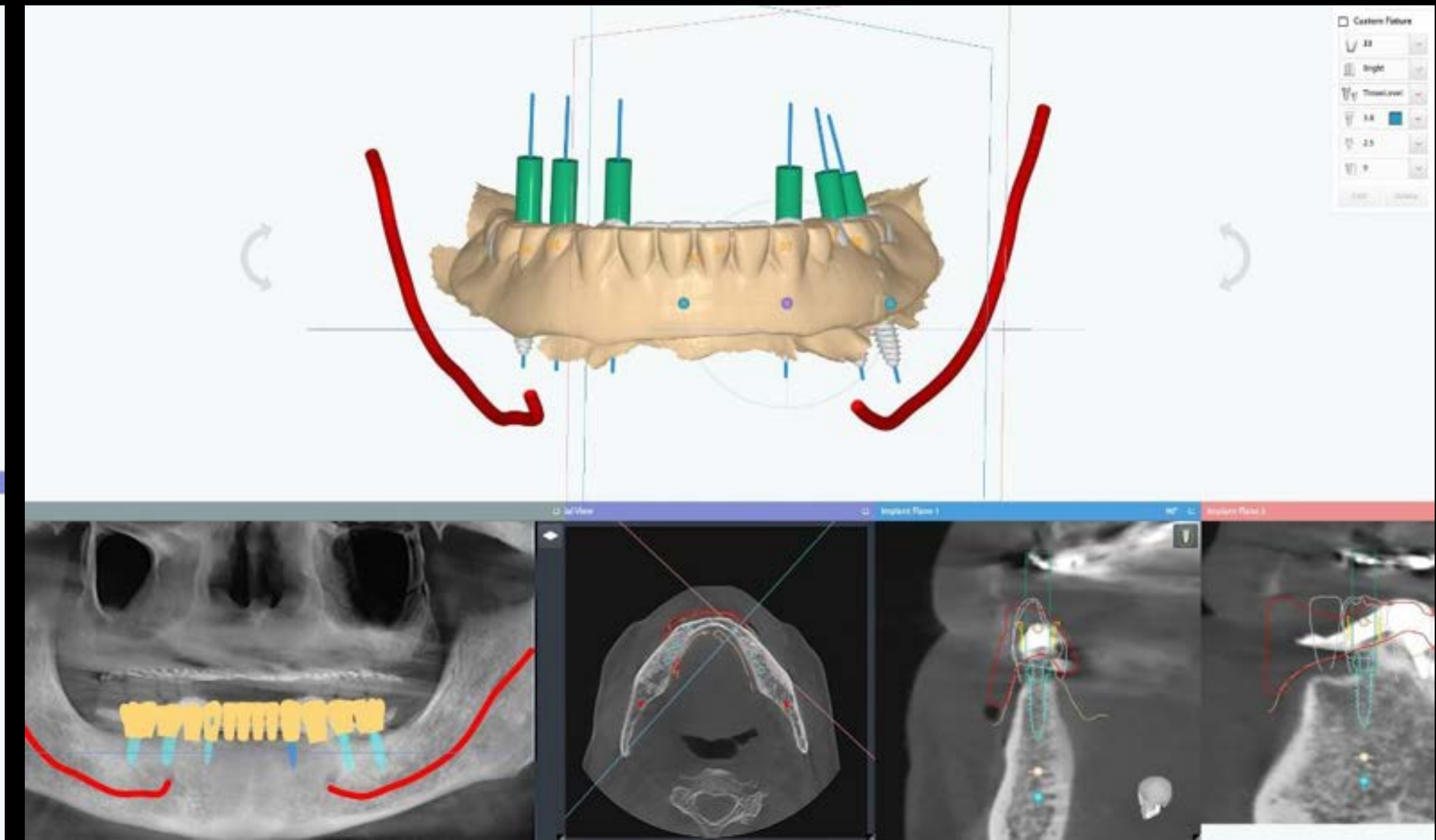
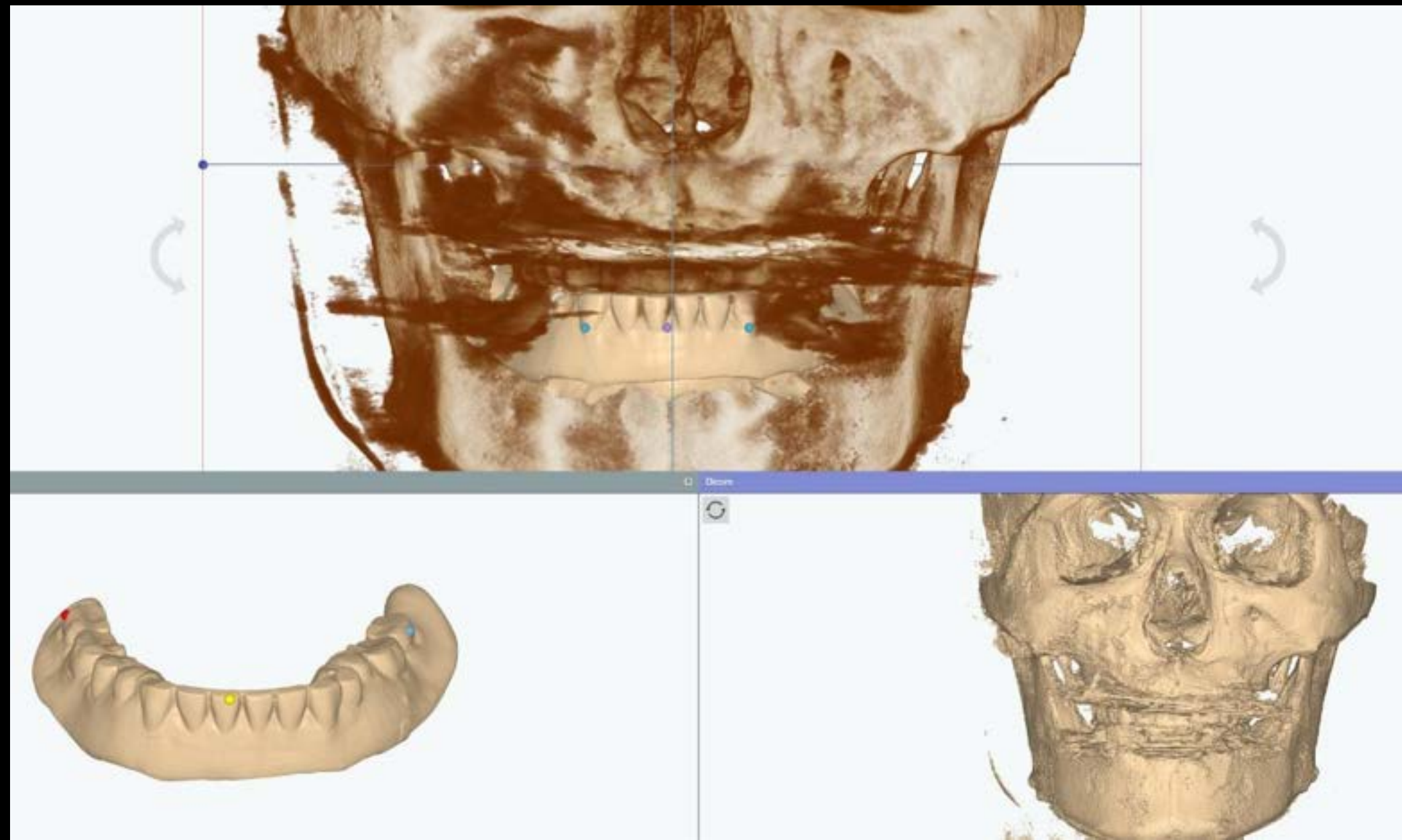
****Digital Guide software is used to check bone density at the surgical site and assess non ideal occlusion****

All on x Denture Stent

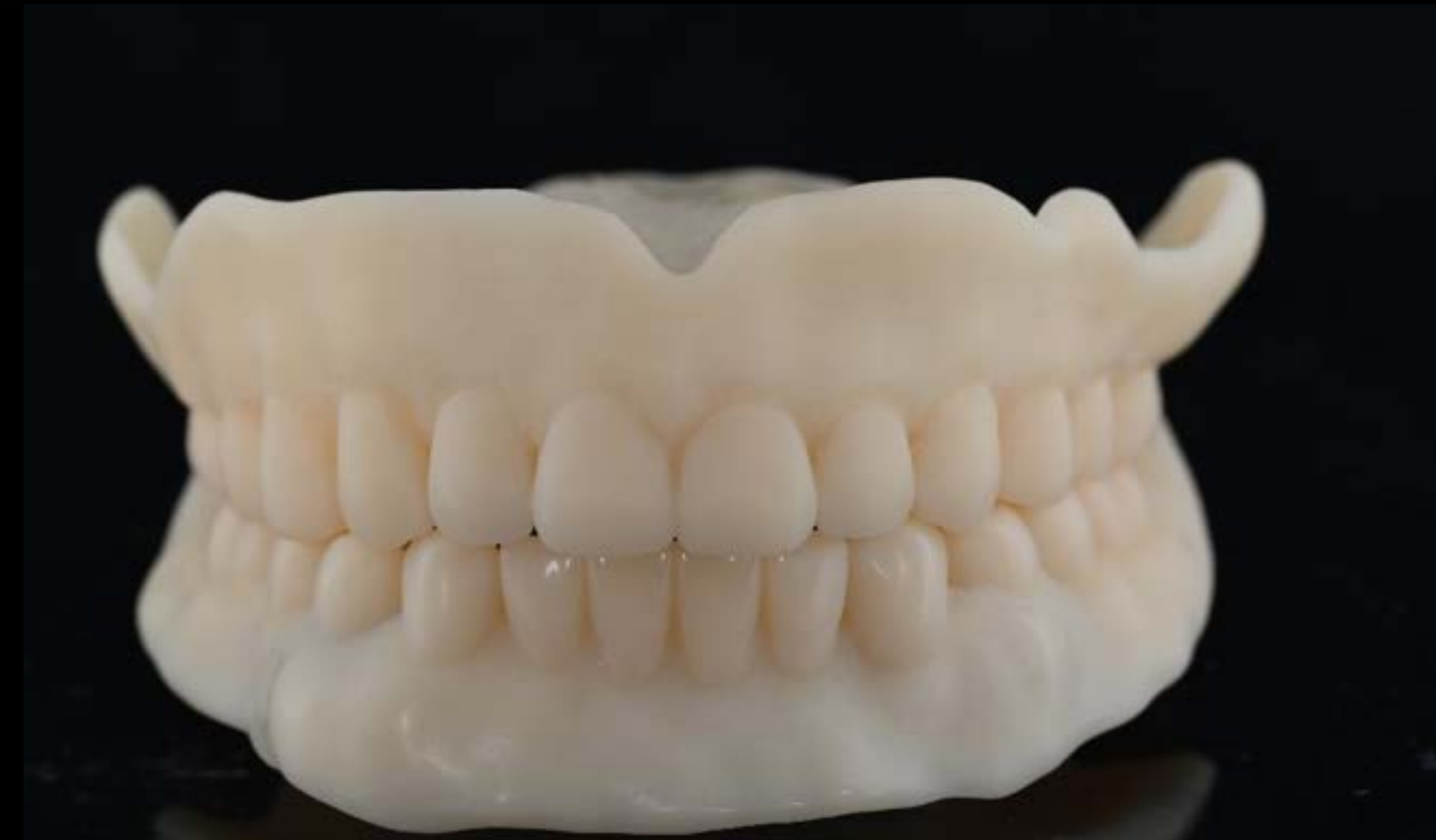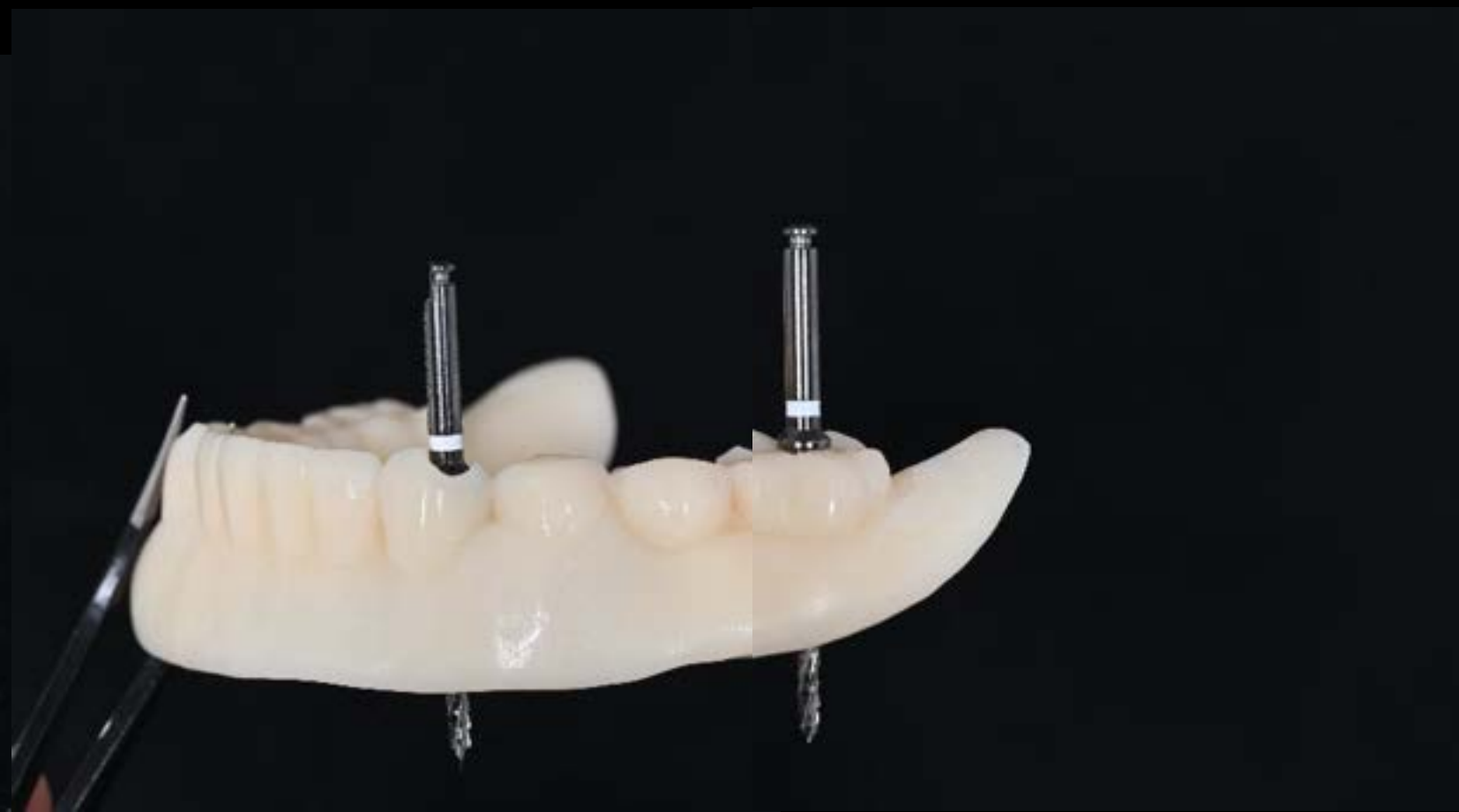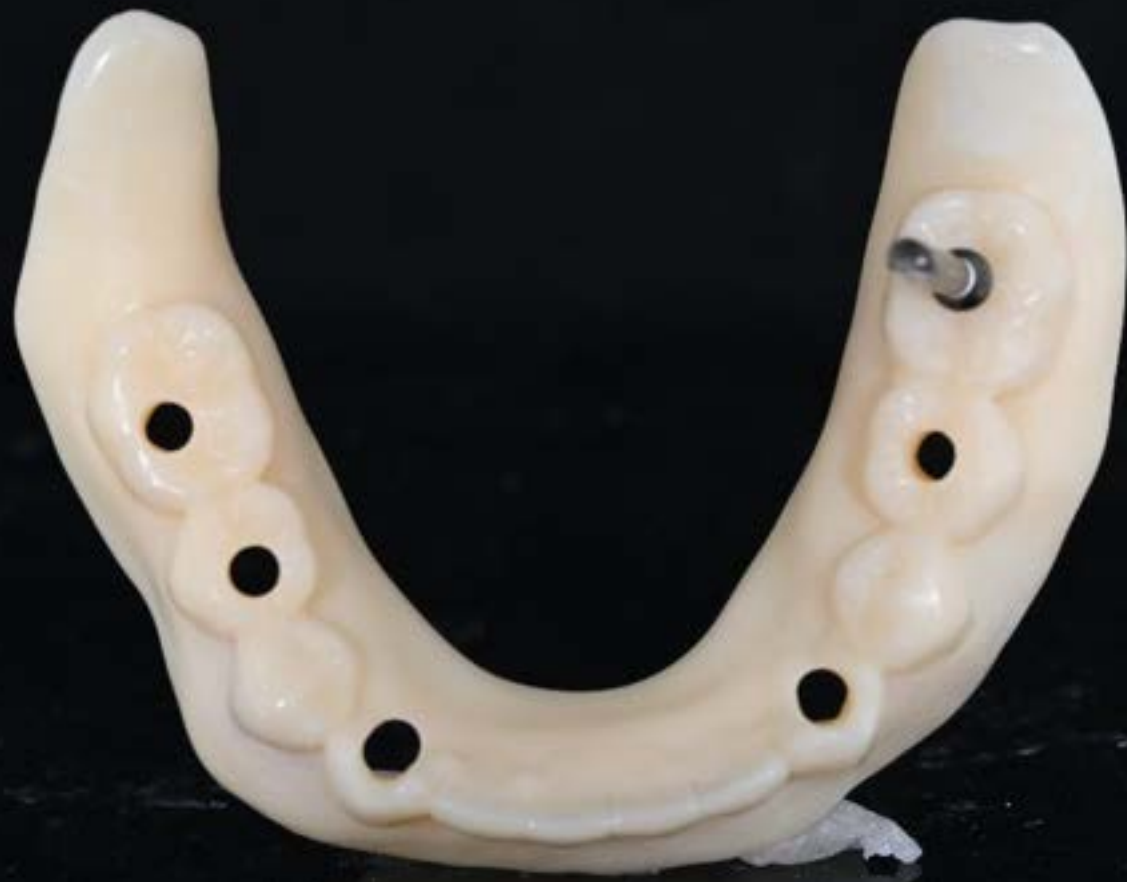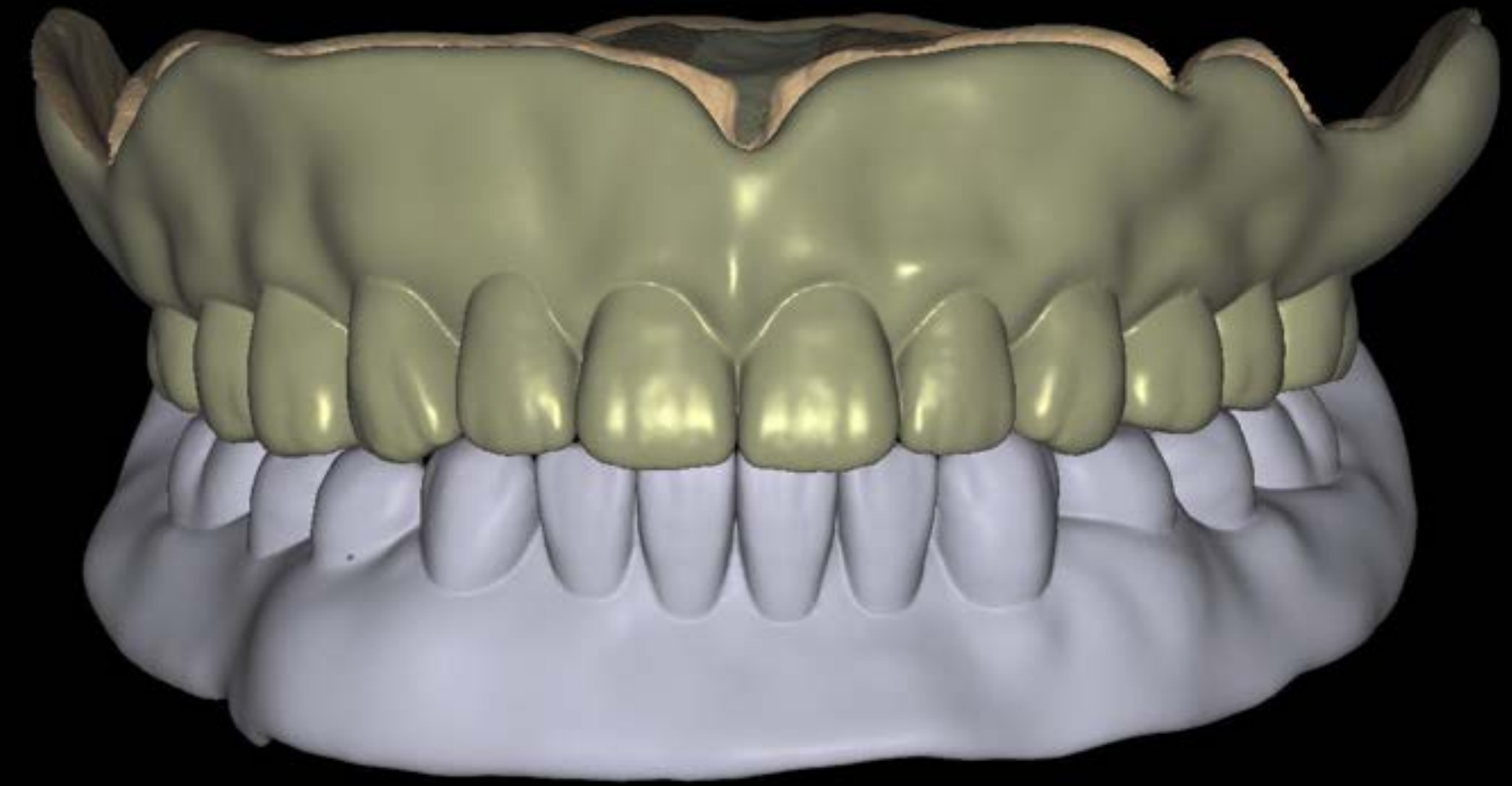
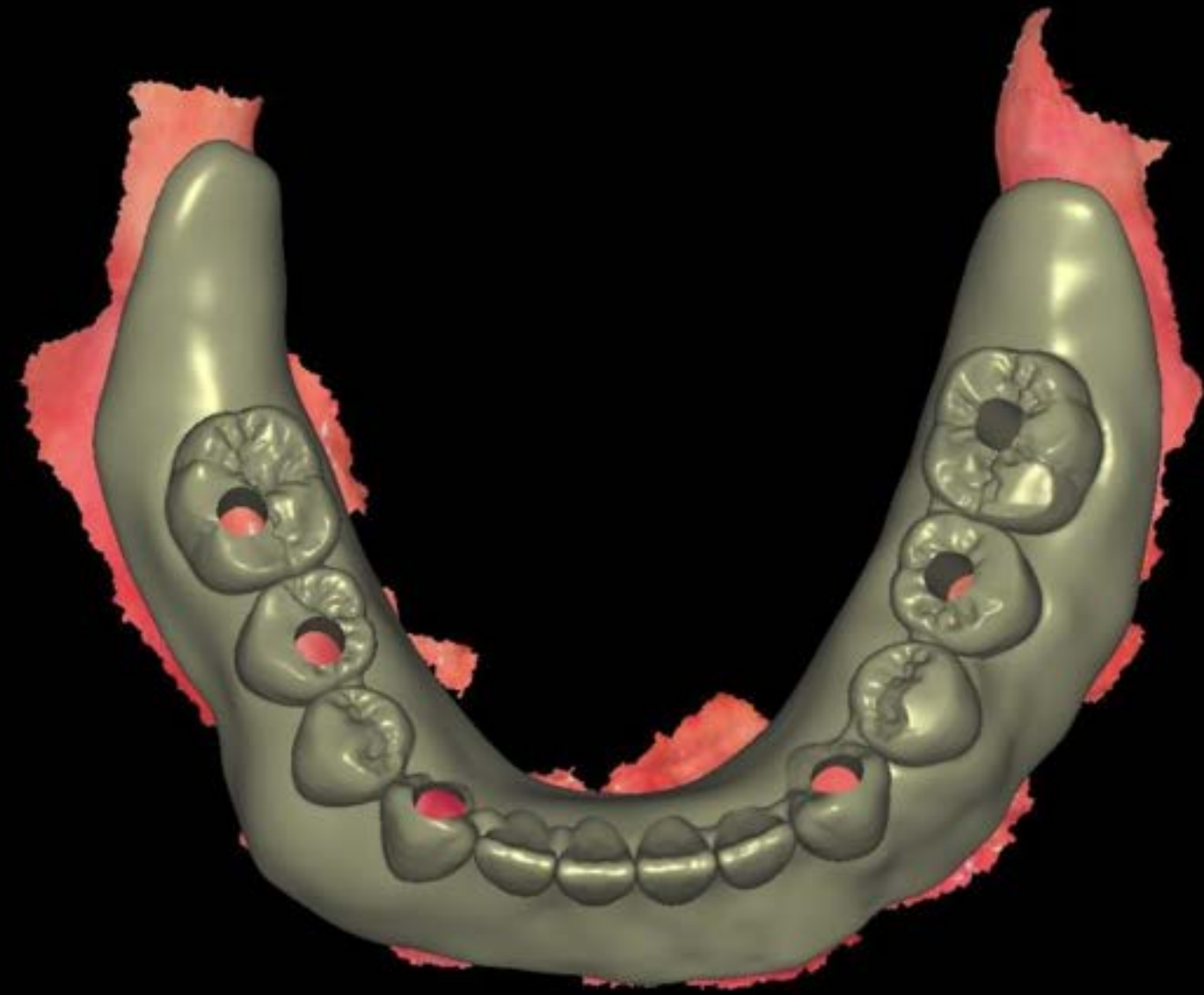


Set up in an ideal position instead of the existing denture's occlusion,
then fabricate a Denture stent & Check bite Denture

All on x Denture Stent

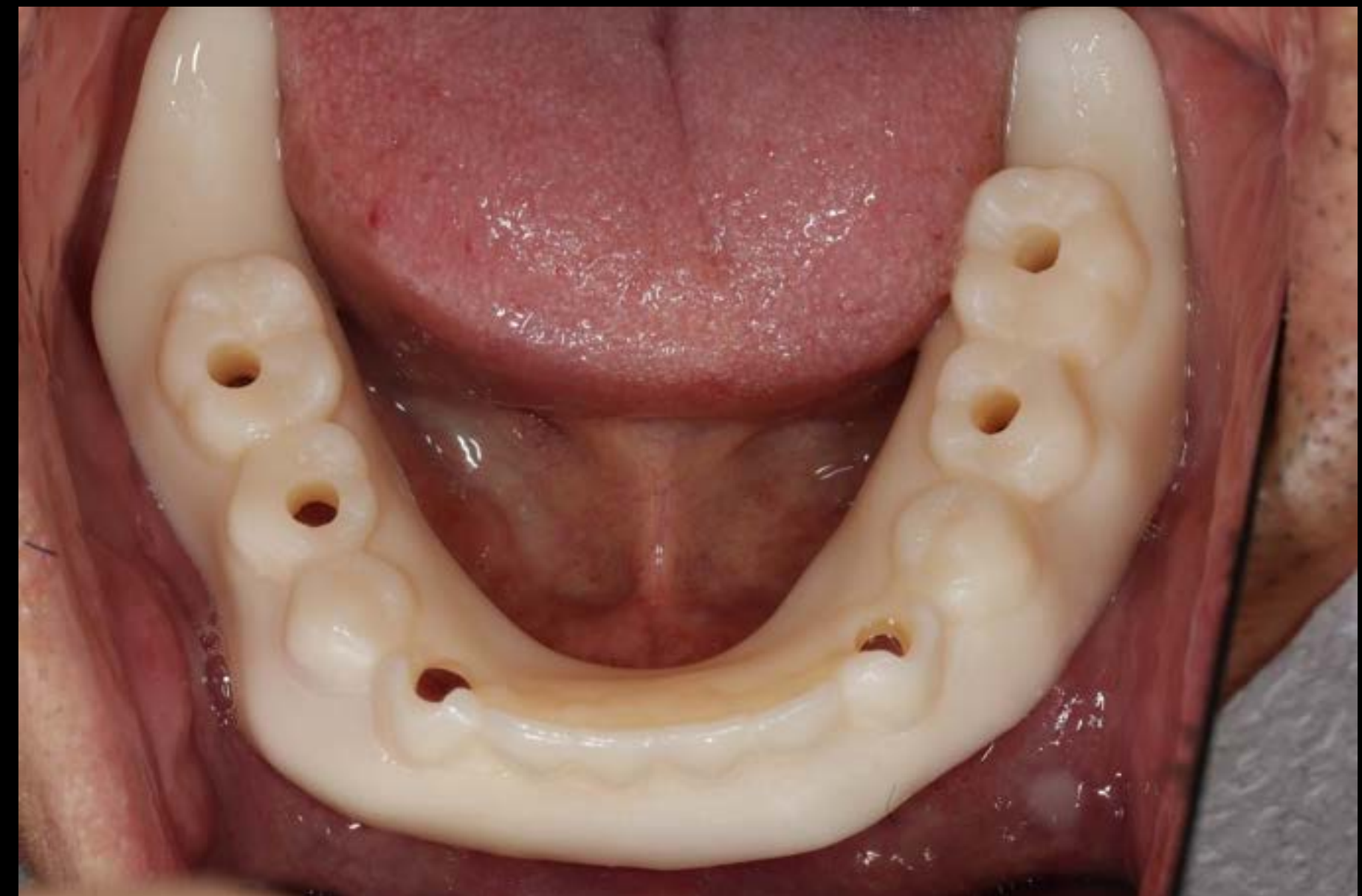
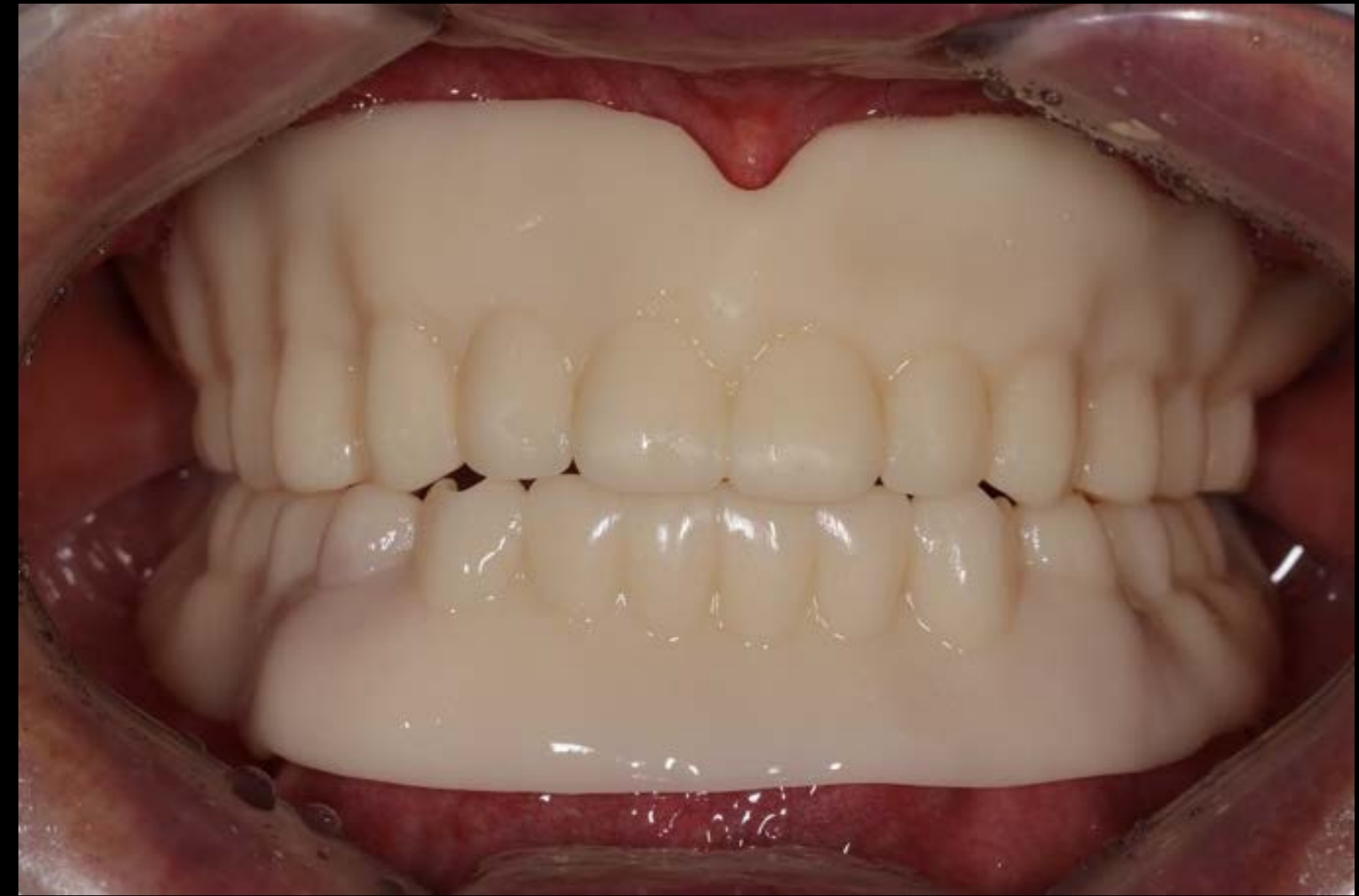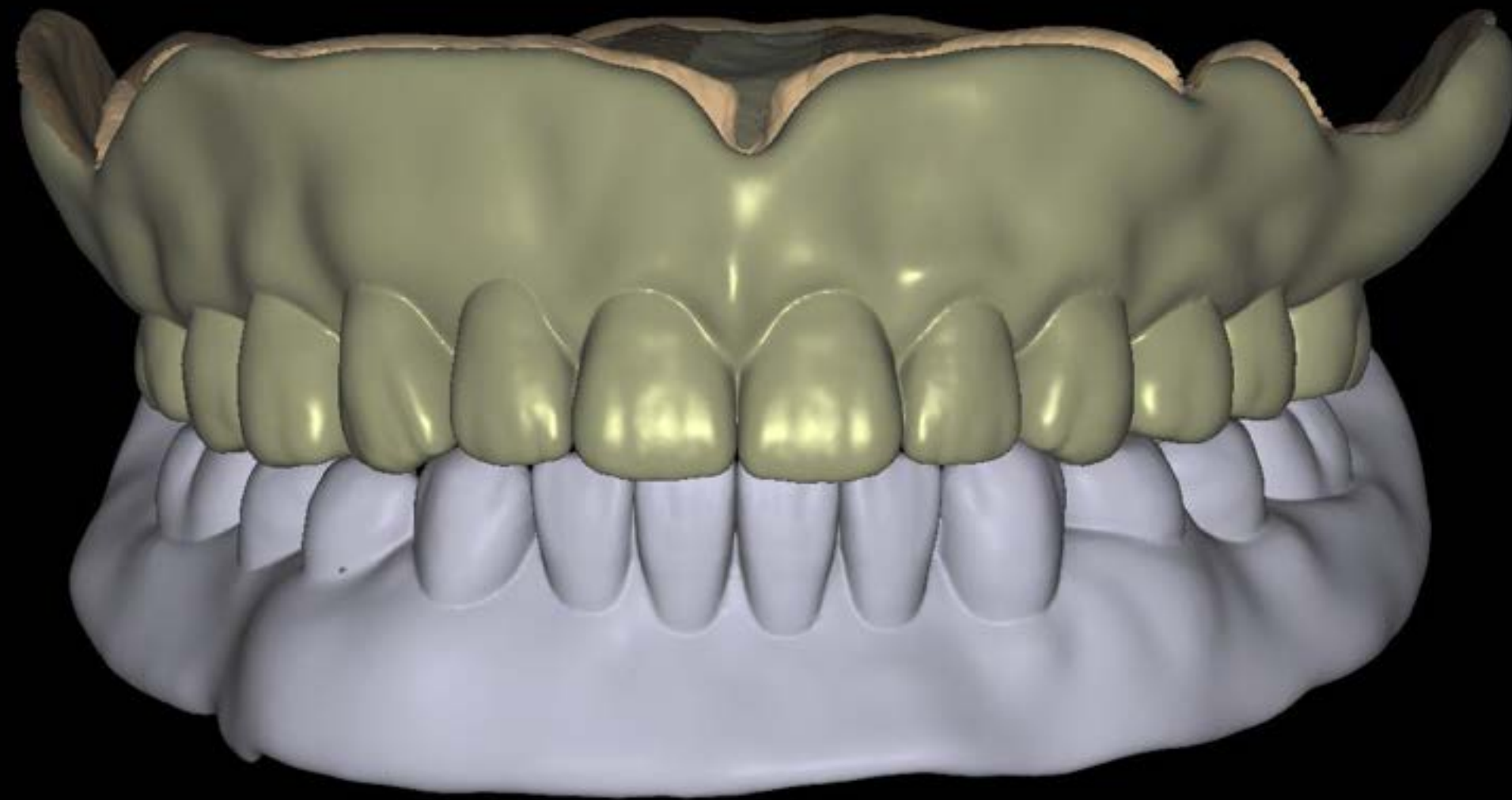


All on x Denture Stent



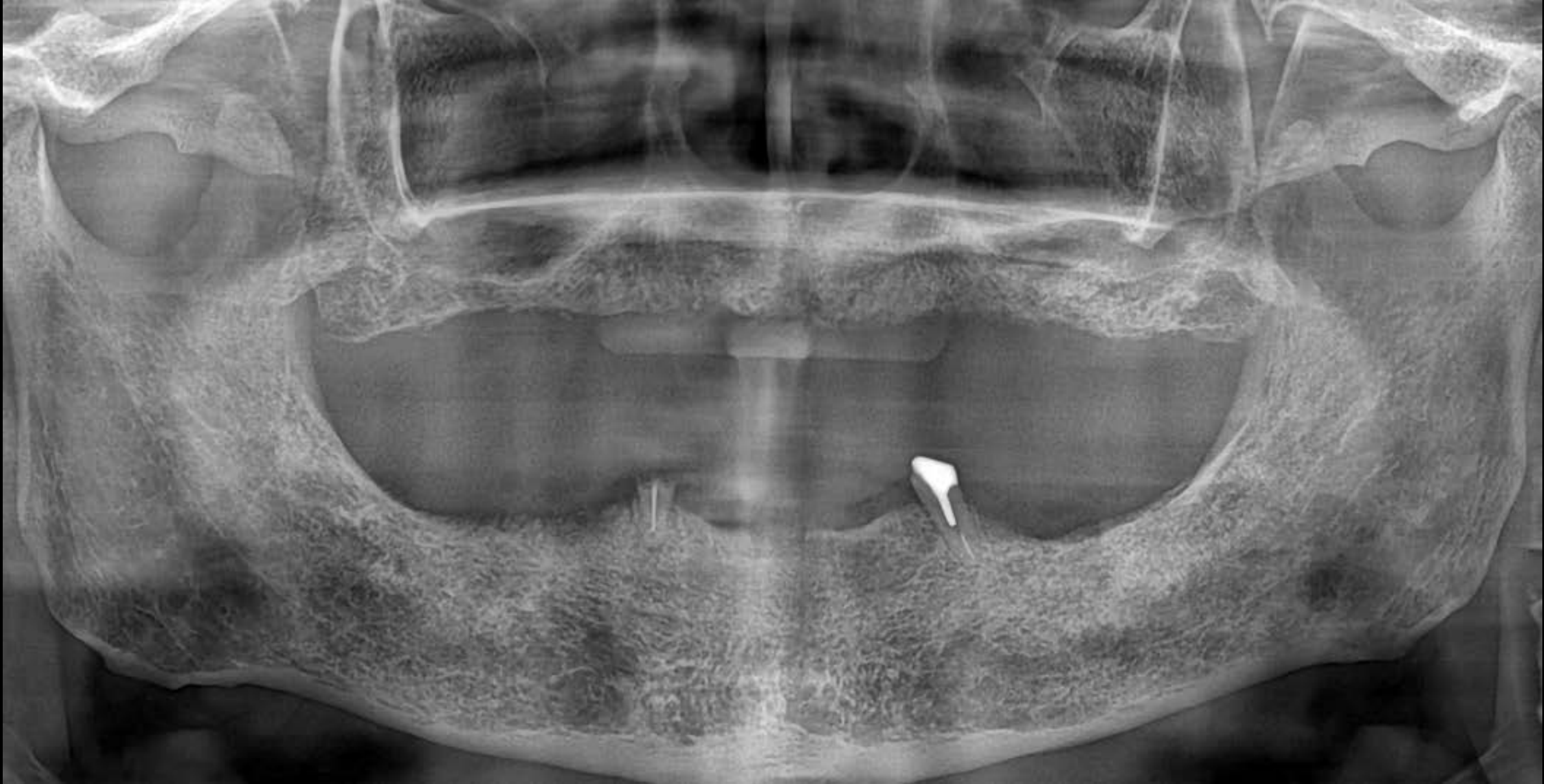기존 Denture의 교합관계 대신 ideal 한 위치로 Set up 후
Denture stent & Check bite Denture 제작

All on x Denture Stent

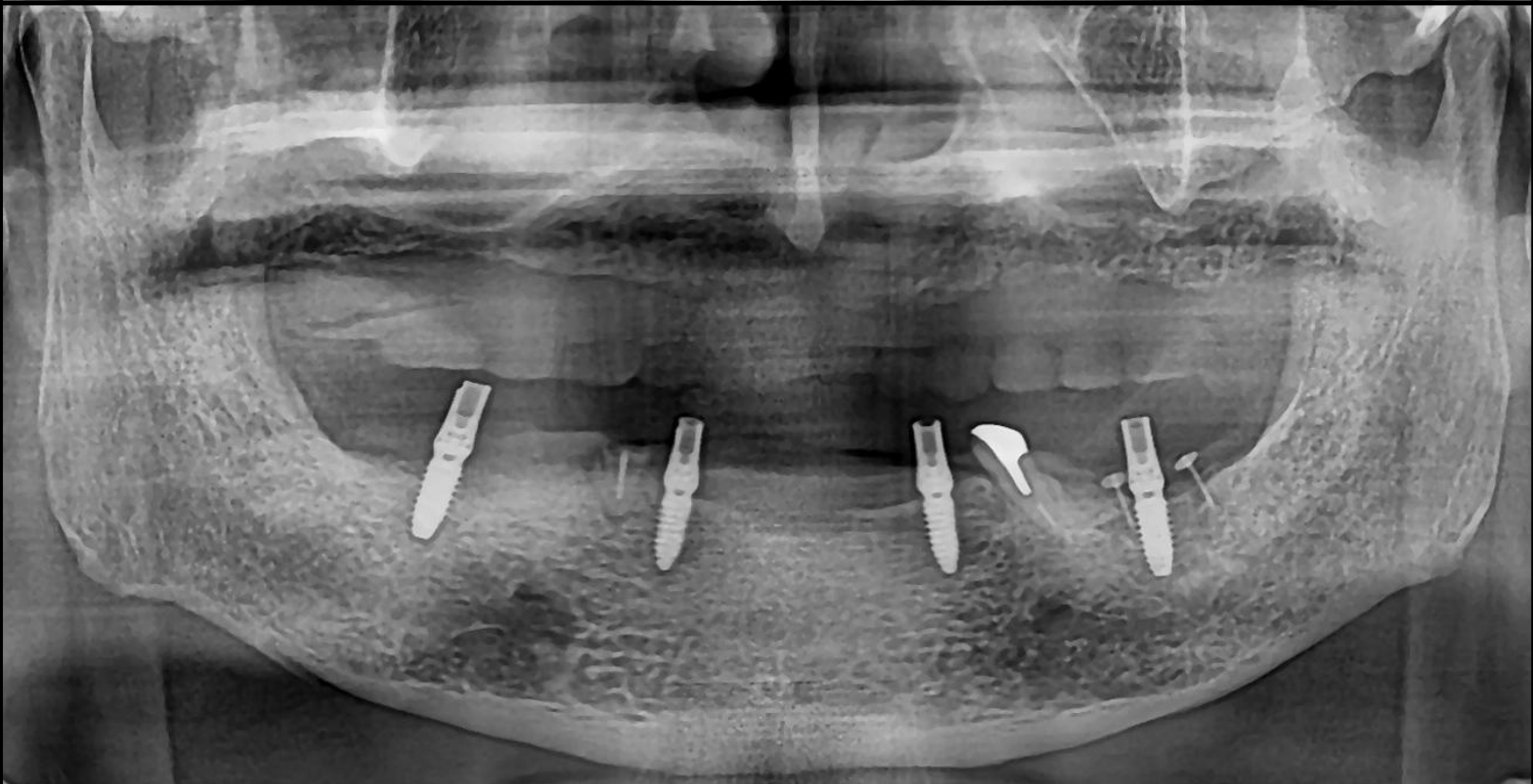


Check bite & Vertical dimension adjustments during the intraoral check bite

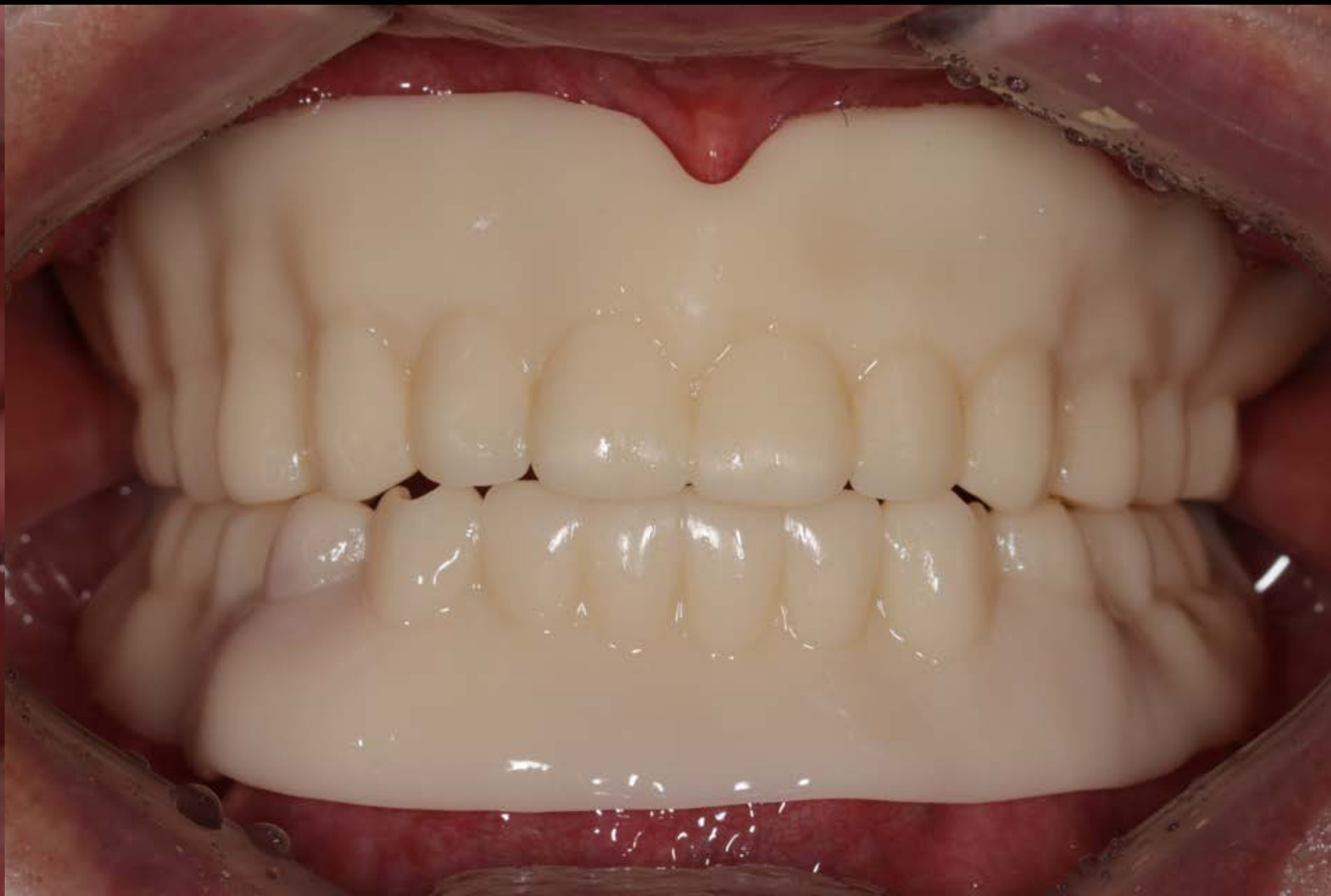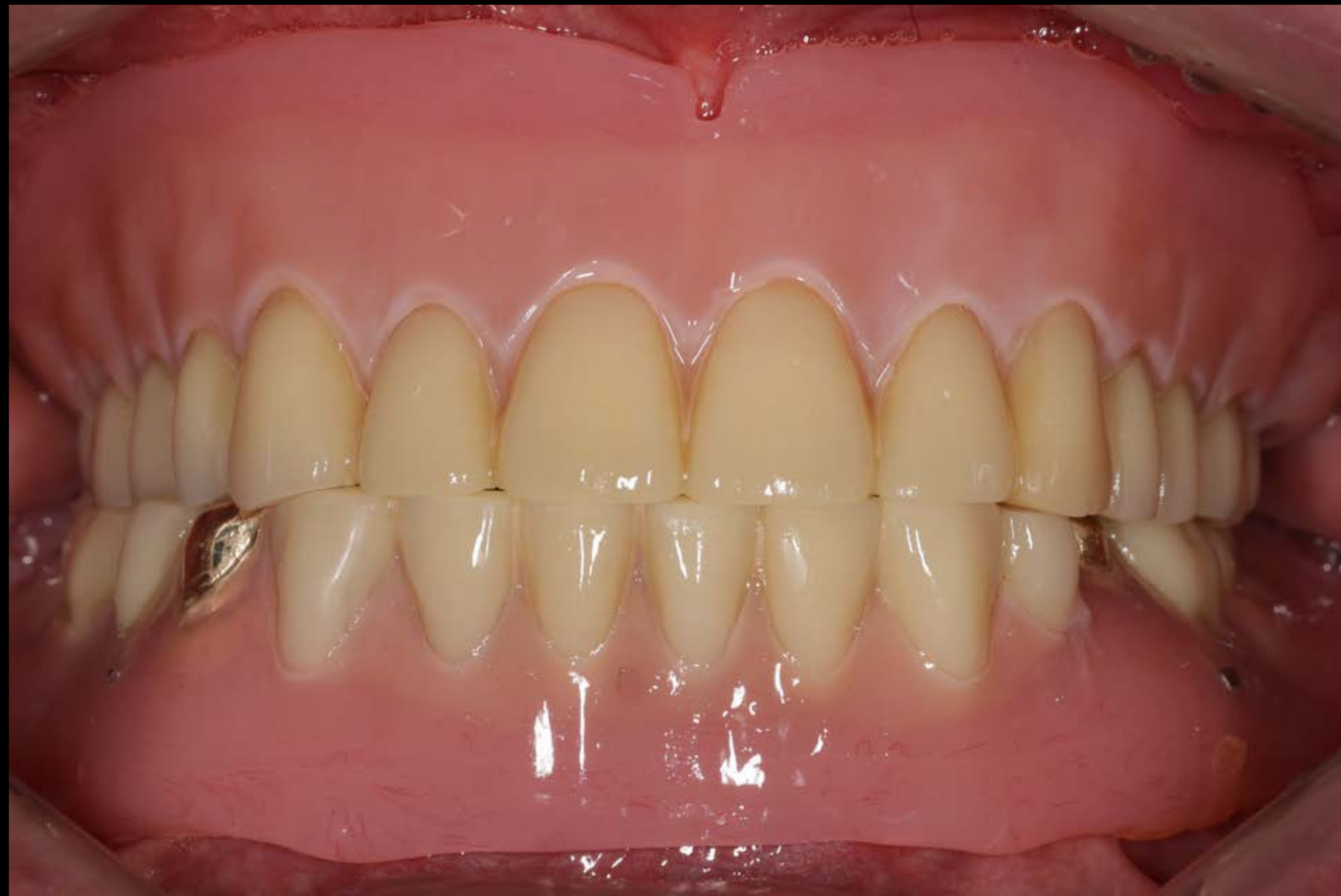Pre-op (2025-07-08)



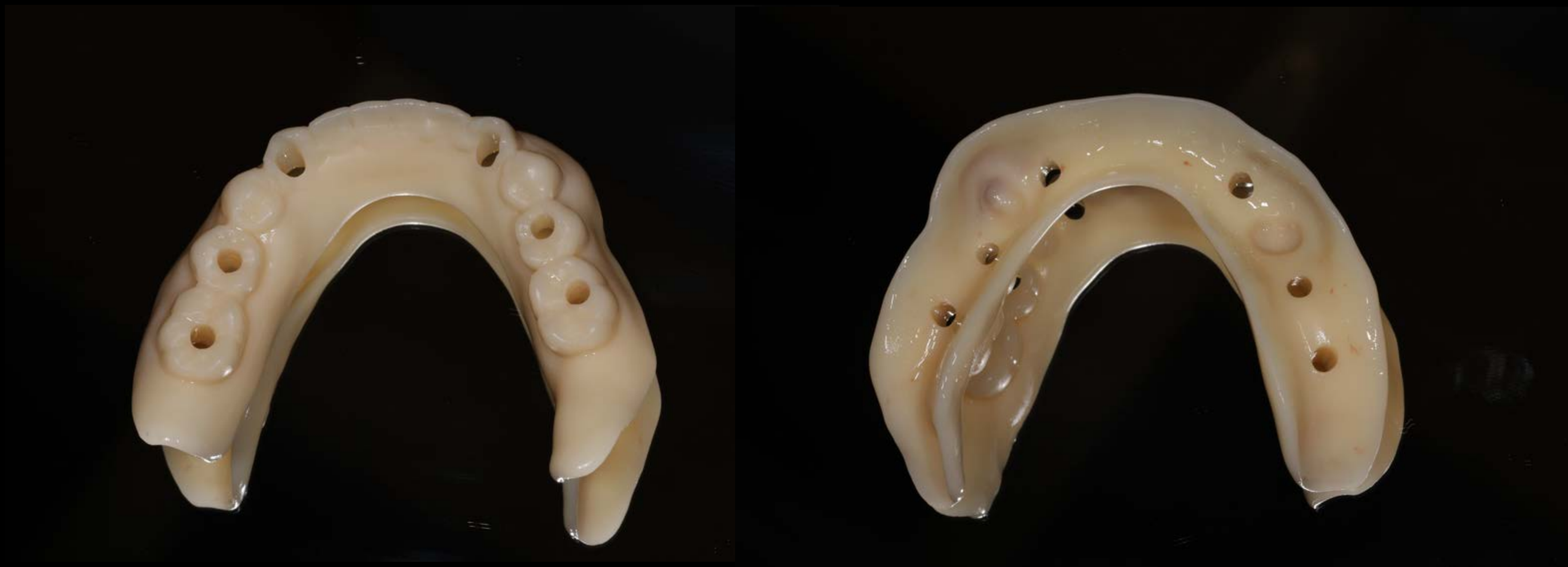Post-op (2025-07-22)



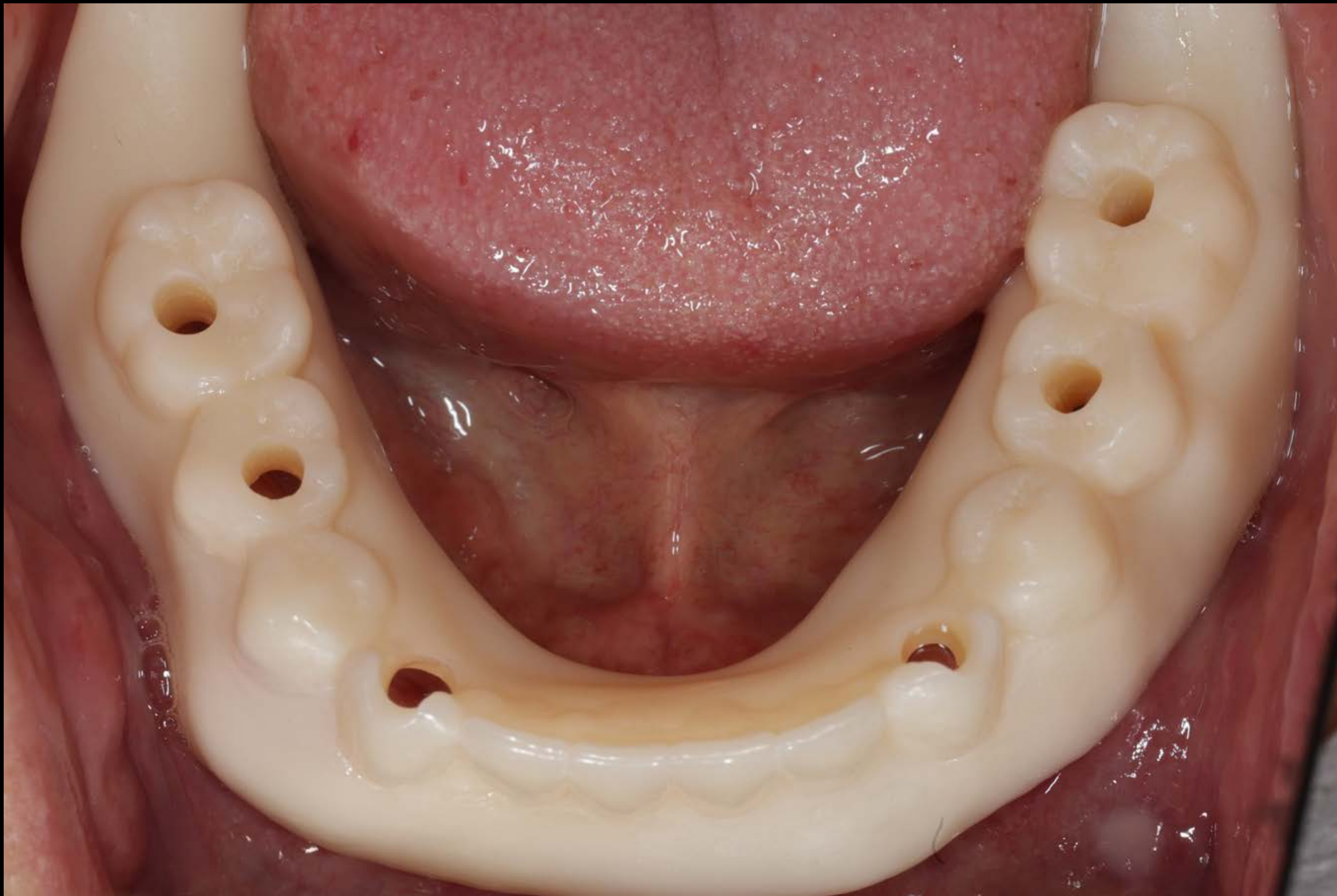
Denture



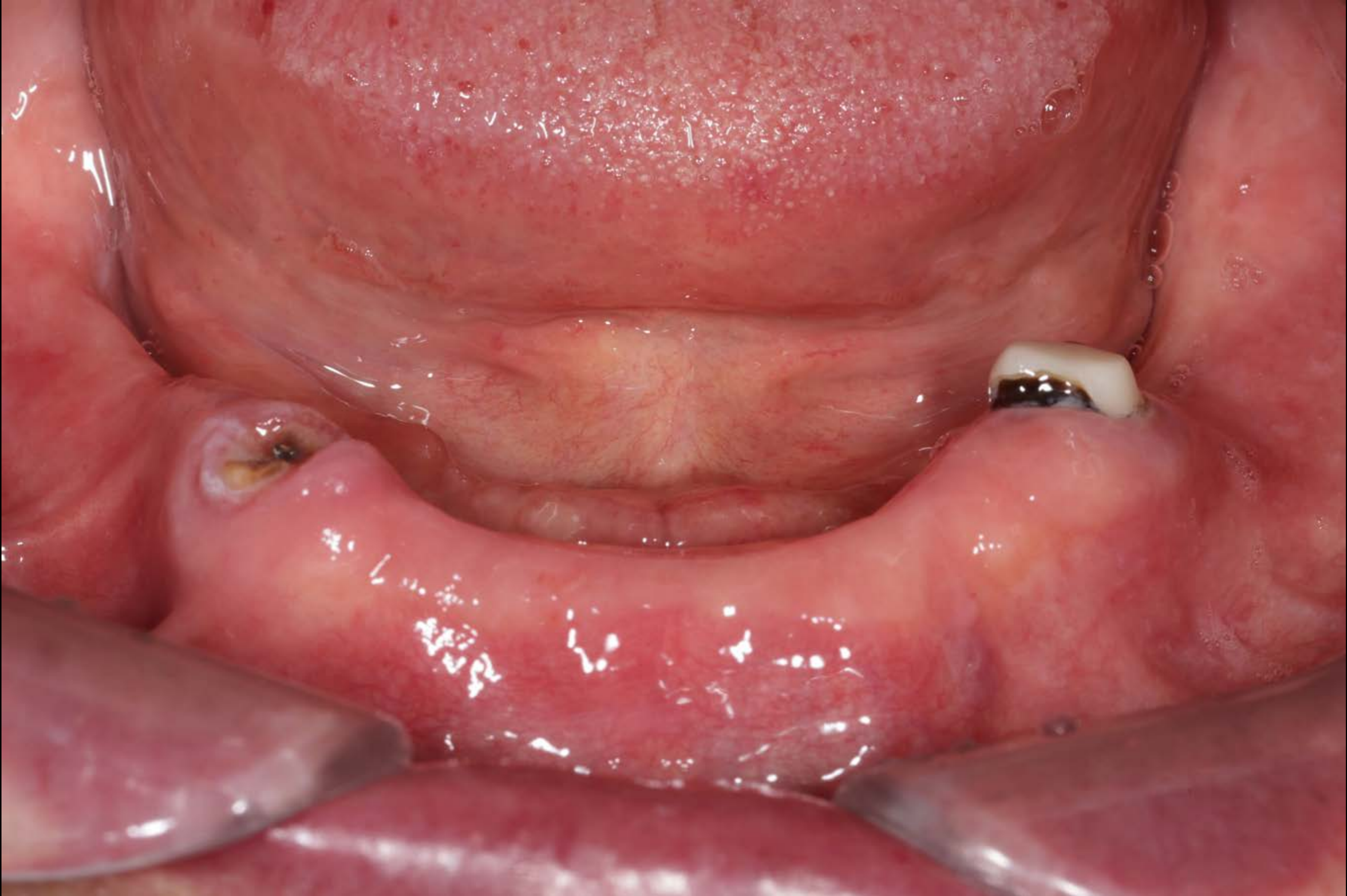Duplicated and 3D-printed Denture for use as a surgical guide



Duplicated and 3D-printed Denture for use as a surgical guide



Pre-op (2025-07-22)



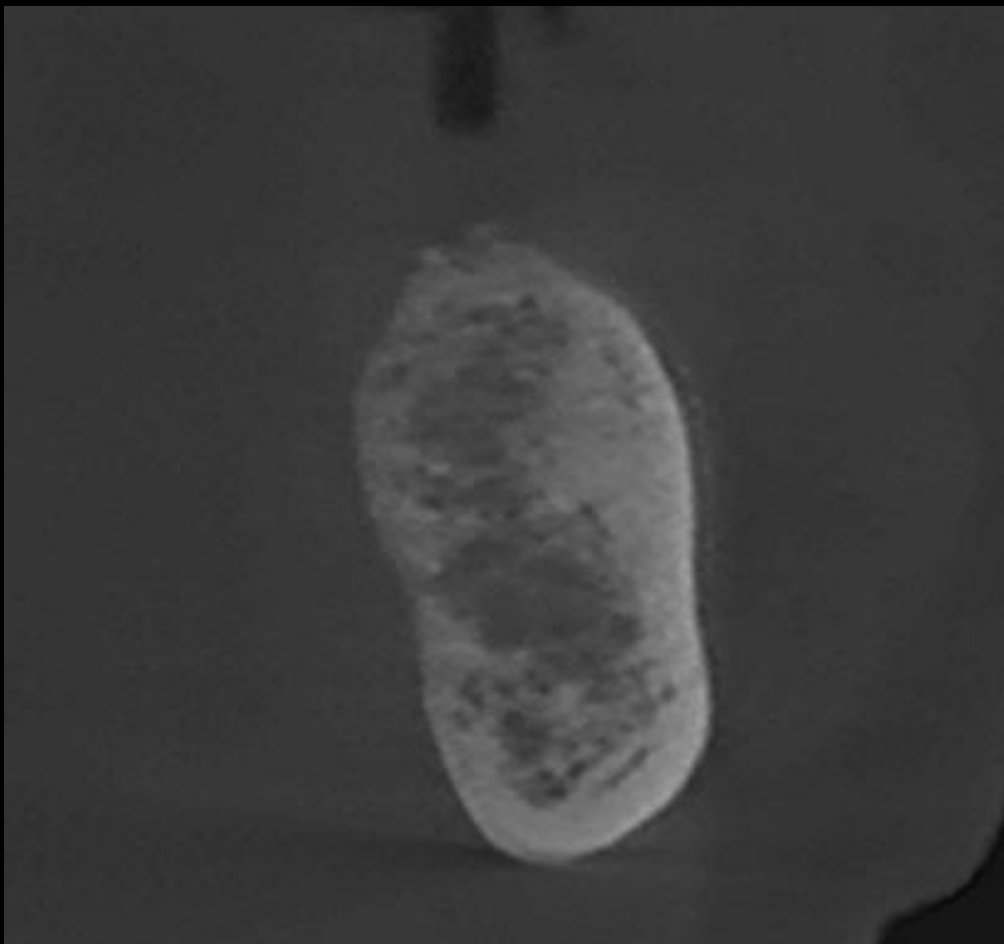An intraoperative photograph showing a surgical site in the mandible. Two dental implants are visible, secured with screws. A large, white, rectangular bone graft or implant component is being positioned between the two implant sites. Surgical forceps are used to hold the graft in place. The surrounding tissue is red and bloody, indicating an active surgical site.

Rehabilitation of Severely atrophic Edentulous mandible

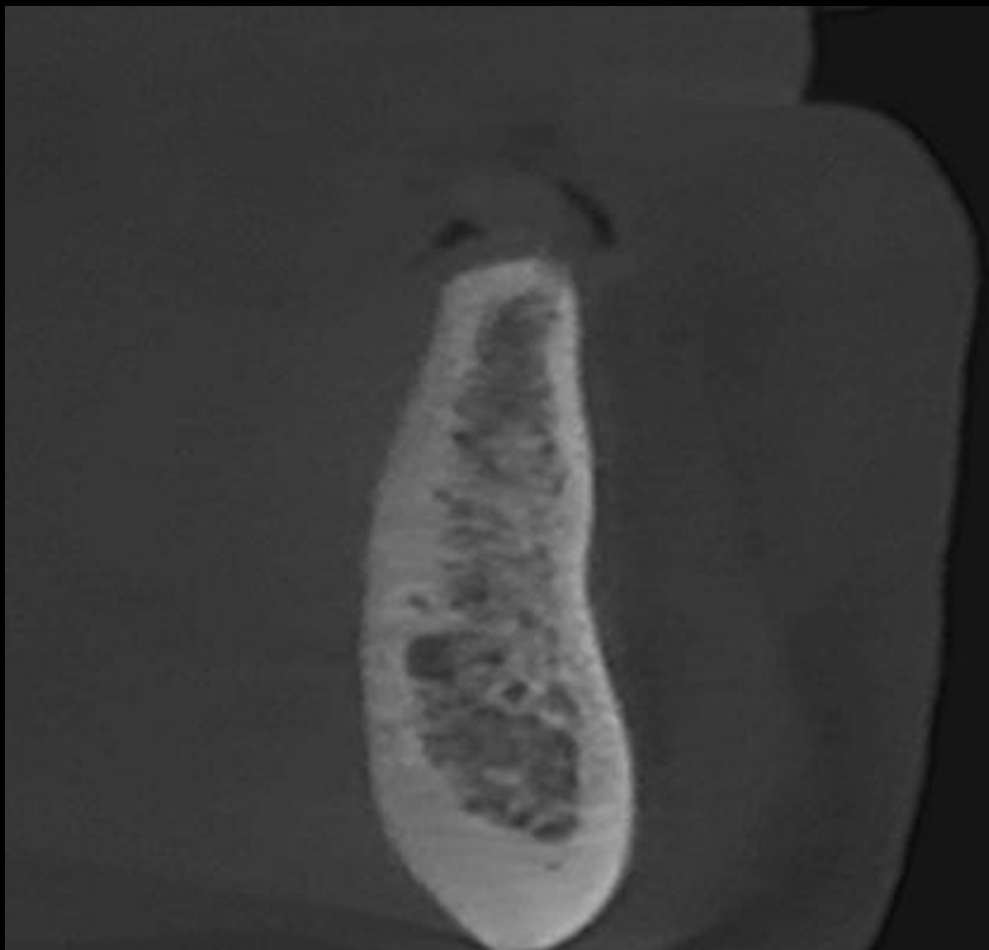
Dentium dental Clinic
Dr. SM Chung

**** 292p Surgery VOD 8**

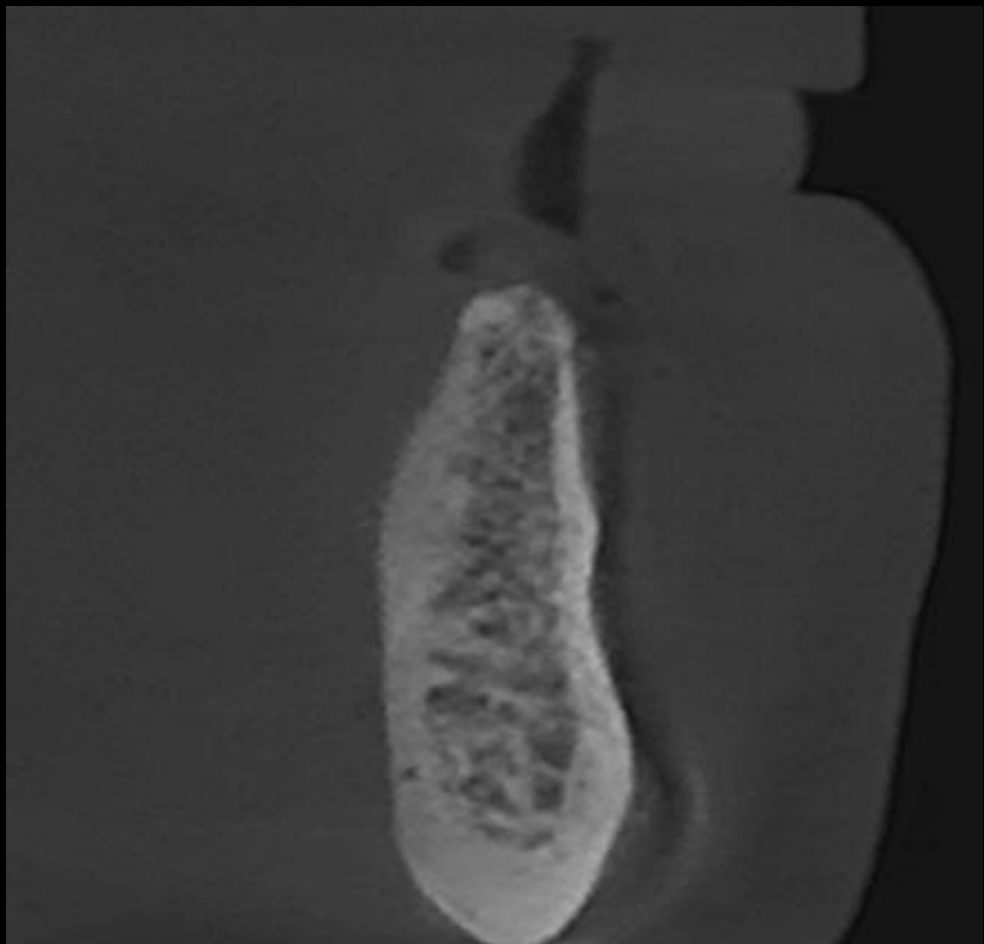
Pre-op CT (2025-07-22)



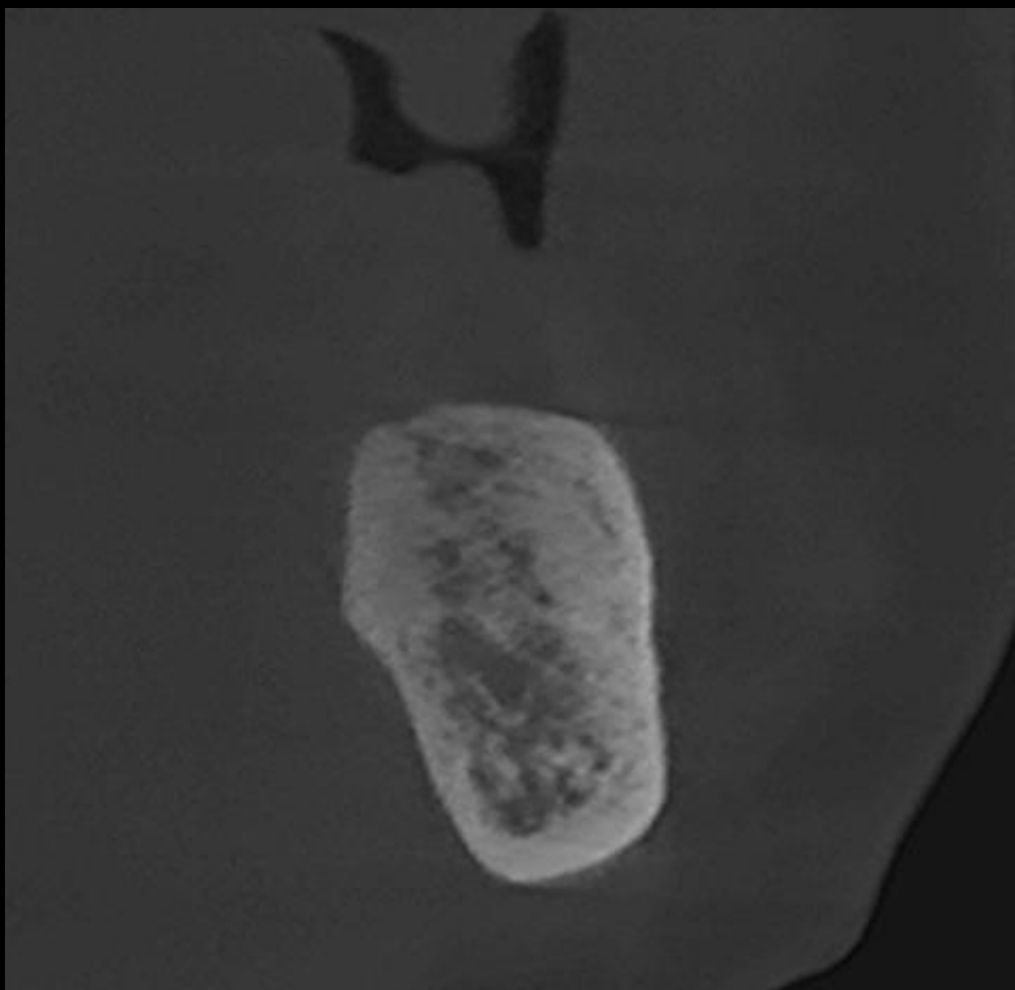
#46



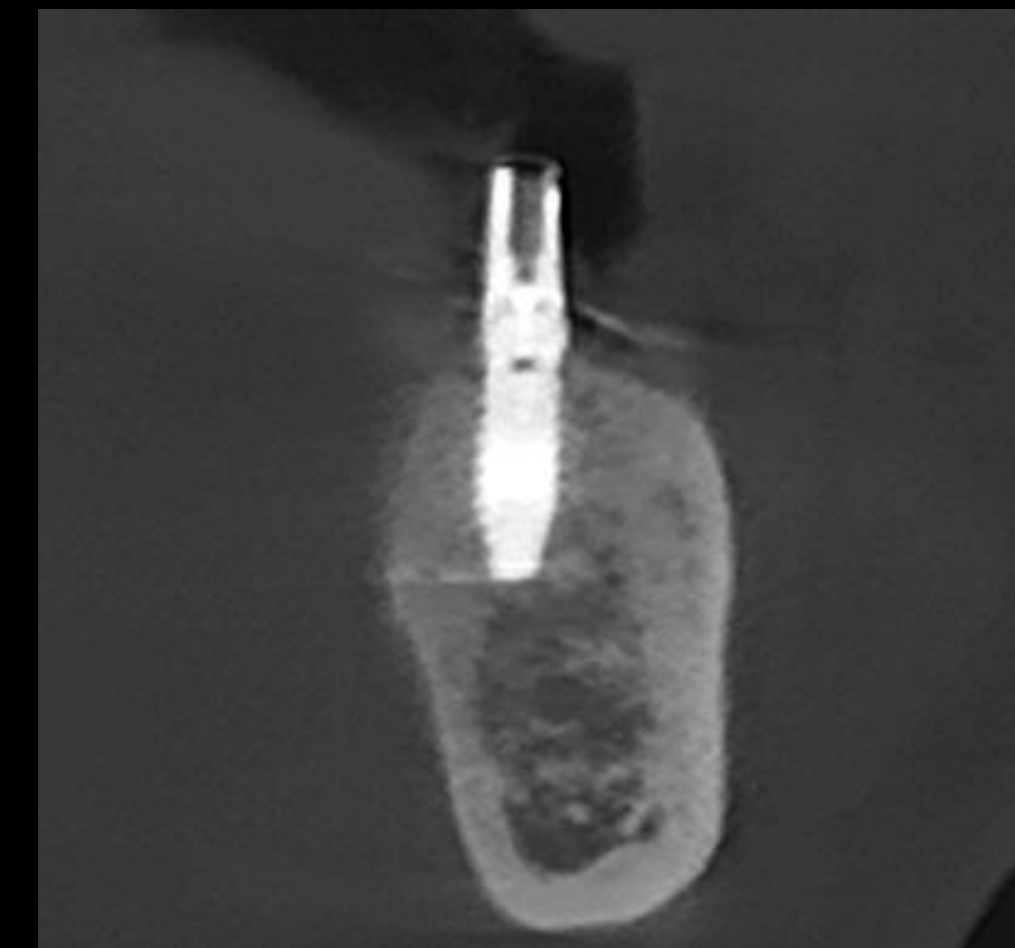
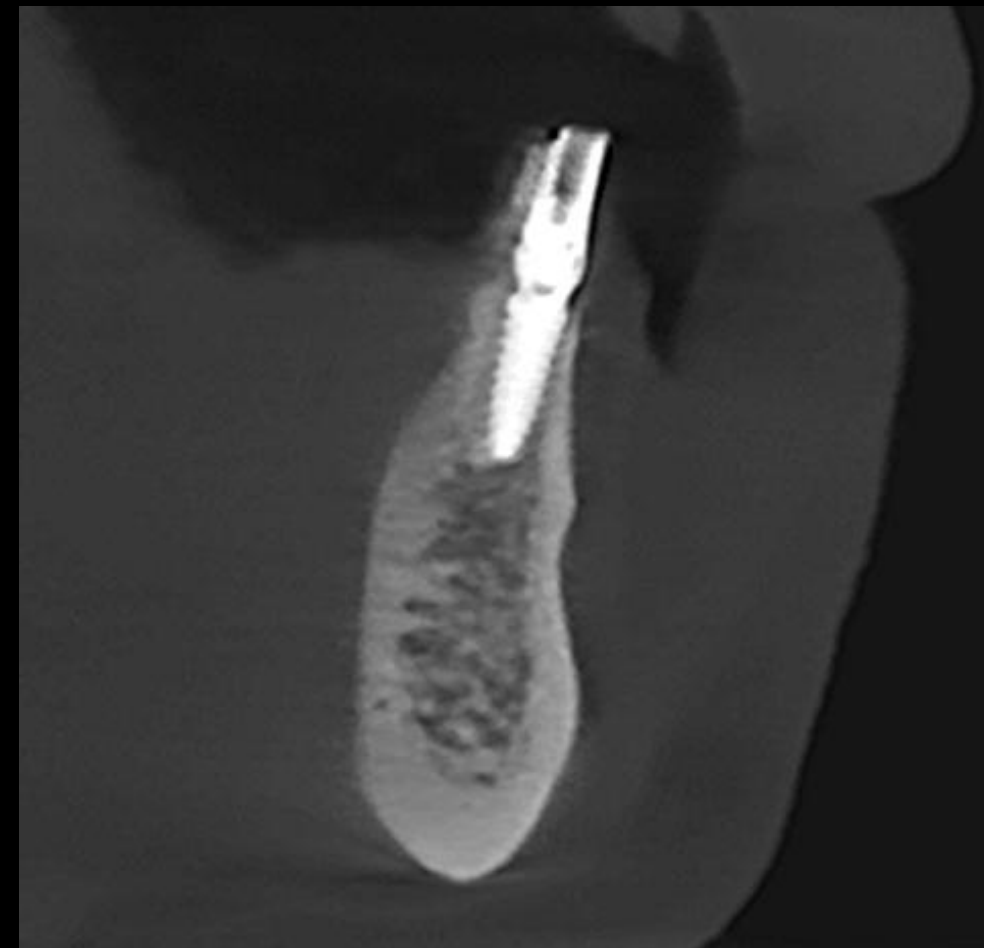
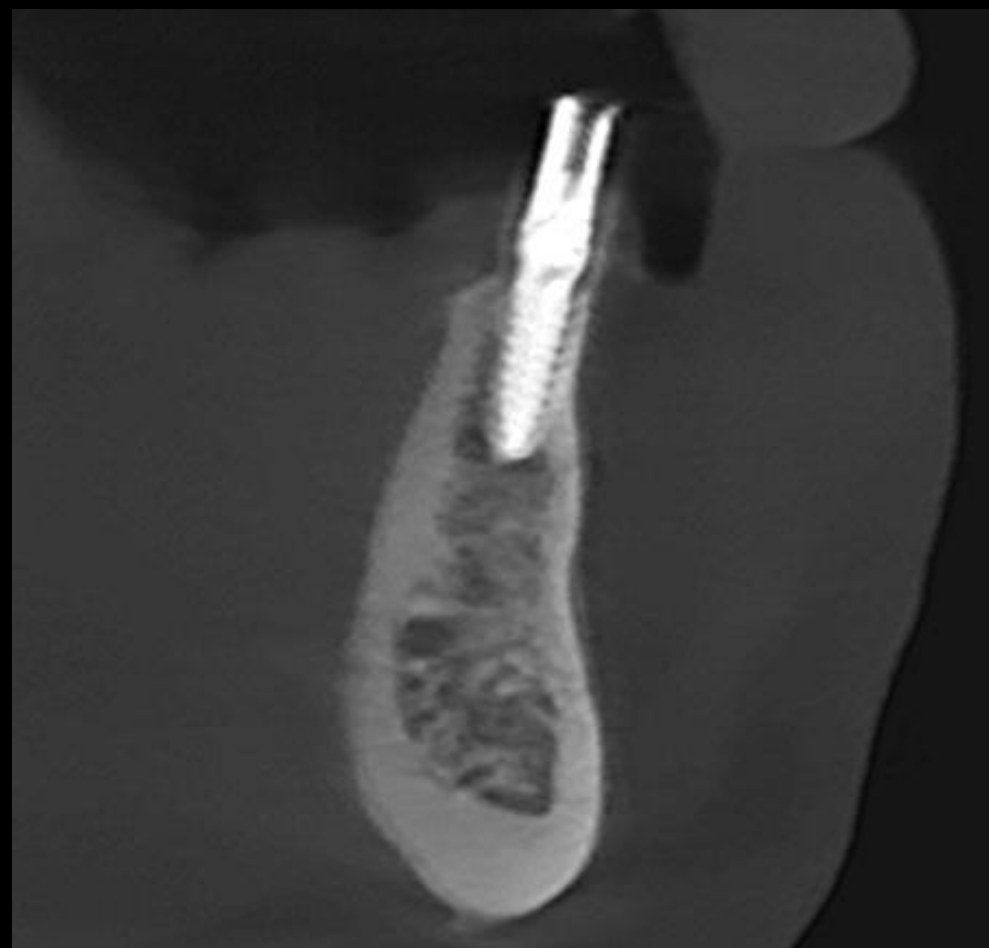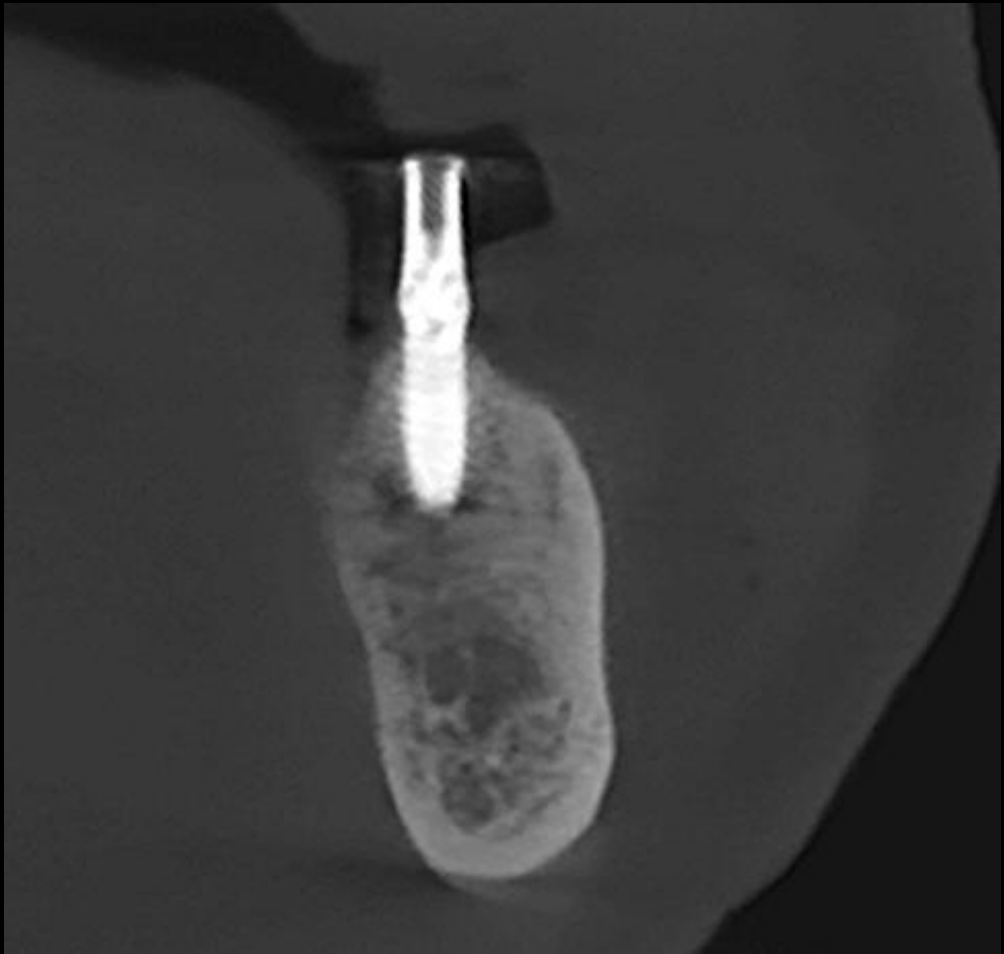#43



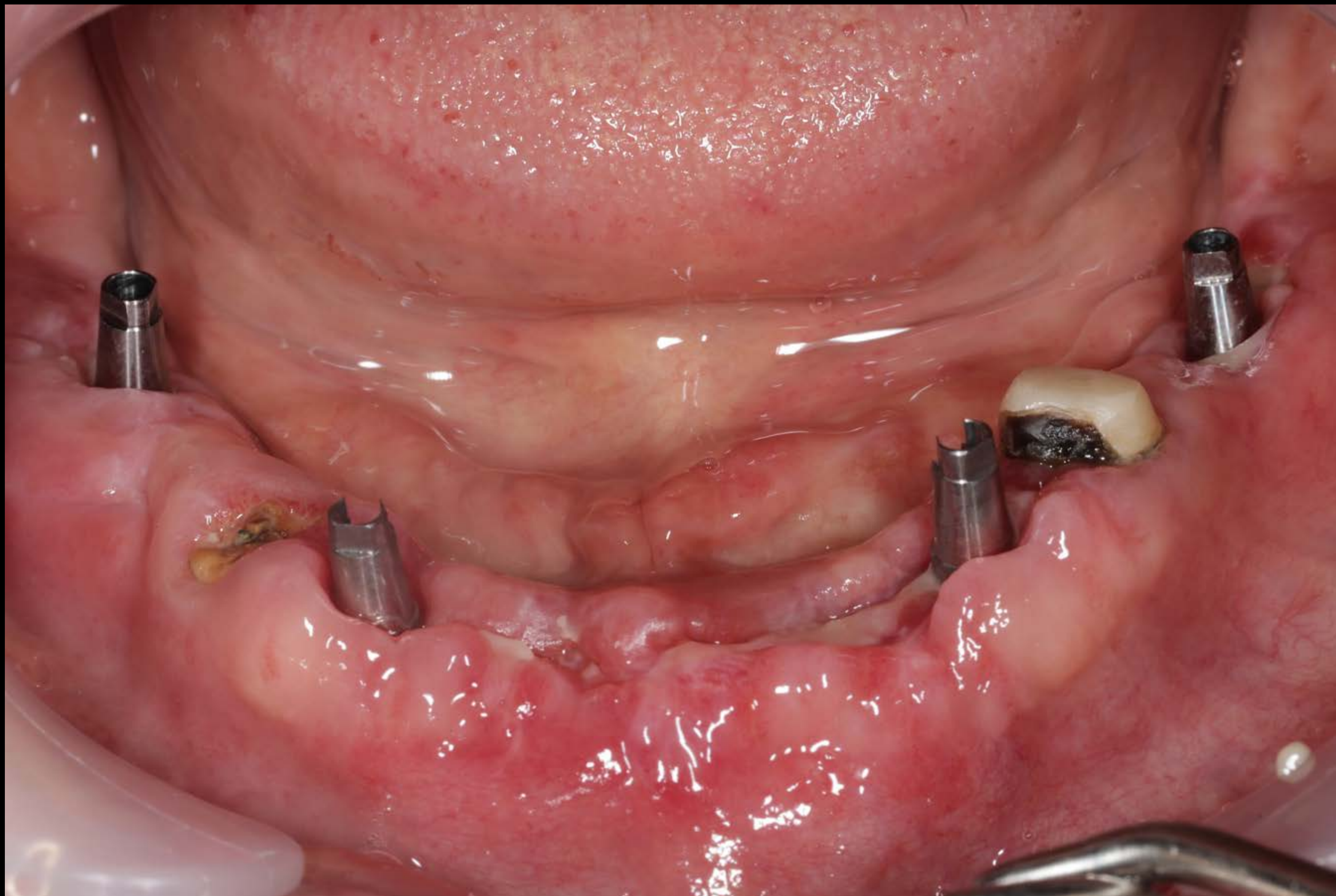#33



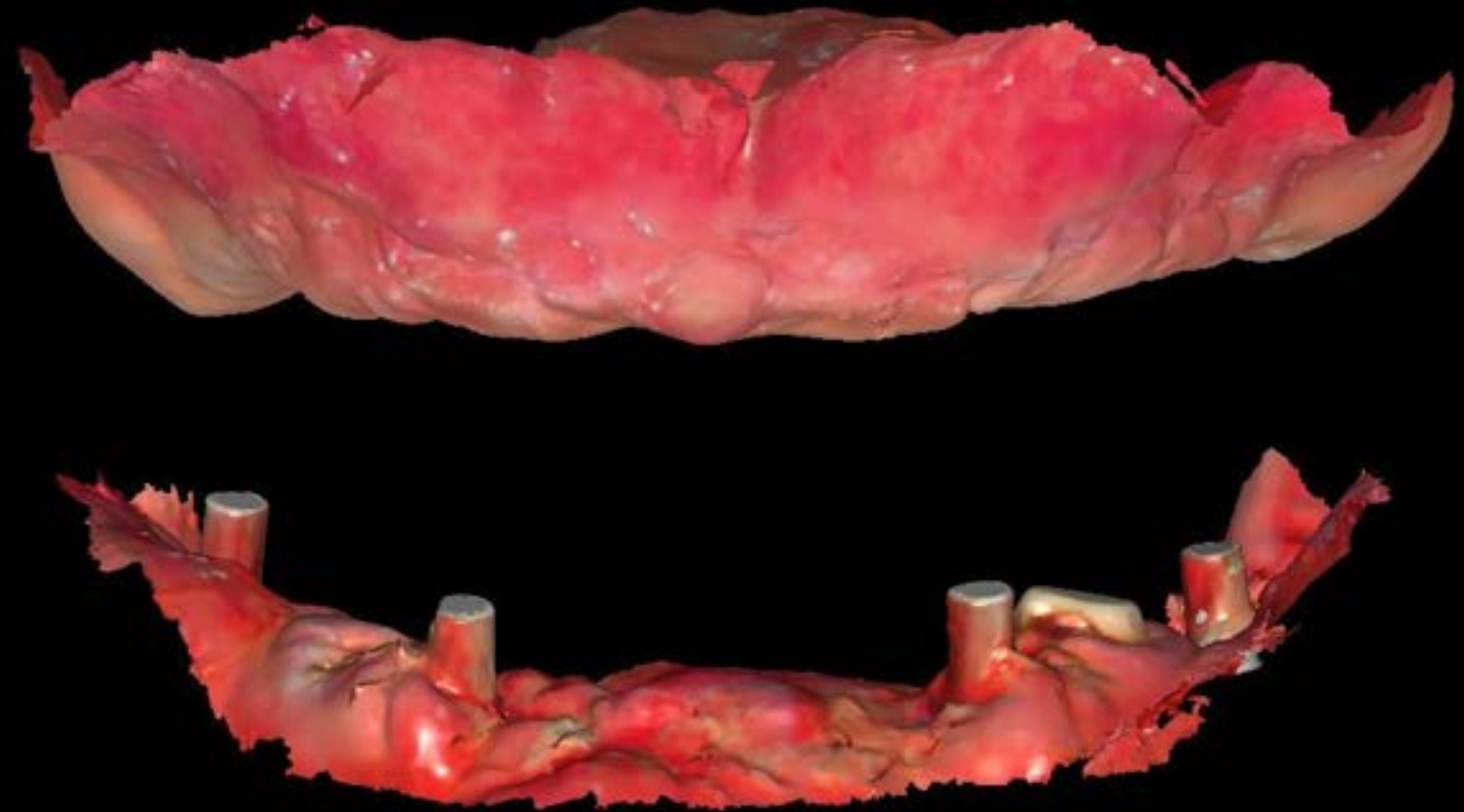
#36



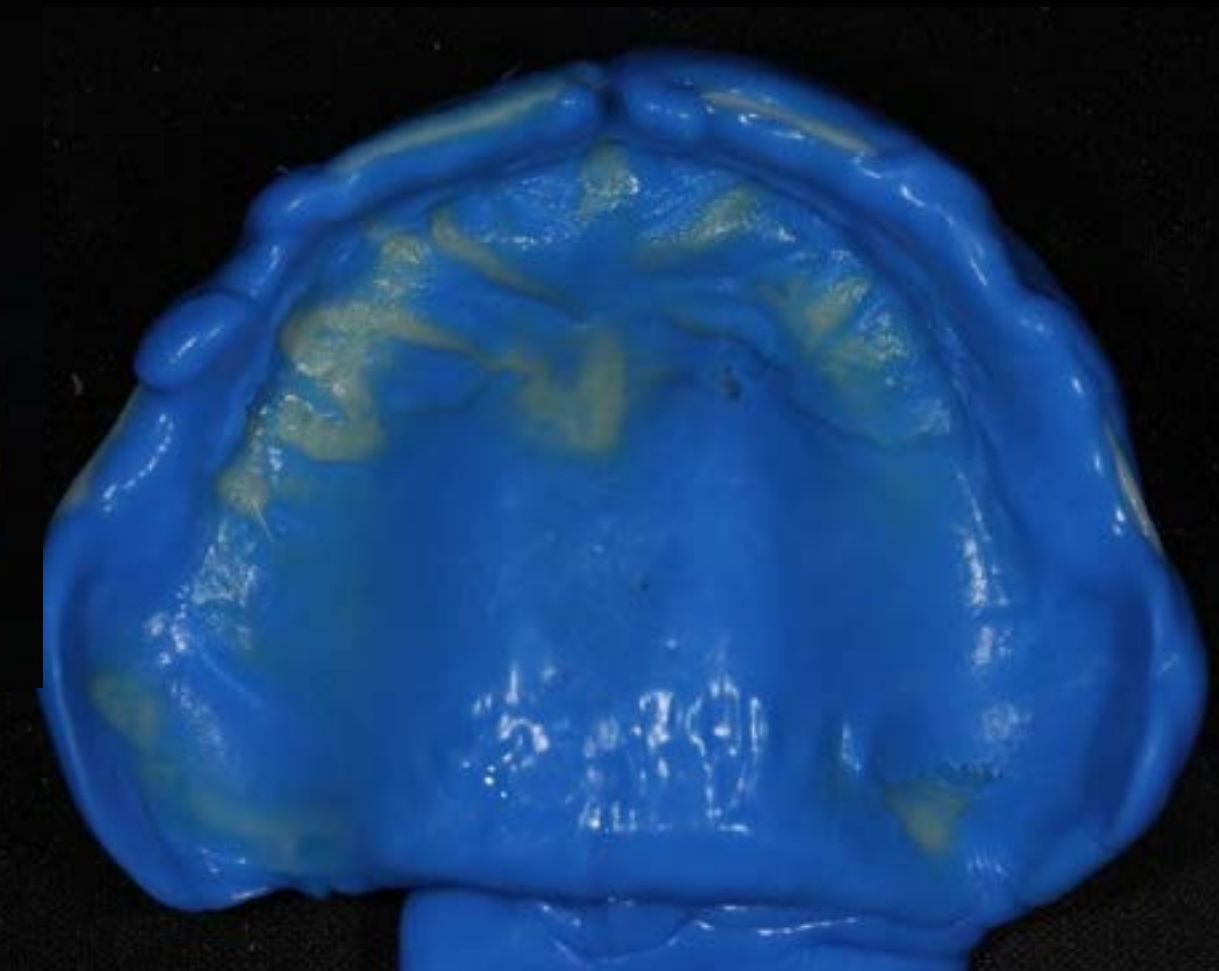
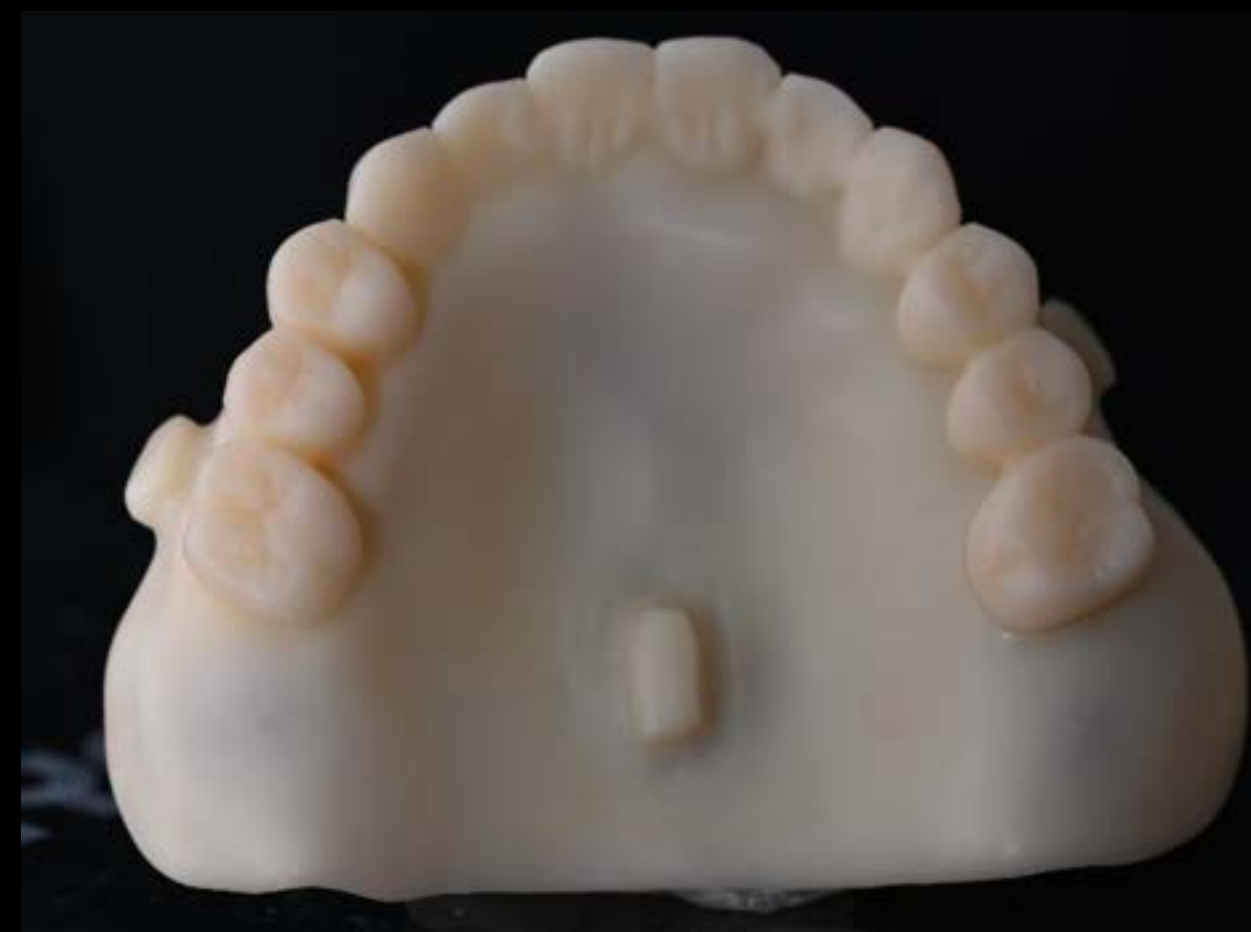Healing : 2 weeks (2025-08-06)



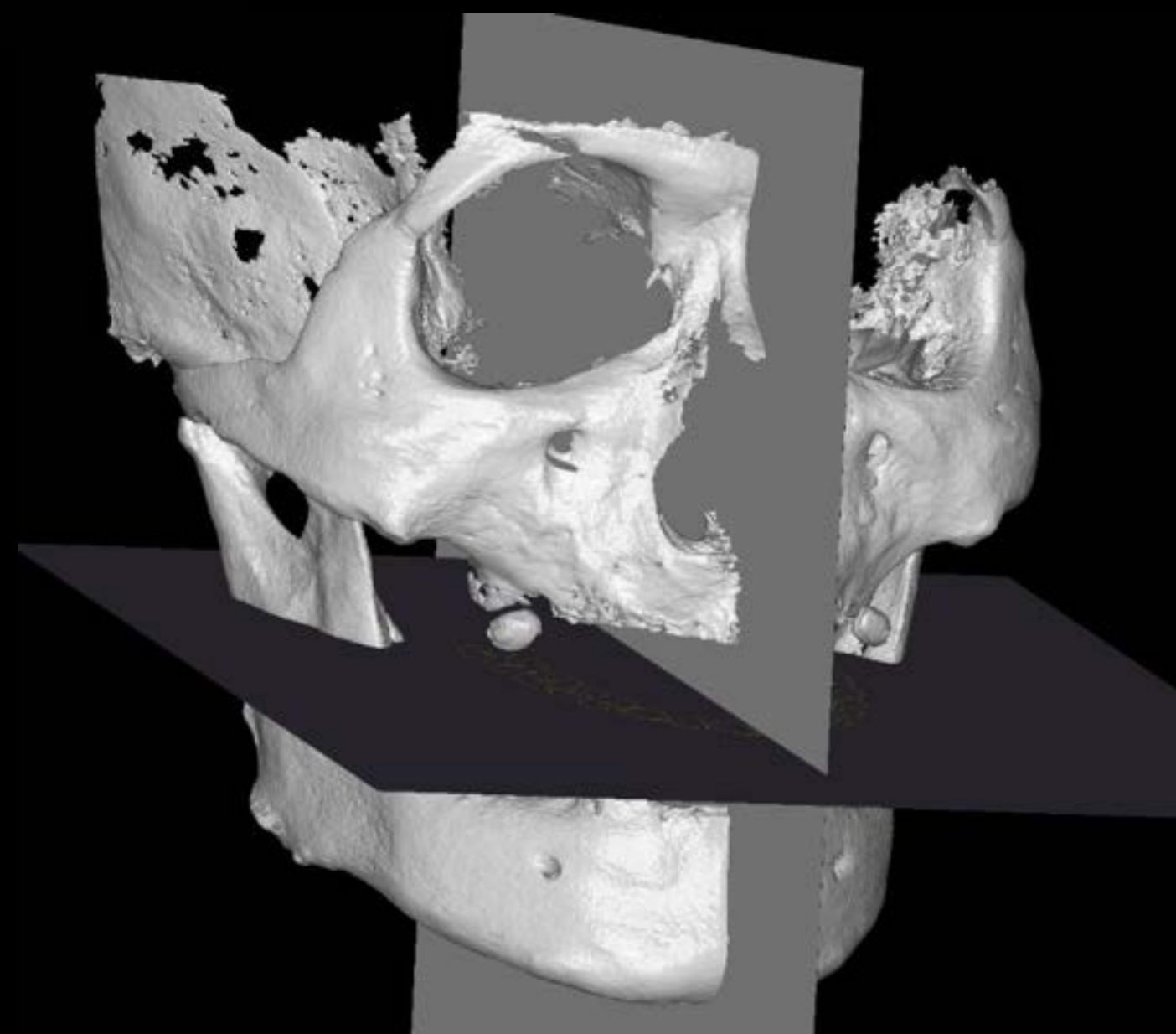
Provisonal restoraiton



Intro oral Scan



Denture Impression & zirconia Marker



CT data
(AI Occlusal Plane)

CT data (AI Occlusal Plane)

Patient Information

김형철
M
ID 12124
Age 77
Exam.date 20250723

Virtual Ceph

Select Mark
Create Ceph
Create YTI

Occlusal Plane(OP)

☒ ☐ AUTO

Render Type

Hard Type

Viewport

☒ ☐ ☐ ☐

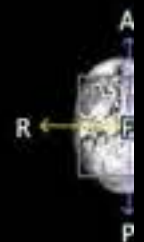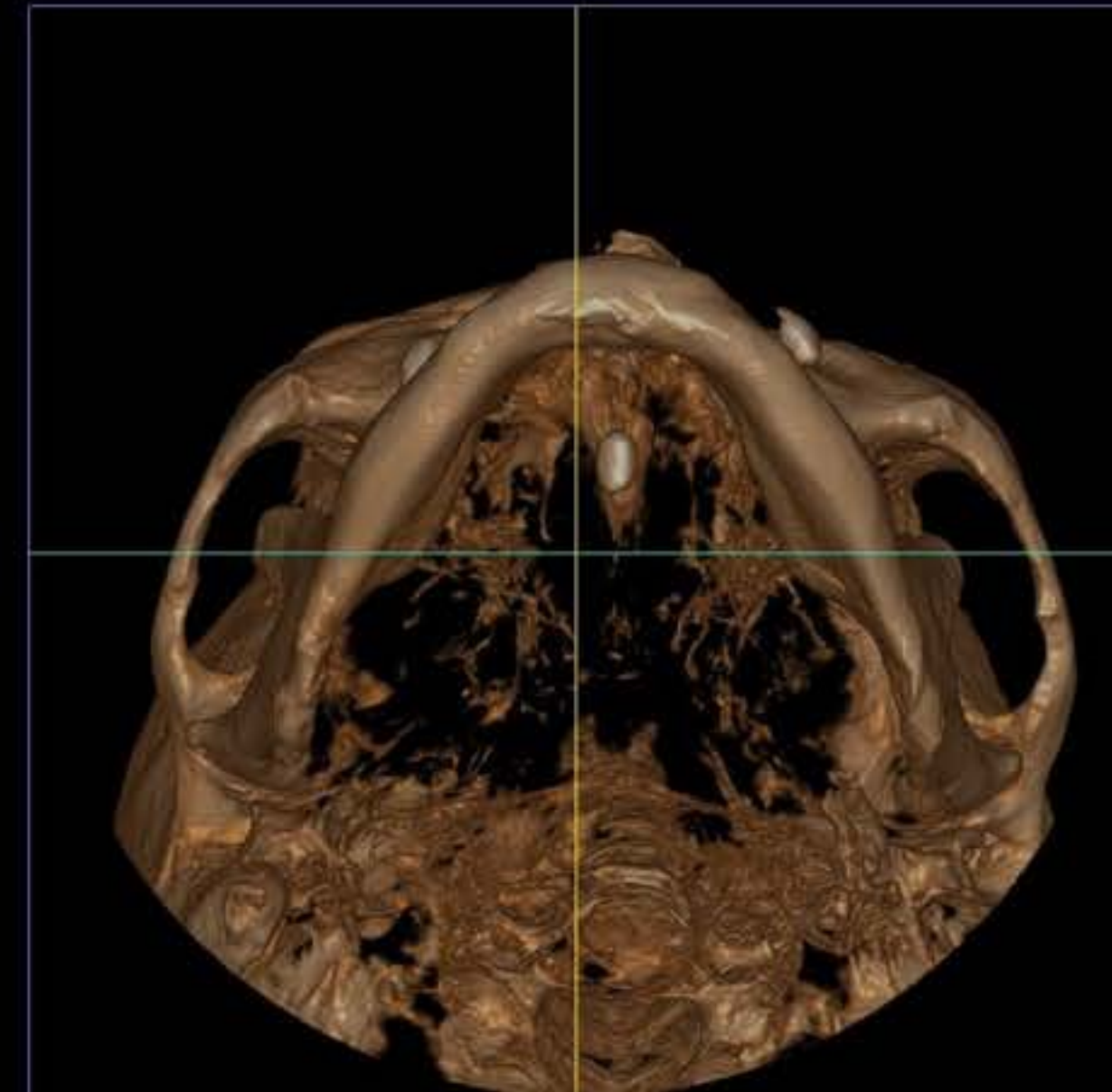
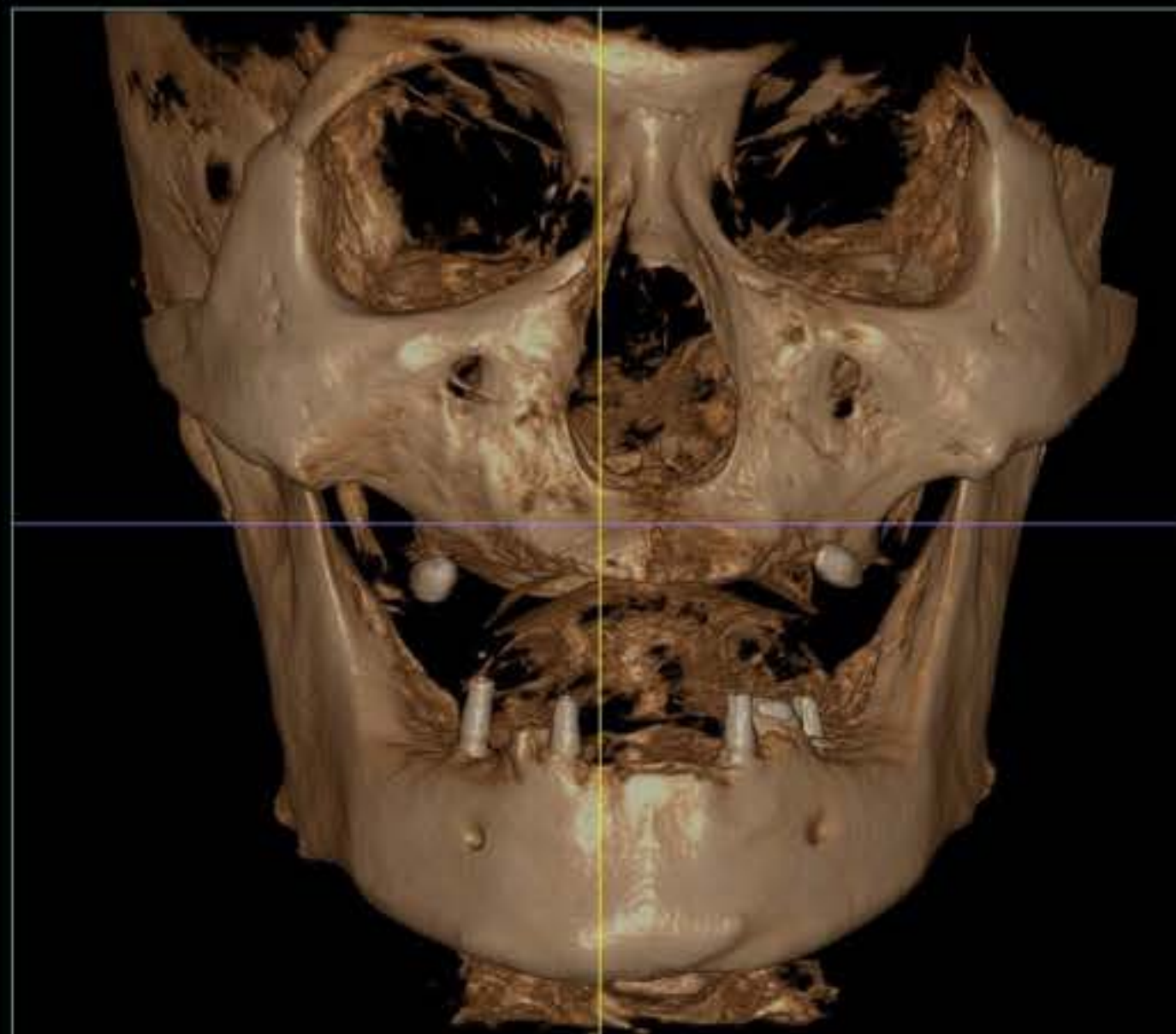
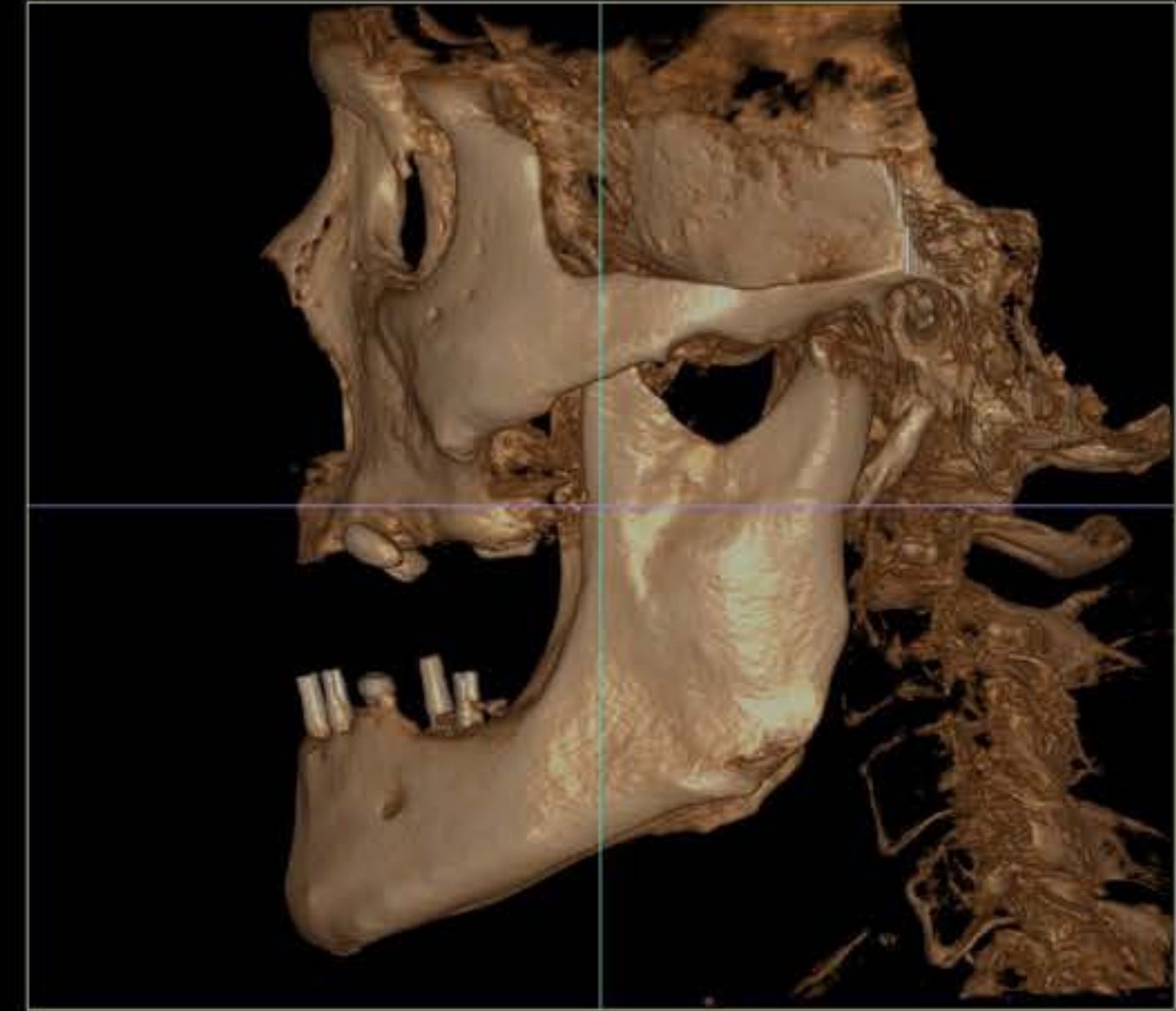
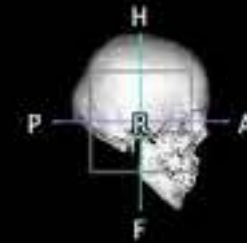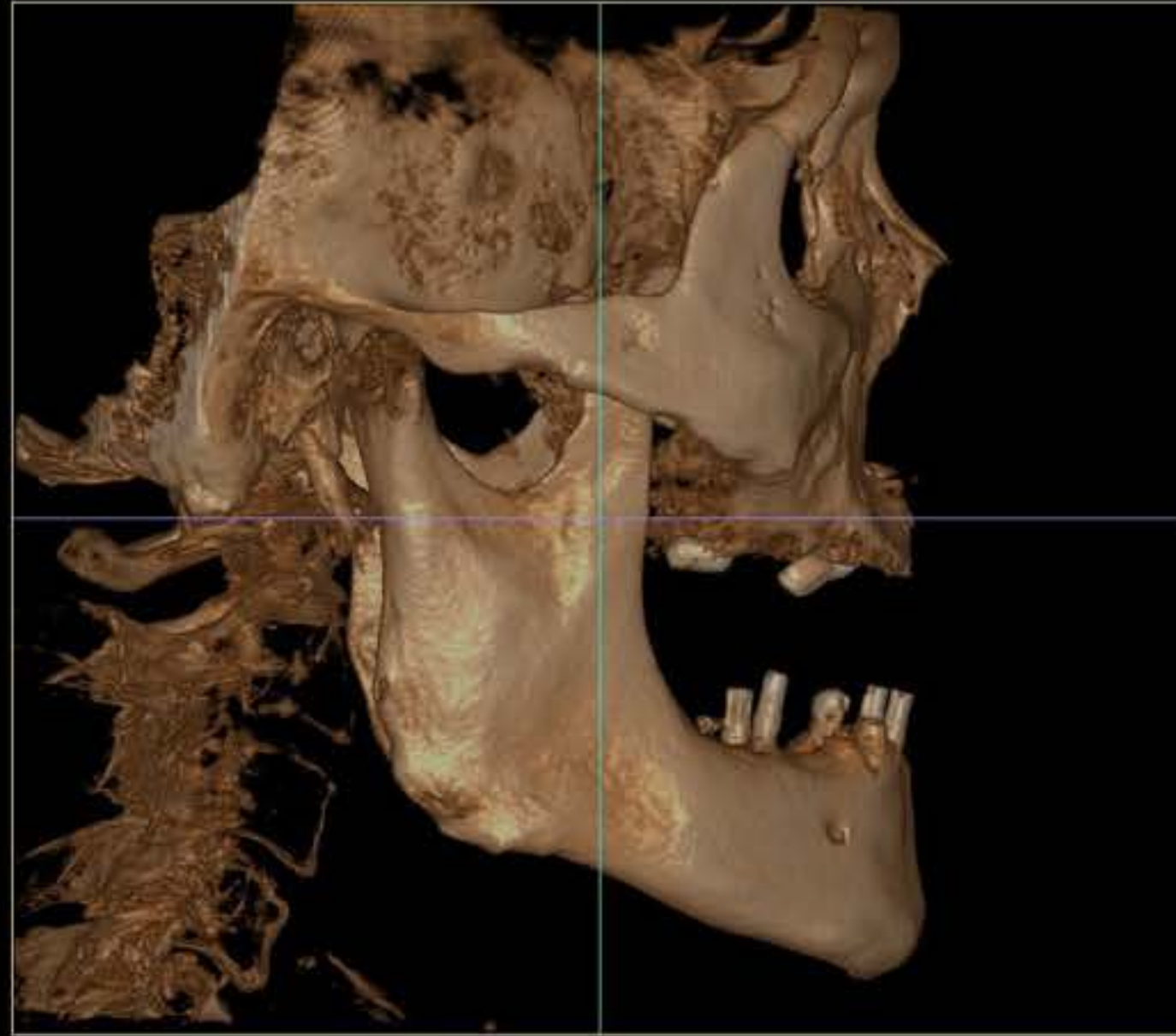
HU 2200
Q 70
Q Default

Capture Group

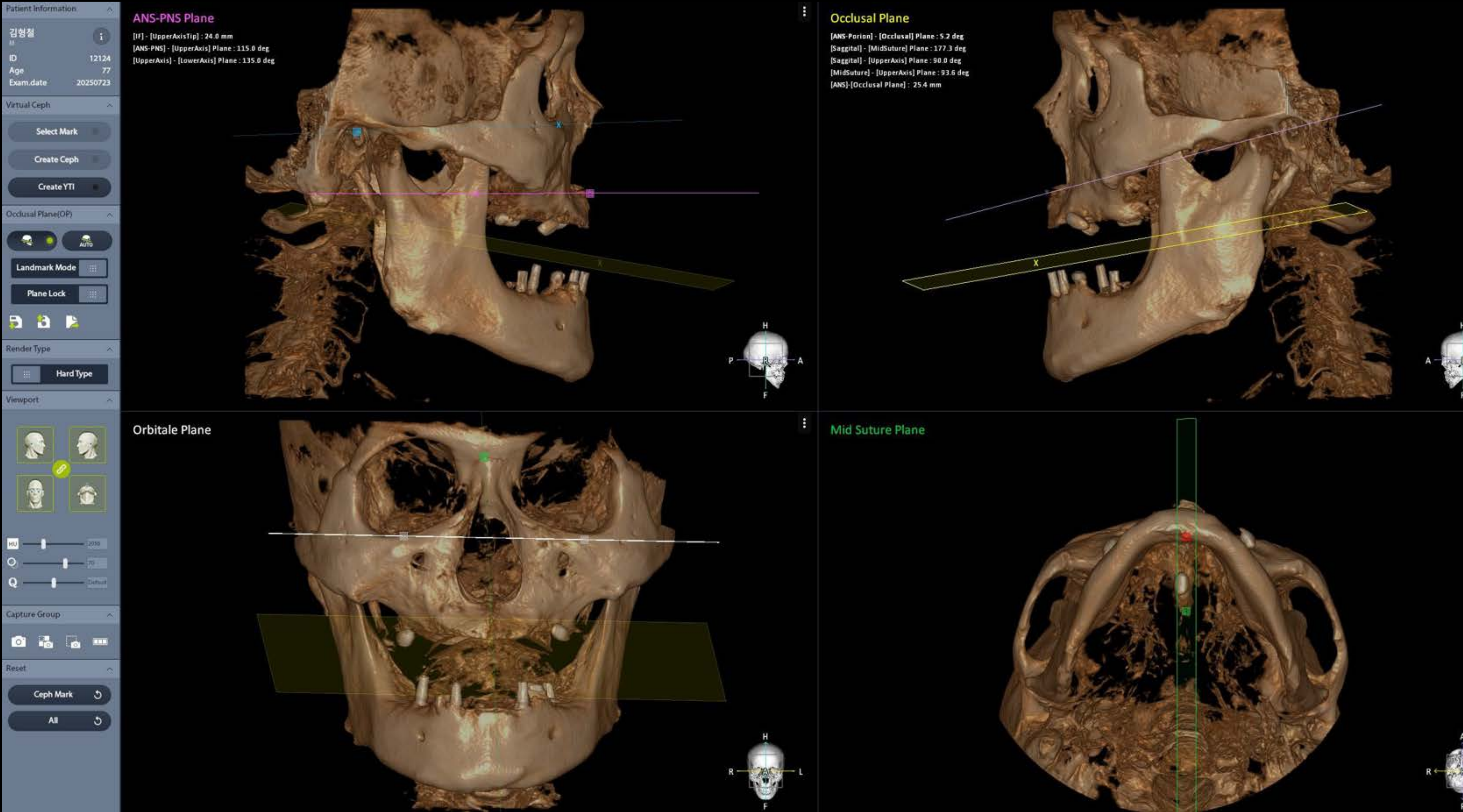
☐ ☐ ☐ ☐

Reset

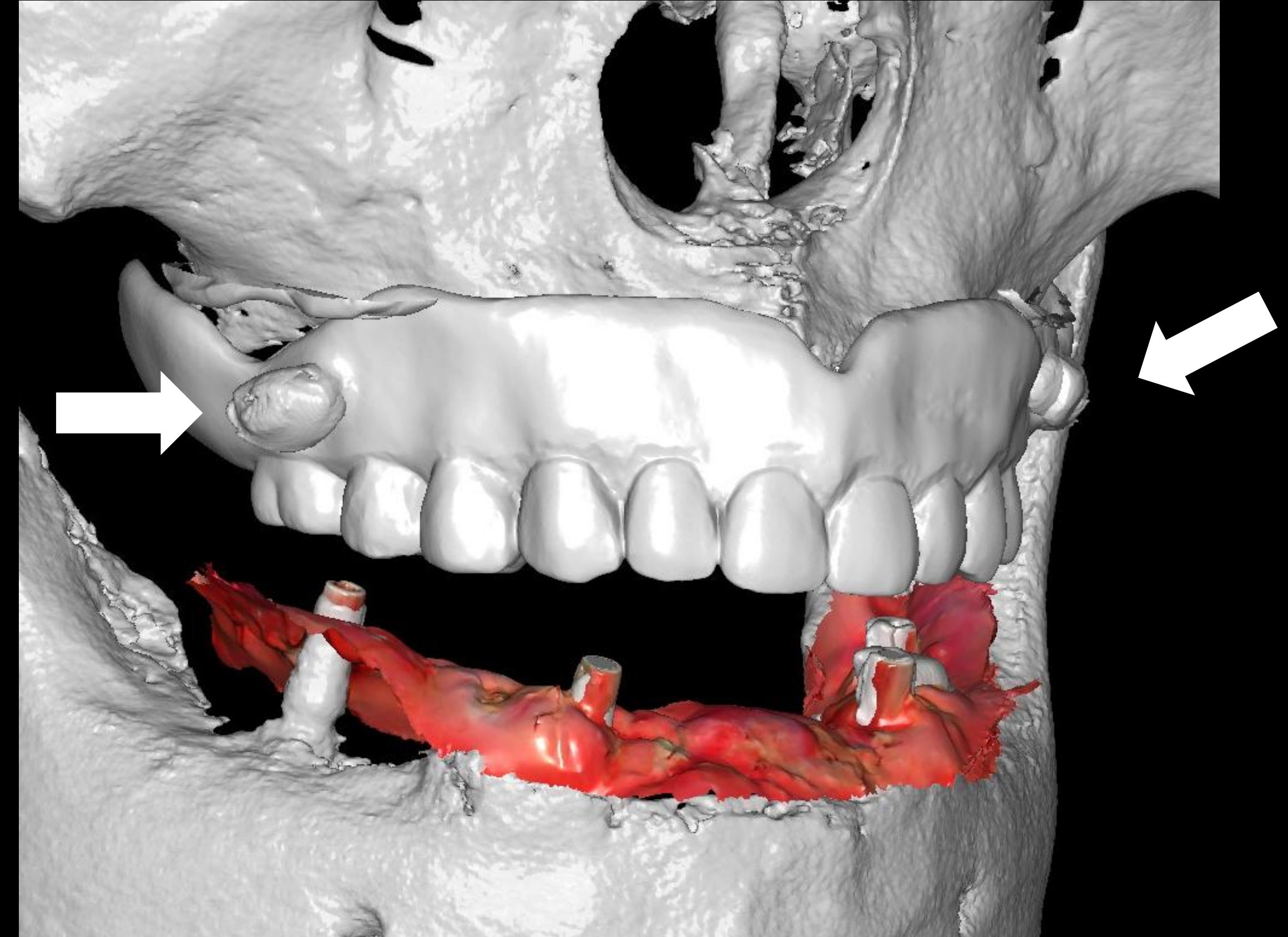
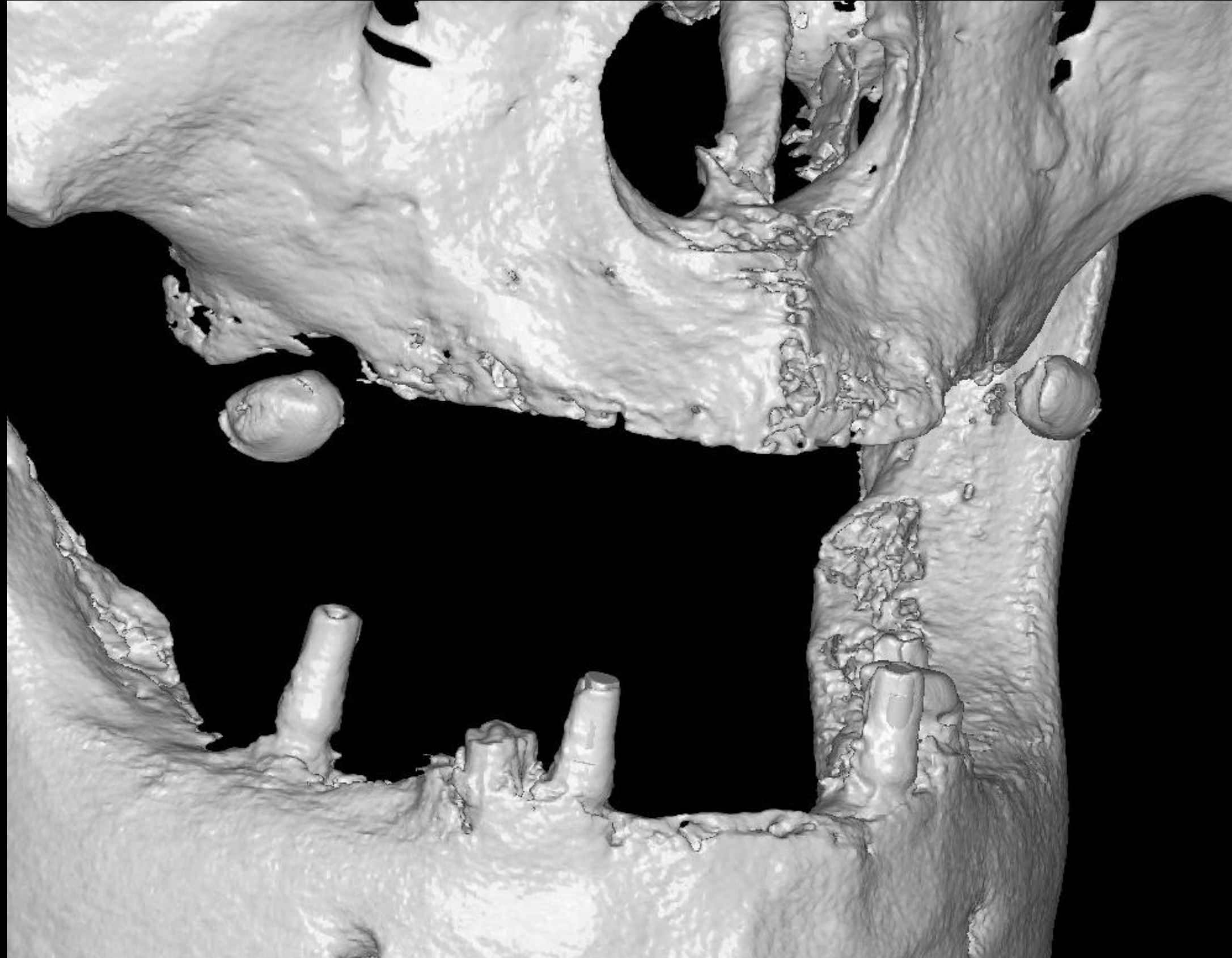
Ceph Mark
All



CT data (AI Occlusal Plane)


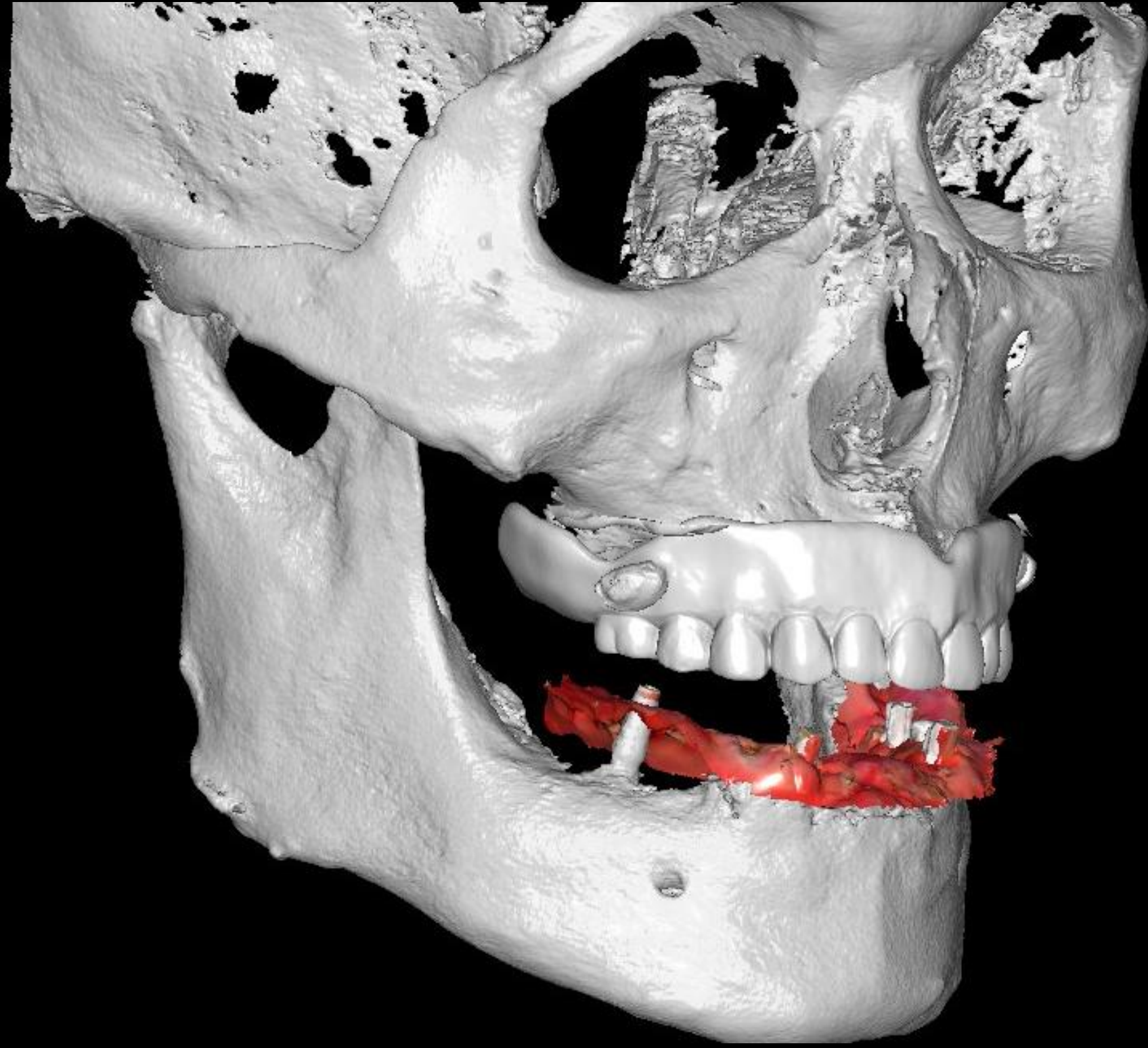


CT data Stitching




CT Check Bite with Zirconia Marker

CAD design

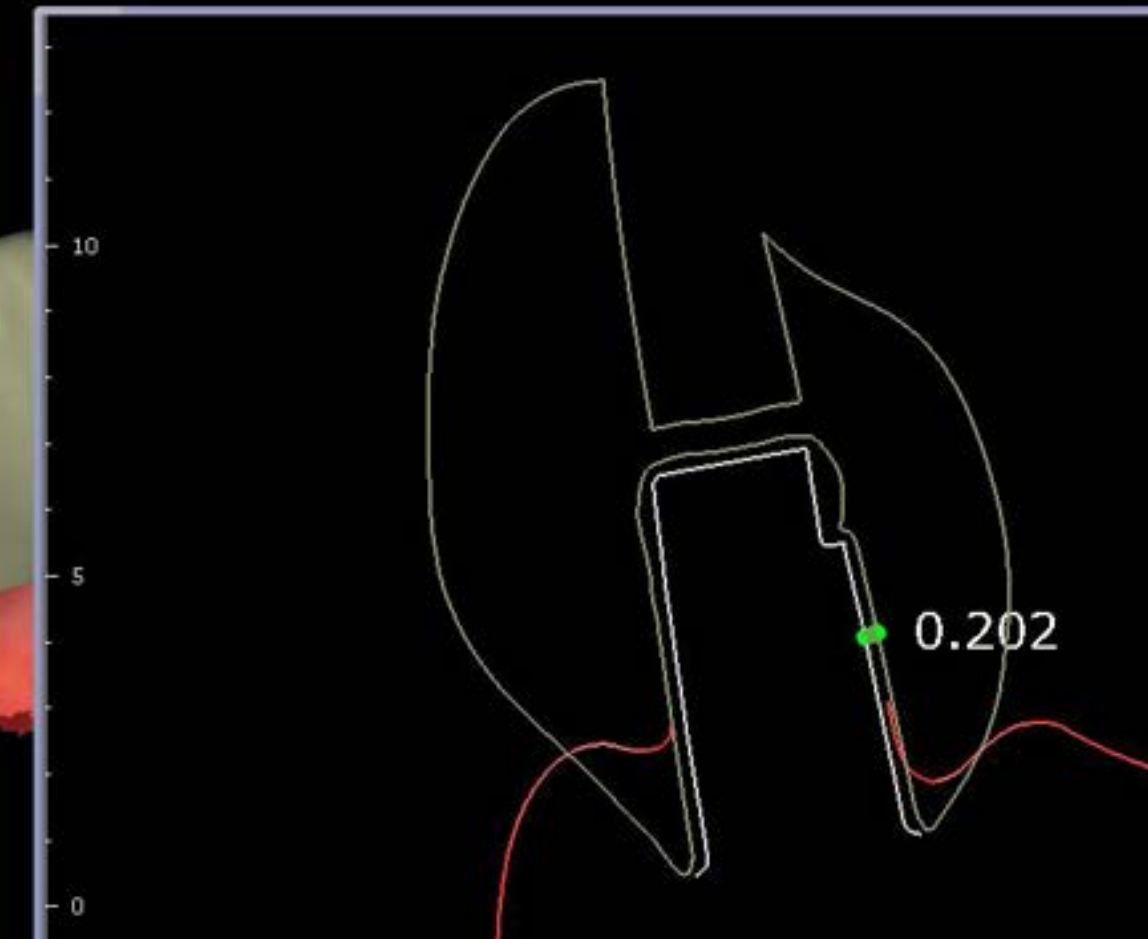
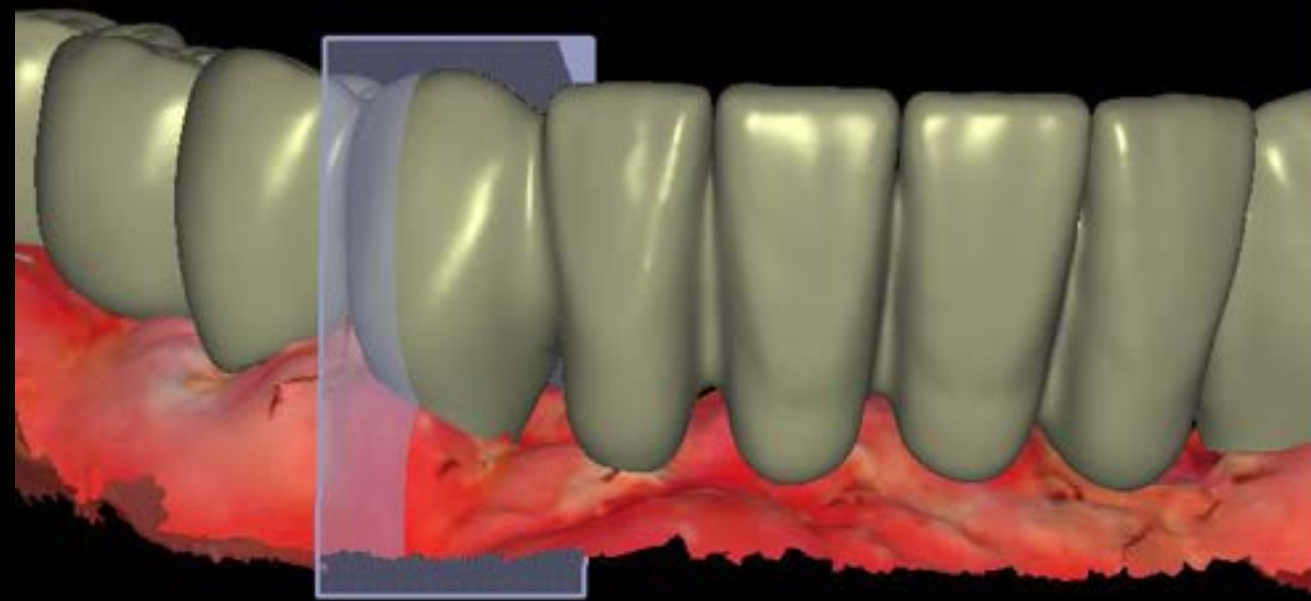


CT Check Bite with Zirconia Marker

CAD design

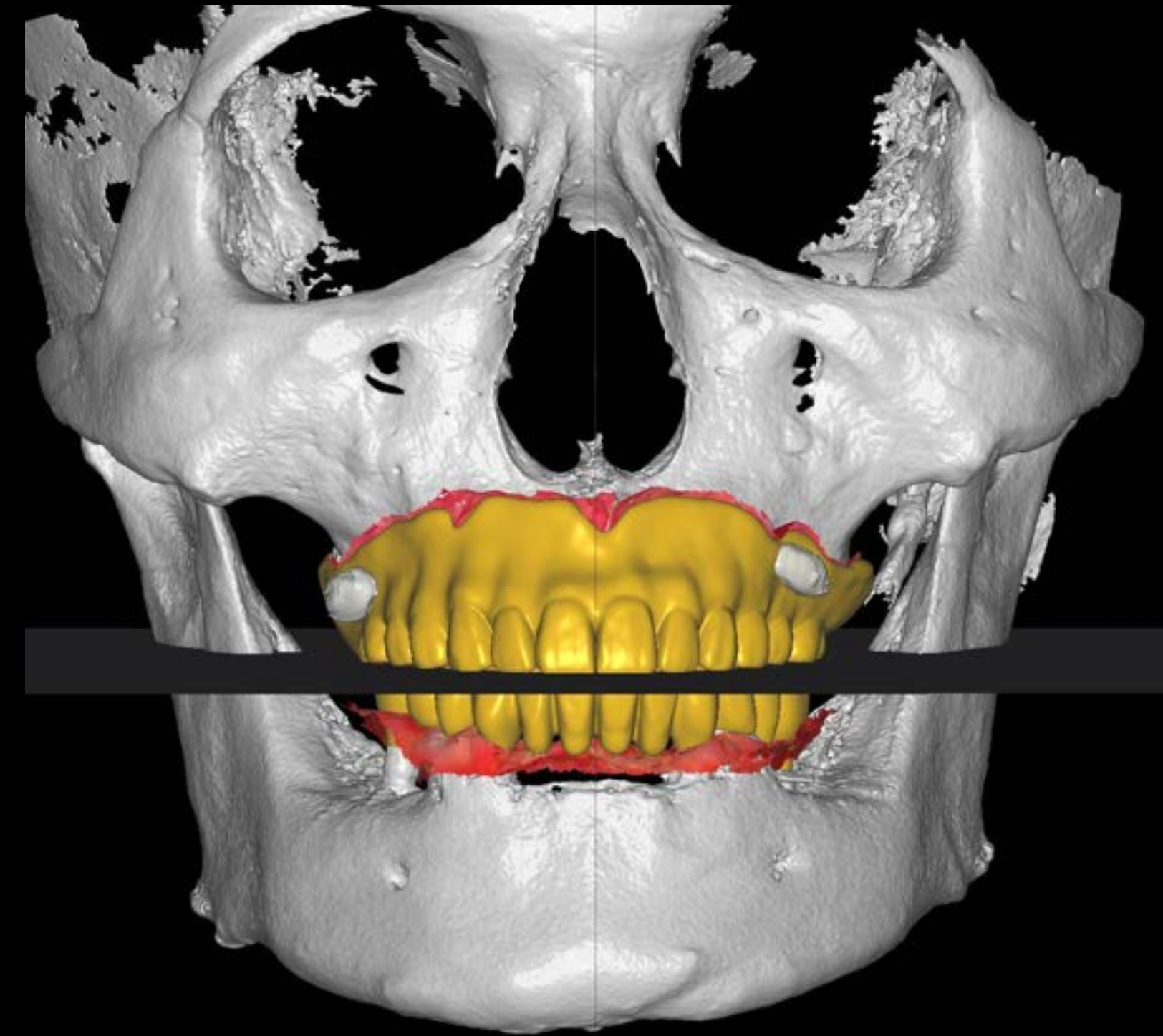
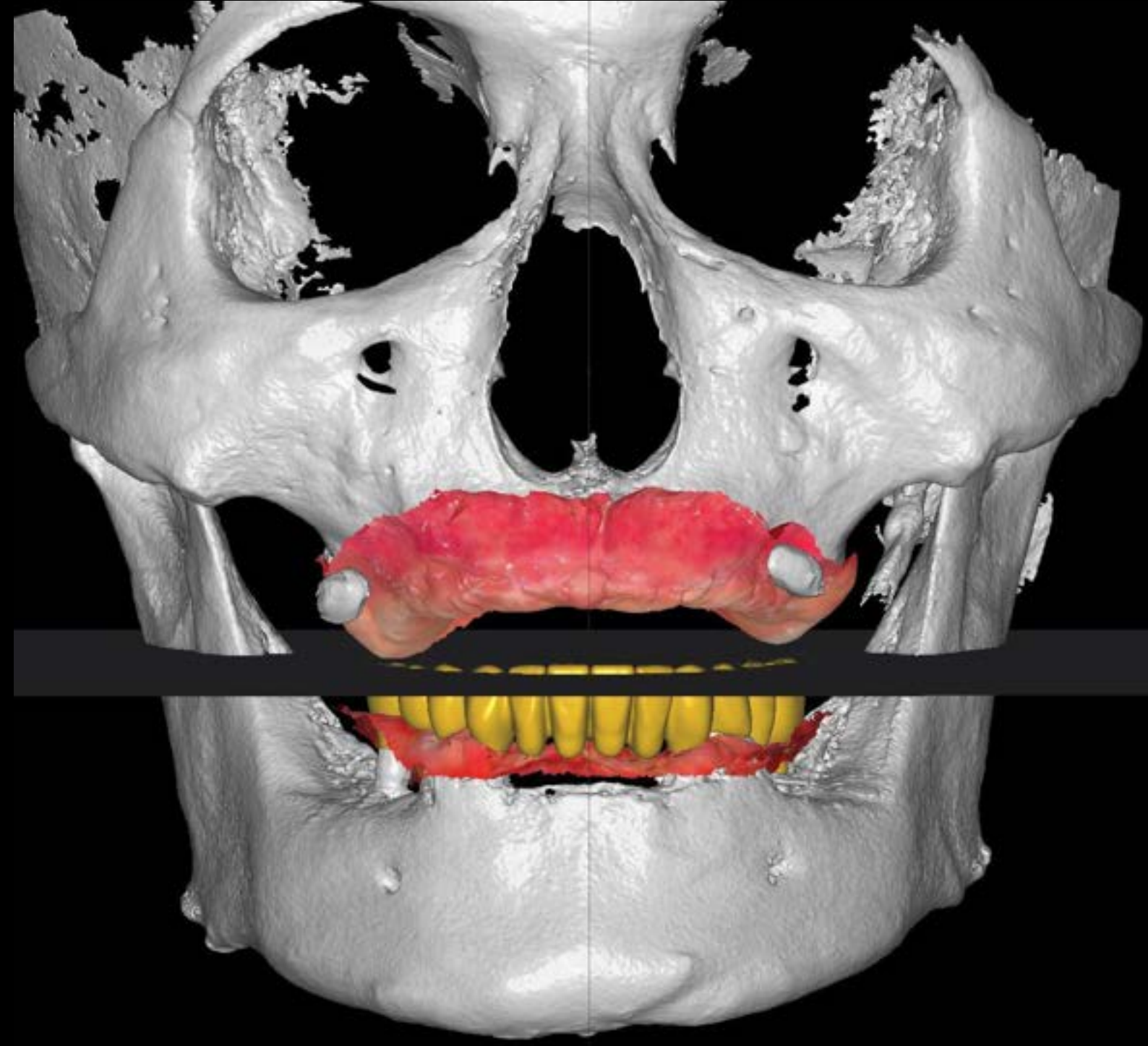
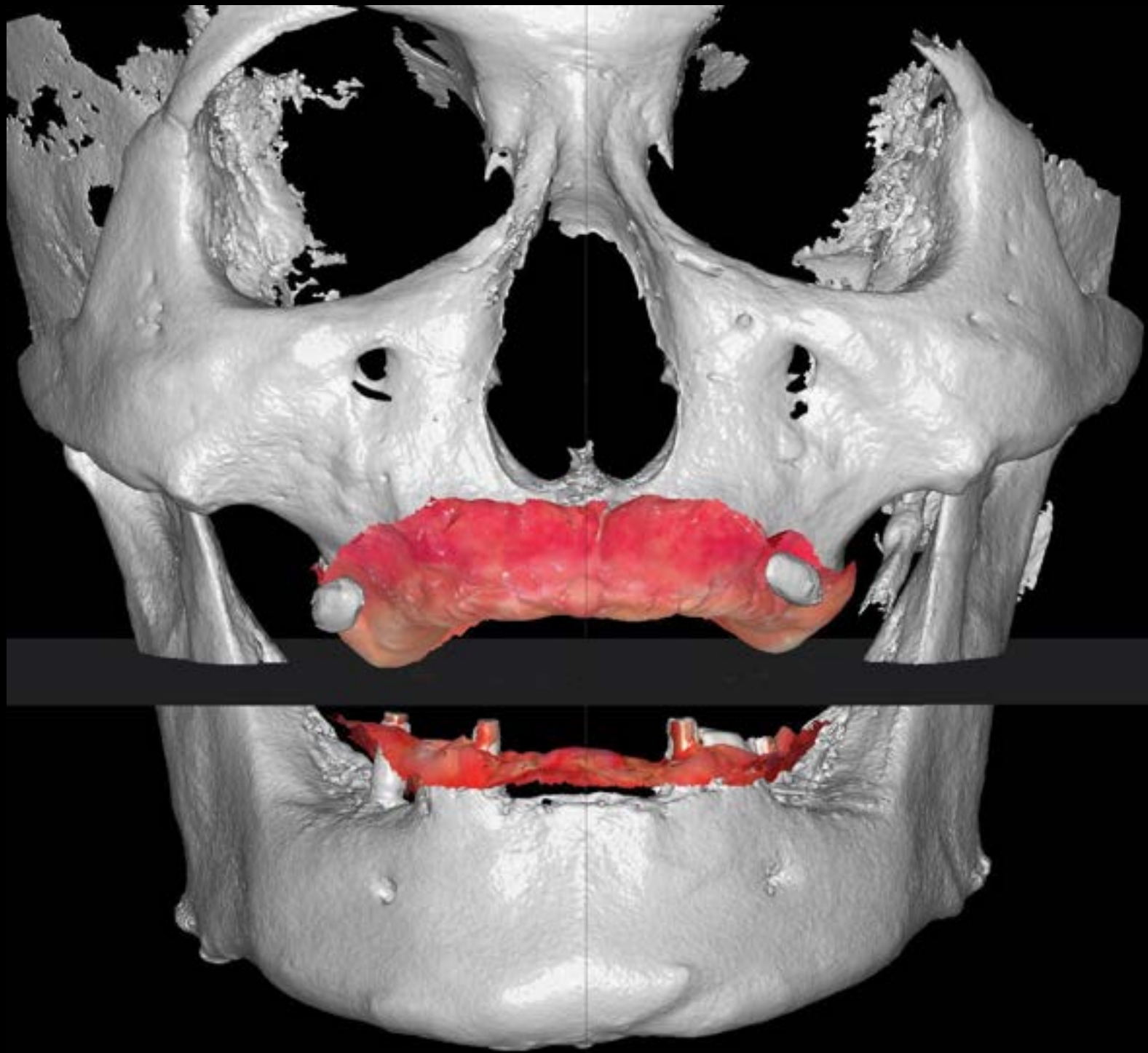Ti base Ø3.8 Gh2.0



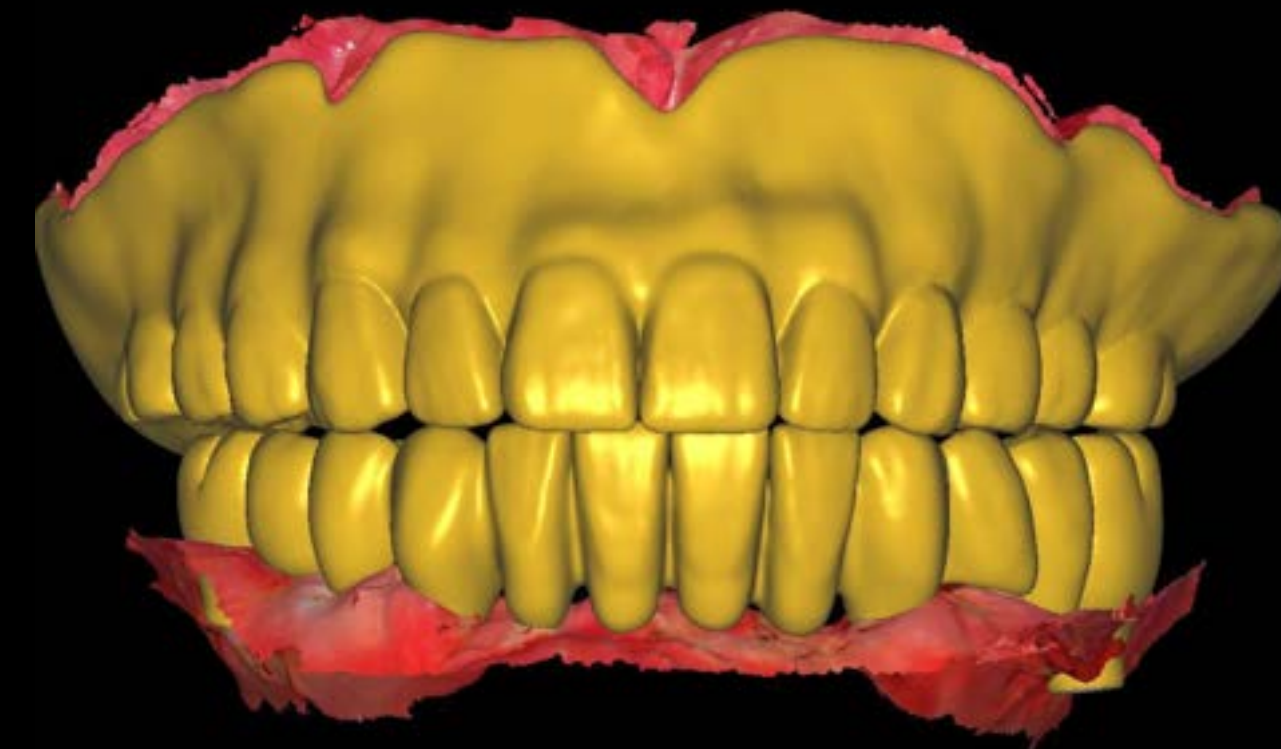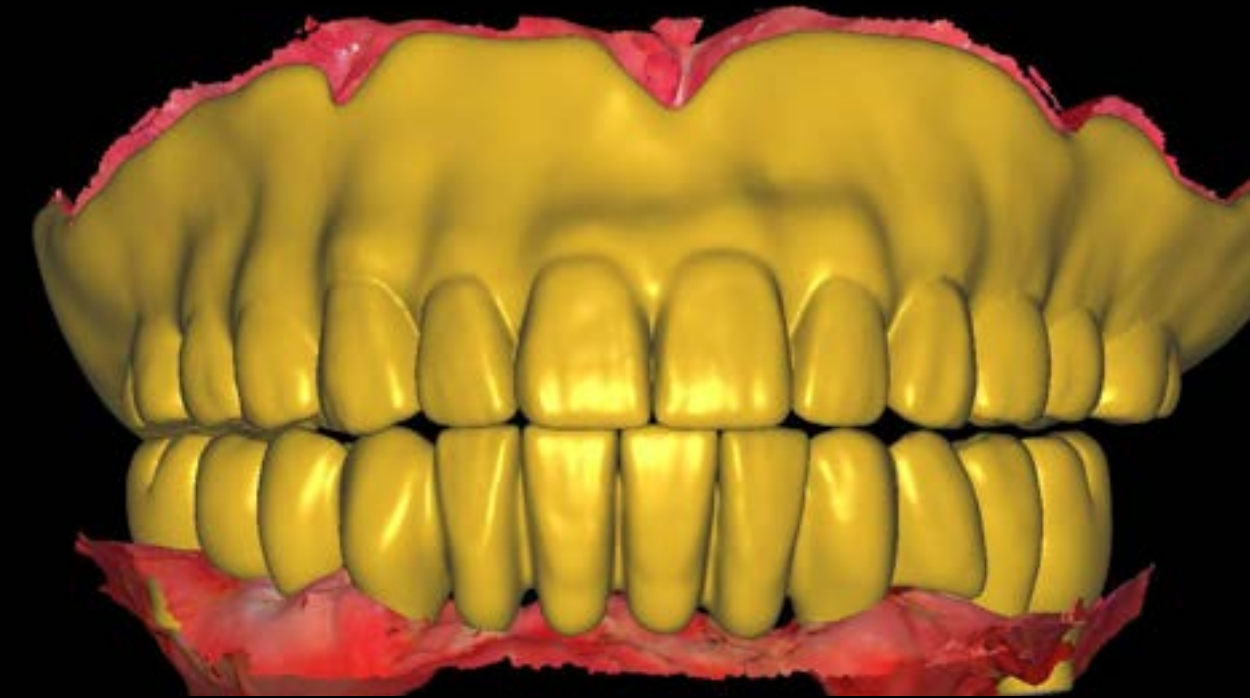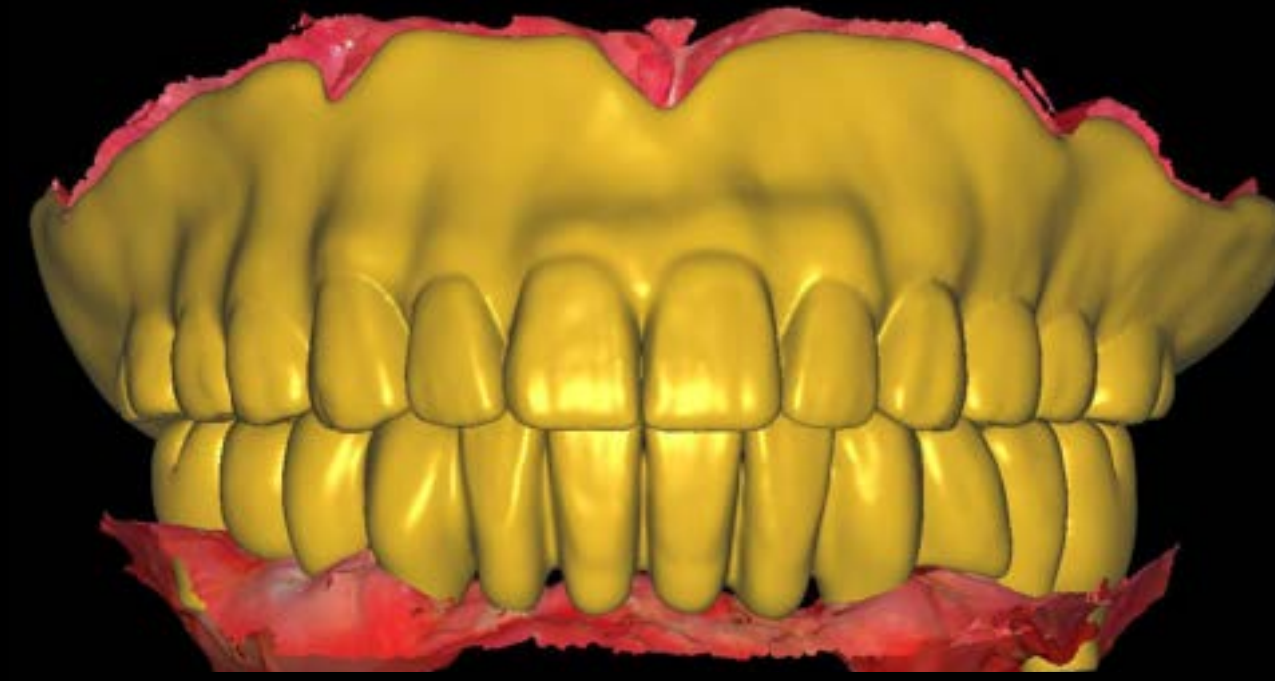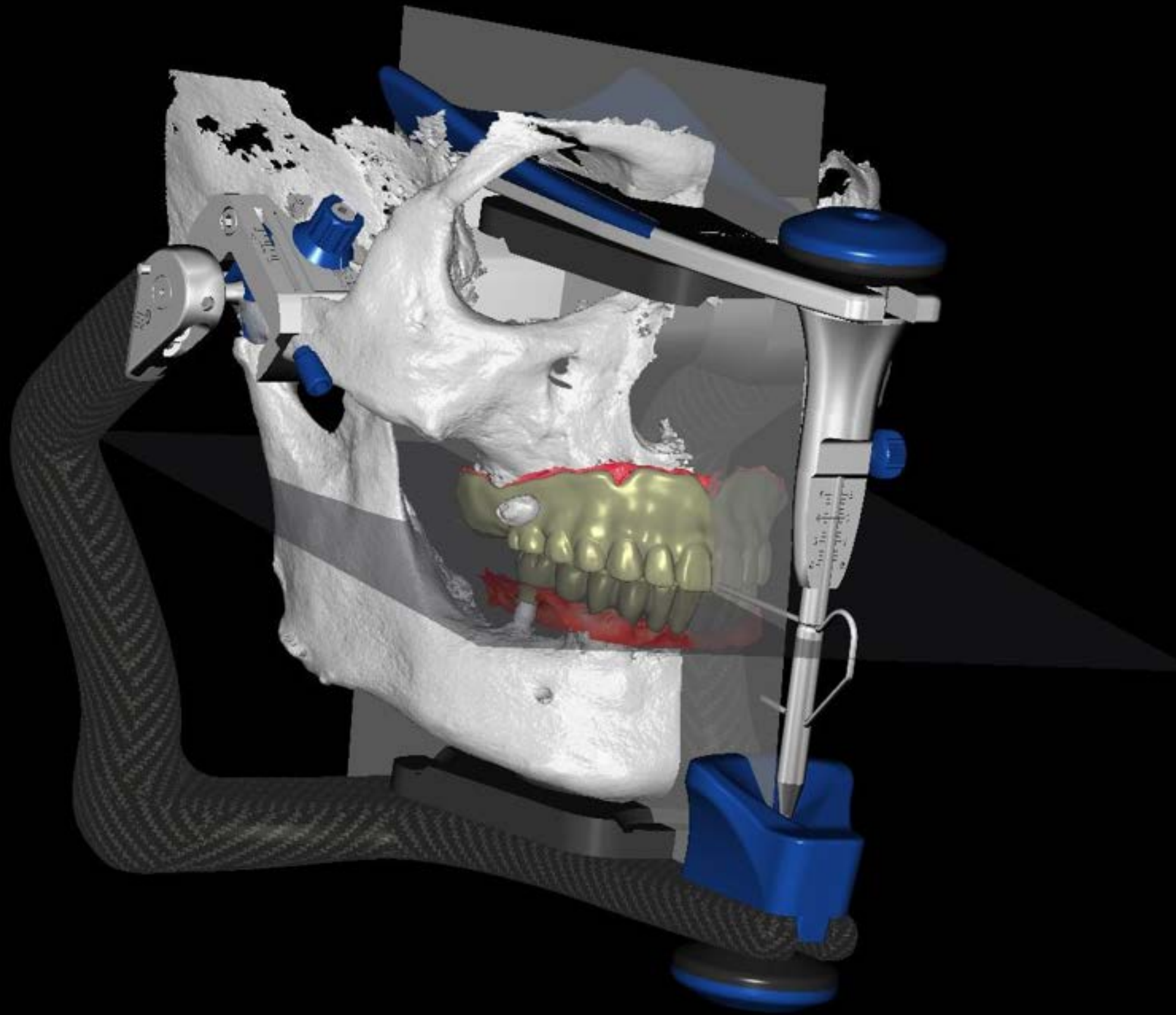
Multiple long case Cement gap

CAD design

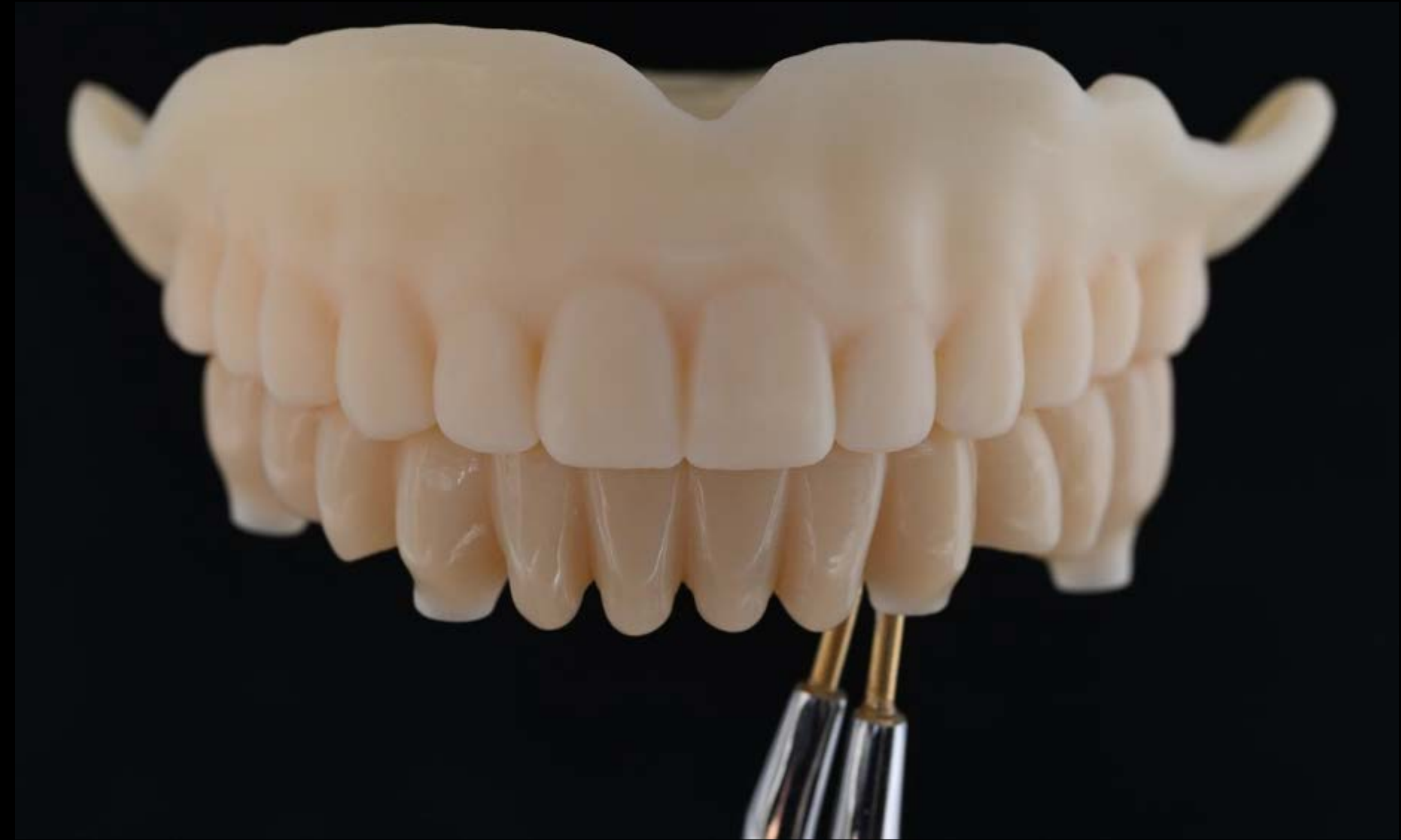
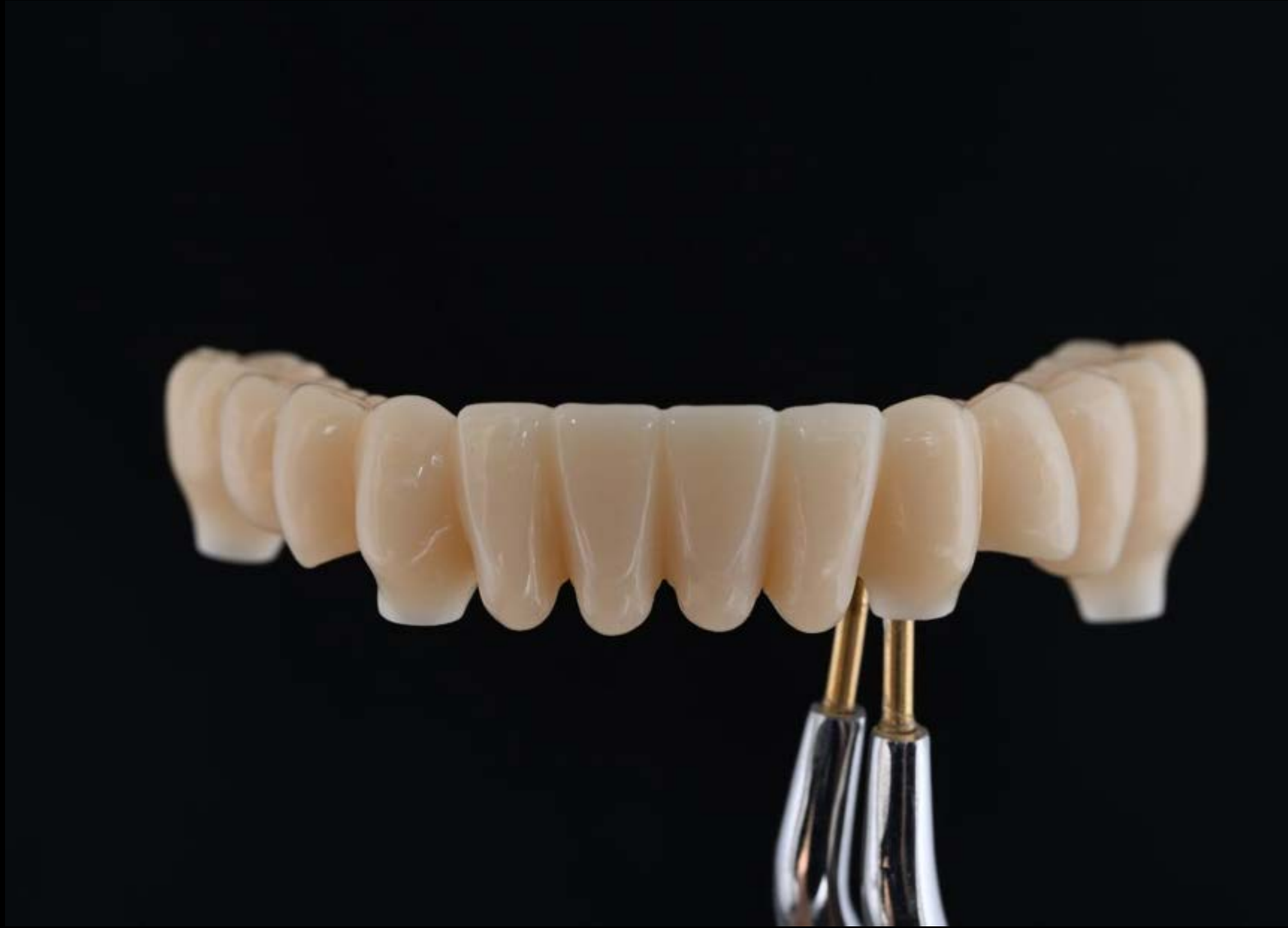
CT Check Bite with Zirconia Marker

Virtual Artricator

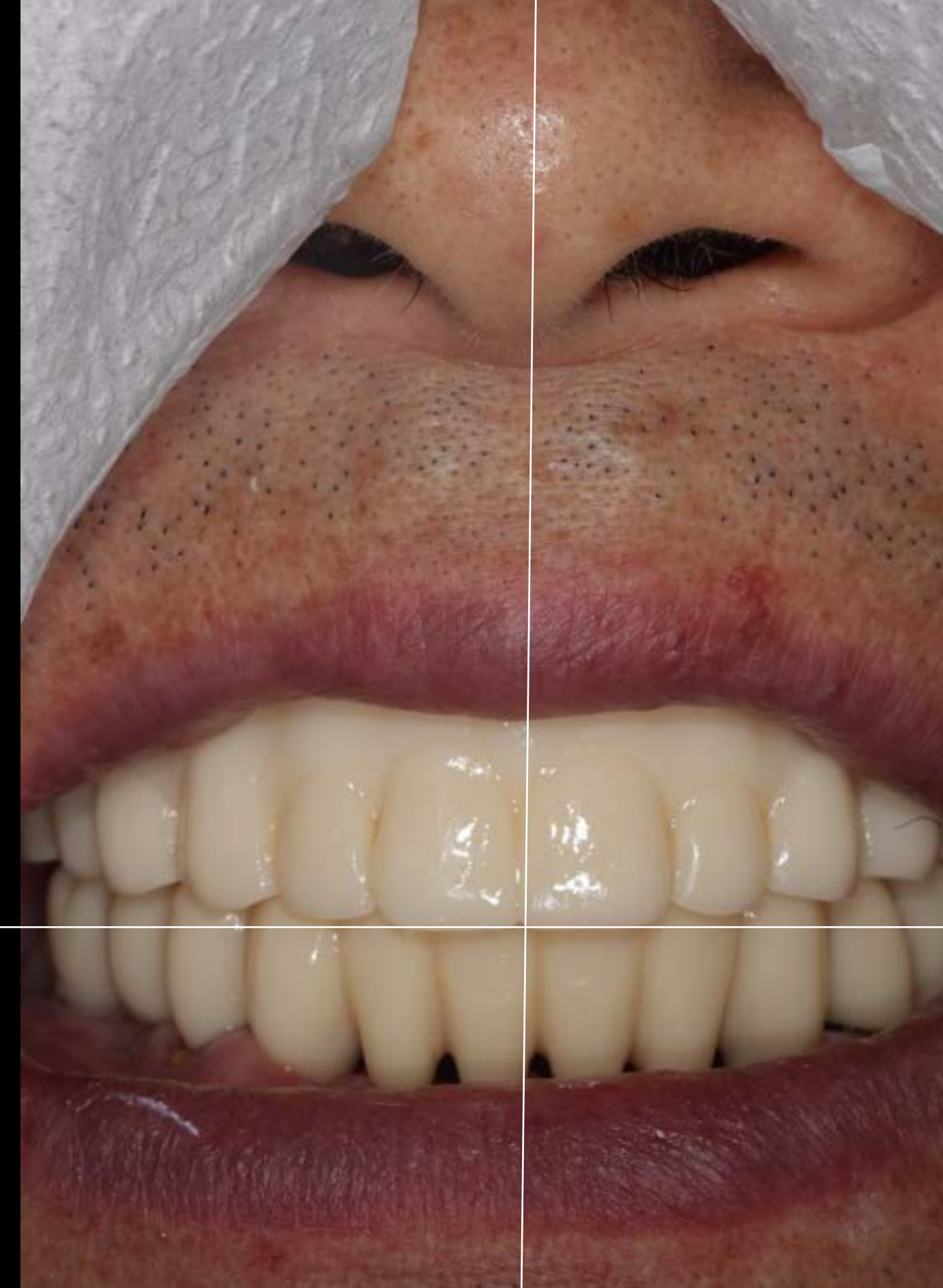
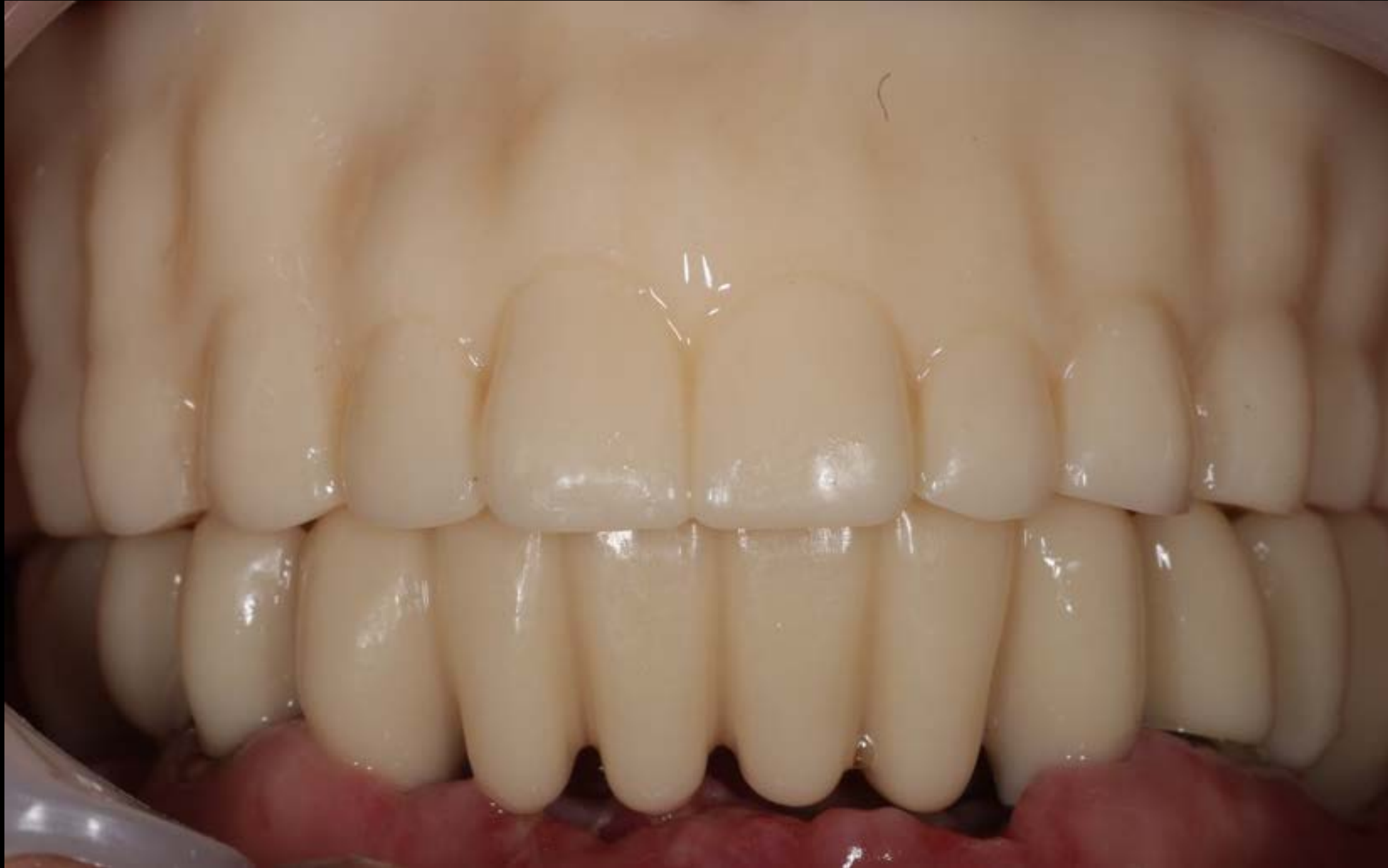

Printing & Milling

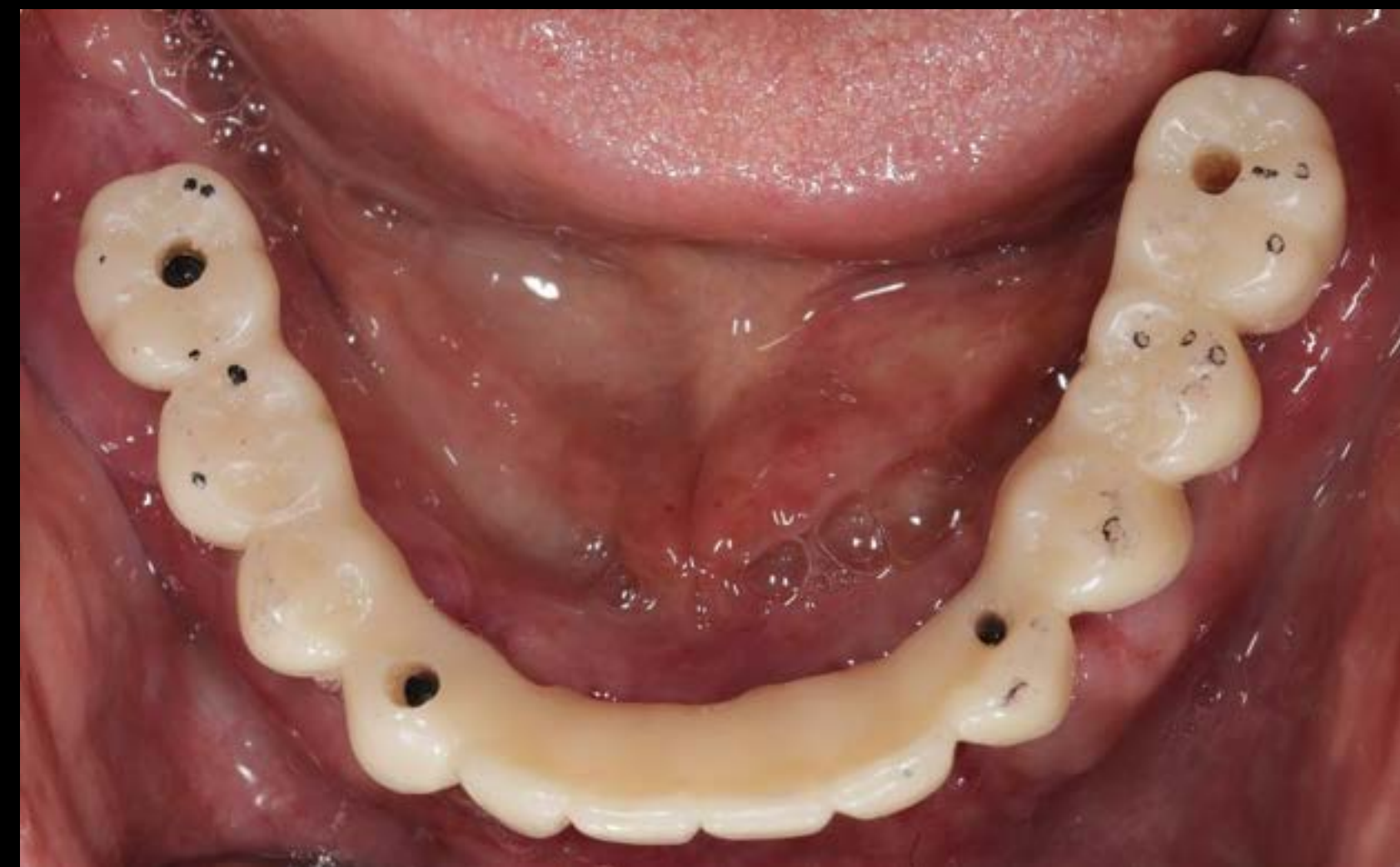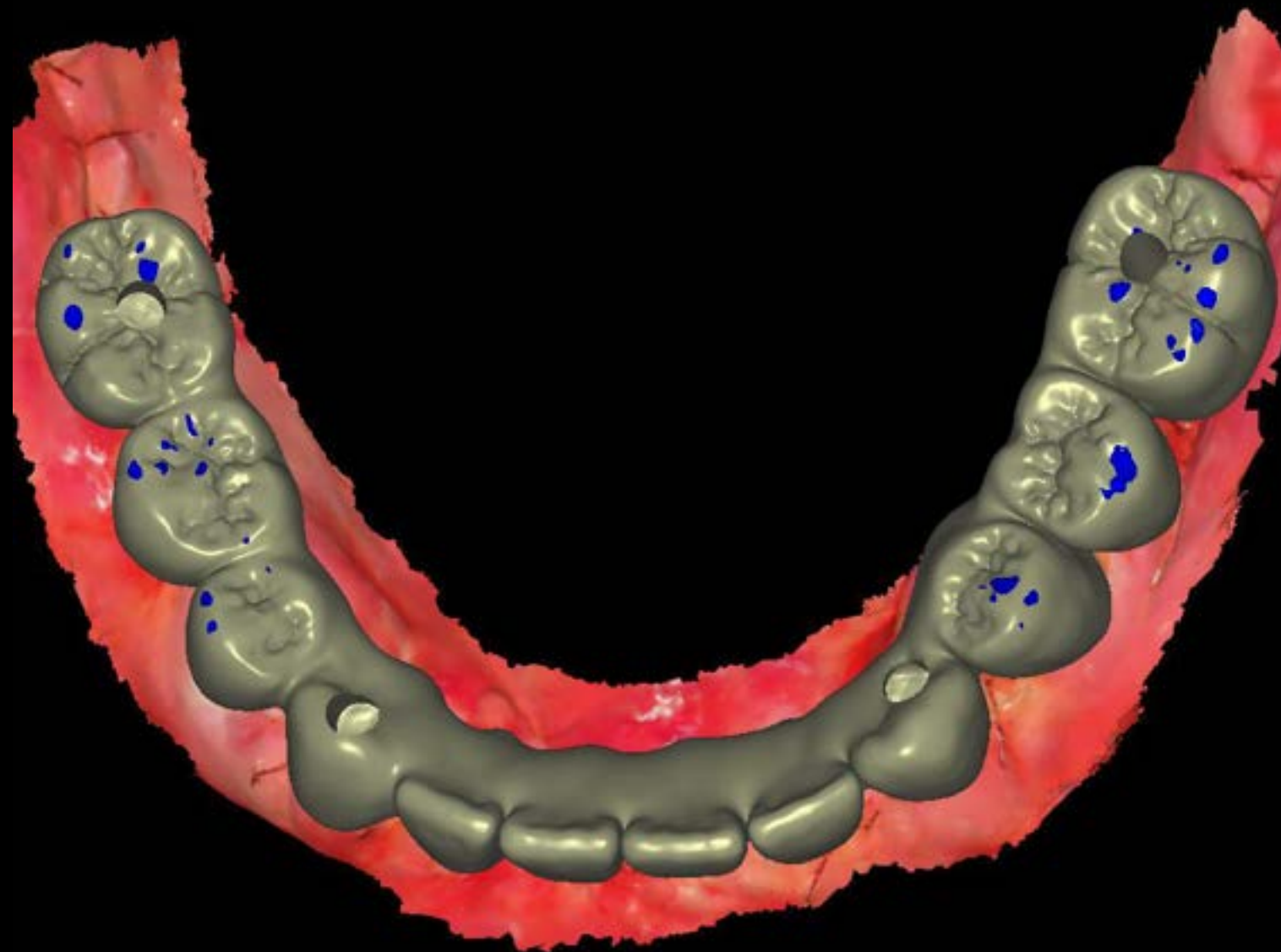
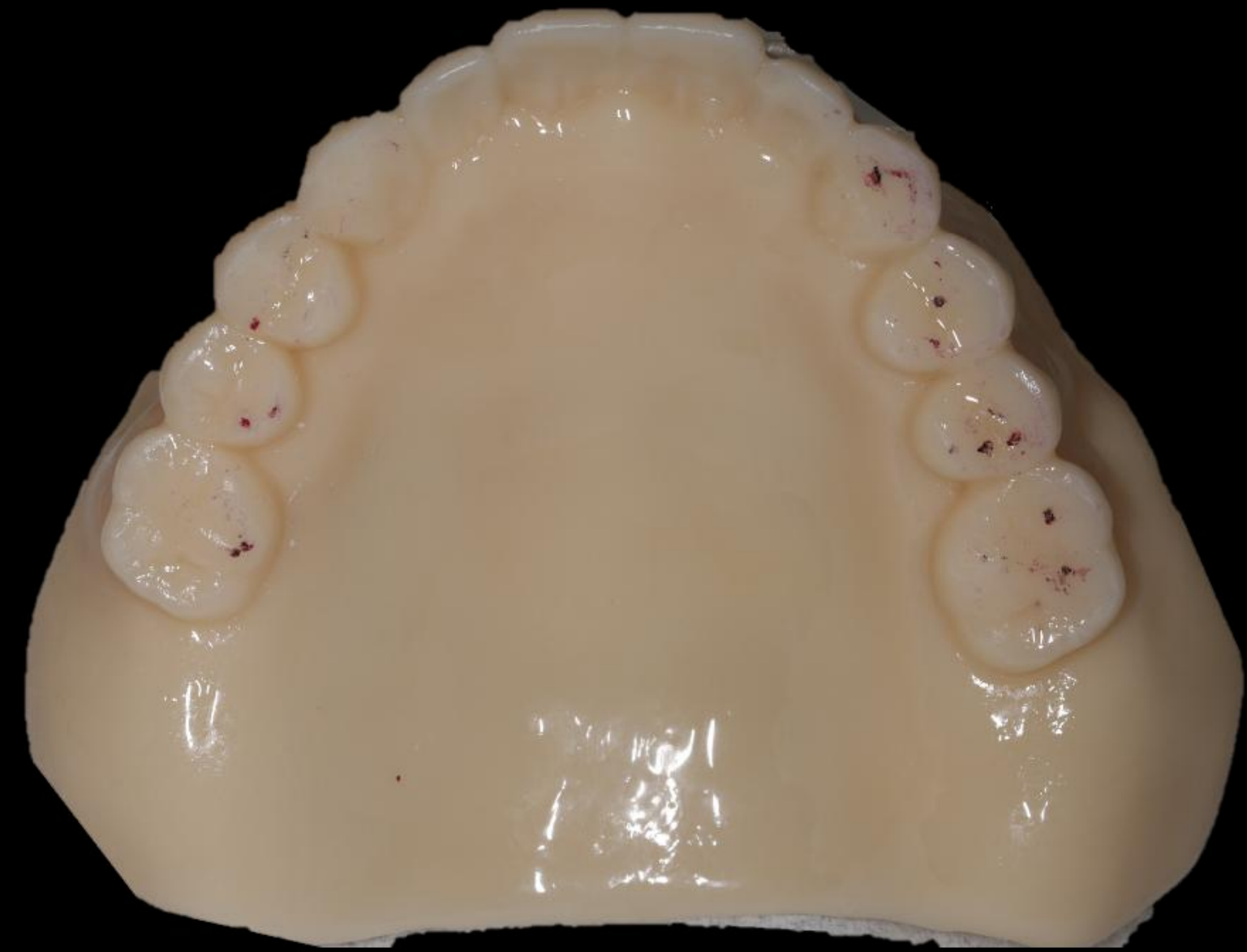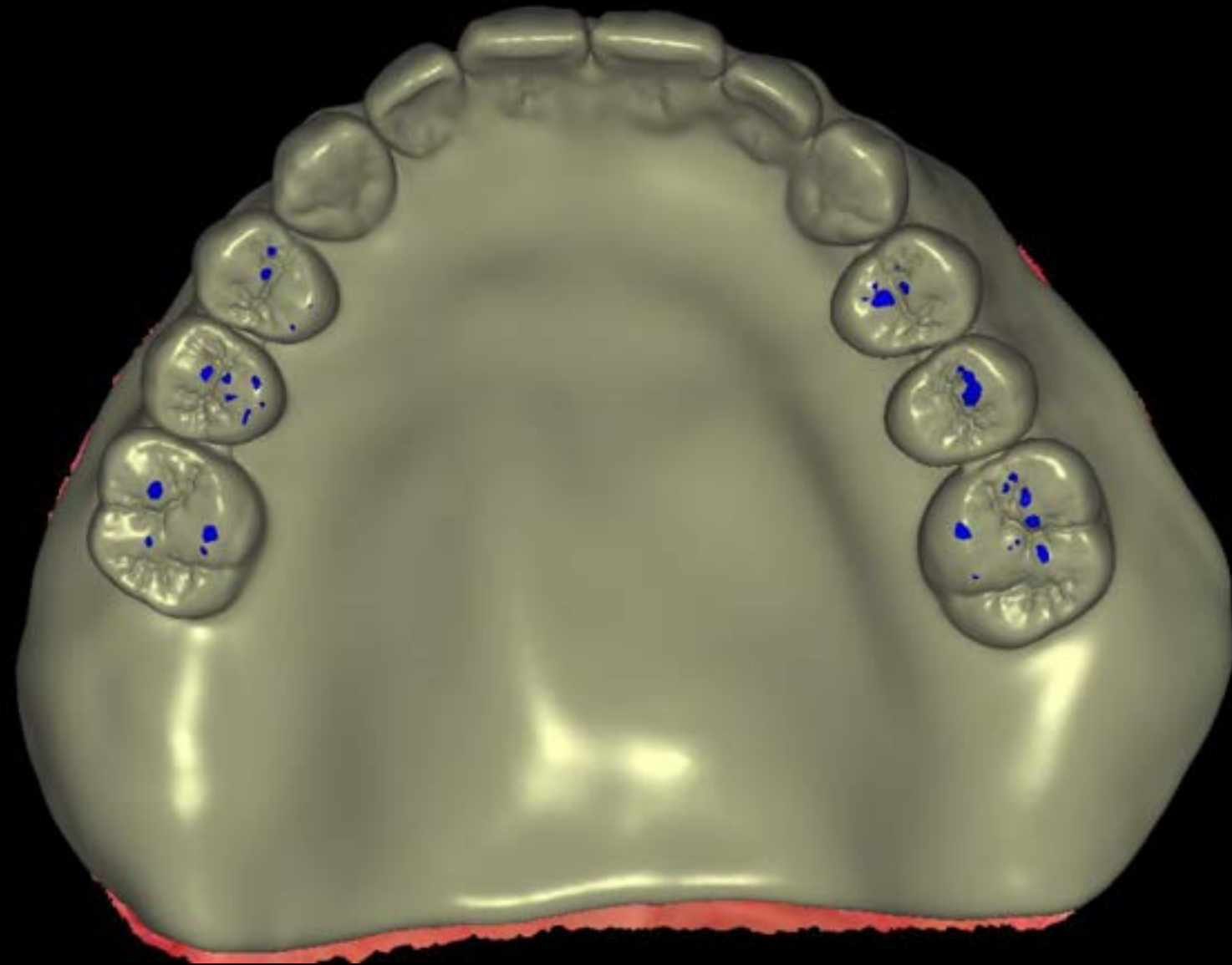


PMMA Block
3D Prininting Resin

Provisional Restoration

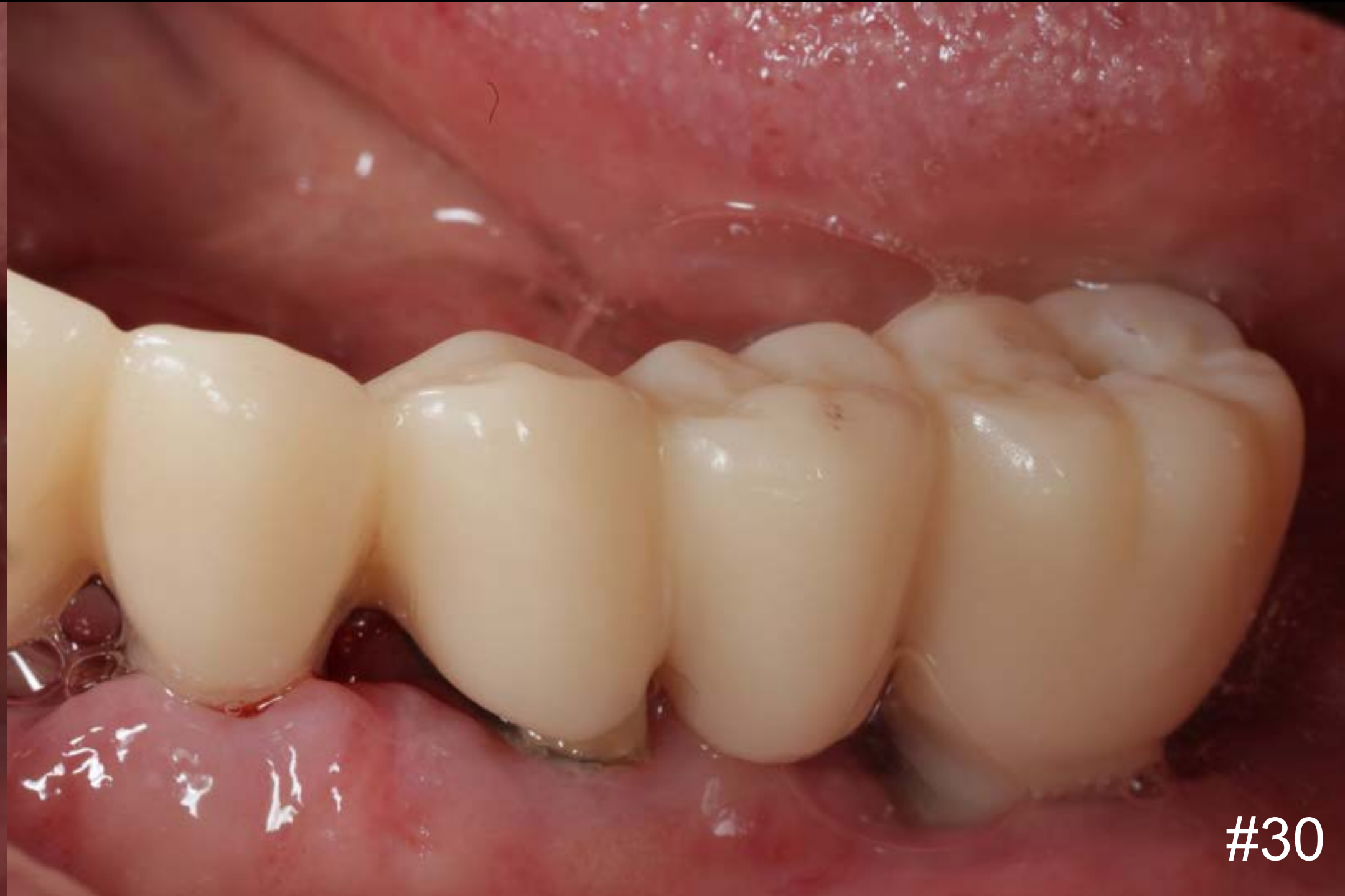
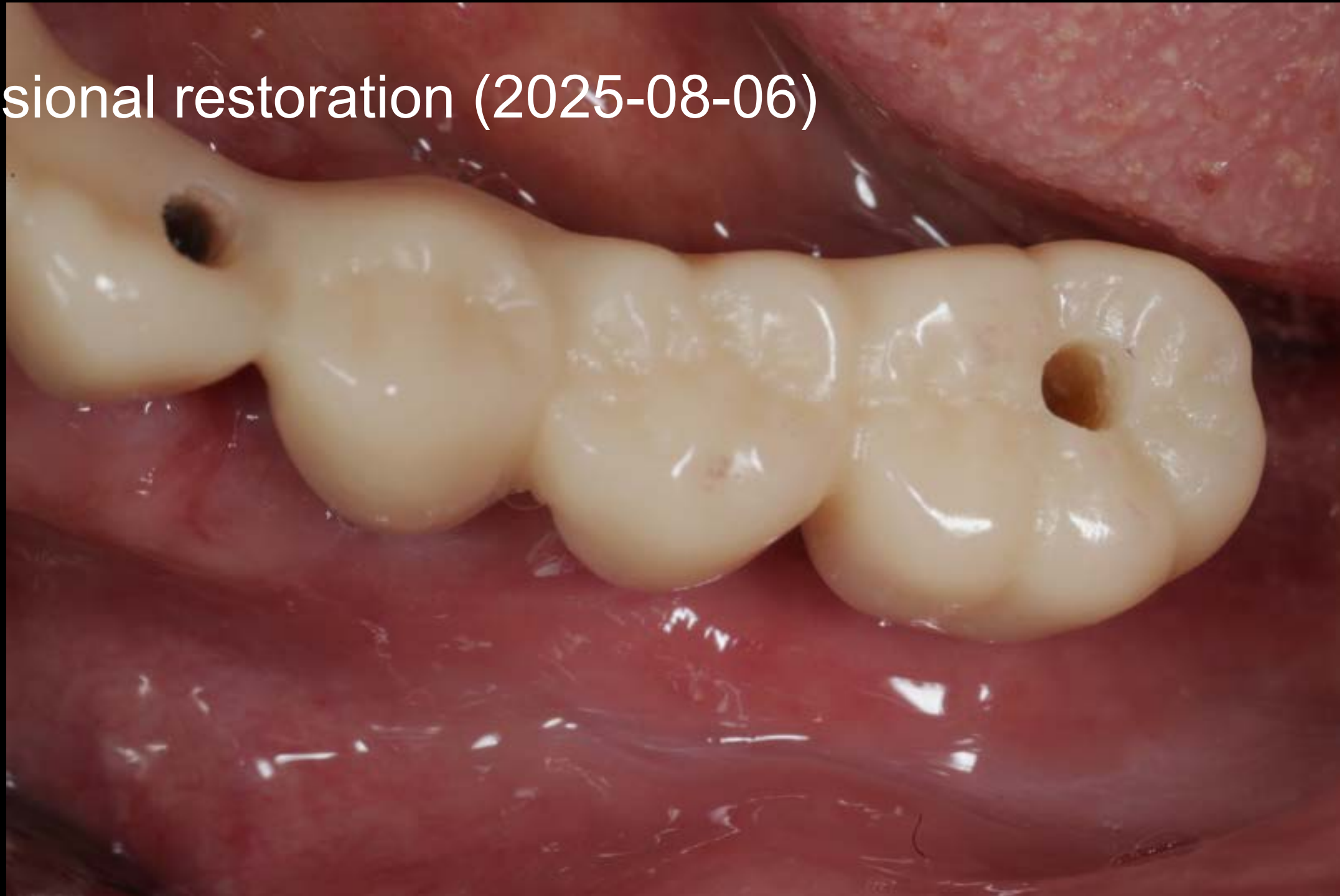
Provisional Restoration

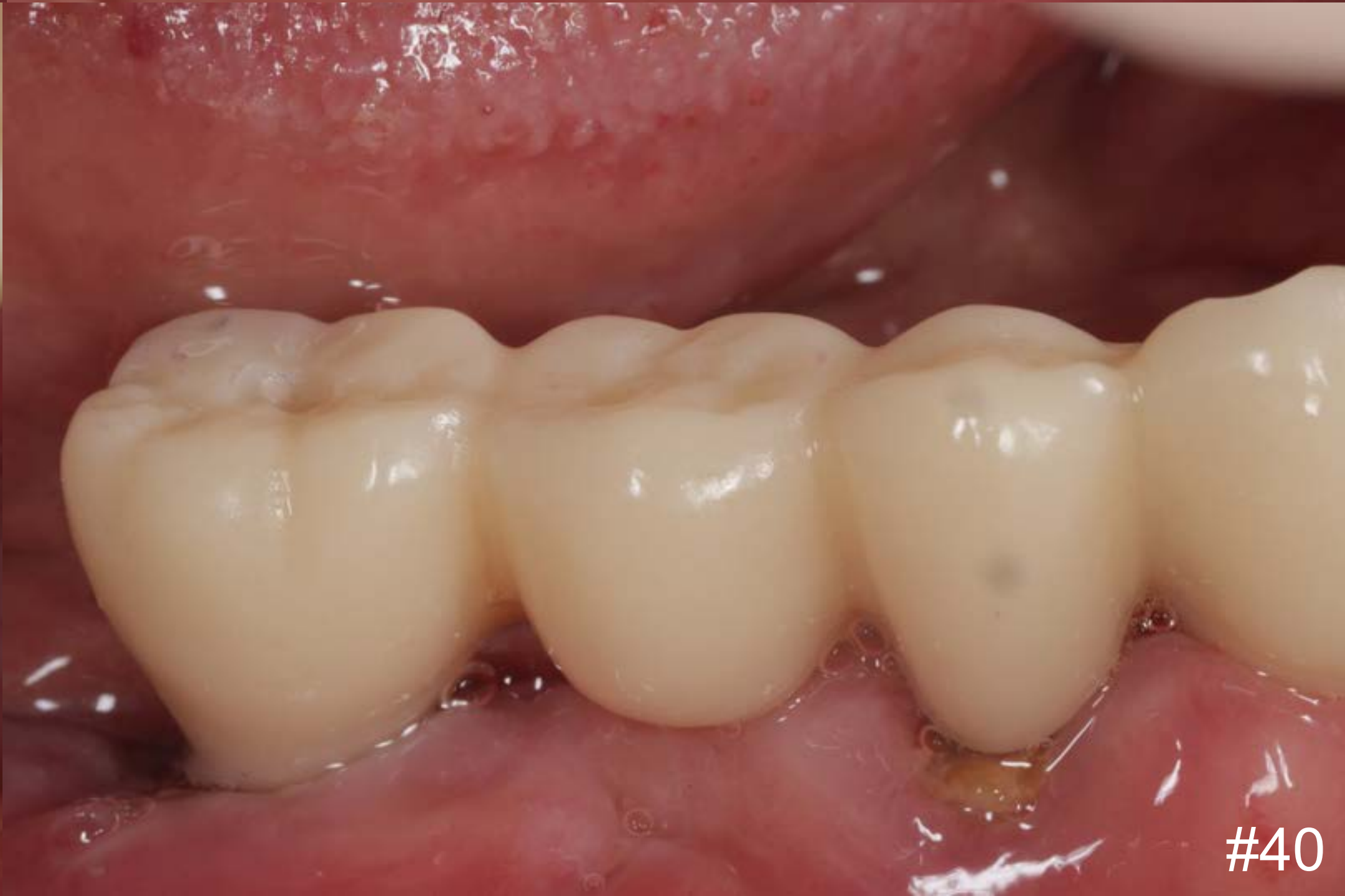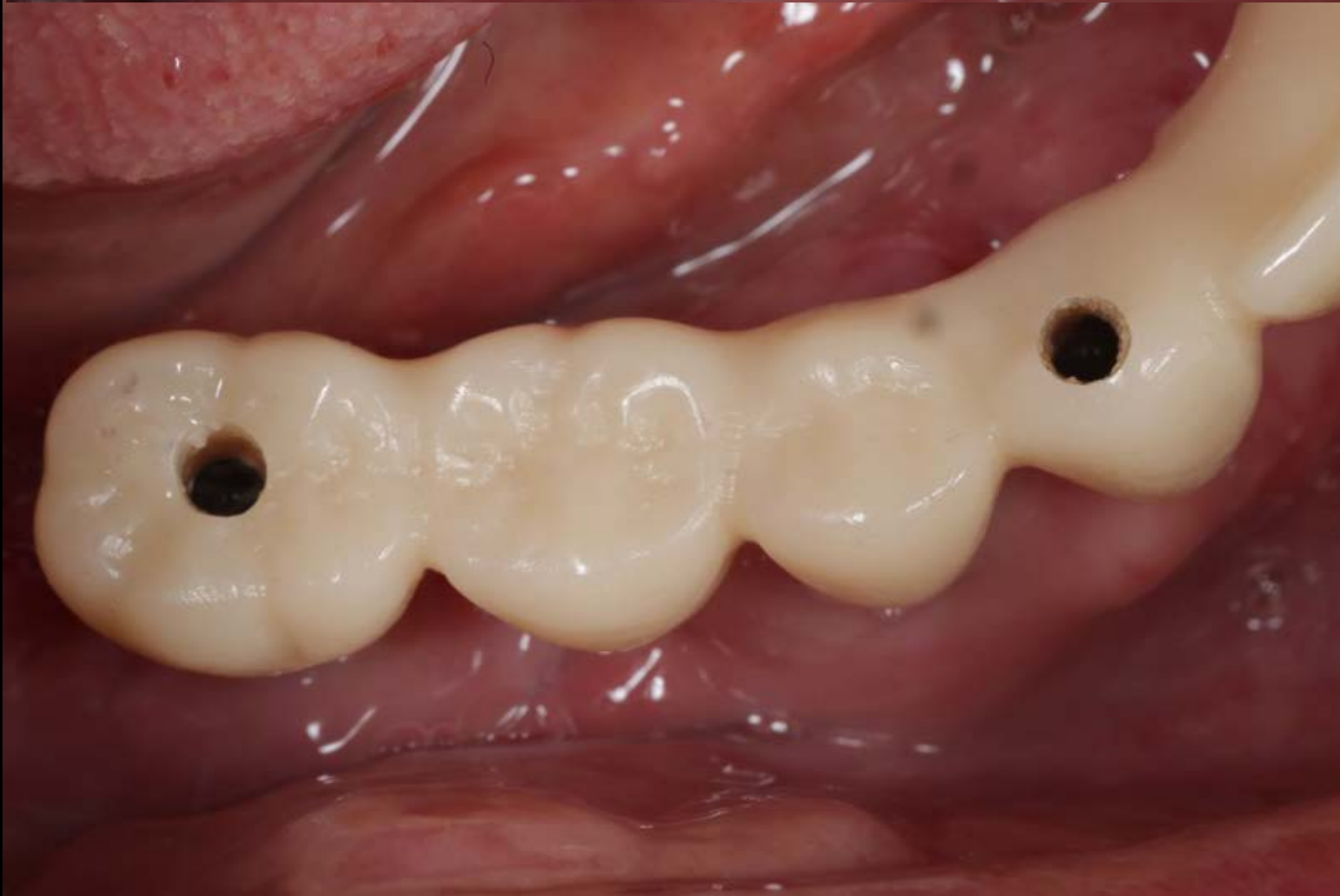


Model-Less

Provisional restoration (2025-08-06)

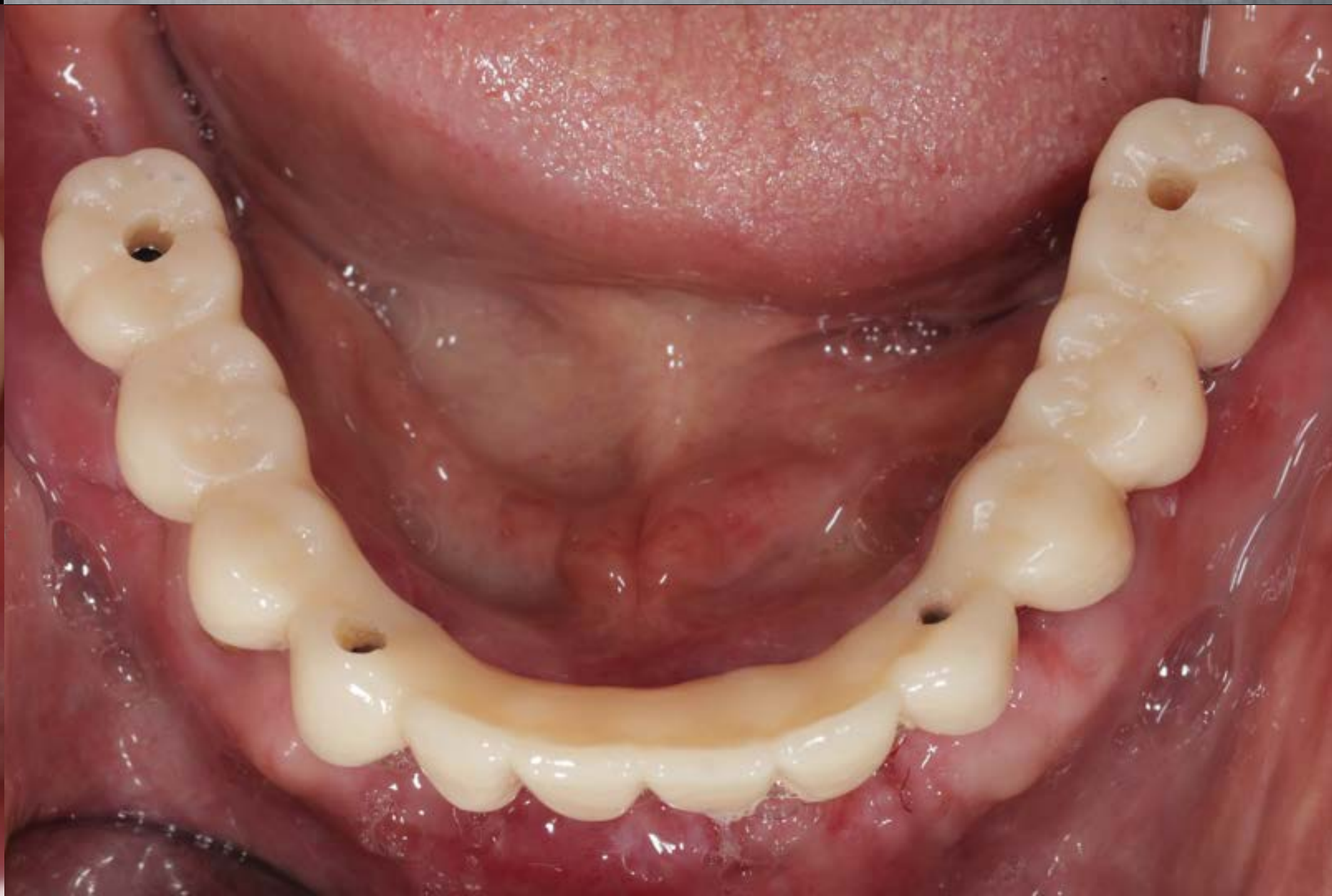
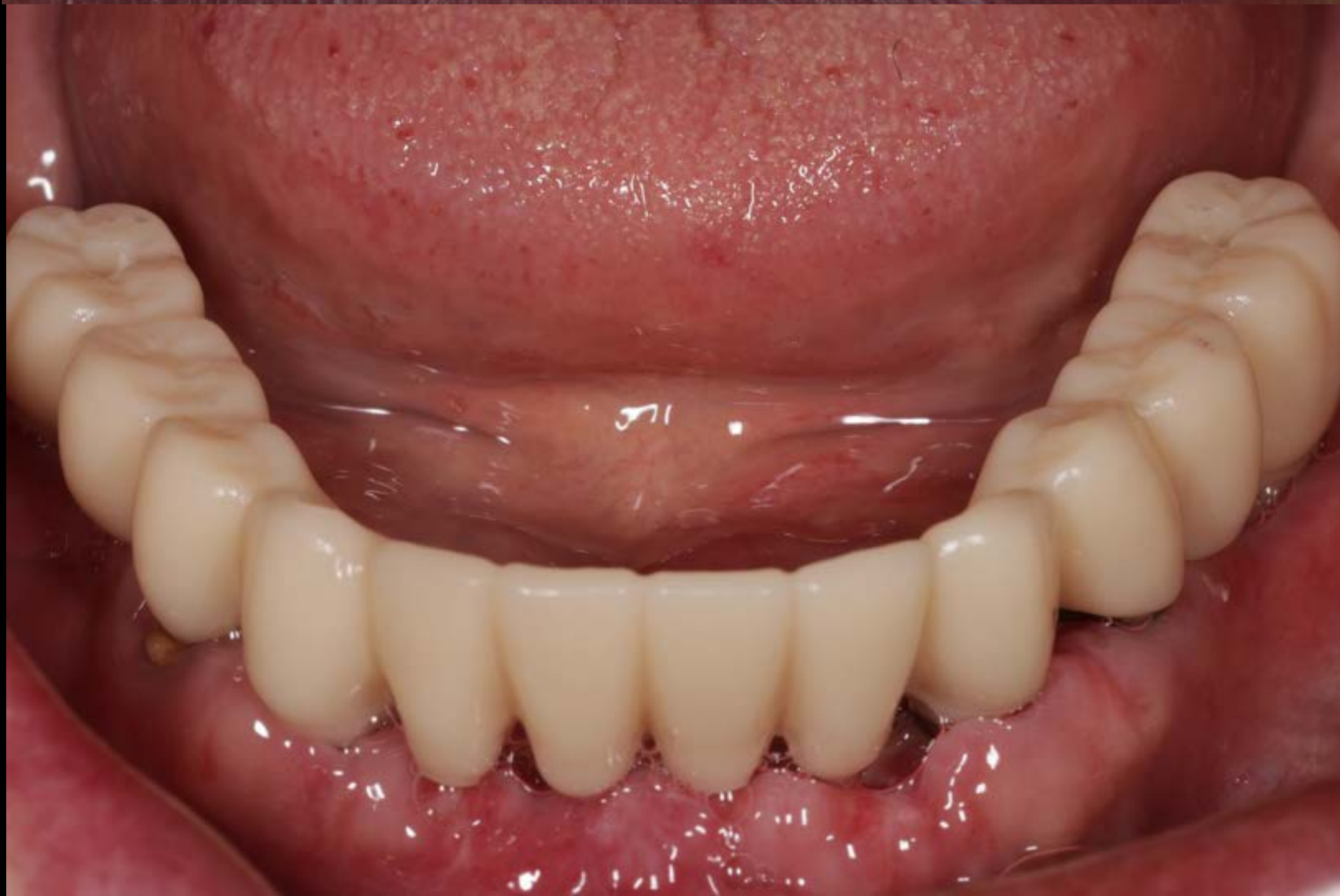
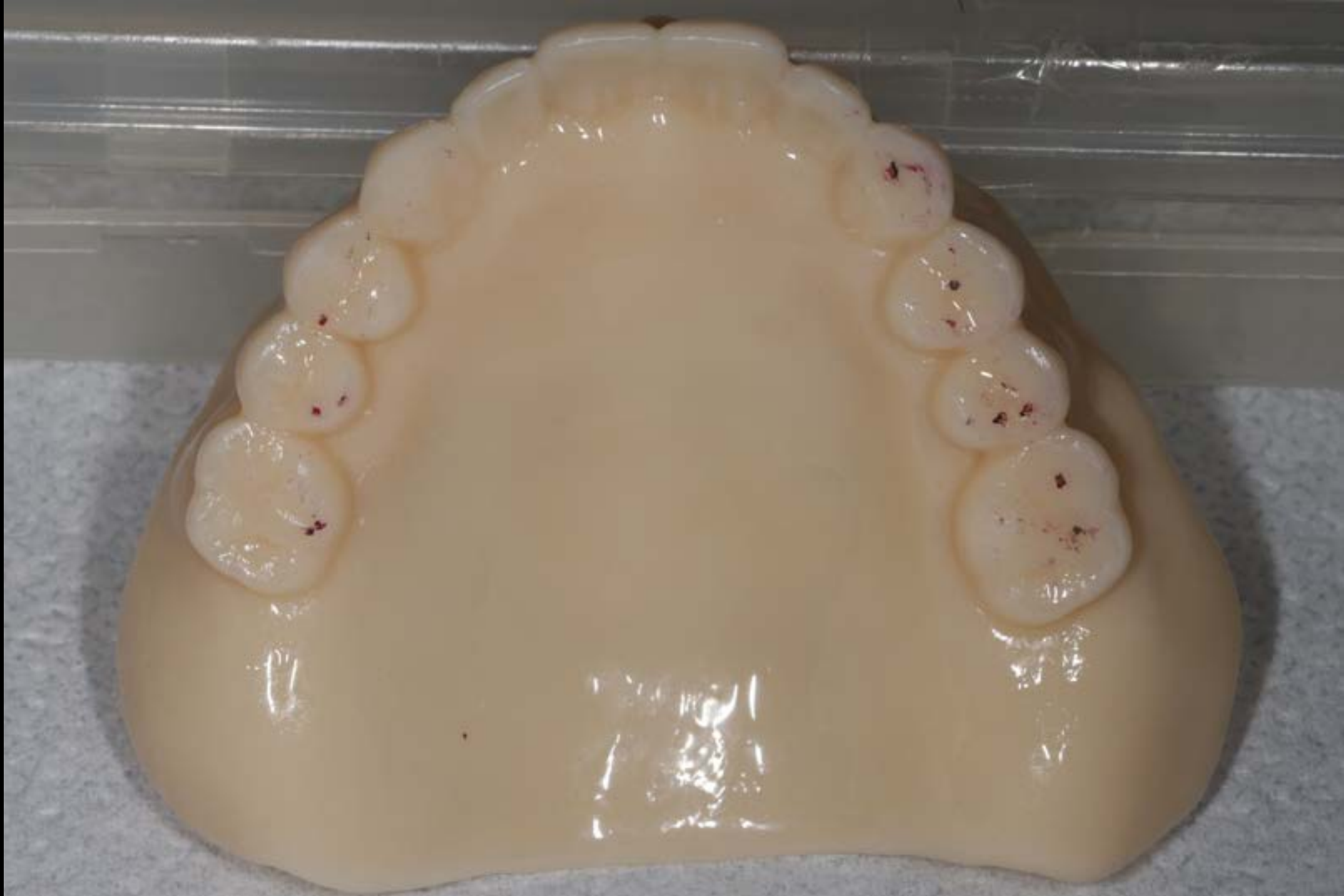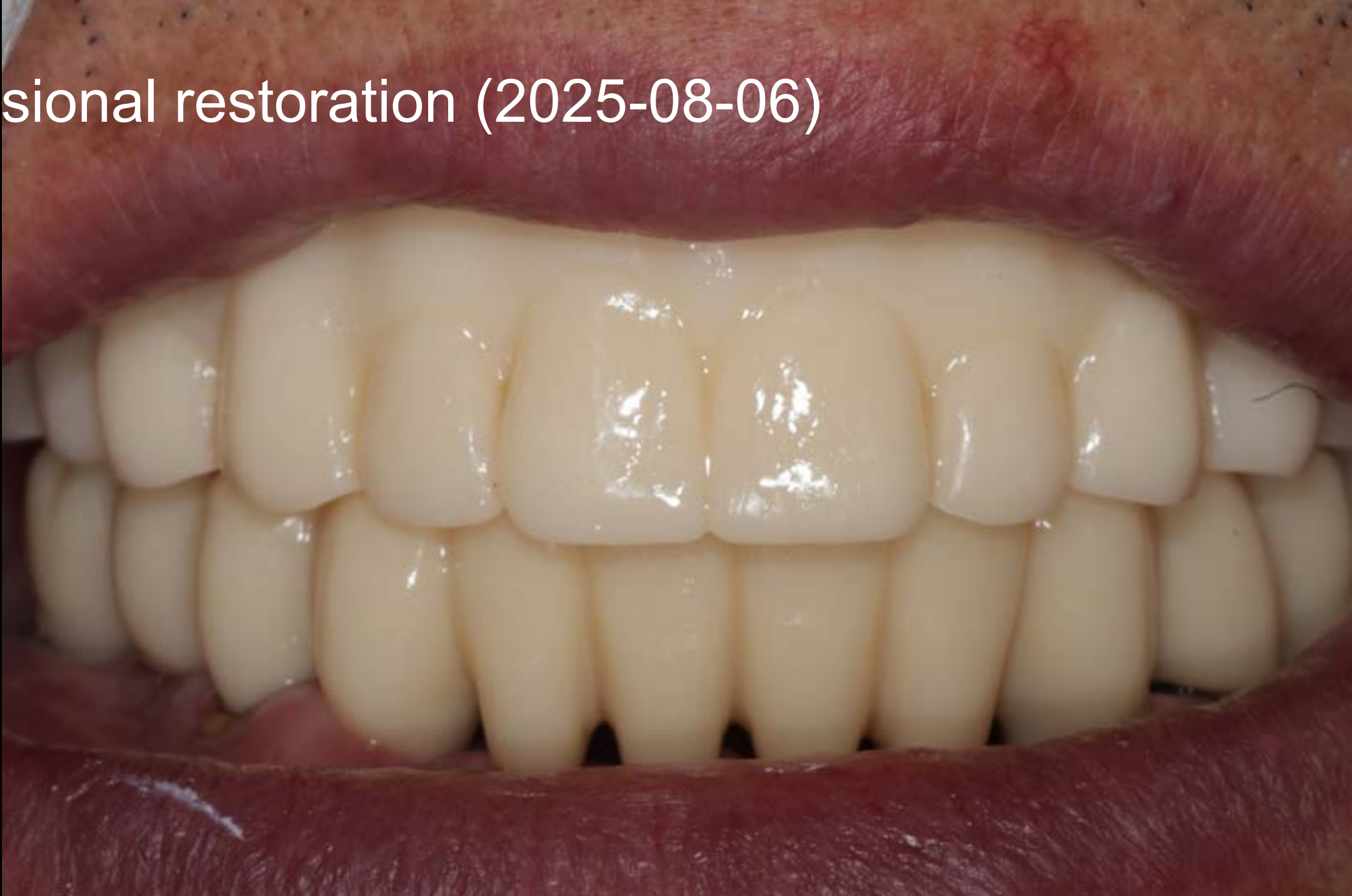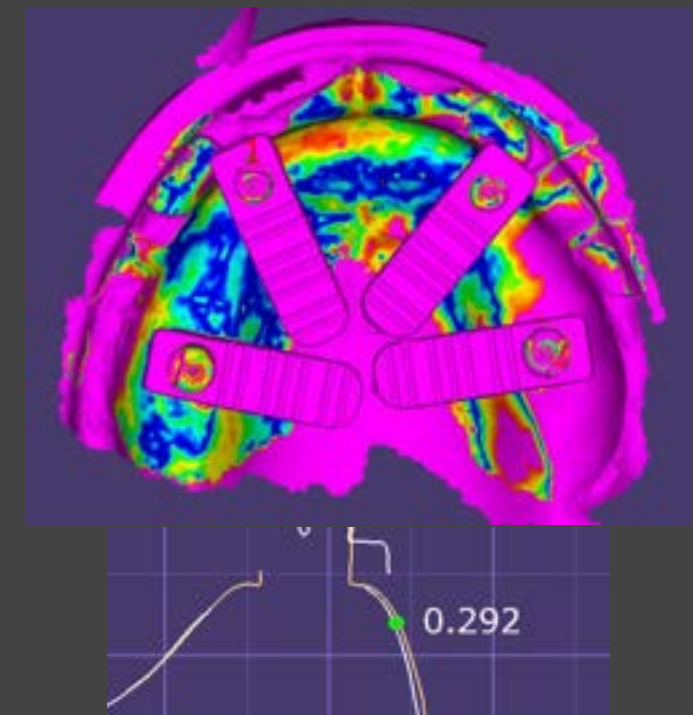
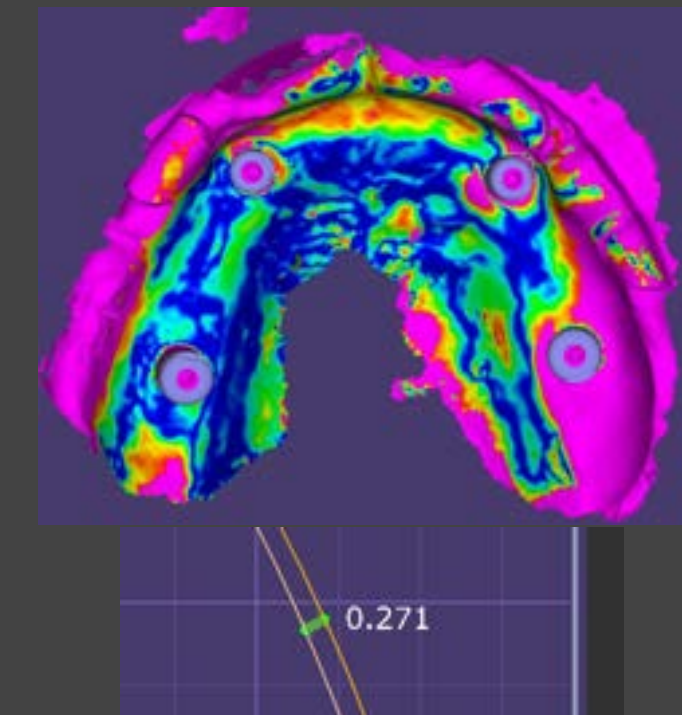
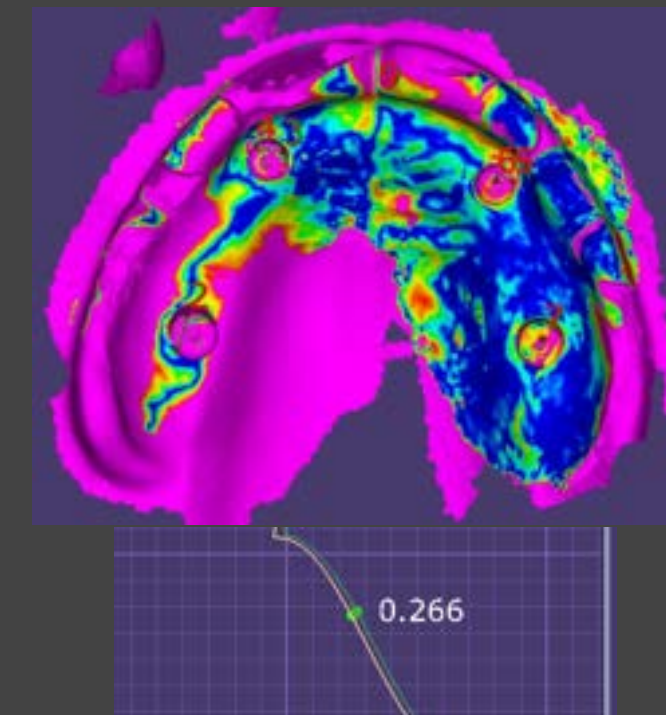
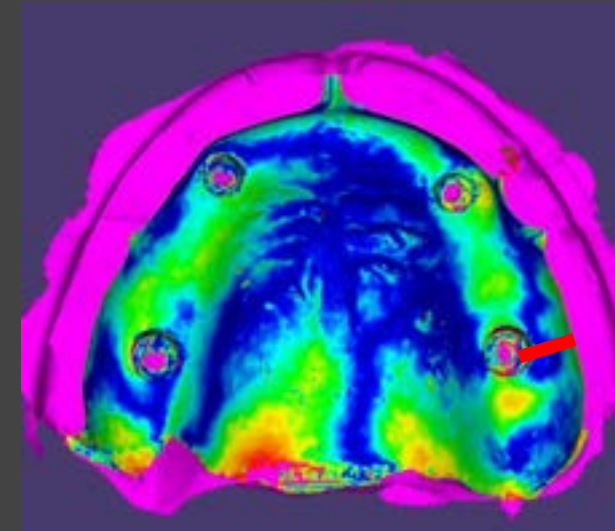

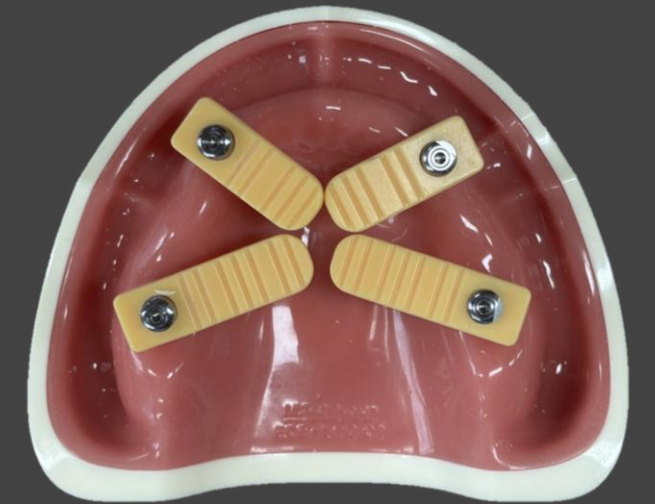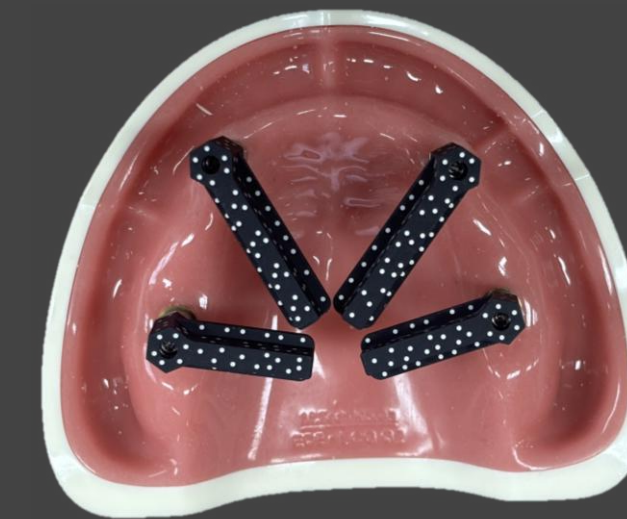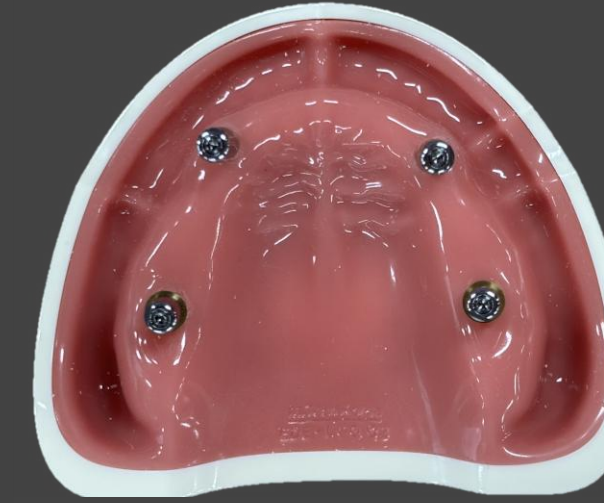
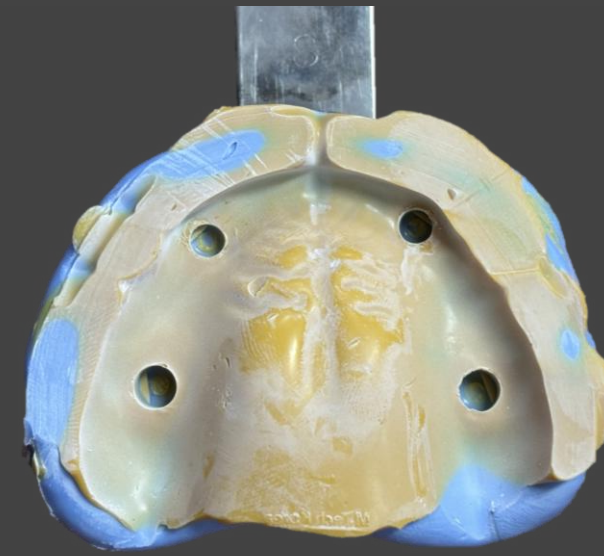
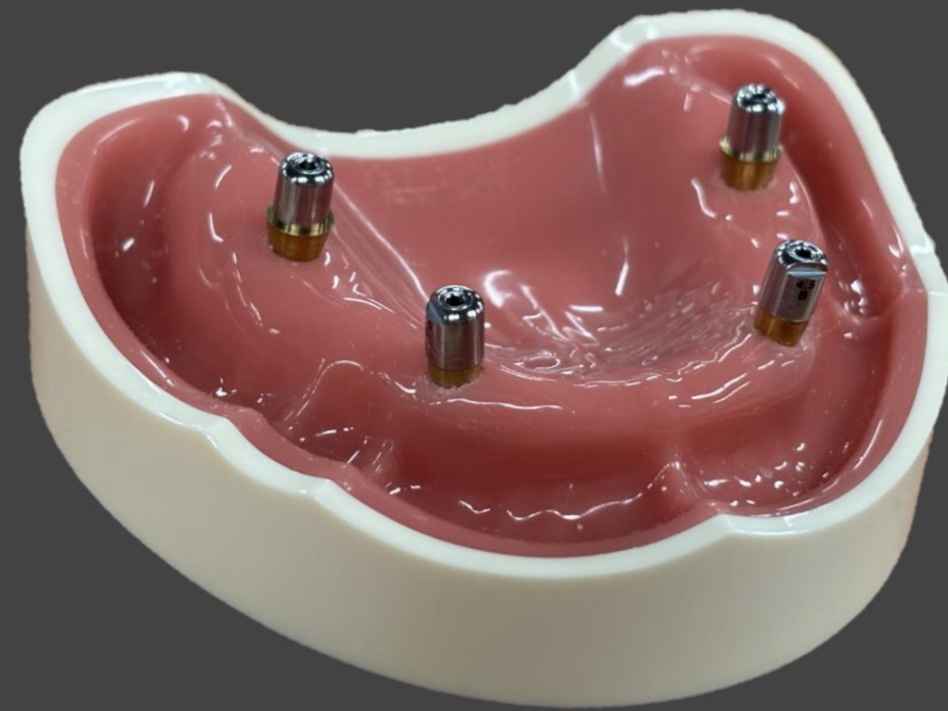
#30



#40

Provisional restoration (2025-08-06)

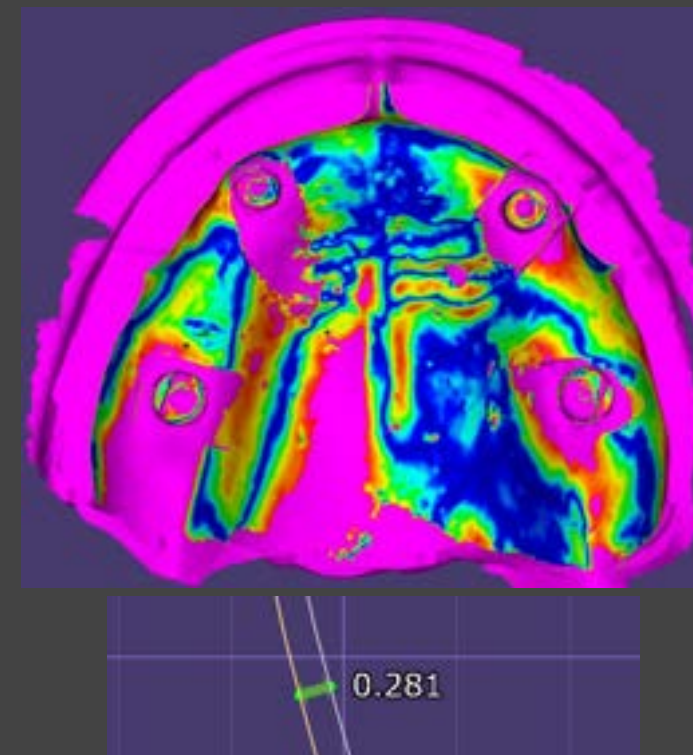
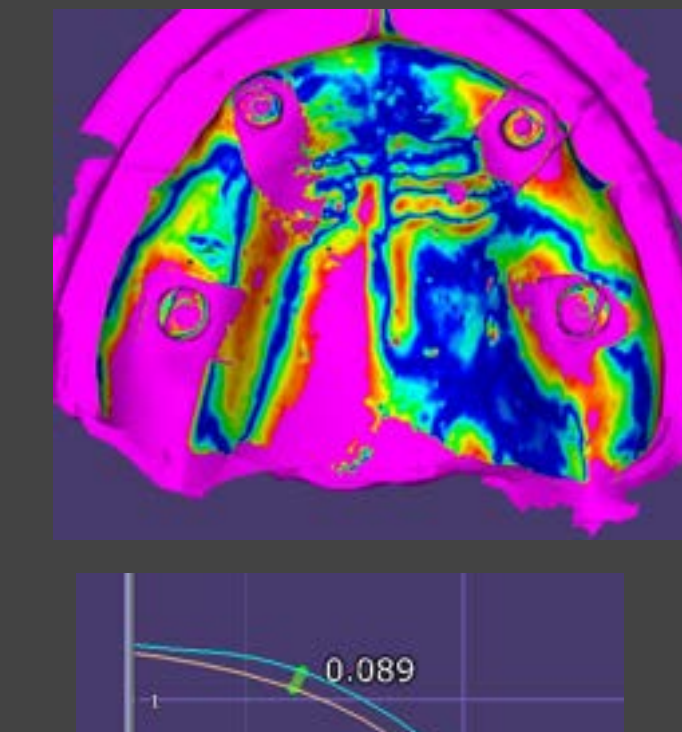
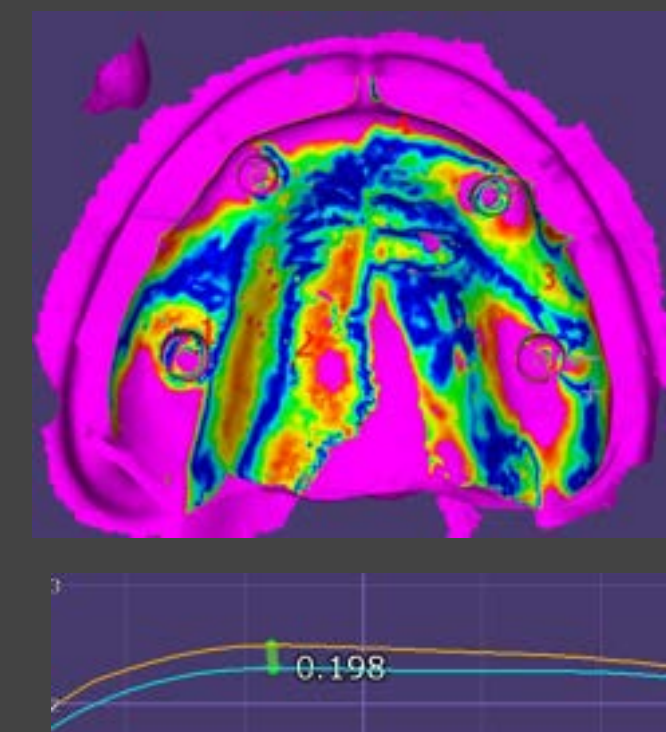




BTS = BOS

Photogrammetry jig and simple jig are similar and fit well

Without Jig is less hittable



Contents

Bright implant

Narrow and short implants

Bone regeneration materials

Simple and exact digital concepts

Filler and toxin in dental field

Safe approach based on evidence

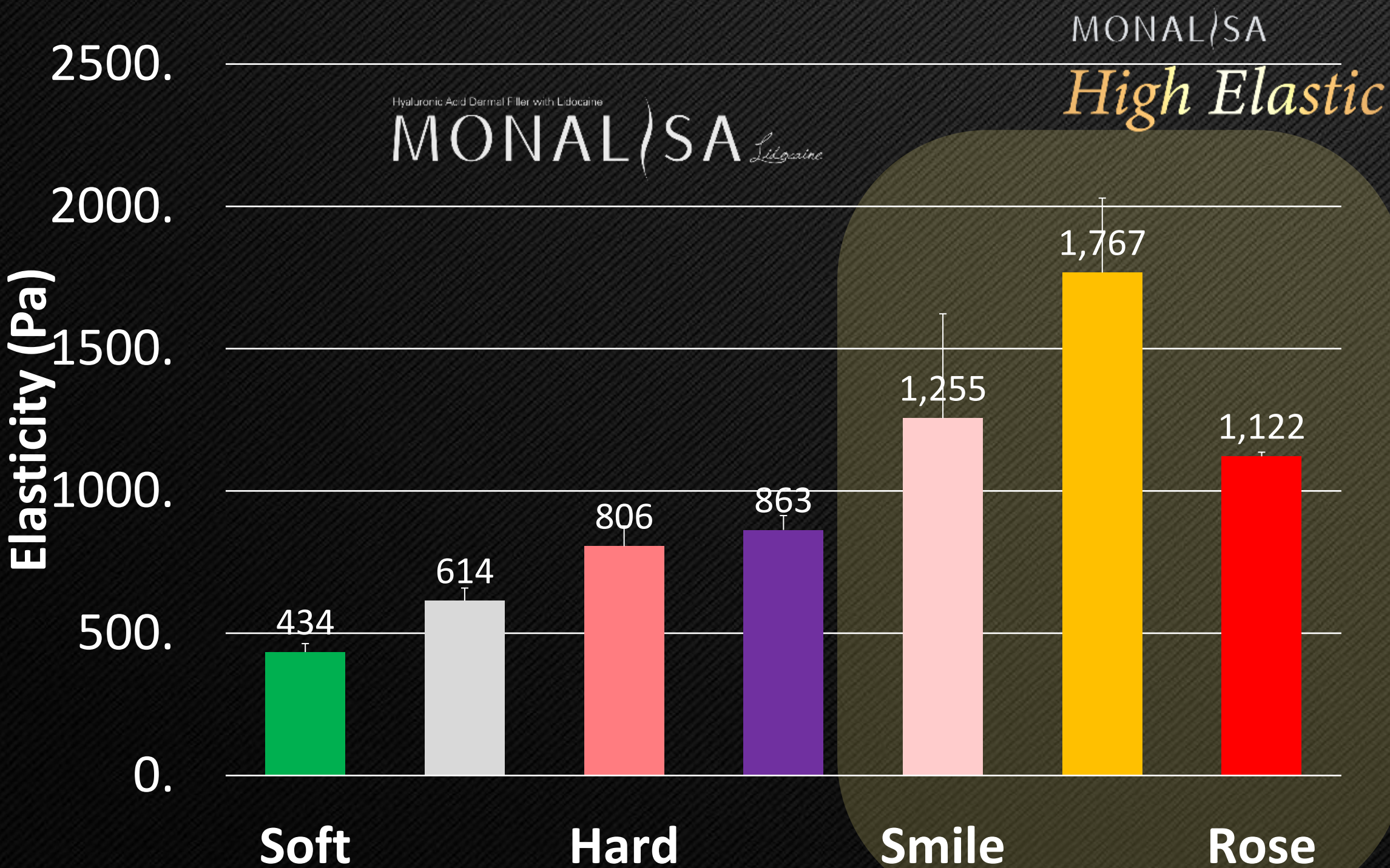
Dynamic approach based on inspiration

New field over dentistry

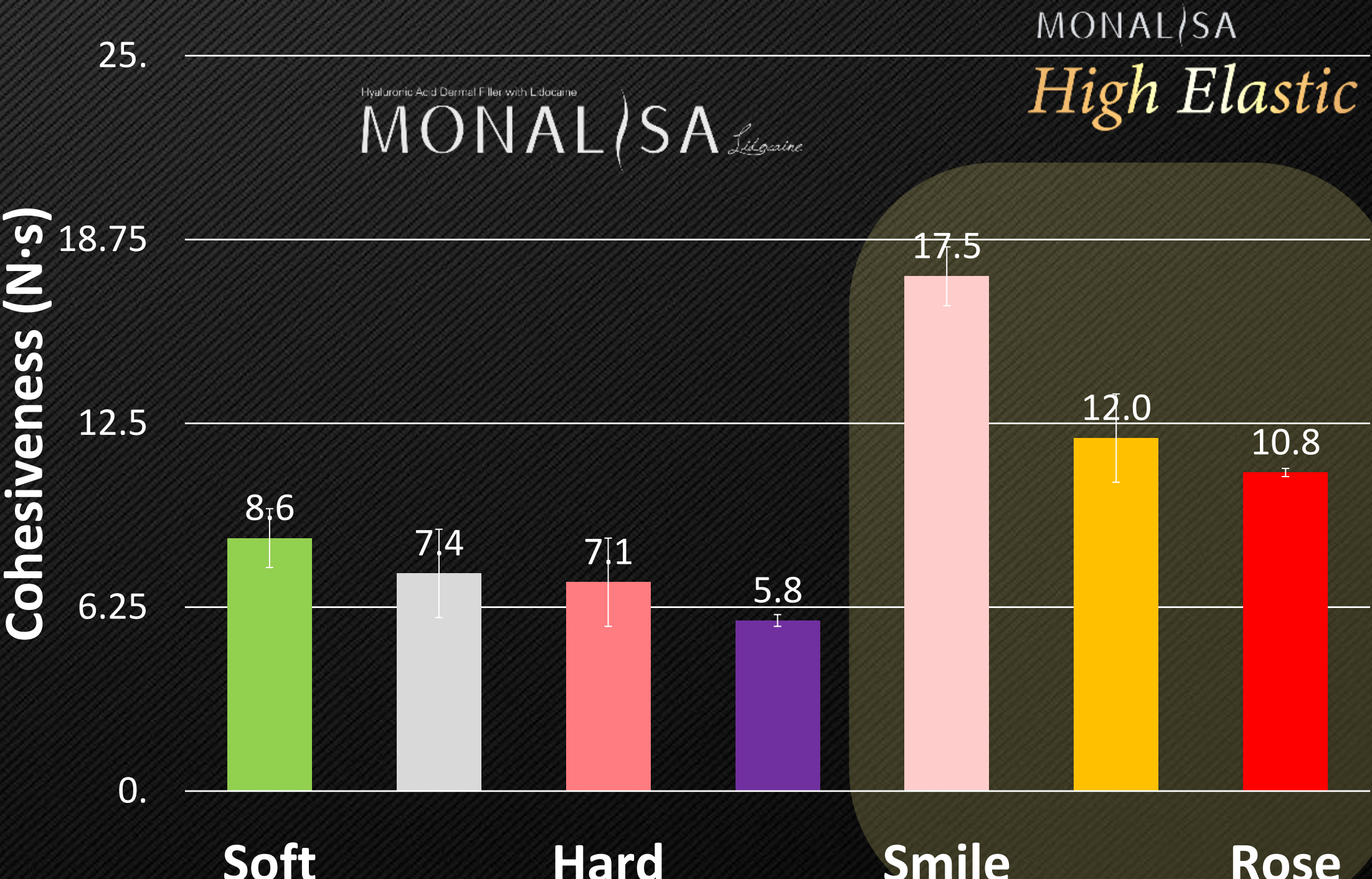
Toxin and filler, PDRN

MONALISA High Elastic

Elasticity

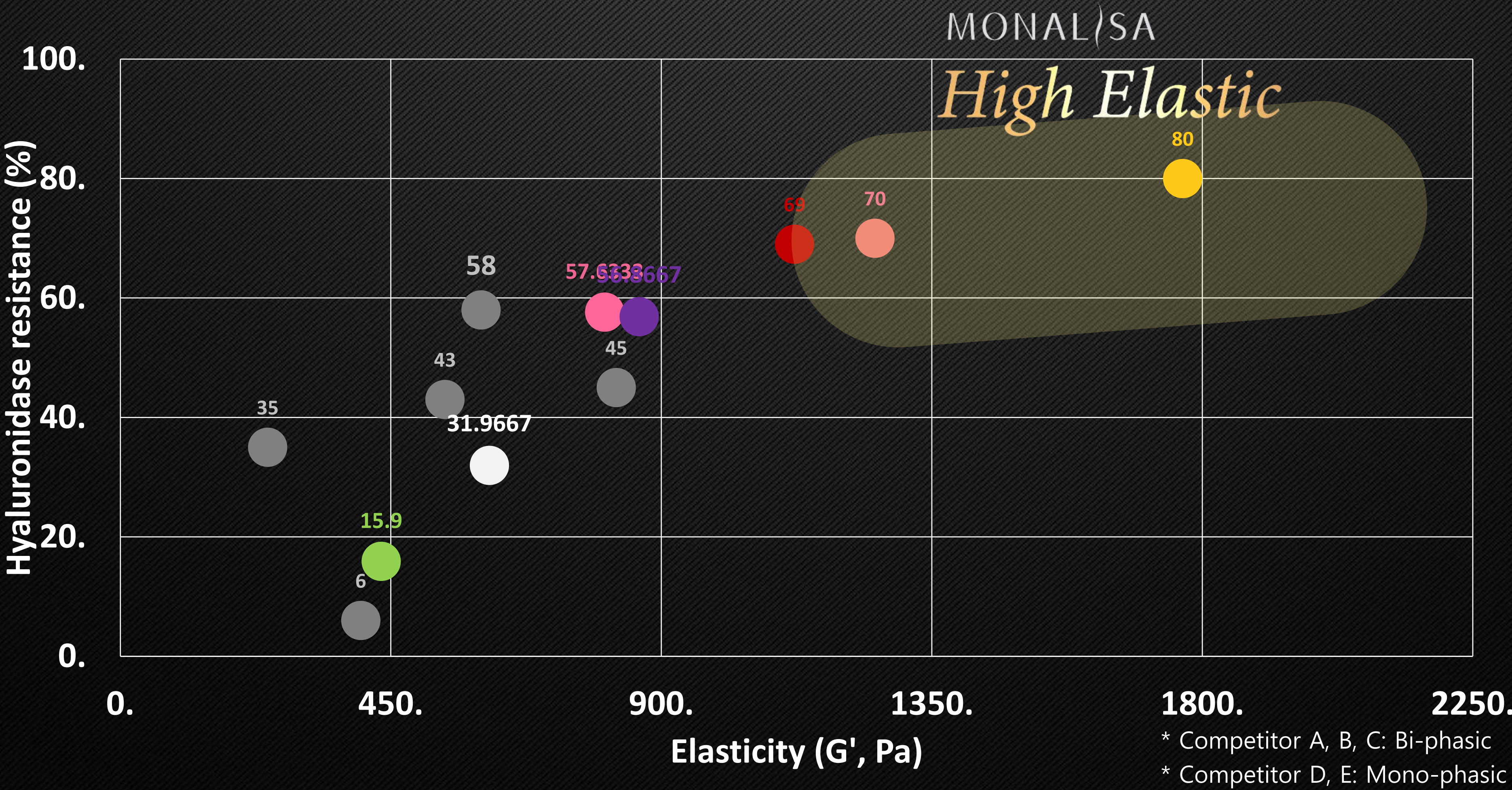


Cohesion

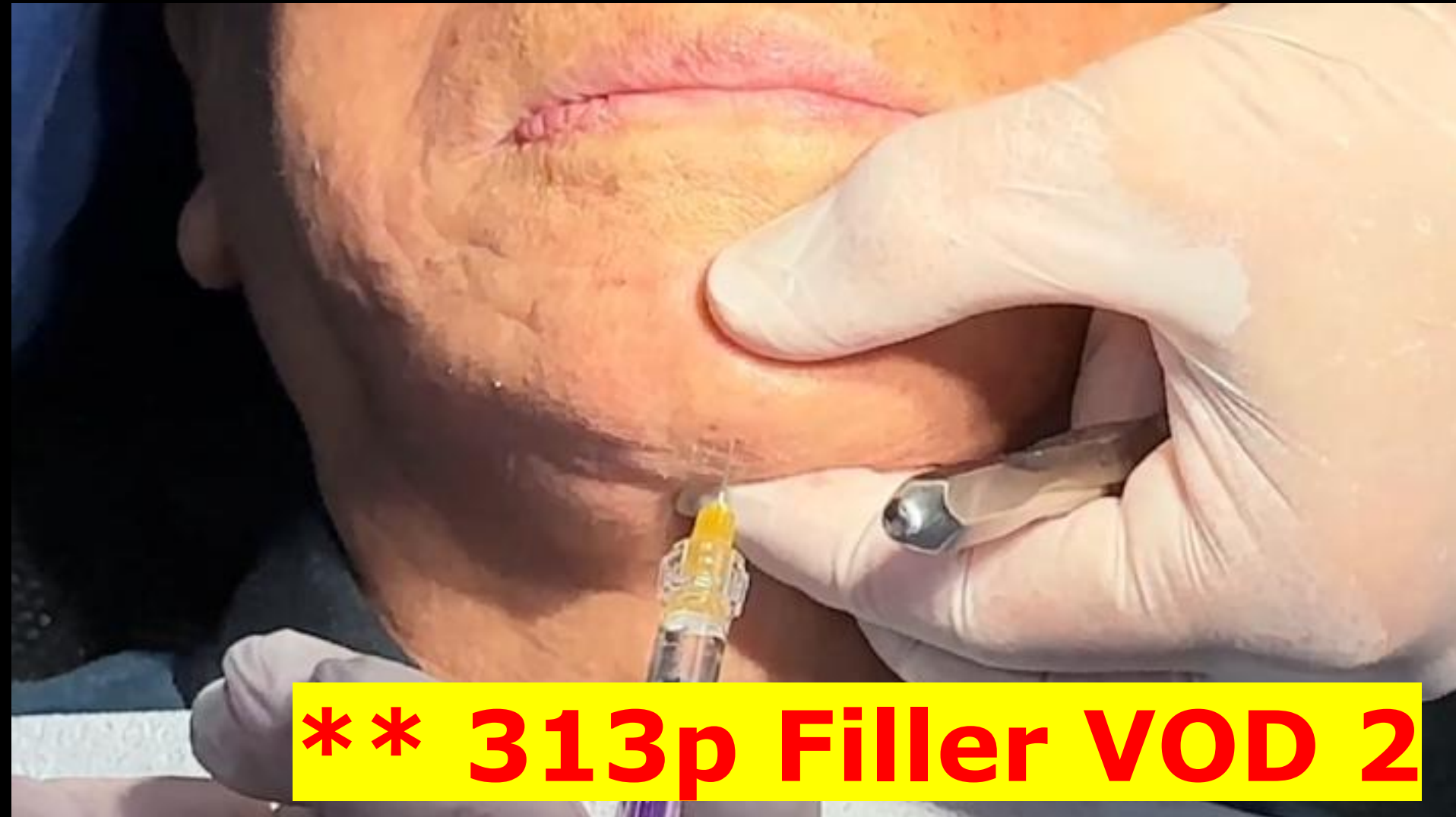

Comparison of physical properties with 5 third-party products

High elasticity and durability compared to other companies



How to “Filler & Toxin”? _ Treatment techniques

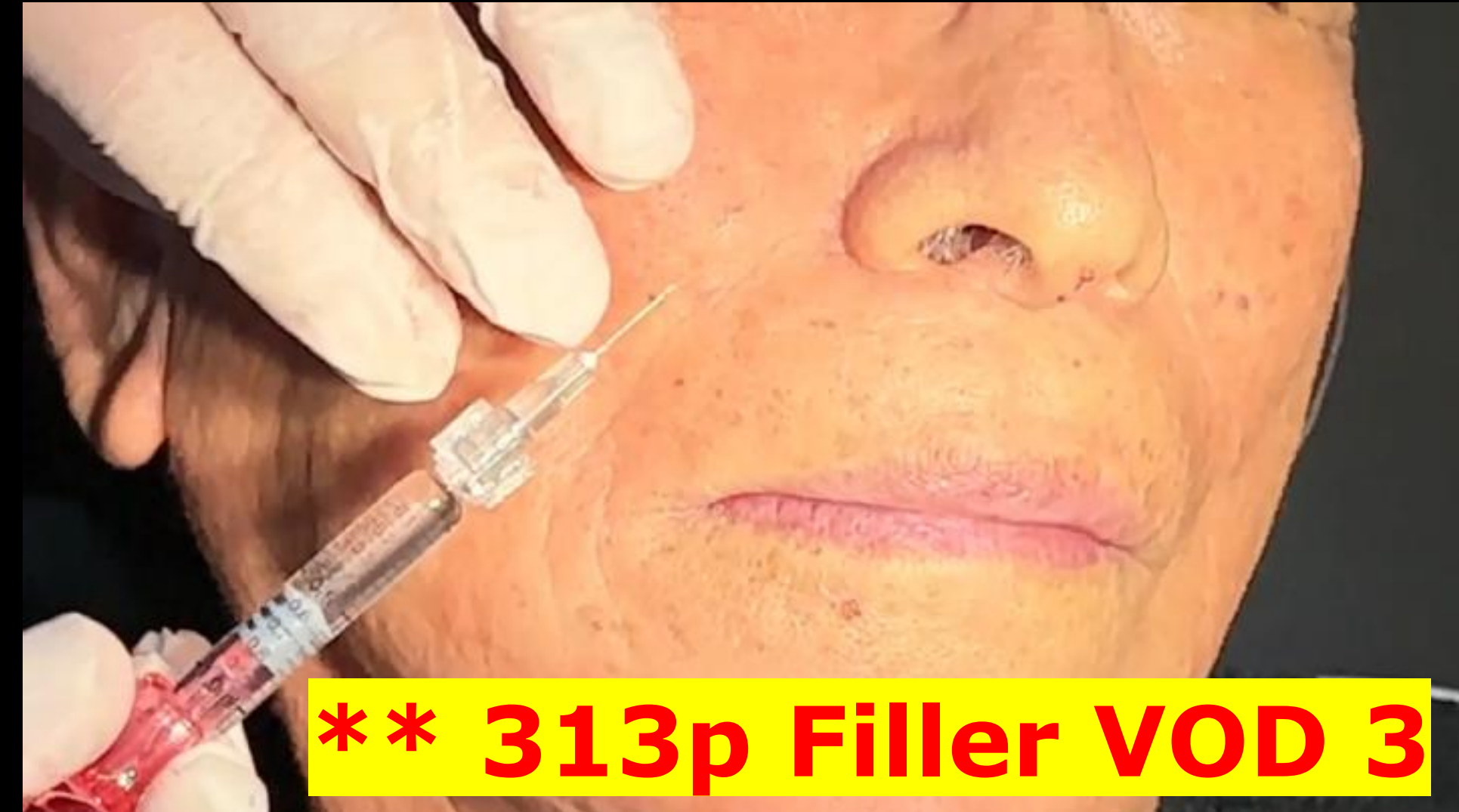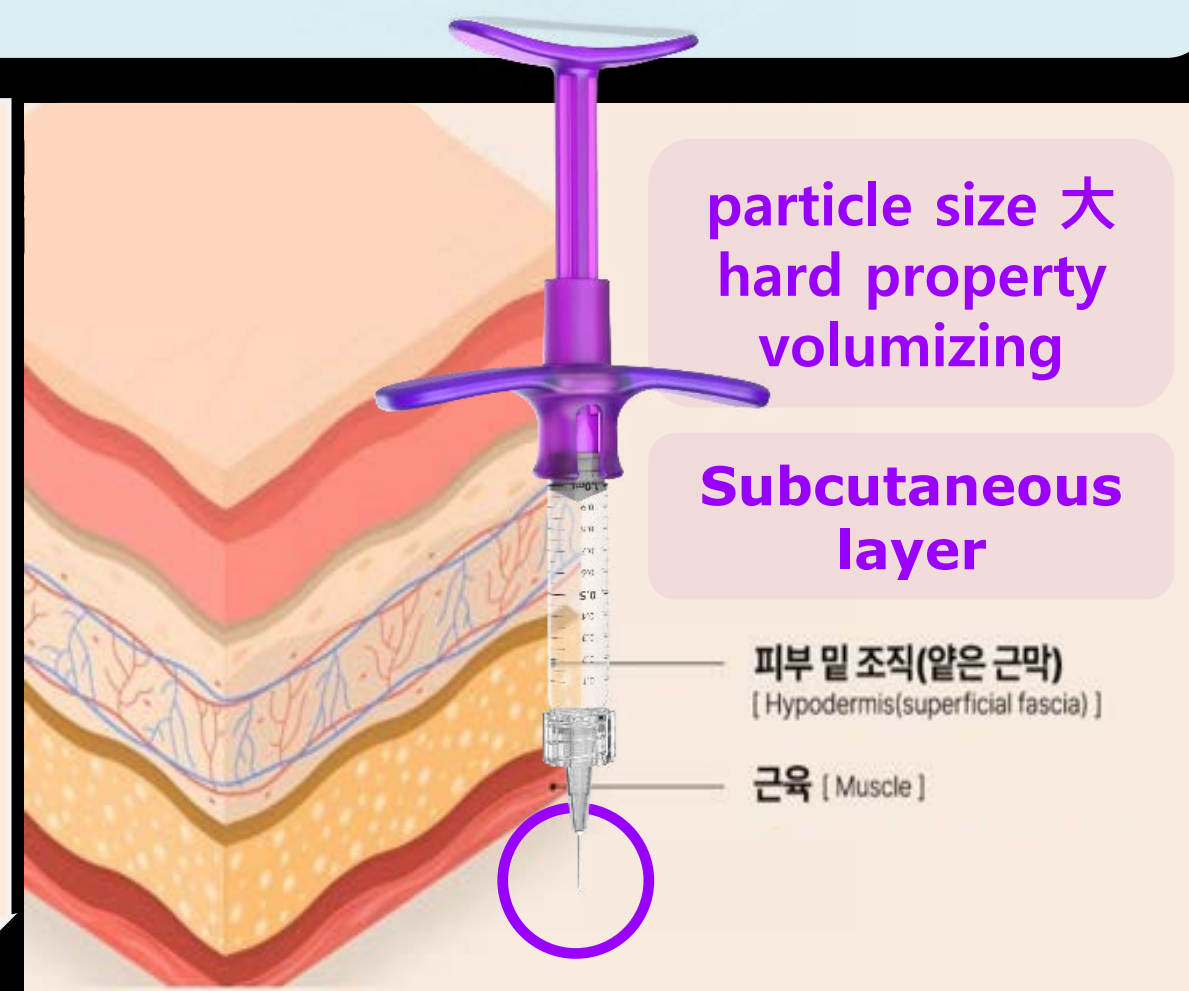


**** 313p Filler VOD 2**

Monalisa High Elastic Volume

Bone-contact technique

- Avoid anatomical hazards
- Minimize connective tissue damage
- Natural appearance
- Long-term stable

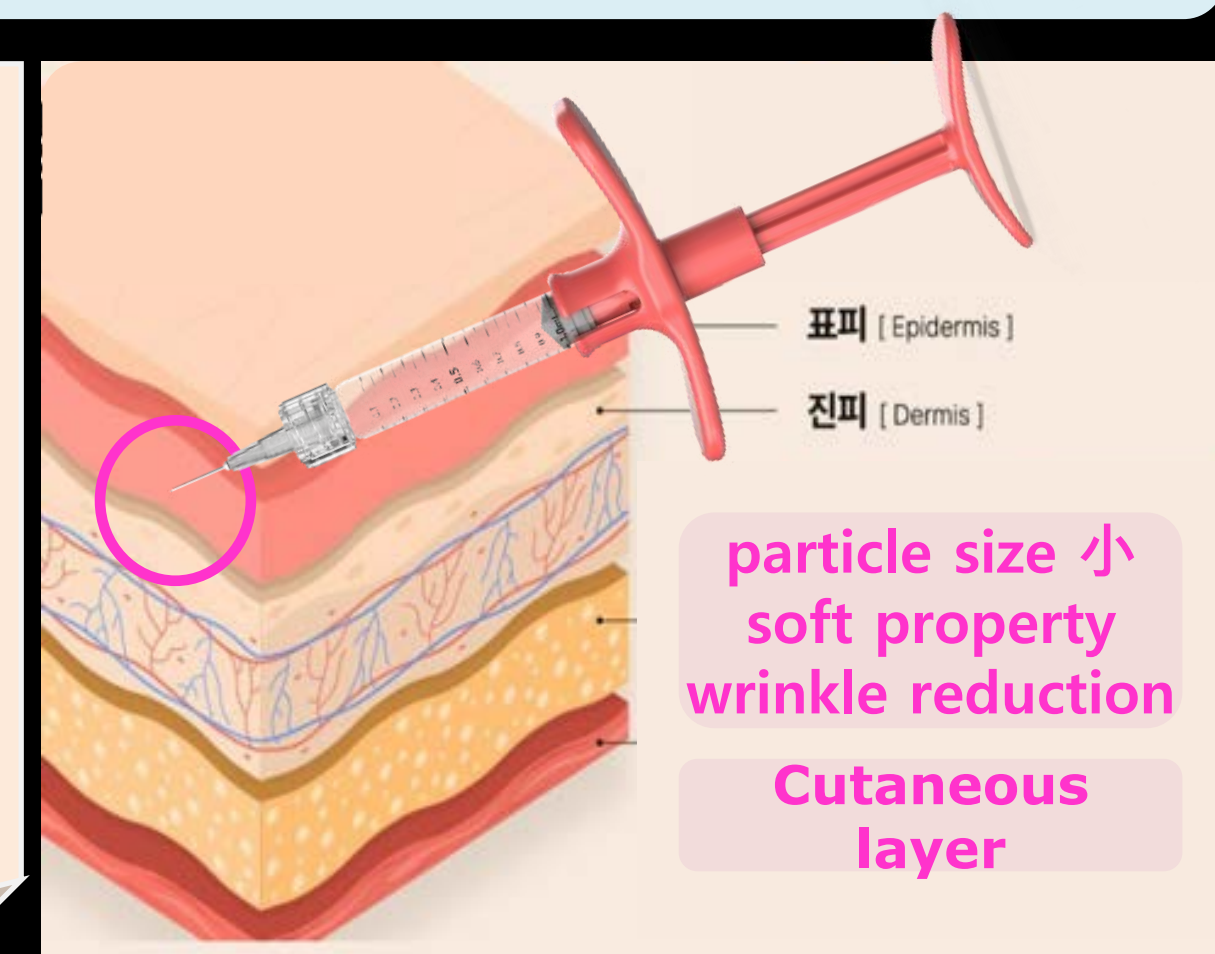


**** 313p Filler VOD 3**

Monalisa High Elastic Rose

Needle-up technique

- Intradermal angle (10~15°)
- On superficial layer
- Maintain smooth appearance
- Less invasiveness



Mental crease

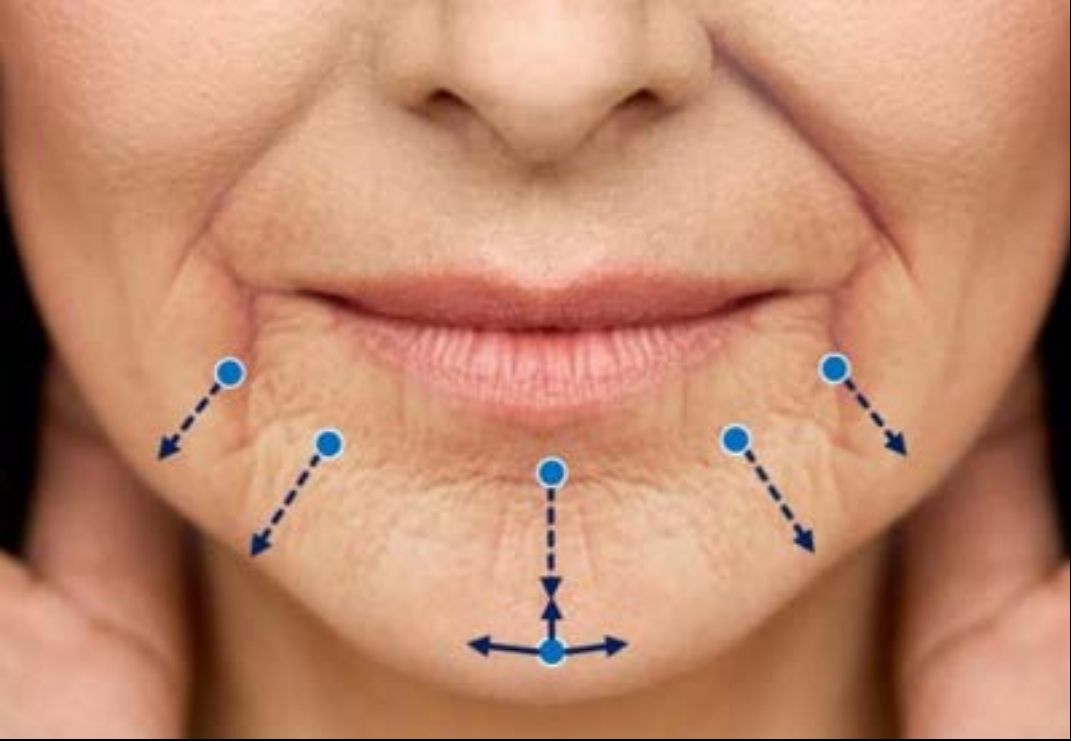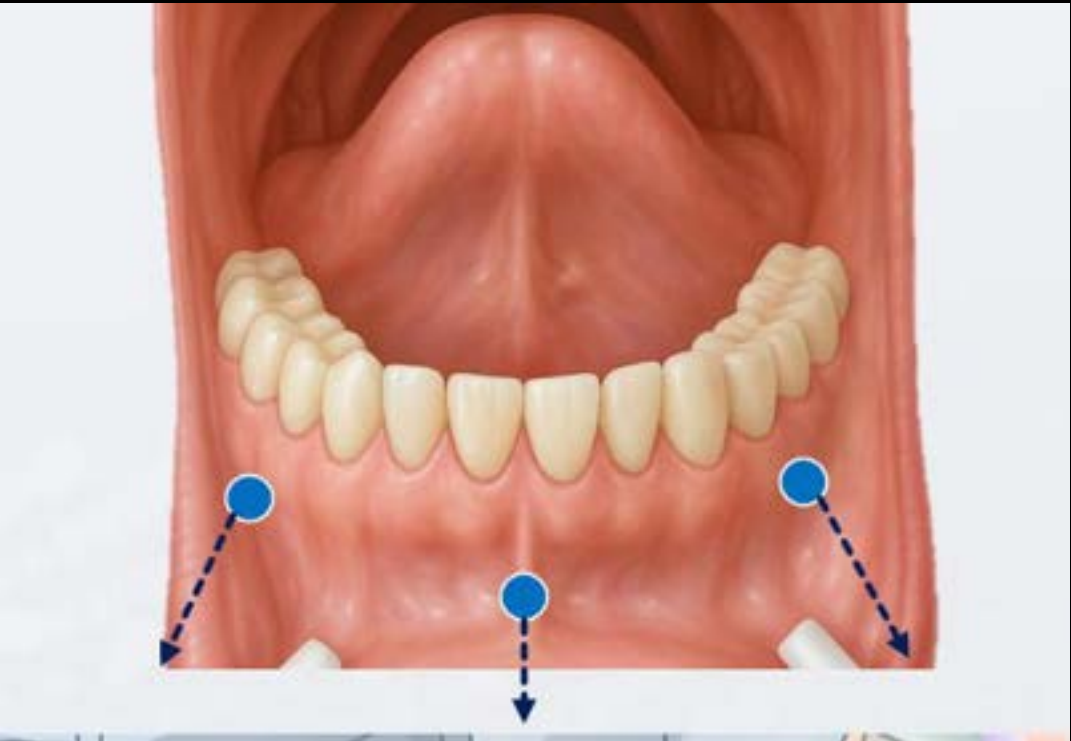

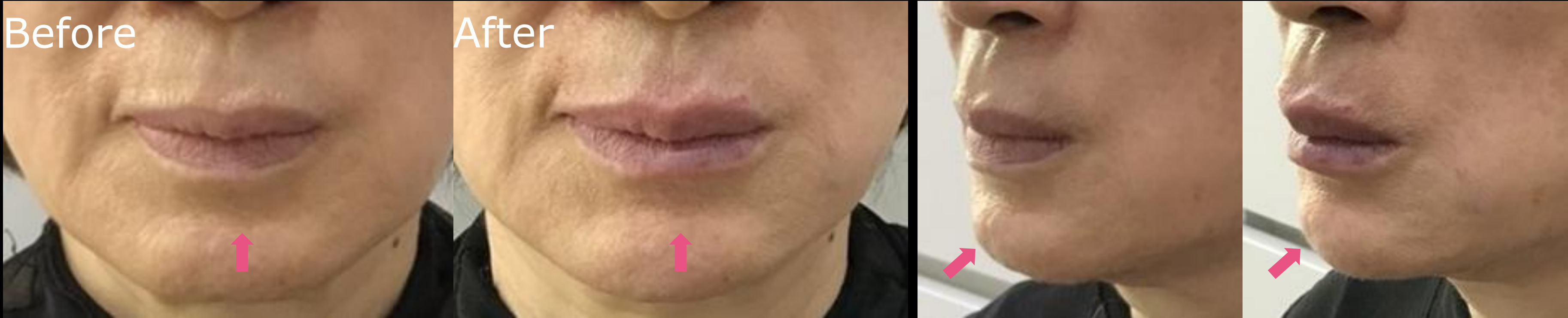
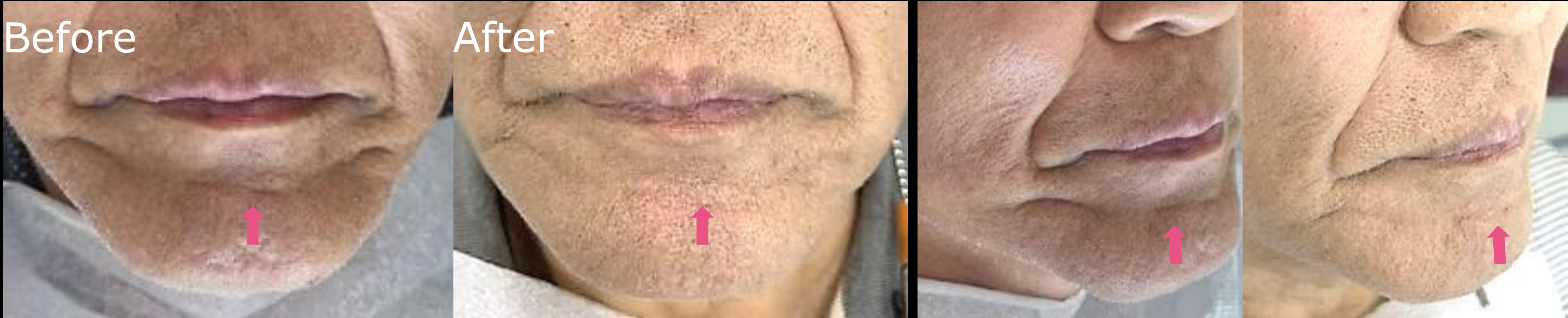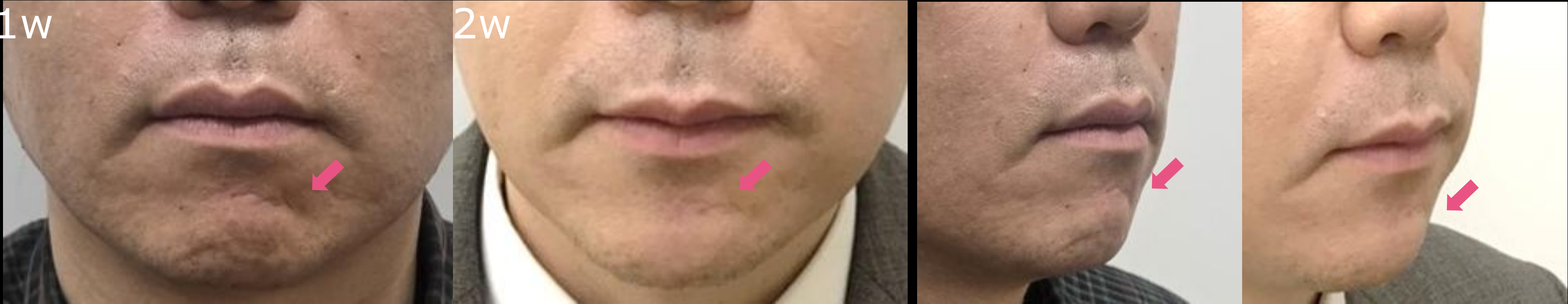Dentium

Application sites

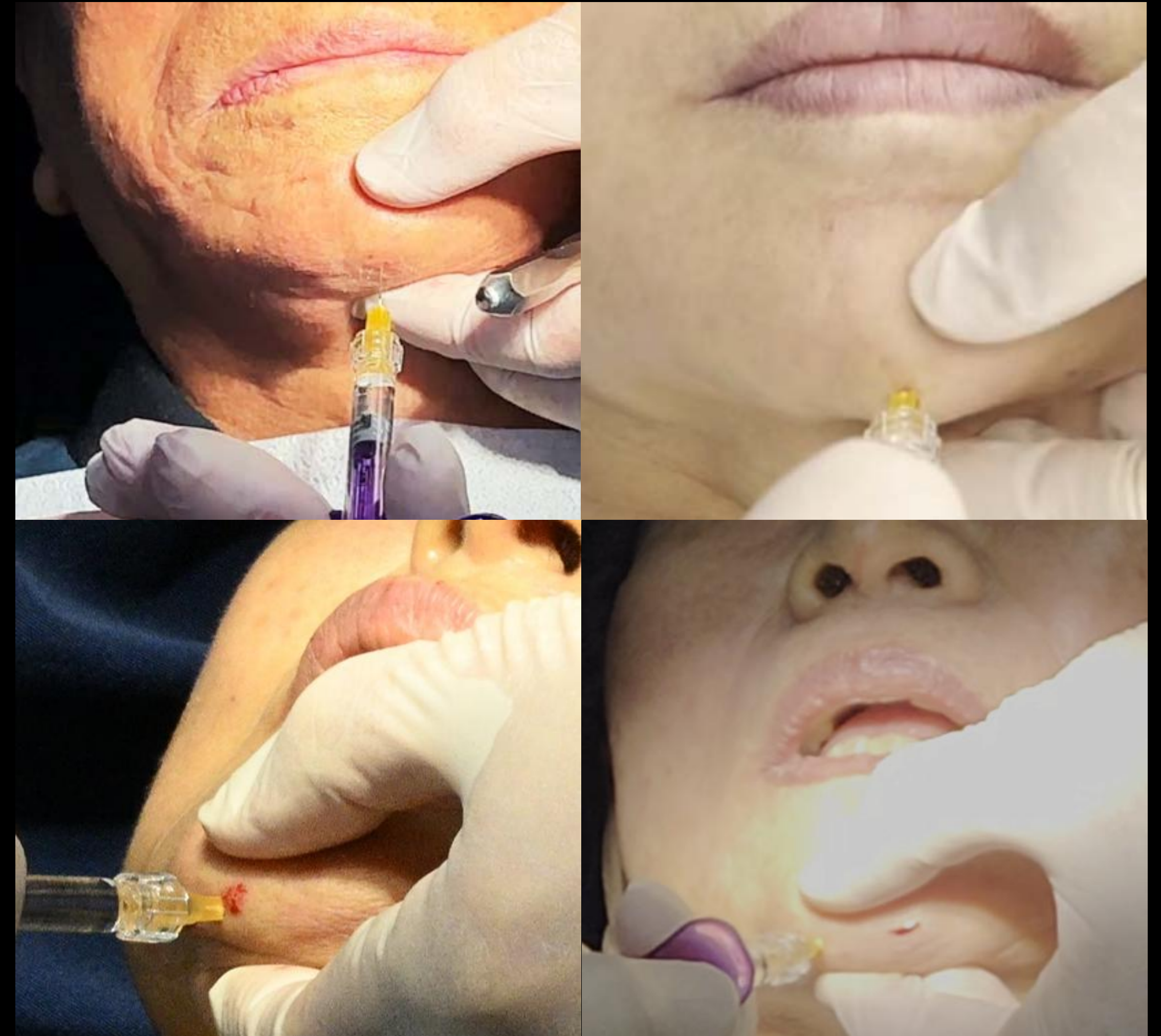Smile / Rose ↙

- Mental crease



Bone contact technique

- With jawline reconstruction for balanced profile
- Superficial injection, ~2 cc total
- linear threading along contour



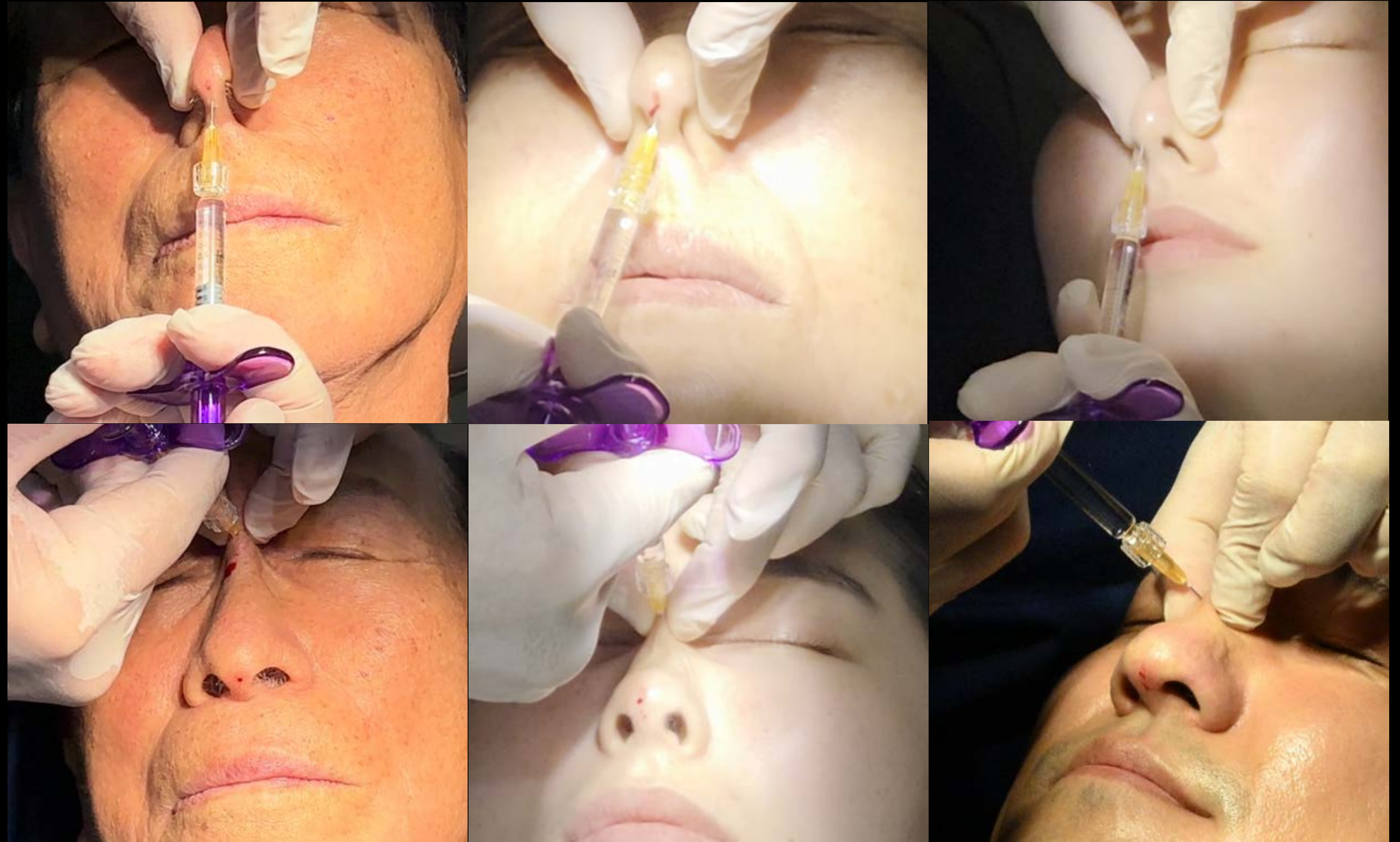Nasal contour

Dentium








Dorsum: bone contact on nasal bone, linear threading

Tip: intraoral or perioral approach, small bolus injection

Caution: avoid vascular compromise (dorsal nasal artery)










Injection point & recommended dose _ HA Filler Dentium

Tx Plan	Intraoral	Perioral					
<div>✓ Volume shrinkage</div> <div>✓ Gingival recession</div> <div>✓ Marionette wrinkle</div> <div>✓ Facial contour</div>							
	Nasolabial folds & Marionette lines	Nasolabial folds & Marionette lines	Nose dorsum	Nose tip	Forehead & Frown line	Lip contour	Chin contour
	<div>✓ Bone contact on buccal apex</div> <div>✓ Canine fossa pressure</div>	<div>✓ Superficial injection</div> <div>✓ 3~5mm upwards from nasolabial folds</div> <div>✓ 0.5-1cc</div>	<div>✓ Bone contact on nasal bone</div>	<div>✓ Both intraoral and perioral approach are achievable</div>	<div>✓ Bone contact on frontal sinus</div> <div>✓ On depressed volume</div>	<div>✓ Subdermal injection</div>	<div>✓ With jawline reconstruction</div> <div>✓ Superficial injection</div> <div>✓ 2cc</div>
	MONALISA High Elastic Volume	MONALISA High Elastic Volume	MONALISA High Elastic Volume	MONALISA High Elastic Volume	MONALISA High Elastic Rose	MONALISA High Elastic Rose	MONALISA High Elastic Volume

Injection point & recommended dose _ Toxin

Dentium

Tx Plan	Intraoral	Perioral					
<div><div>✓ VD reconstruction (4~5mm)</div><div>✓ TMD</div><div>✓ Bruxism</div><div>✓ Habitual clenching</div><div>✓ CR adaptation after orthodontic treatment</div><div>✓ Wrinkles and folds</div></div>							
	Lateral pterygoid	Masseter	SCM (sternocleidomastoid)	Temporalis	Depressor anguli oris	Mentalis	Procerus
	<div><div>✓ Palpation on bucco-apex area of 3rd molar</div><div>✓ Induce the patient to clench</div></div>	<div><div>✓ Male : 40 unit</div><div>✓ Female : 20 unit</div><div>✓ Palpation & inducing the patient to clench</div></div>	<div><div>✓ 10 unit</div><div>✓ On superior aspect of SCM</div></div>	<div><div>✓ 5 unit</div><div>✓ Palpation & inducing the patient to clench</div></div>	<div><div>✓ Prior to HA filler injection</div></div>	<div><div>✓ 2–5 units per side (total 4–10 units)</div></div>	<div><div>✓ 4–8 units at frown-line</div></div>

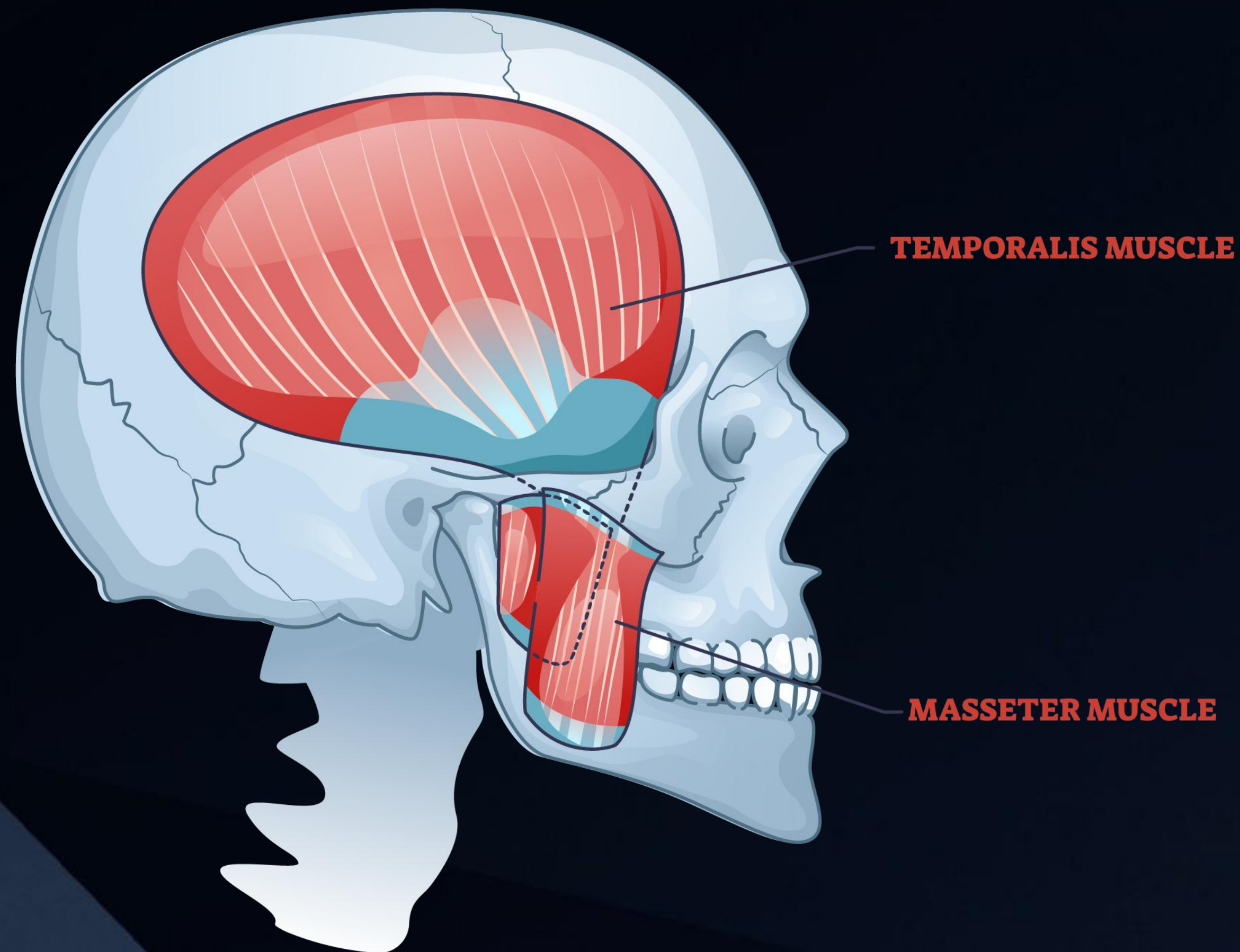
PDRN injection into TMJ

TMJ problem patients - sound, displacement, dislocation and resorption

Clinically not yet proven but effective due to strong anti-inflammatory
and regenerative effects

Why Filler and Botox?

Botox



Traditionally focused
on jaw-closing muscles

Limited to the masseter and
temporalis muscles

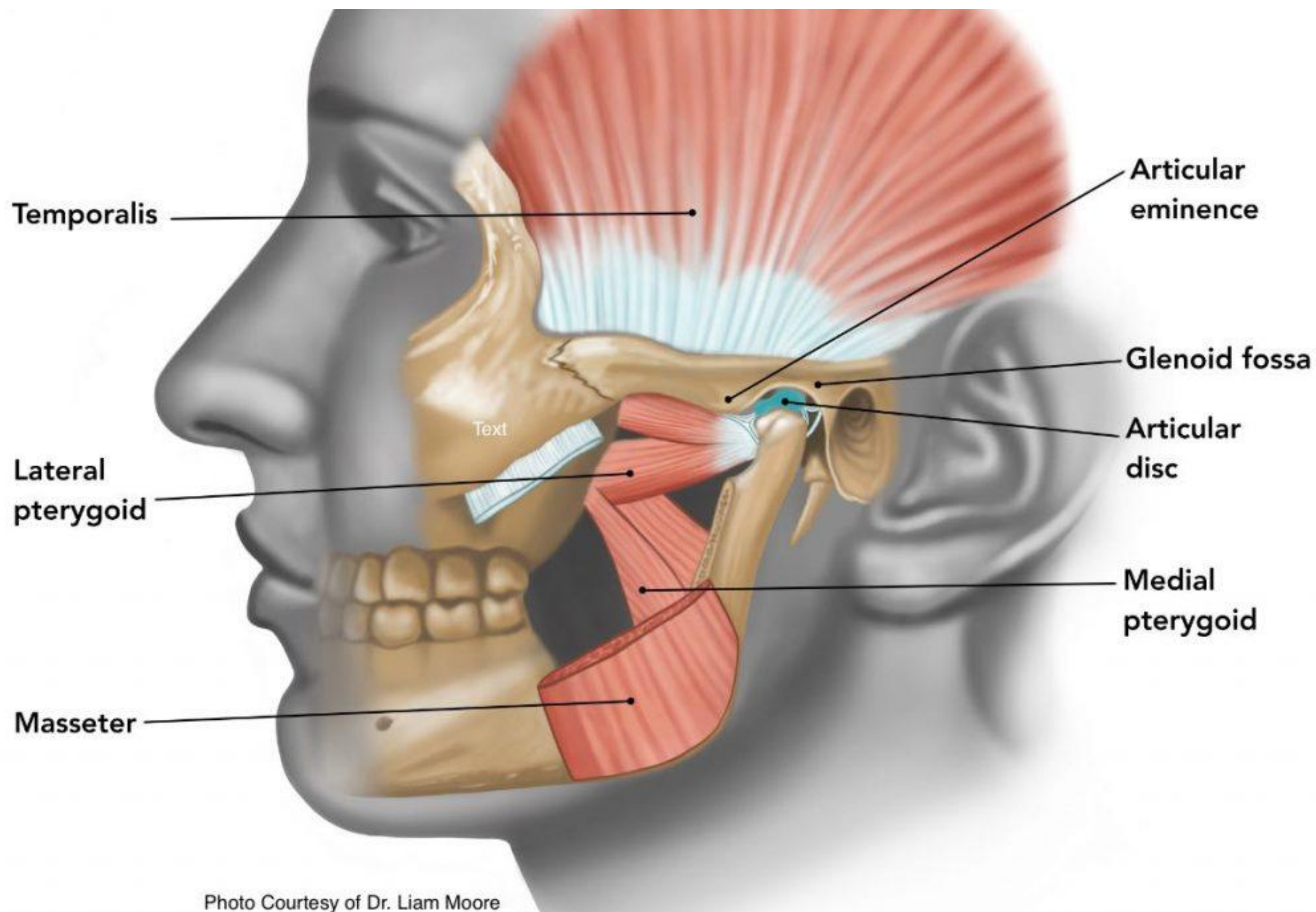
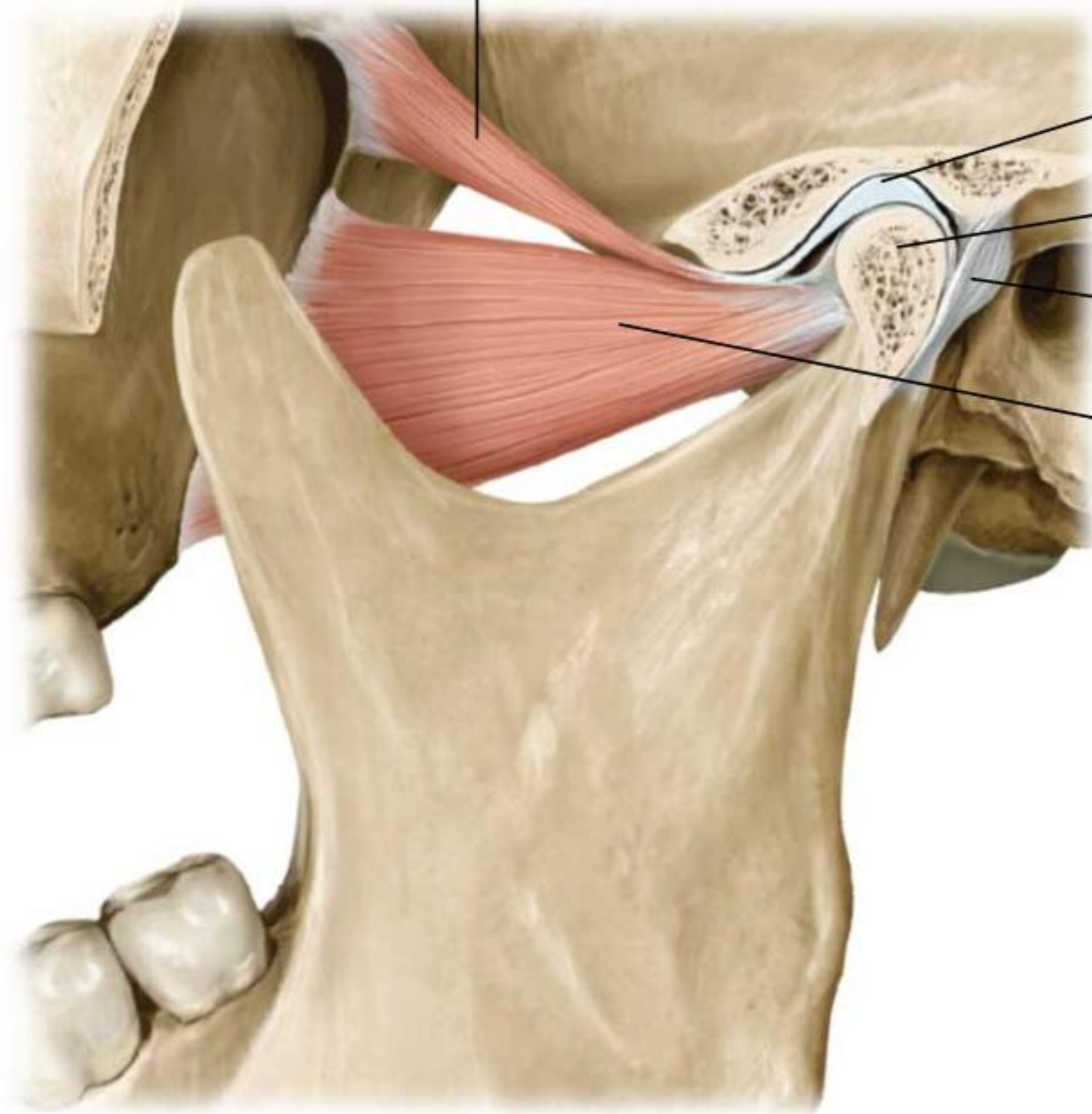


Photo Courtesy of Dr. Liam Moore

Lateral pterygoid muscle,
superior head



Articular disk

Head of mandible

Joint capsule

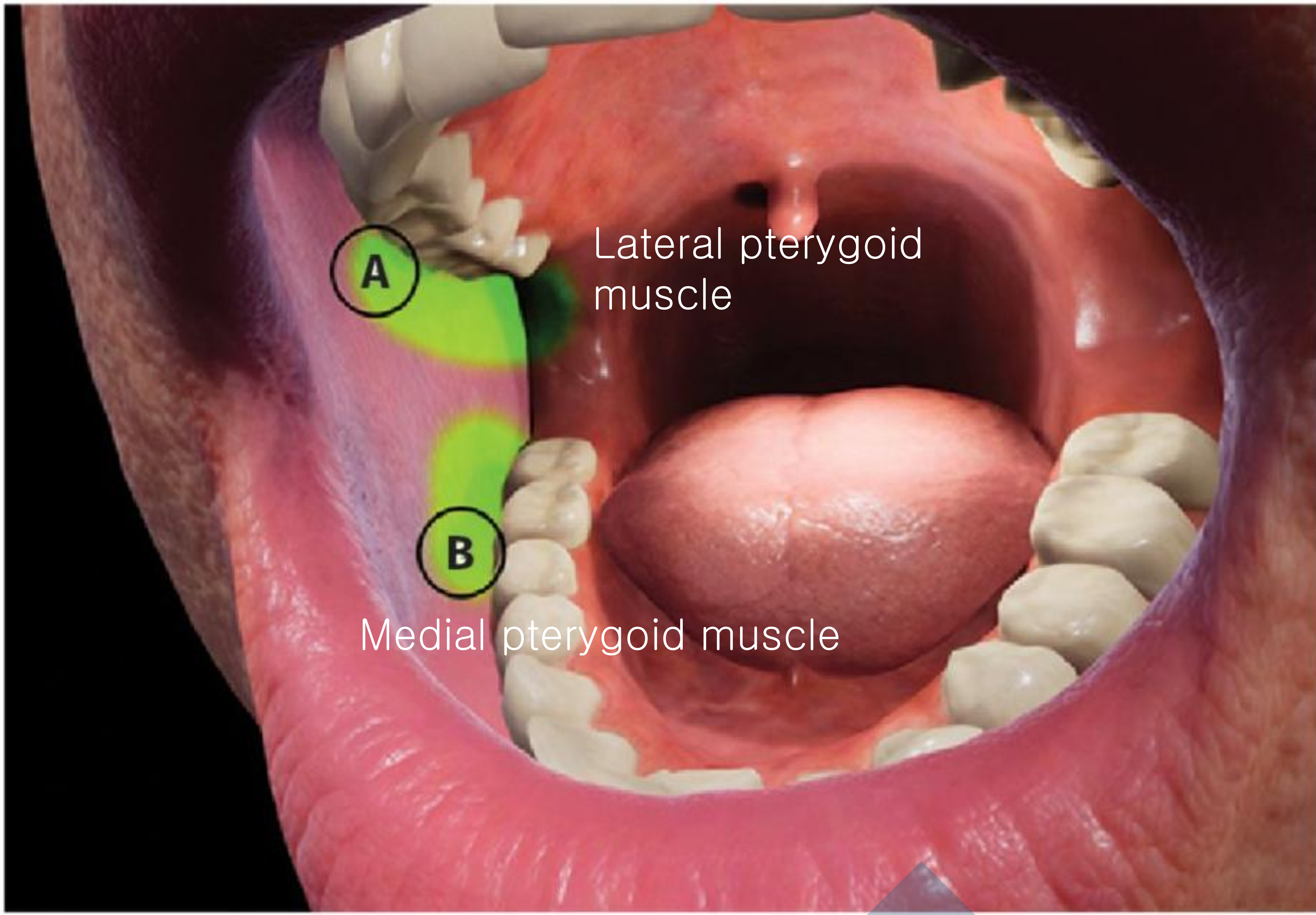
Lateral pterygoid
muscle,
inferior head

A

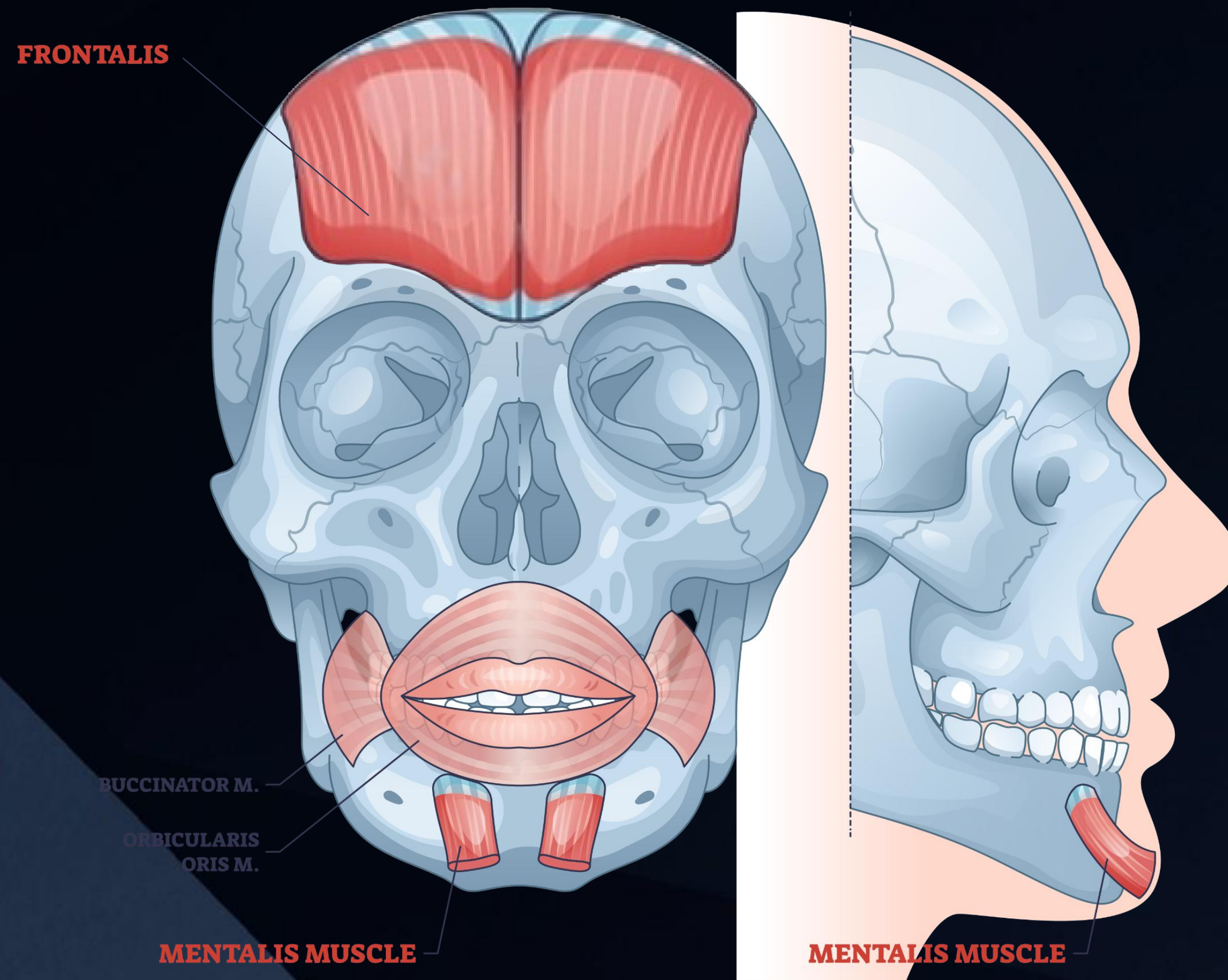
Lateral pterygoid muscle

B

Medial pterygoid muscle



Botox



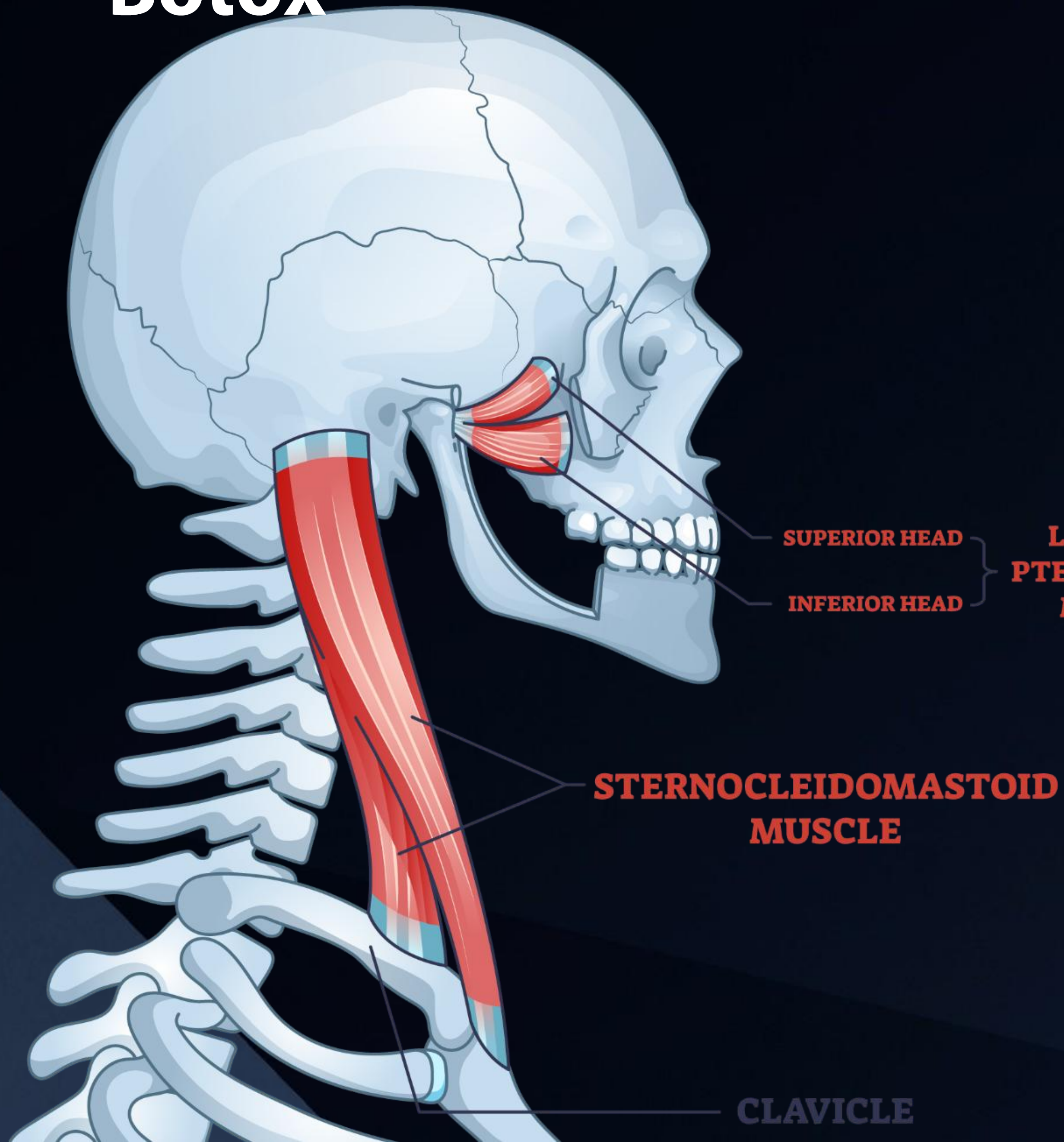
Glabellar and forehead line correction aimed at balanced brow and forehead harmony

Reducing dynamic wrinkles and puckering in the chin area

Botox

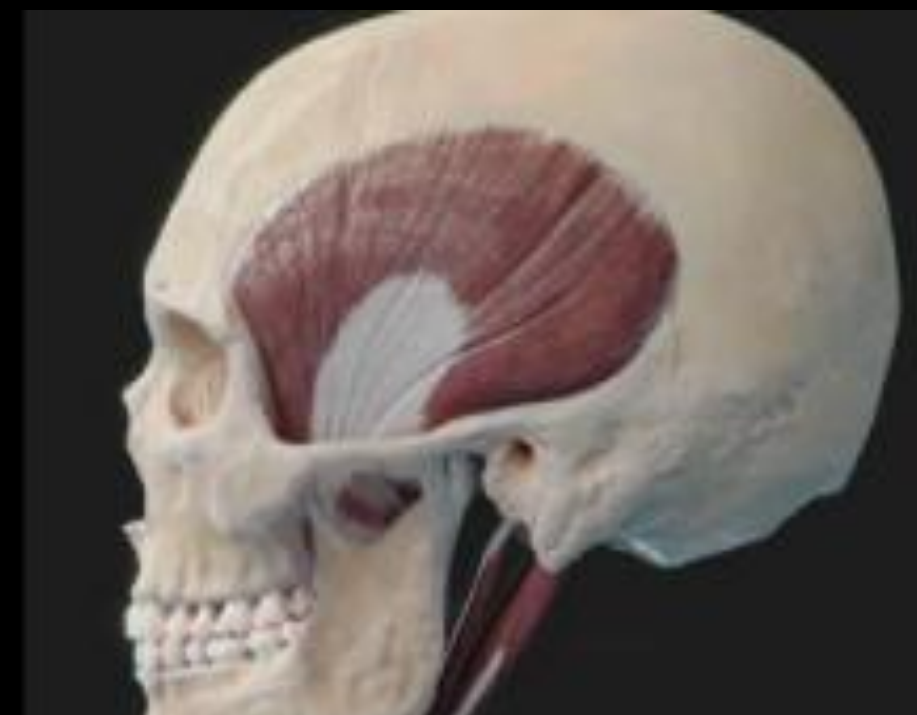Expanded to include
External pterygoid muscle
and **Sternocleidomastoid muscle**

Presenting various clinical options
for temporomandibular and
neck muscle disorders



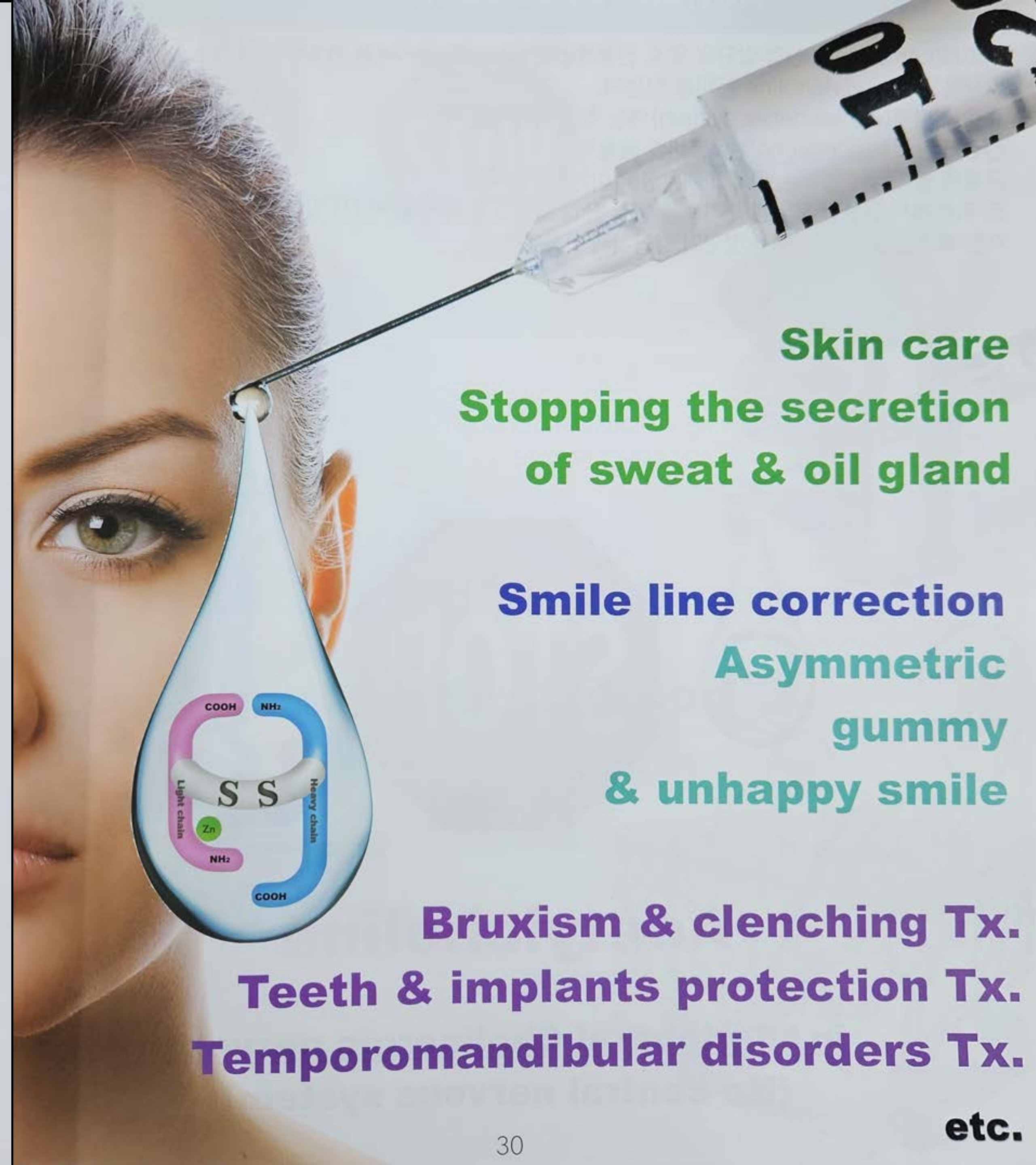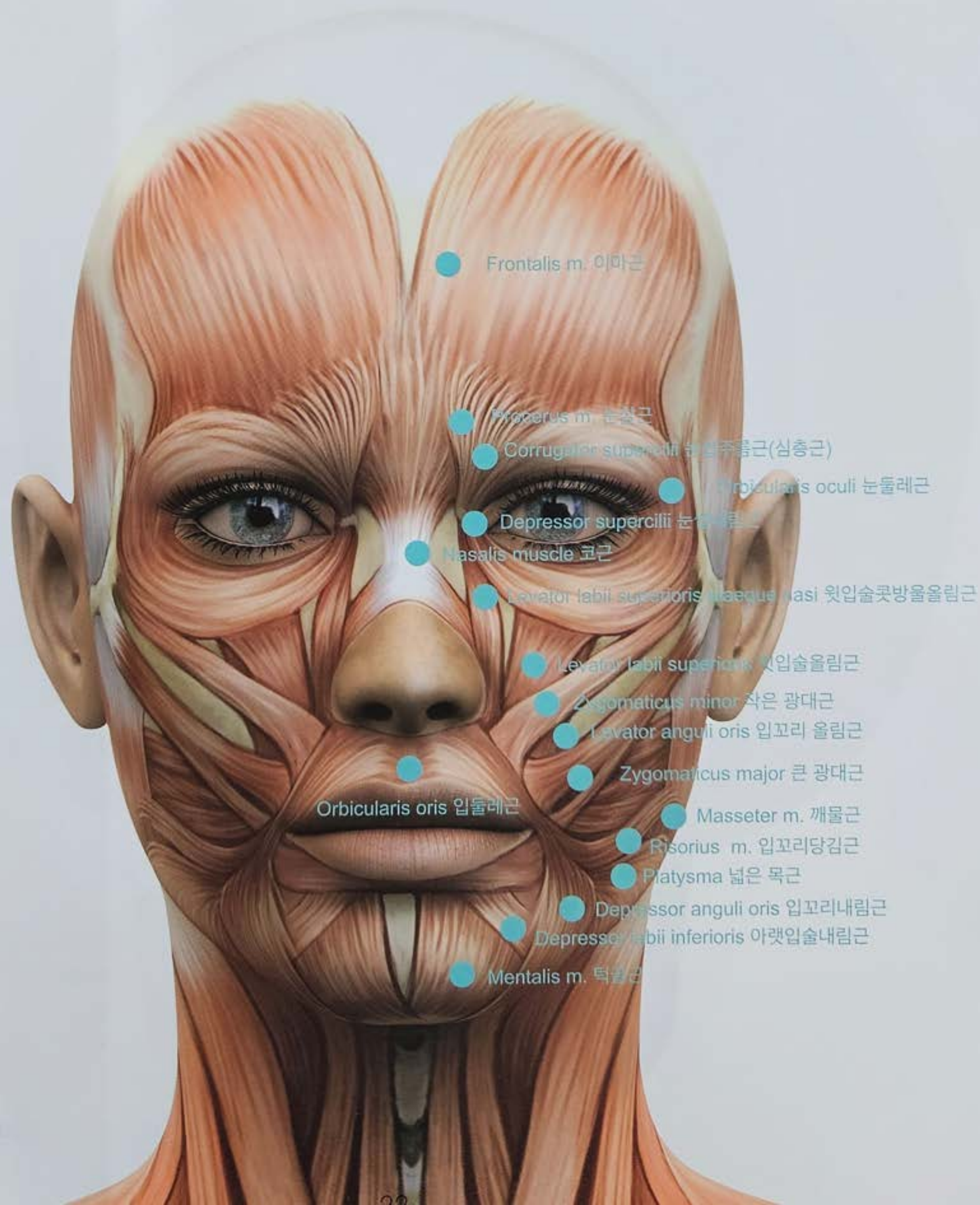
Botulinum toxin injection & Jaw management

Dentium d
SM Chung



**** 327p TMJ PDRN VOD 2,3**

Facial muscles



Skin care
Stopping the secretion
of sweat & oil gland

Smile line correction
Asymmetric
gummy
& unhappy smile

Bruxism & clenching Tx.
Teeth & implants protection Tx.
Temporomandibular disorders Tx.

etc.

Why *at now* Filler ?

Aged person wrinkle



Dermal filler

It improves the shape of the face by increasing volume and smoothing it out. It fills in gaps caused by age or accidents.

Derma filler

Increase soft-tissue volume to improve and soften facial contours

Filling spaces created by aging, trauma, or other causes of volume loss

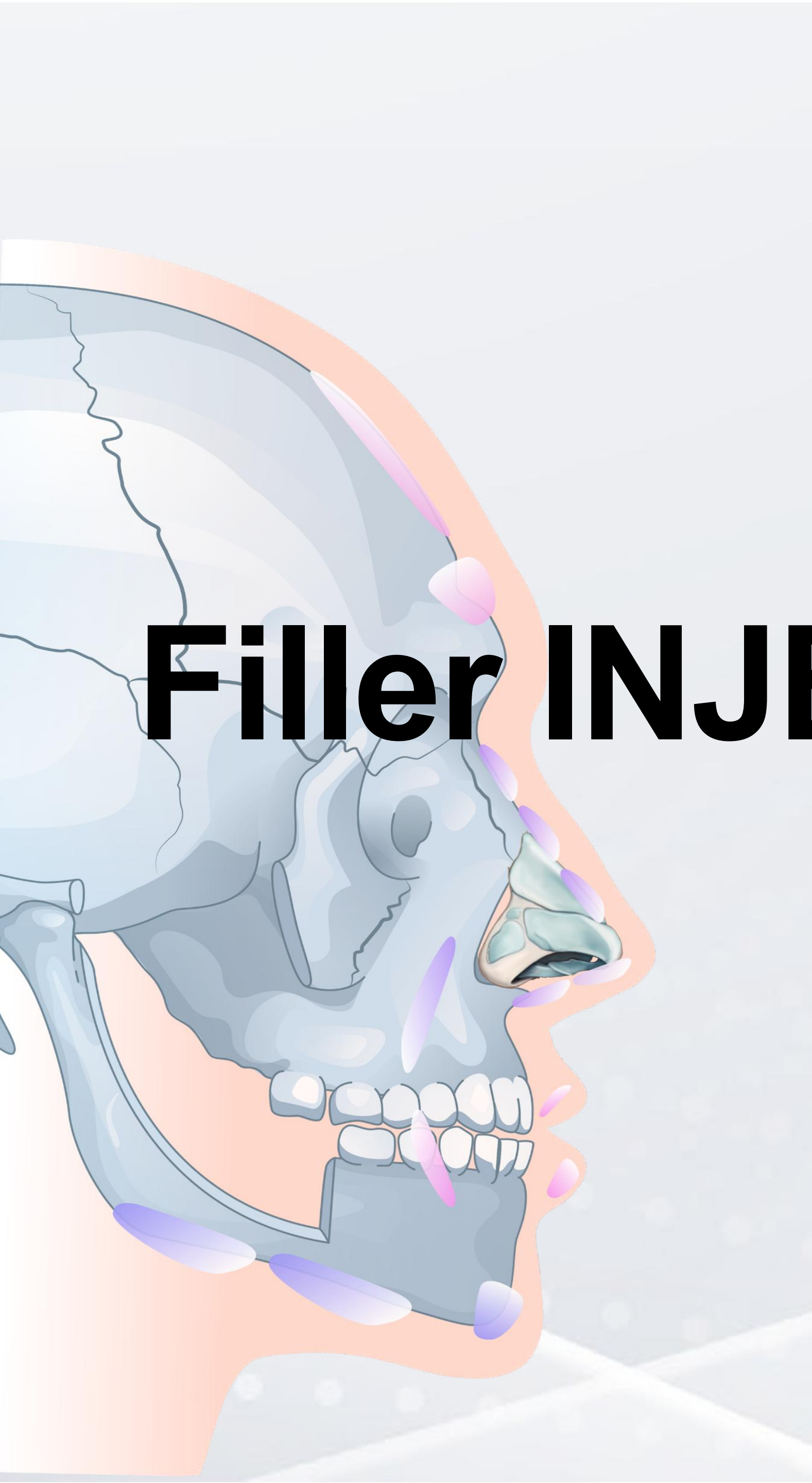
Types of fillers

Hyaluronic acid - 6 to 18months

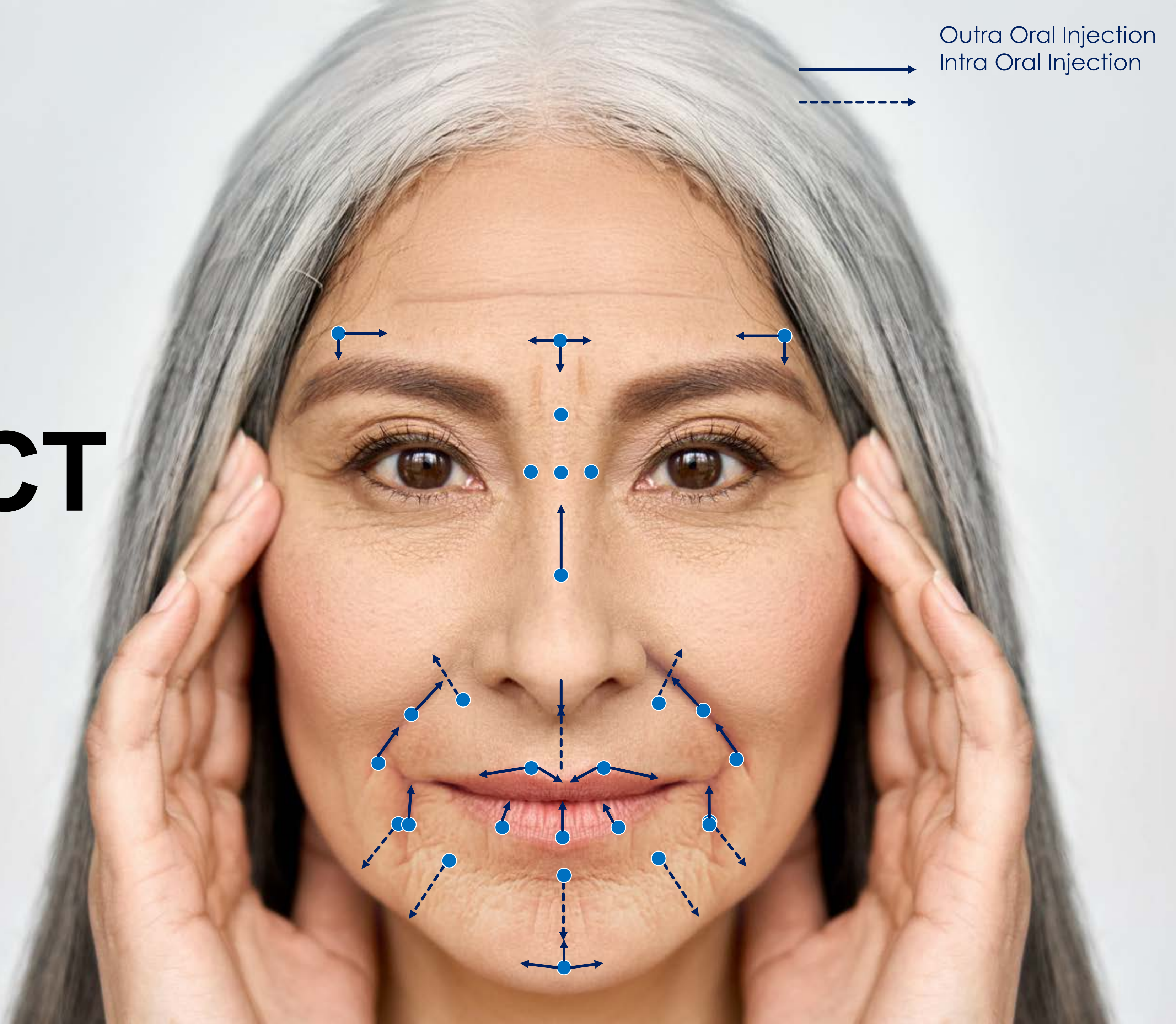
CaHA - 12 to 18months

PLLA - over 2 years

PCL



Filler INJECT



Outra Oral Injection
Intra Oral Injection

Hyaluronic Acid Dermal Filler

MONALISA

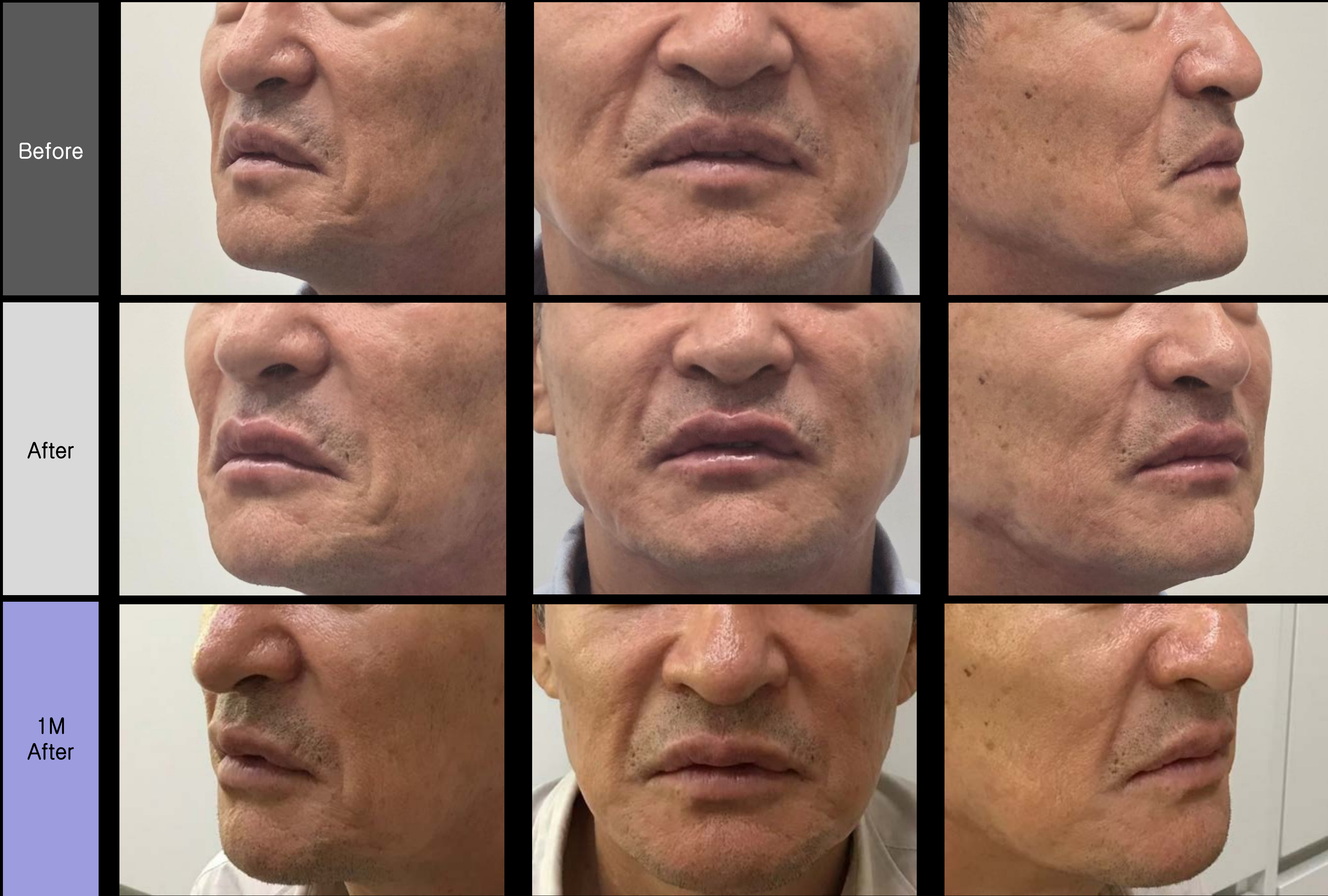Long-term Volume Up

Dentium Dental Clinic
Dr. SM Chung



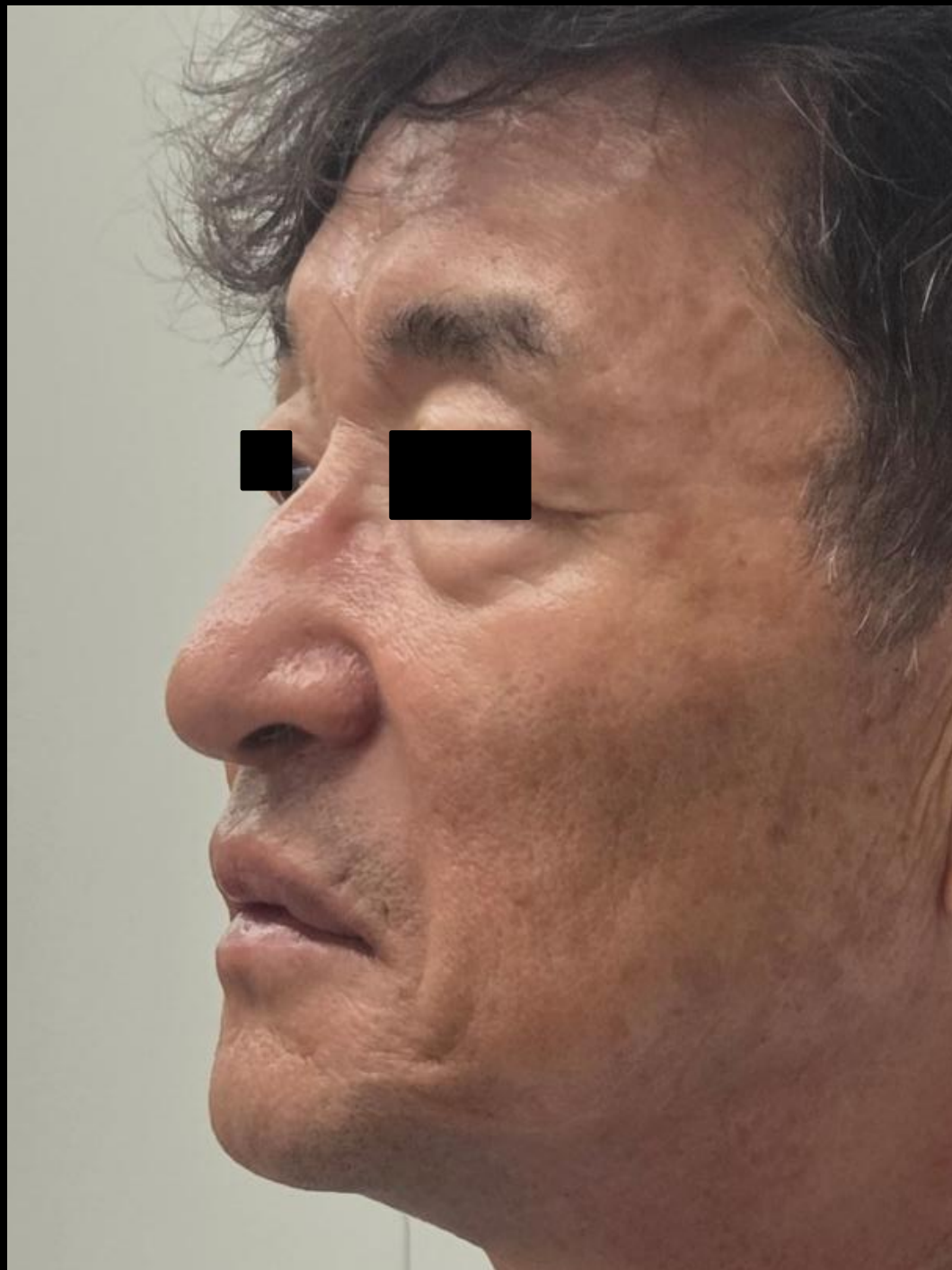**** 334p Filler VOD 4**

Clinical case : Lip, Chin, Nasolabial fold

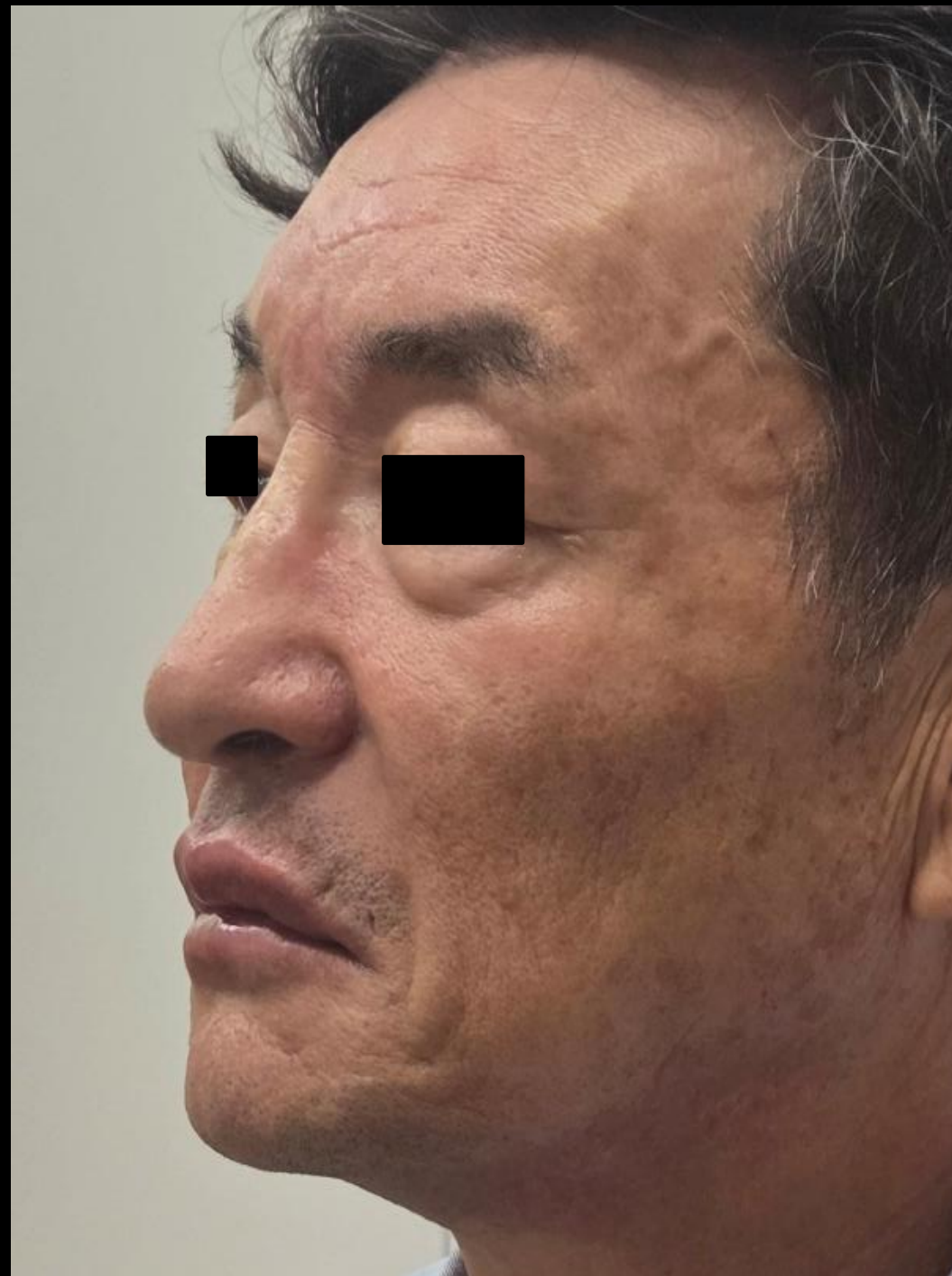

The left side

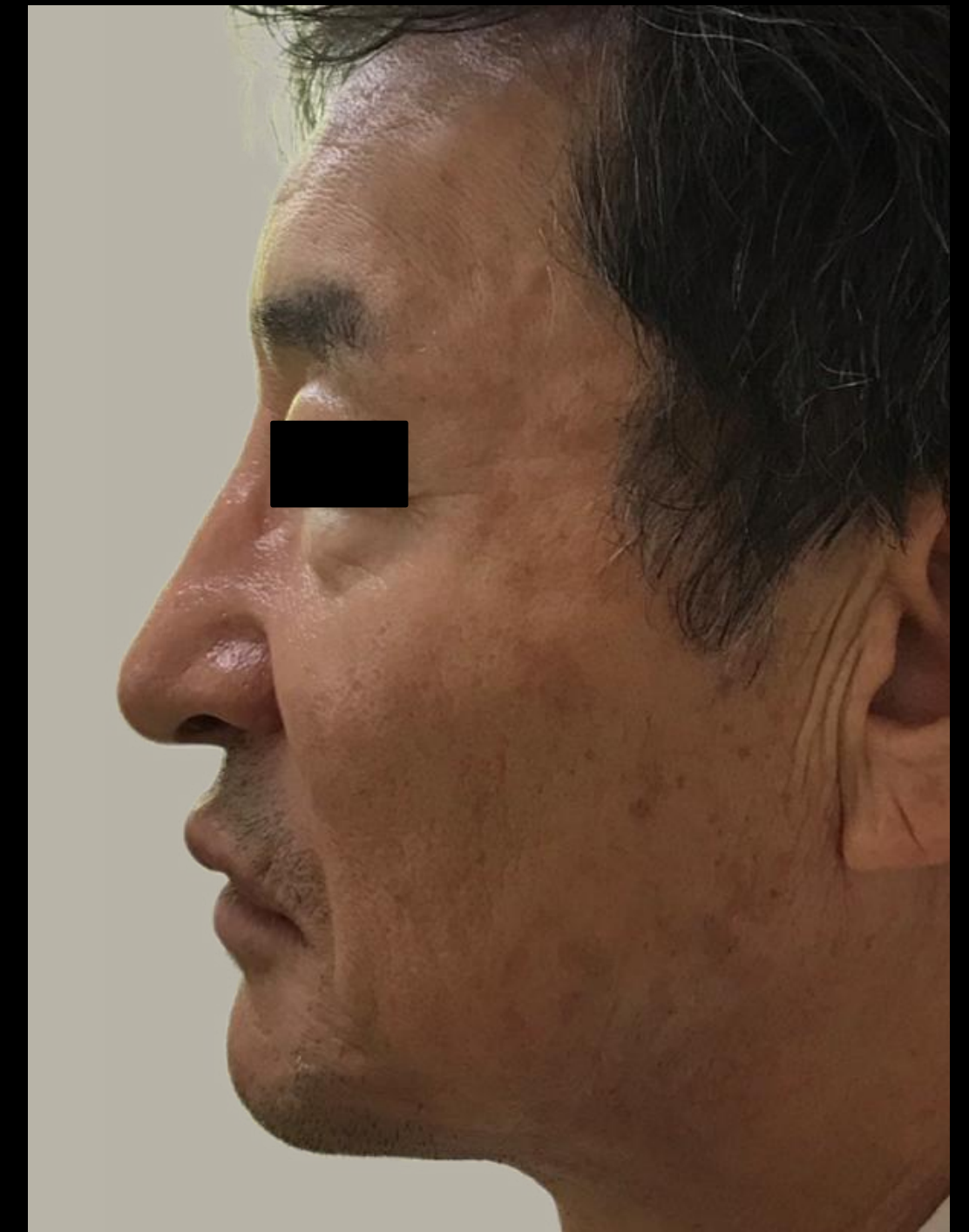Before



After

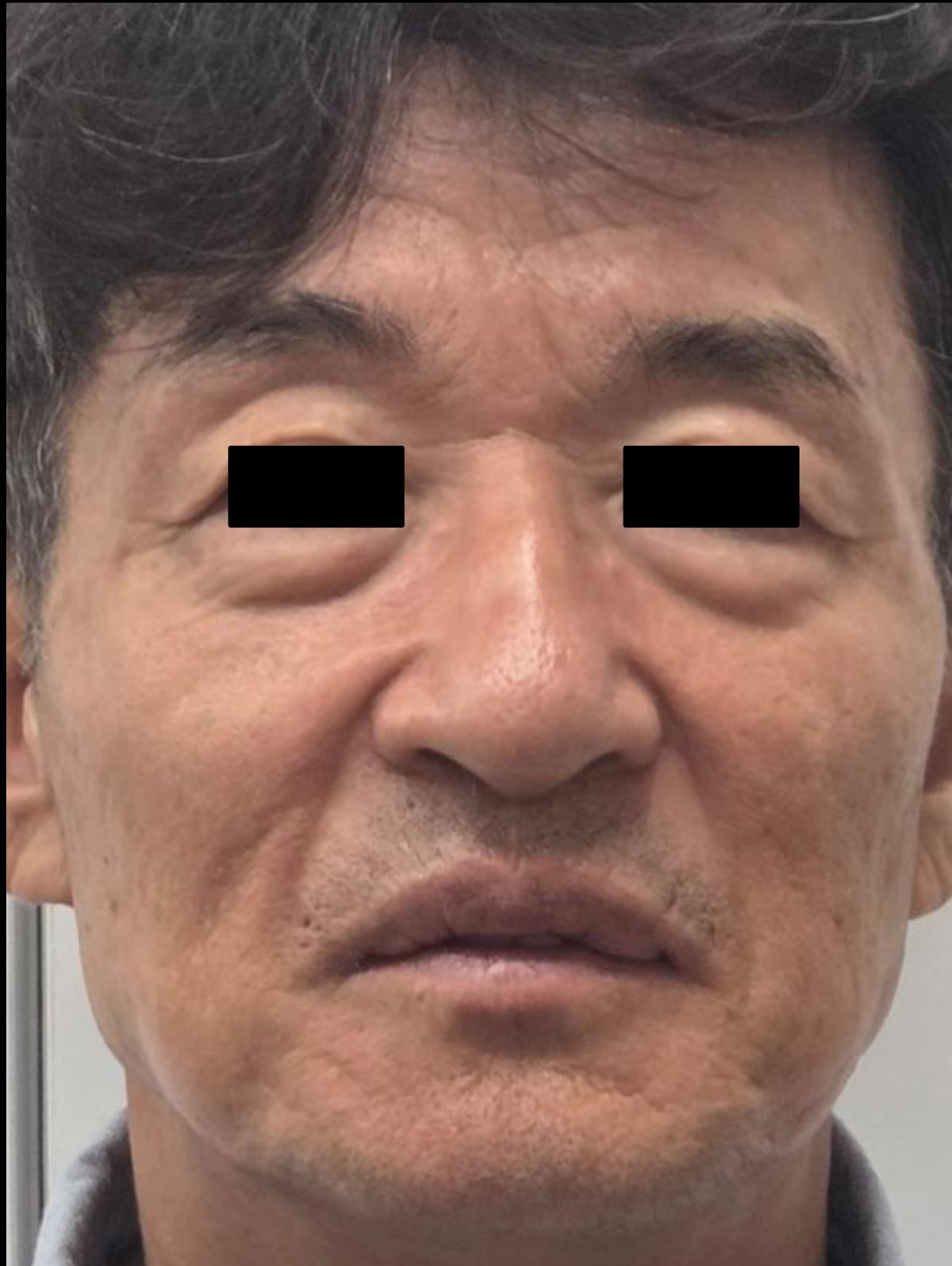


After : 1 month

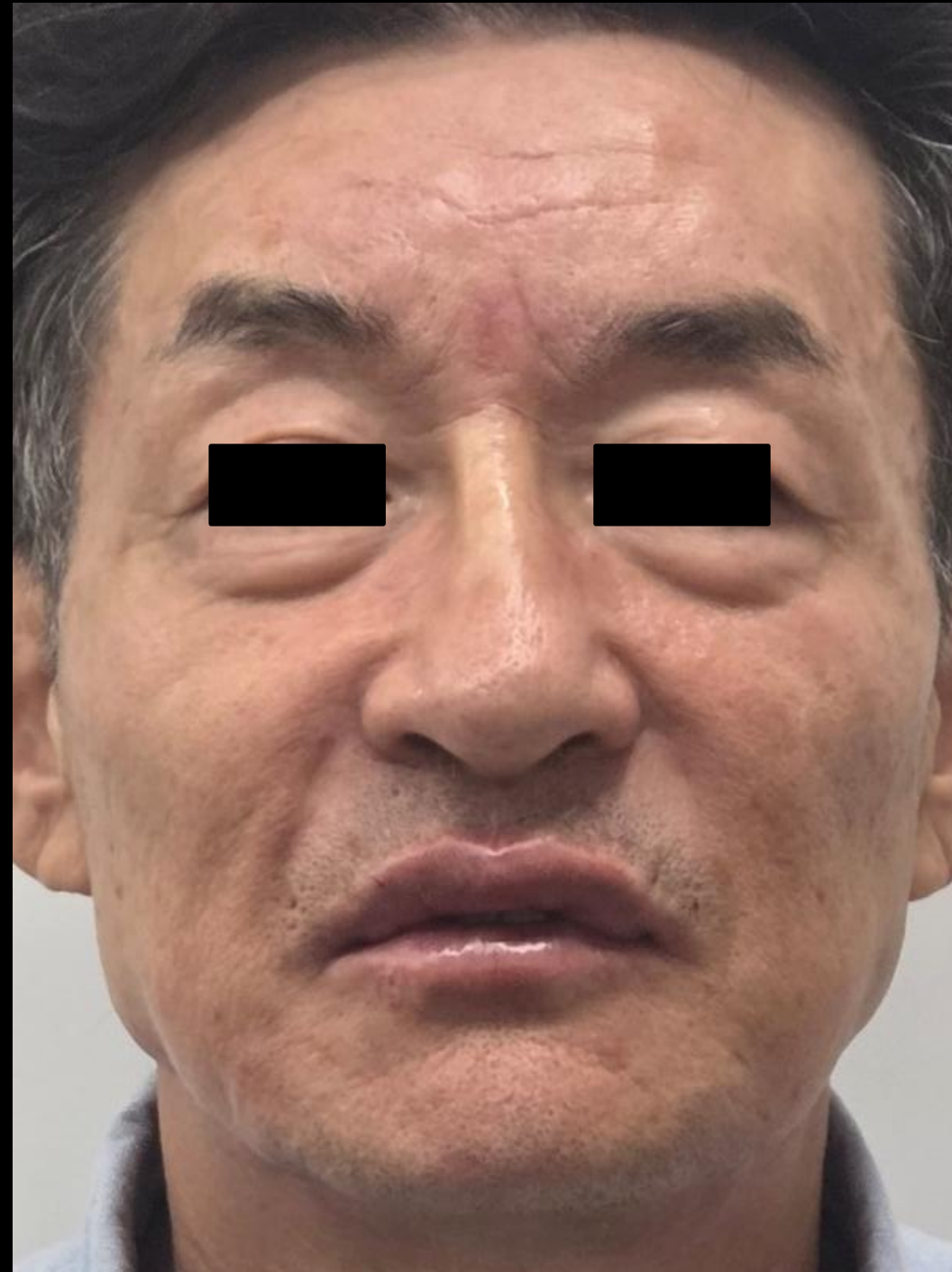

The front of

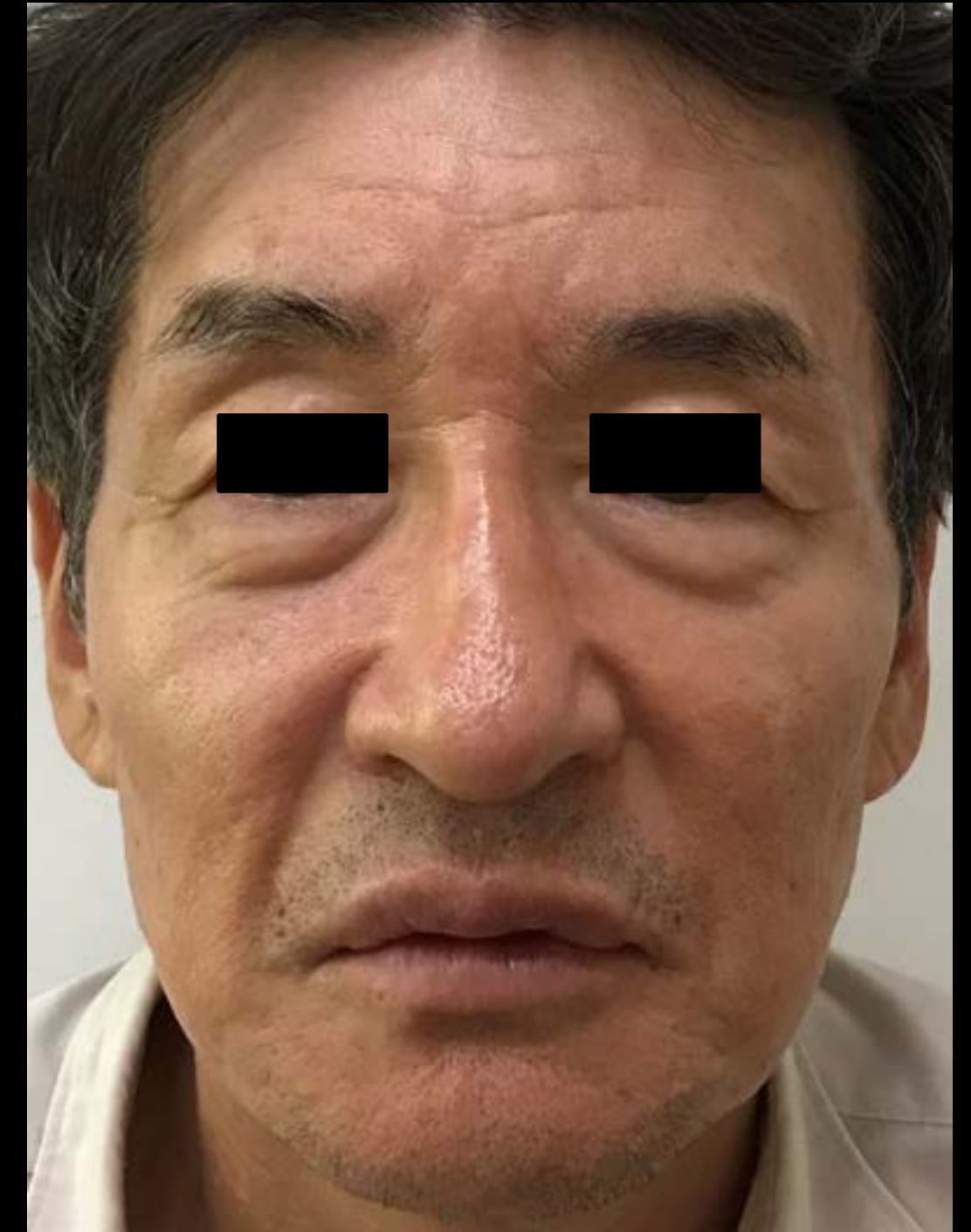Before



After

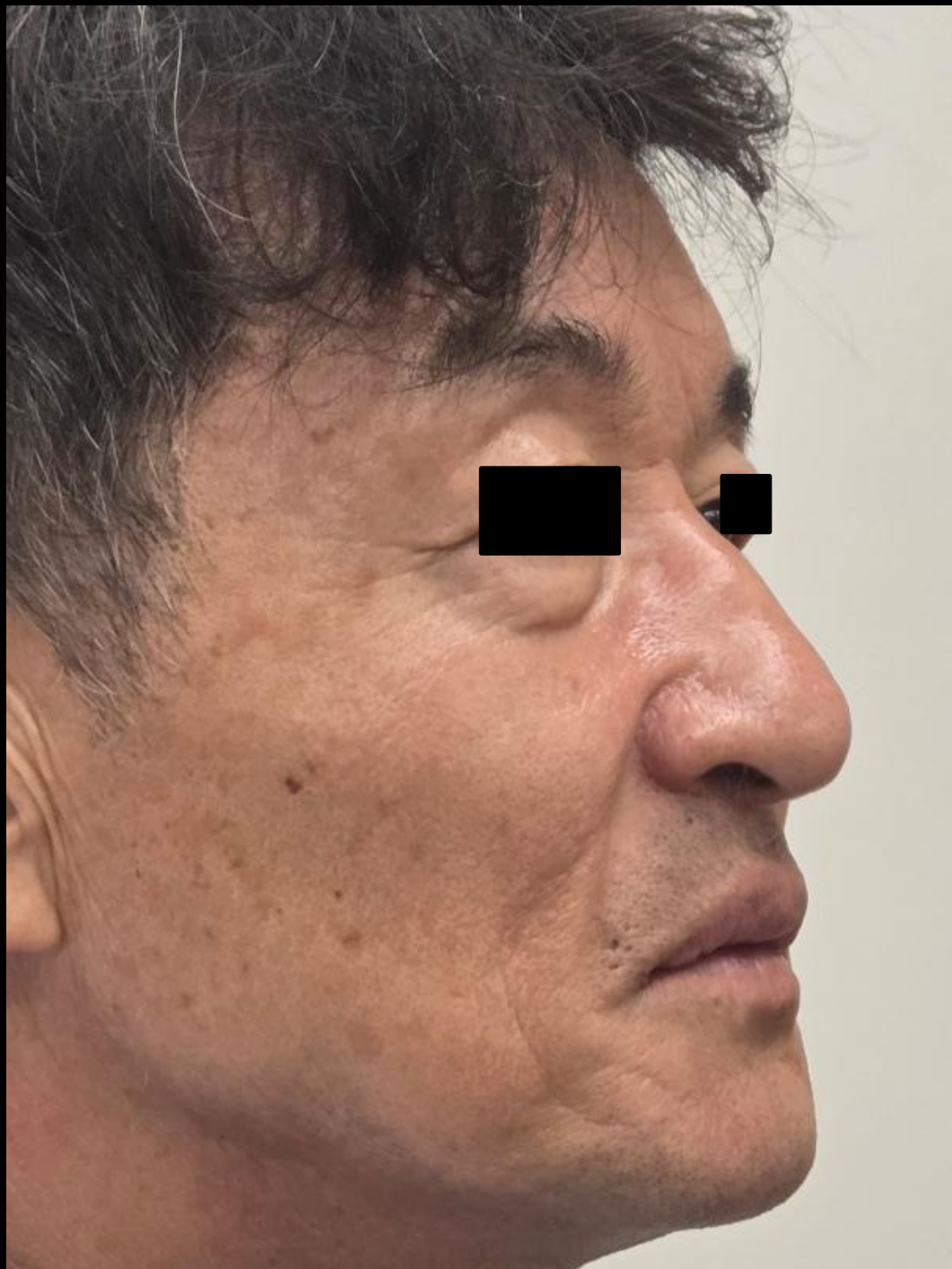


After : 1 month

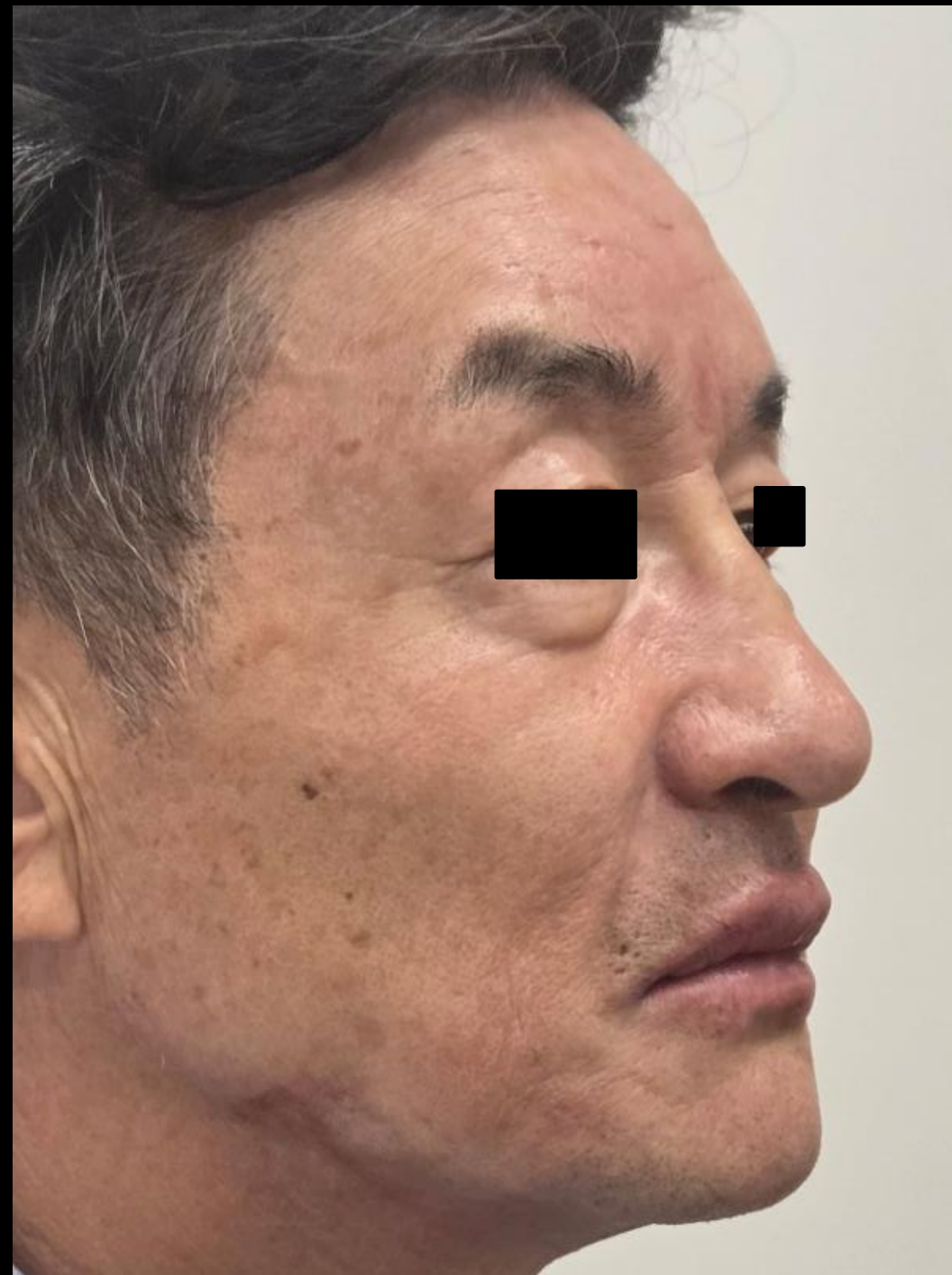

The right side

Before



After



After : 1 month

