



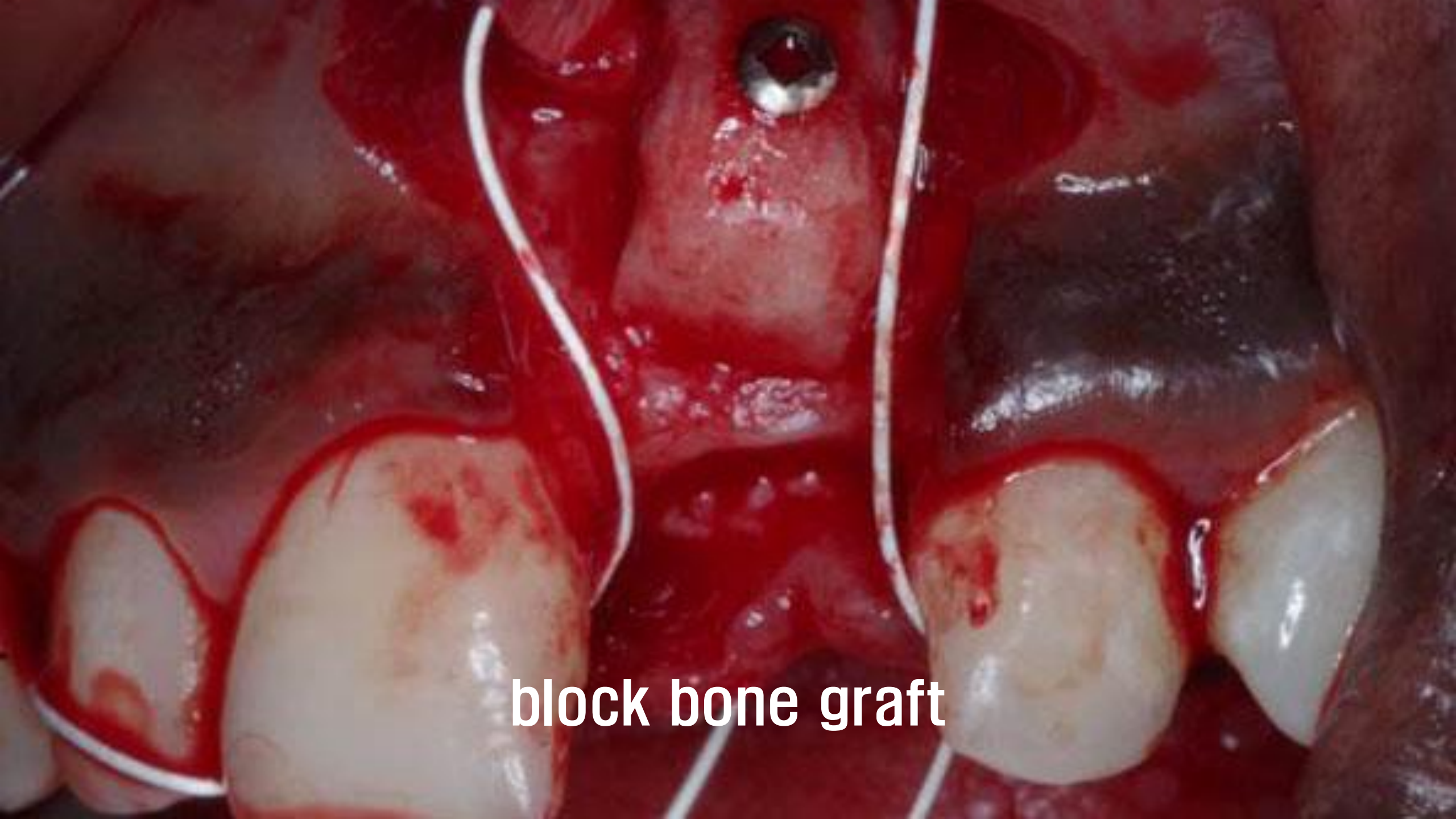
A highly versatile new implant system: bright BL, TL

Mei-Sha WELL dental clinic
Lim, Sang Chul

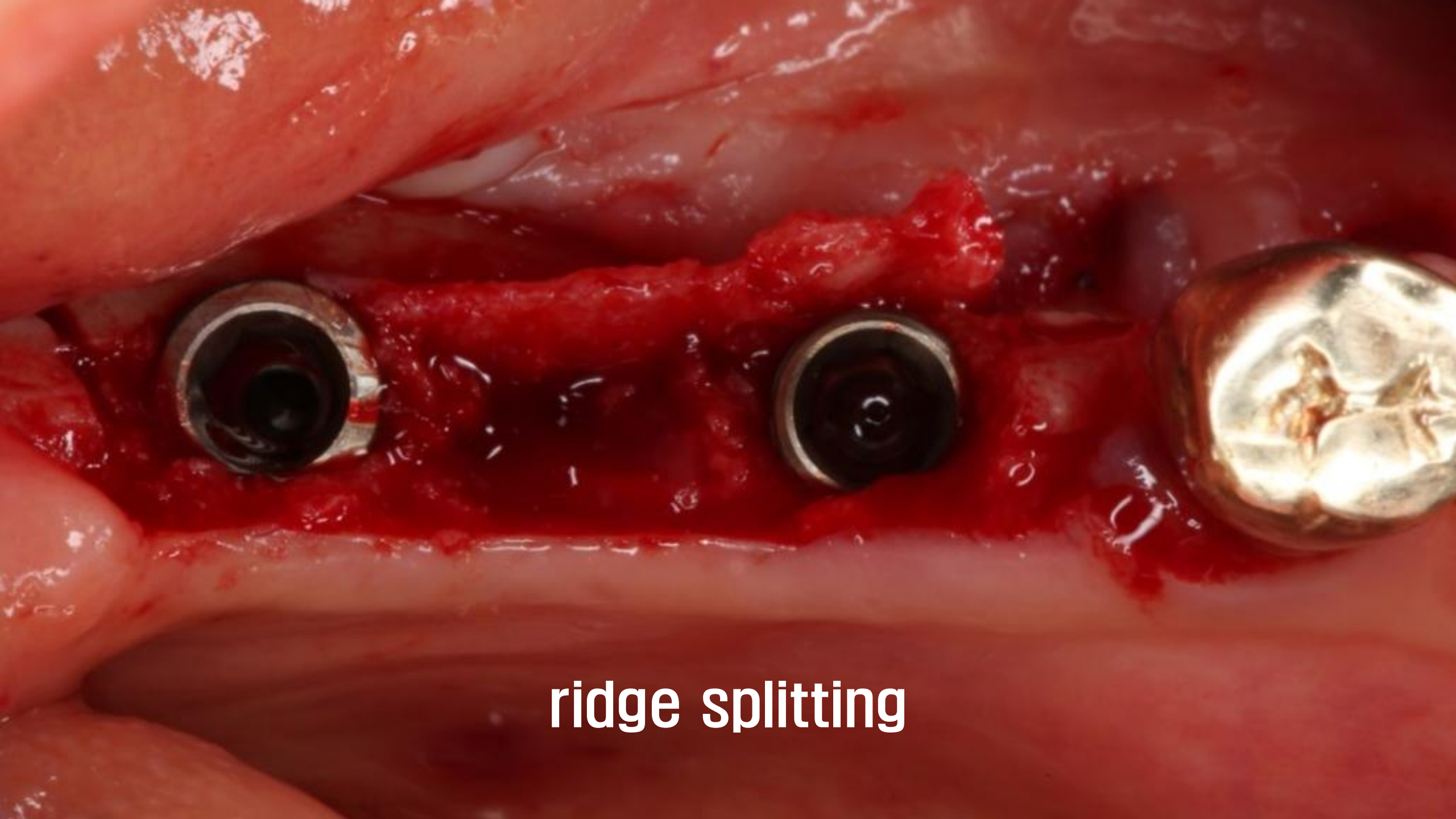
‘stress free bright’ concept

An intraoperative photograph of a maxillary surgical site. The image shows a long, narrow, and somewhat irregular ridge of bone and soft tissue extending horizontally across the middle of the frame. The tissue is highly vascularized, appearing bright red. To the right, a dental implant with a yellow crown is visible. In the lower foreground, two dark, rounded surgical instruments or retractors are positioned. The overall scene is a clinical view of a surgical procedure.

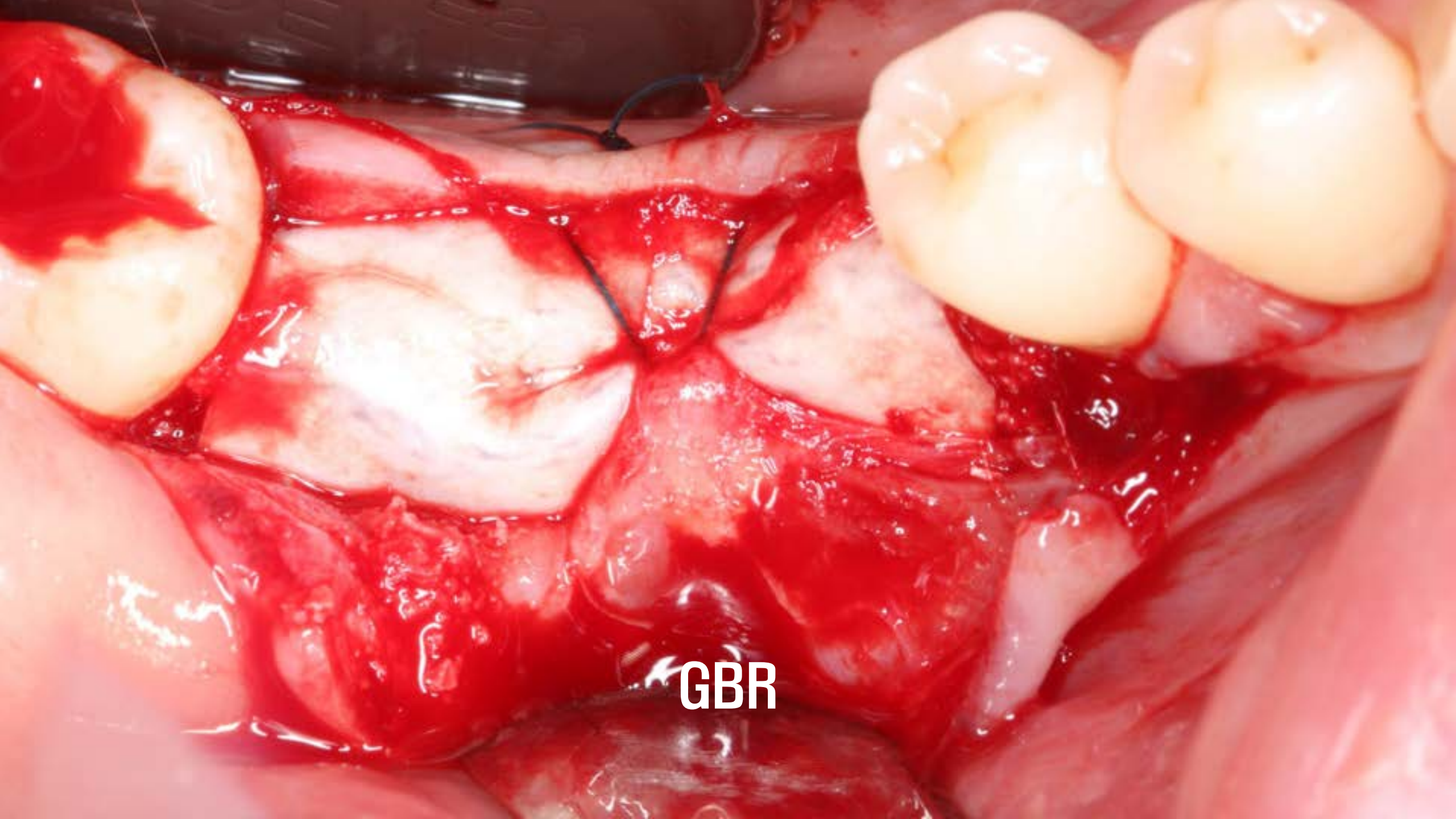
narrow ridge on posterior region
What is your plan?



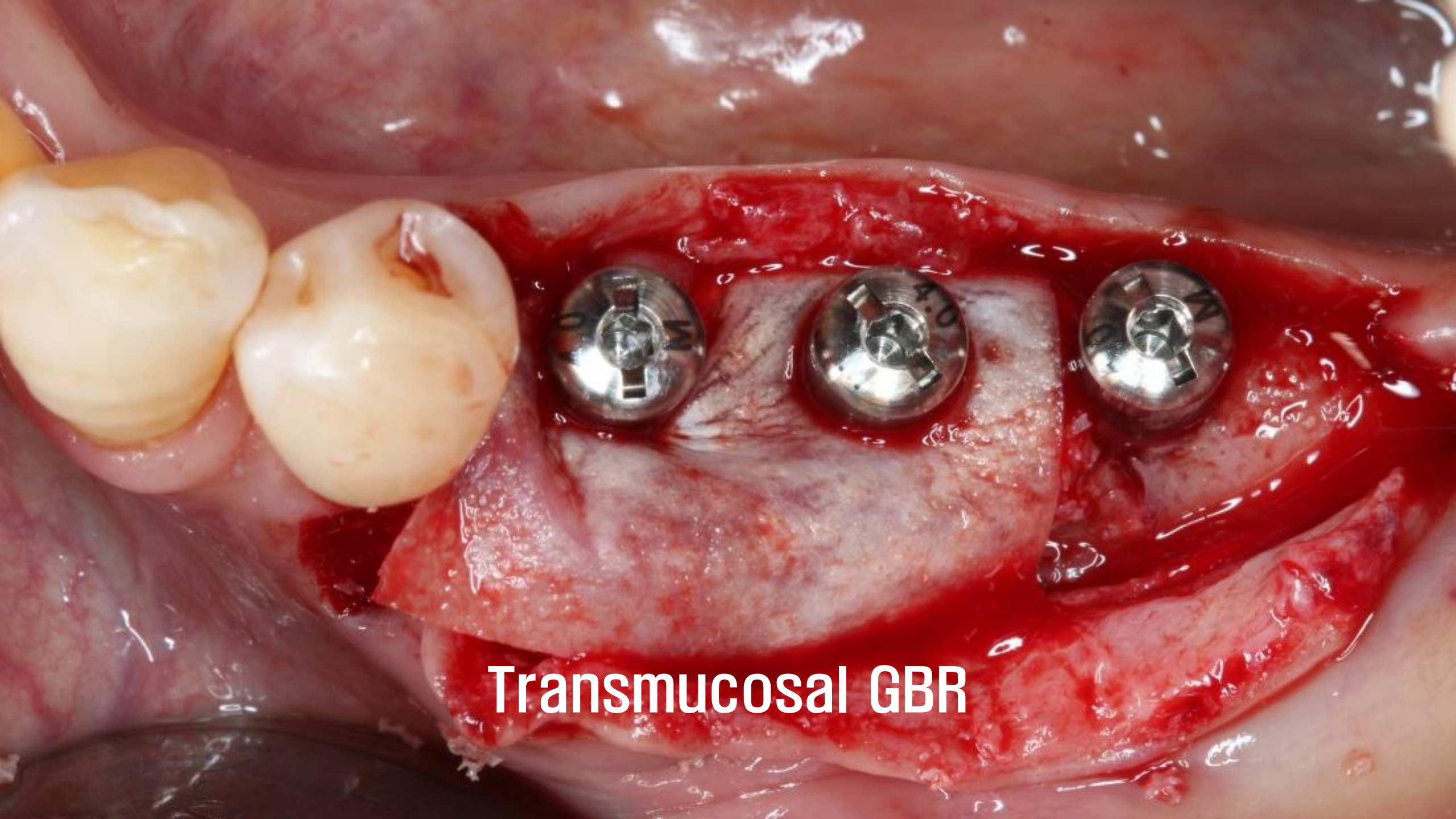
block bone graft



ridge splitting

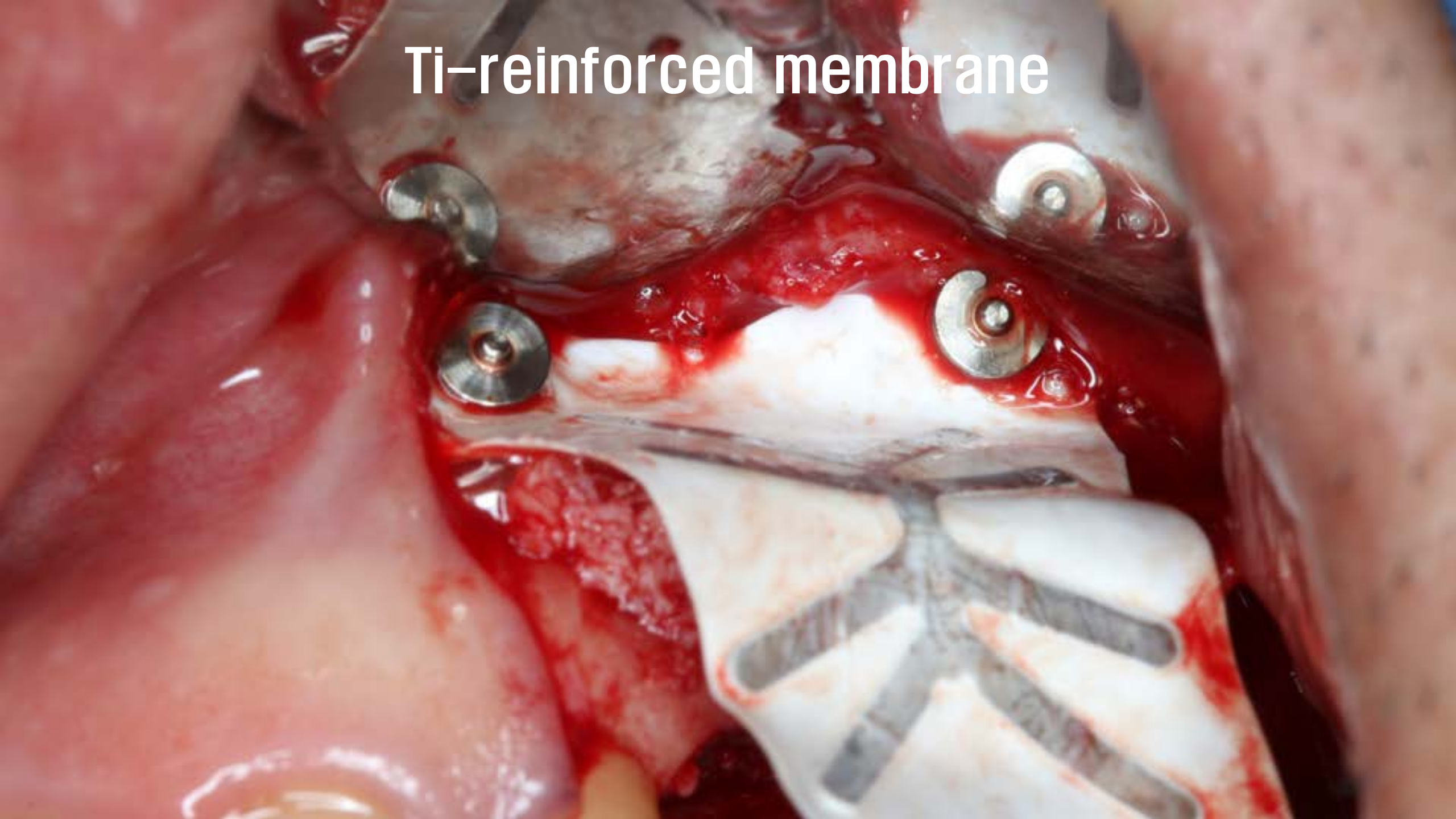


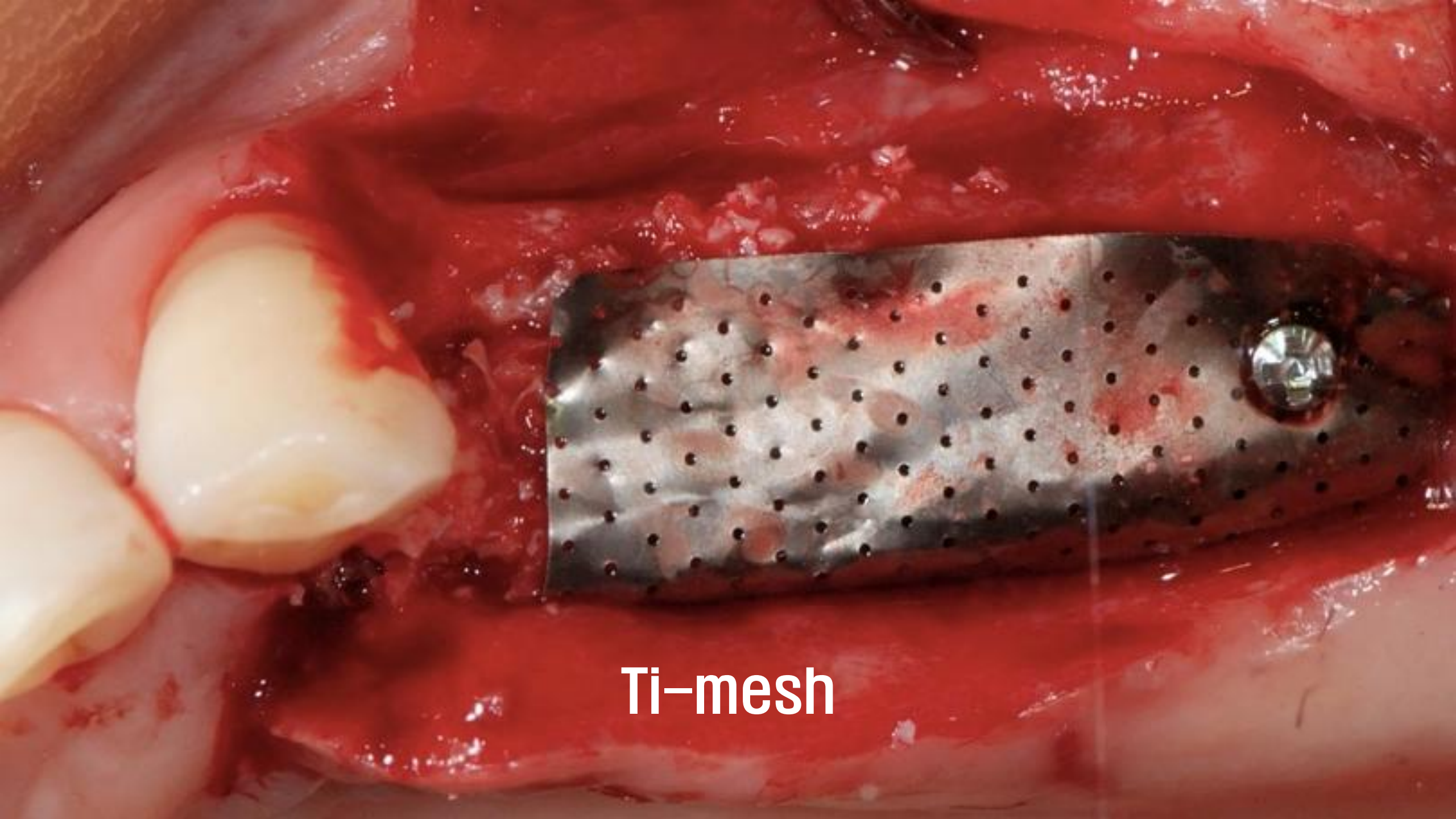
GBR



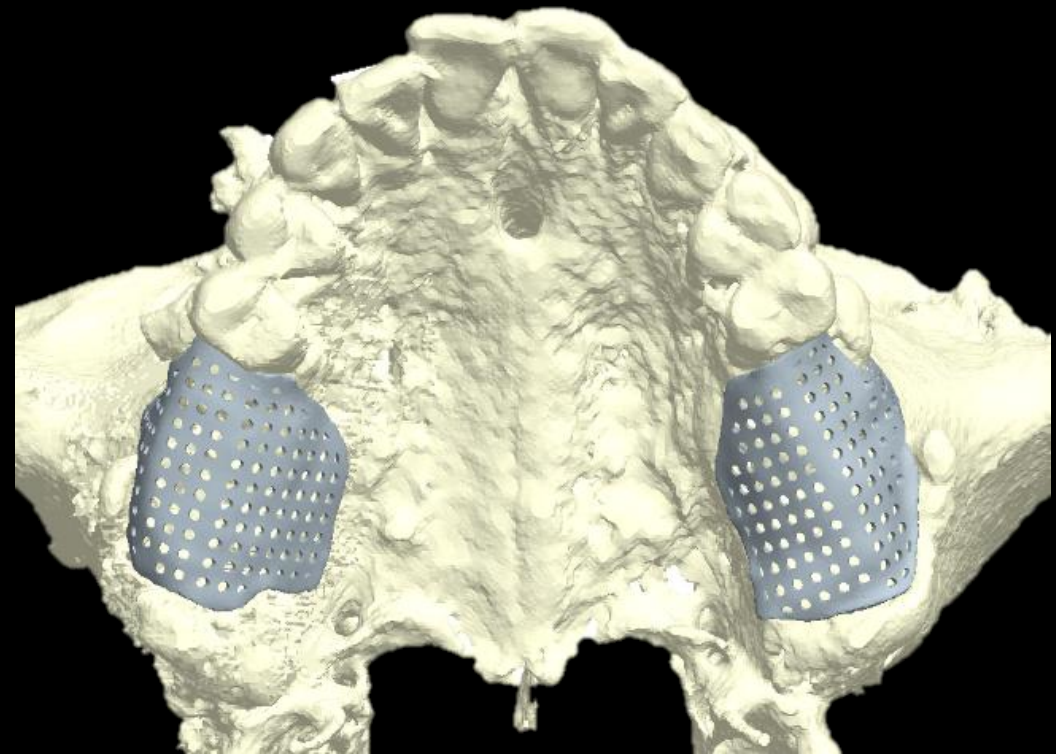
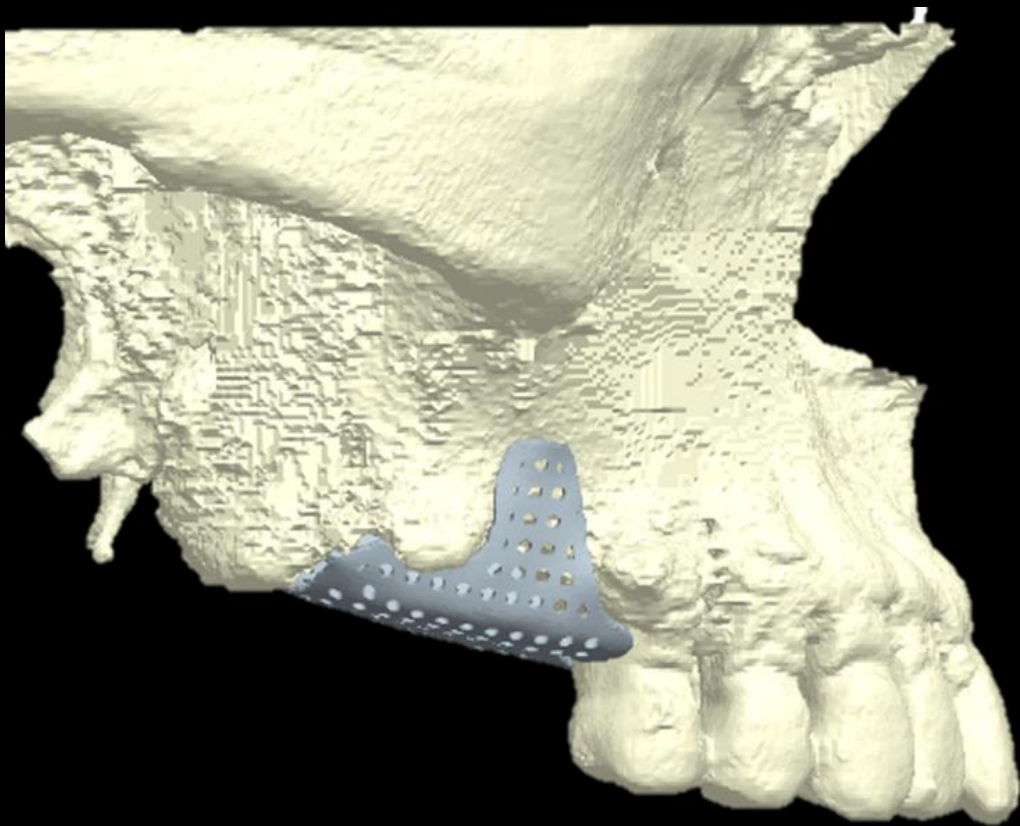
Transmucosal GBR

Ti-reinforced membrane






Ti-mesh



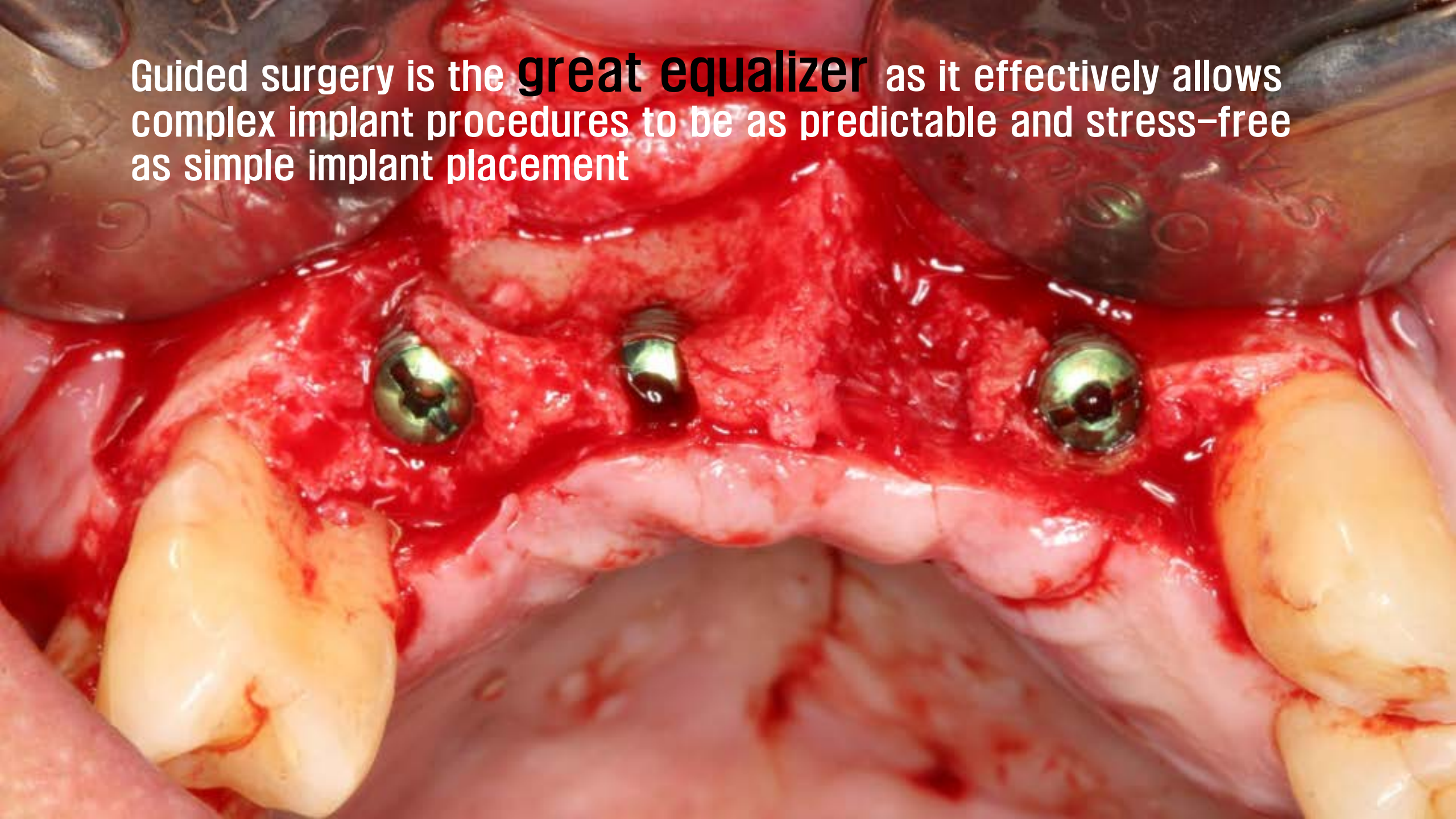3D printing customized Ti-mesh

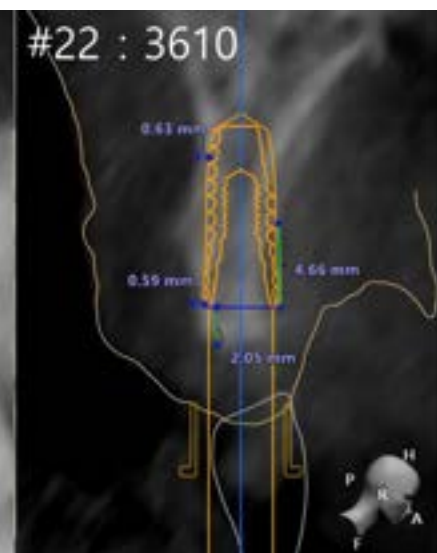
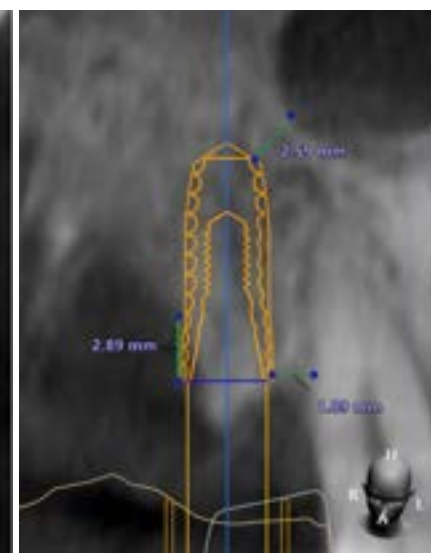
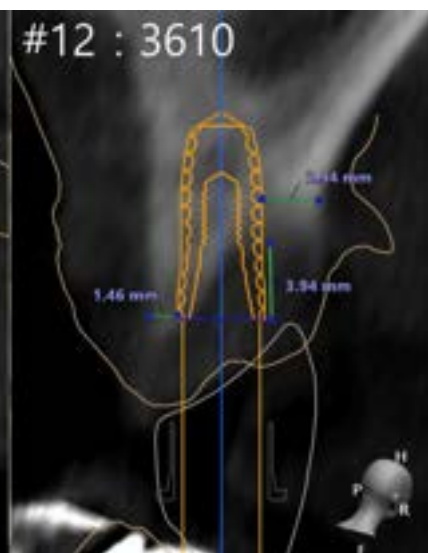
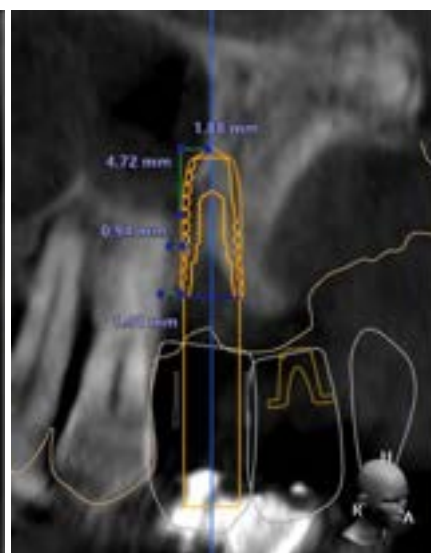
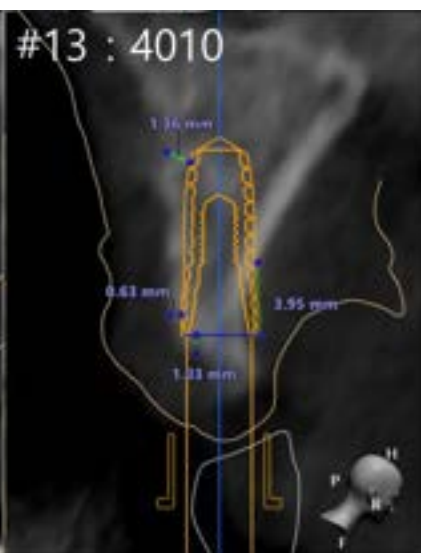
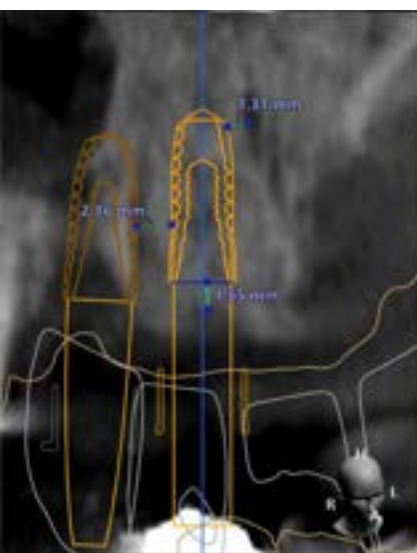
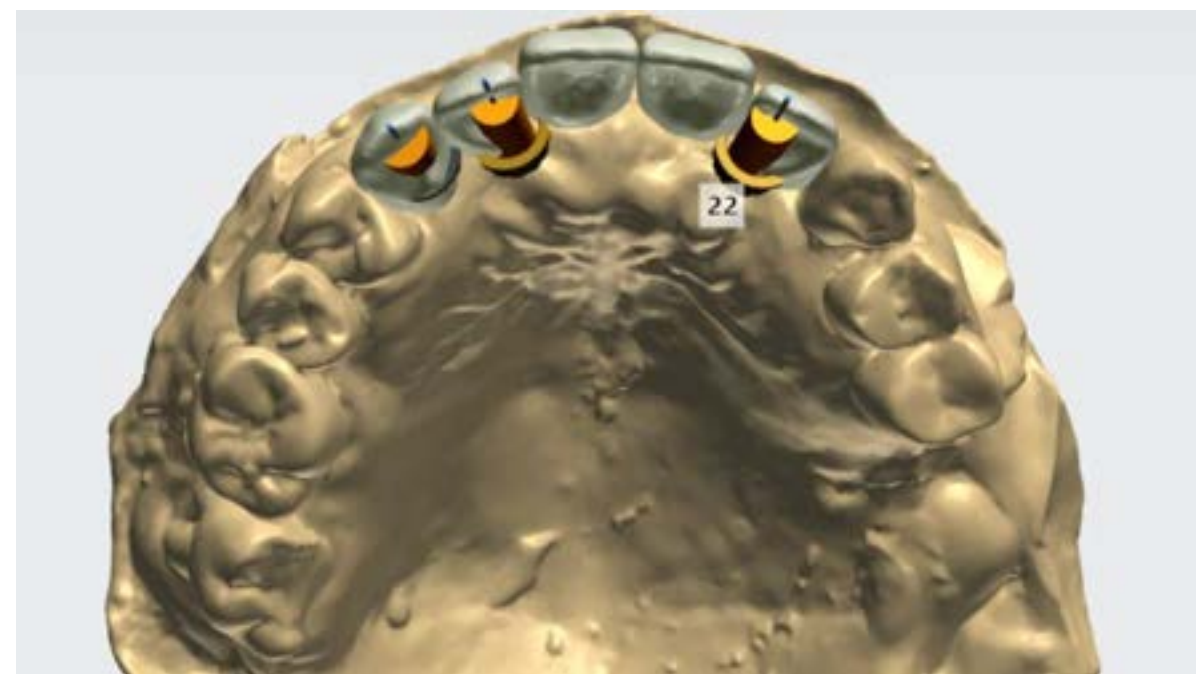
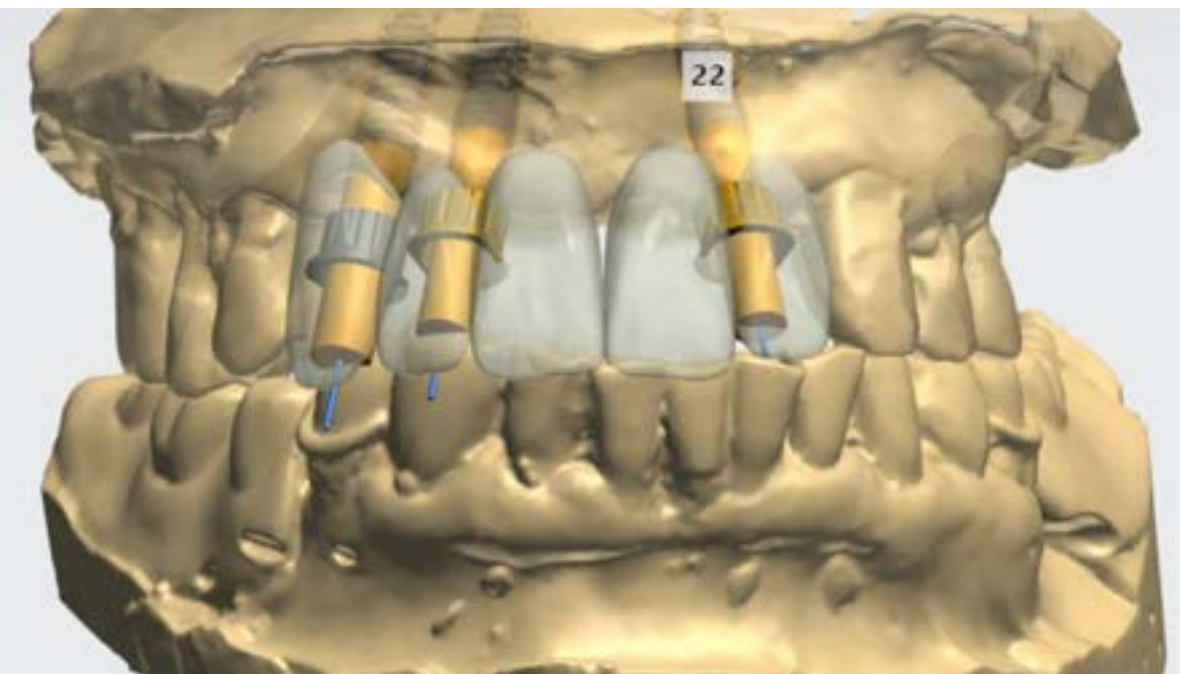


3D printing customized Ti-mesh

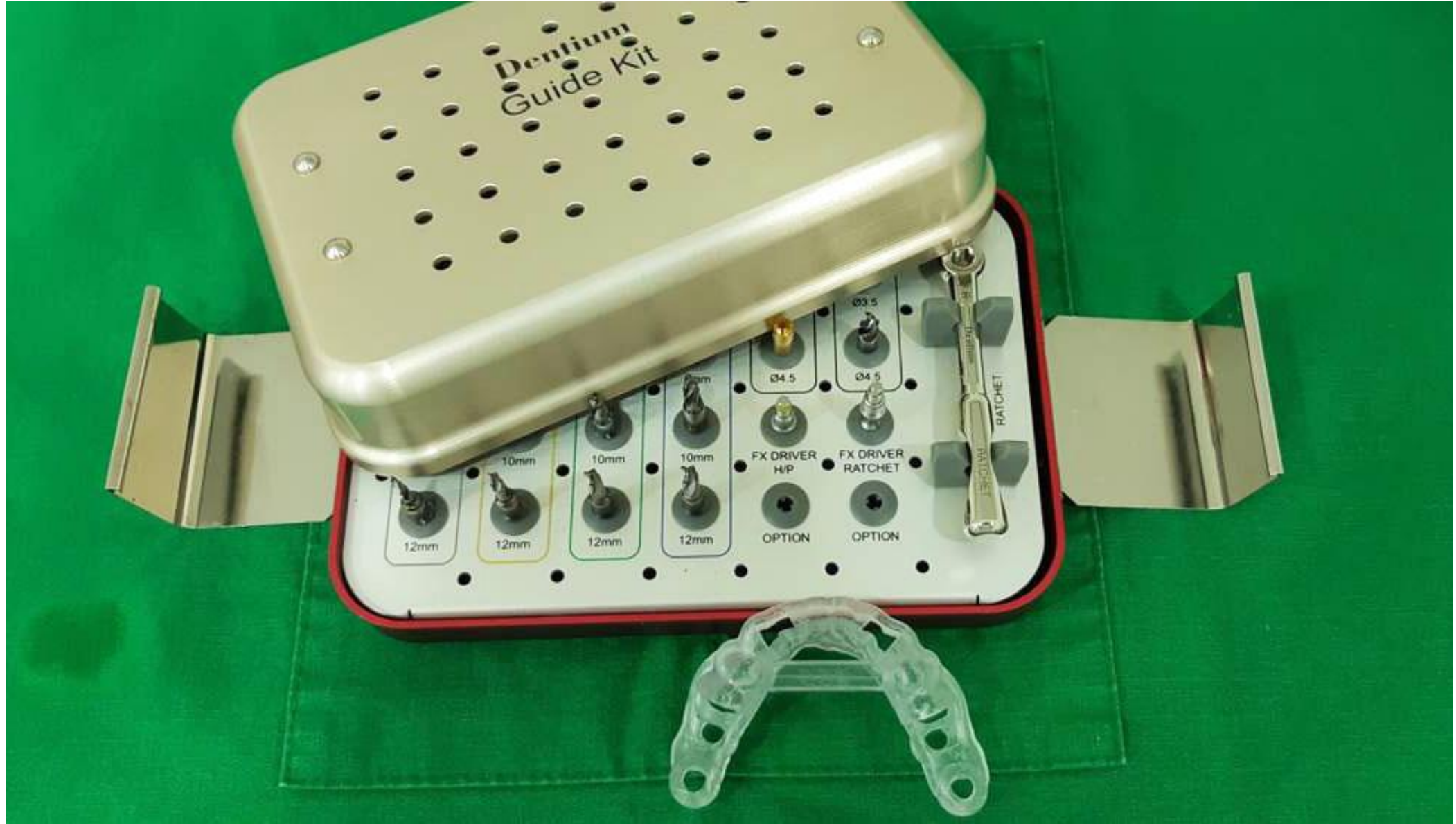Digital Technology

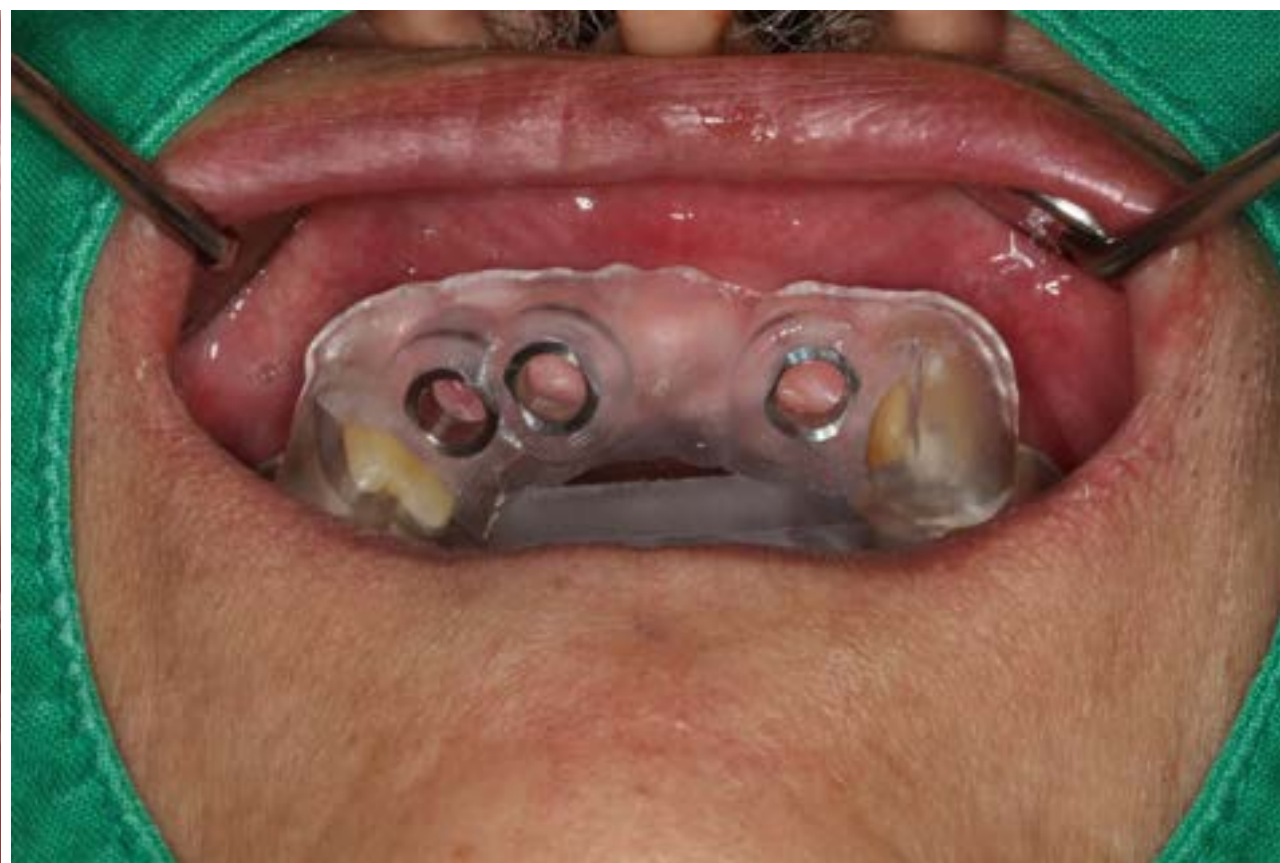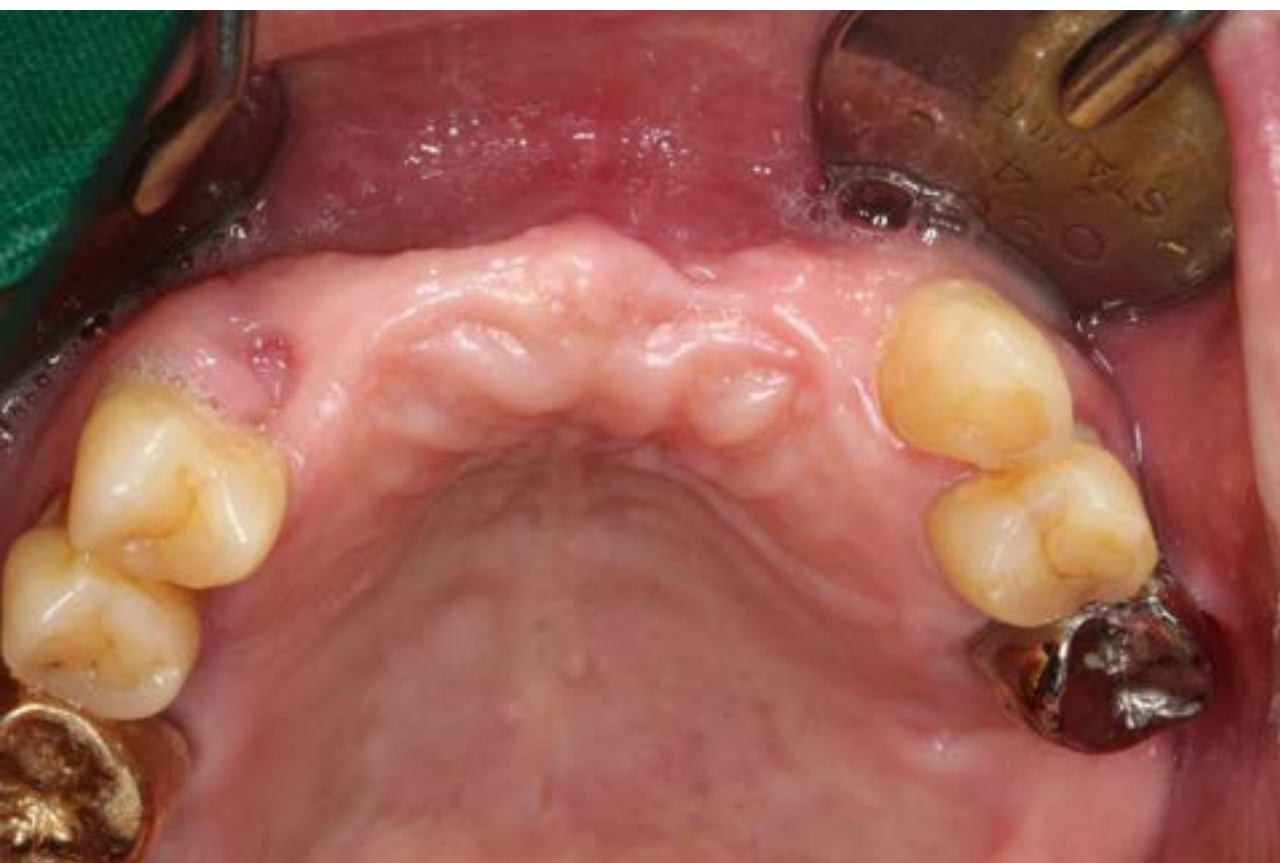Guided surgery is the **great equalizer** as it effectively allows complex implant procedures to be as predictable and stress-free as simple implant placement

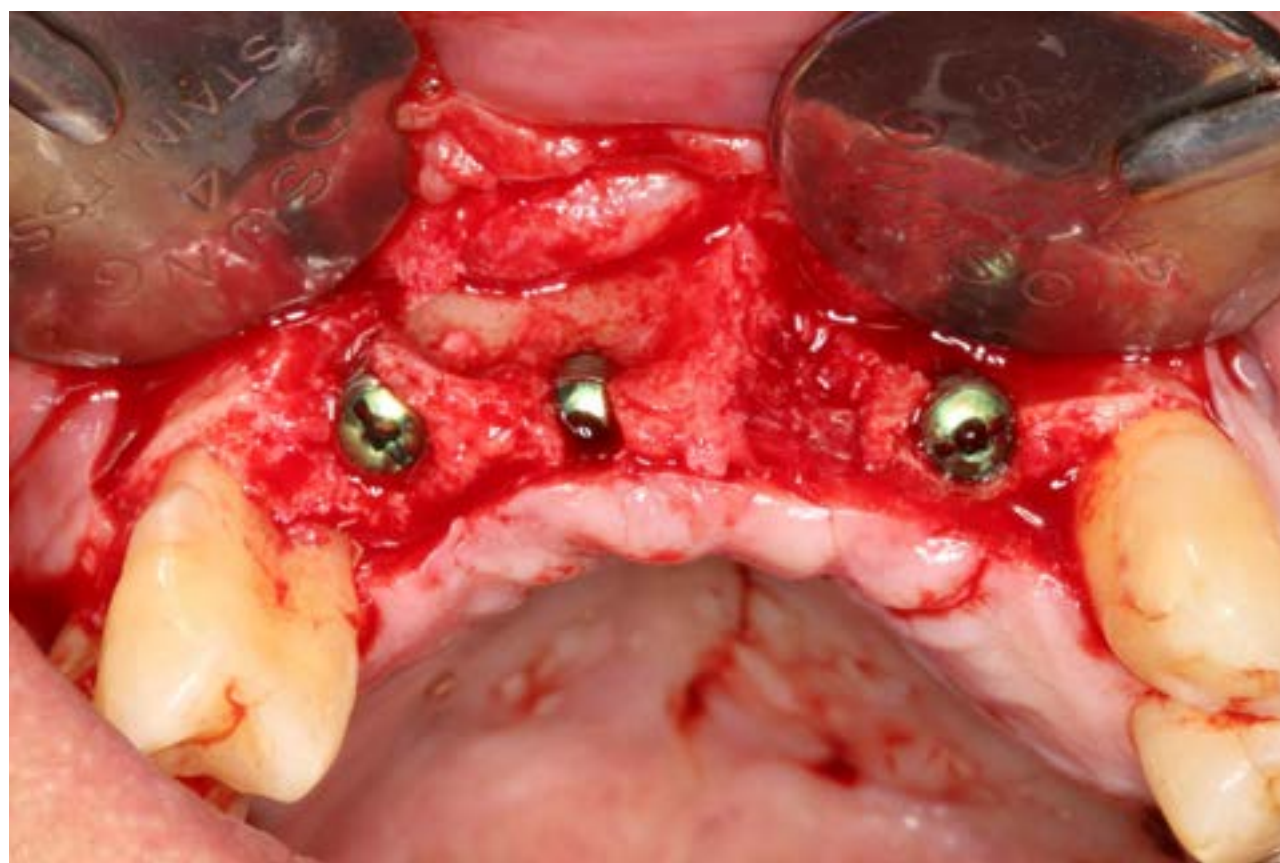
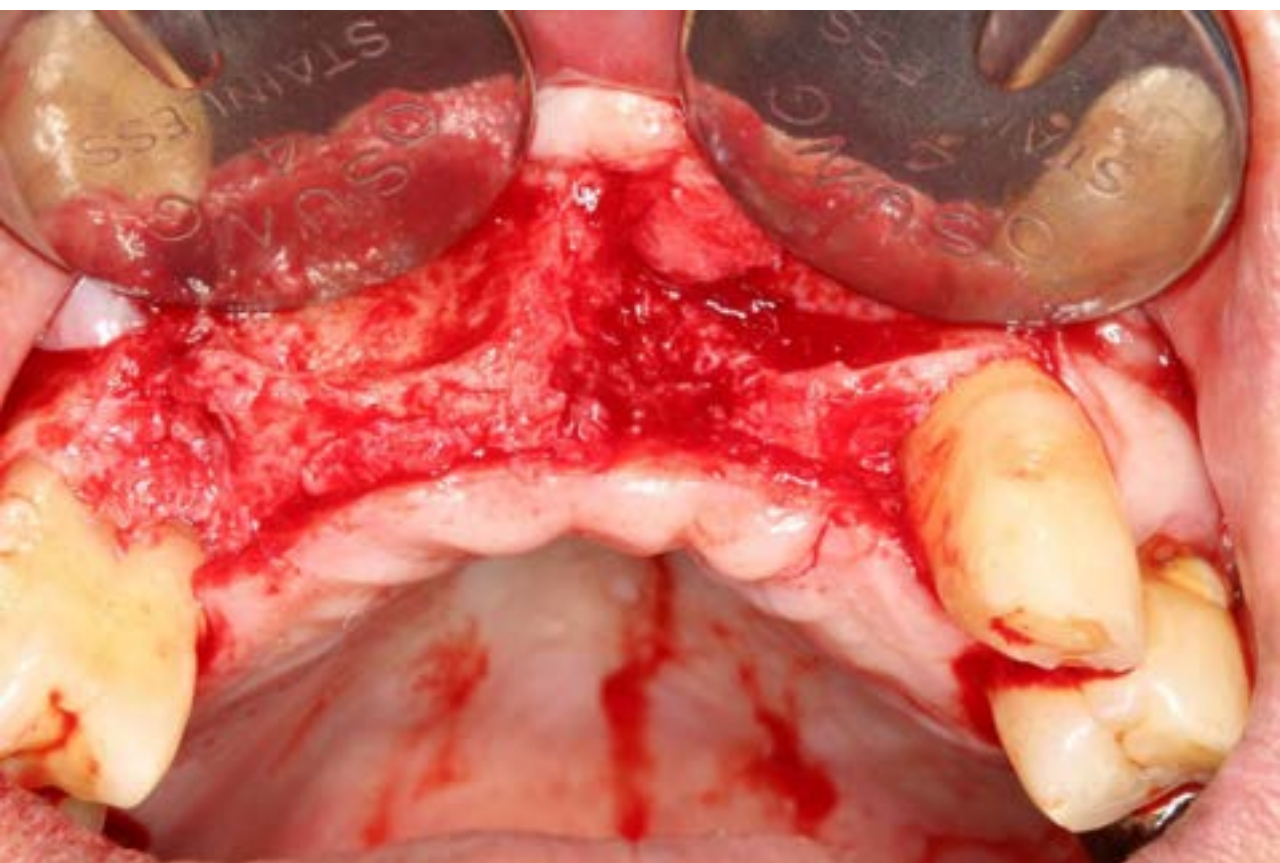




Dentium Digital Guide Surgery



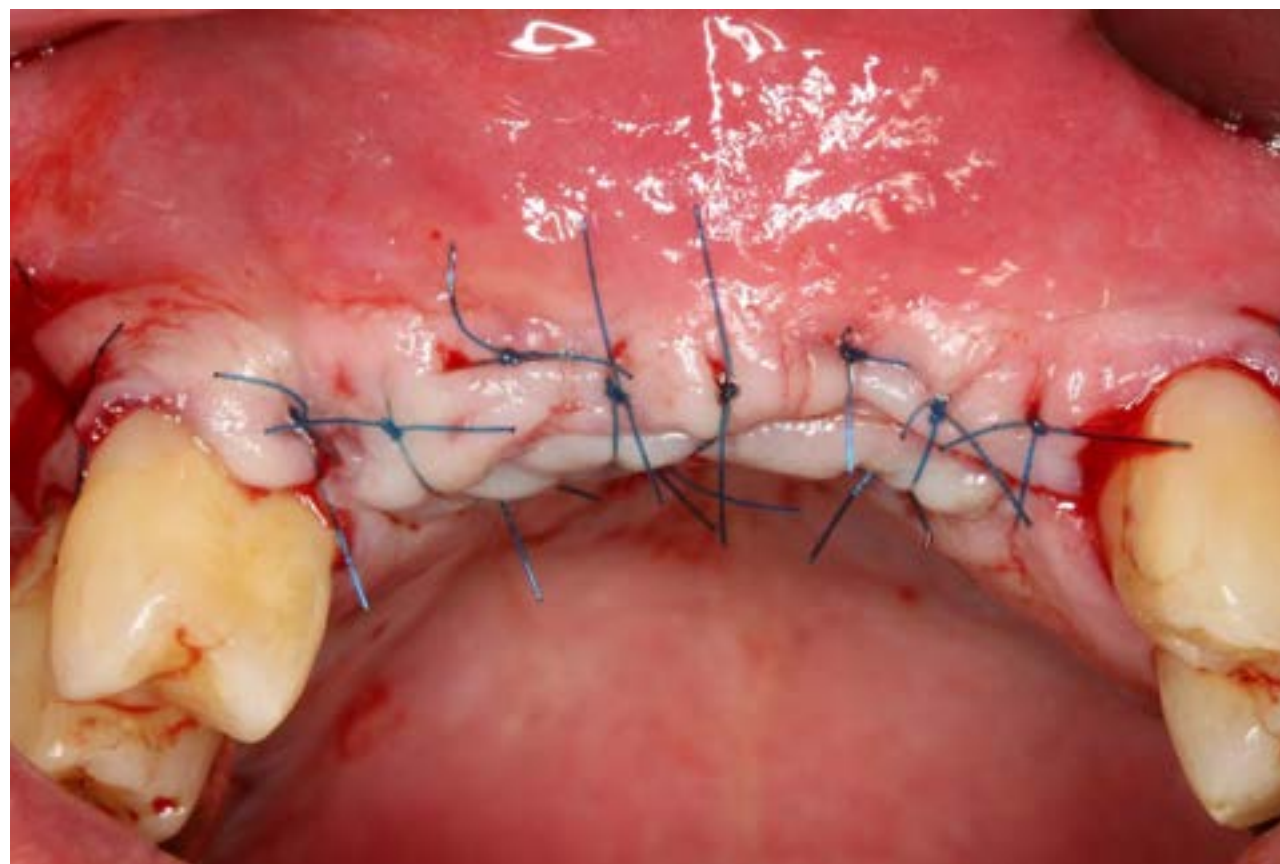
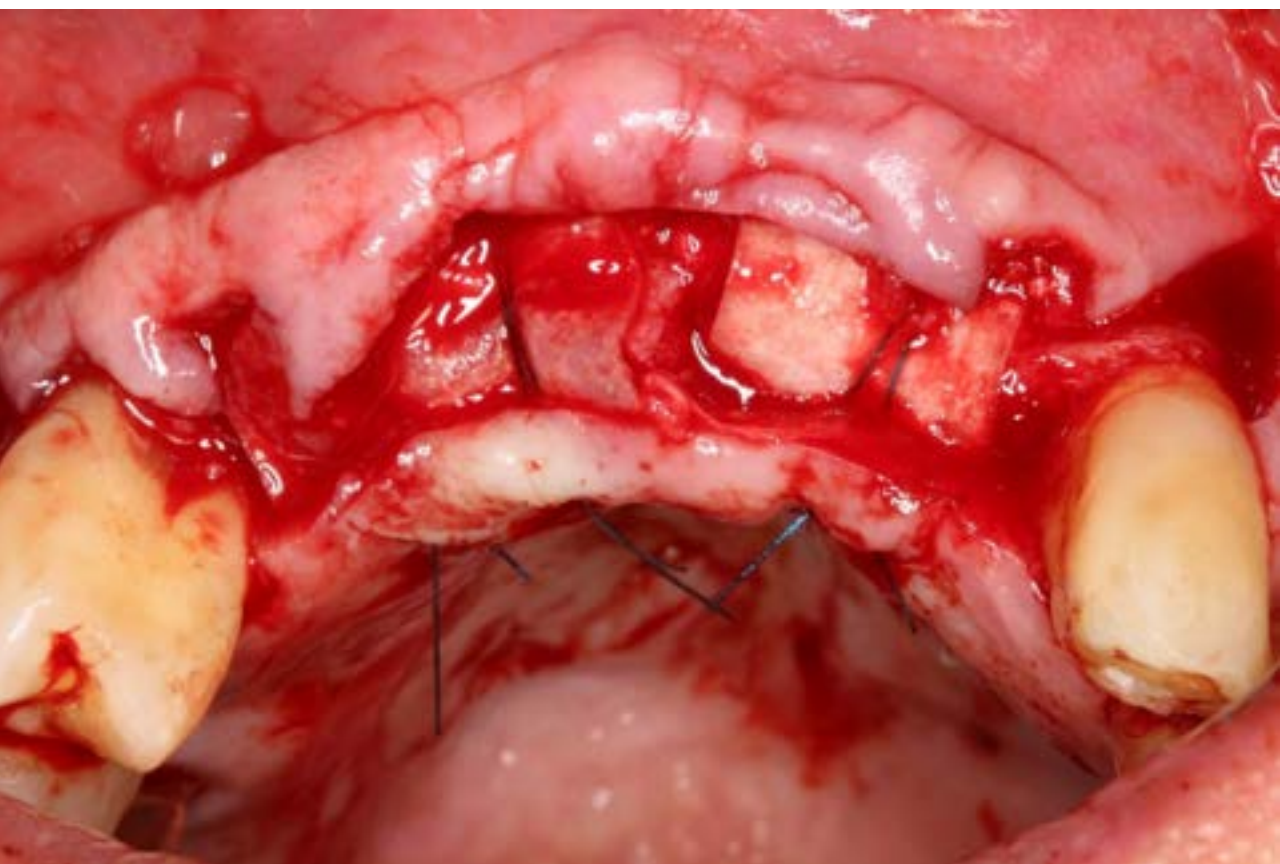




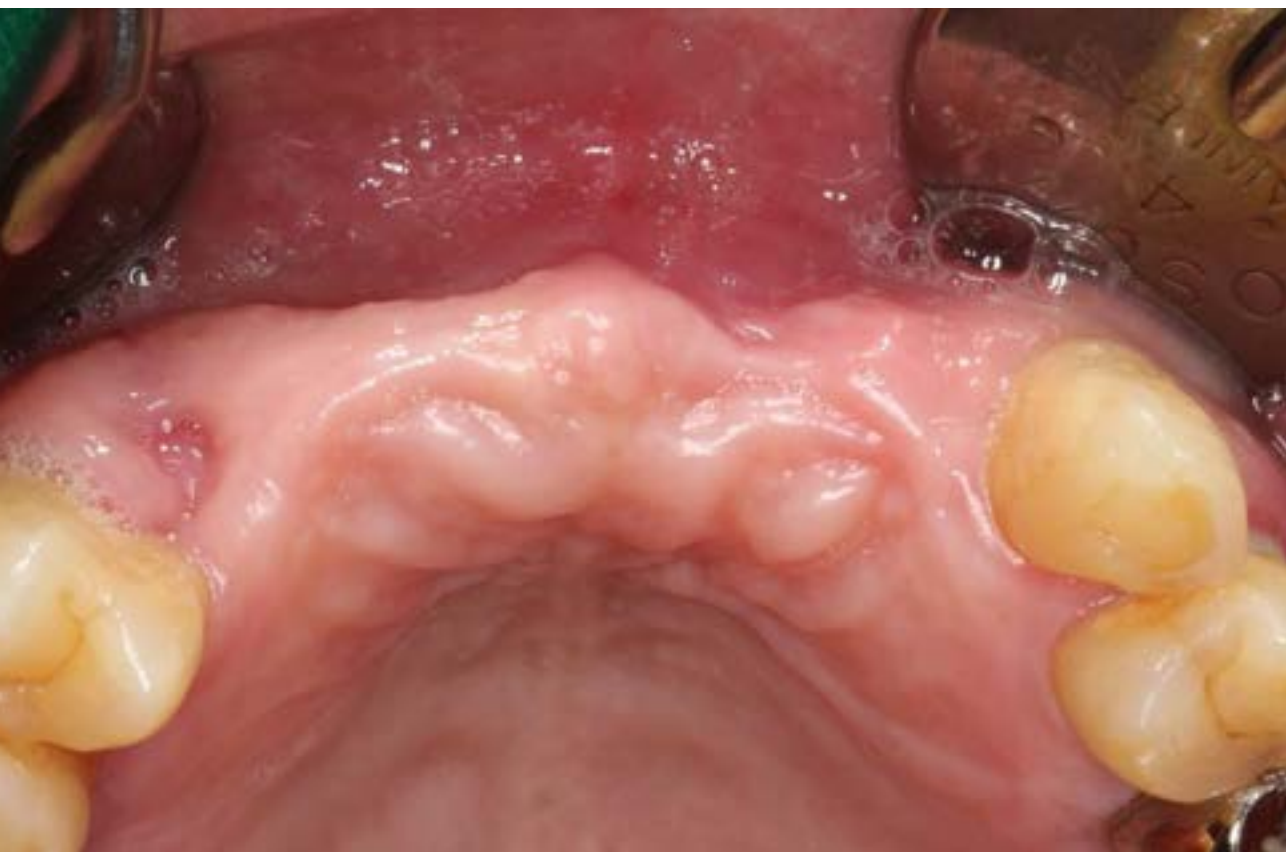Layering technique

03C

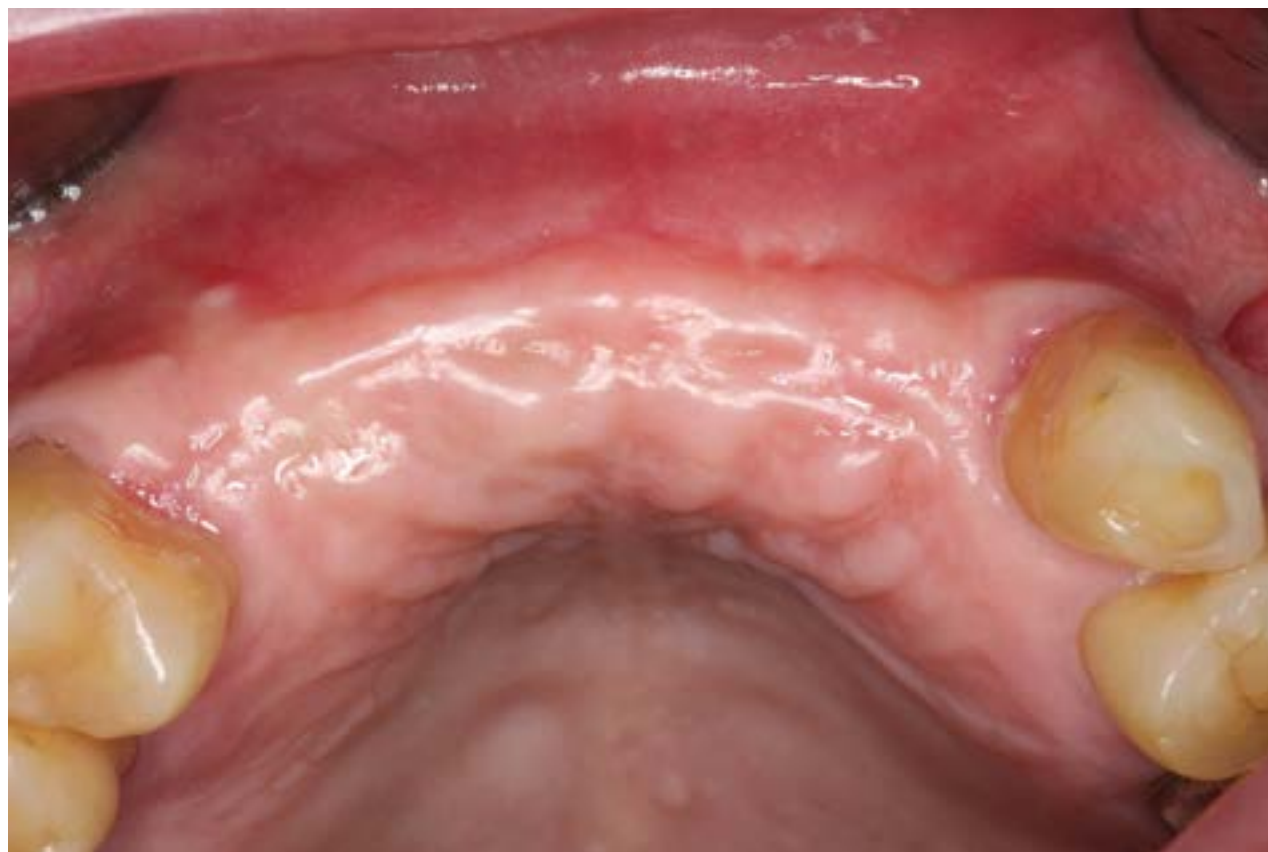Xenograft + Alloplastic graft materials (03C)



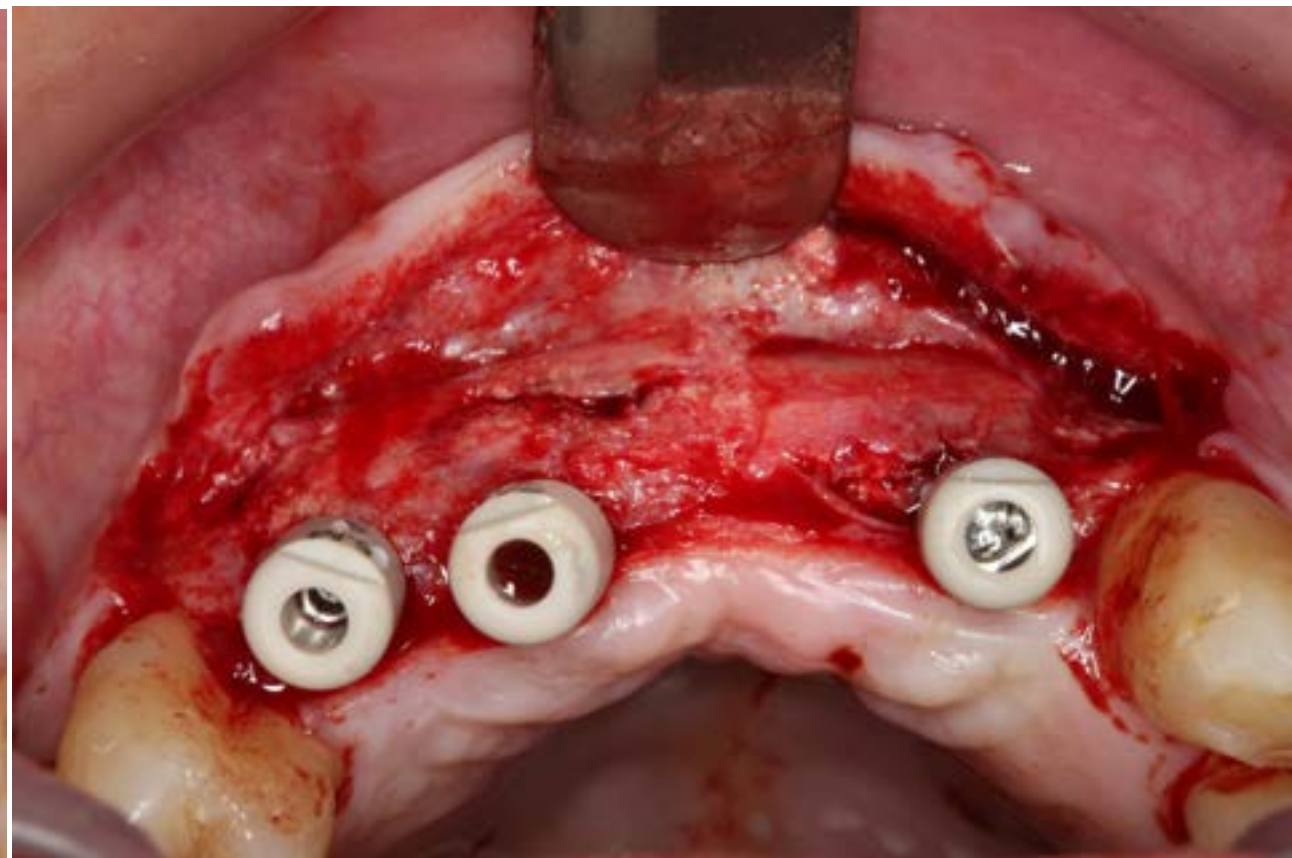
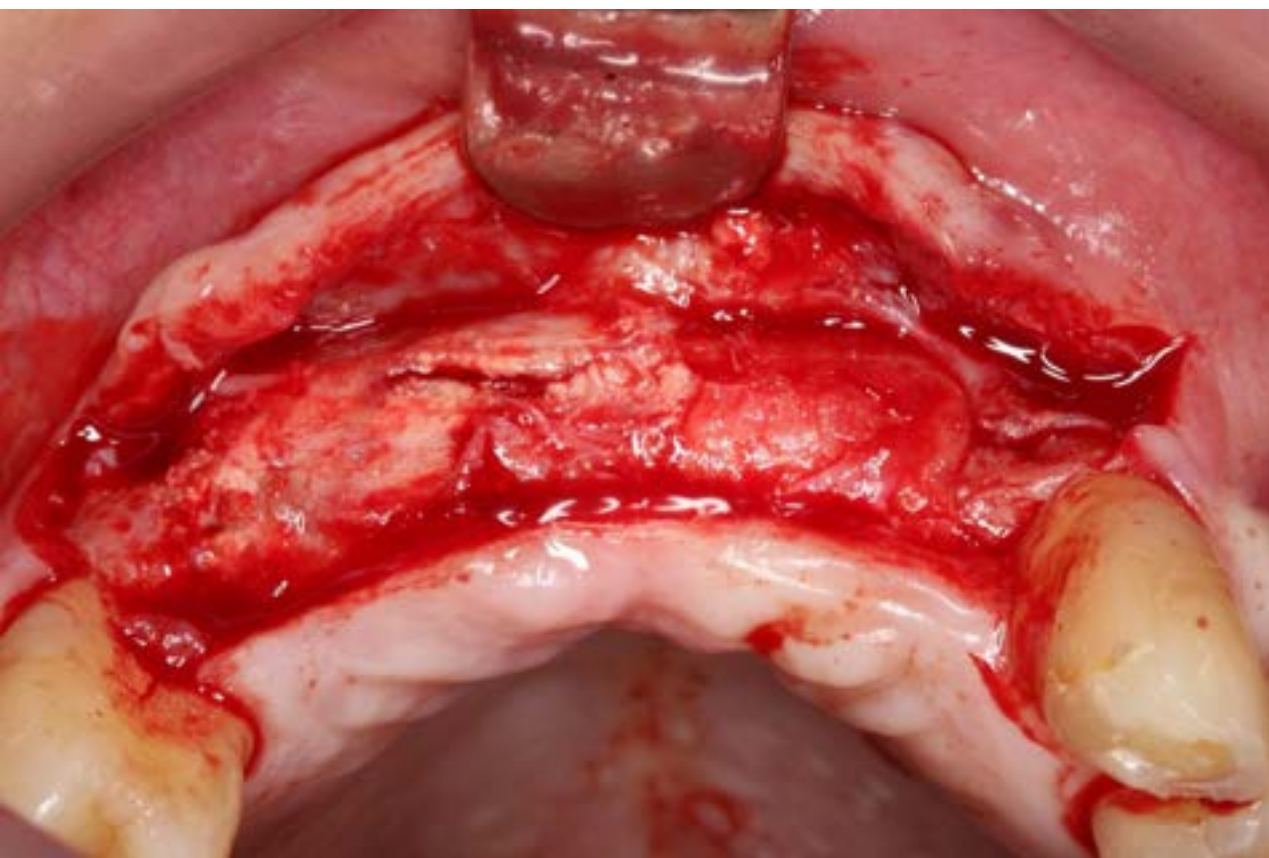
Dentium Collagen Membrane (stiff)

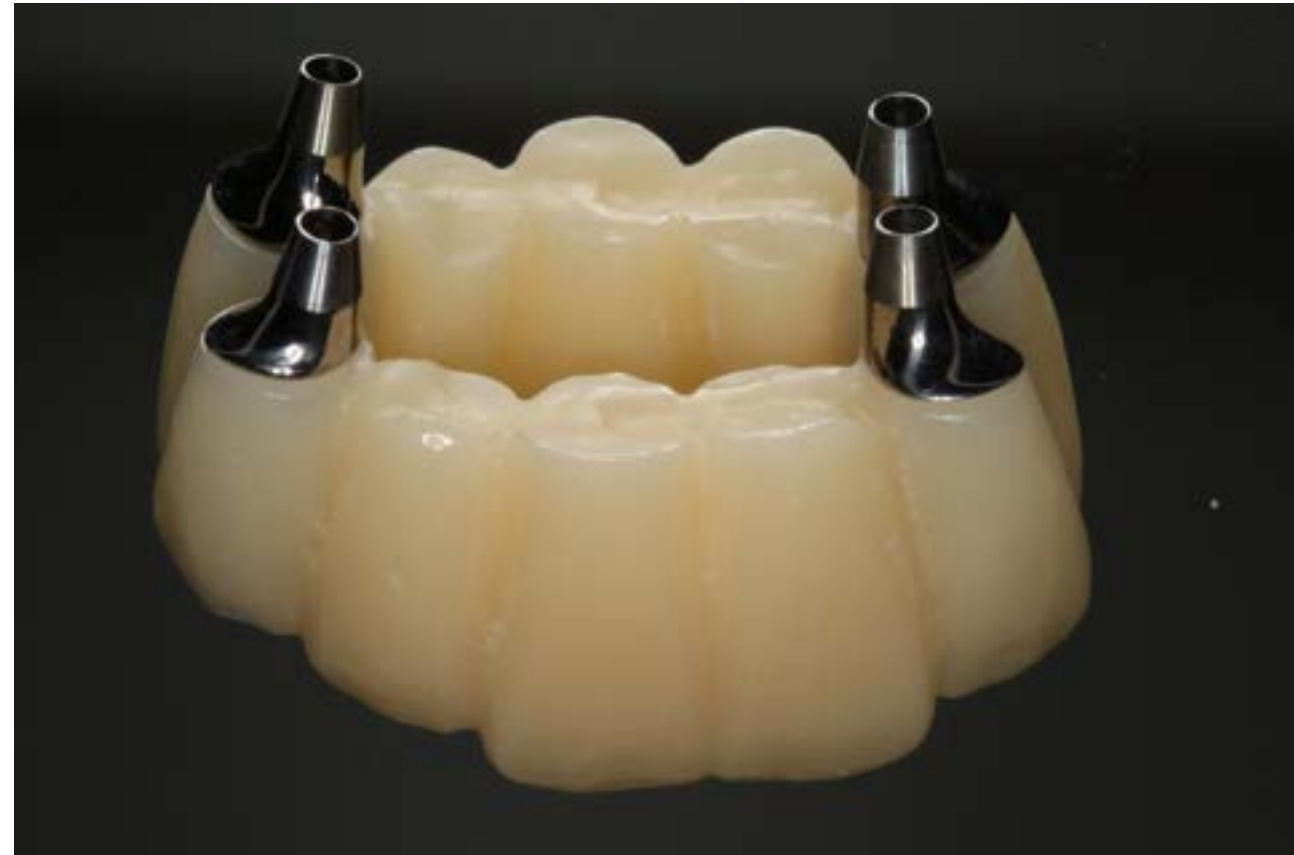

Pre-op

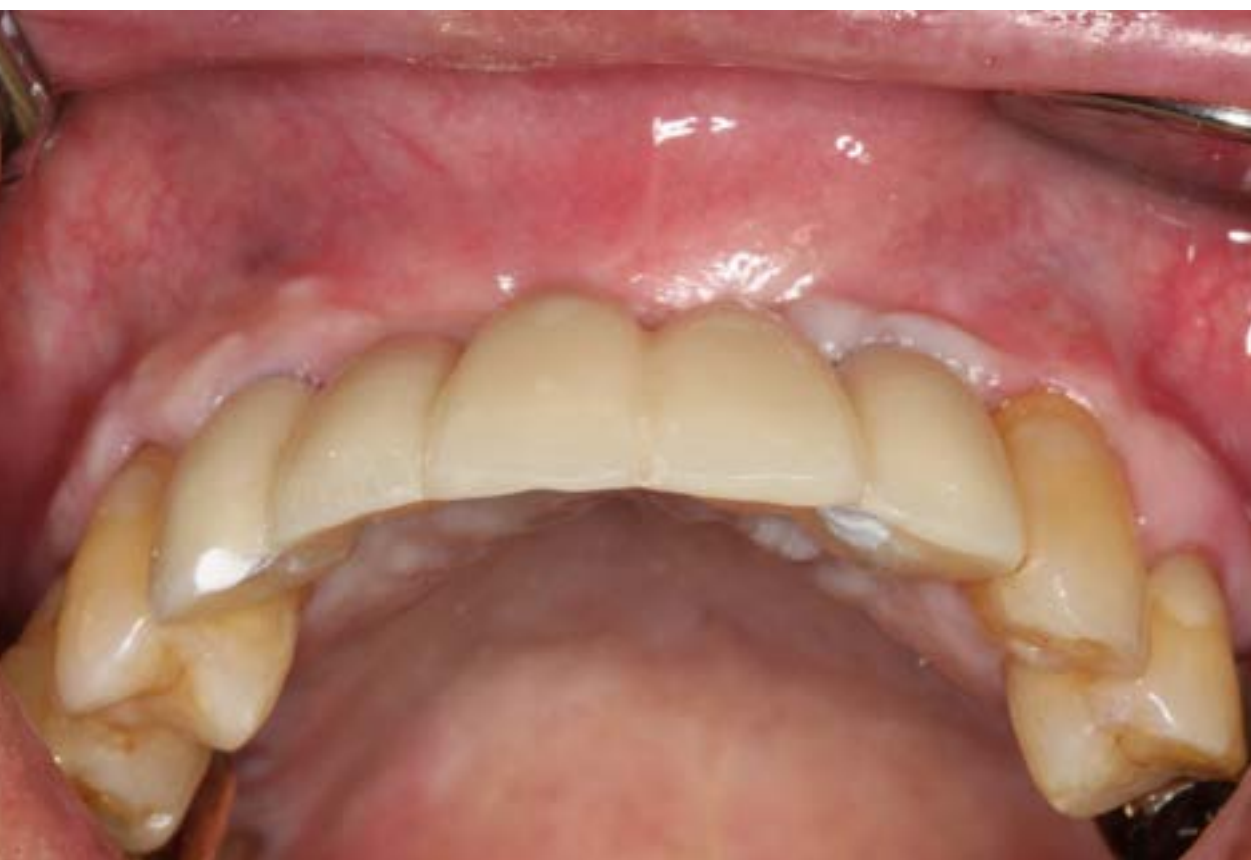

6 months later

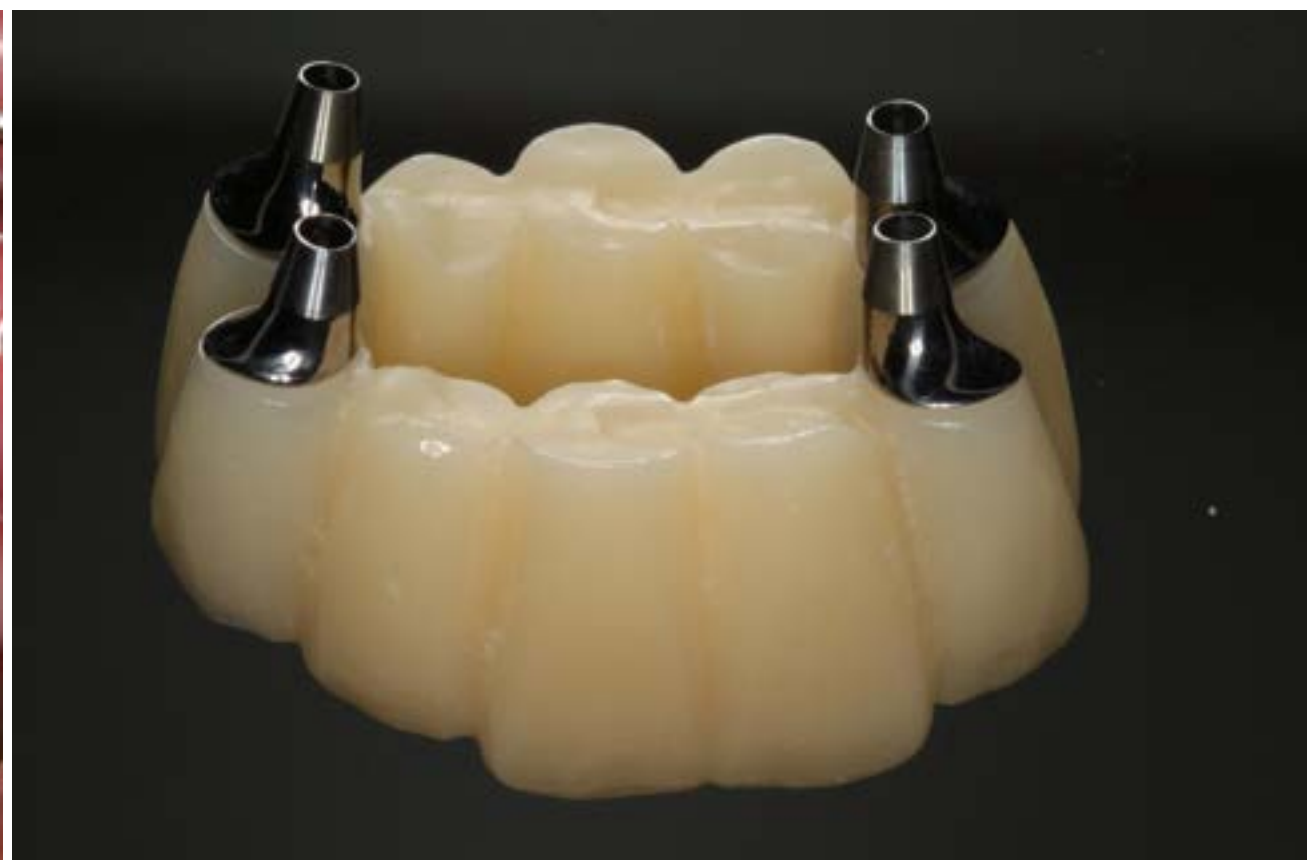



PMMA provisional

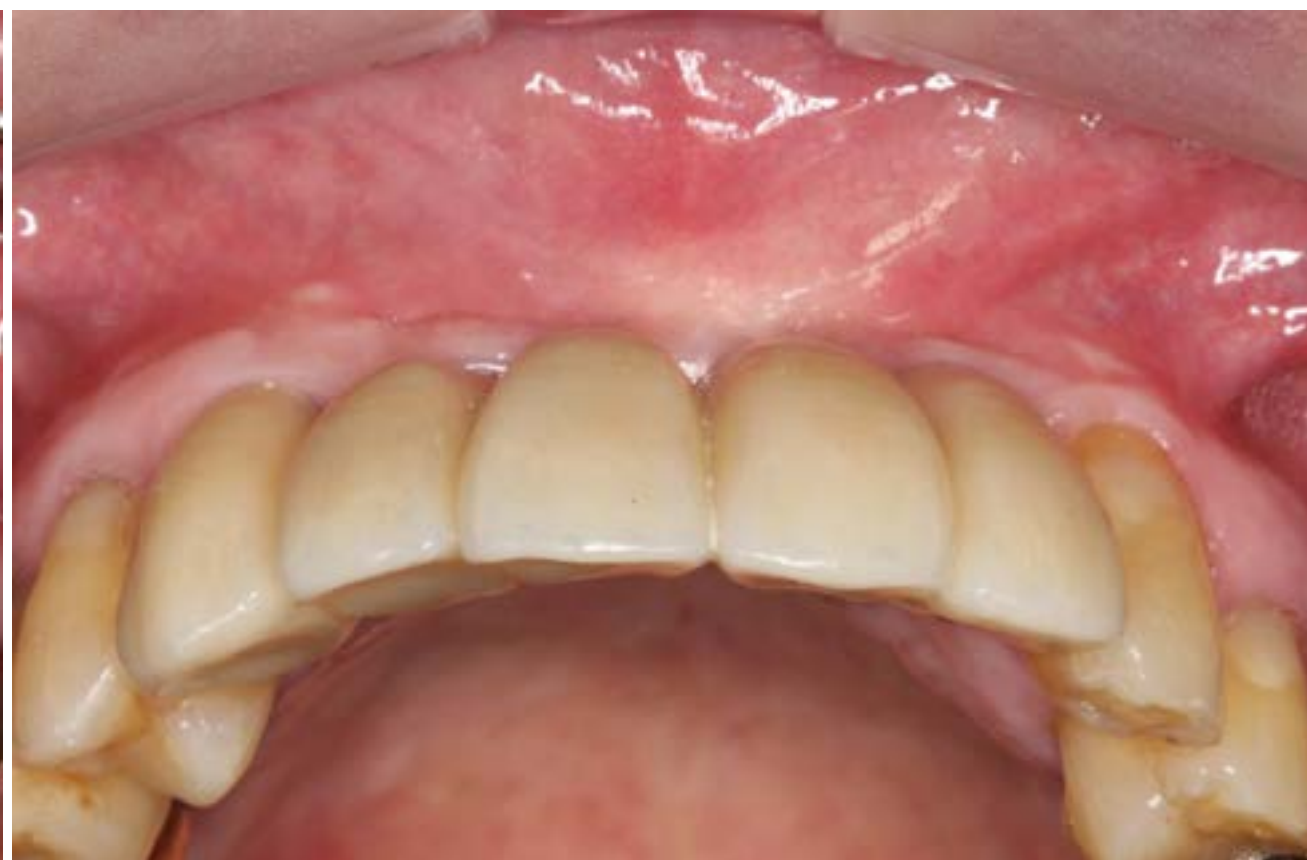

PMMA provisional

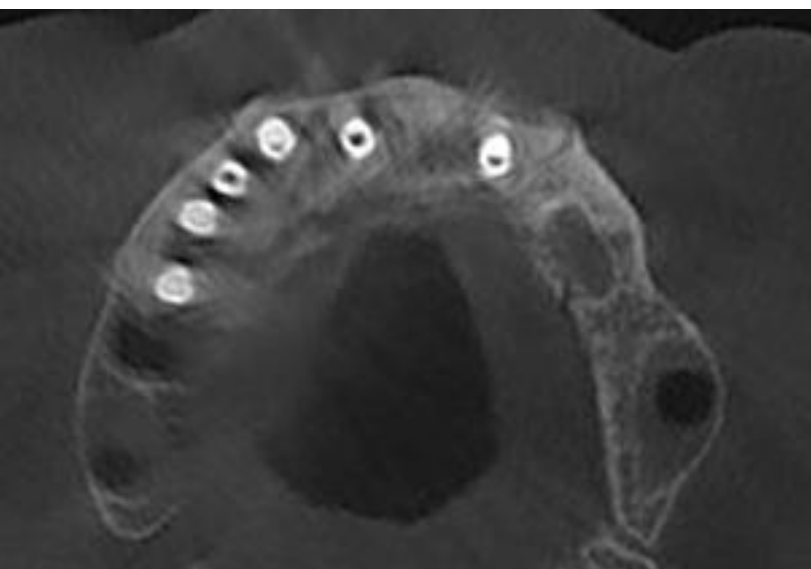




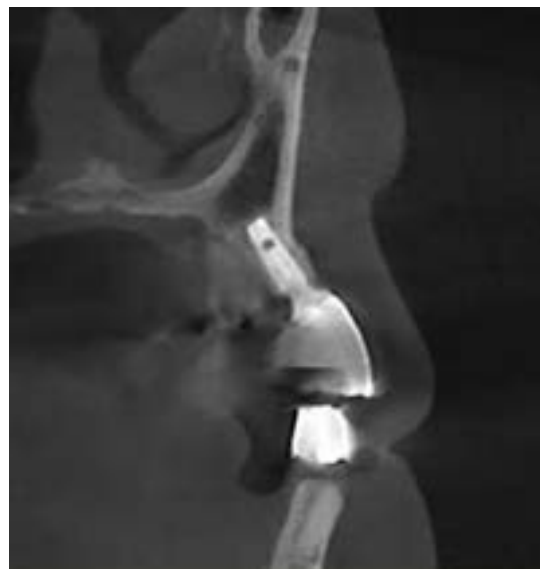PMMA provisional



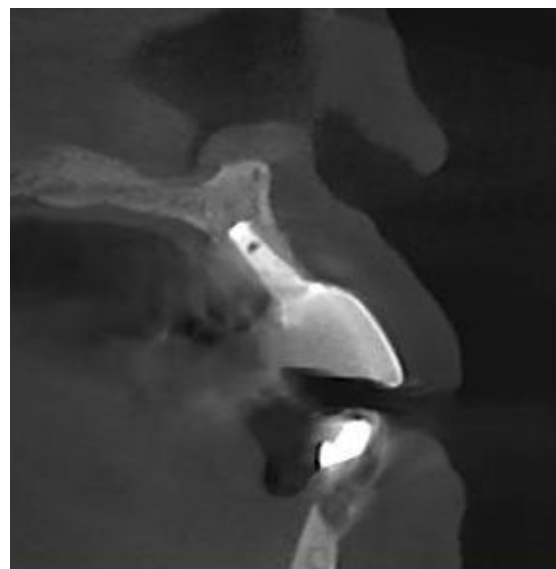
Zirconia final prosthesis



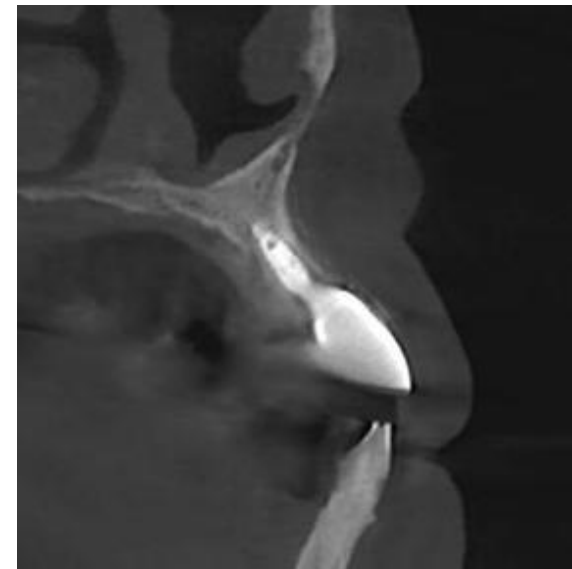
4.5 yrs F/U



#13



#12



#22

Narrow ridge를 극복하기 위한 방안 중 하나로 임플란트 형태에 대한 다양한 연구와 시도가 있어왔습니다.

Article

Wedge-Shaped Implants for Minimally Invasive Treatment of Narrow Ridges: A Multicenter Prospective Cohort Study

Tomaso Vercellotti ¹, Giuseppe Troiano ², Francesco Oreglia ³, Teresa Lombardi ⁴, Gianluca Gregori ⁵, Emanuele Morella ⁶, Antonio Rapani ⁷ and Claudio Stacchi ^{7,*}

¹ Department of Surgical Sciences and Integrated Diagnostics, University of Genova, 16100 Genova, Italy; tomaso@vercellotti.com

² Department of Clinical and Experimental Medicine, University of Foggia, 71122 Foggia, Italy; giuseppe.troiano@unifg.it

³ Private Practice, 37126 Verona, Italy; foreglia@yahoo.it

⁴ Department of Health Sciences, Magna Graecia University, 88100 Catanzaro, Italy; drtemalombardi@libero.it

⁵ Private Practice, 33012 Sappada (UD), Italy; gregorigg@libero.it

⁶ Private Practice, 20099 Sesto San Giovanni (MI), Italy; info@studiodrmorella.com

⁷ Department of Medical, Surgical and Health Sciences, University of Trieste, 34129 Trieste, Italy; rapani.antonio@gmail.com

* Correspondence: claudio@stacchi.it; Tel.: +39-0481-531-229

Received: 31 August 2020; Accepted: 13 October 2020; Published: 14 October 2020




Abstract: The present study aims to investigate clinical and patient-centered outcomes after the implant-supported rehabilitation of narrow ridges using a novel wedge-shaped implant. Forty-four patients were treated with the insertion of 59 tissue-level wedge implants (1.8 mm bucco-lingual width) in horizontally atrophic ridges (mean bone width 3.8 ± 0.4 mm). The main outcome measures were: implant stability quotient (ISQ), marginal bone loss (MBL) and patient morbidity. Fifty-eight implants were functioning satisfactorily after one year of loading (98.3% survival rate). ISQ values measured in the mesio-distal direction resulted significantly higher than those in the bucco-lingual direction at all time points ($p < 0.001$). Both mesio-distal and bucco-lingual ISQ values at 6-month follow-up resulted significantly higher than at 4-month follow-up ($p < 0.001$ for both). Mean MBL was 0.38 ± 0.48 mm at prosthesis delivery (6 months after implant insertion) and 0.60 ± 0.52 mm after one year of functional loading. The majority of patients reported slight discomfort related to the surgical procedure. Postoperative pain score was classified as mild pain on the day of surgery and the first postoperative day and no pain over the following five days. Within the limitations of the present study, the device investigated showed low morbidity and positive short-term clinical results in narrow ridges treatment.

Keywords: wedge implant; narrow ridge; piezosurgery; atrophic ridge; minimally invasive; patient-related outcomes


1. Introduction

The progressive resorption of the alveolar ridge after tooth extraction may lead to different degrees of jaw atrophy, resulting in reduced horizontal or vertical dimensions of the bone crest or in a combination of the above [1]. Insufficient bone volume can hinder implant therapy by causing two main problems: impossibility to insert the fixture in an adequate bone envelope and difficulty to place the implant in an optimal prosthetic position. The use of implants of reduced diameter has been proposed to overcome this situation. However, recent meta-analyses showed

Dentium Implant System



bright BL




NRLine



Implantium II




SuperLine



SlimLine



SimpleLine II



bright TL



bright **BL**


bright BL



Bone Level Implant – Thread

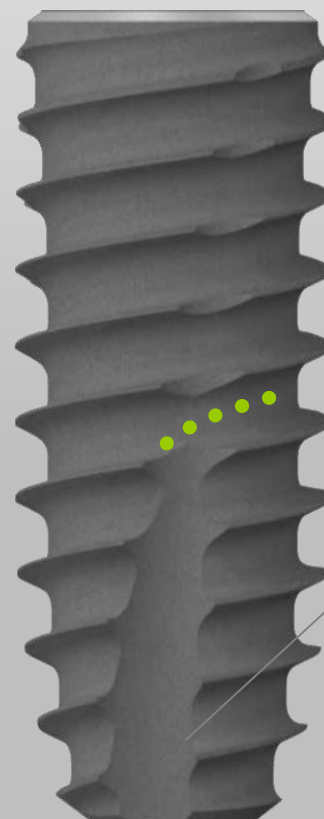
For Simplified Surgical Procedure

- Long Cutting Edge & Aggressive Thread
- Final Drill Only (except FX 6.0)




Pitch 0.80

Double thread



Aggressive Thread Design



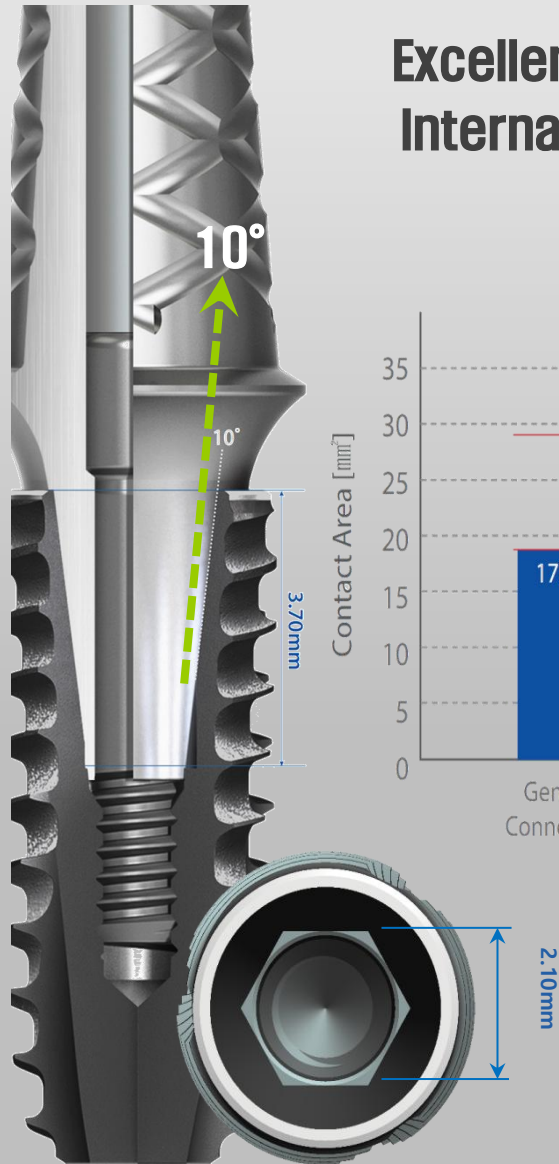
Long Triple Cutting Edge

Bone Level Implant – Connection

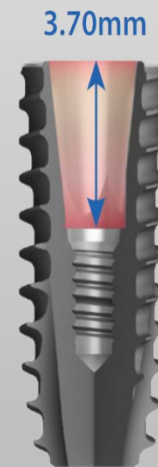
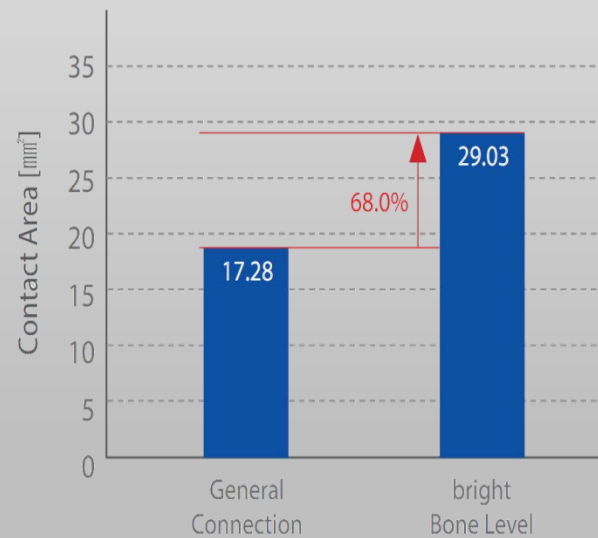
bright

10° , 3.70 mm Deep Connection

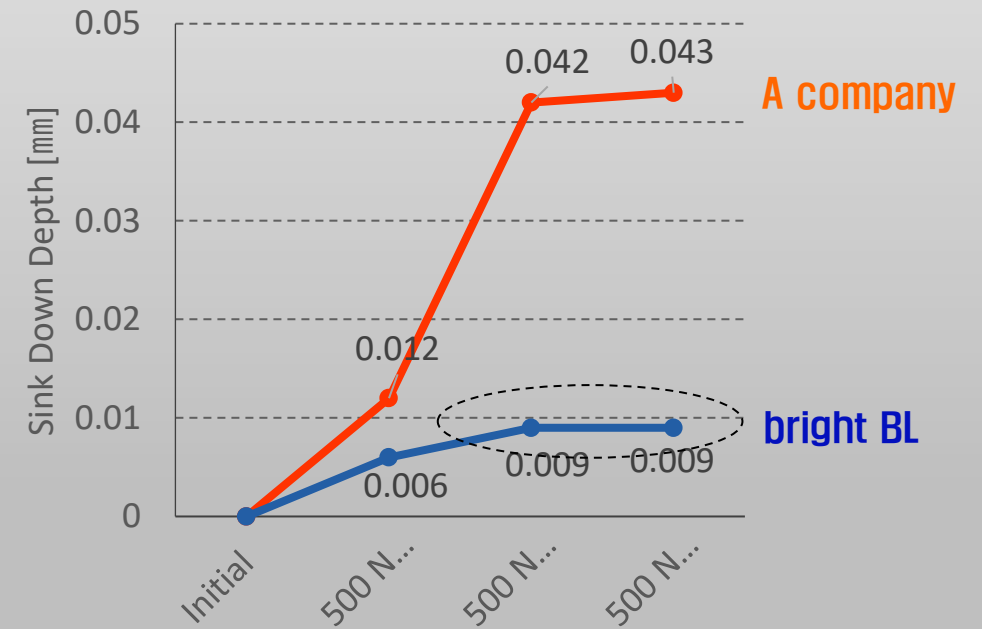
Excellent Joint Stability
Internal Hex 2.10



Contact Area

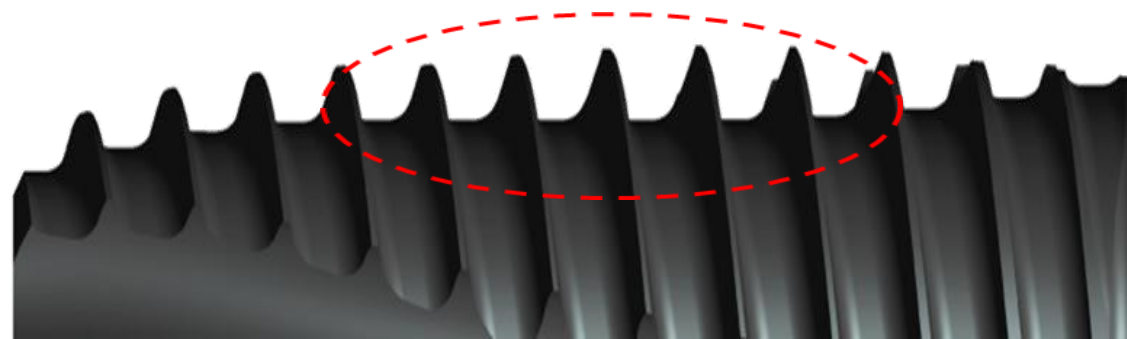
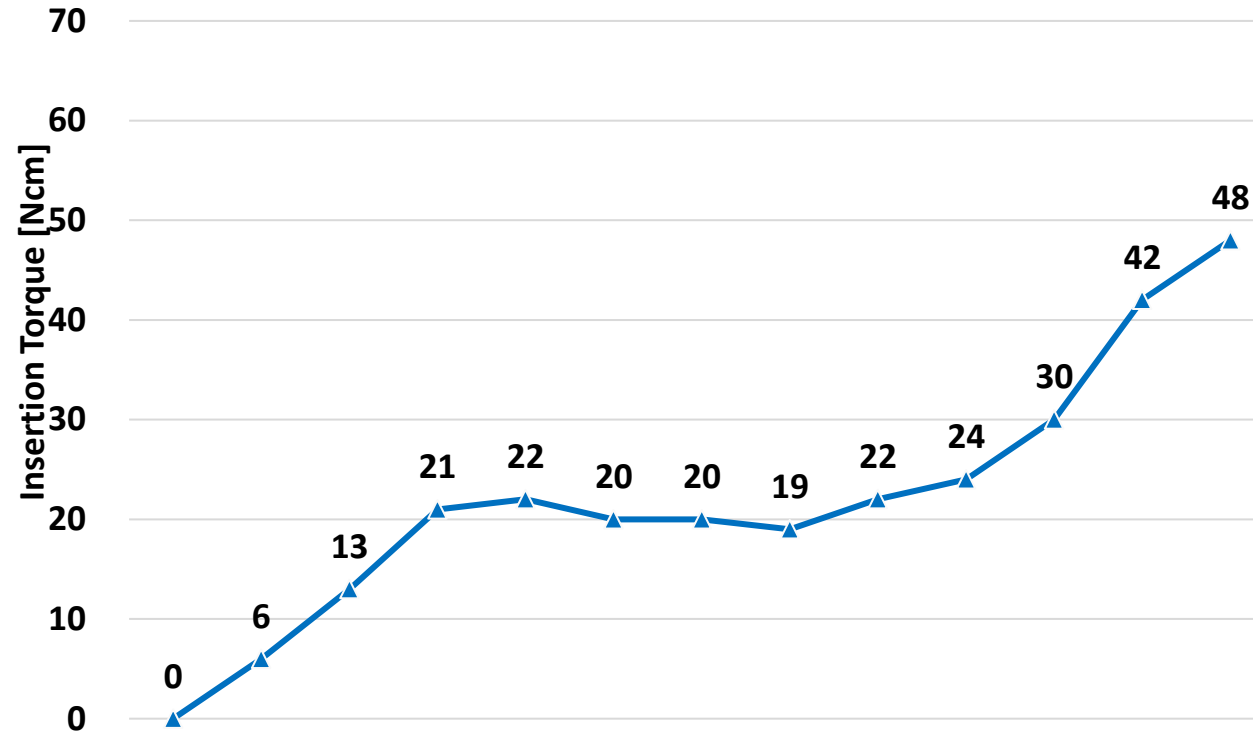


No more Sink Down



Insertion Torque Pattern @ Type 2 bone

This pattern is advantageous in hard bone



Abutment connection



S.L.A.

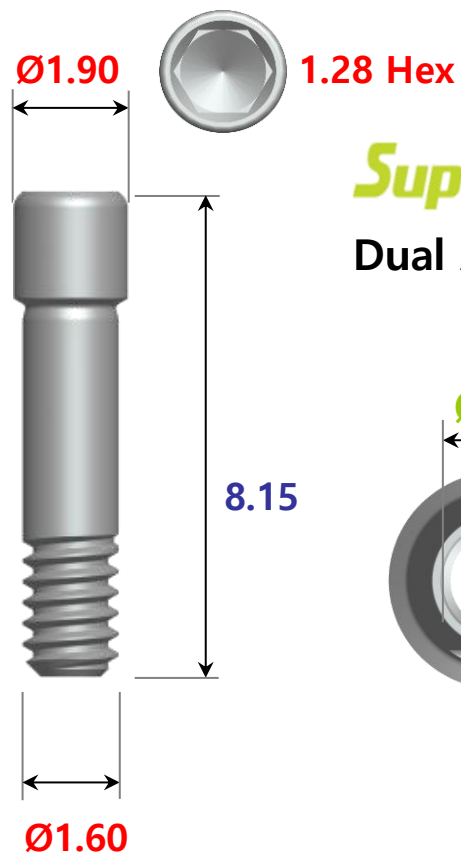
Single Connection



Ti grade 4

bright BL prosthetic line-up

Abutment Screw



SuperLine II

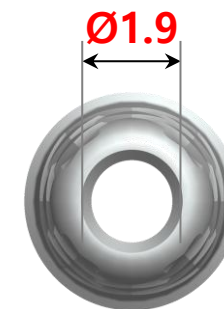
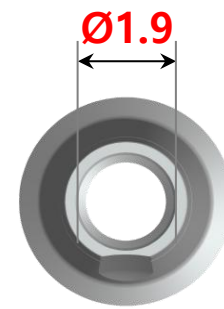
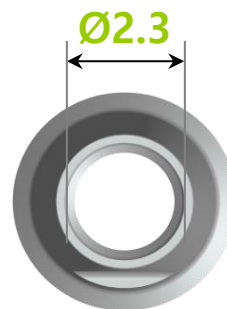
Dual Abutment

NR Line

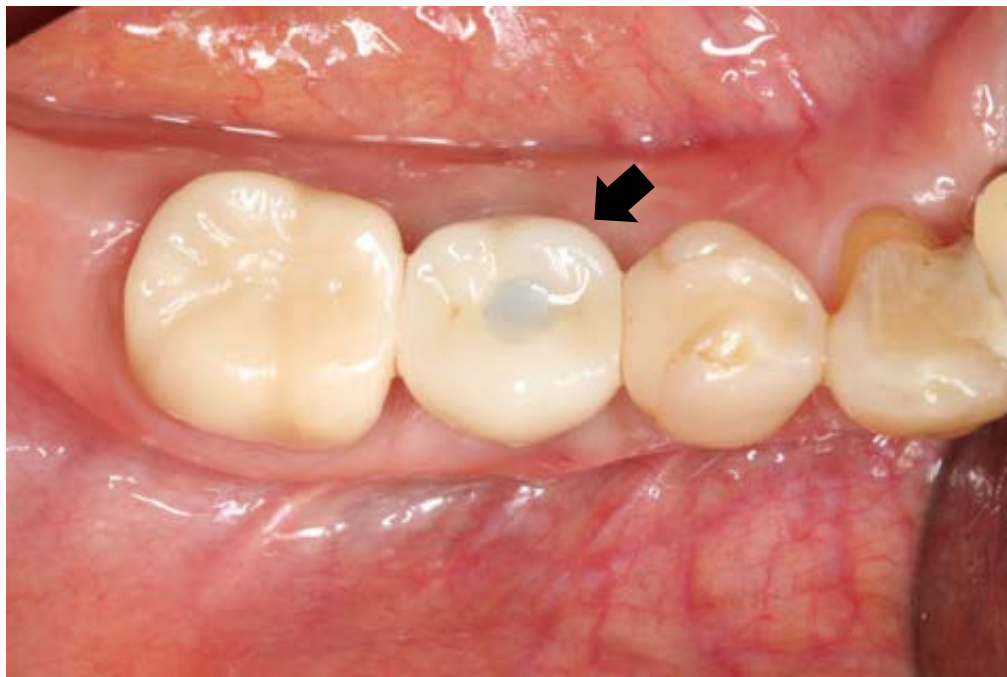Dual Abutment

bright

Metal Link



※ Recommended Torque : 20 N.cm



smaller screw hole

SuperLine

bright



screw drivers are available in both system



Superline

bright



same size hex

Superline

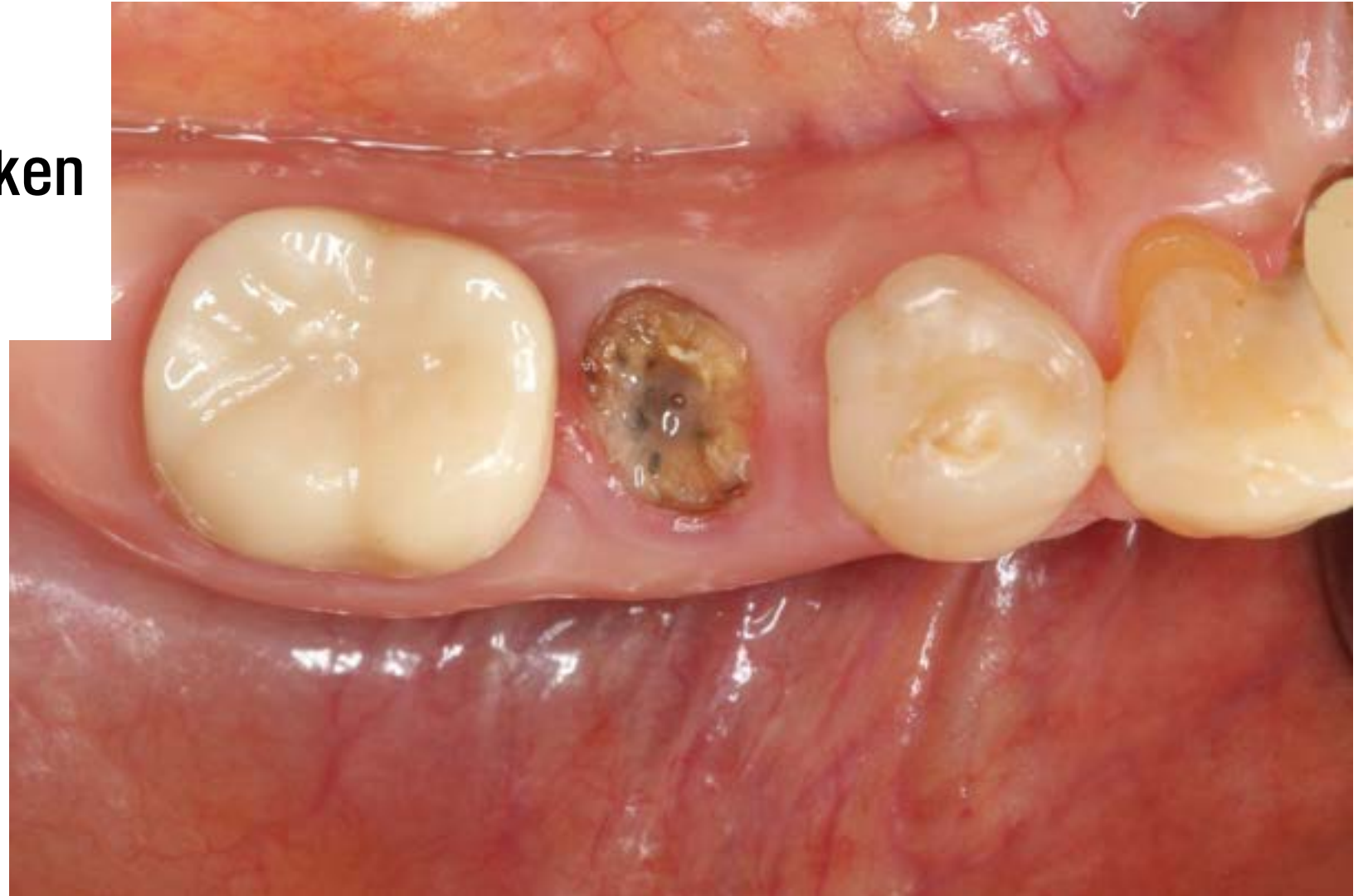bright

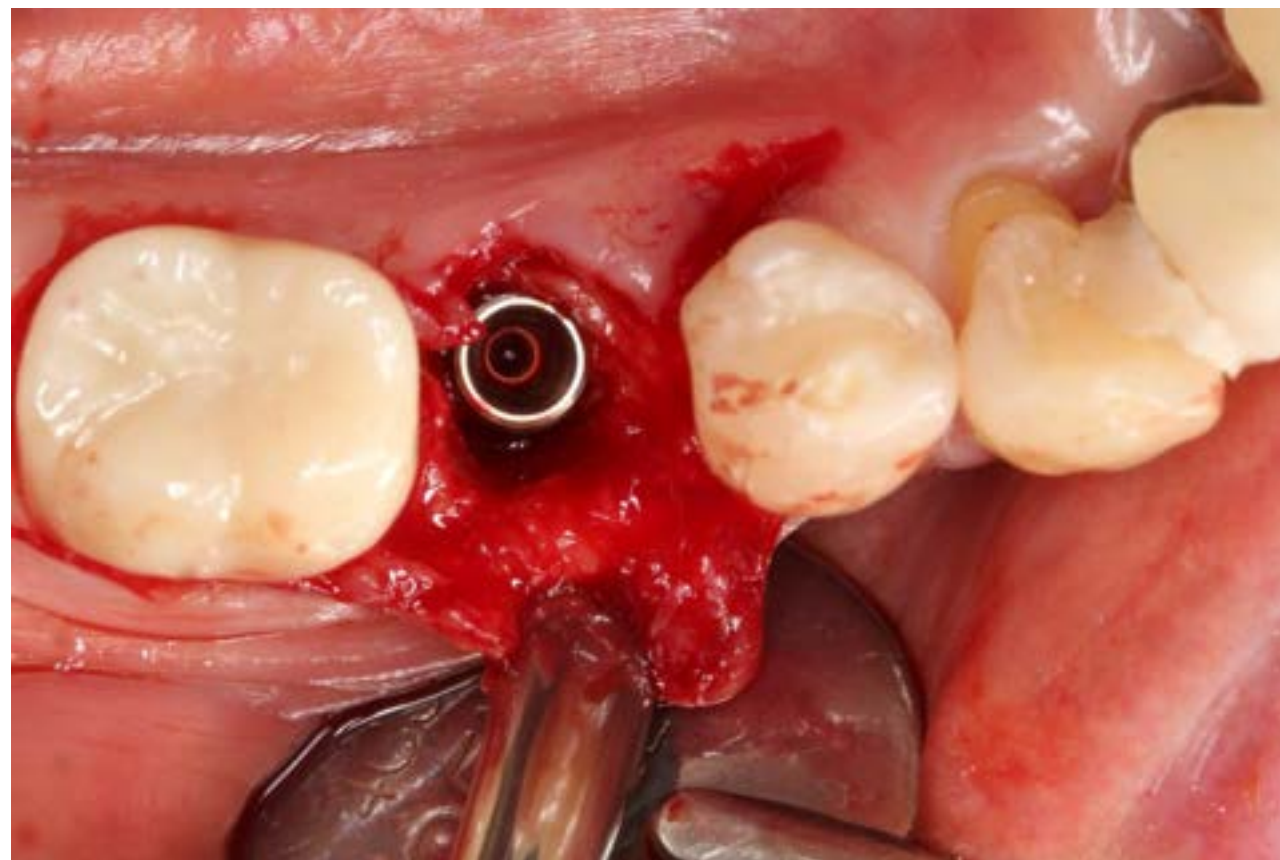
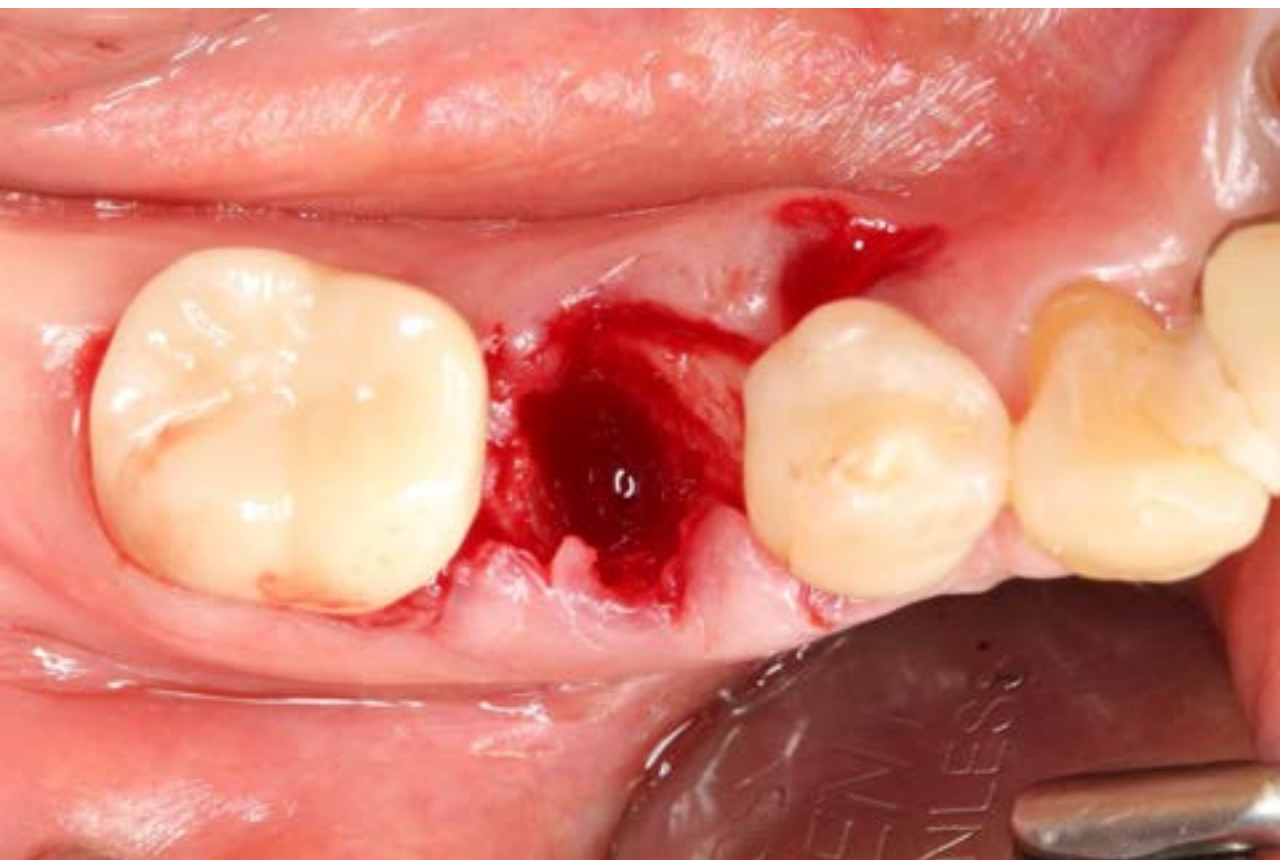bright BL : immediate socket

Pt. : Oh, J S (78, F)

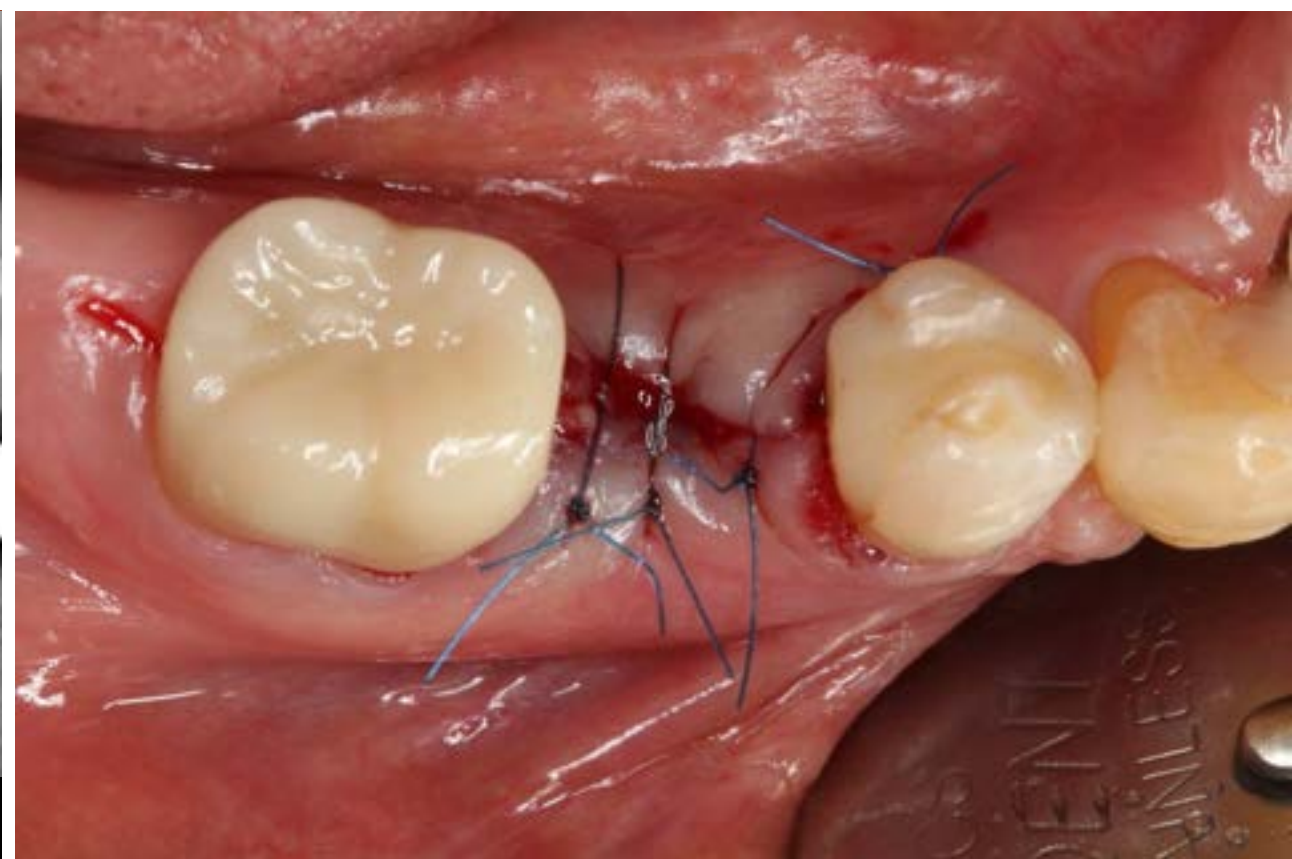
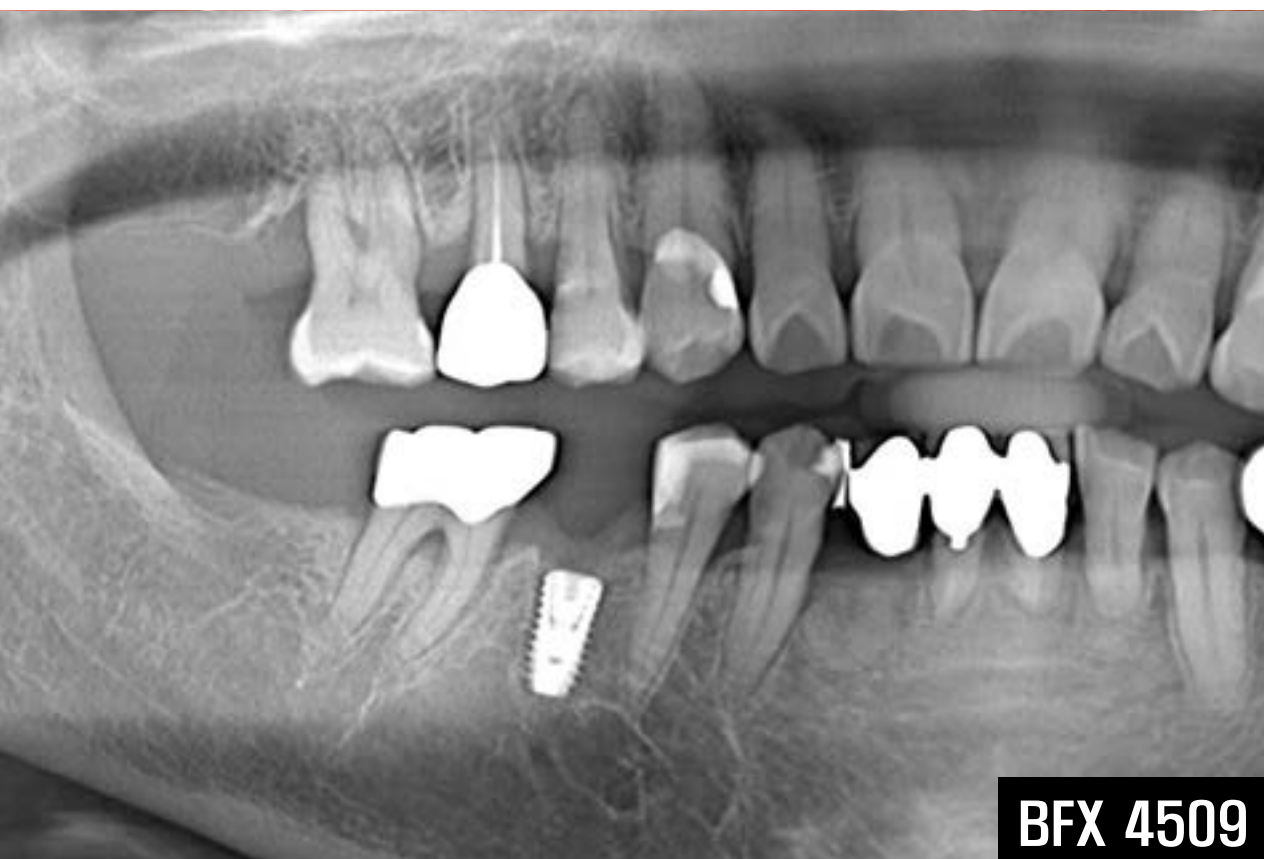
C.C. : my tooth was broken

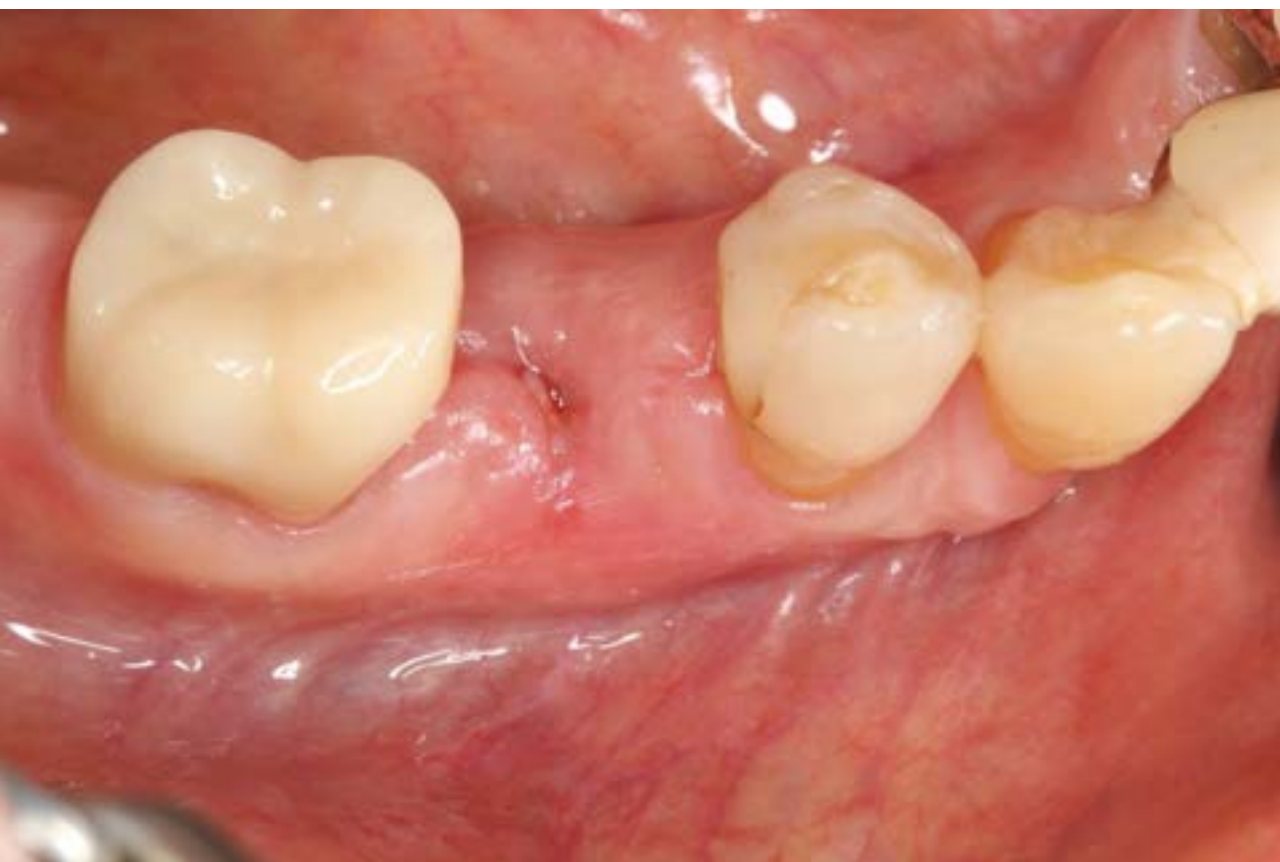immediate implantation



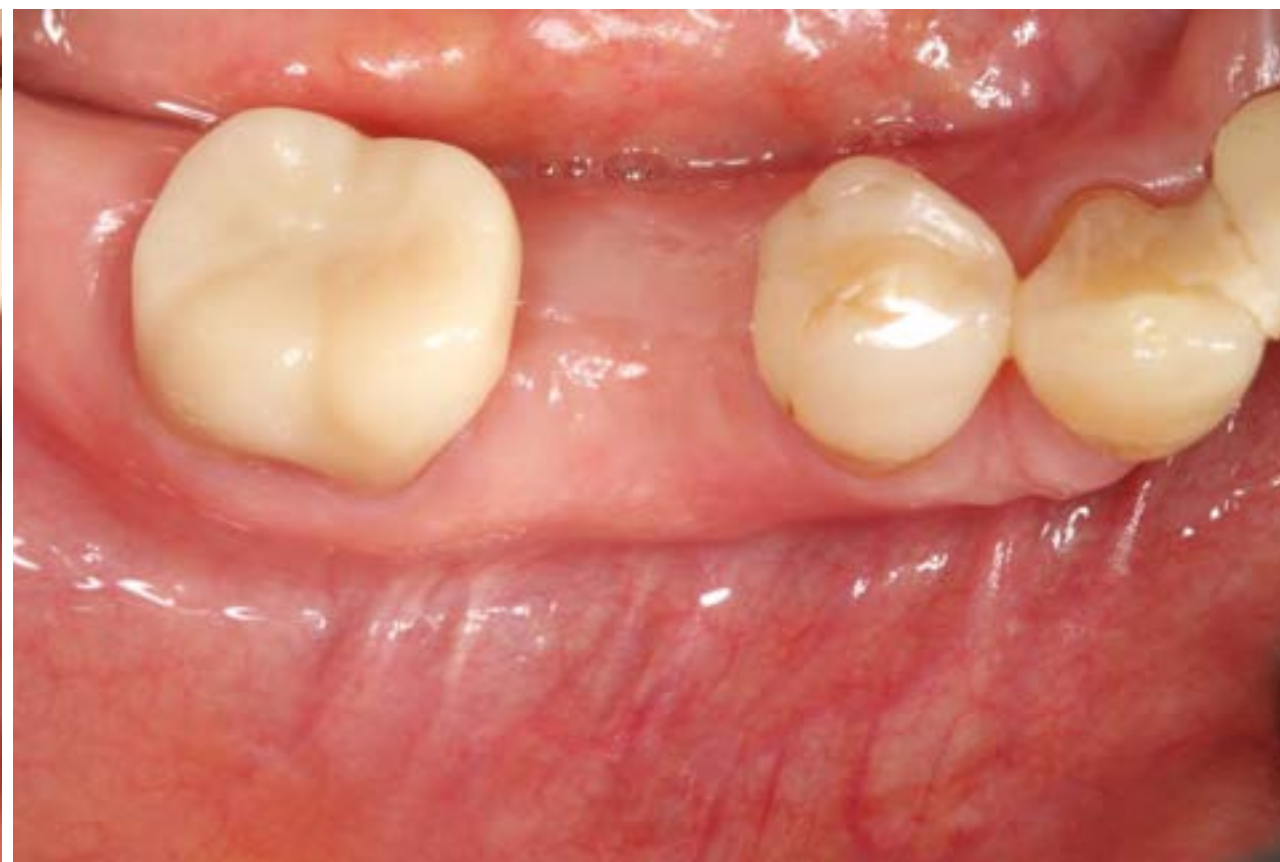

No counter sink drill, No tilting tendency

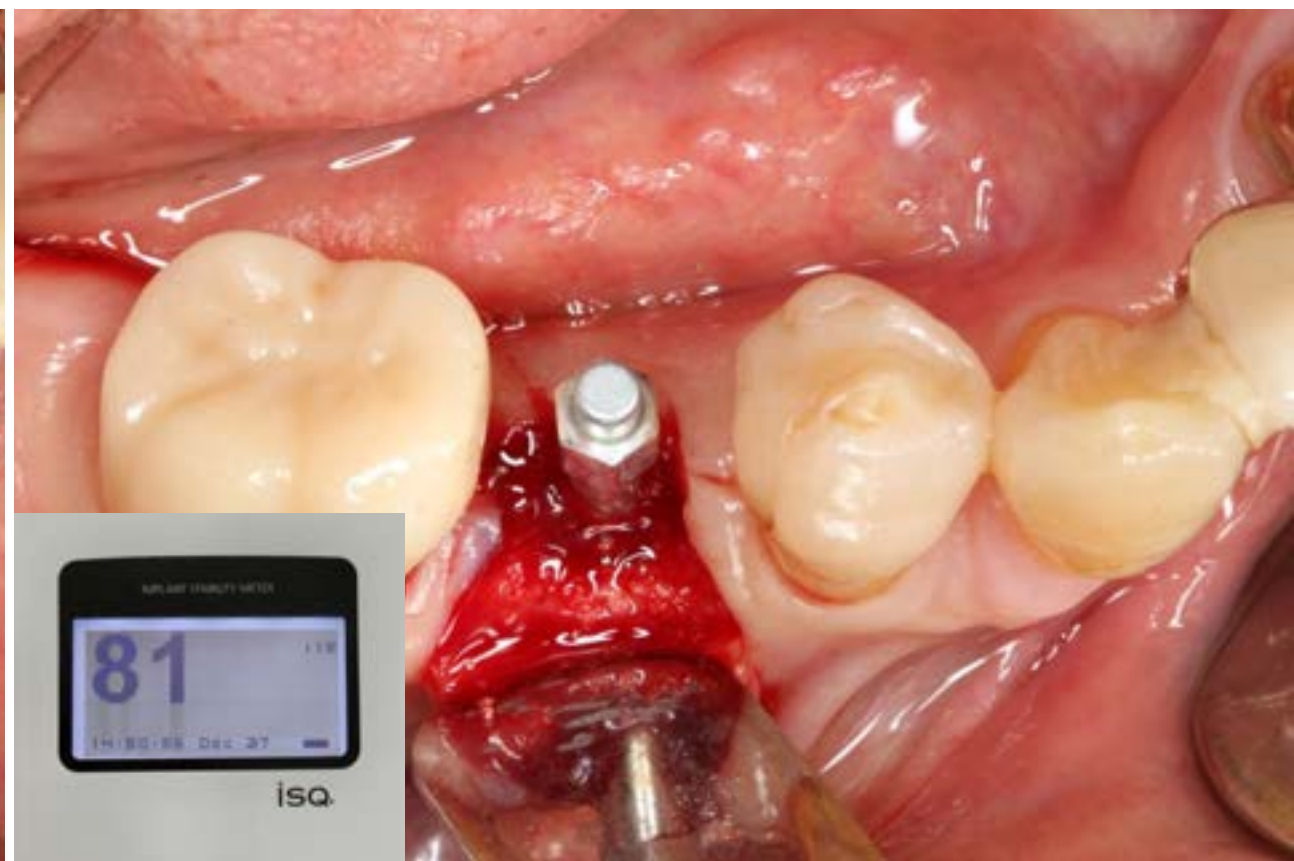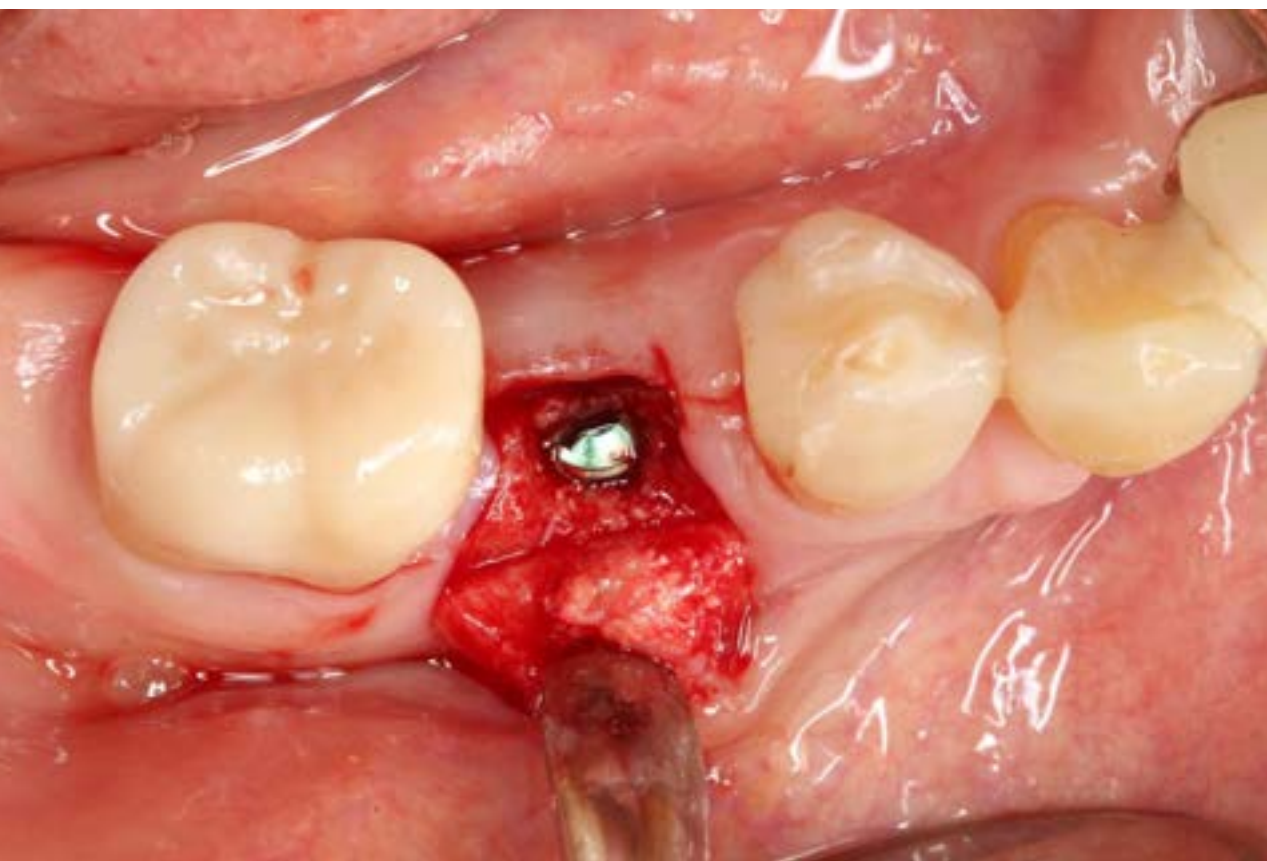


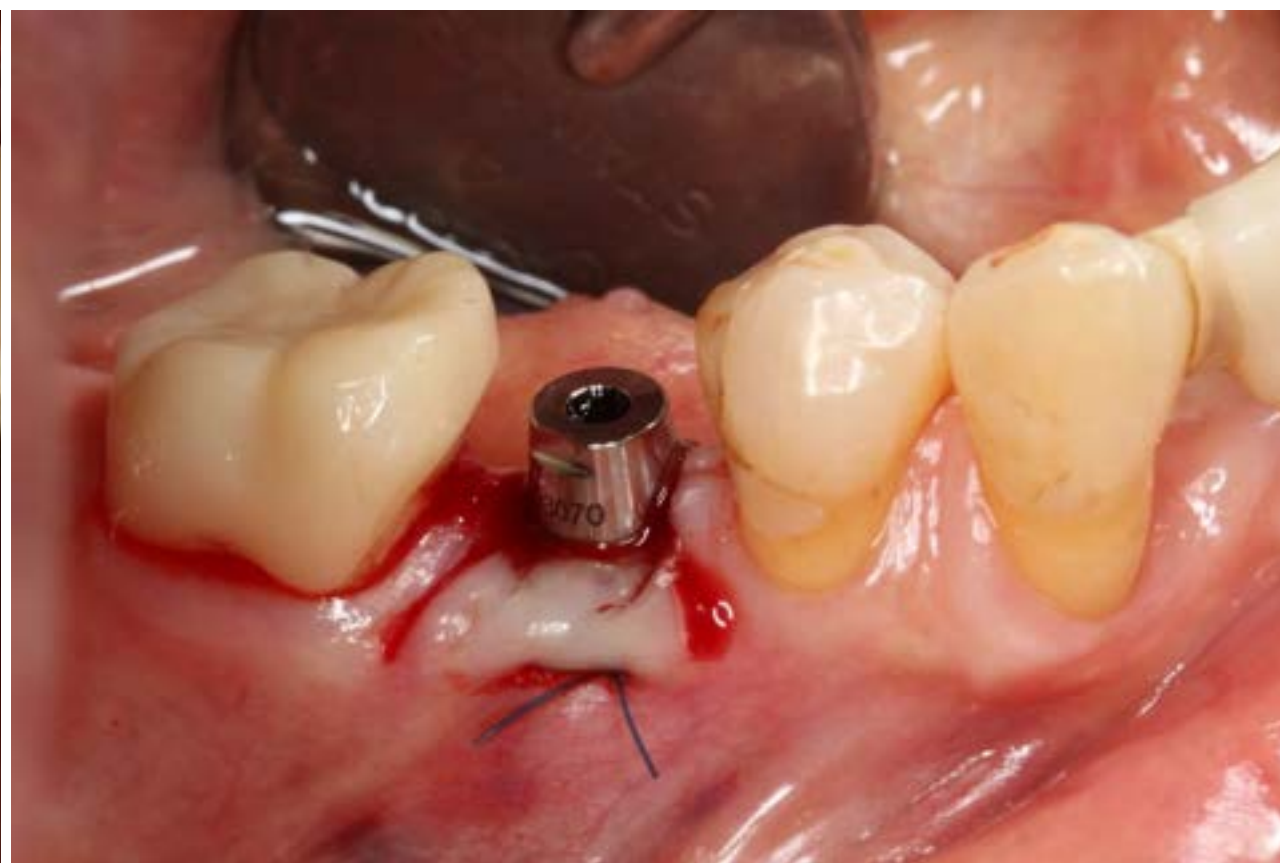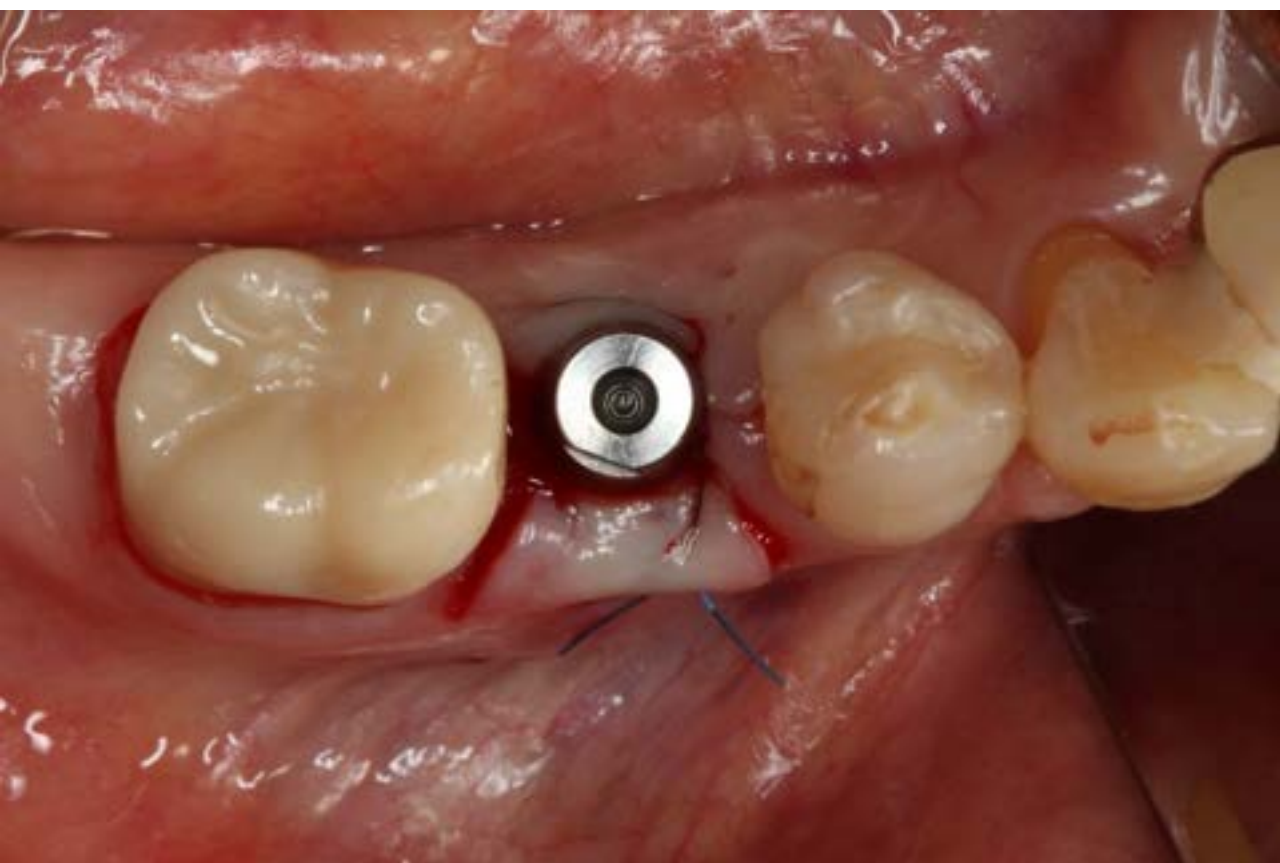


2 weeks later

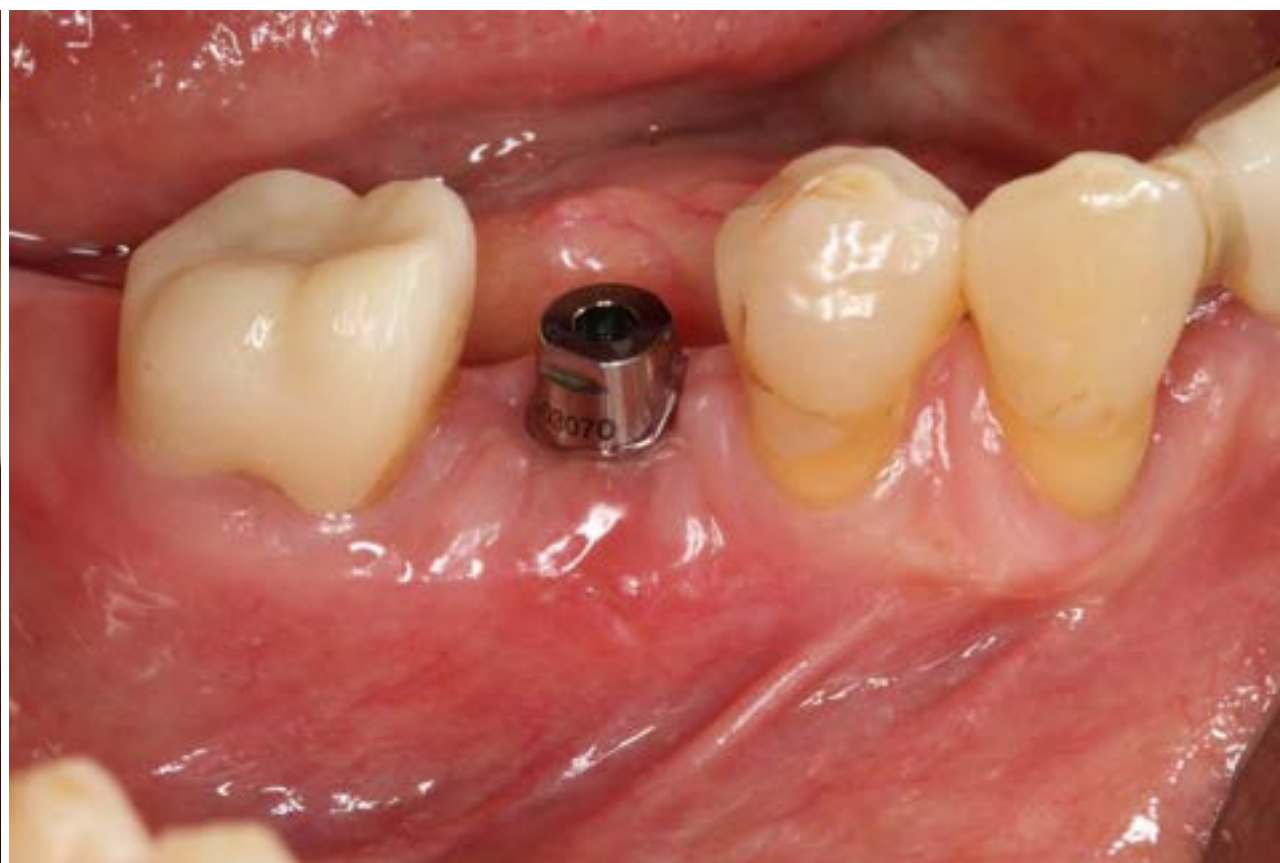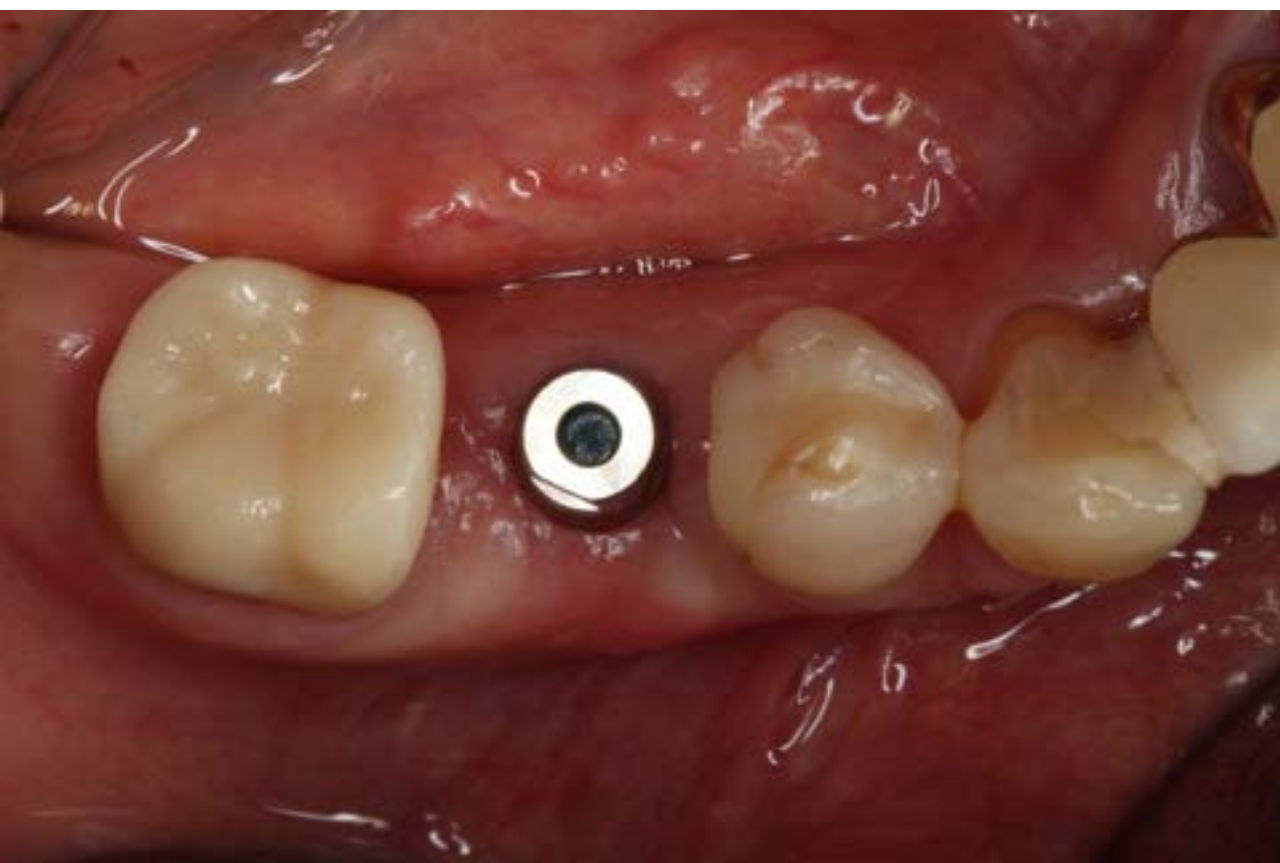


2 months later

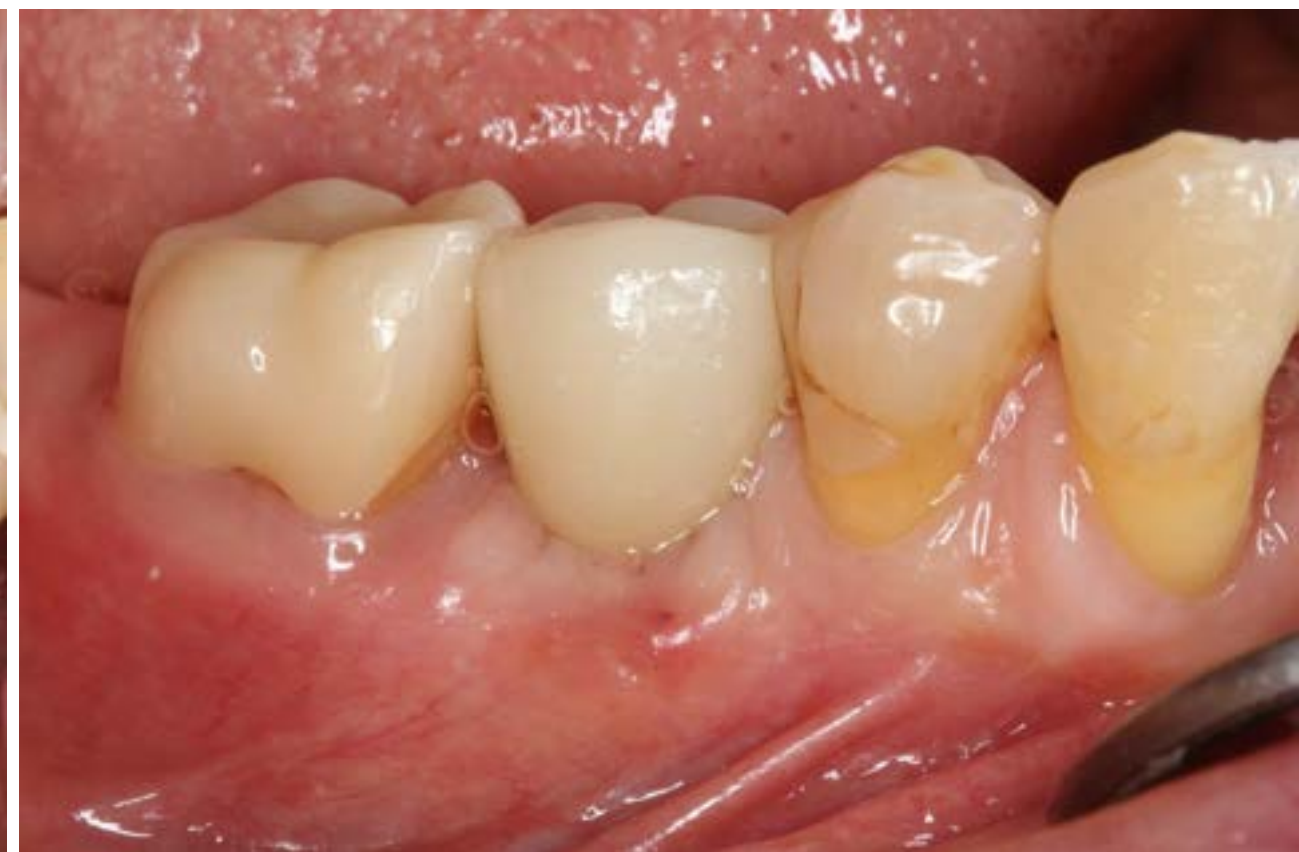
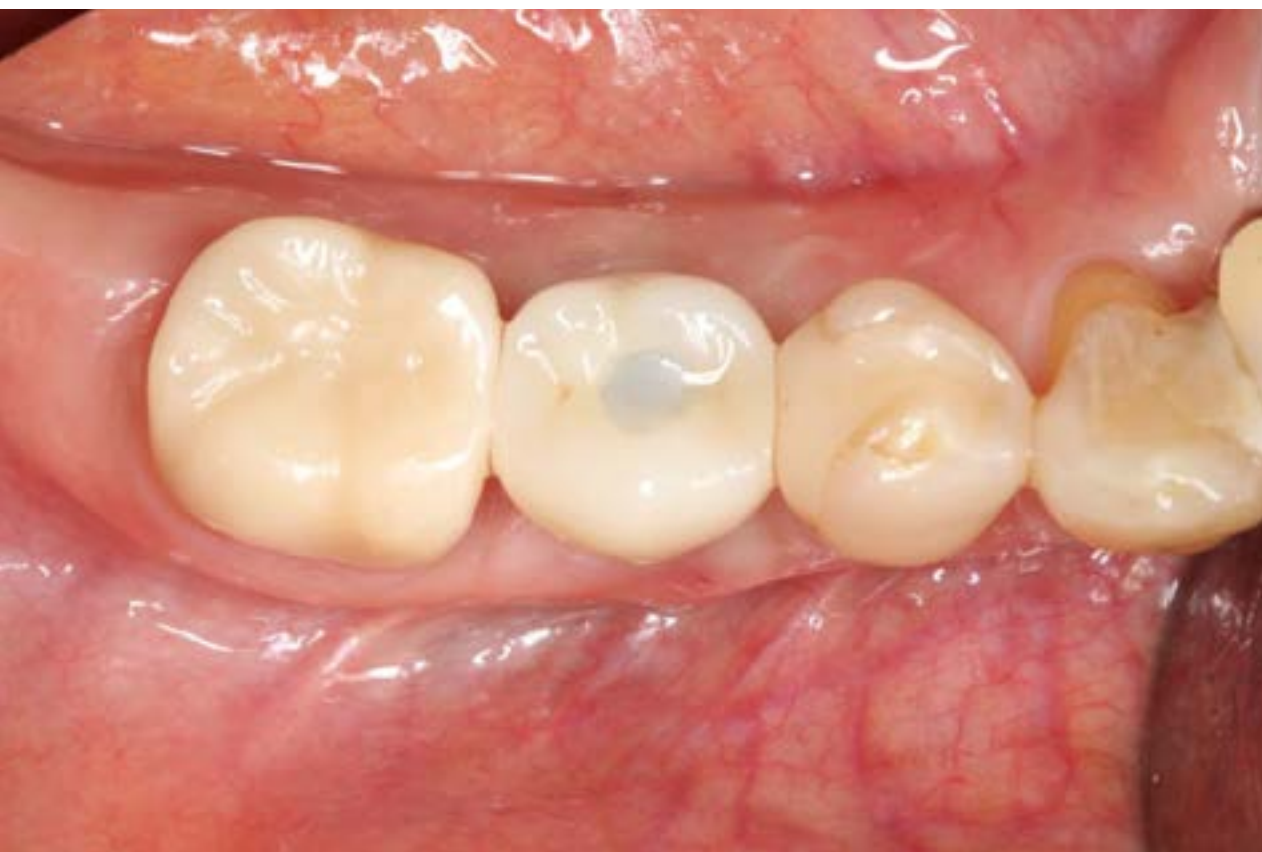


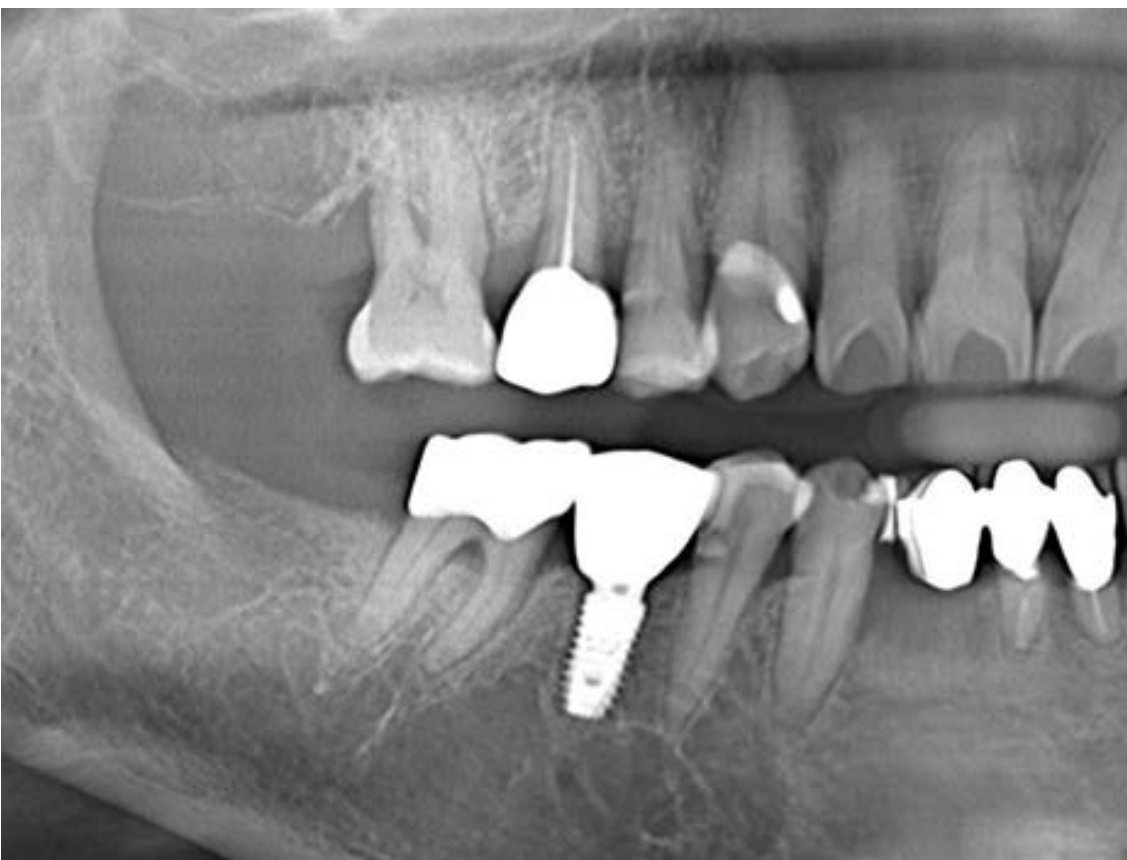
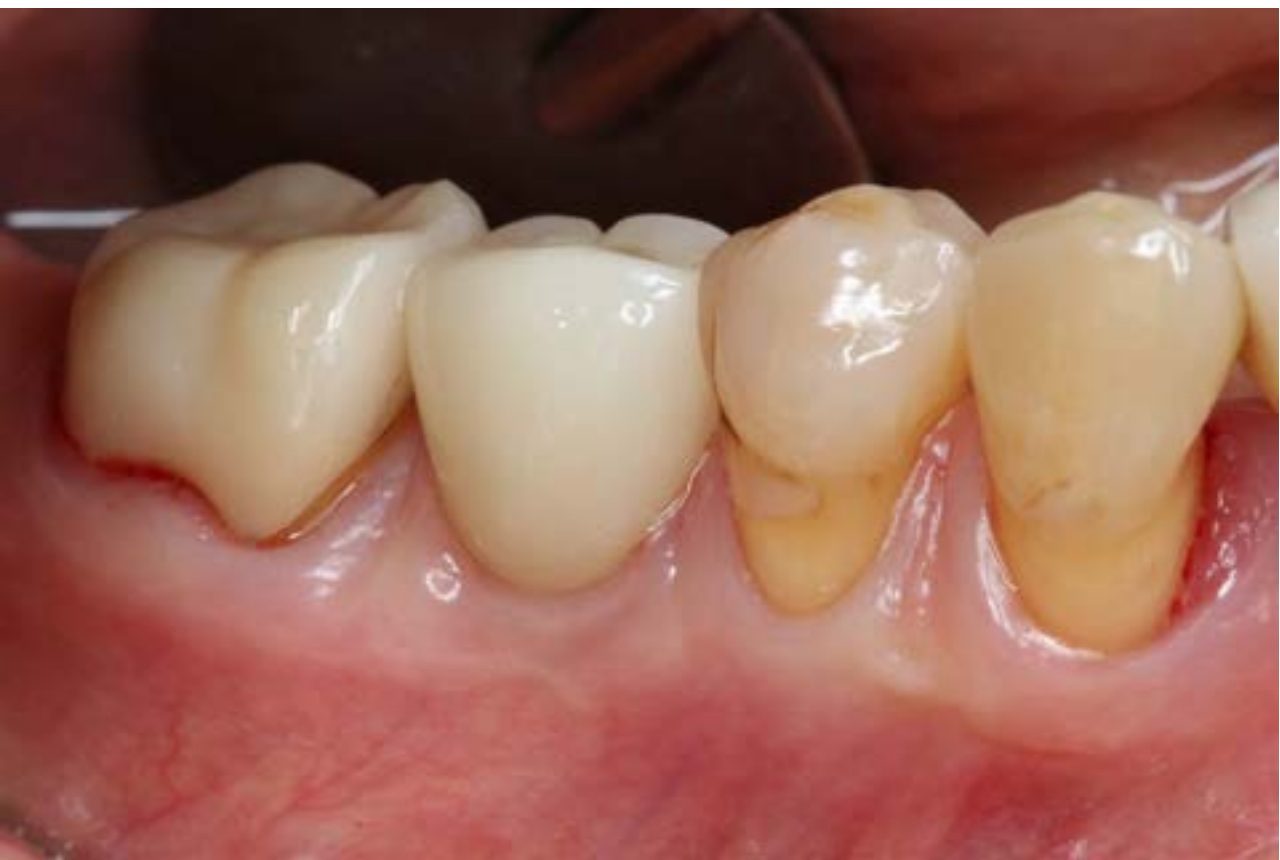Flap folding suture, Scan abutment, Digital impression



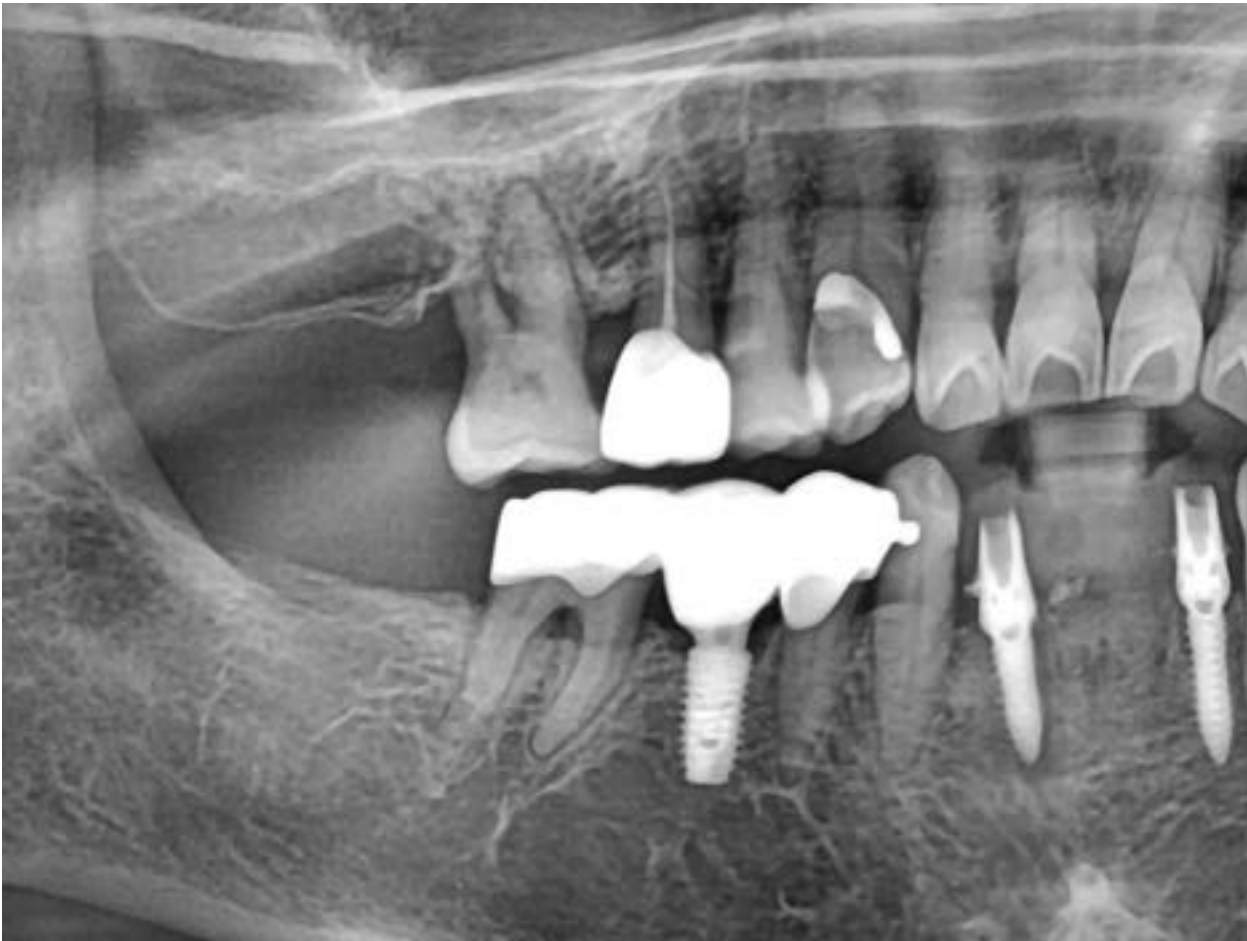2 weeks later : healing



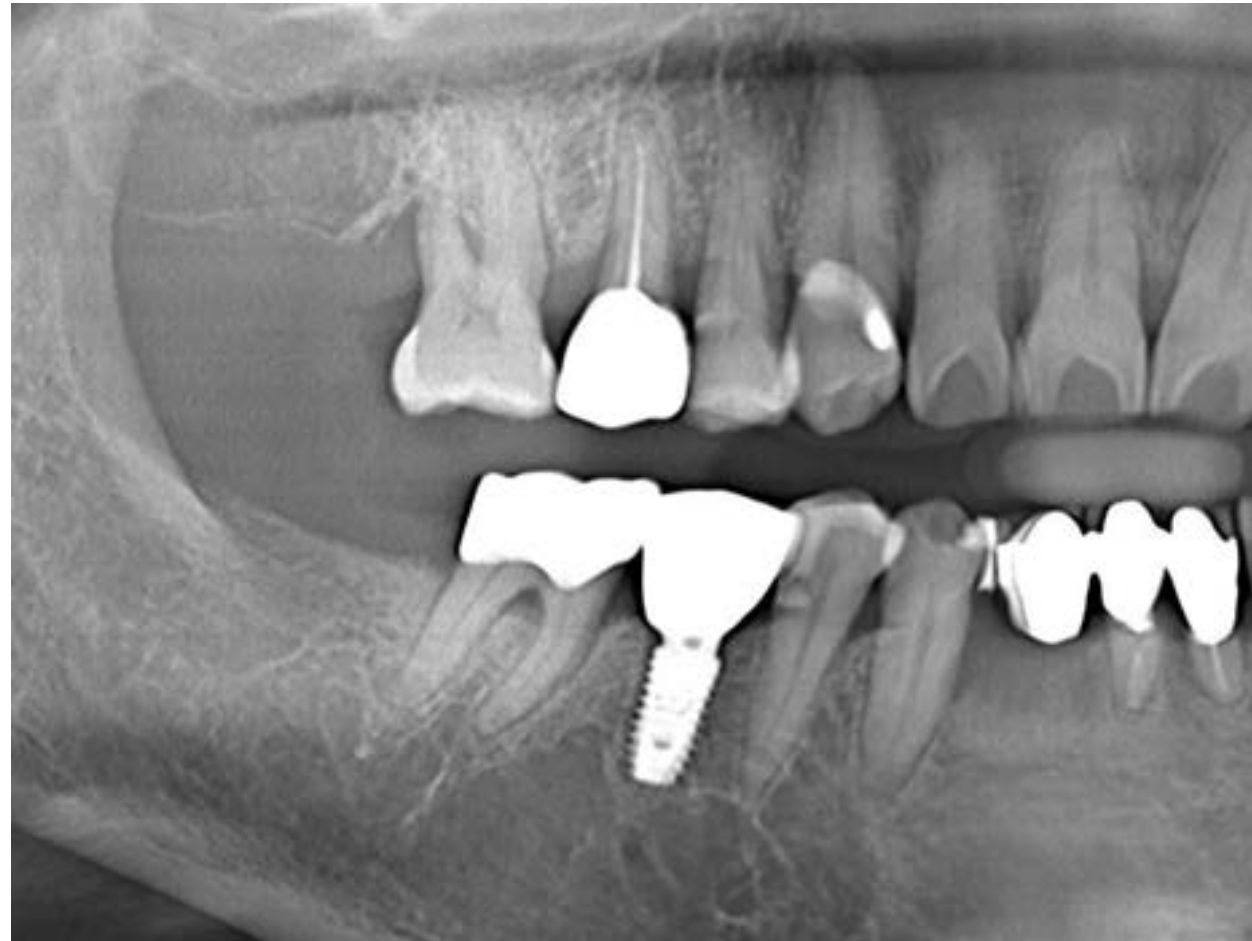
Final prosthesis



2 years F/U



4 years F/U




2 years F/U

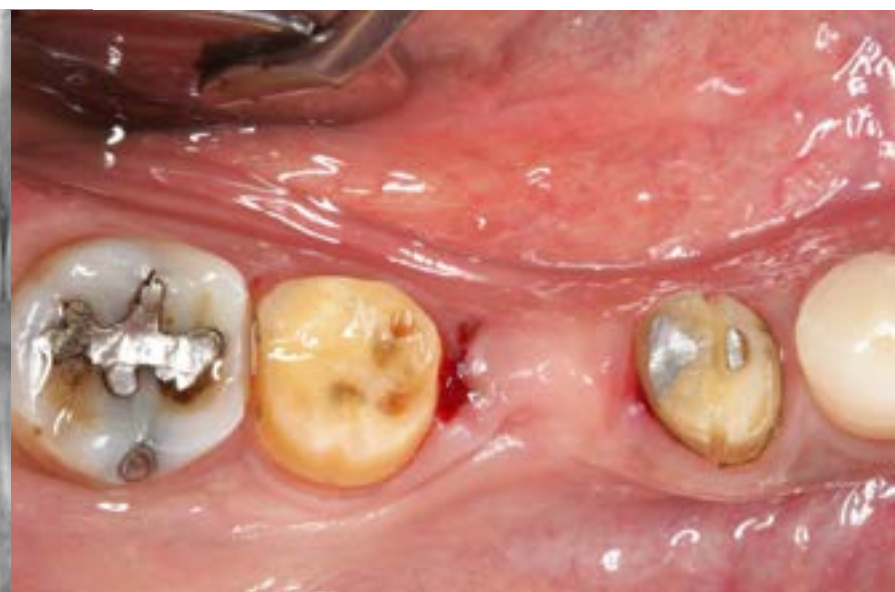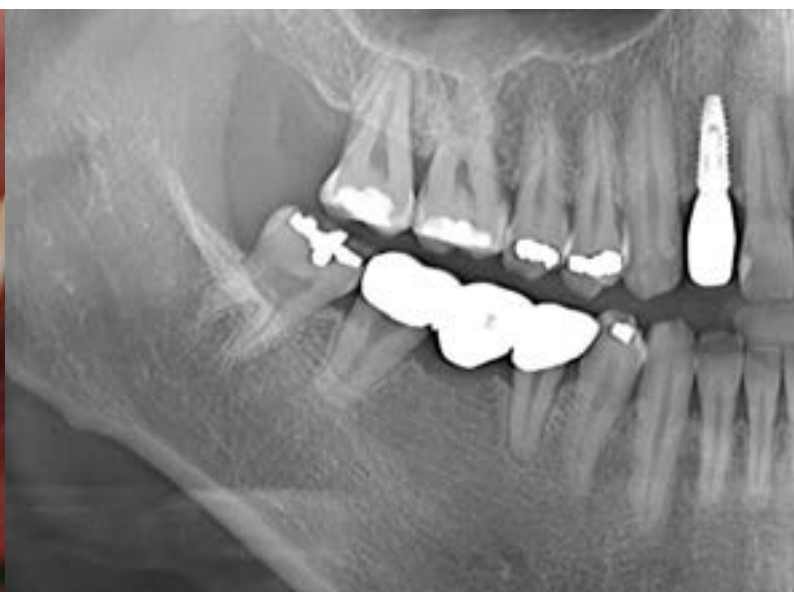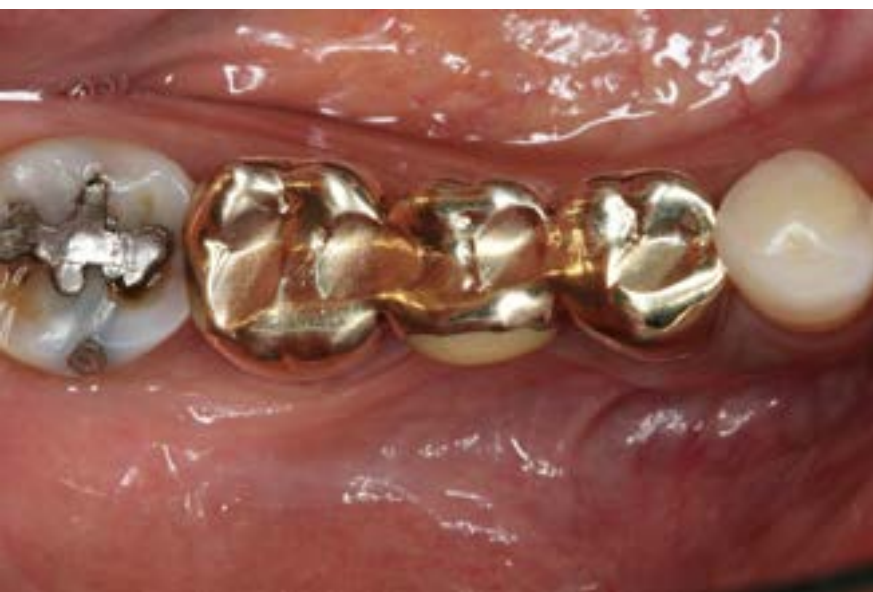bright BL

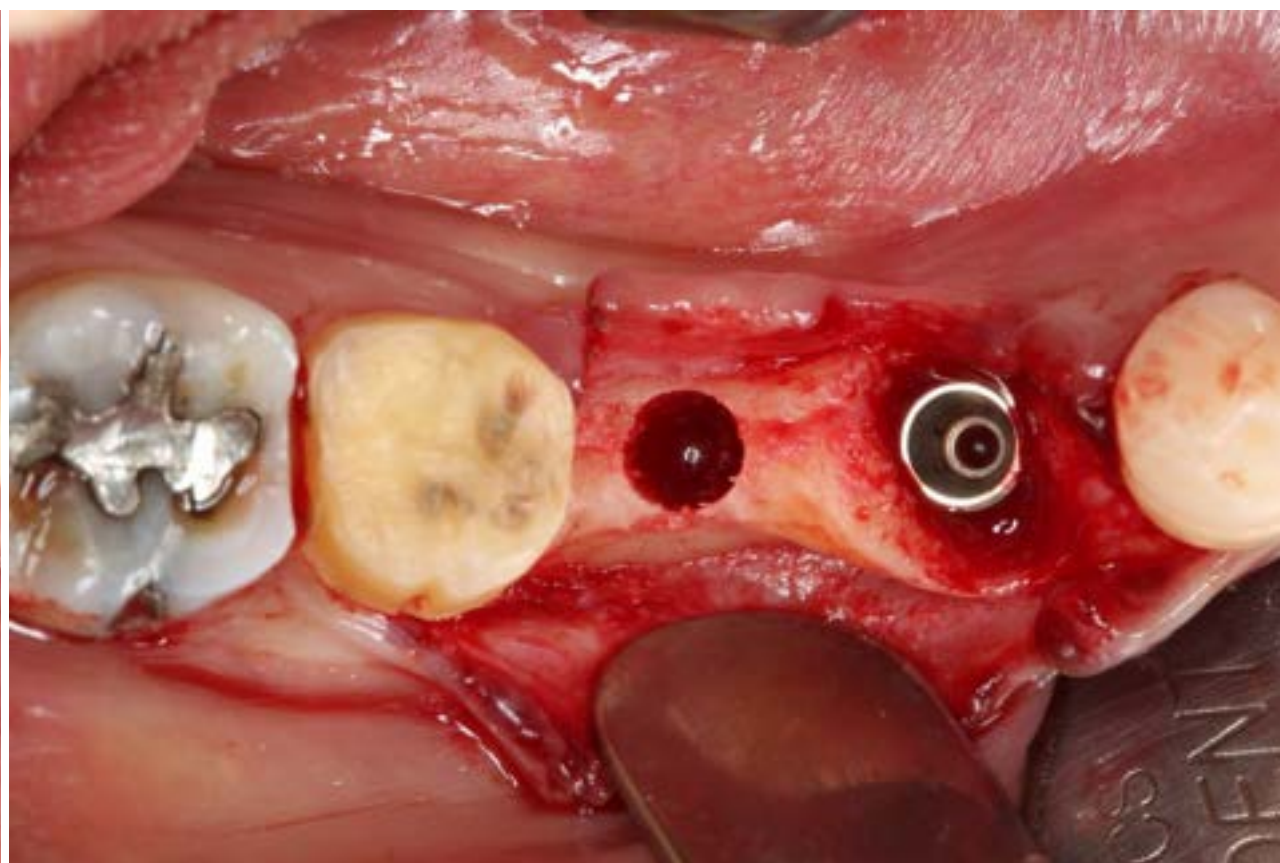
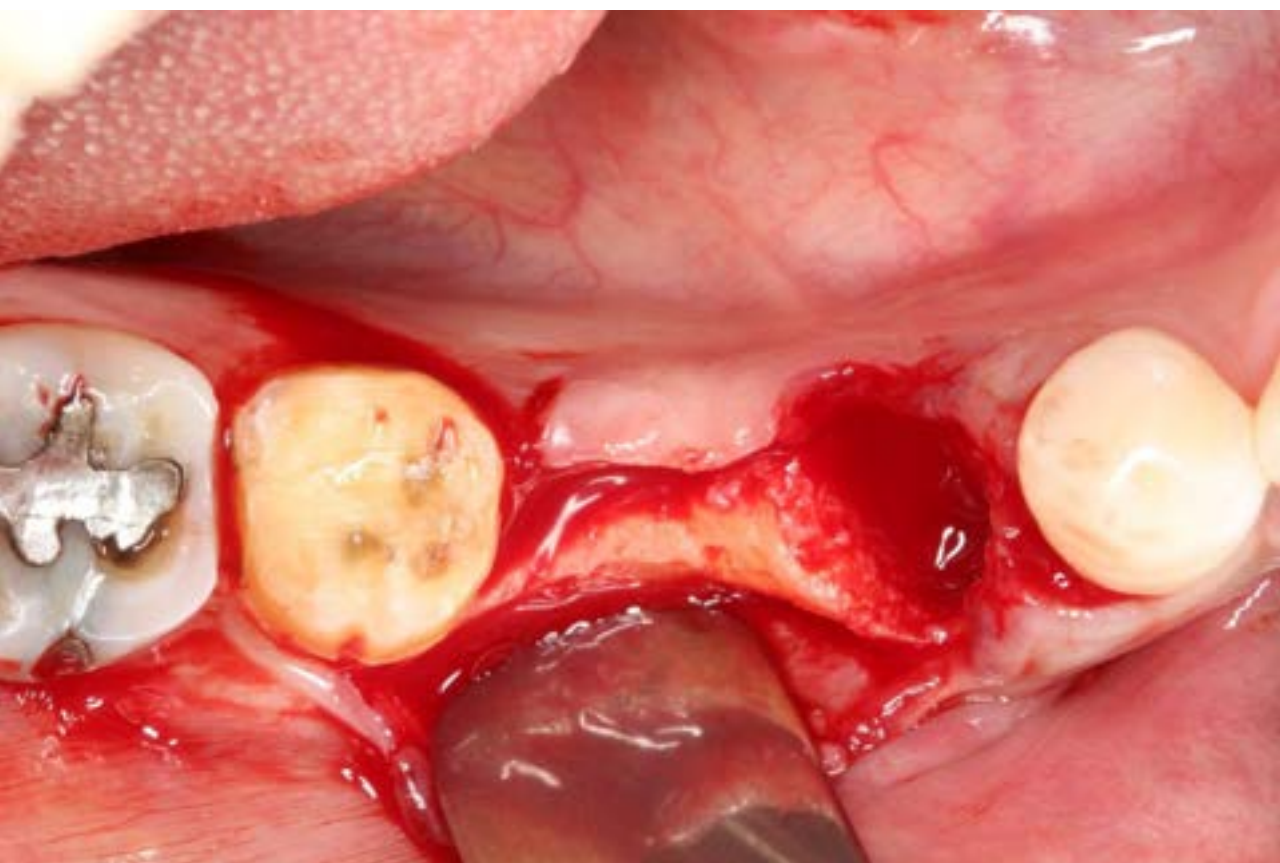
10° , 3.70 mm Deep Connection

Pt. : Park, Y I (41, M)
C.C. : I want to have a new teeth
immediate implantation

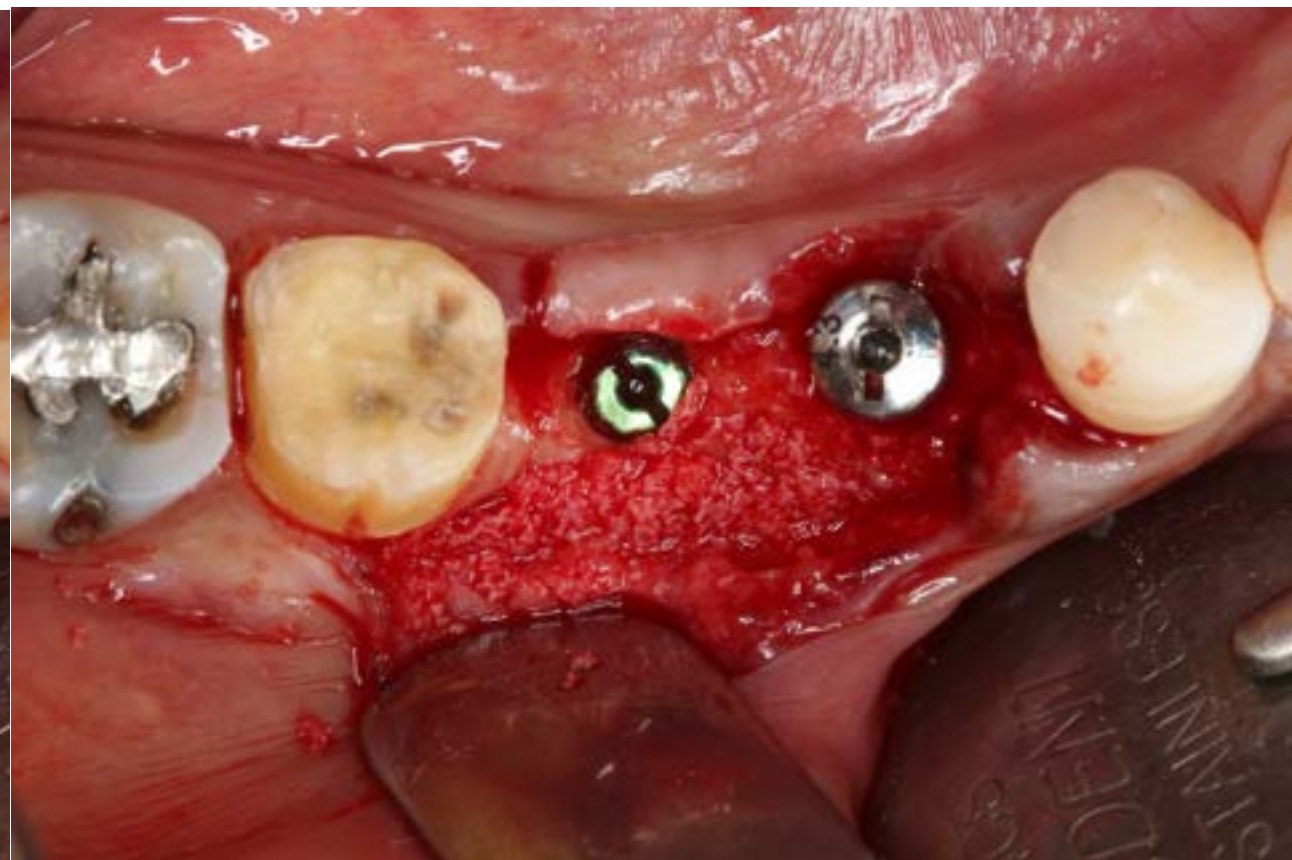
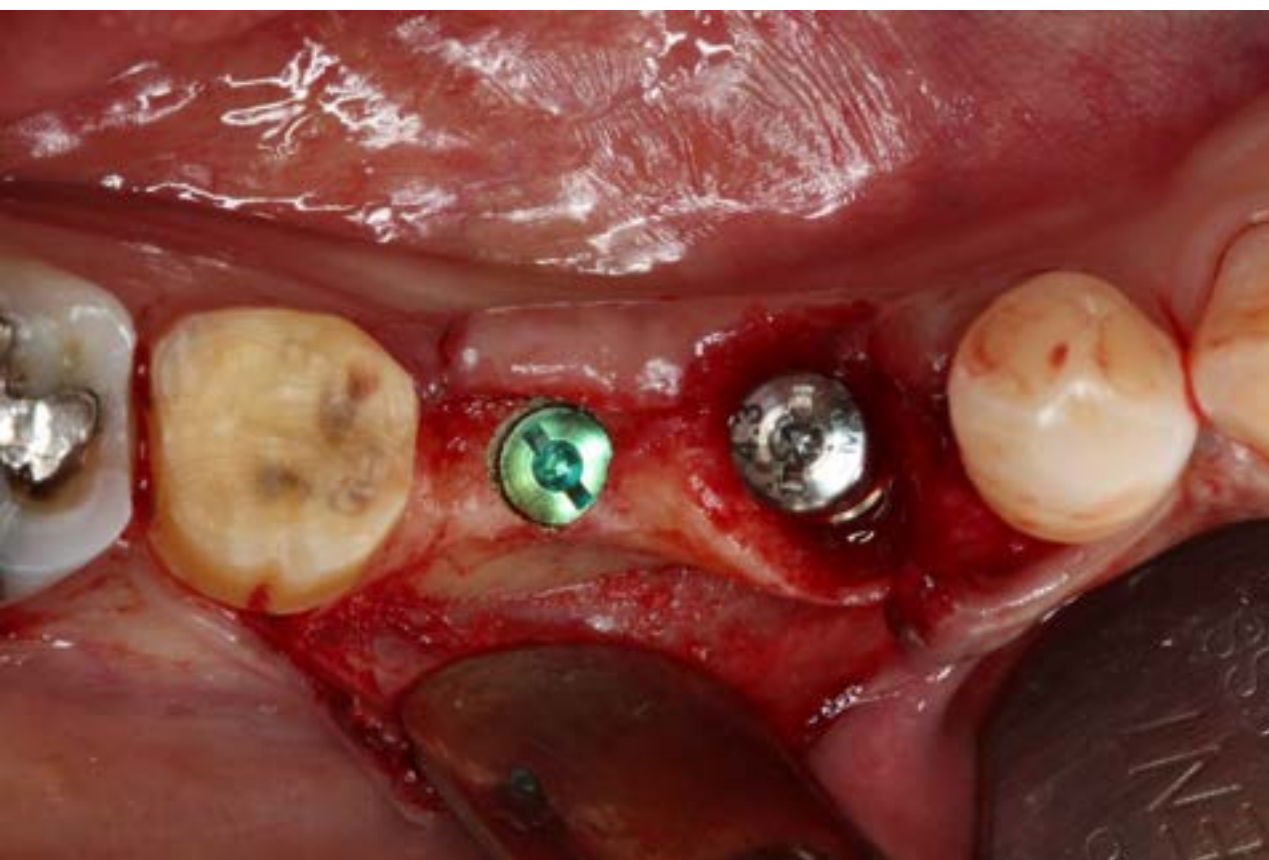


BFX4009

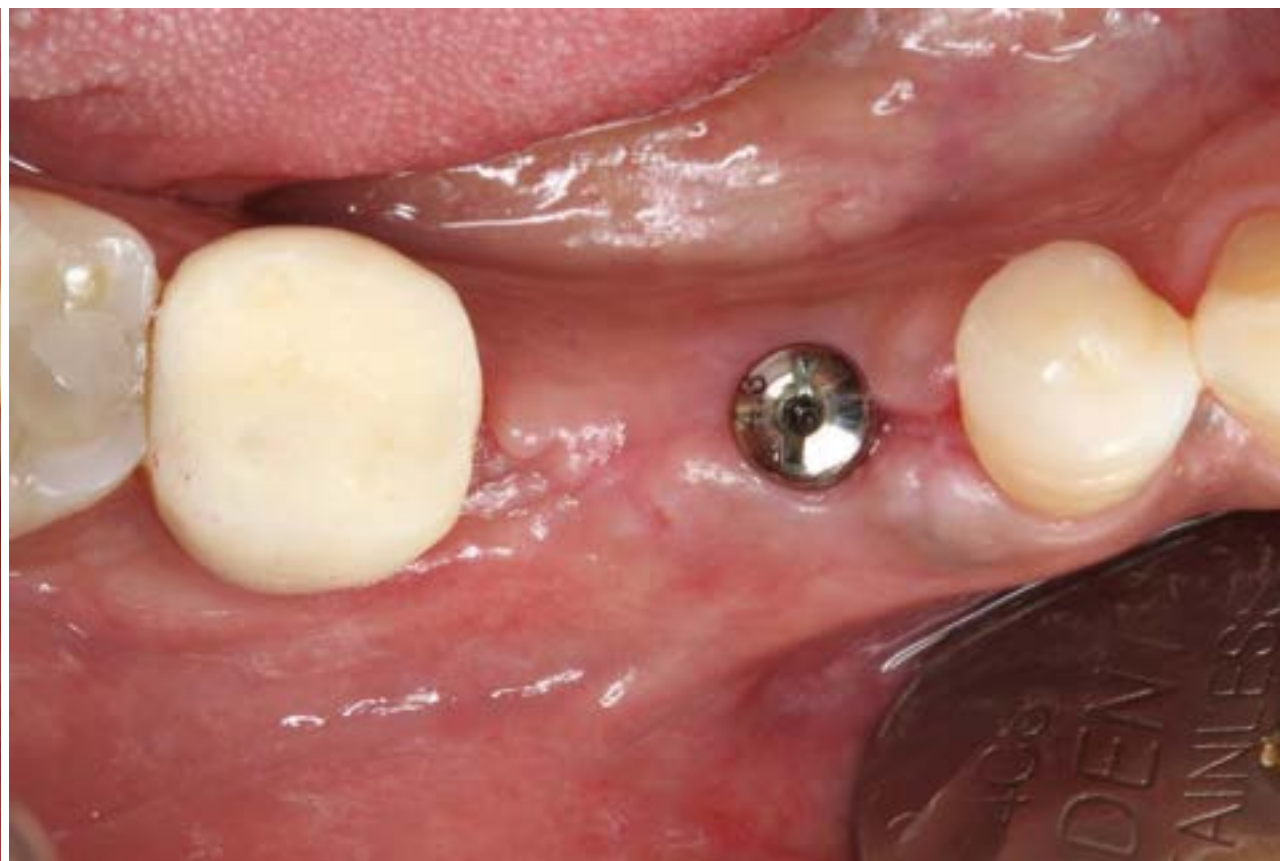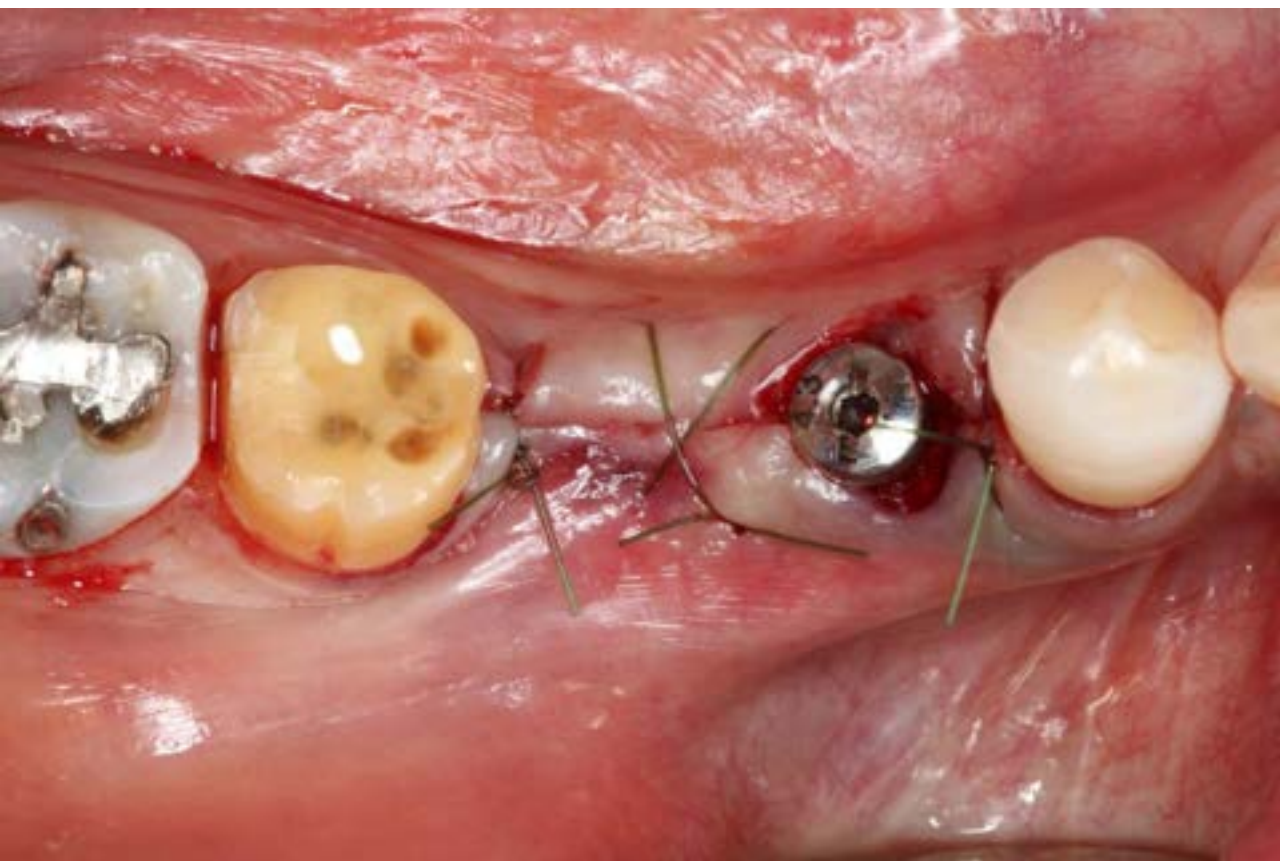




No counter sink drill, Save the marginal bone

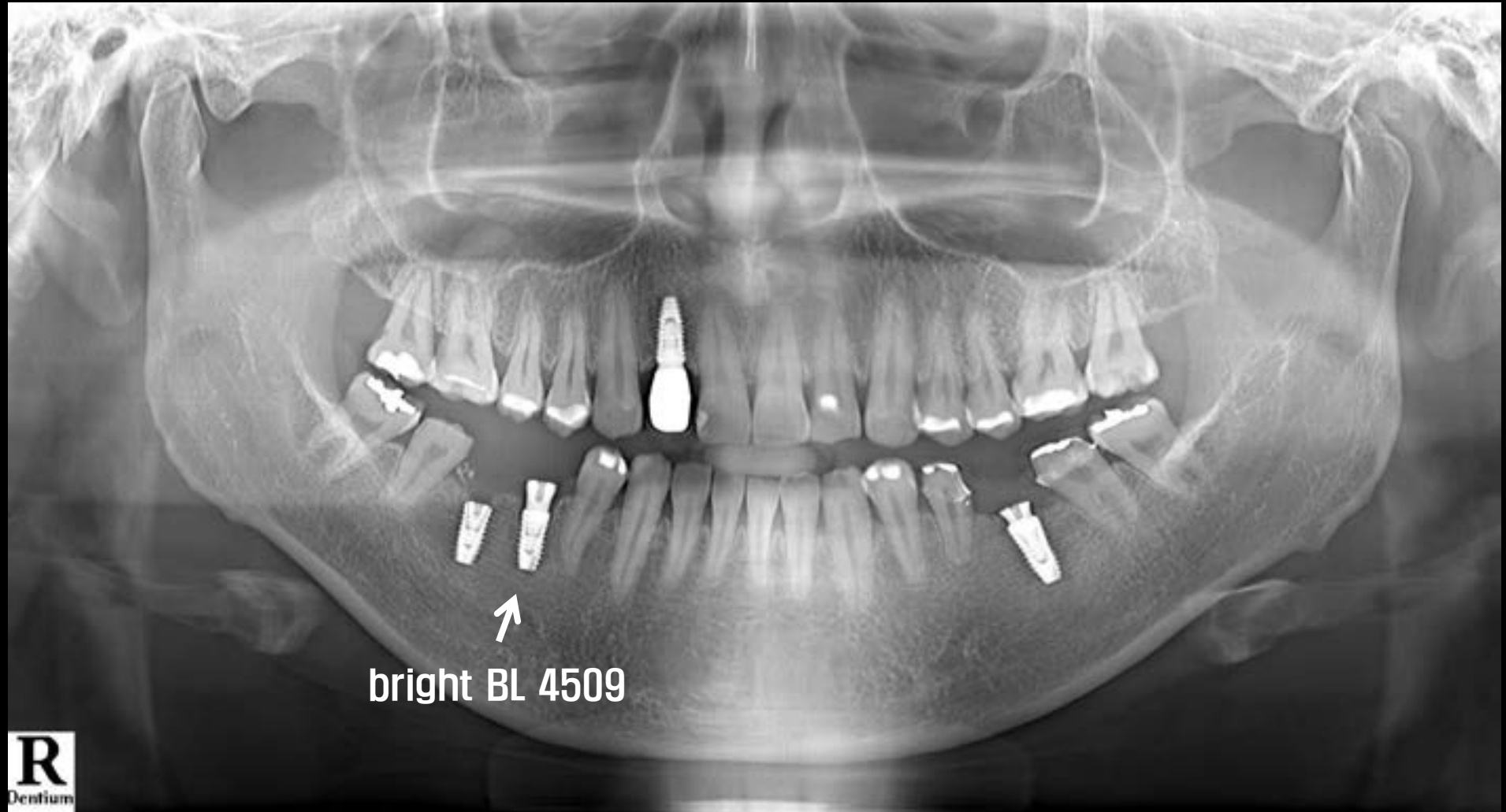


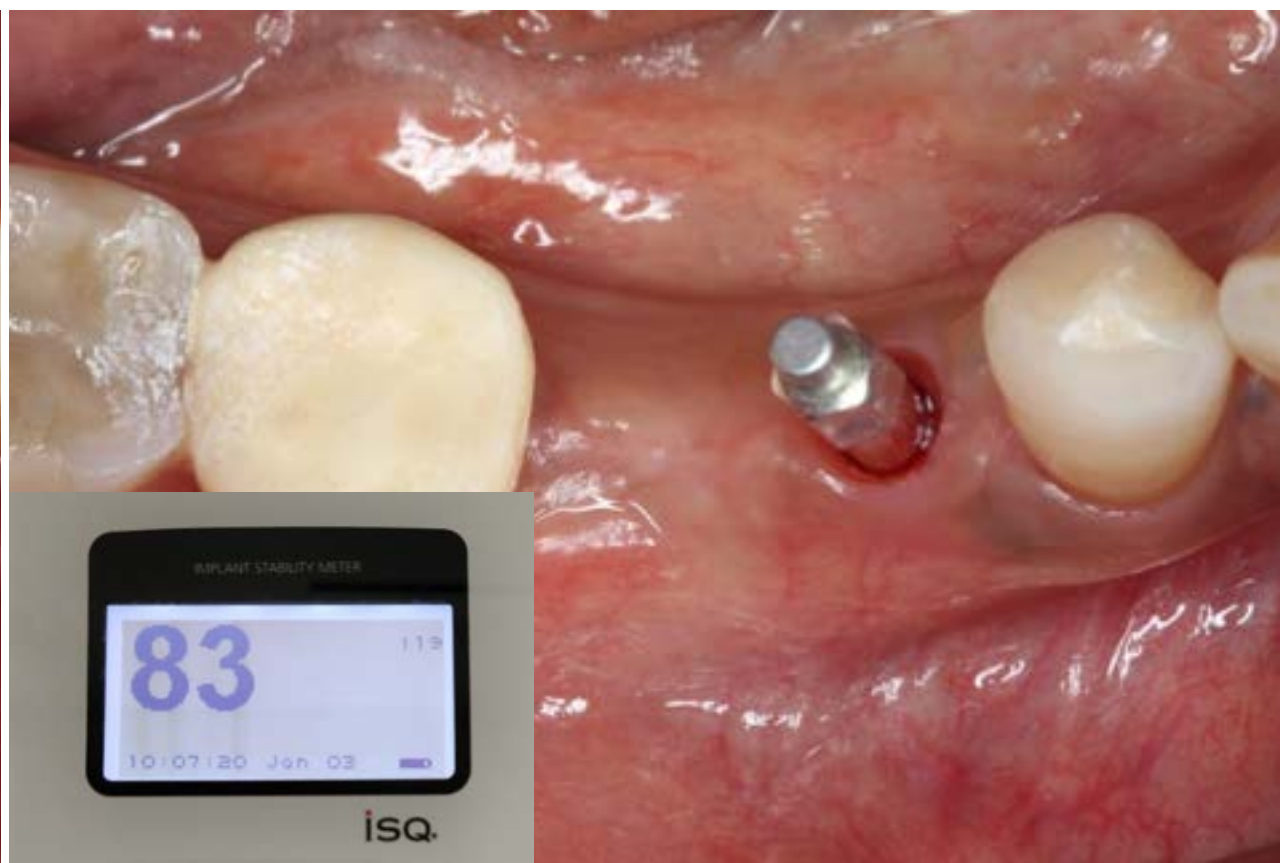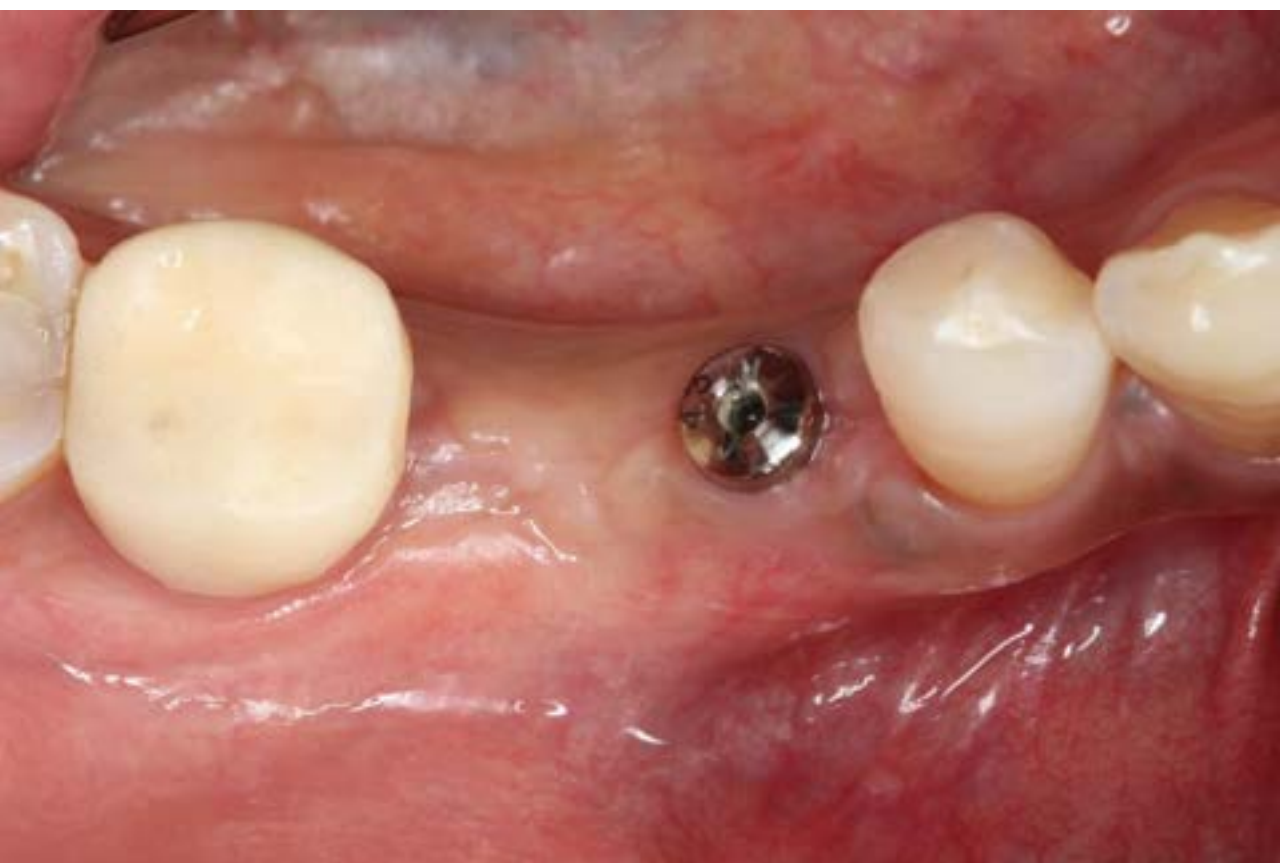simple bone grafting



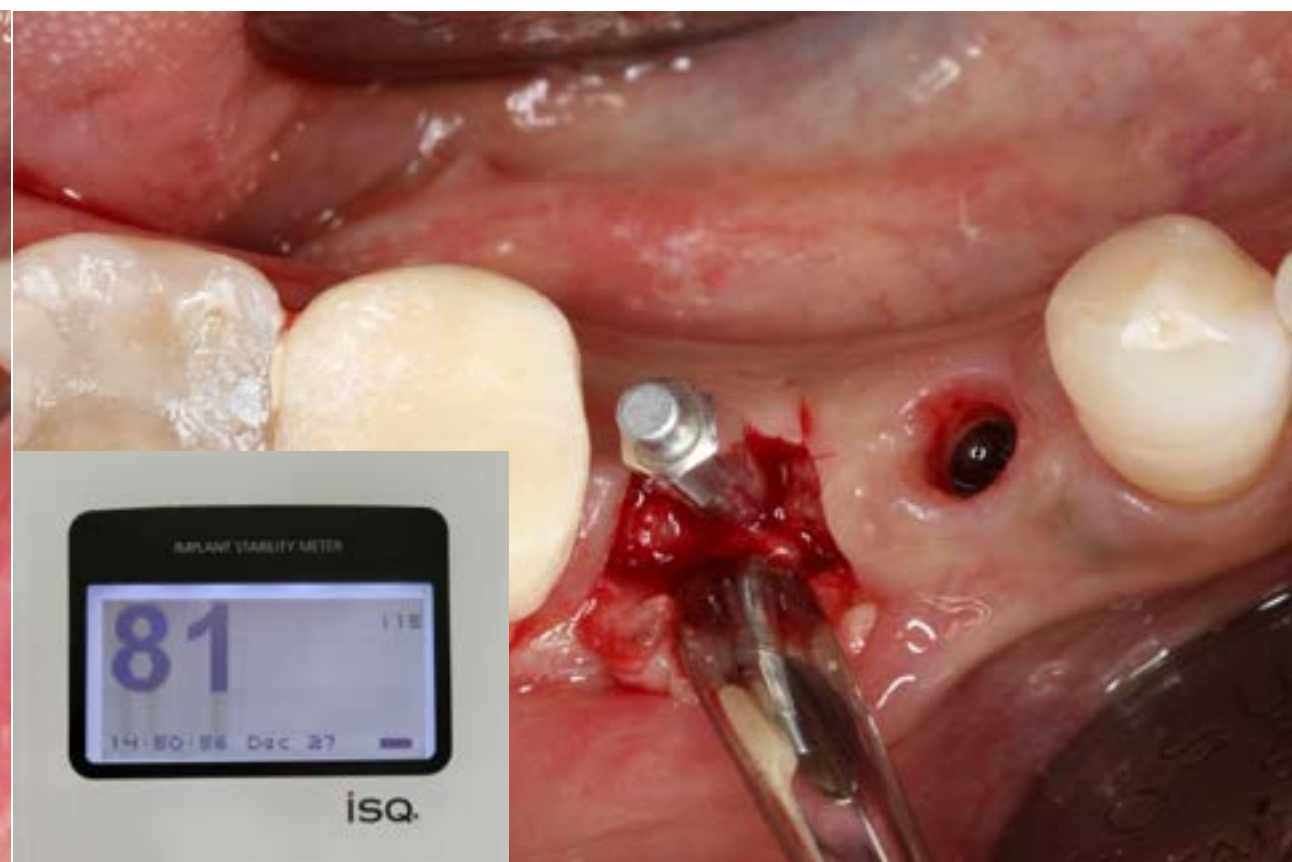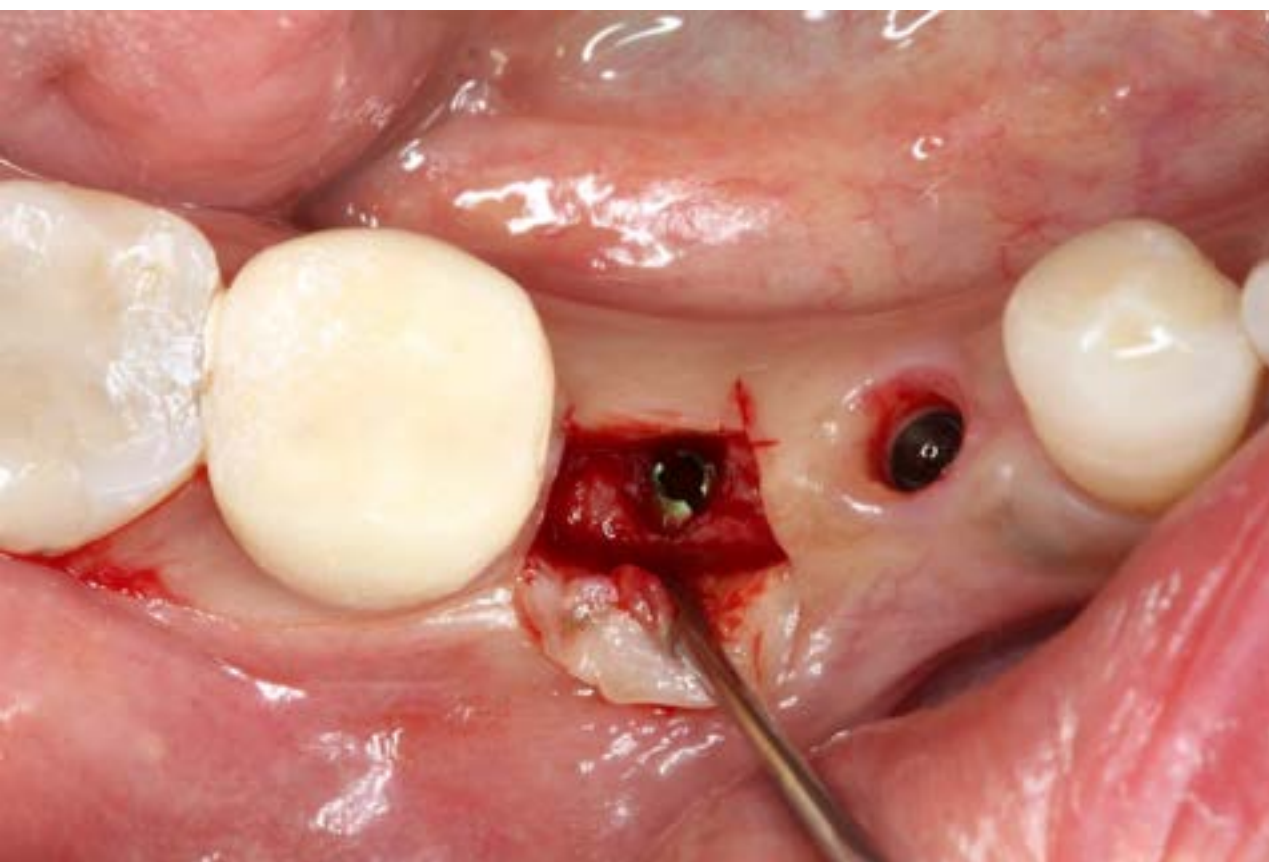
2 weeks later

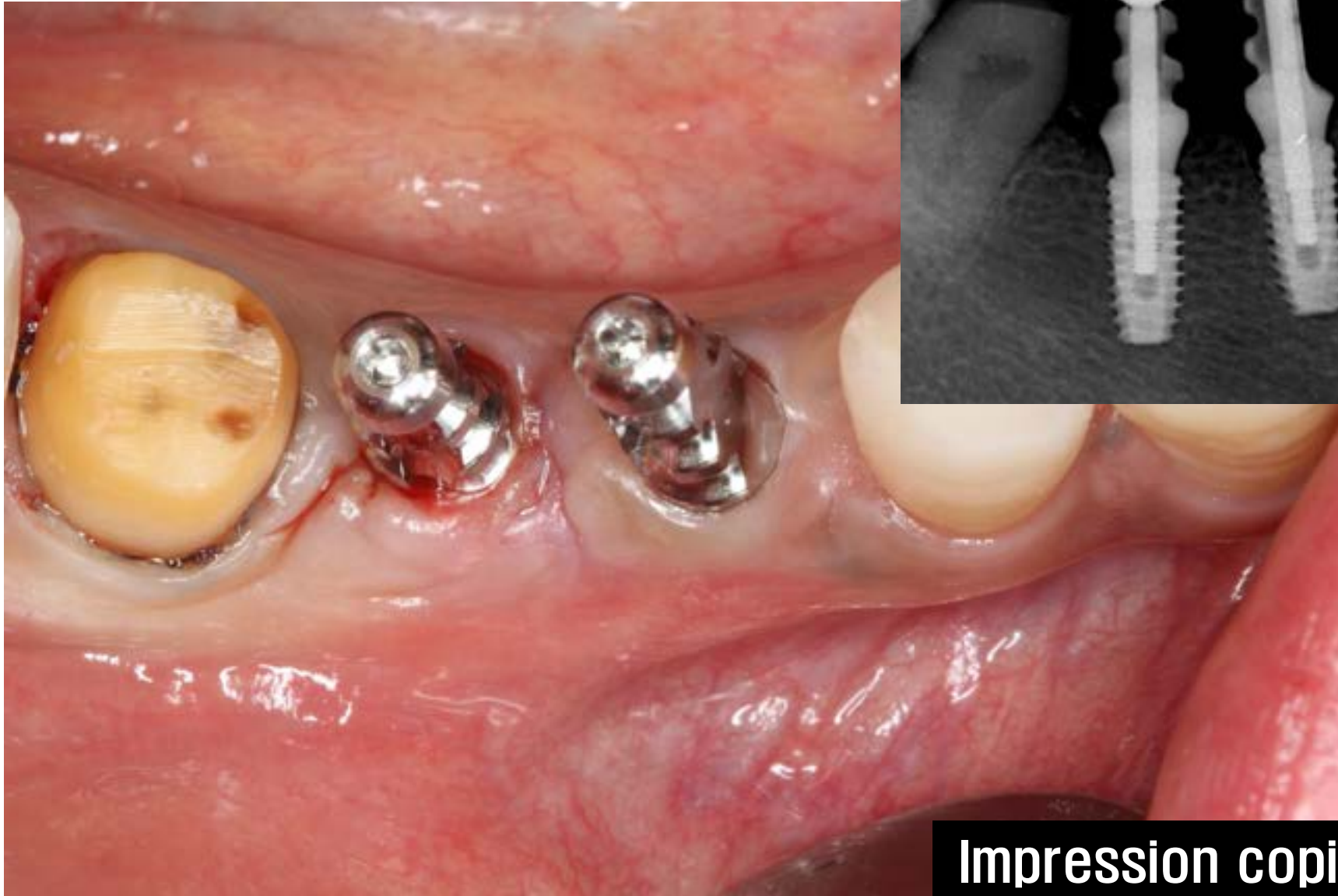
bright BL : easier insertion on hard bone





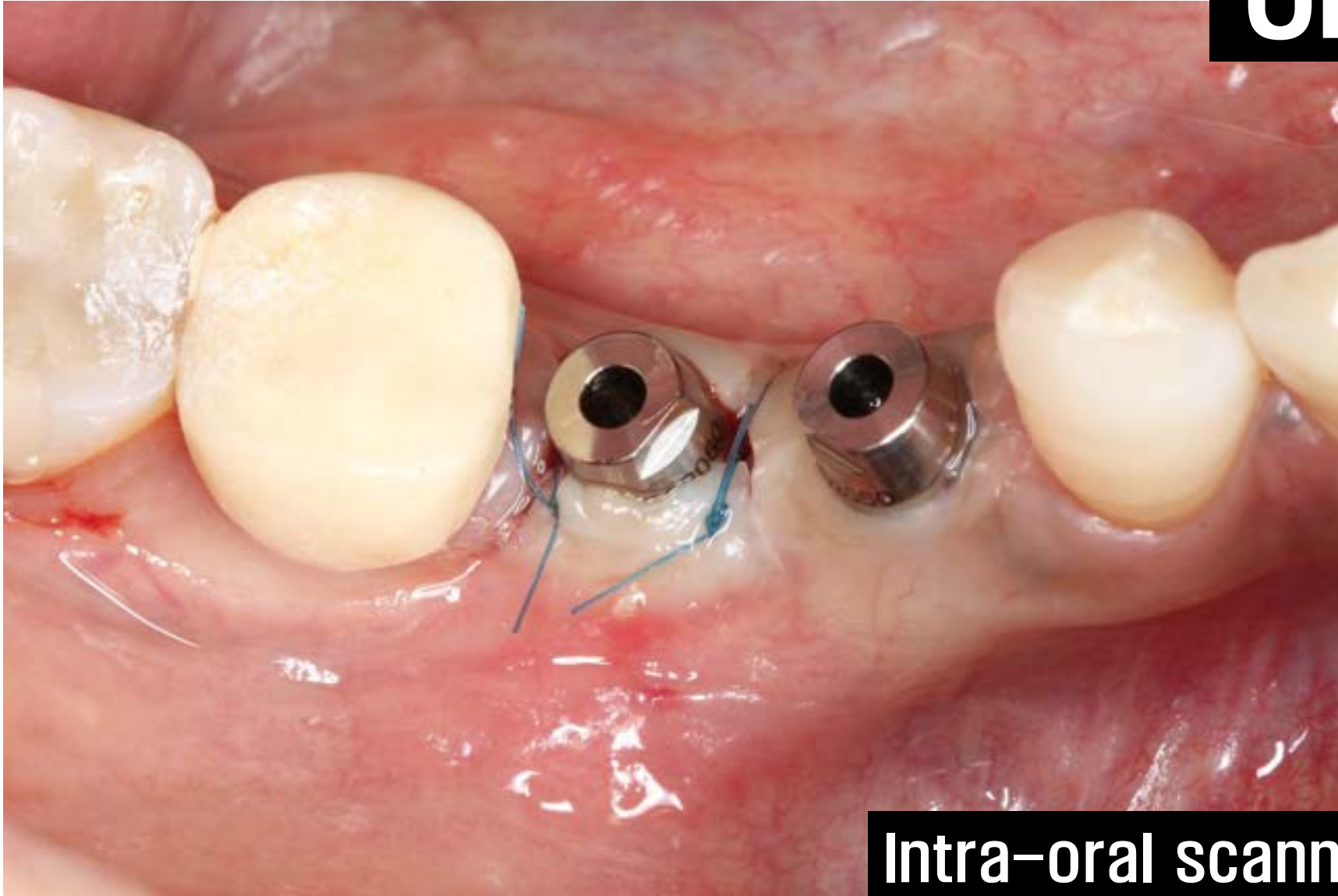
6 weeks later



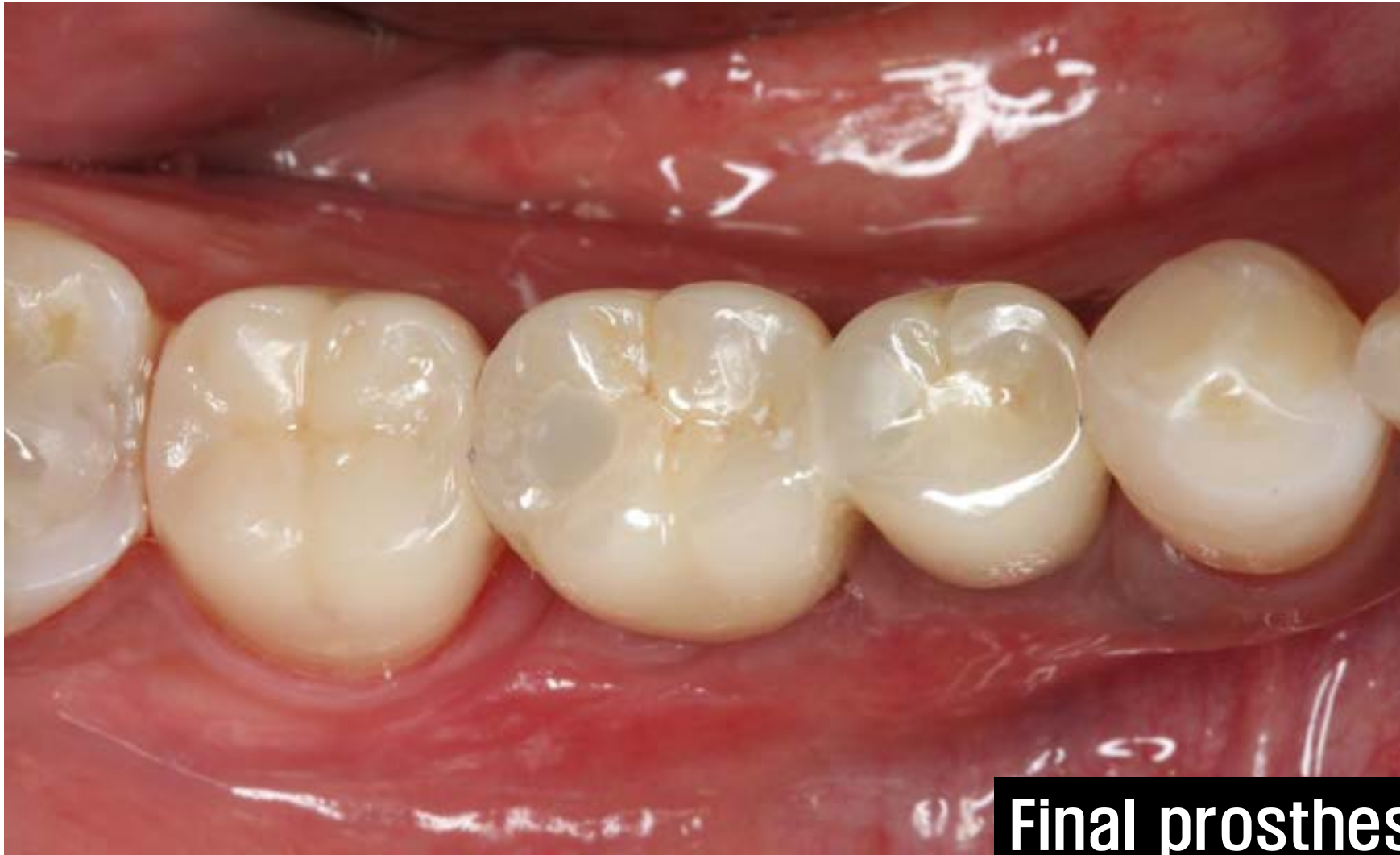

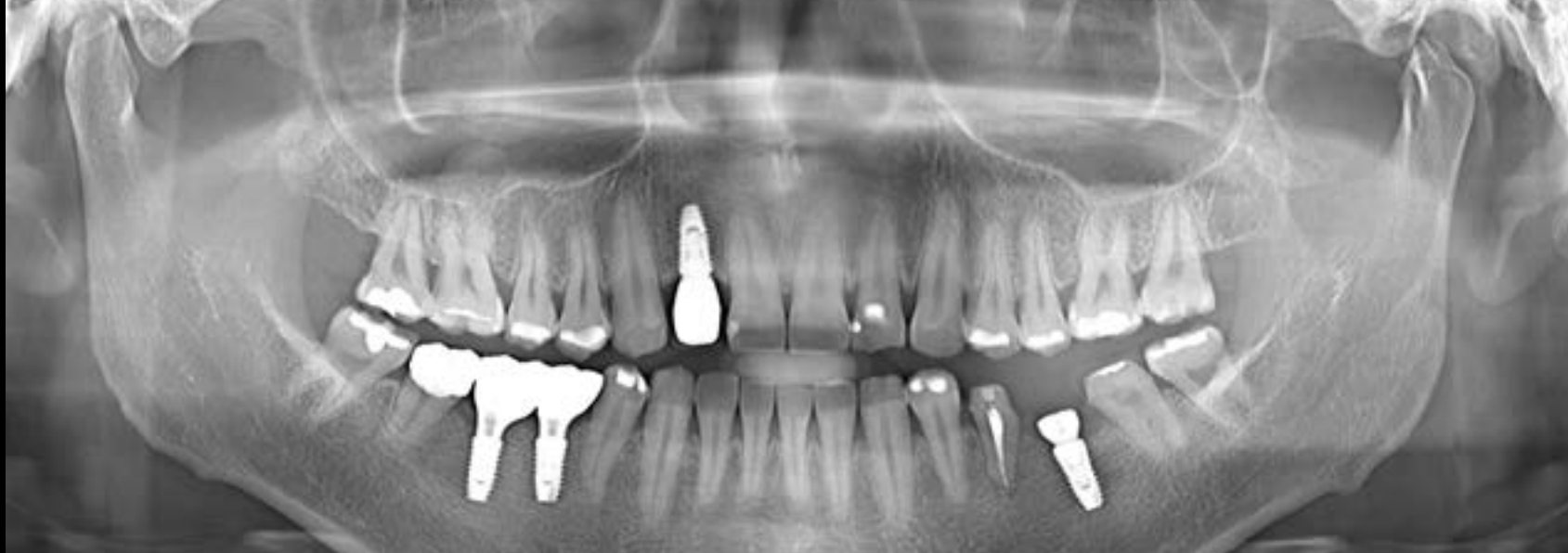Impression coping

OR

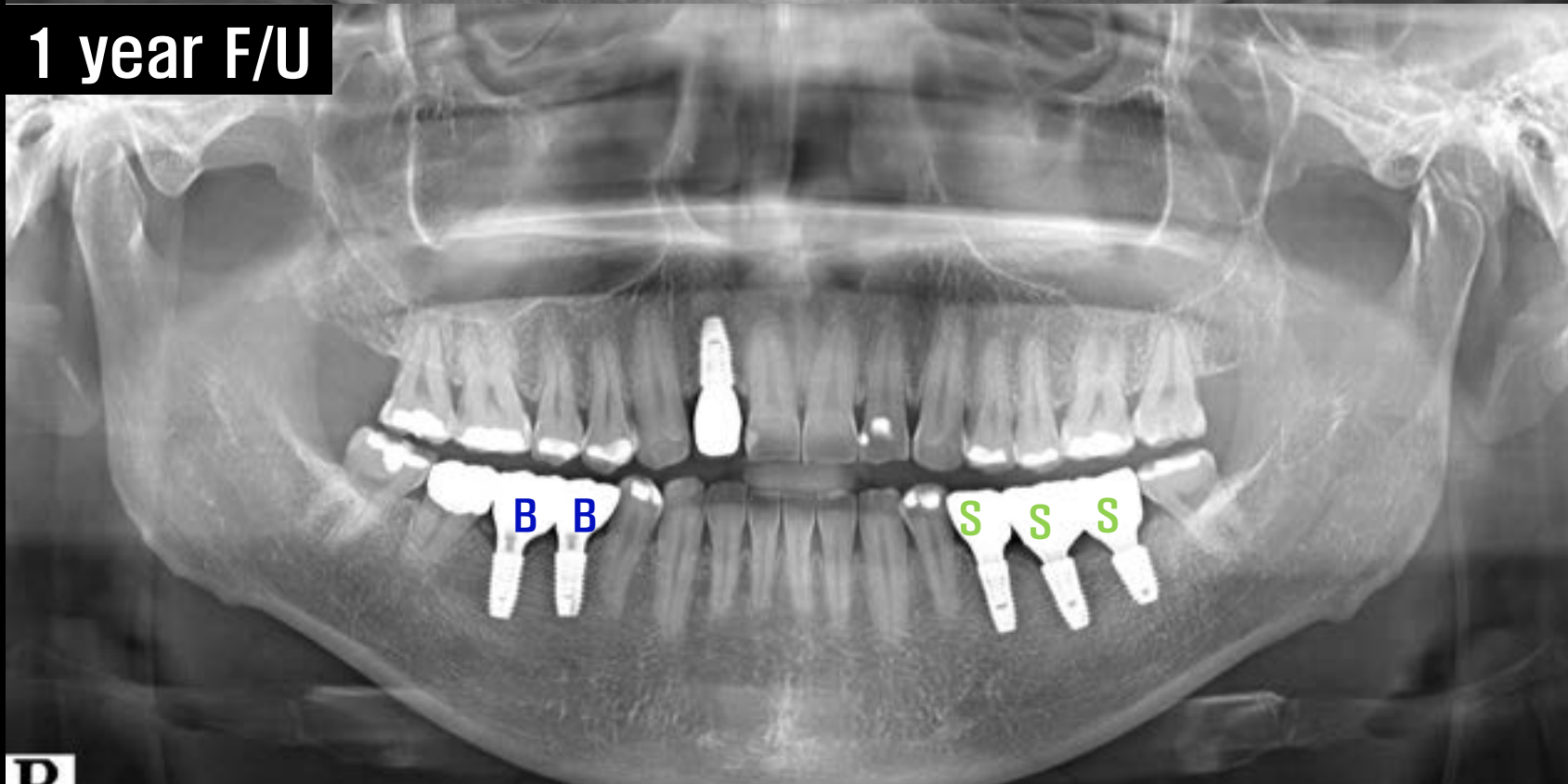


Intra-oral scanner





1 year F/U




P

bright BL : Ant. immediate

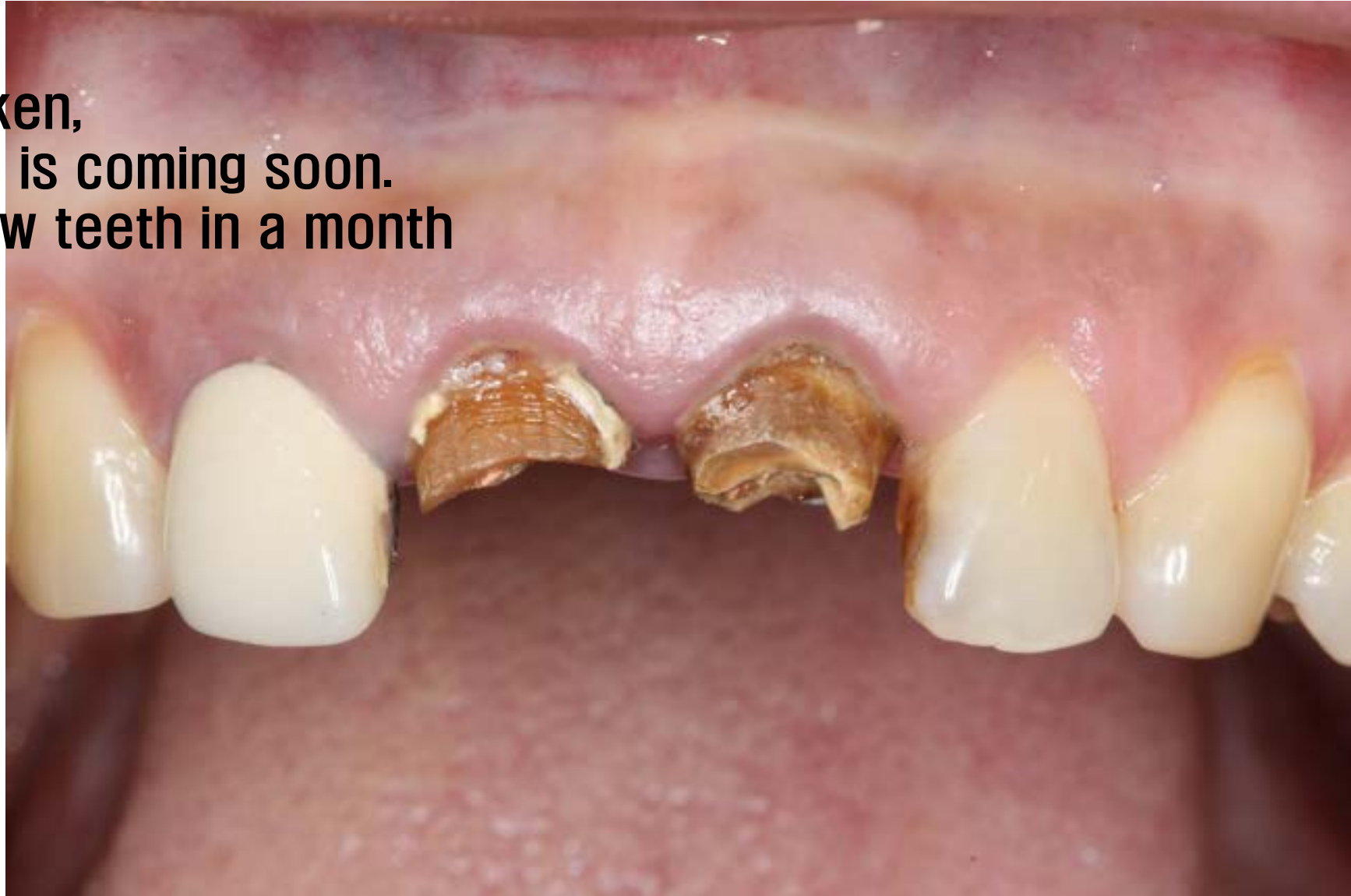Pt. : Lee, S O (60, F)

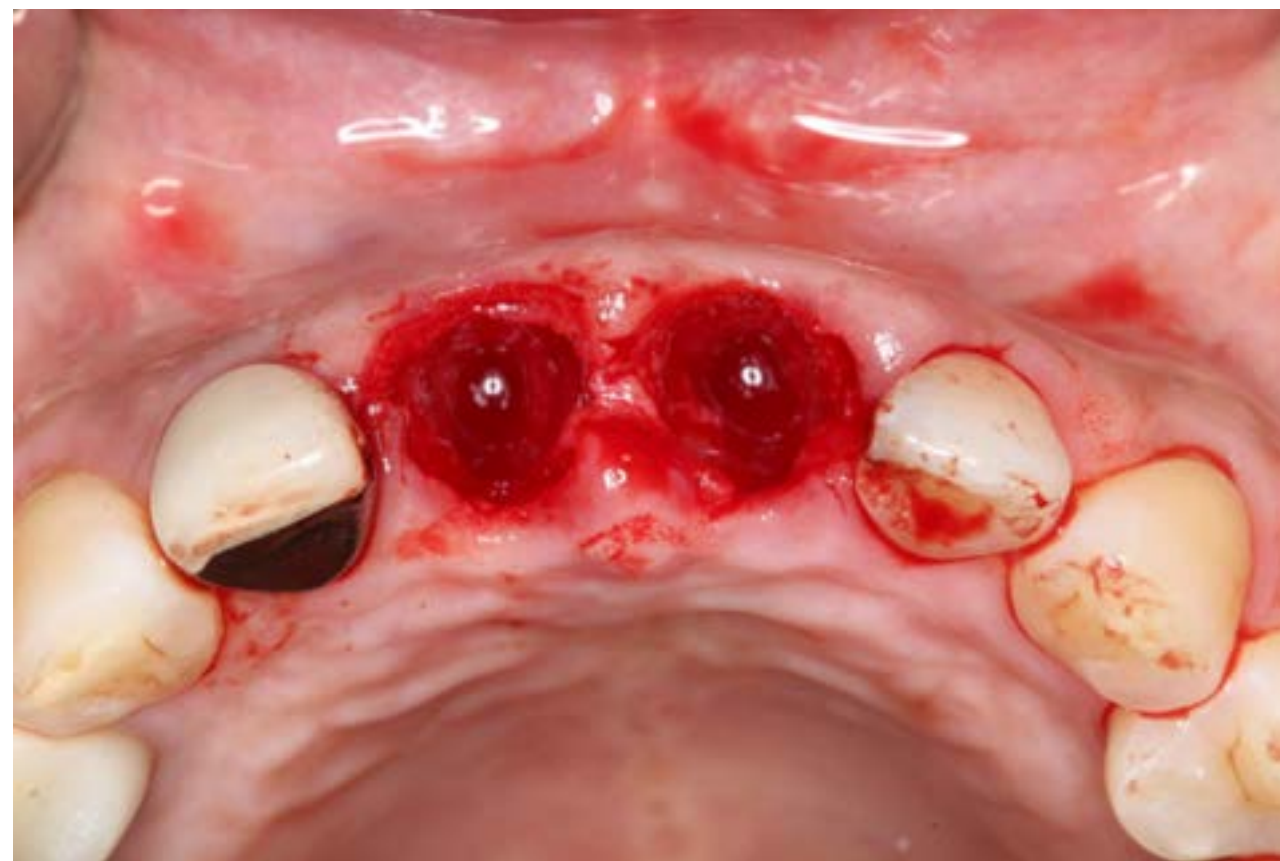
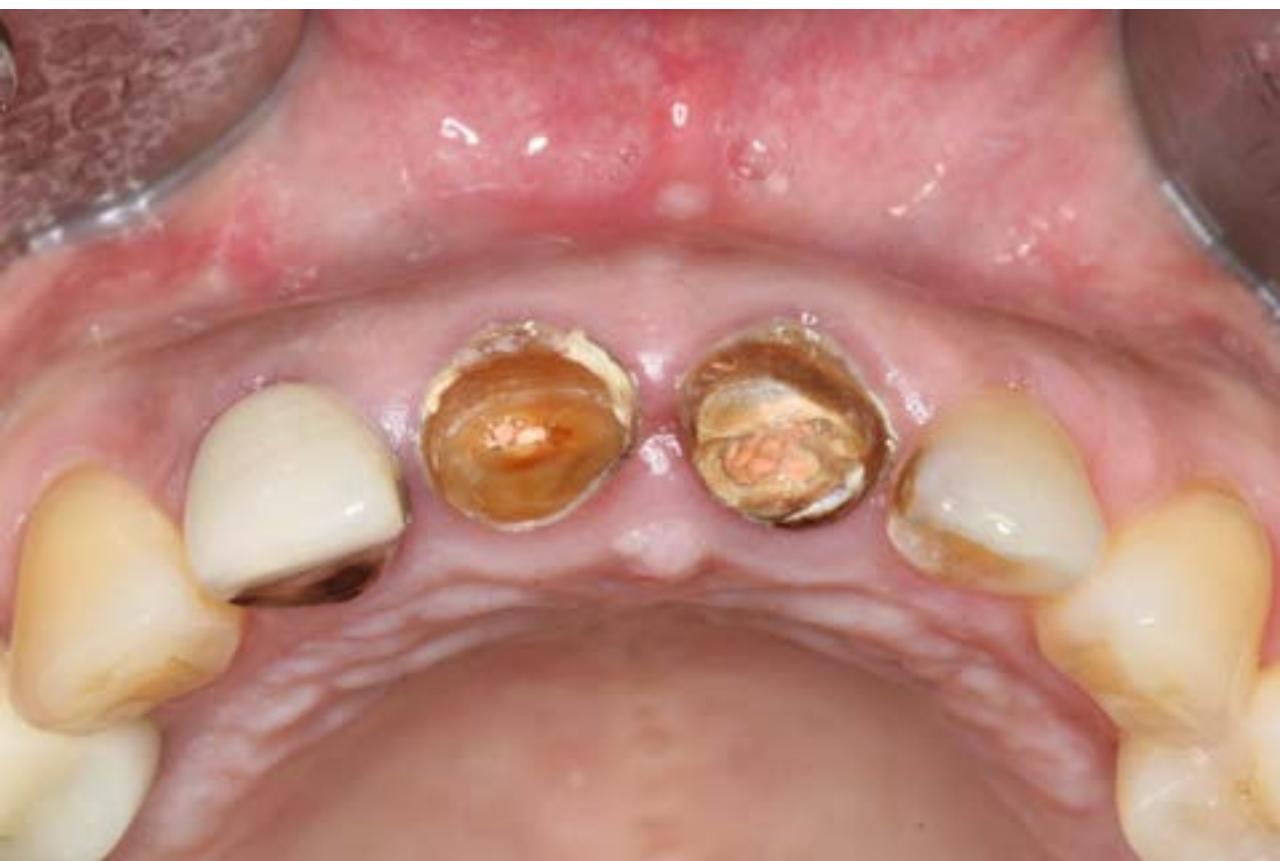C.C. : my teeth were broken,
my son' s wedding is coming soon.
Can you make a new teeth in a month

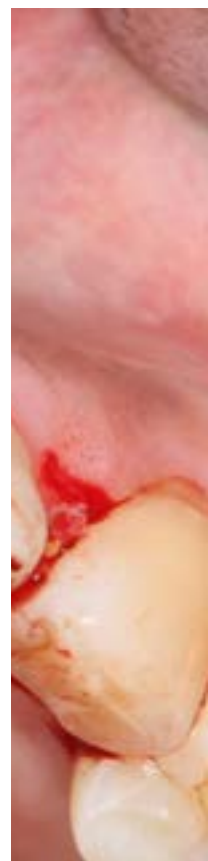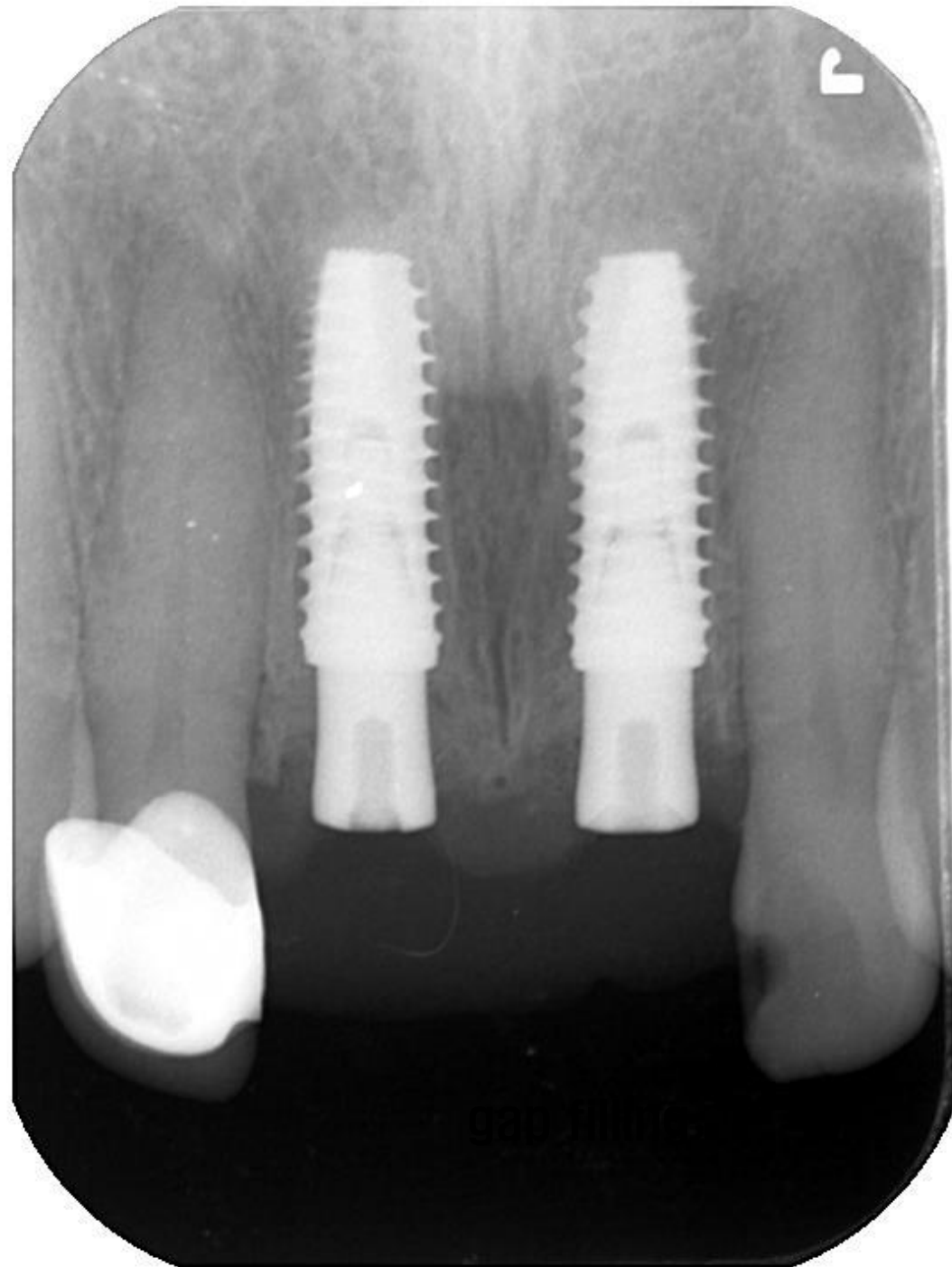
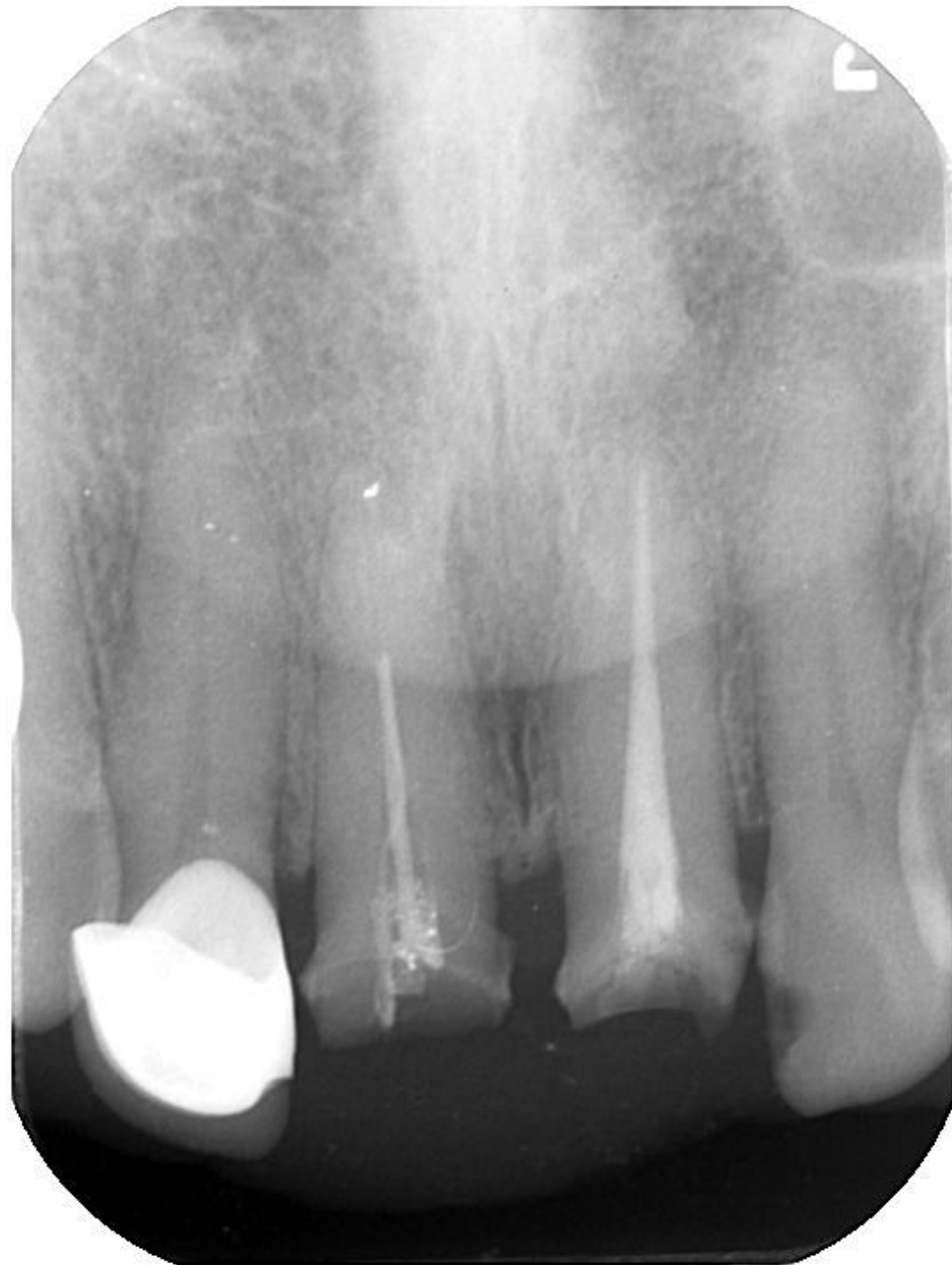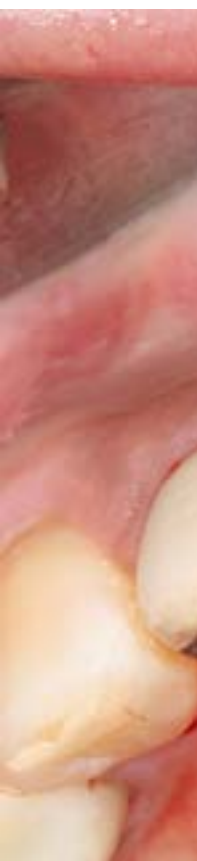immediate implantation

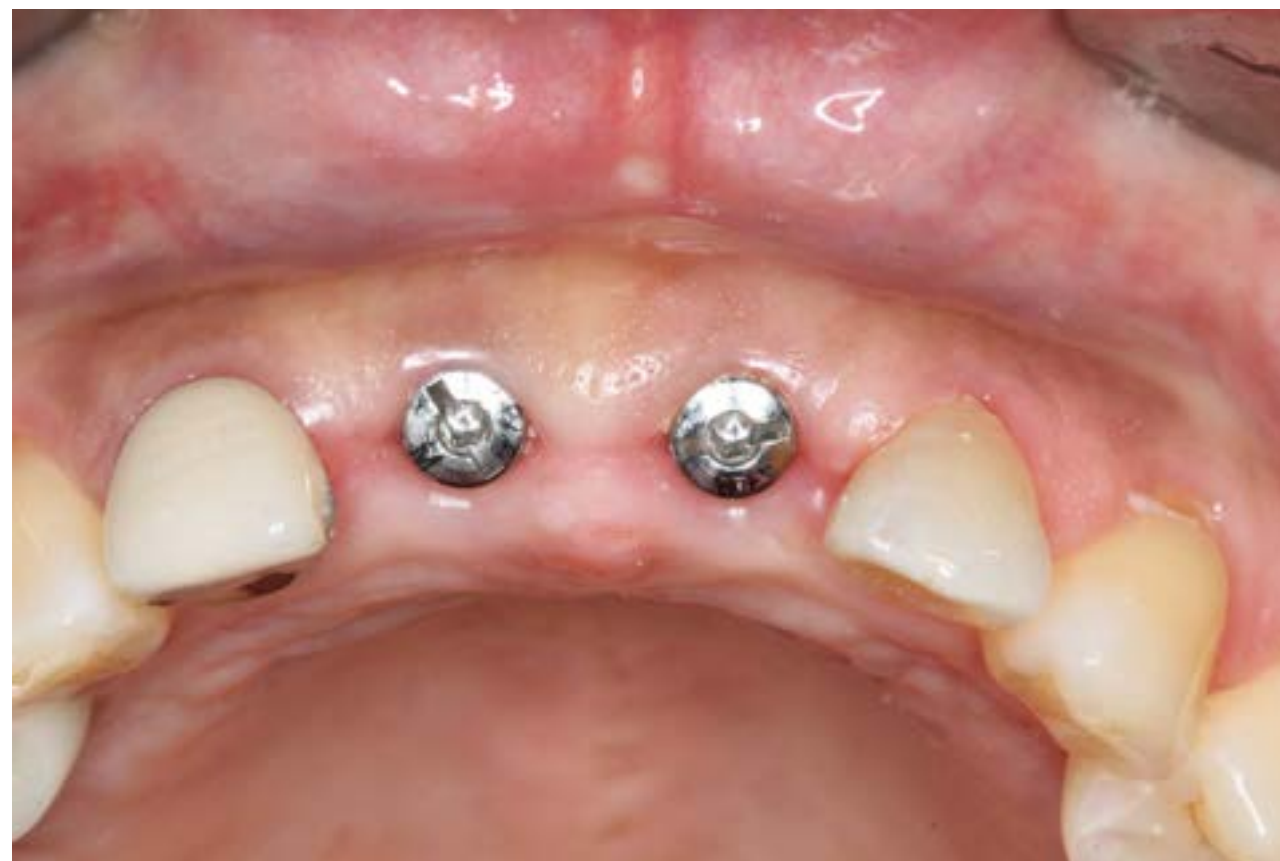
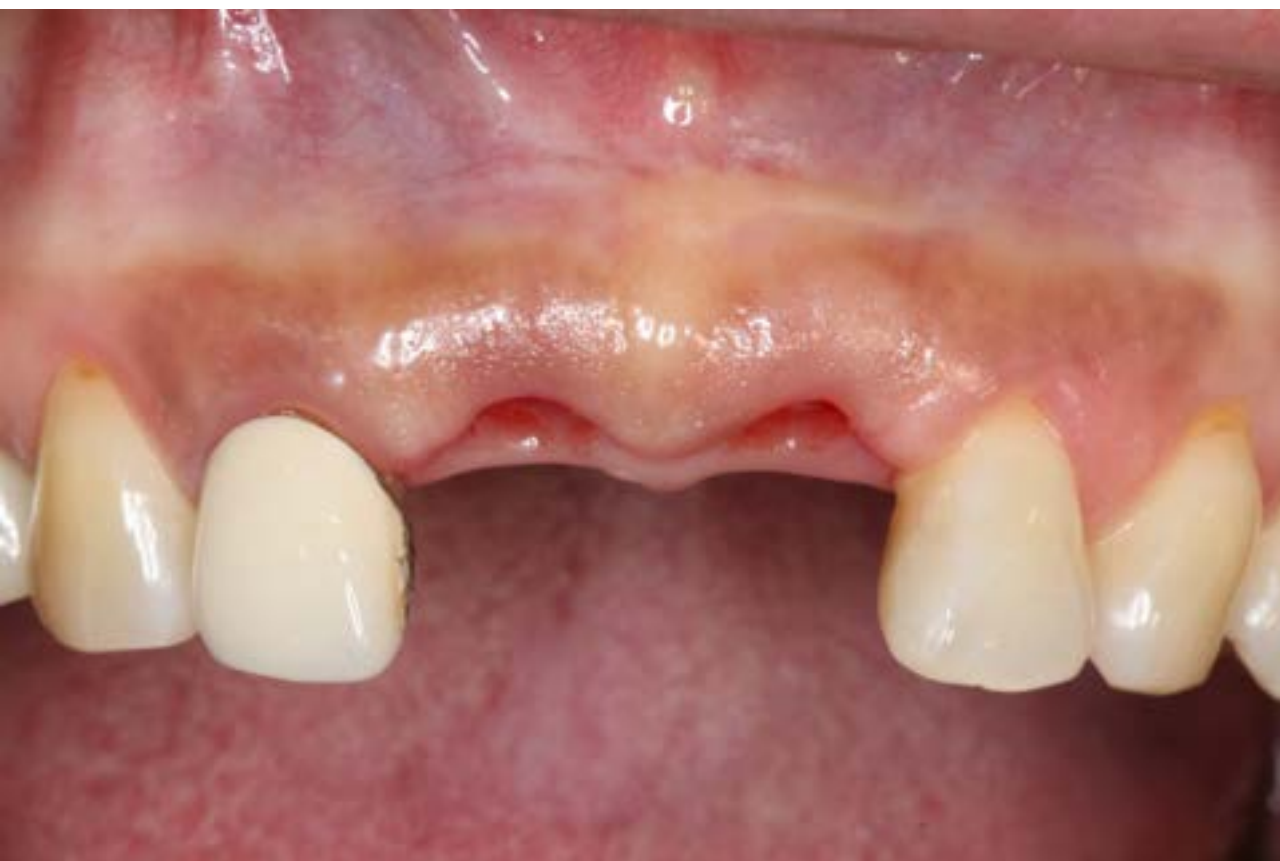
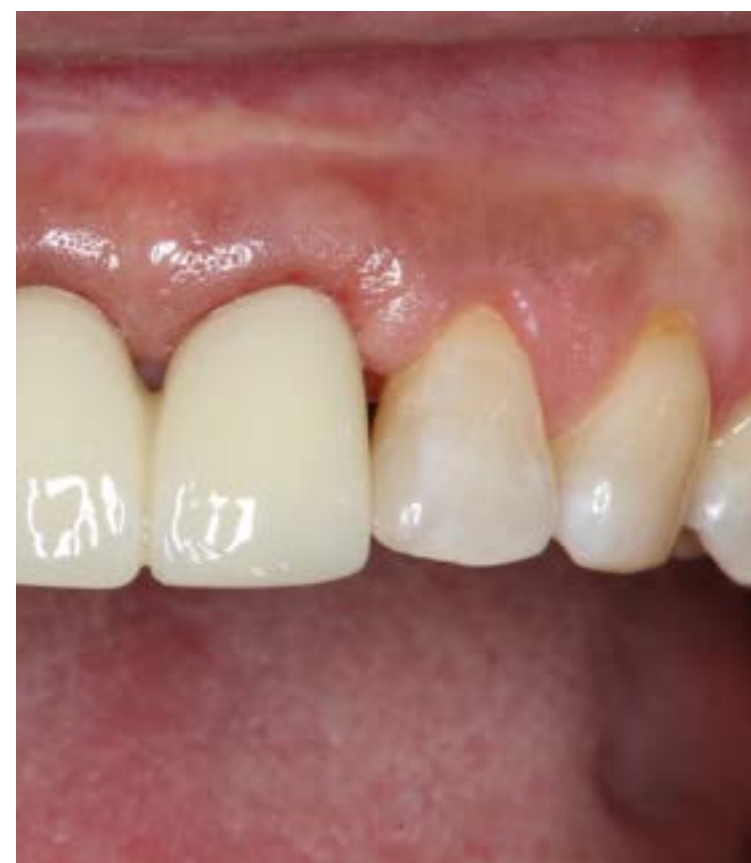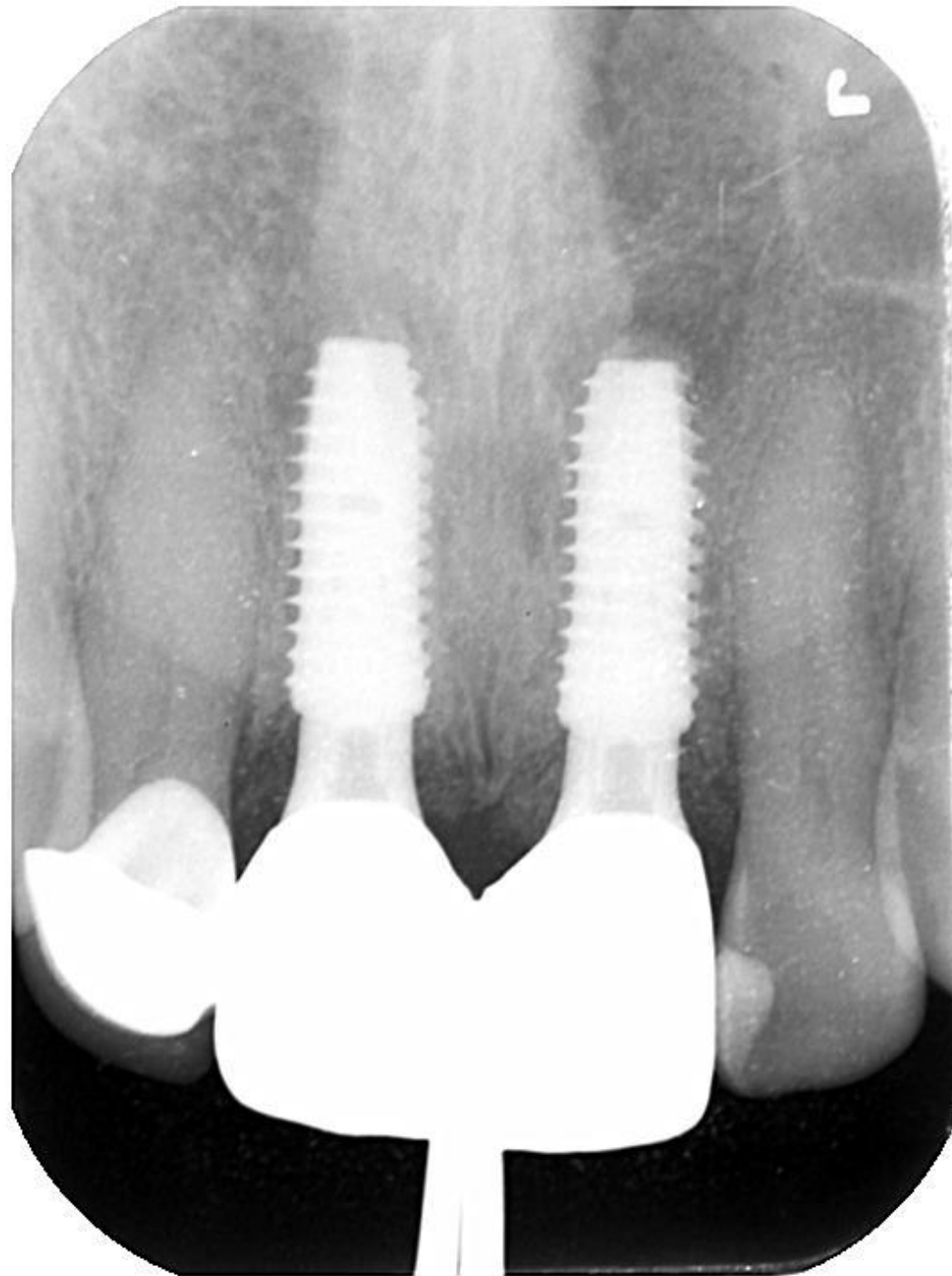
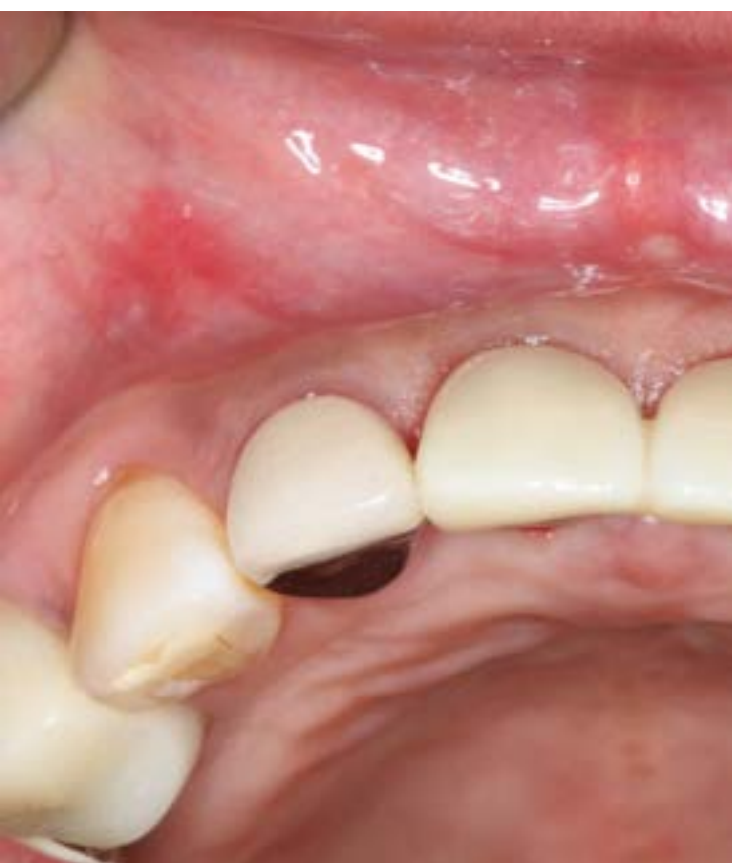bright BL



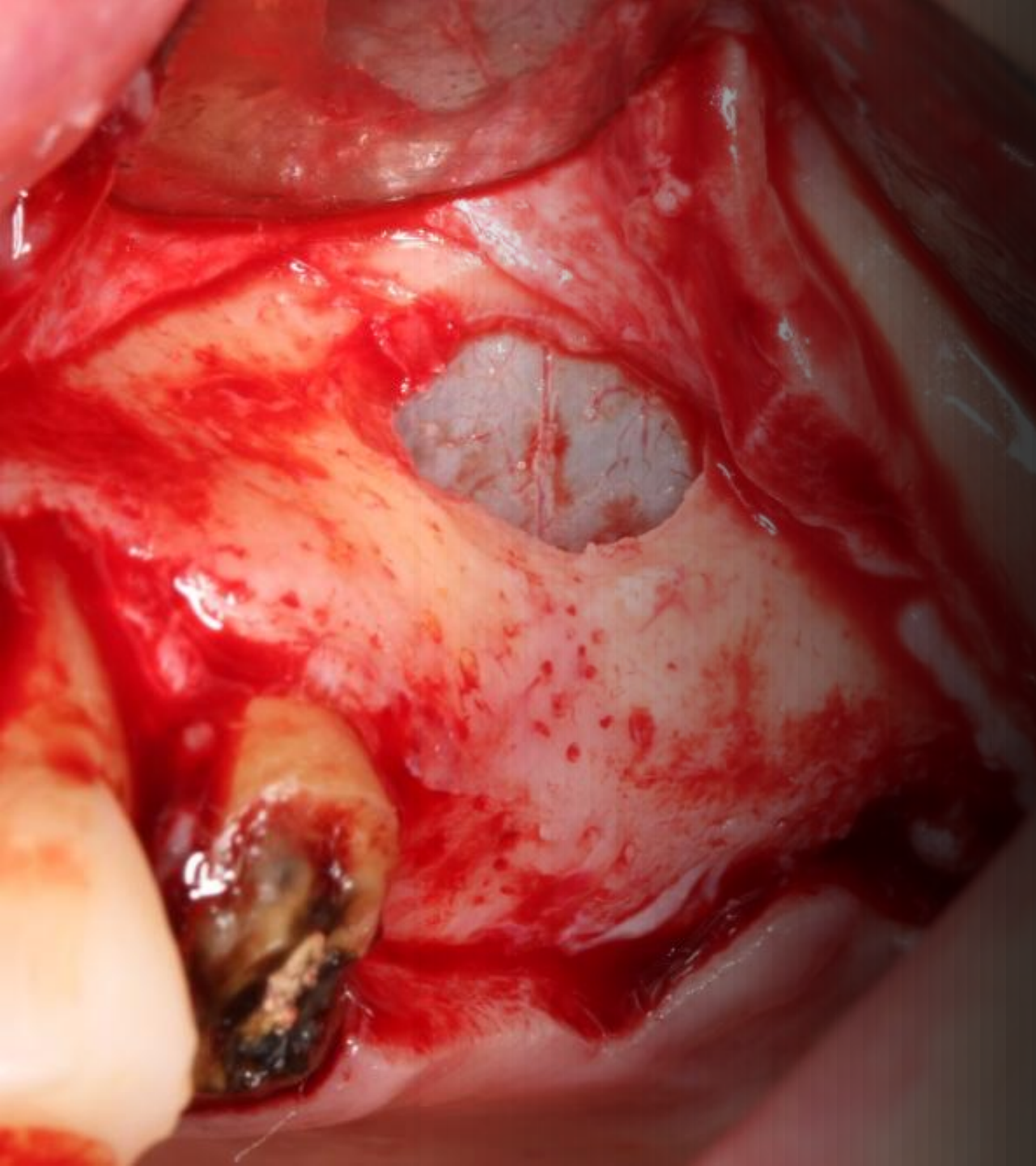








sinus elevation in narrow ridge



—
it can save marginal
bone




bright BL : sinus elevation

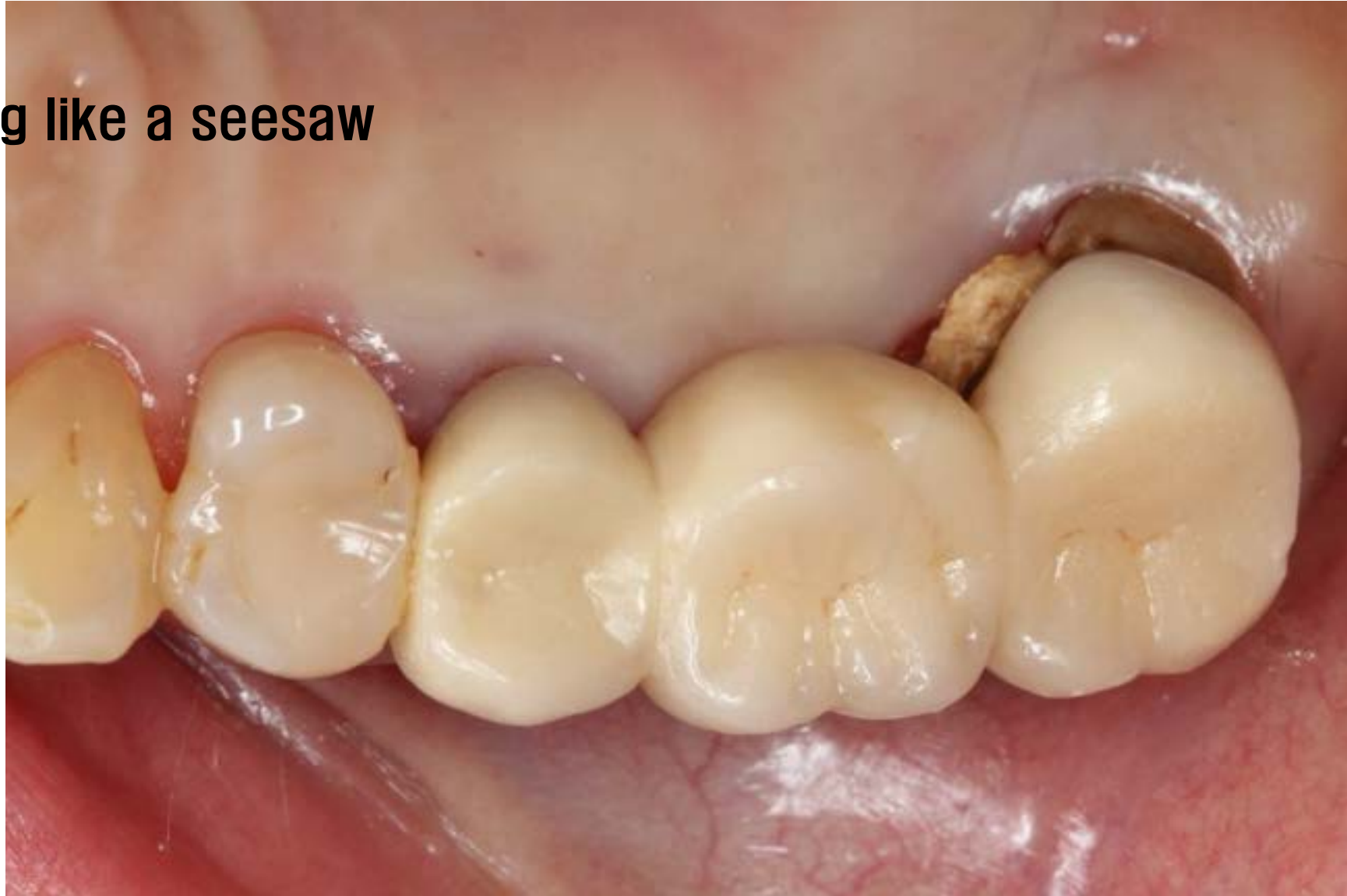Pt. : Lee, M J (80, F)

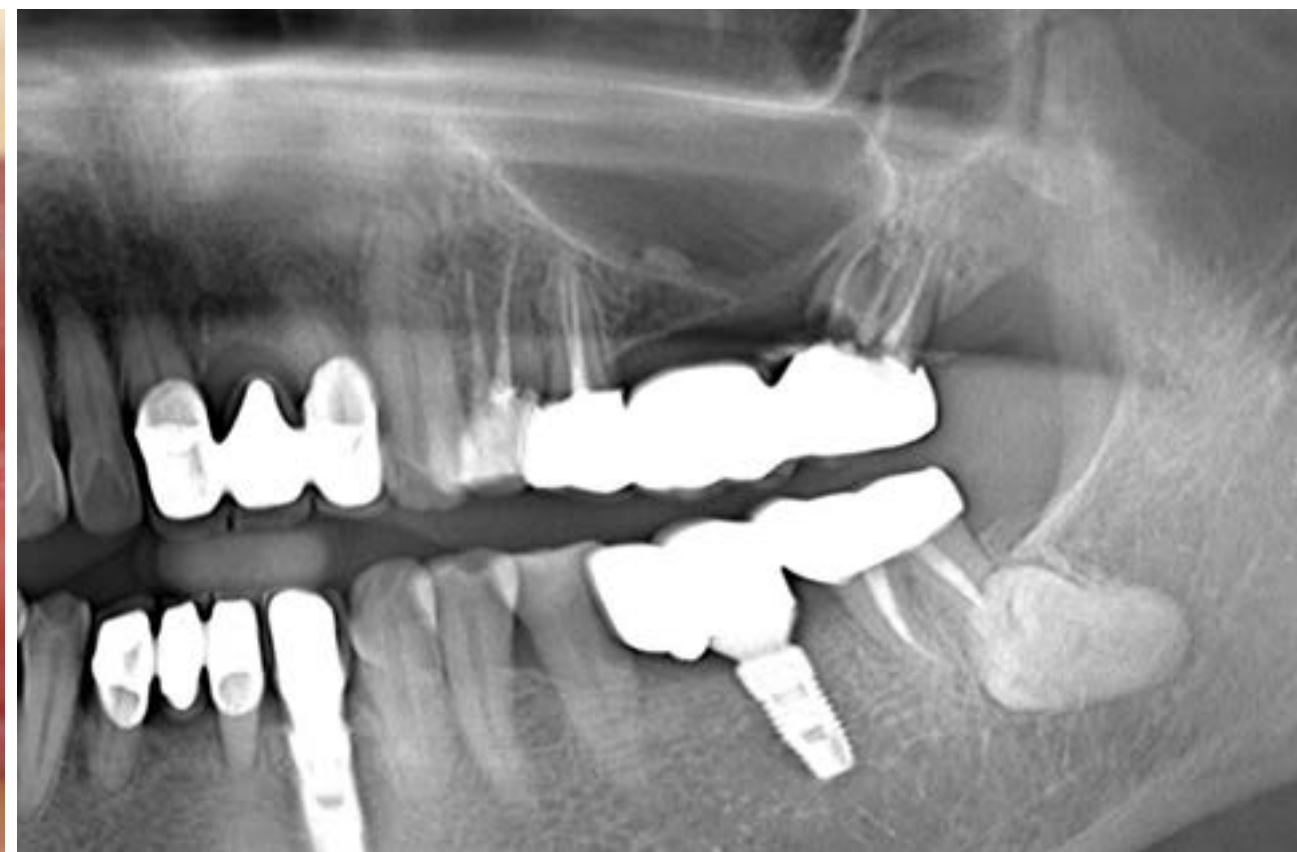
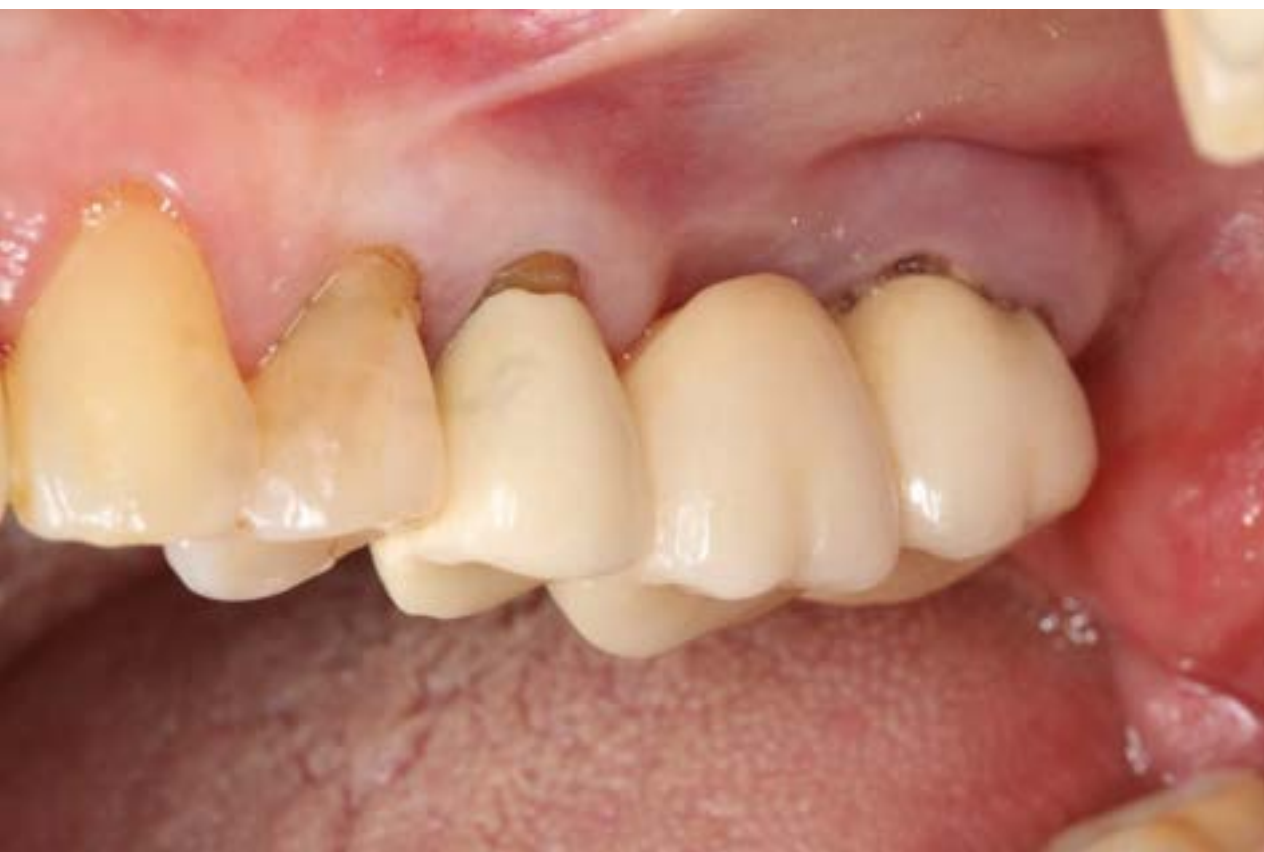C.C. : my teeth are moving like a seesaw

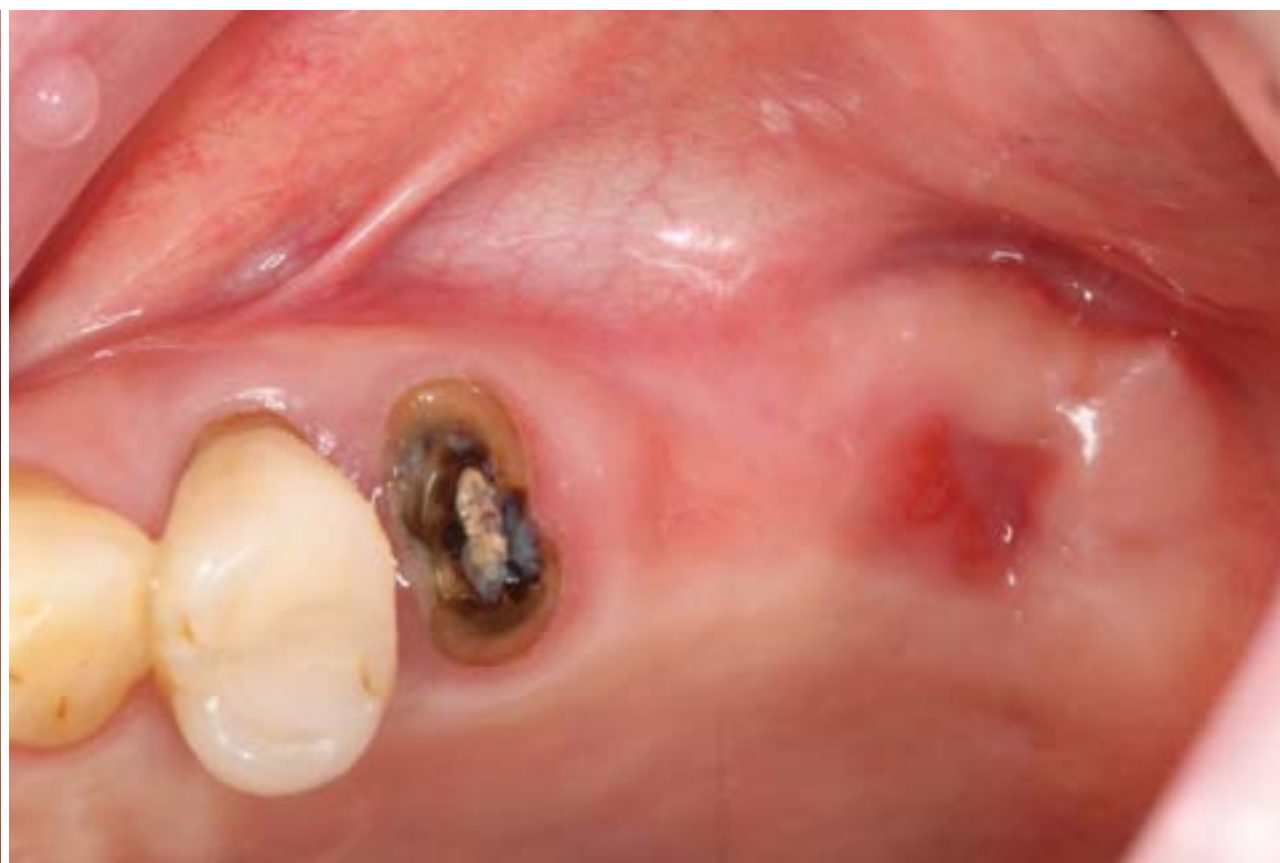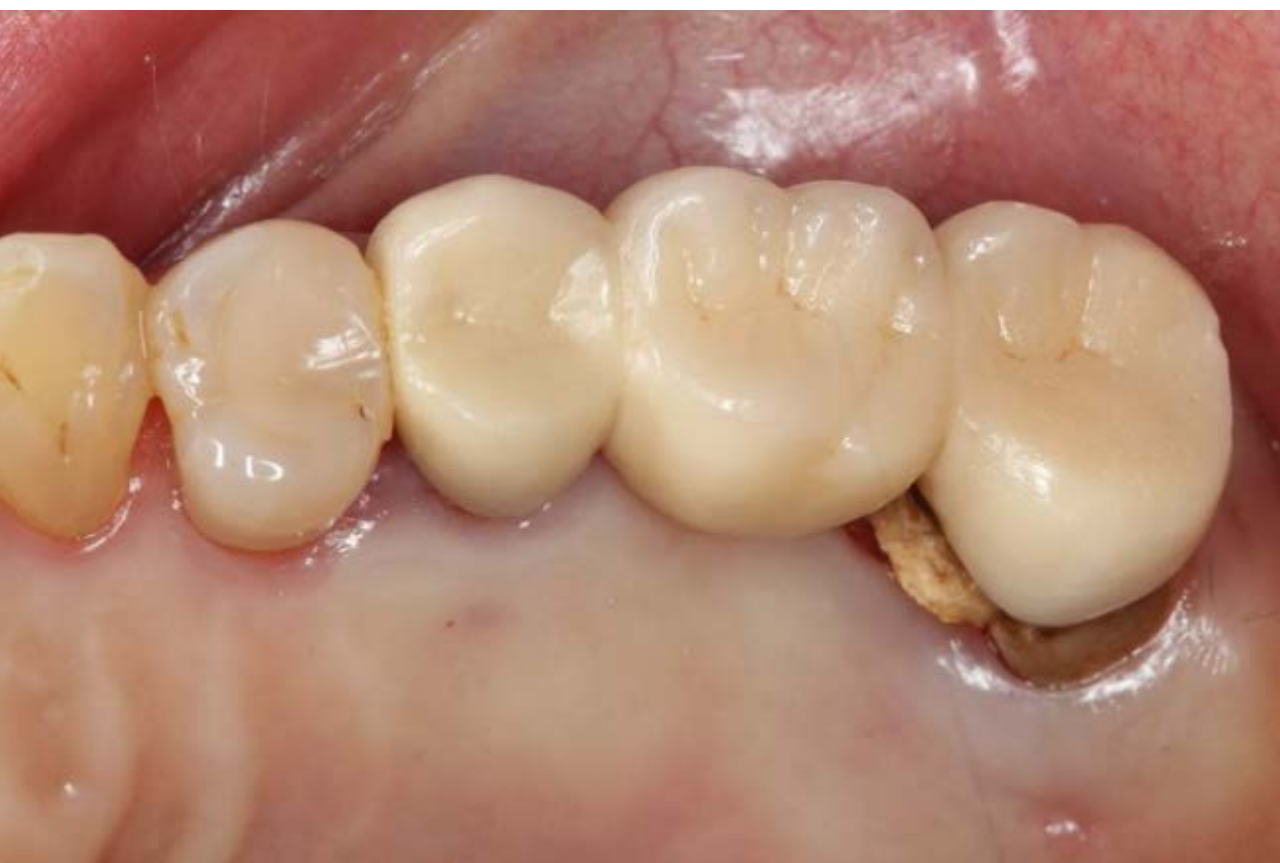immediate implantation
Sinus elevation

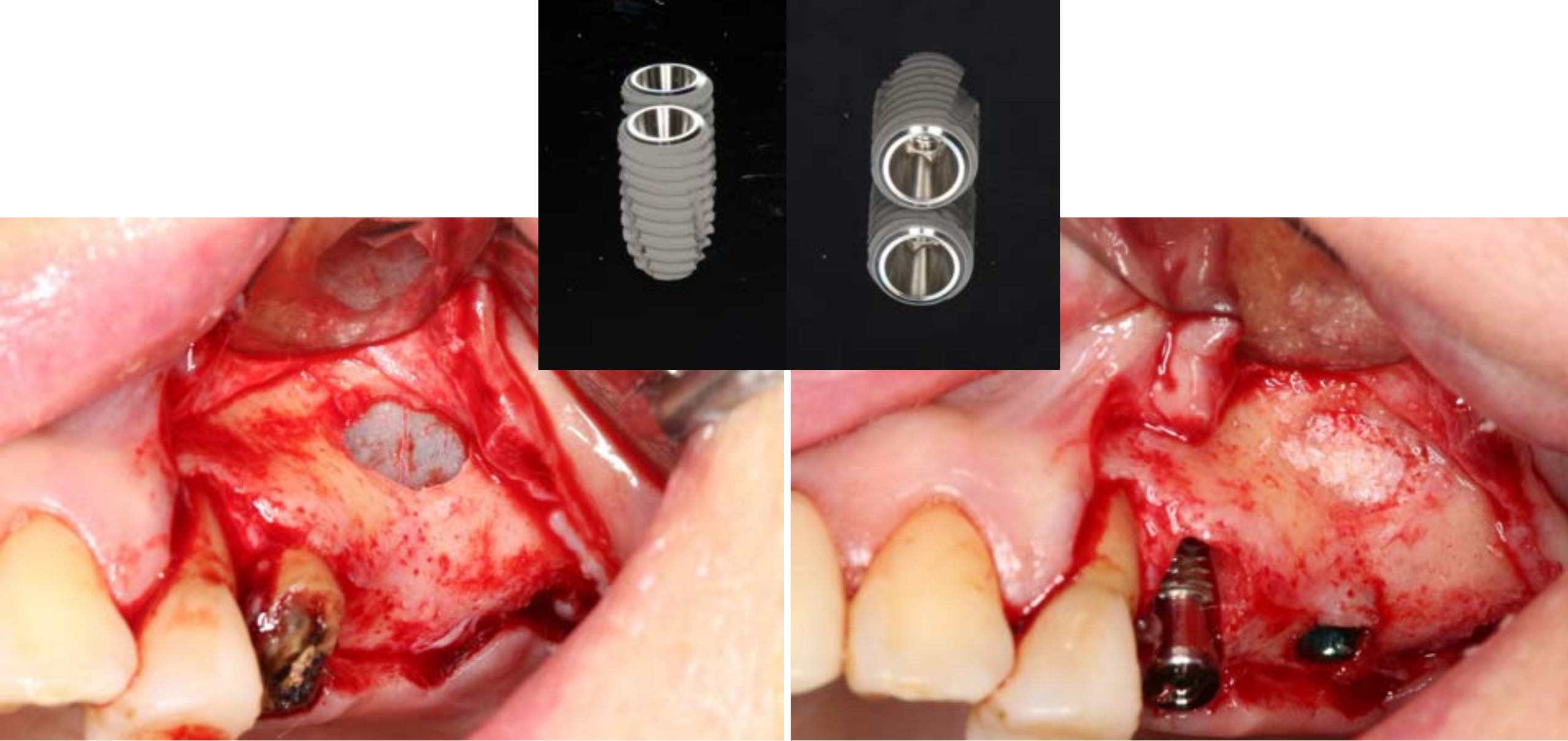


bright BL



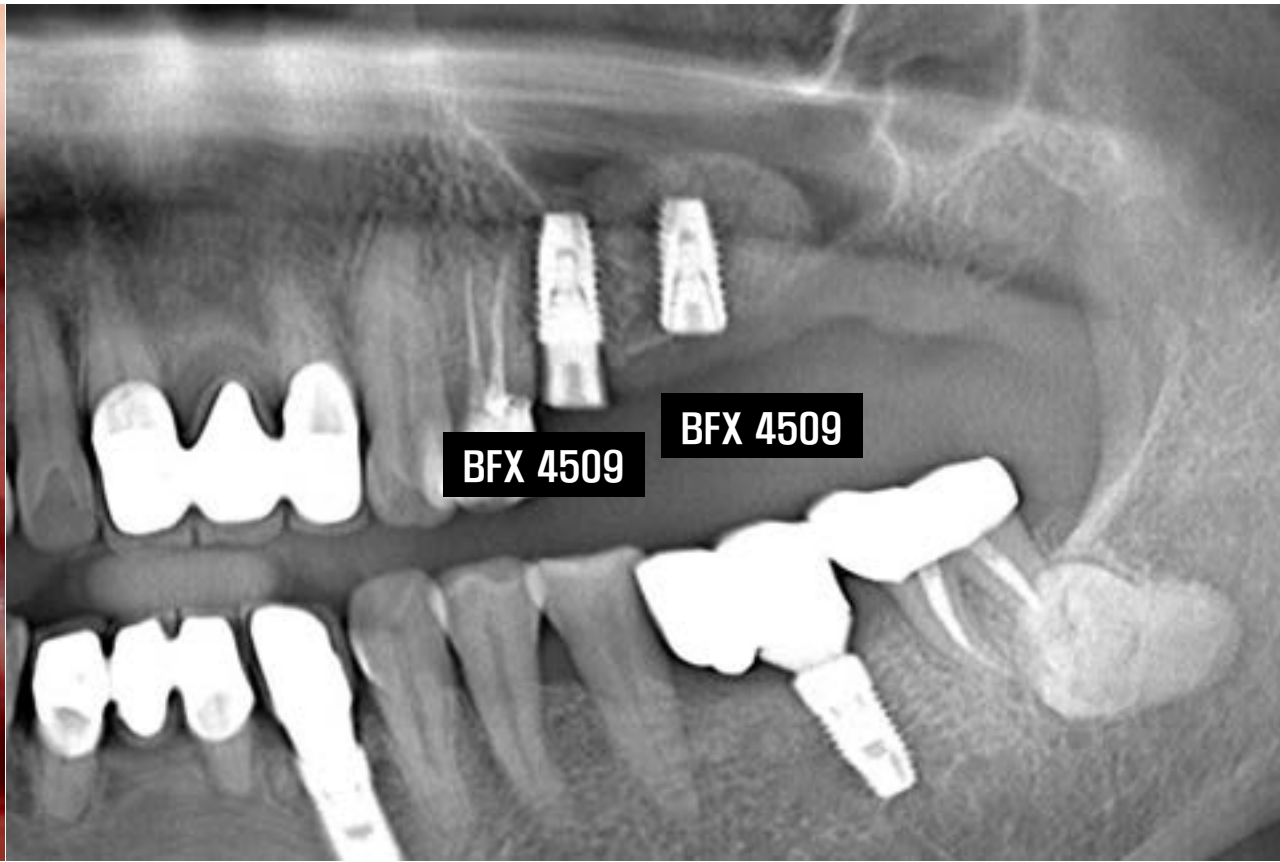
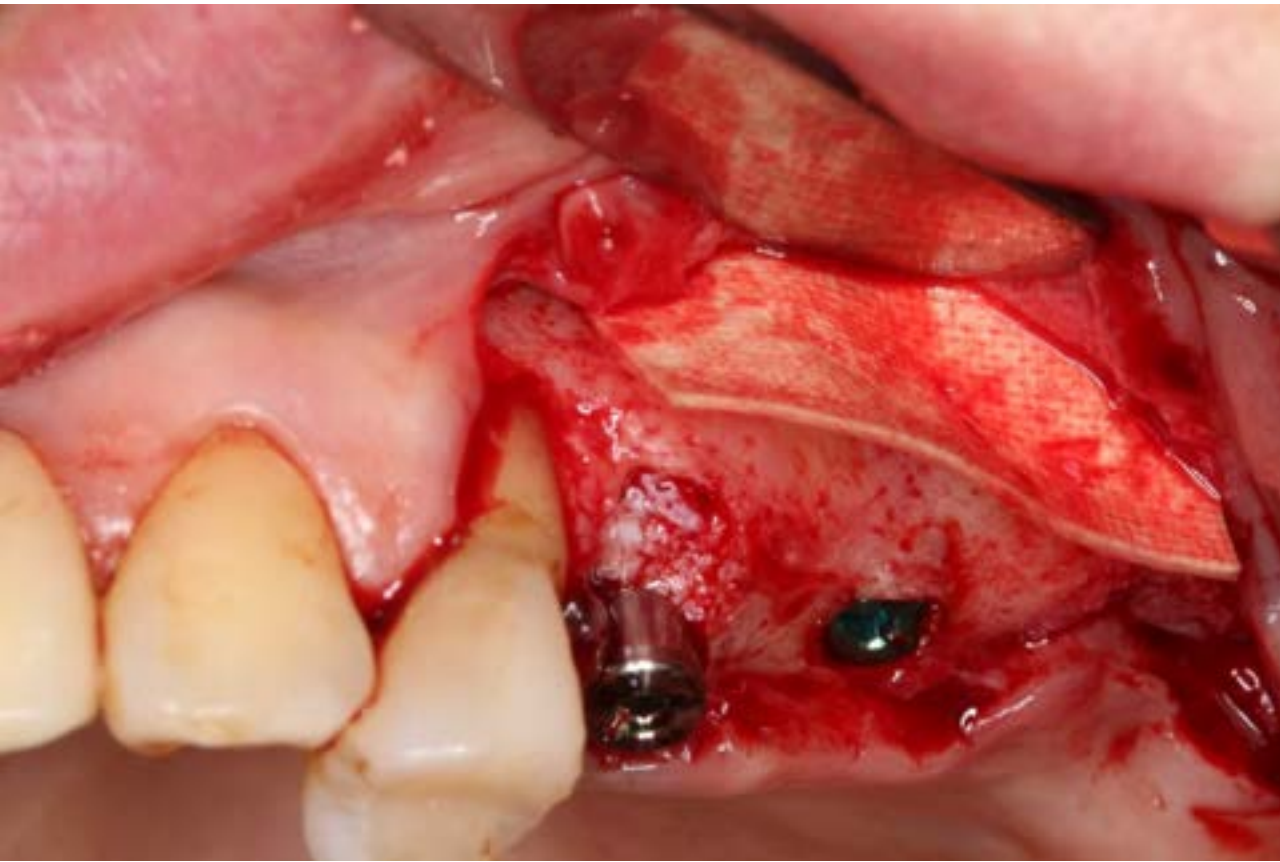


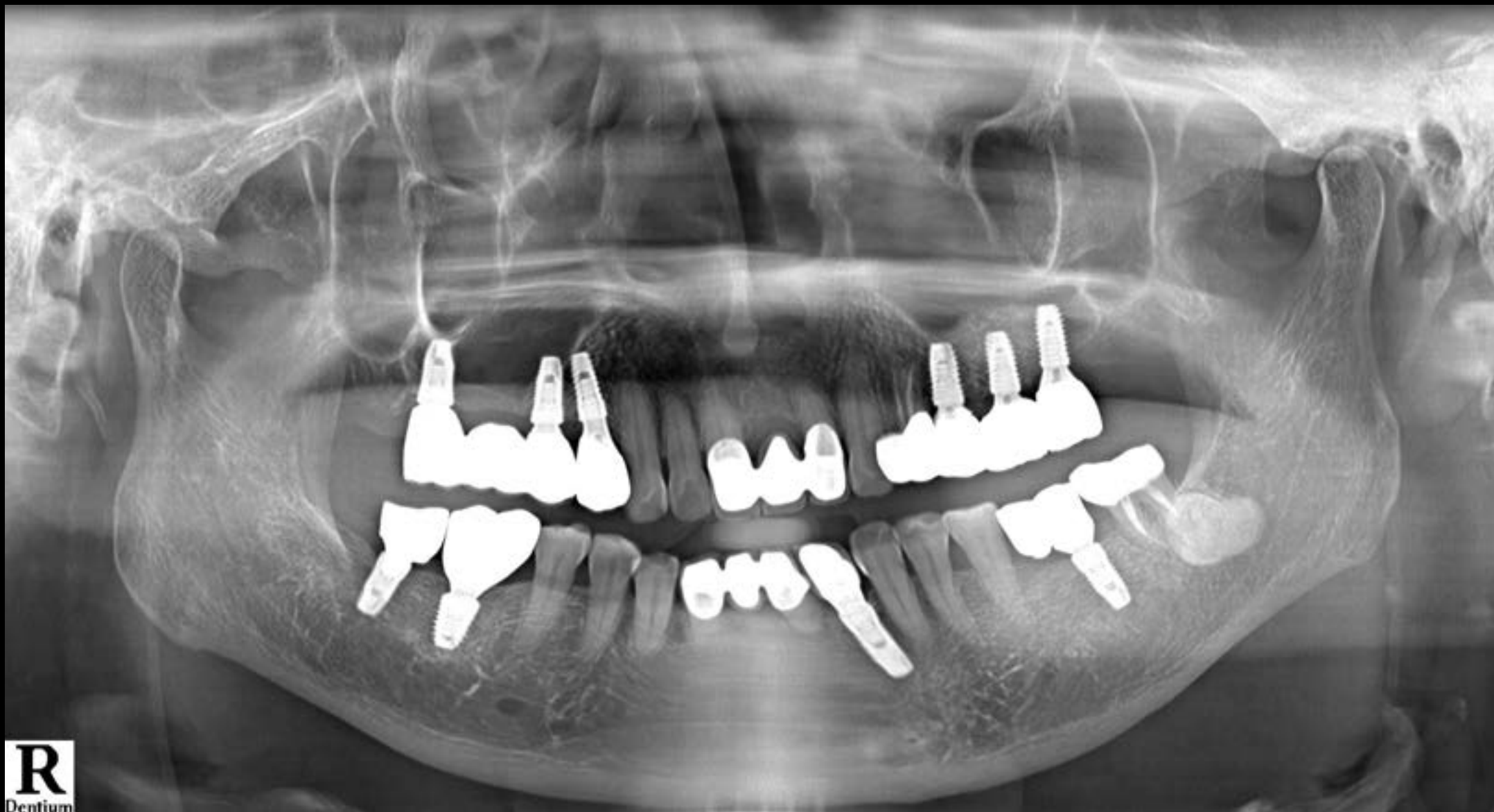


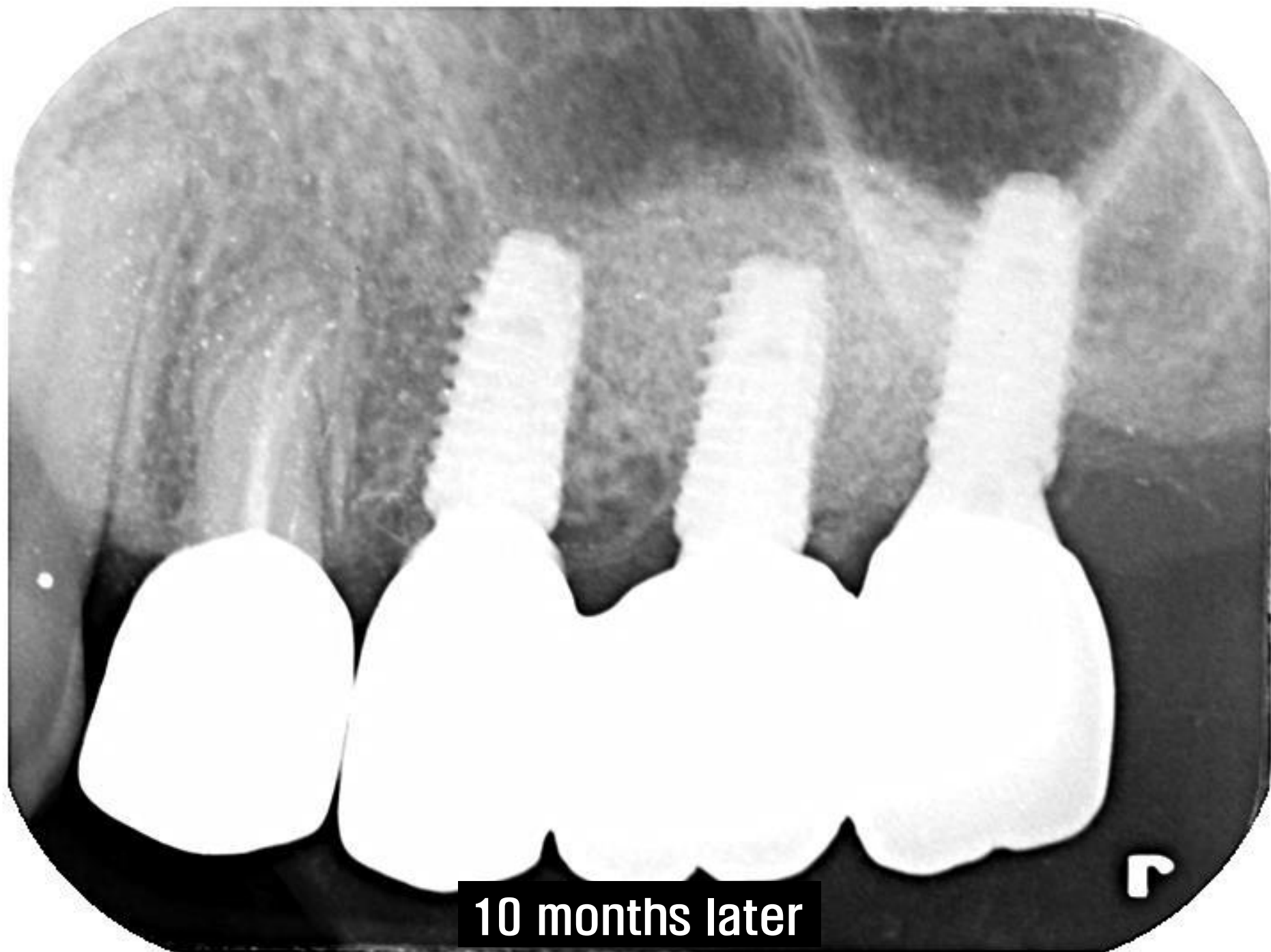
it can save marginal bone

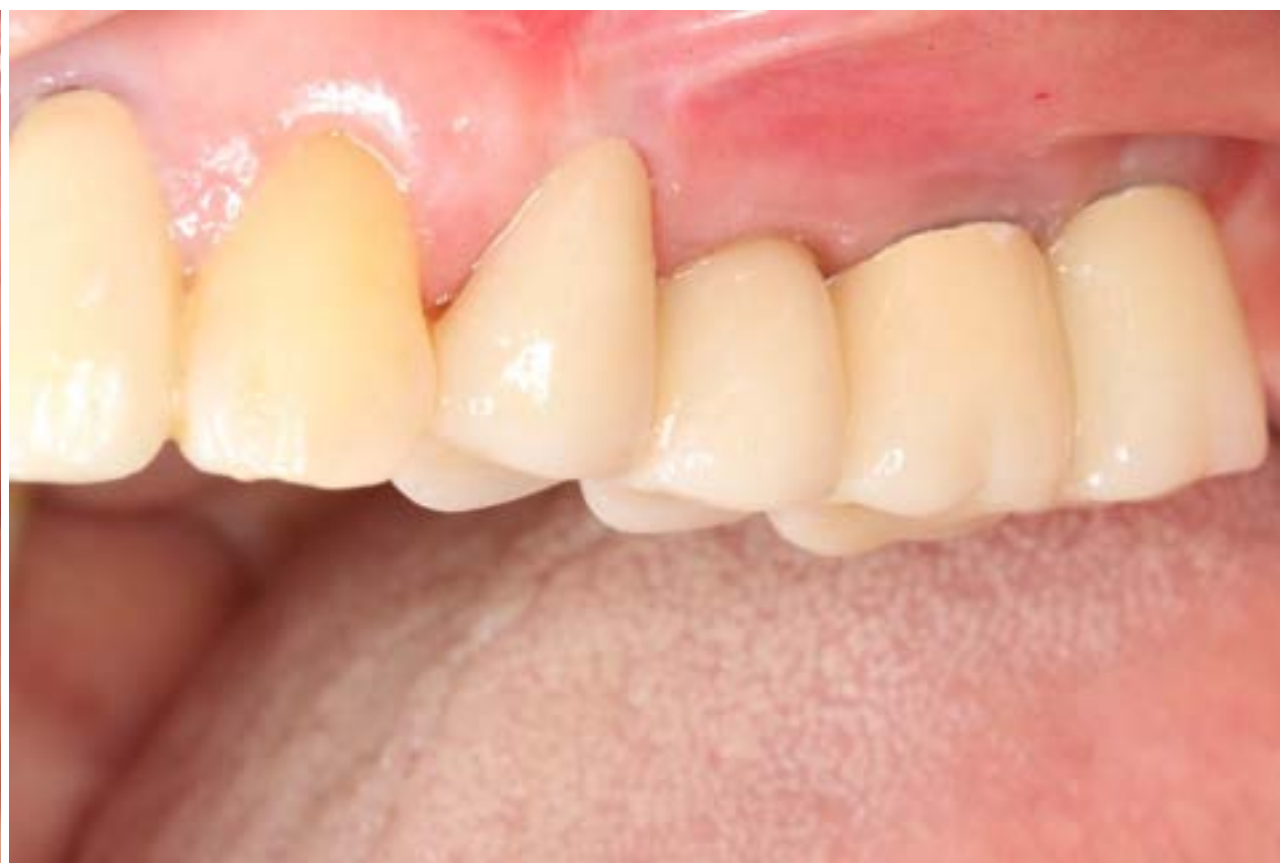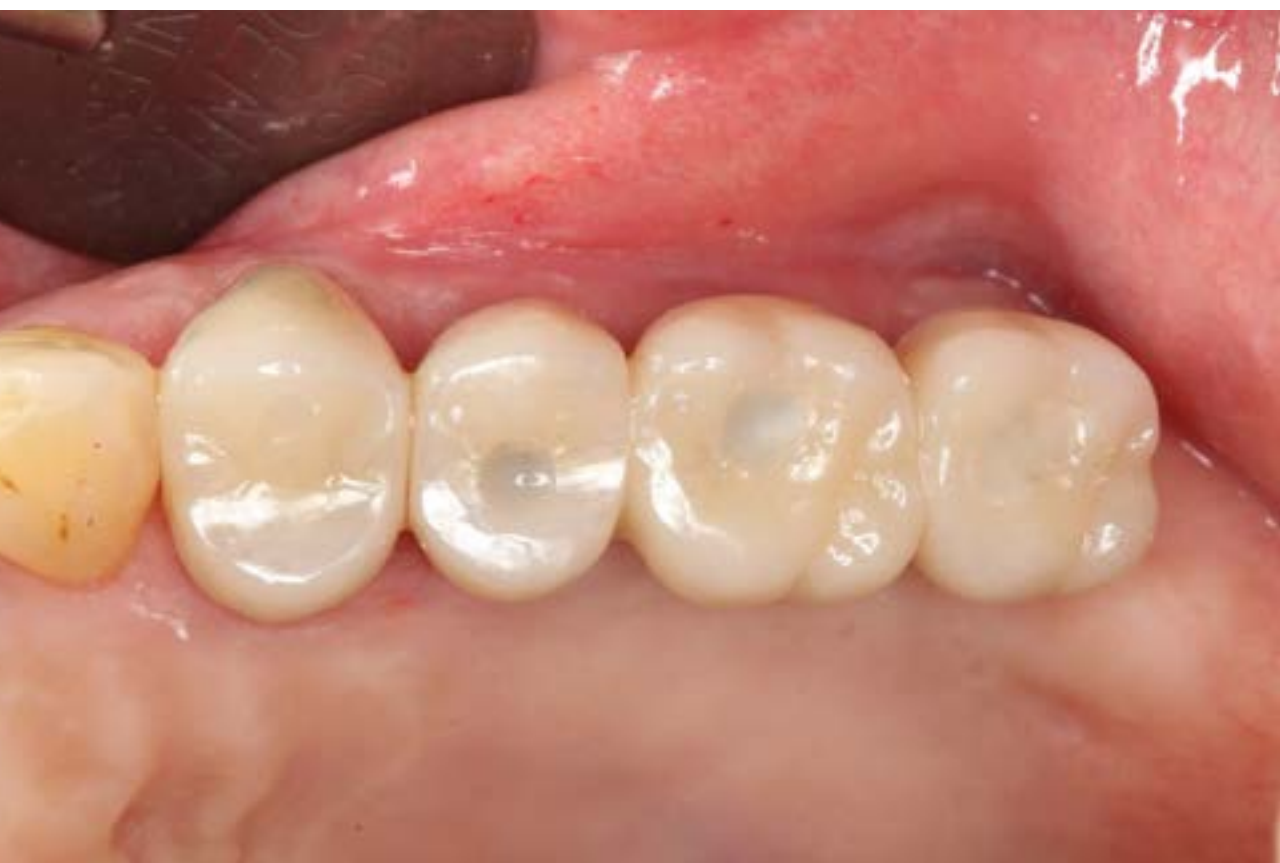Keep the marginal bone : bright BL



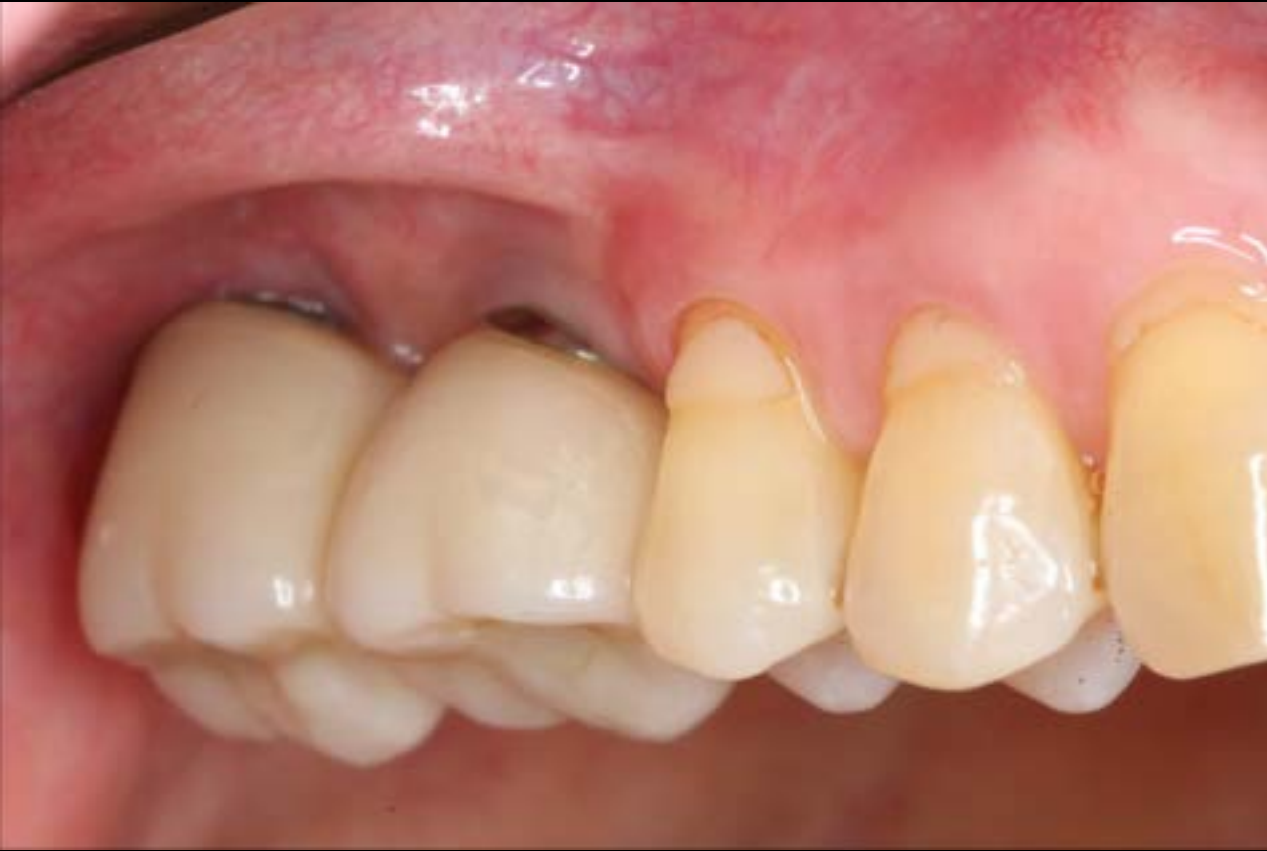



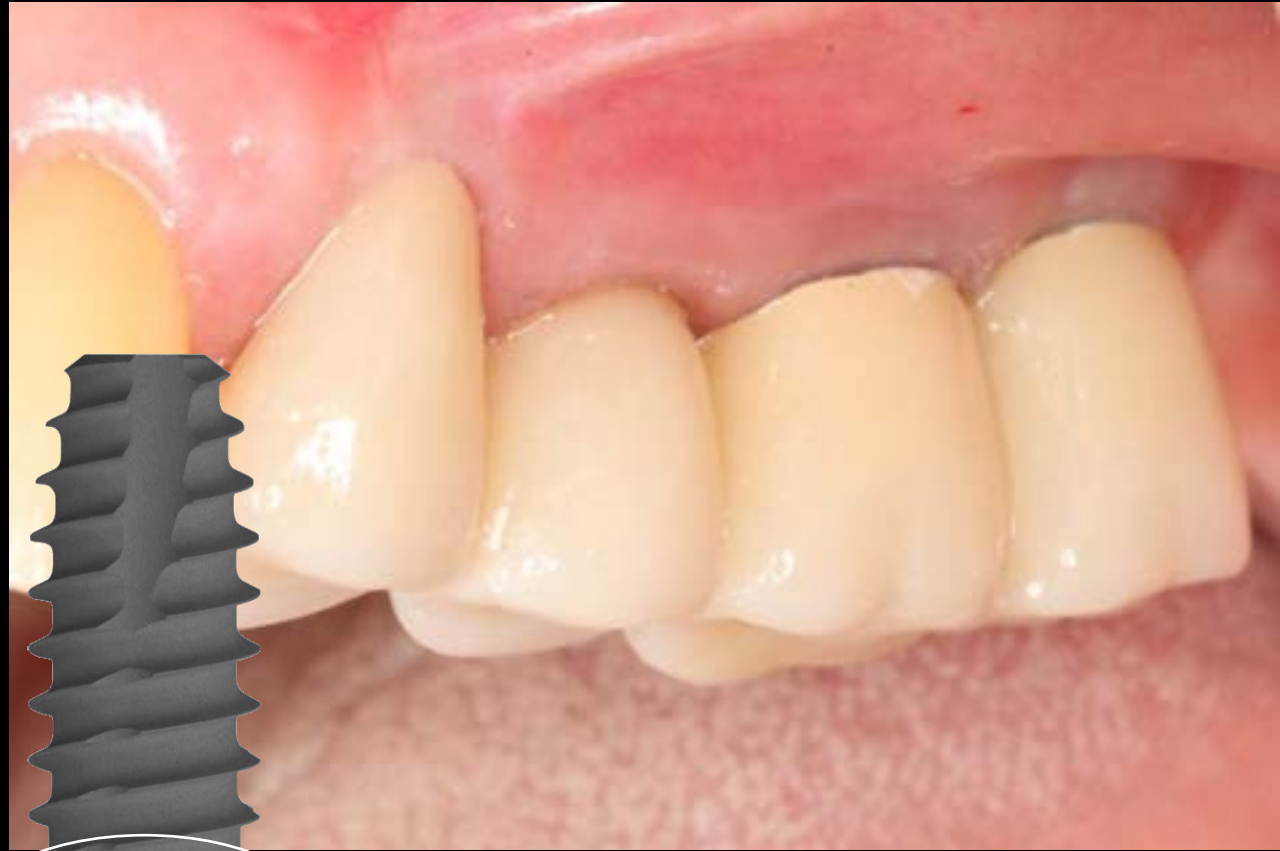10 months later



Keep the marginal bone : bright BL



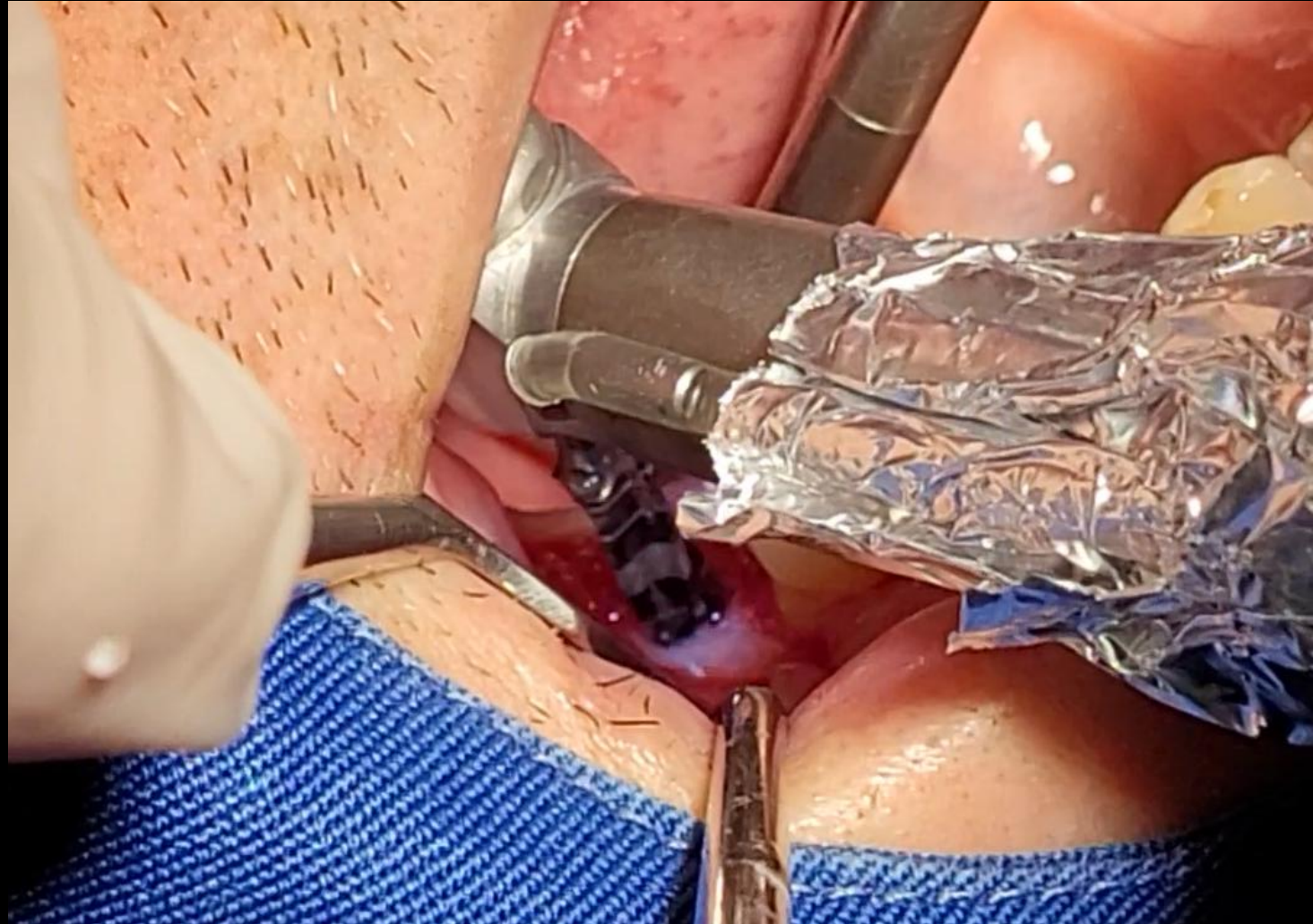
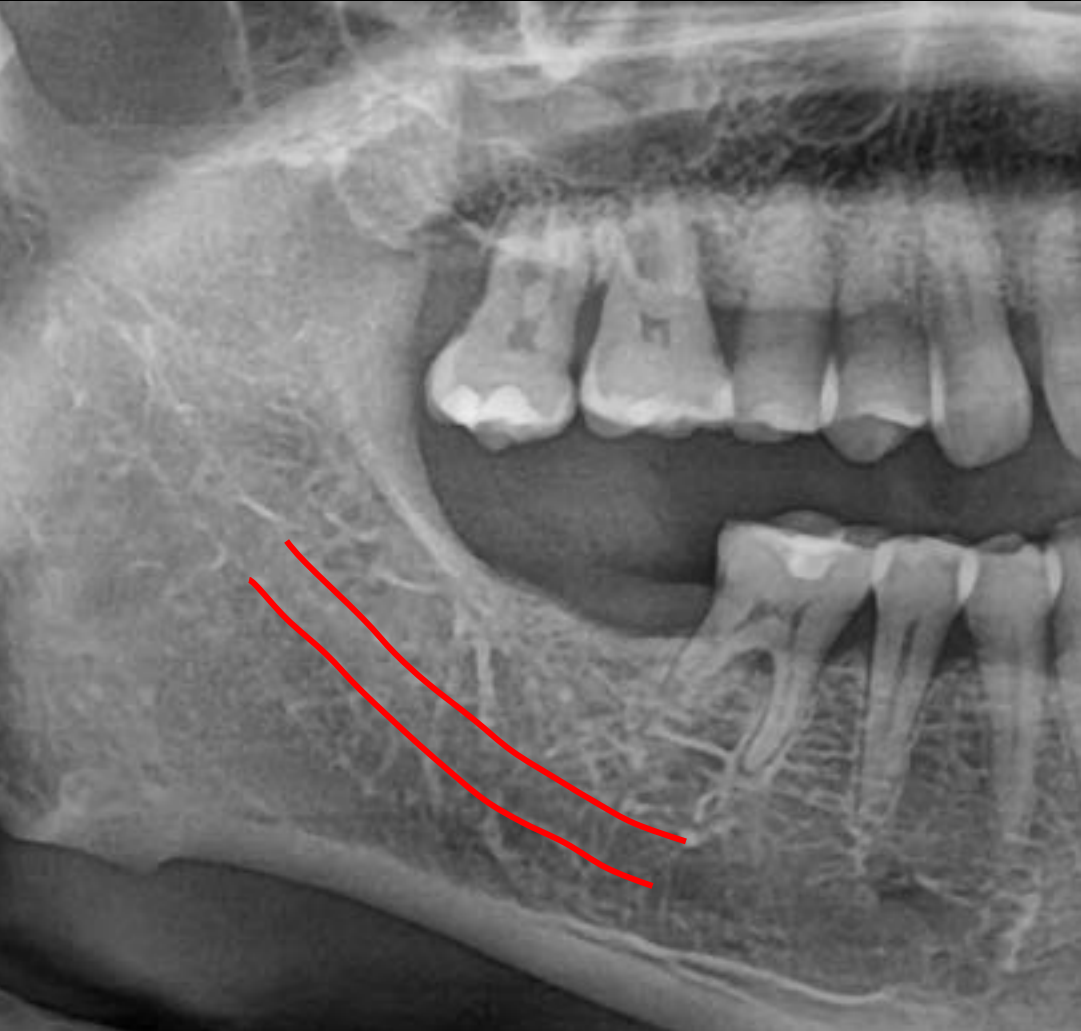
Tapered

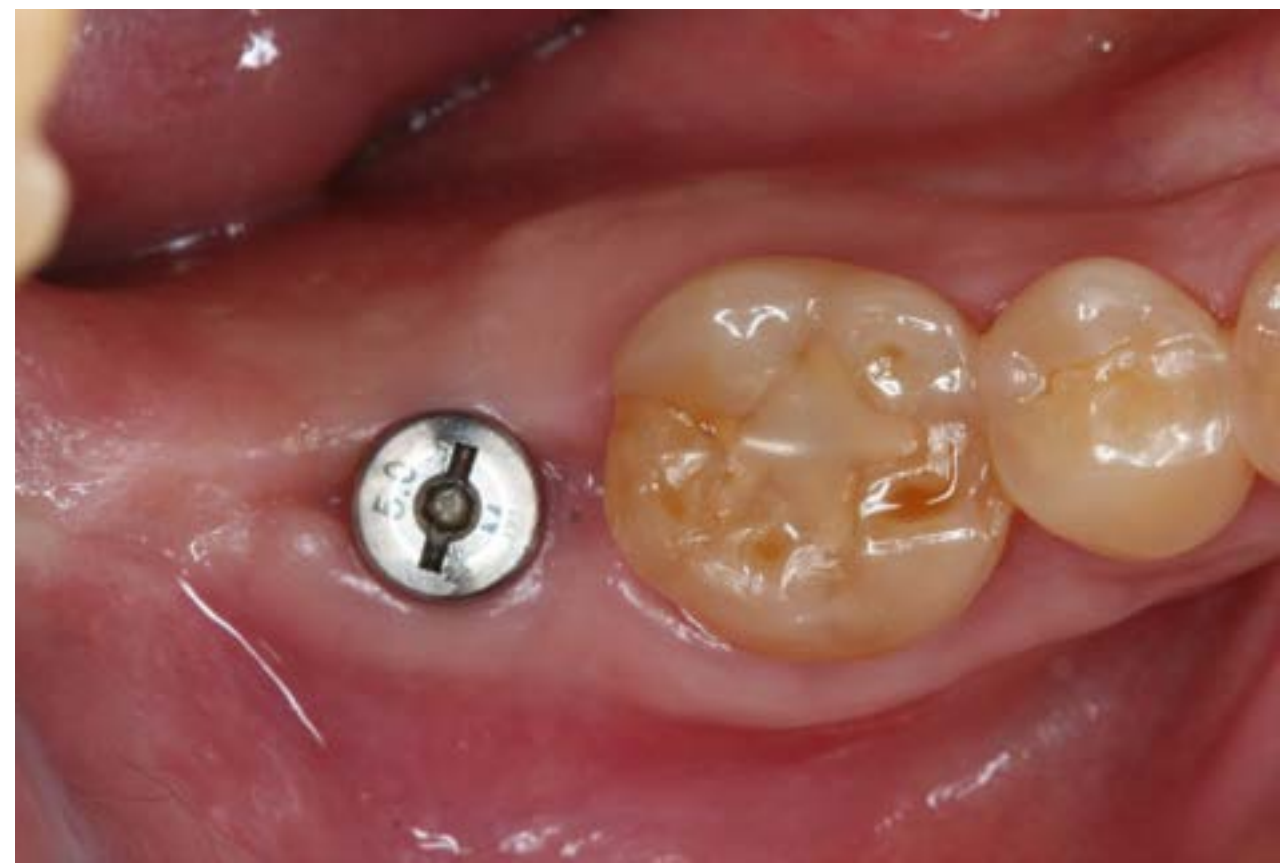
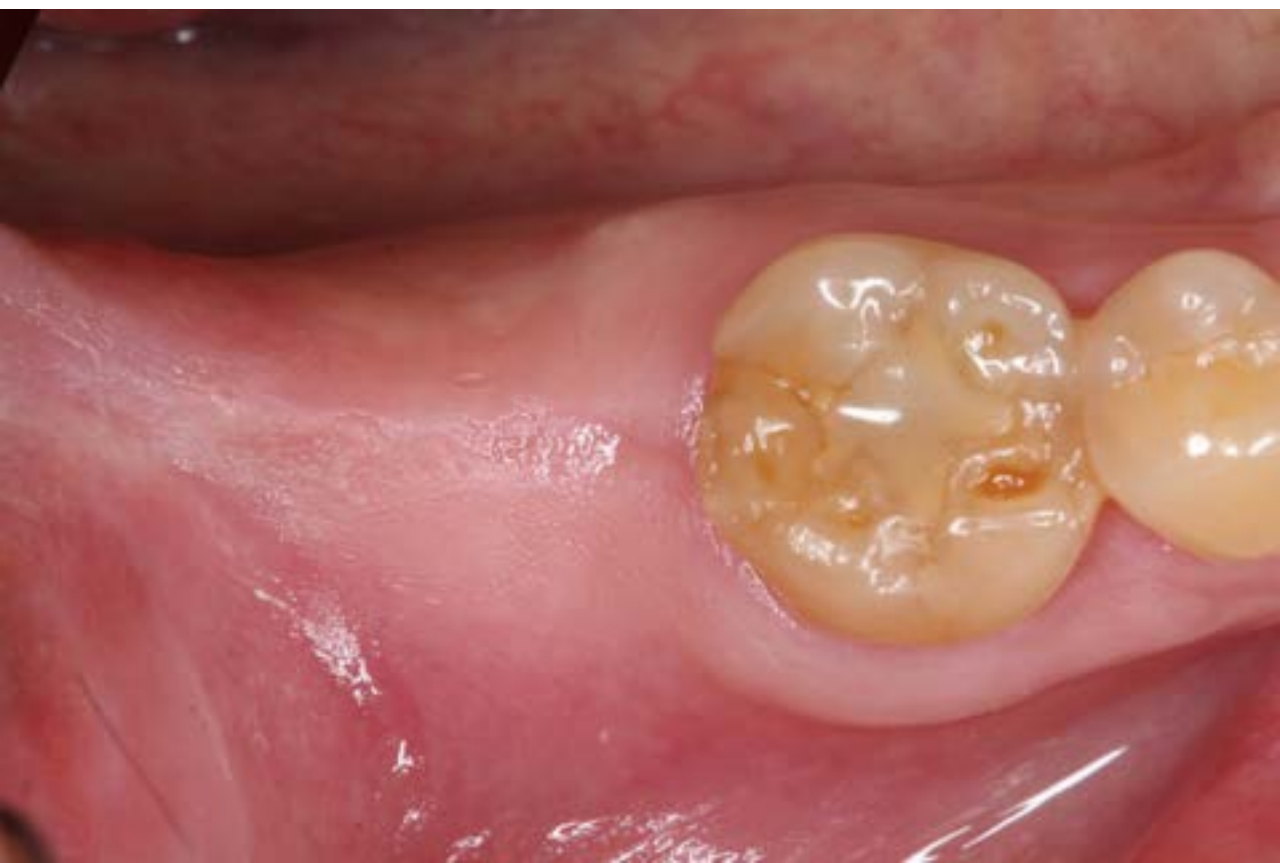
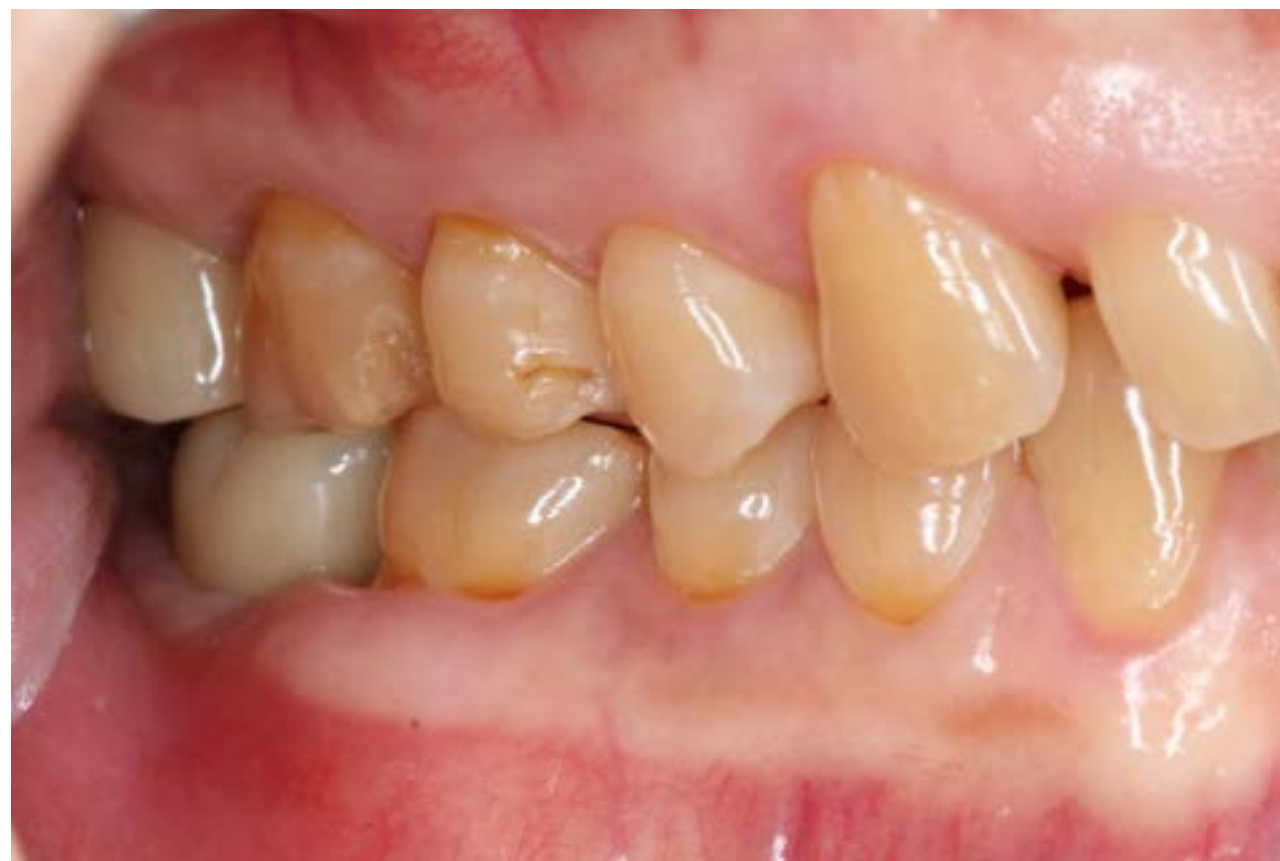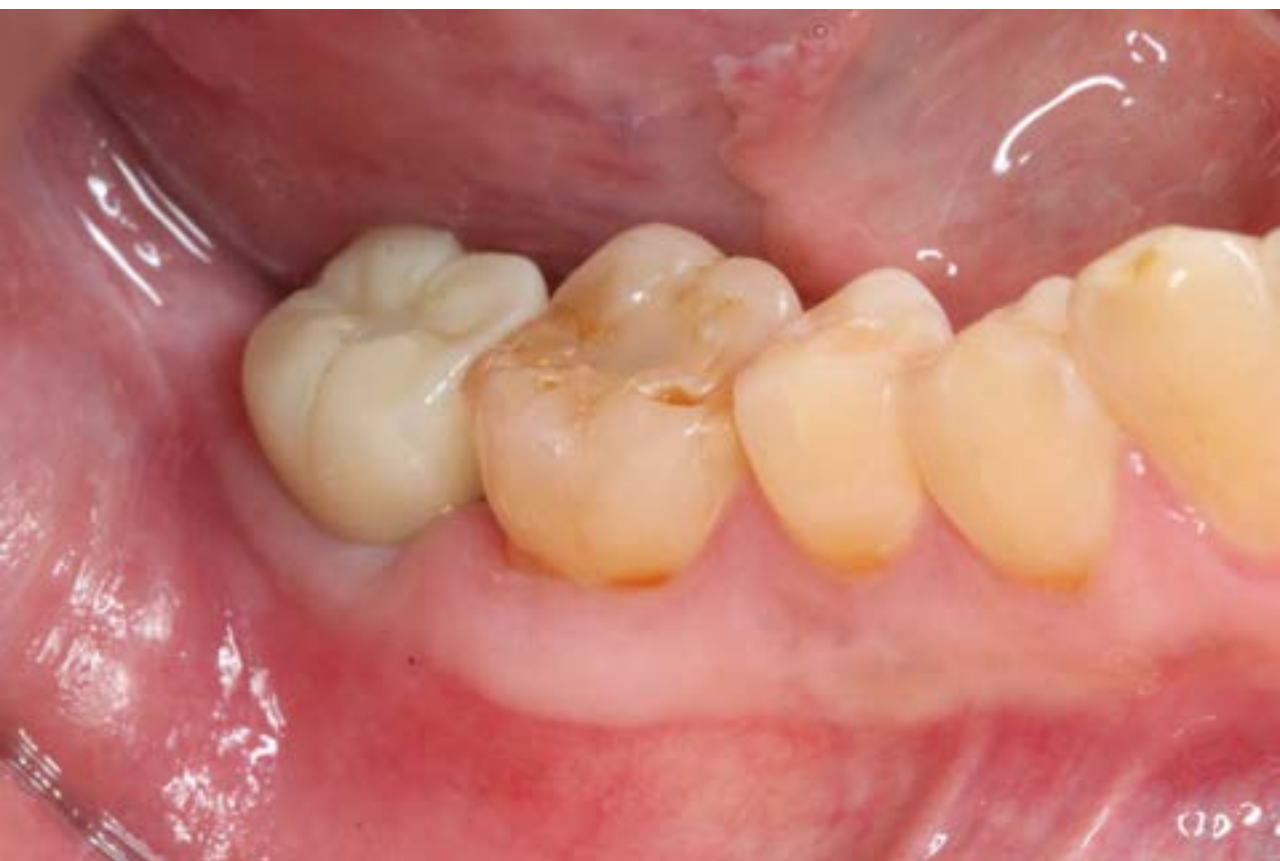bright BL

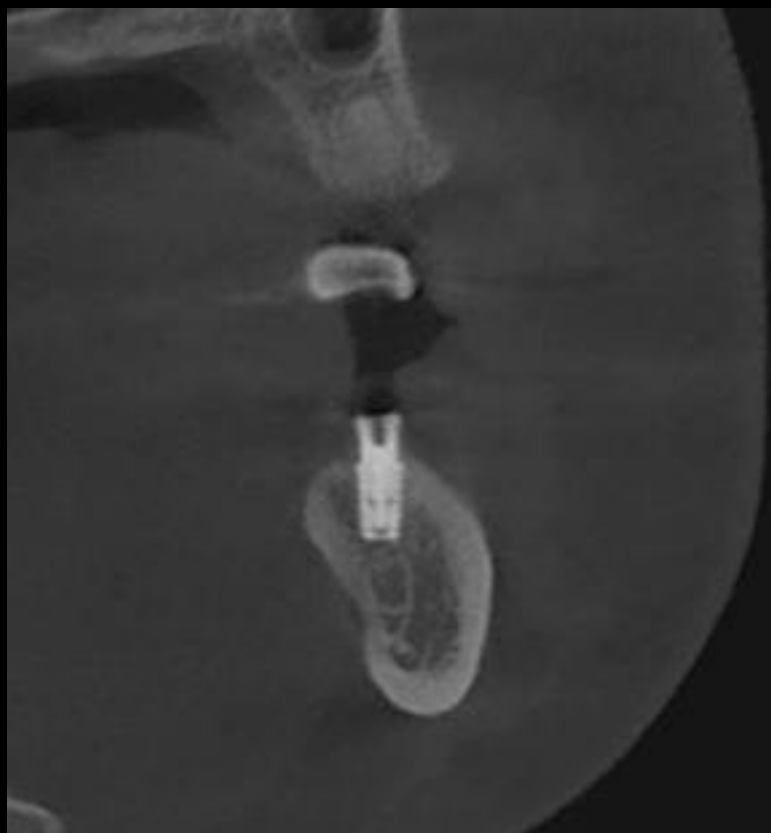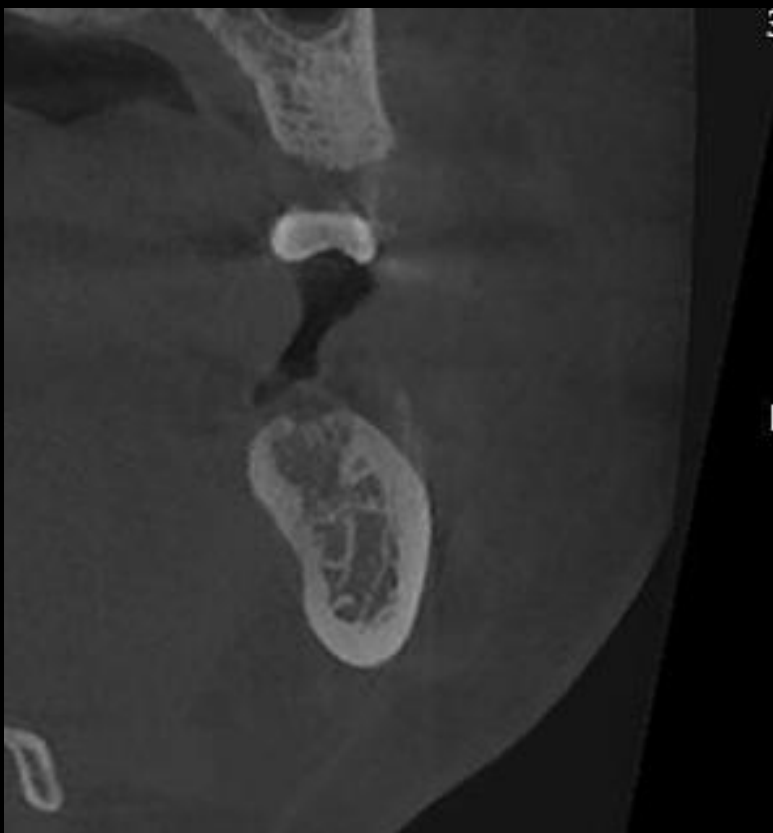


bright BL 7mm : post. mandible

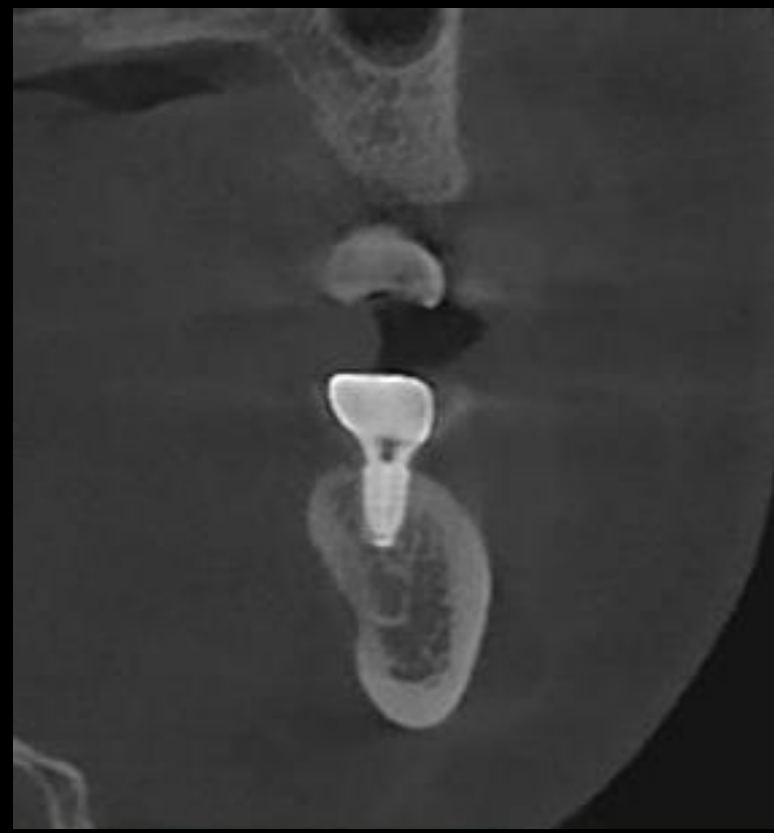








installation




2 months later

**Bright BL ... is
complementary in many ways**



bright TL


bright TL



bright TL



External connection



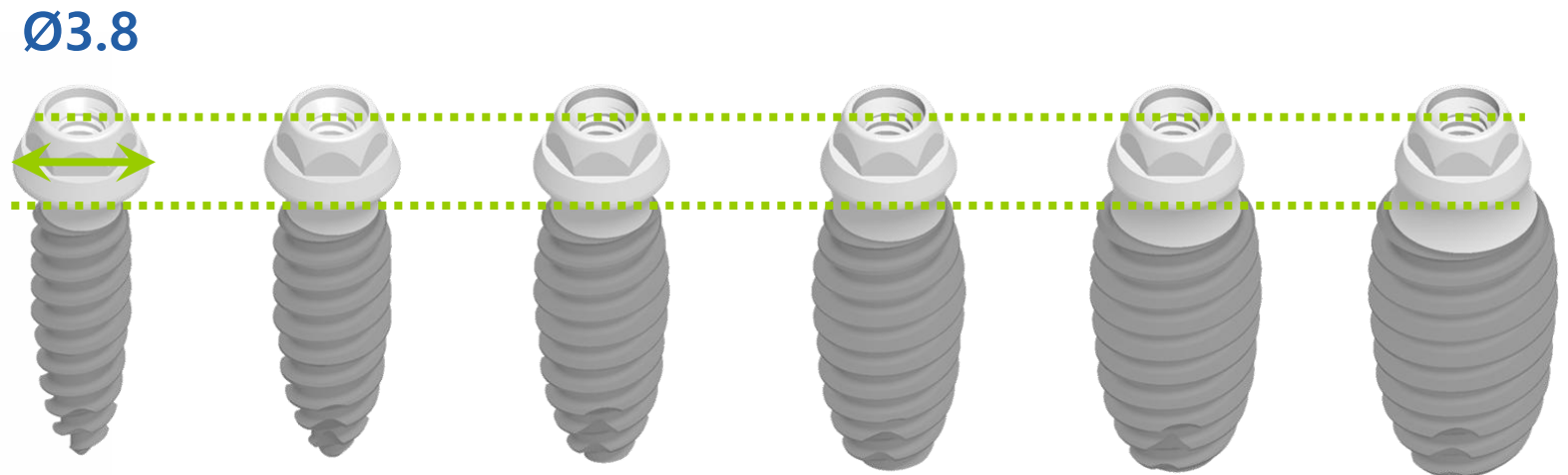
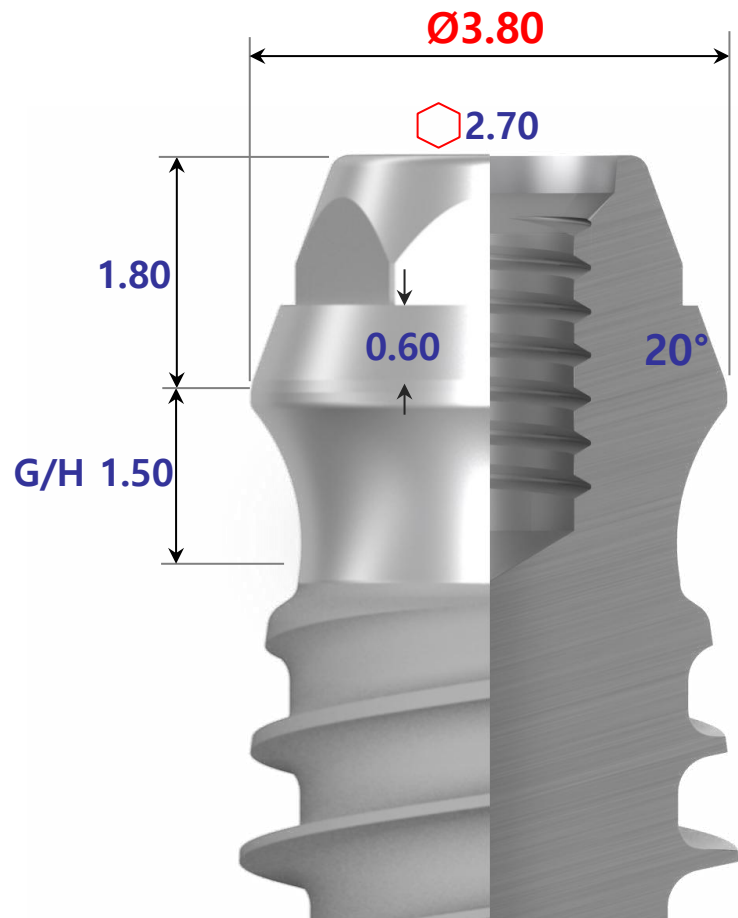
Beveled external connection



Tissue Level Platform

1-Platforms for All Indications

- One Connection – One Prosthetic Line



Tissue Level Platform

20° External Taper Fit | External Hex Connection

- Excellent Joint Stability
- Multi Purpose and Easy-to-Use Connection in Trans-Mucosa

External Hex



- Confidence Application

Taper-fit

- External Conical Seal Effect
- High Flexibility and Strength
- Easy Handling for Multiple Prosthetic

Reduced Neck

- Slim and Under-contoured



Tissue Level Implant Thread

For Simplify Surgical Procedure

- Thin, Deep & Sharp Thread
- Final Drill Only

Pitch 0.90

Double thread

Thin & Deep
Thread Design

Easy Insertion

Optimal Primary Stability

Increase Bone-Implant Contact Area

Bone preservation

Ensure Confidence in Immediate Loading

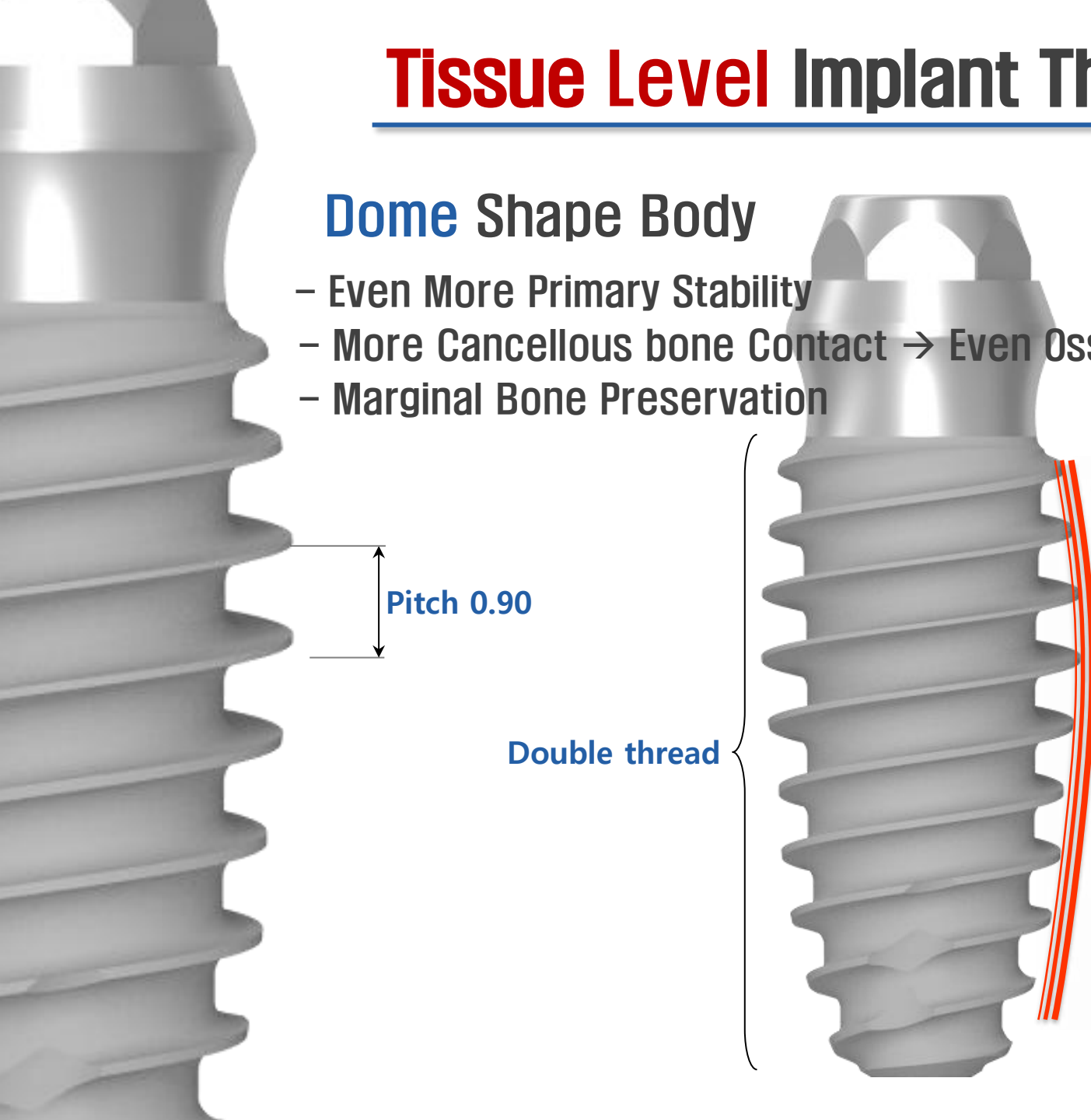
Tissue Level Implant Thread

Dome Shape Body

- Even More Primary Stability
- More Cancellous bone Contact → Even Osseointegration time
- Marginal Bone Preservation


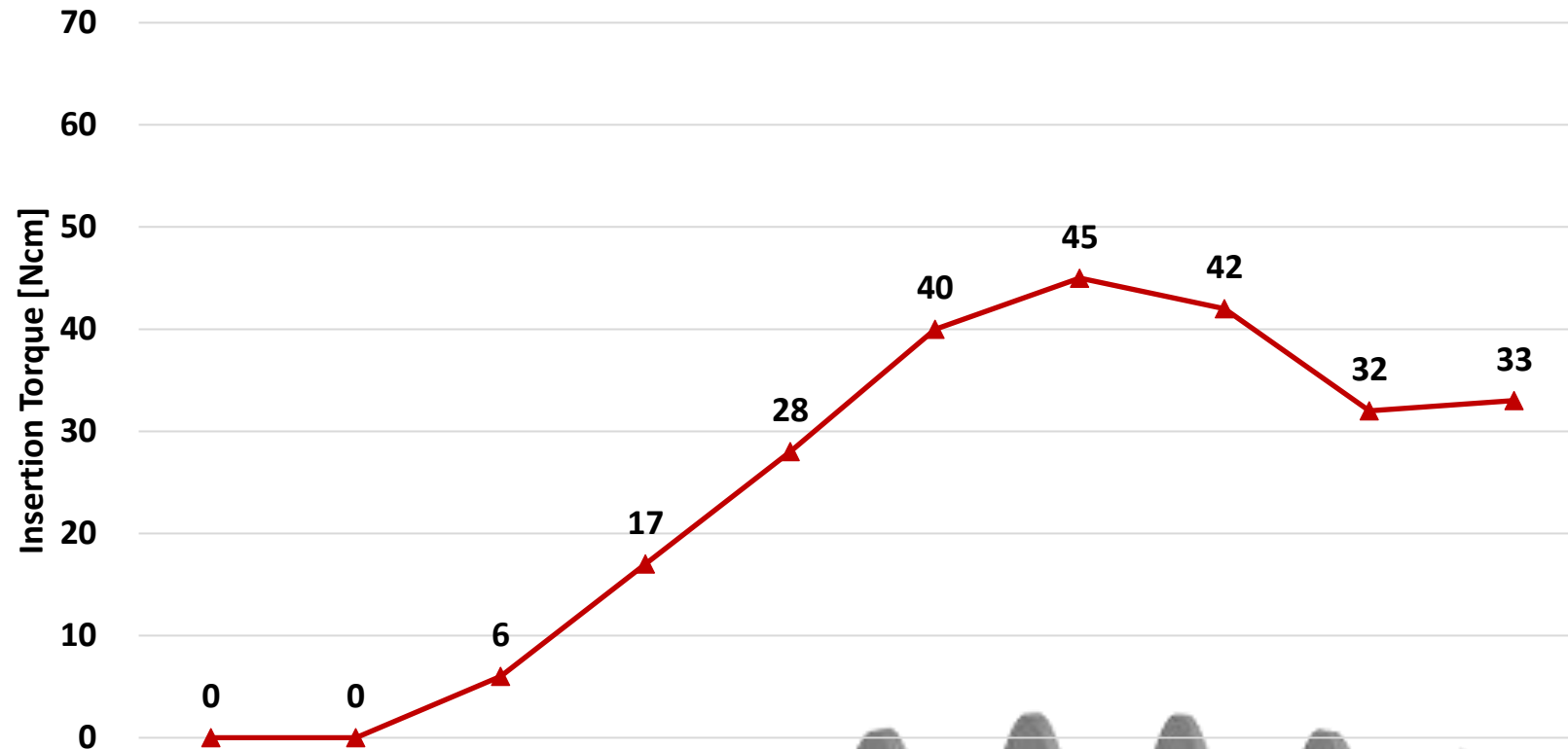
Pitch 0.90

Double thread



Tissue Level Drilling Procedure

Insertion Torque Pattern @ Type 2 bone

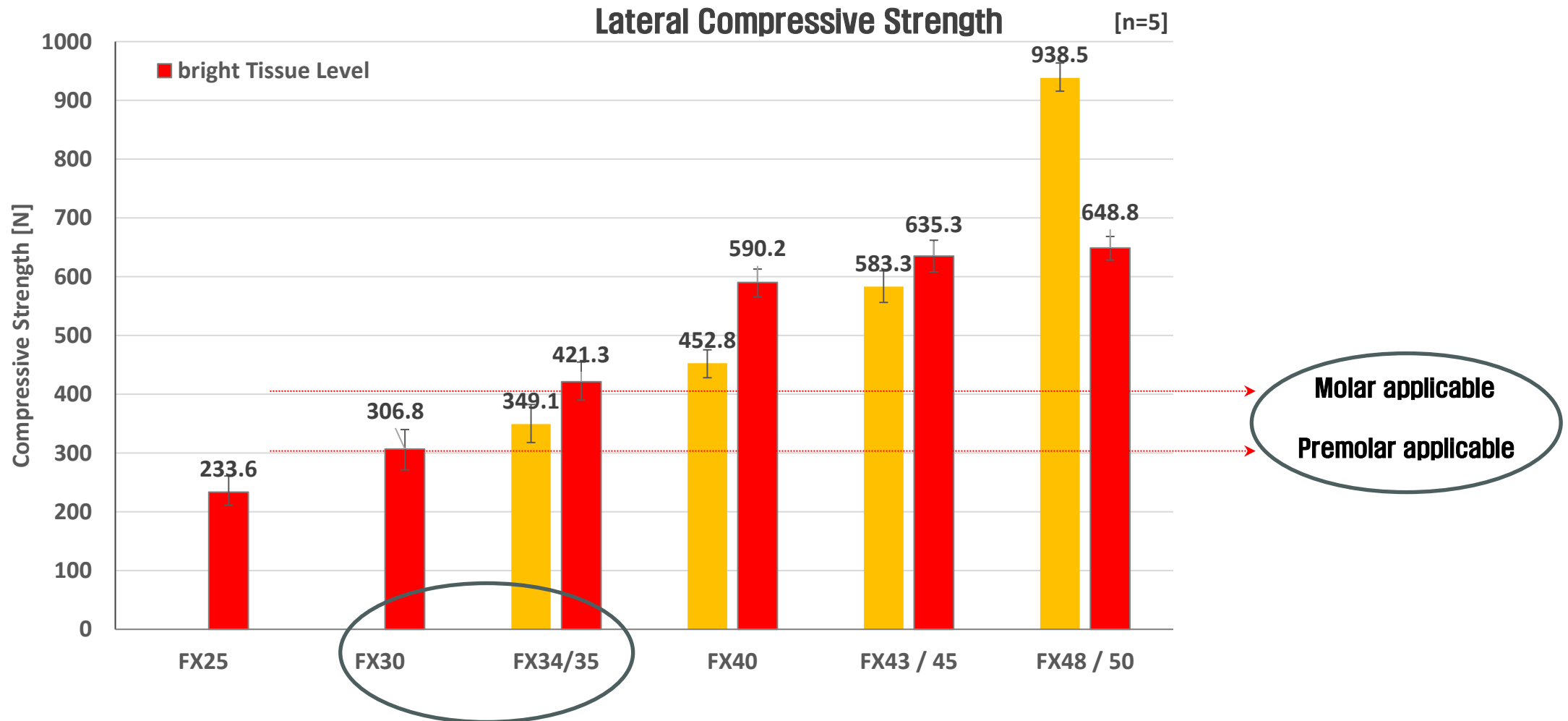


strength

Tissue Level Implant Strength

thin but strong

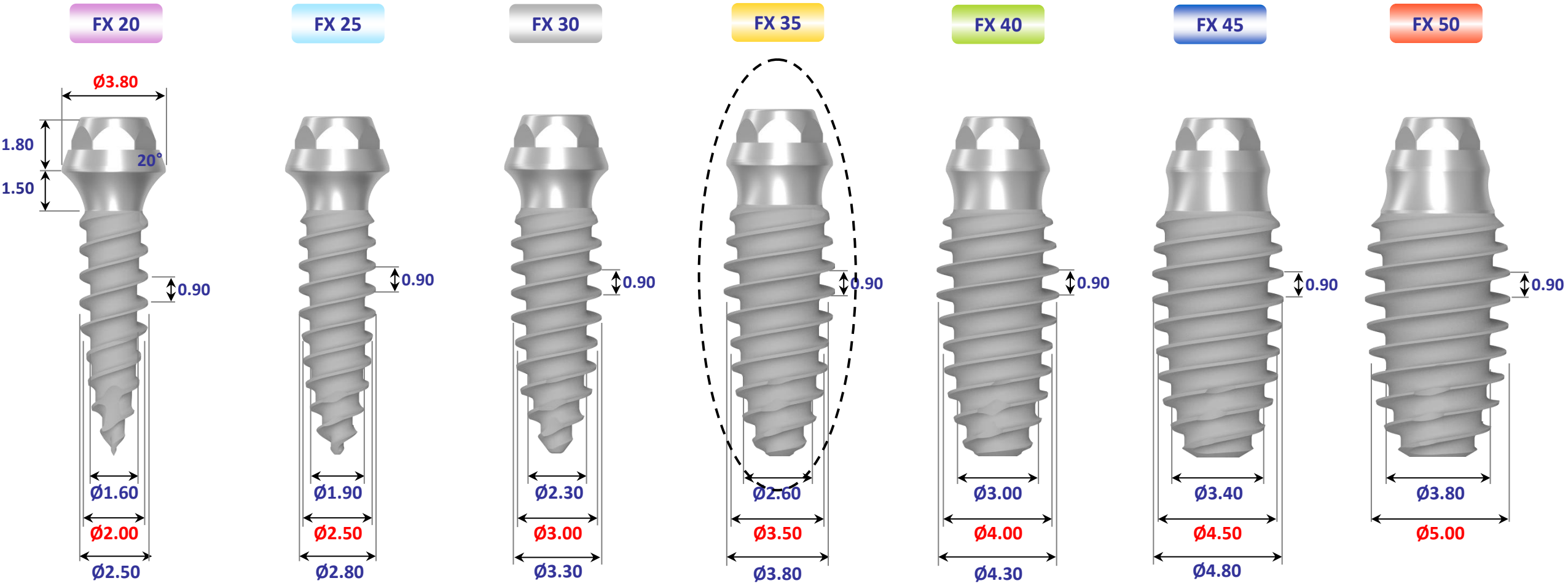
– Excellent Joint Stability



Tissue Level Implant

bright

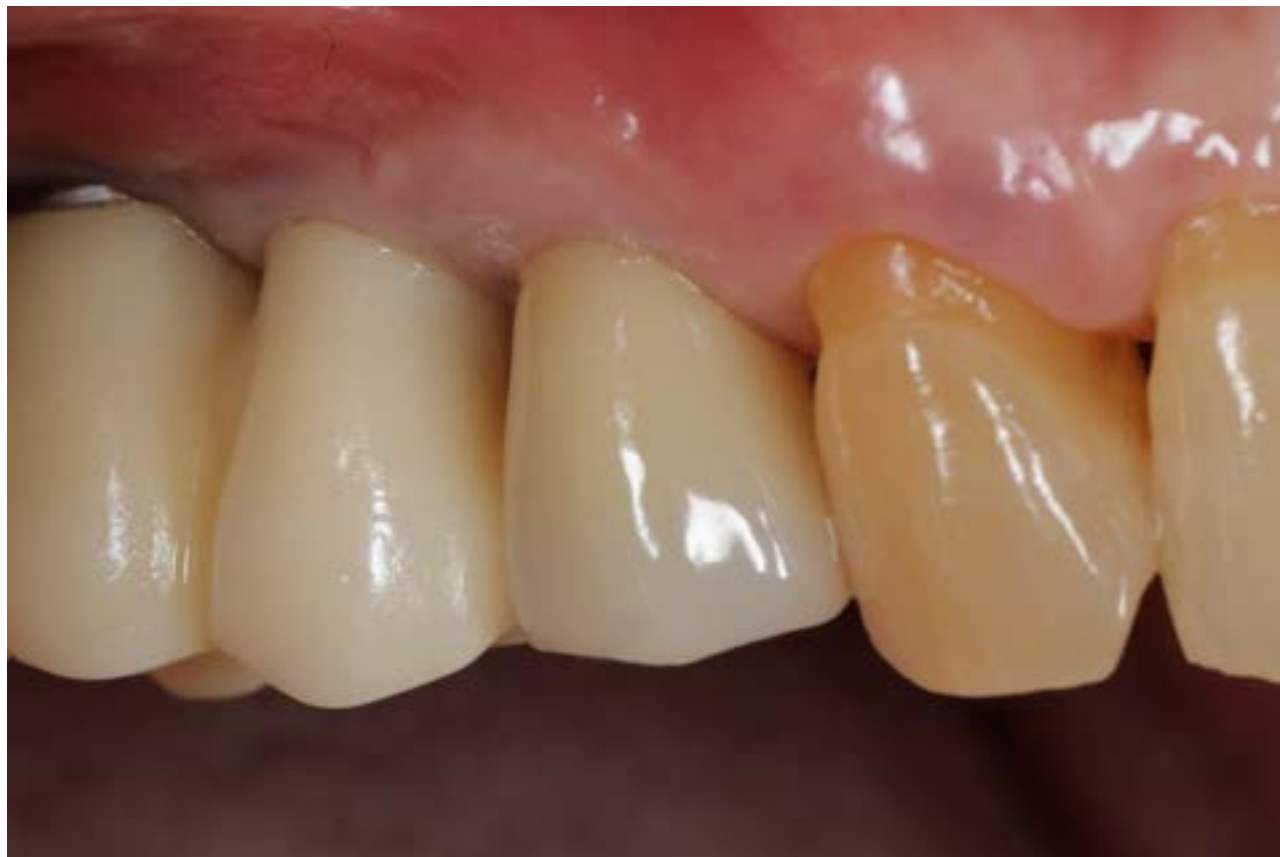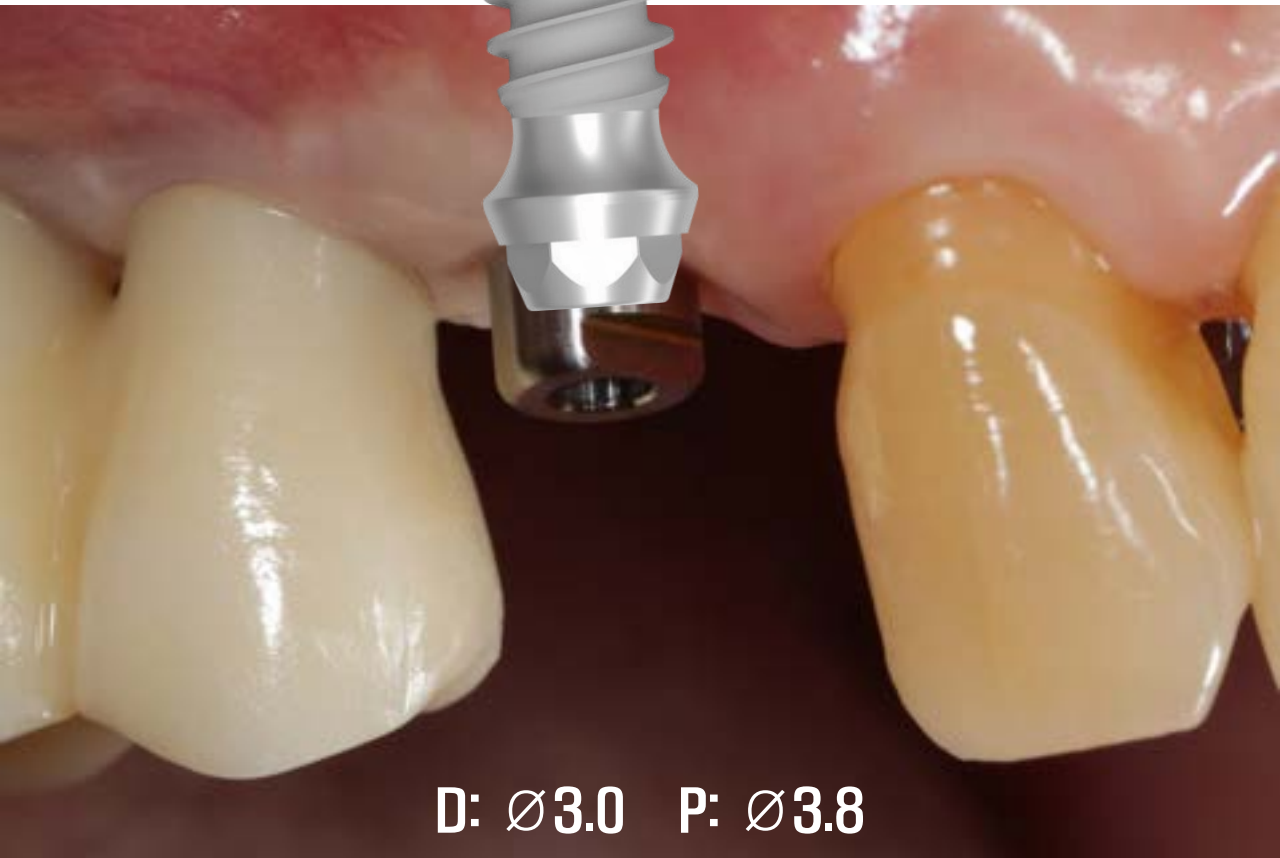Indication



Incisor / Canine / Premolar

Premolar / Molar

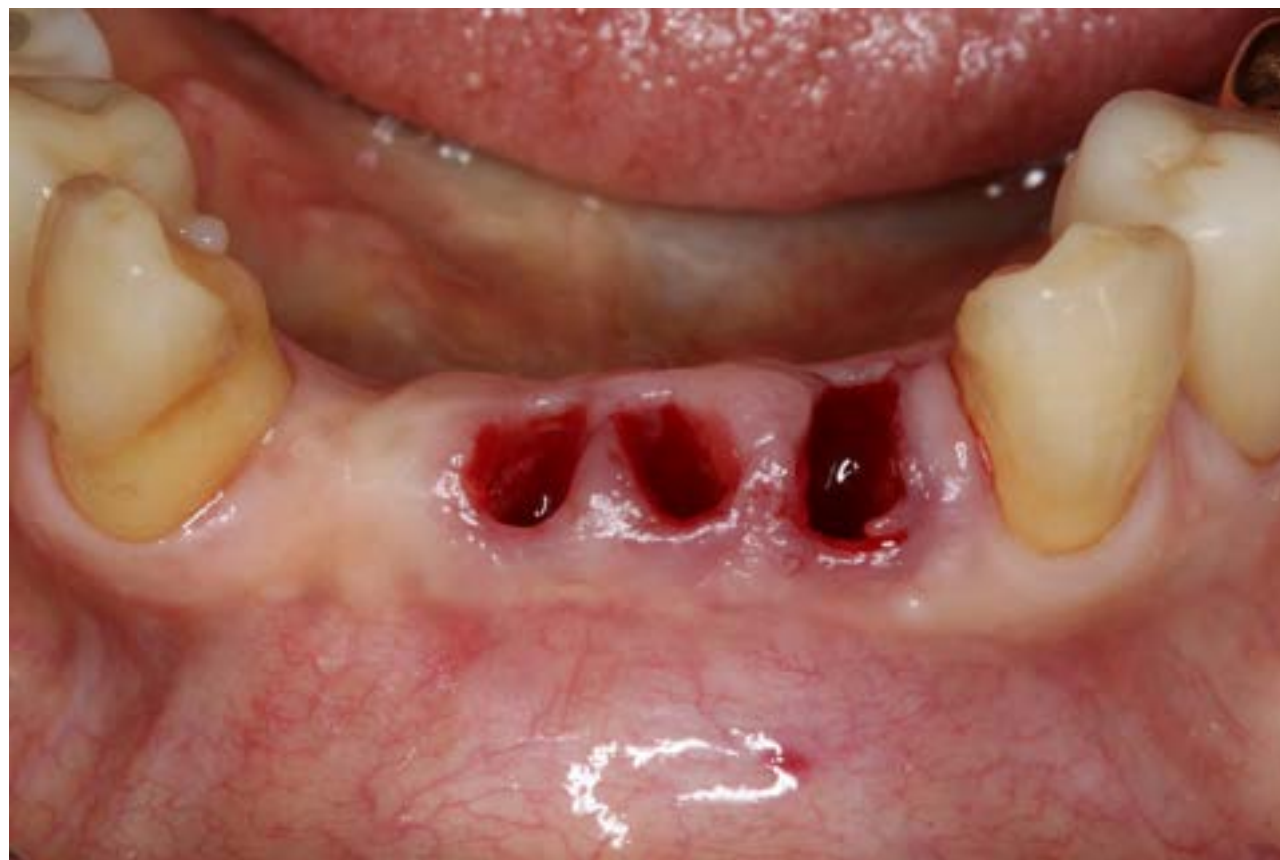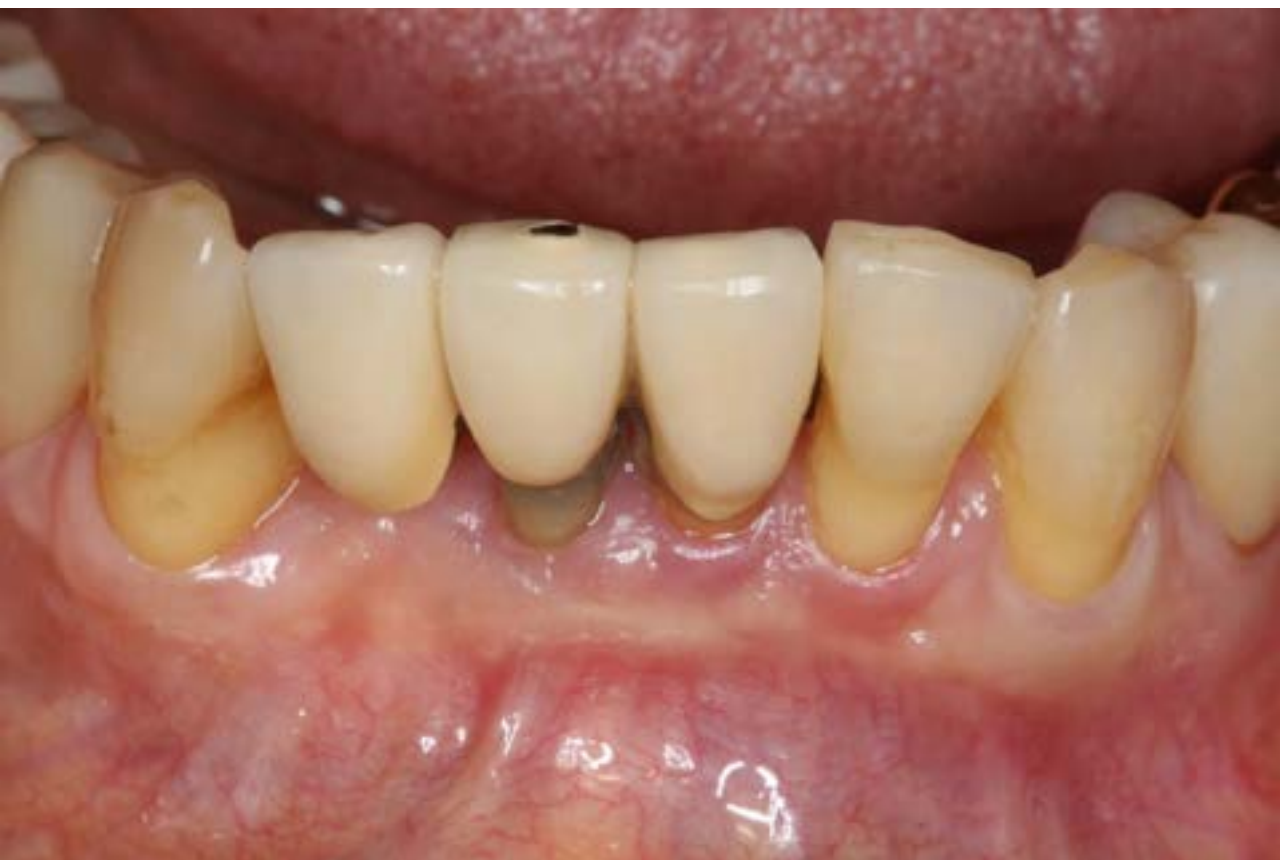Good emergence profile

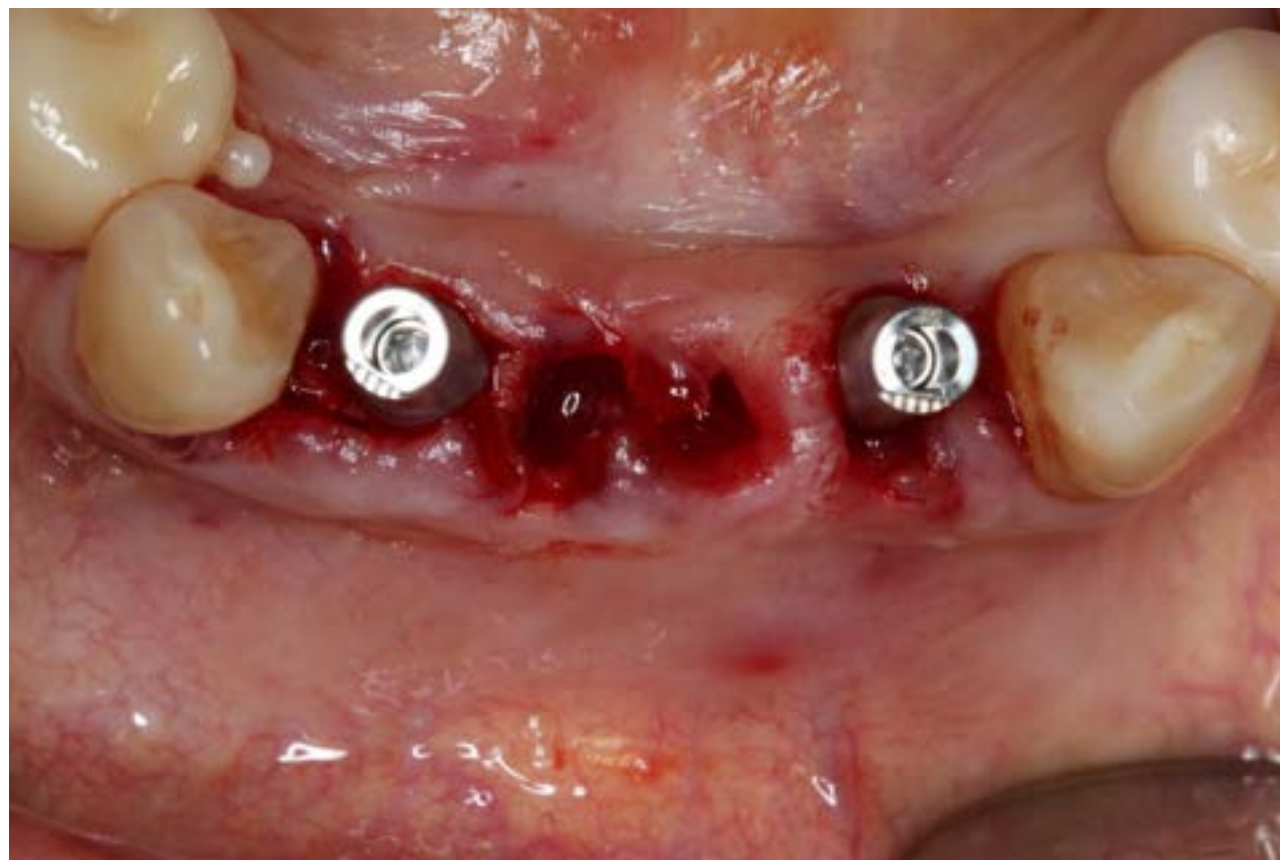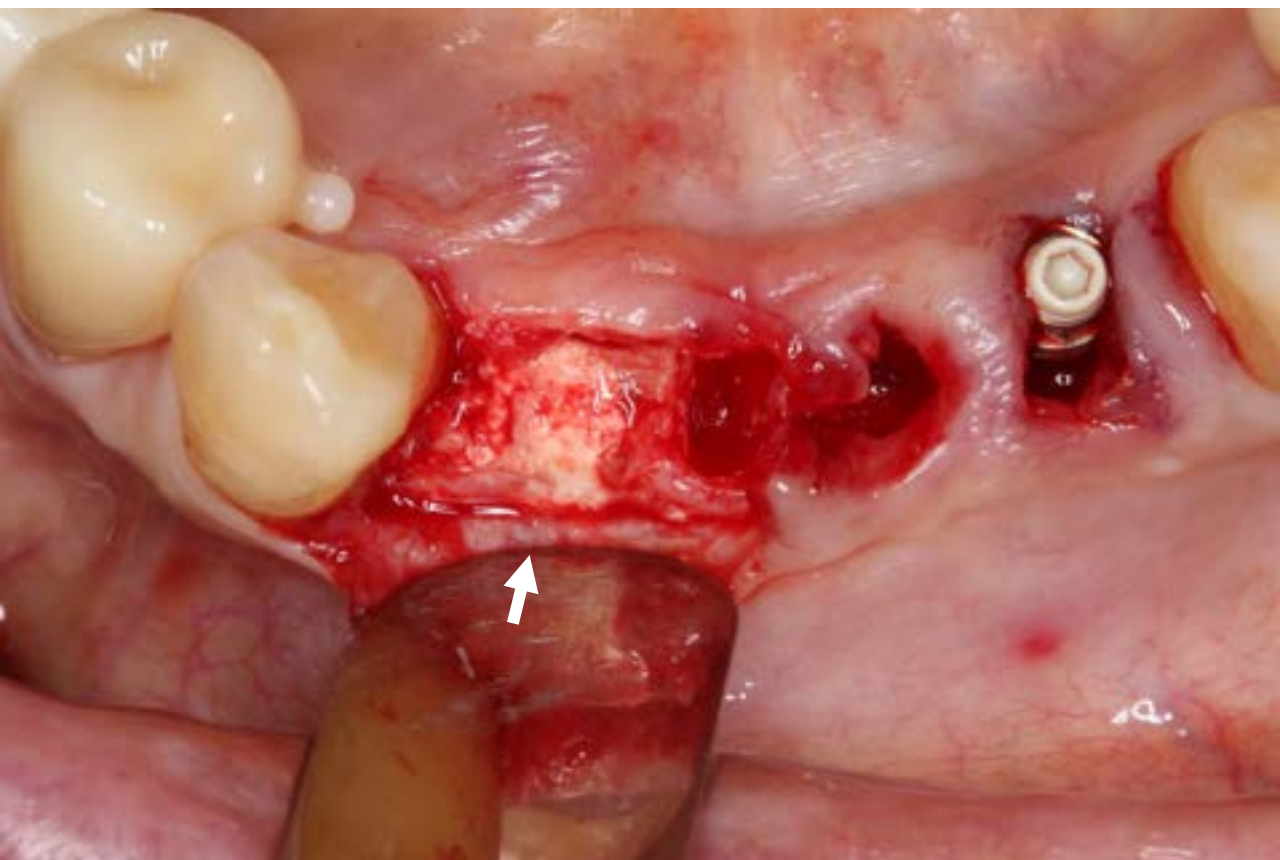




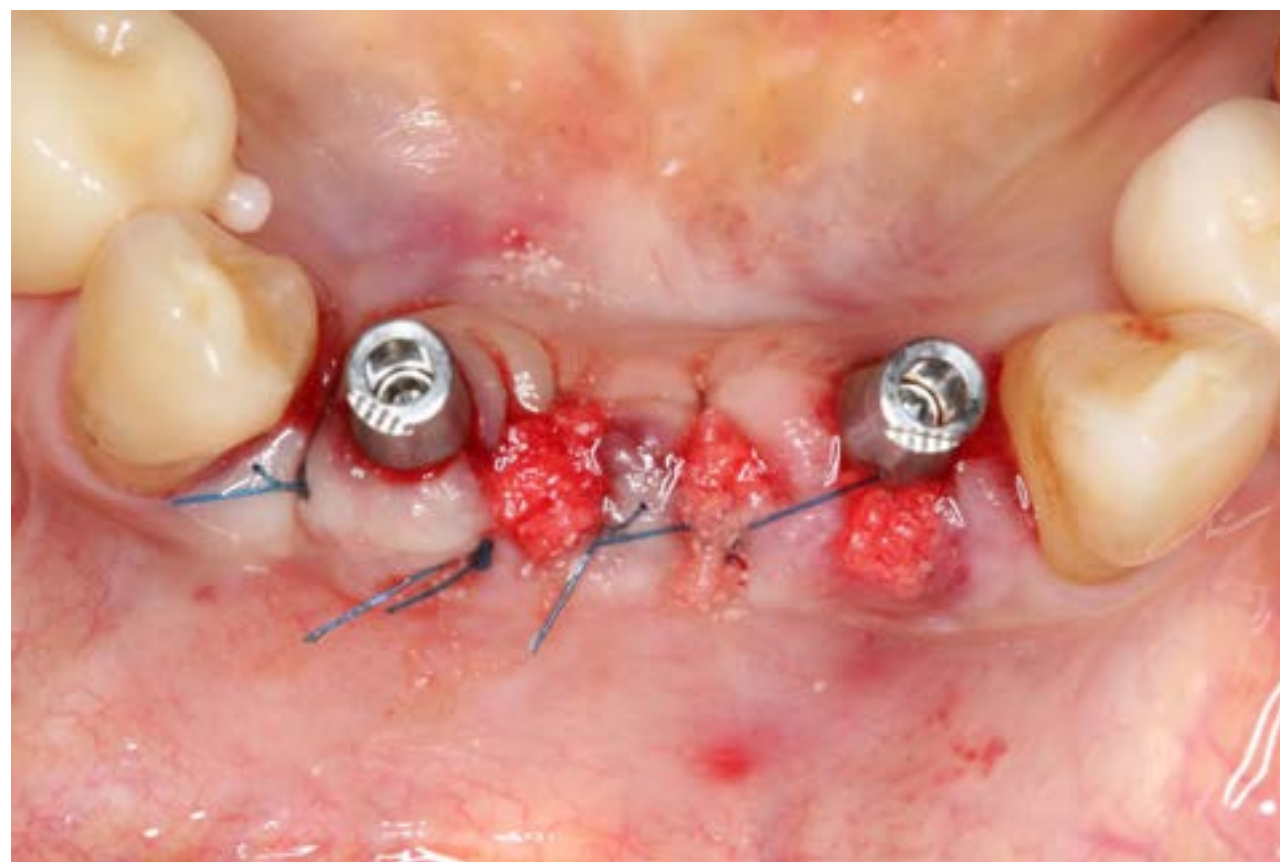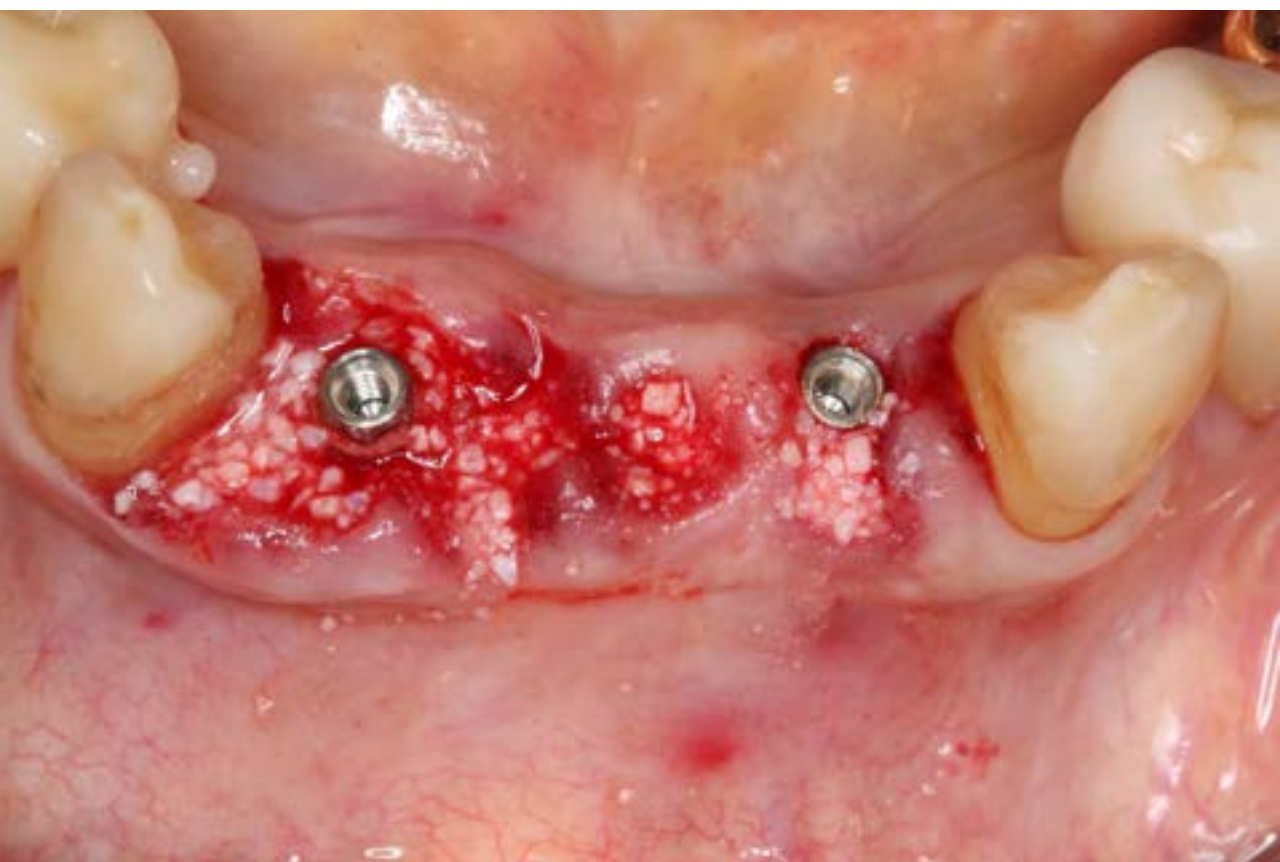bright TL
beveled external connection

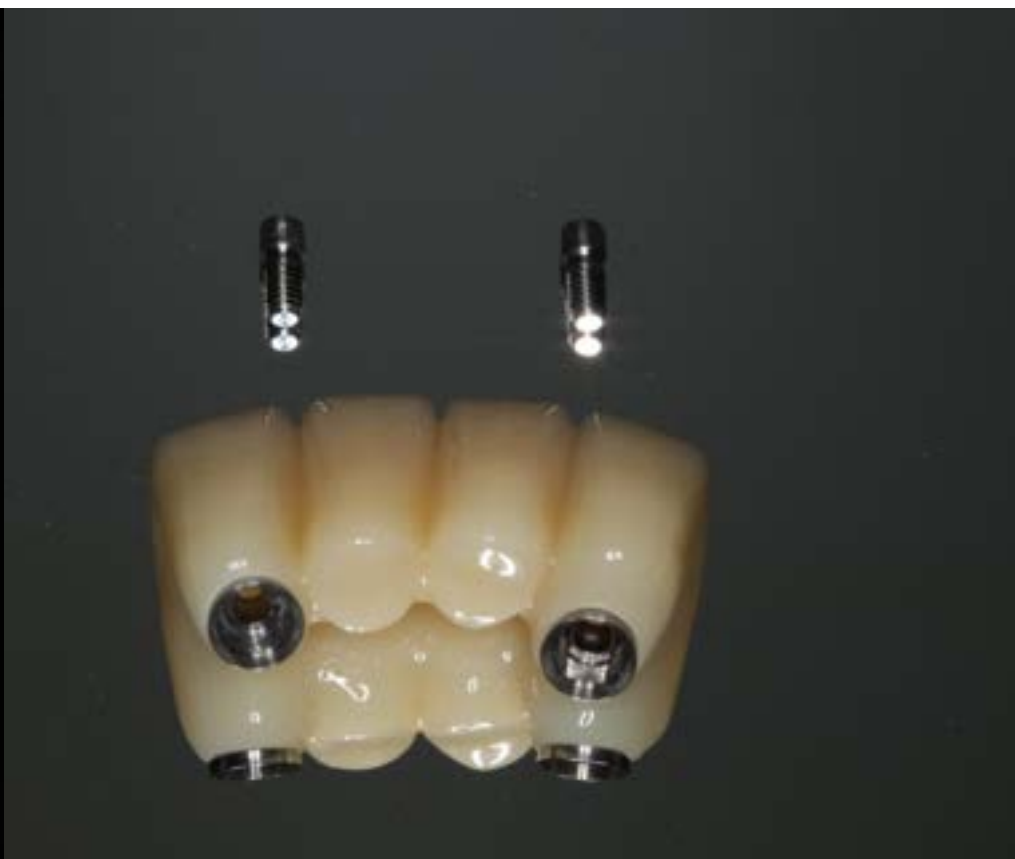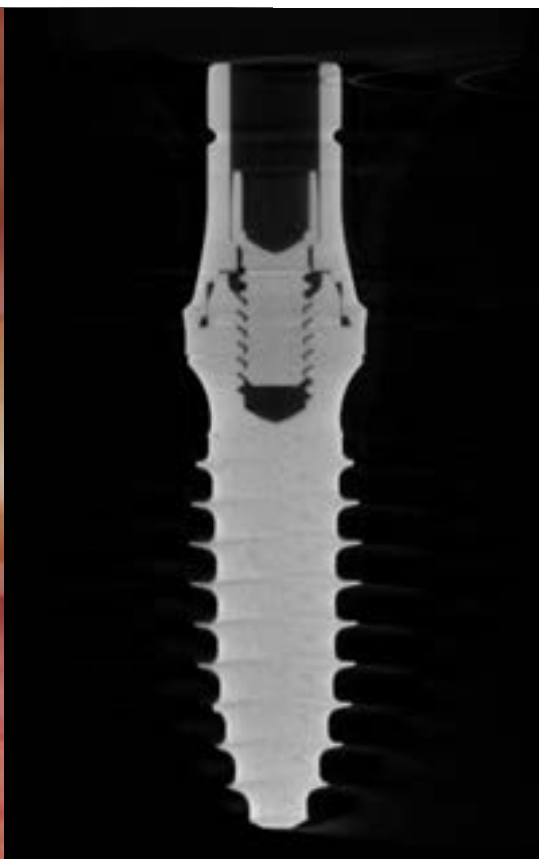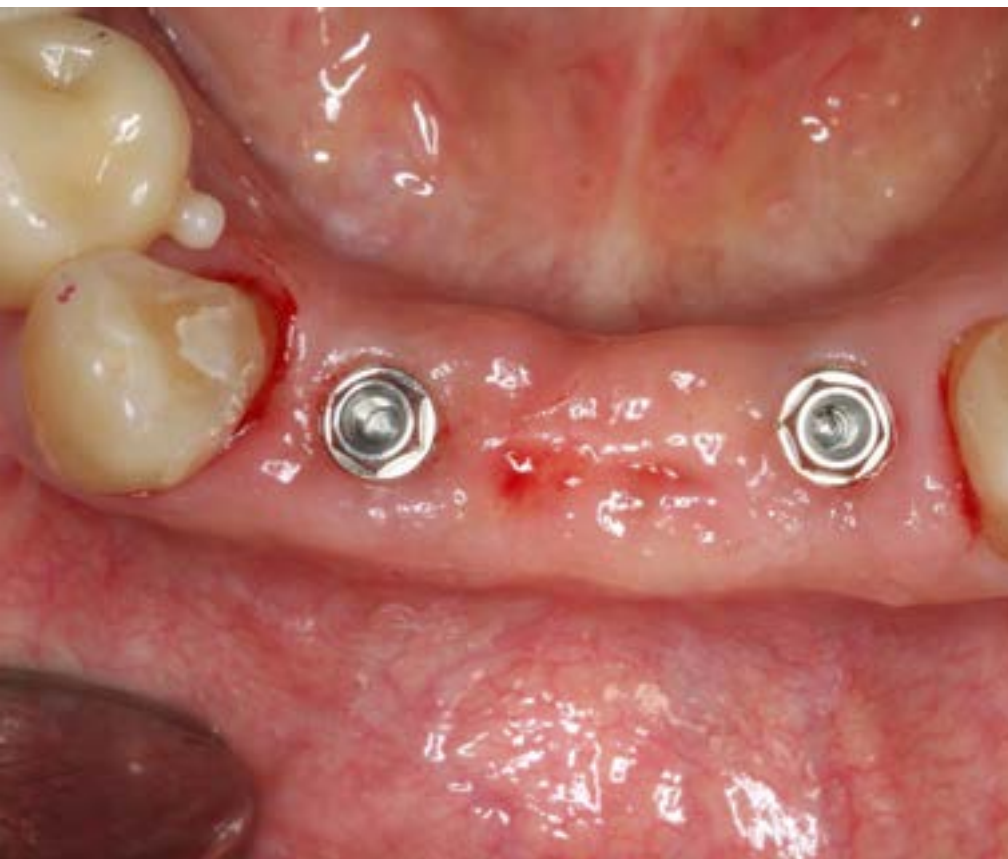- Pt. : OH, J S (82, F)
- C.C. : I' ve got tooth mobility on lower anterior





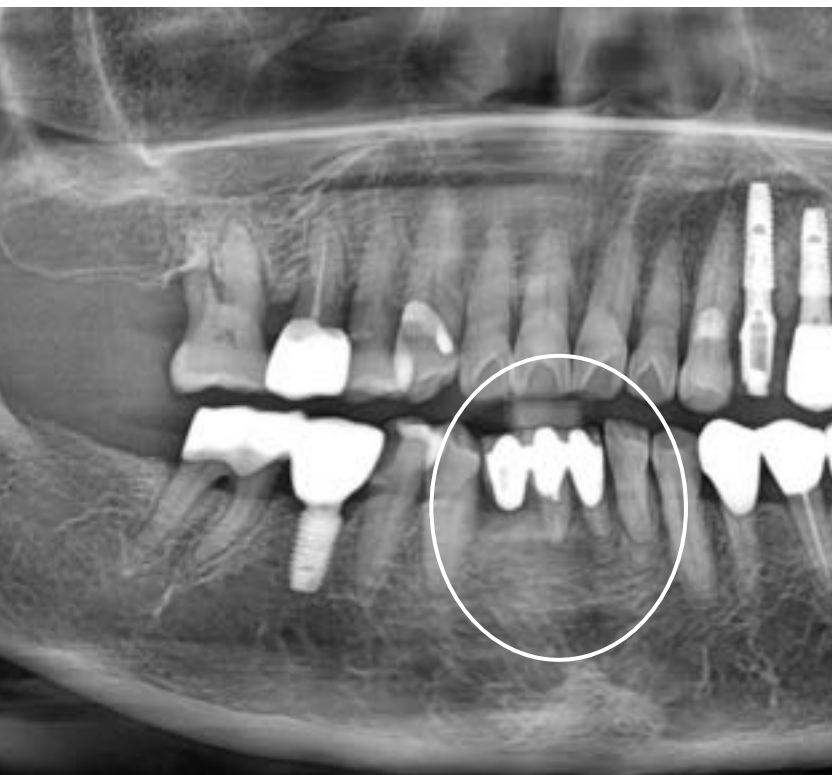
bone grafting of 03C : 5 years ago



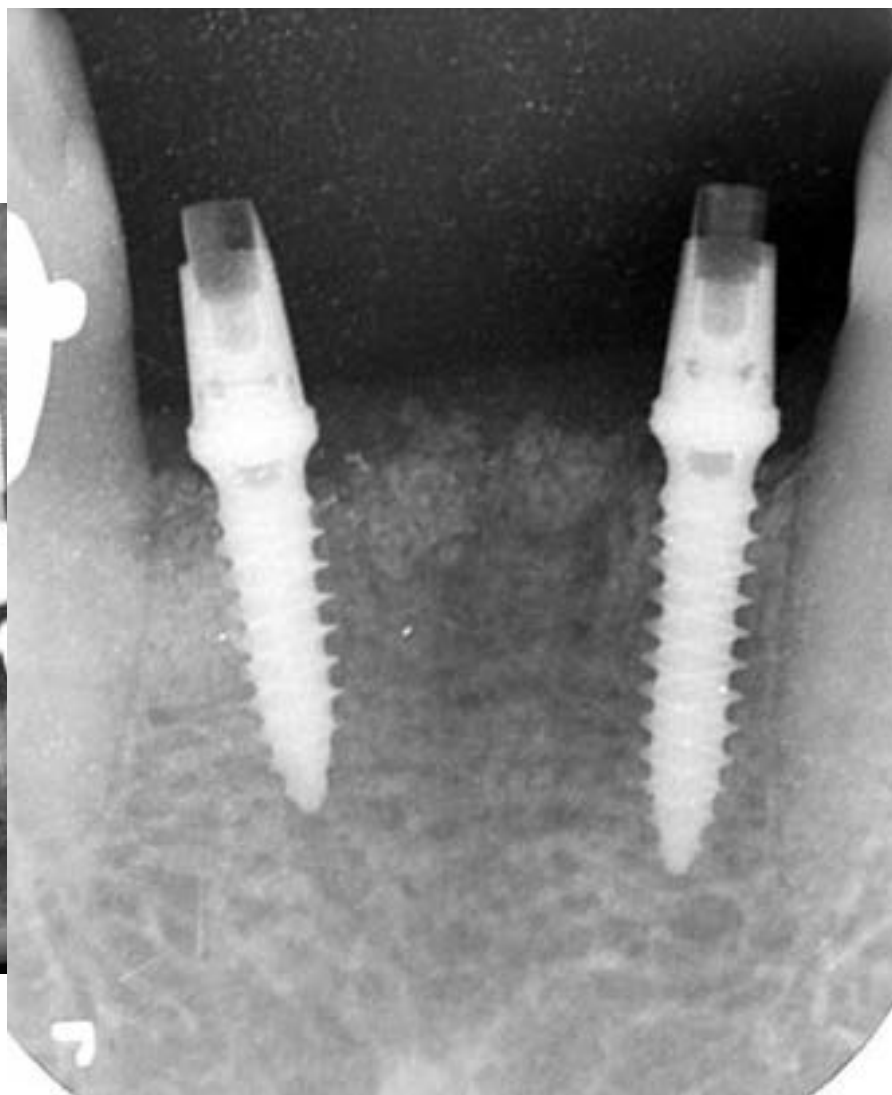

good healing status : 3 M

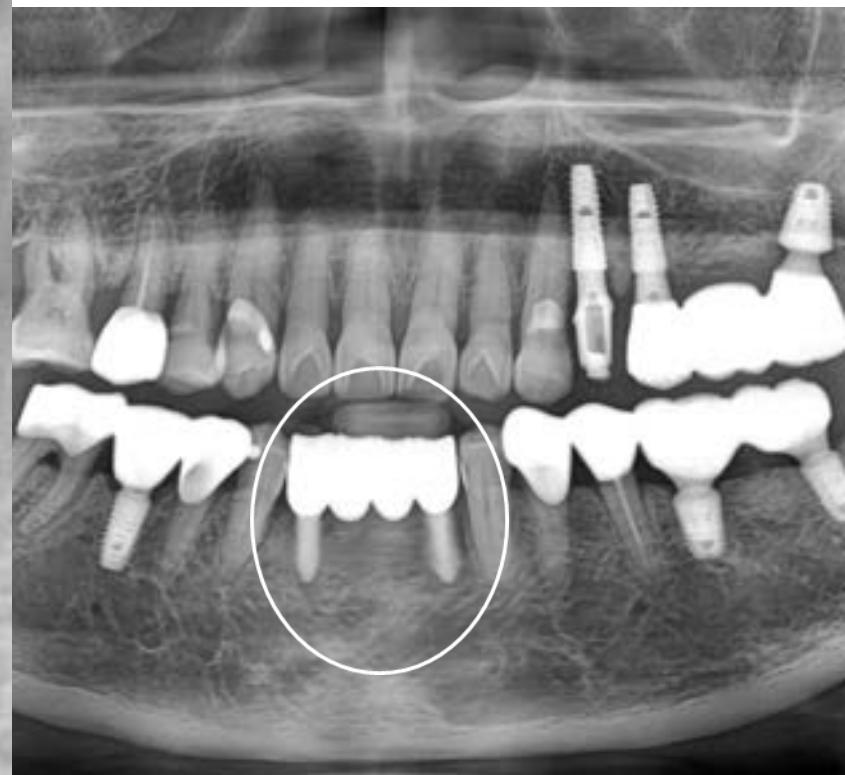
20° External Taper Fit



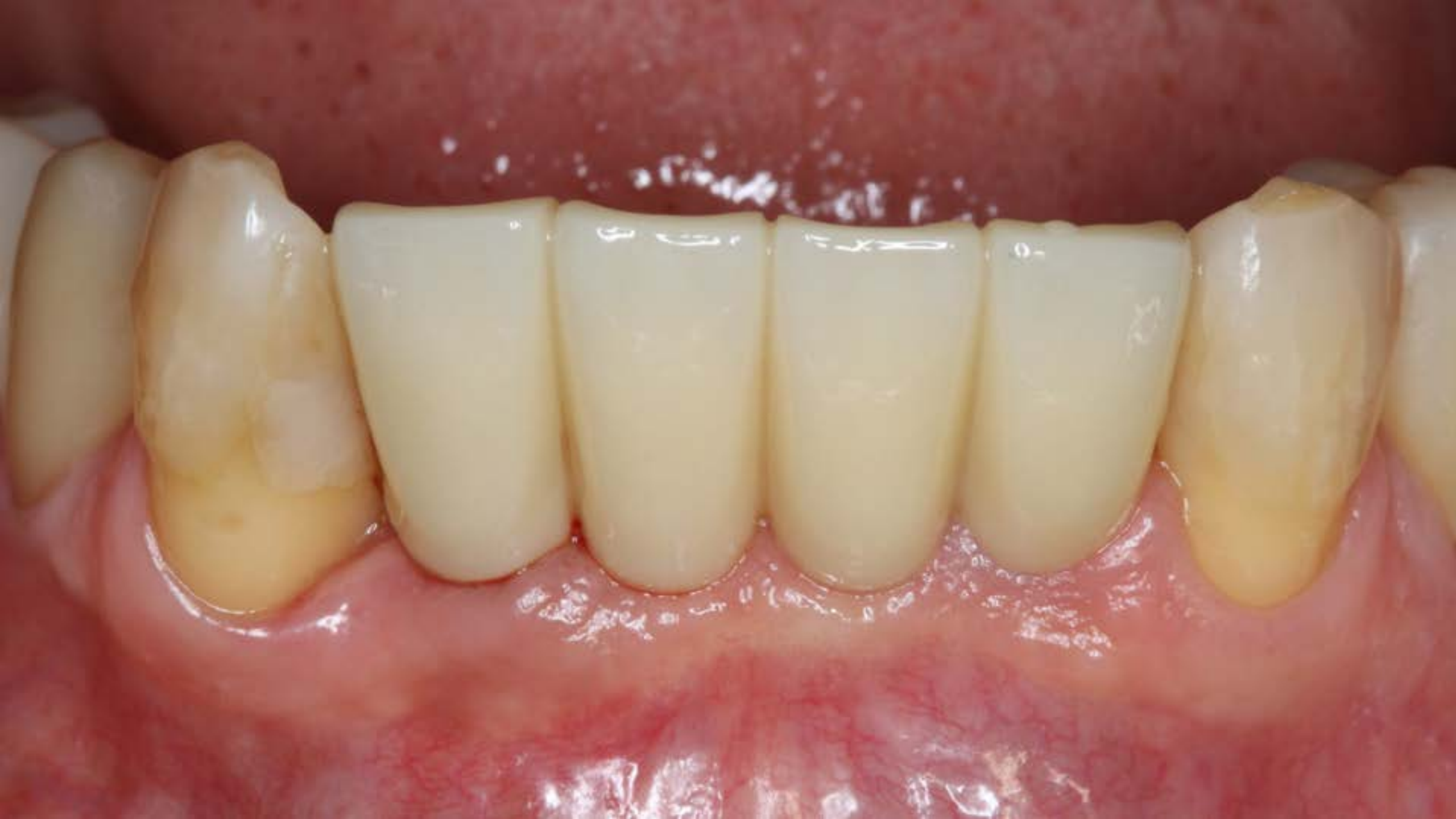Pre-op



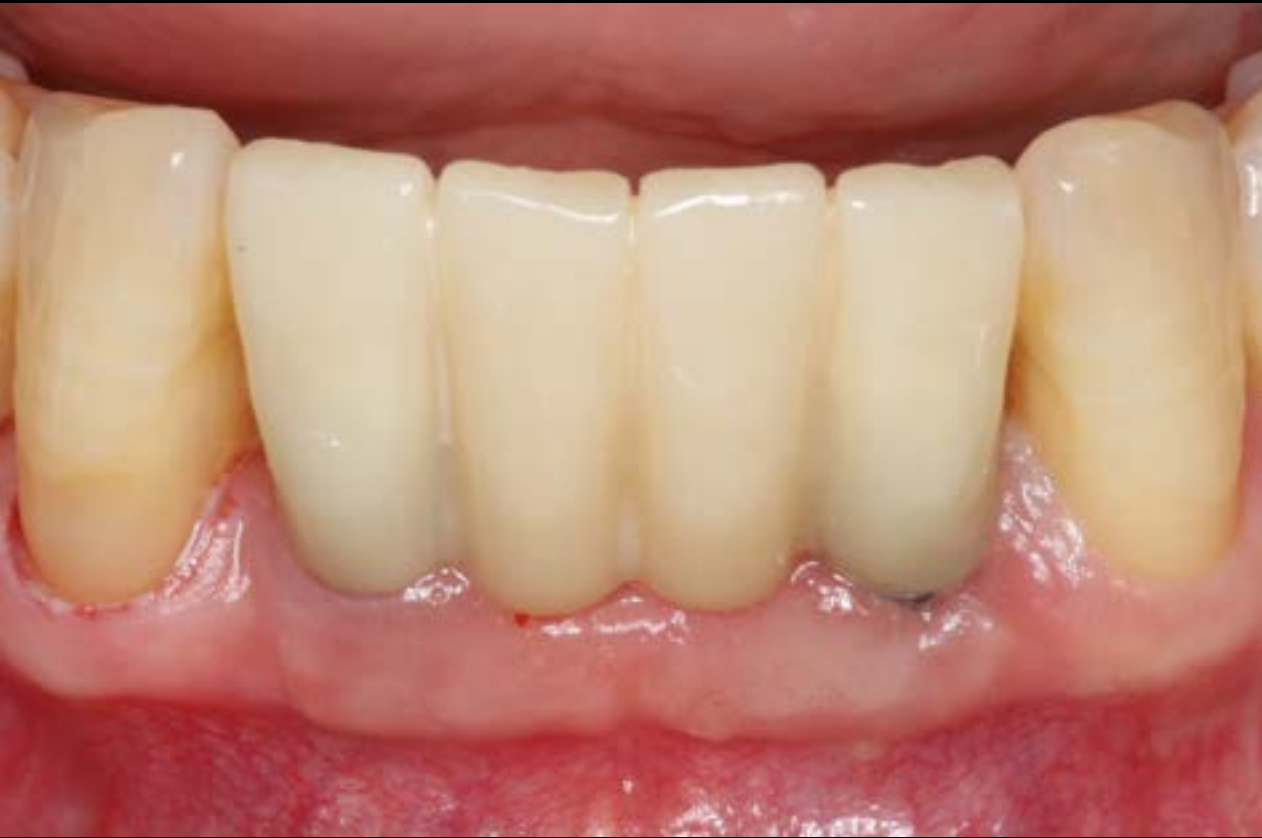Post-op



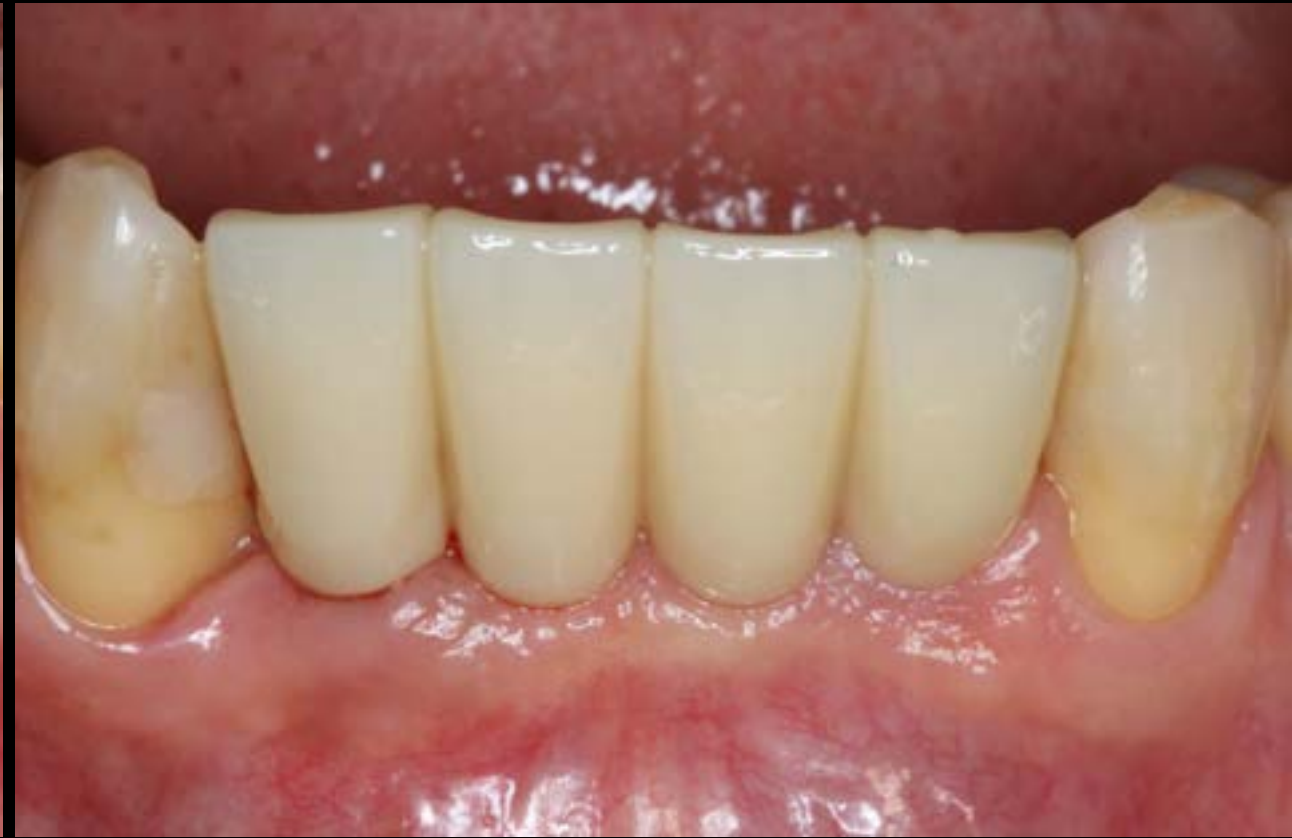final



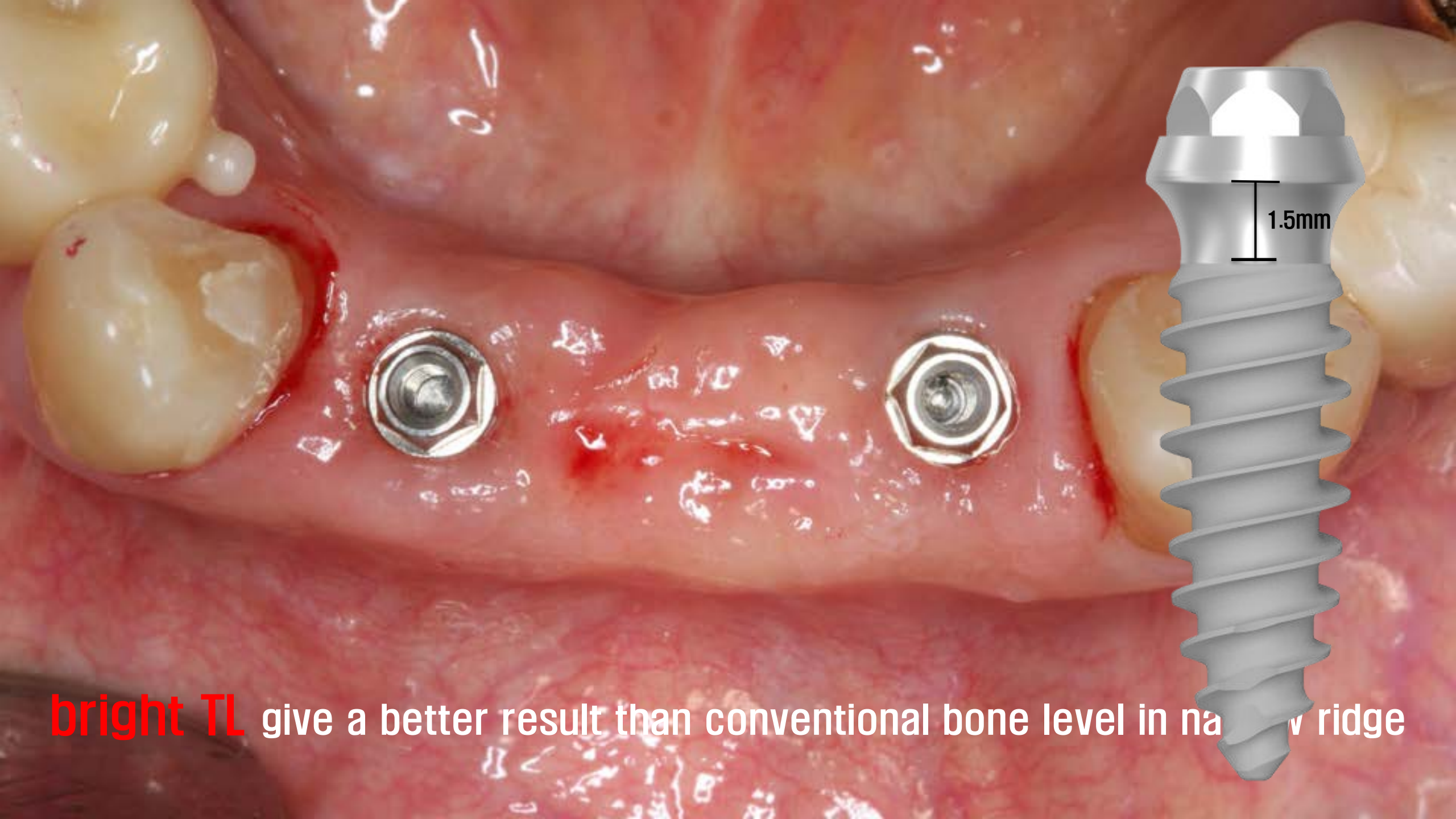internal connection



beveled external connection

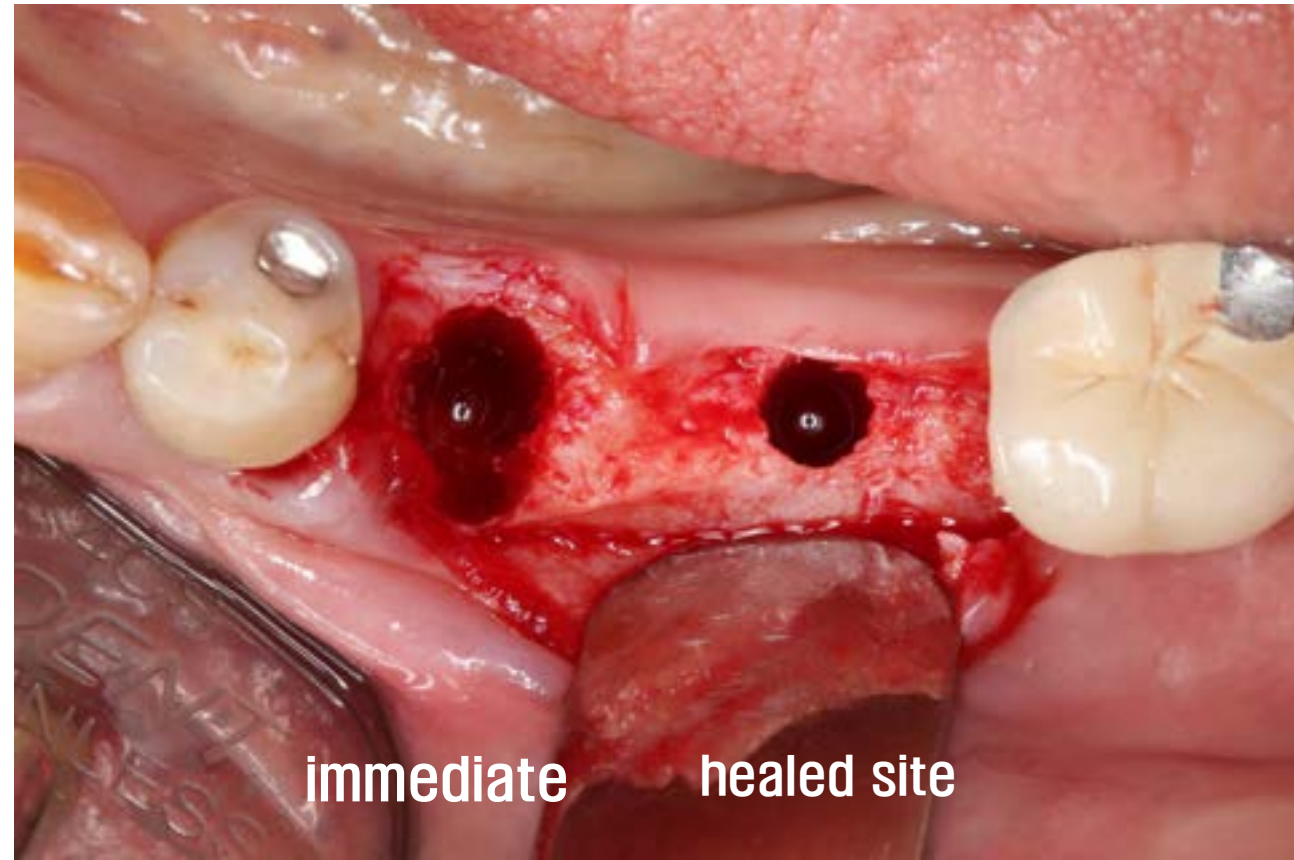
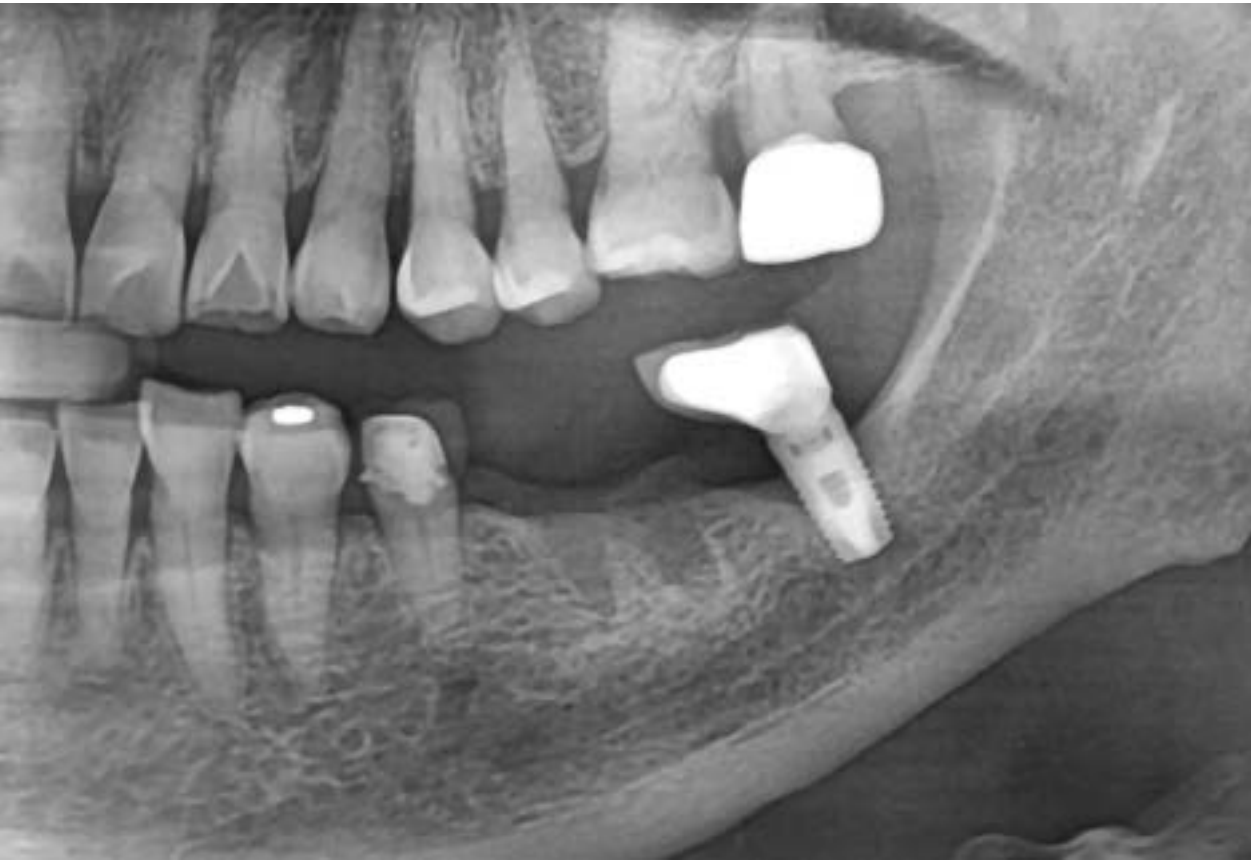

bright TL



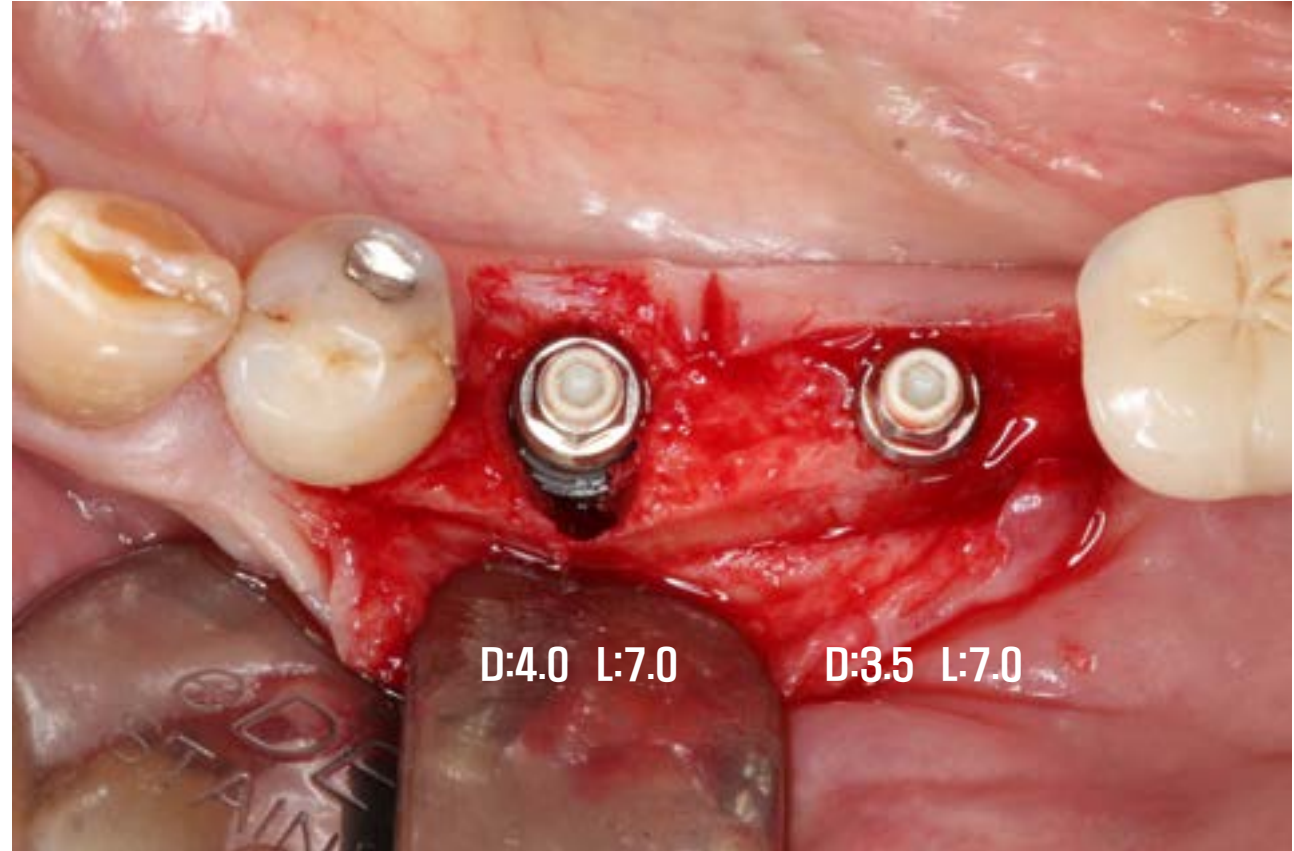
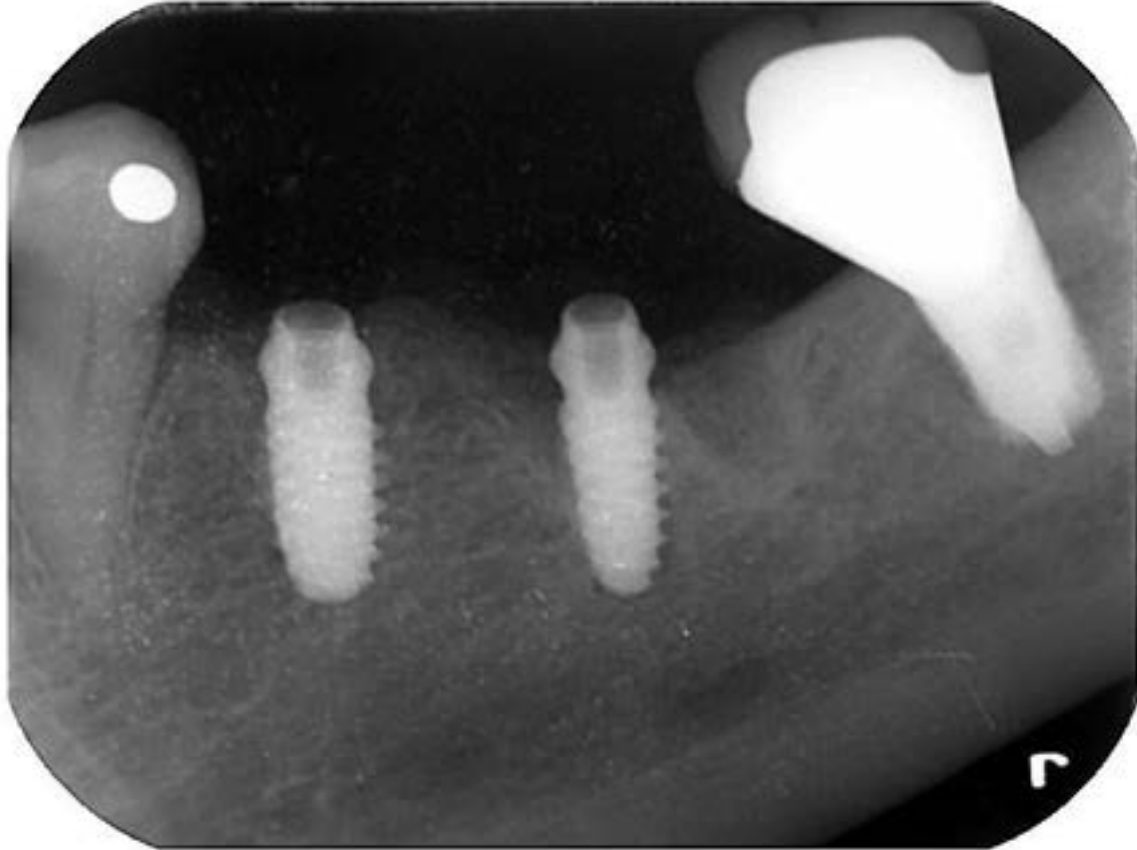
bright TL give a better result than conventional bone level in narrow ridge

premolar & molar region

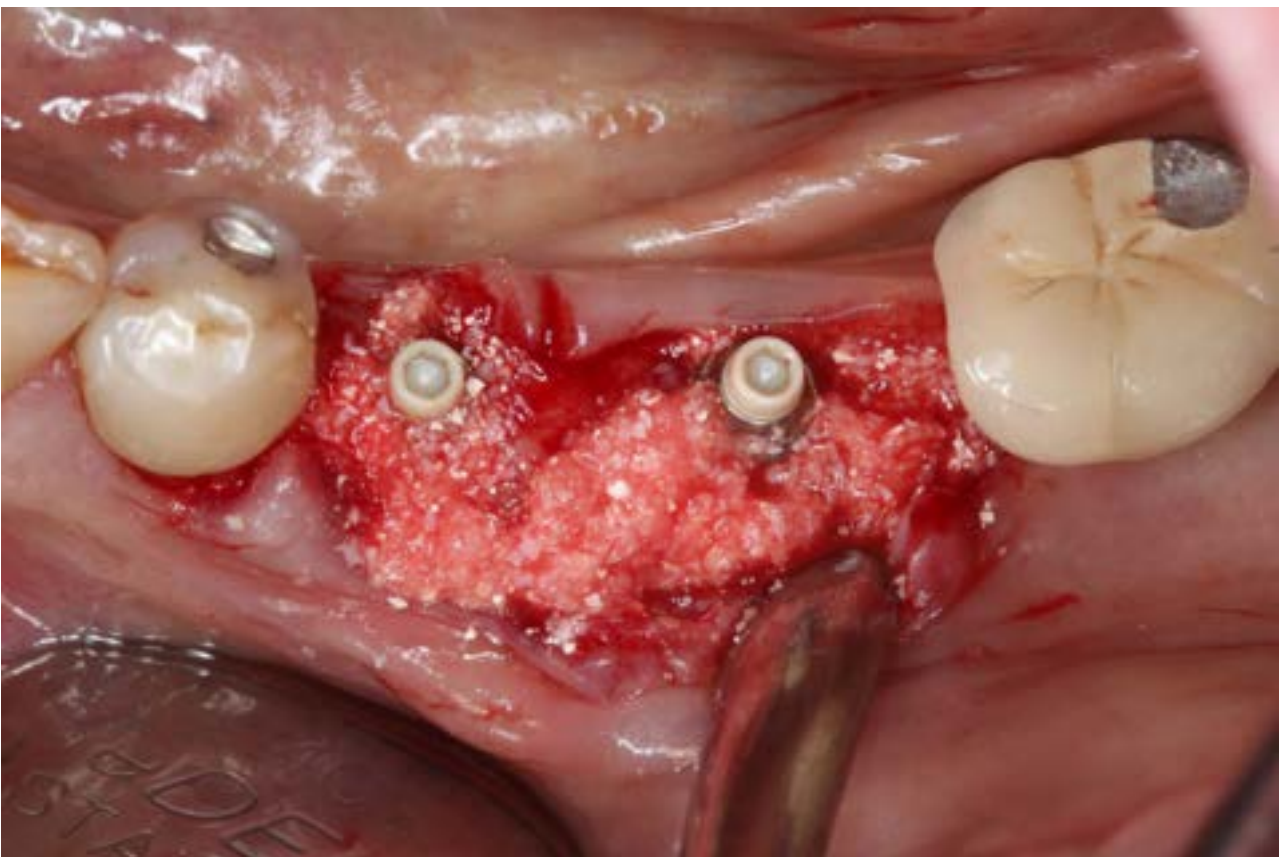


- Pt. : PAK, S M (77, F)
- C.C. : I want to have new implant teeth on Lt. lower posterior

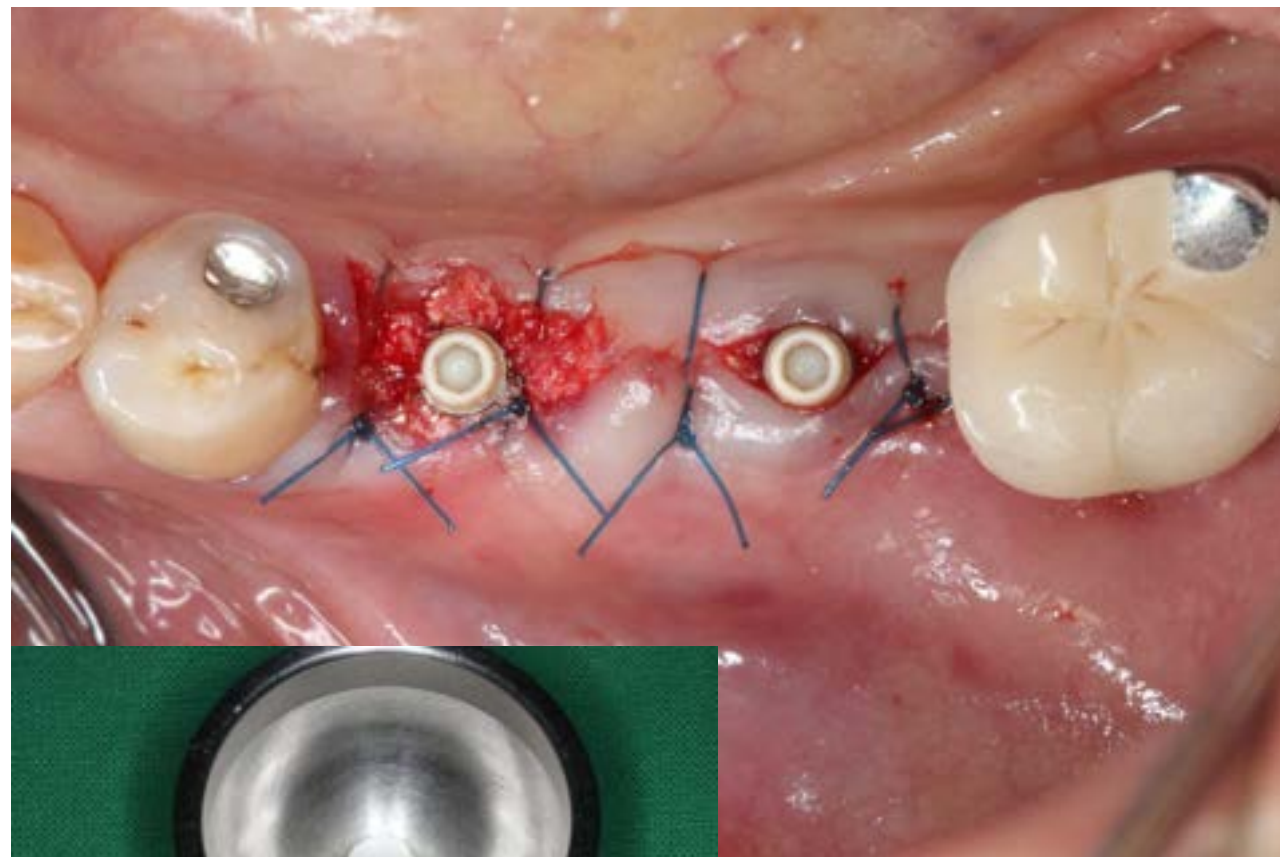
3.5 diameter is sufficient for post. region

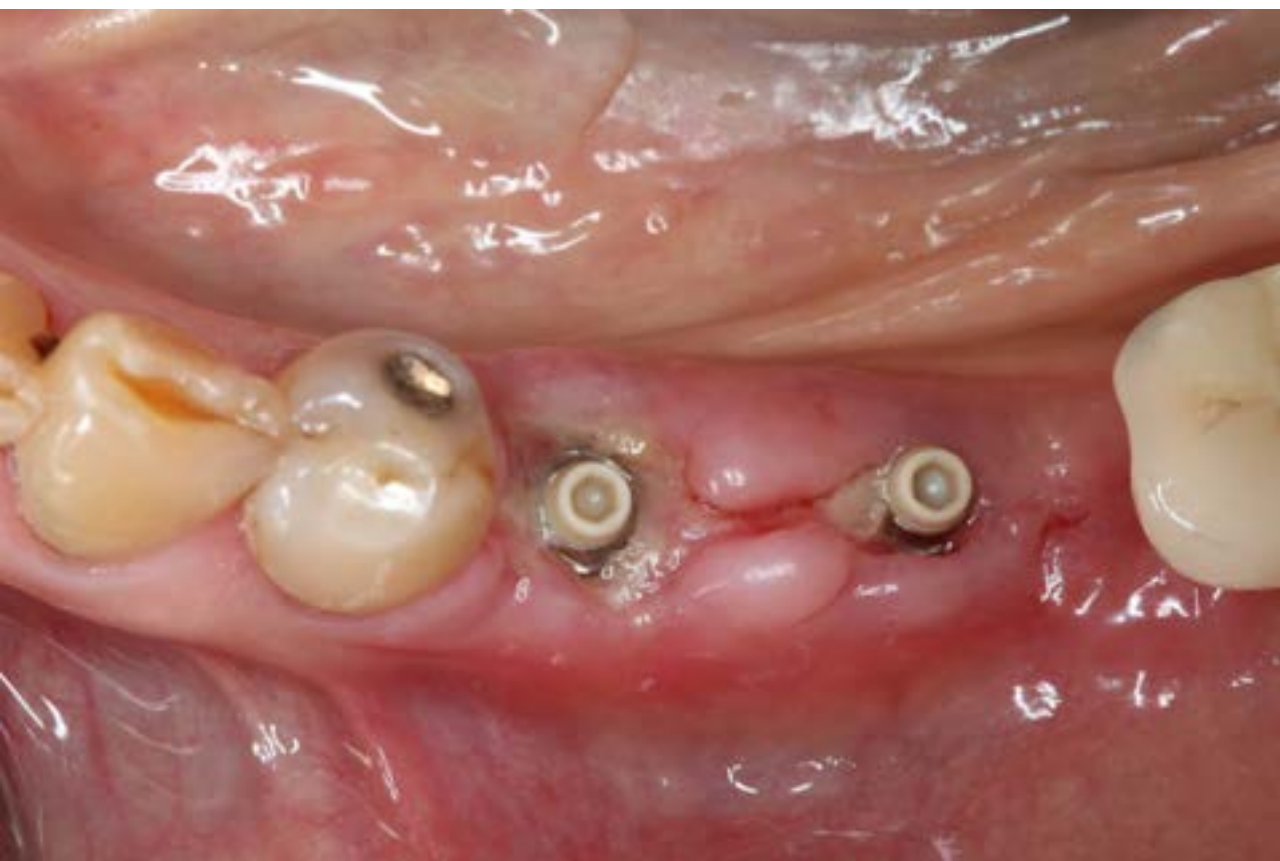


Excellent partner for simpler bone grafting

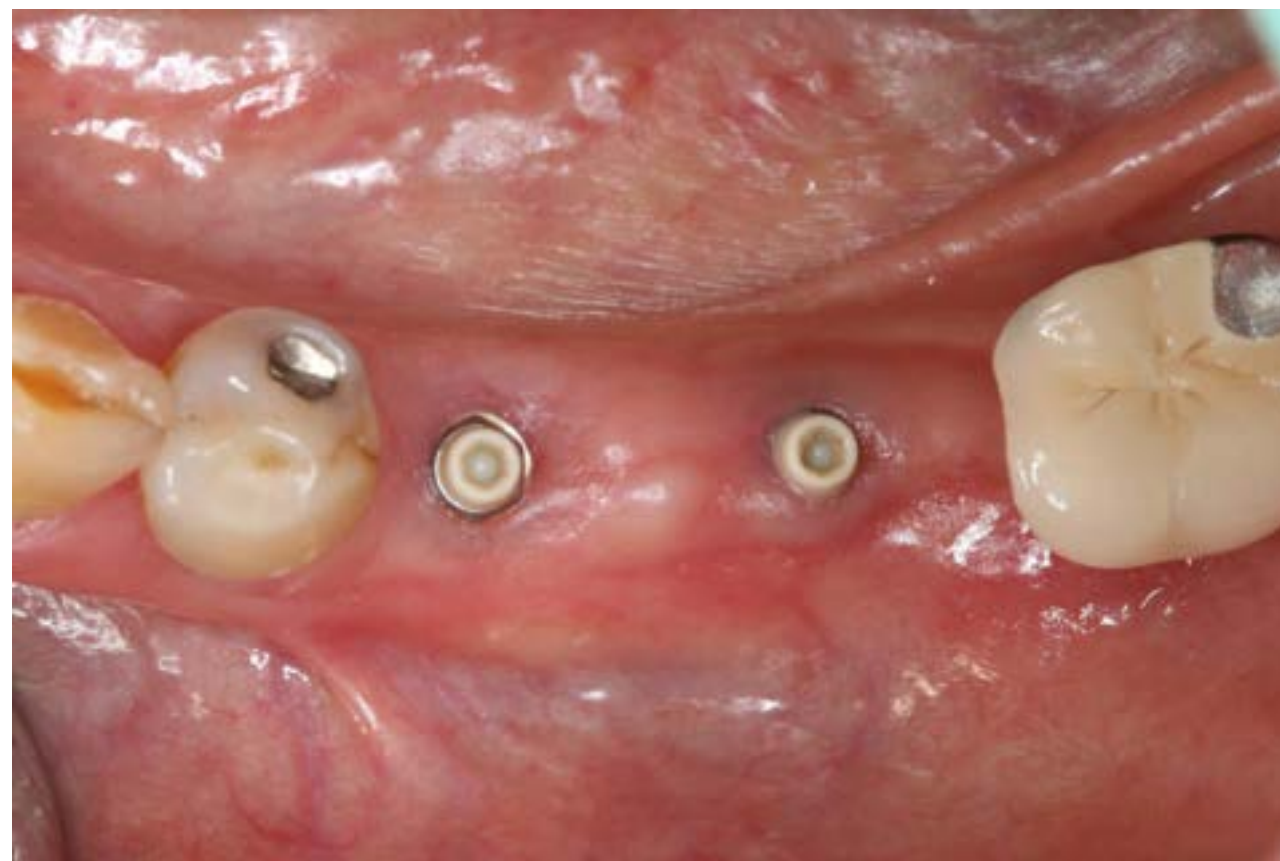

Collagenated bone graft mat.
: Osteon *Xeno* Collagen (OXC)

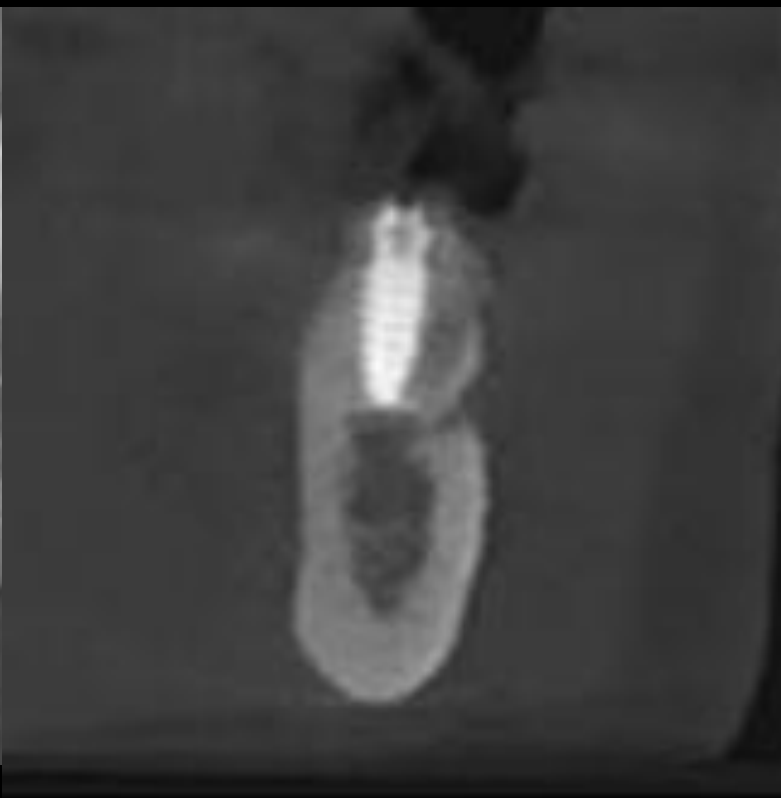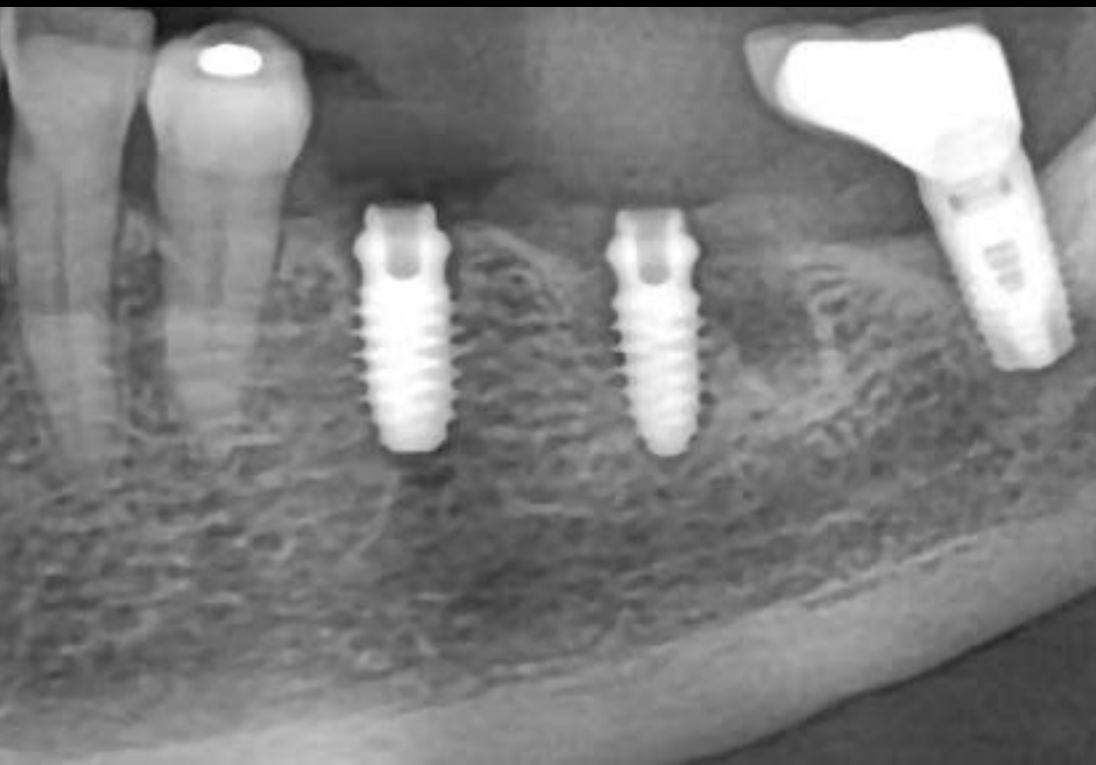




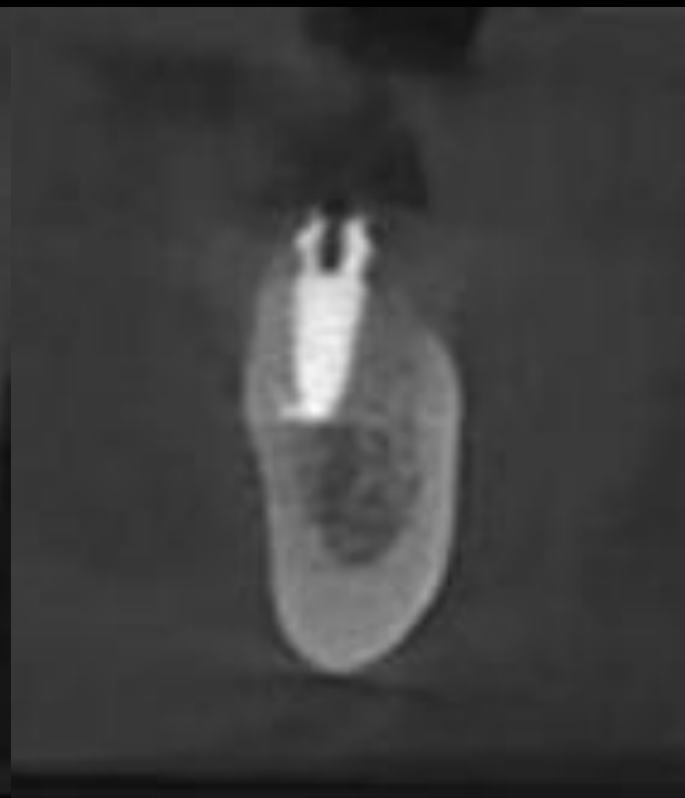Post-op 2w



Post-op 5w



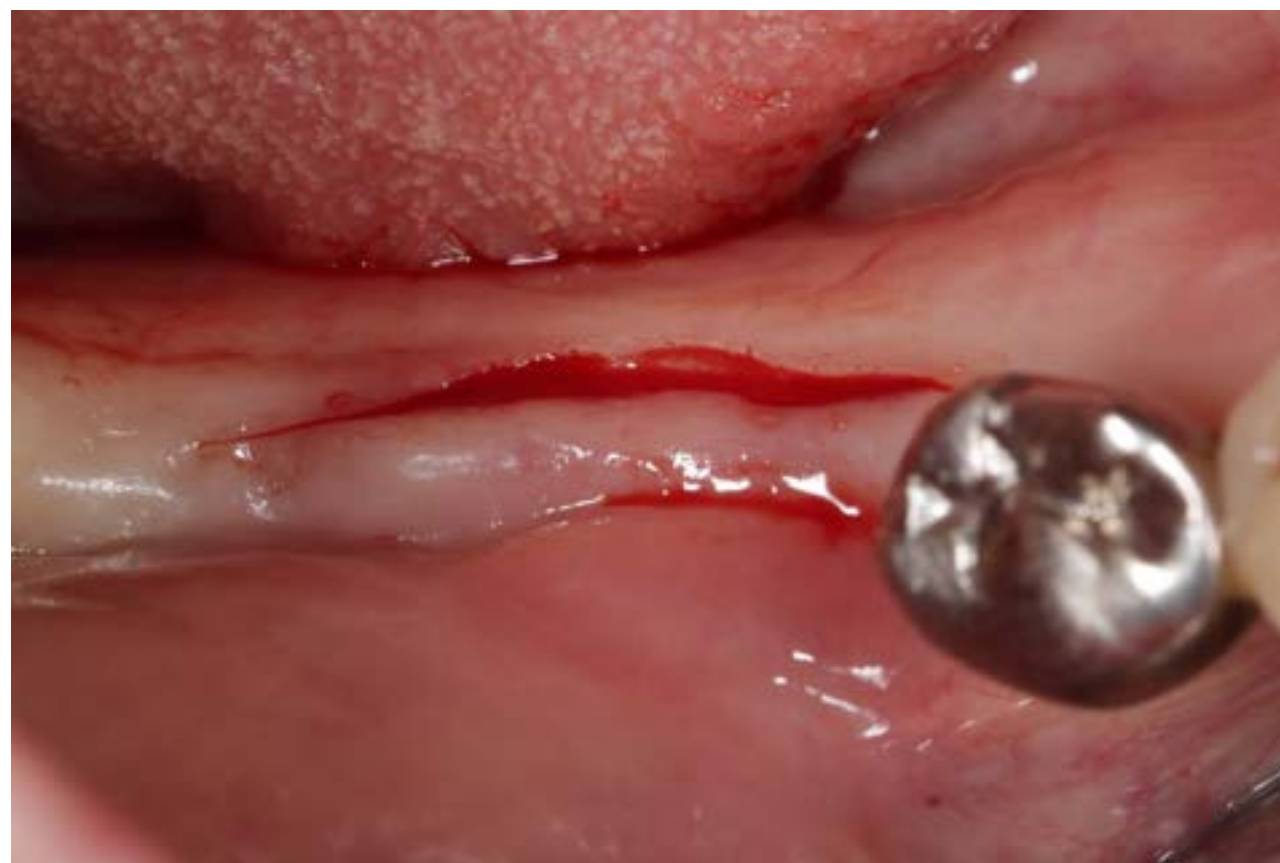
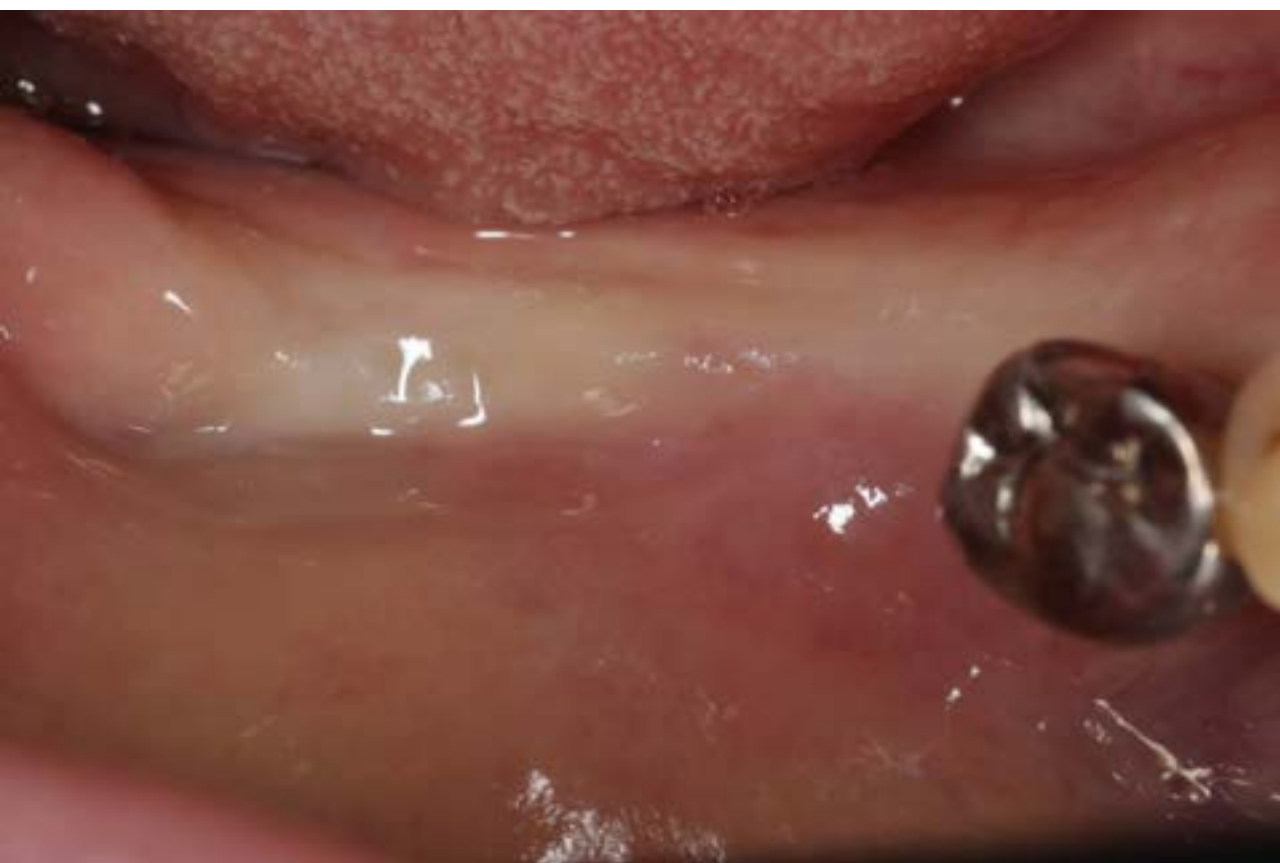35

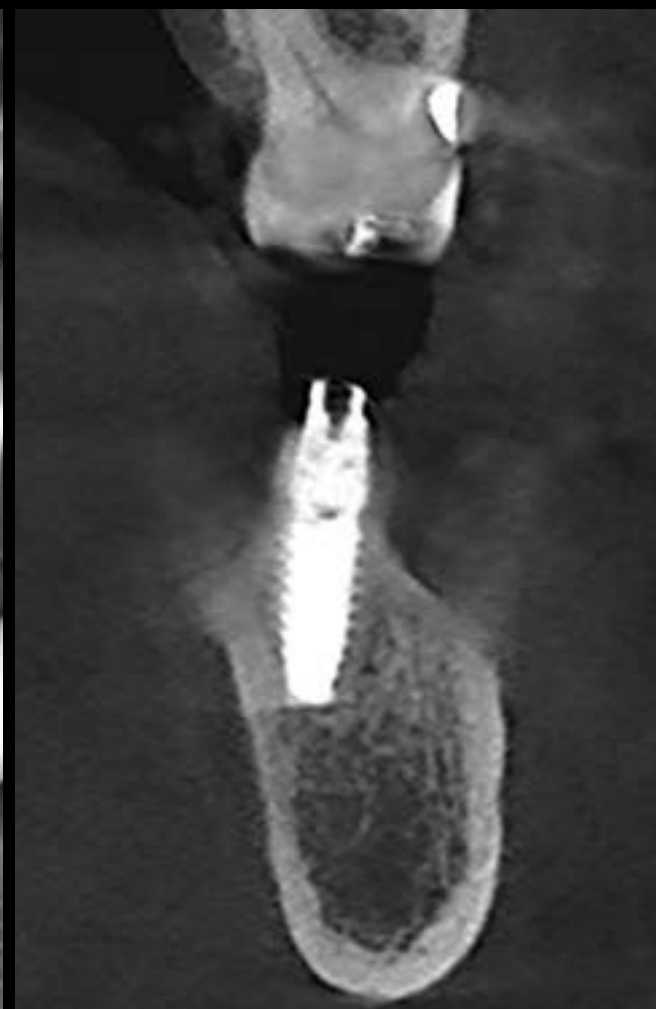
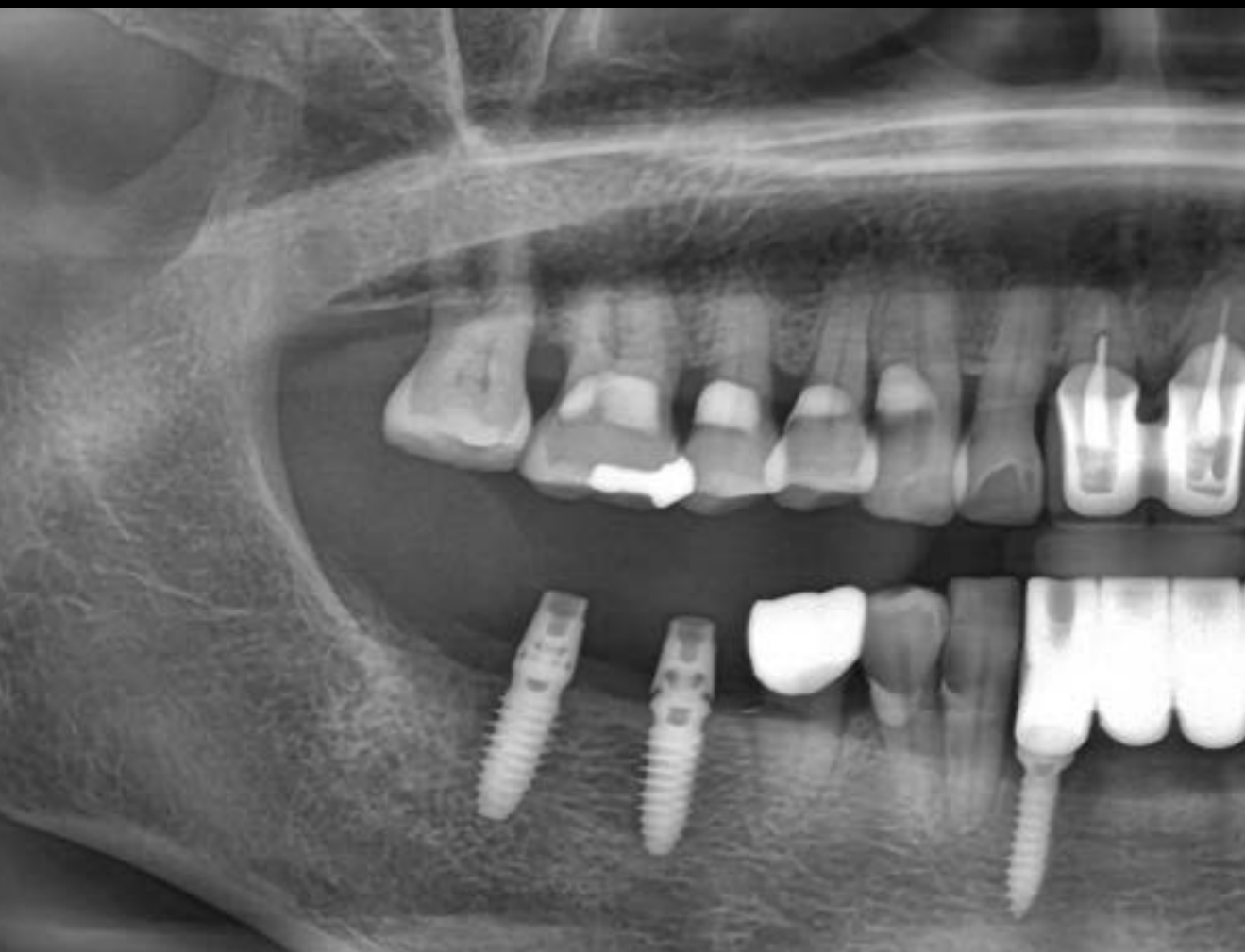

#36

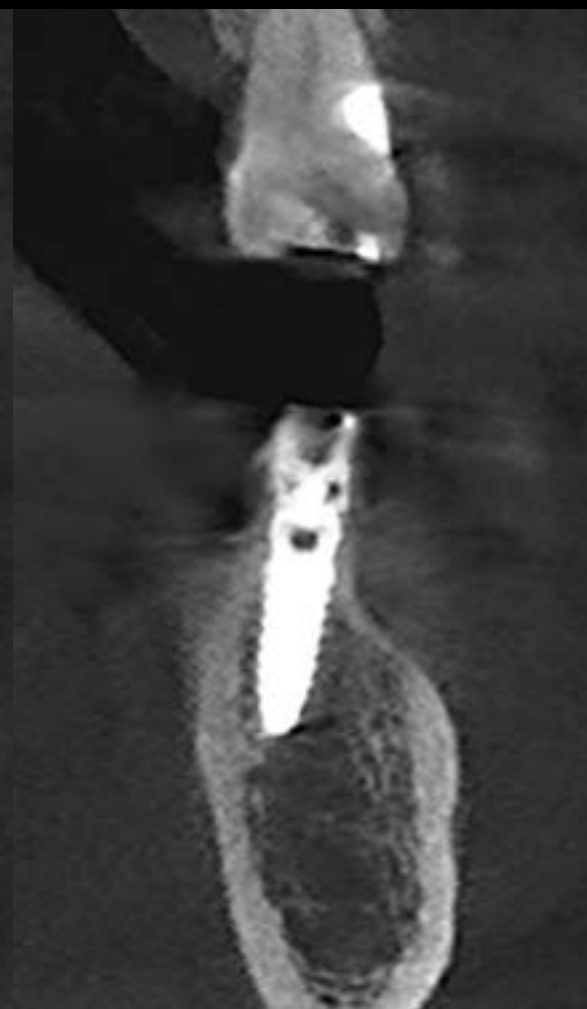
Cancellous Bone Engagement

**bright TL is the optimized system
for the minimalism concept**

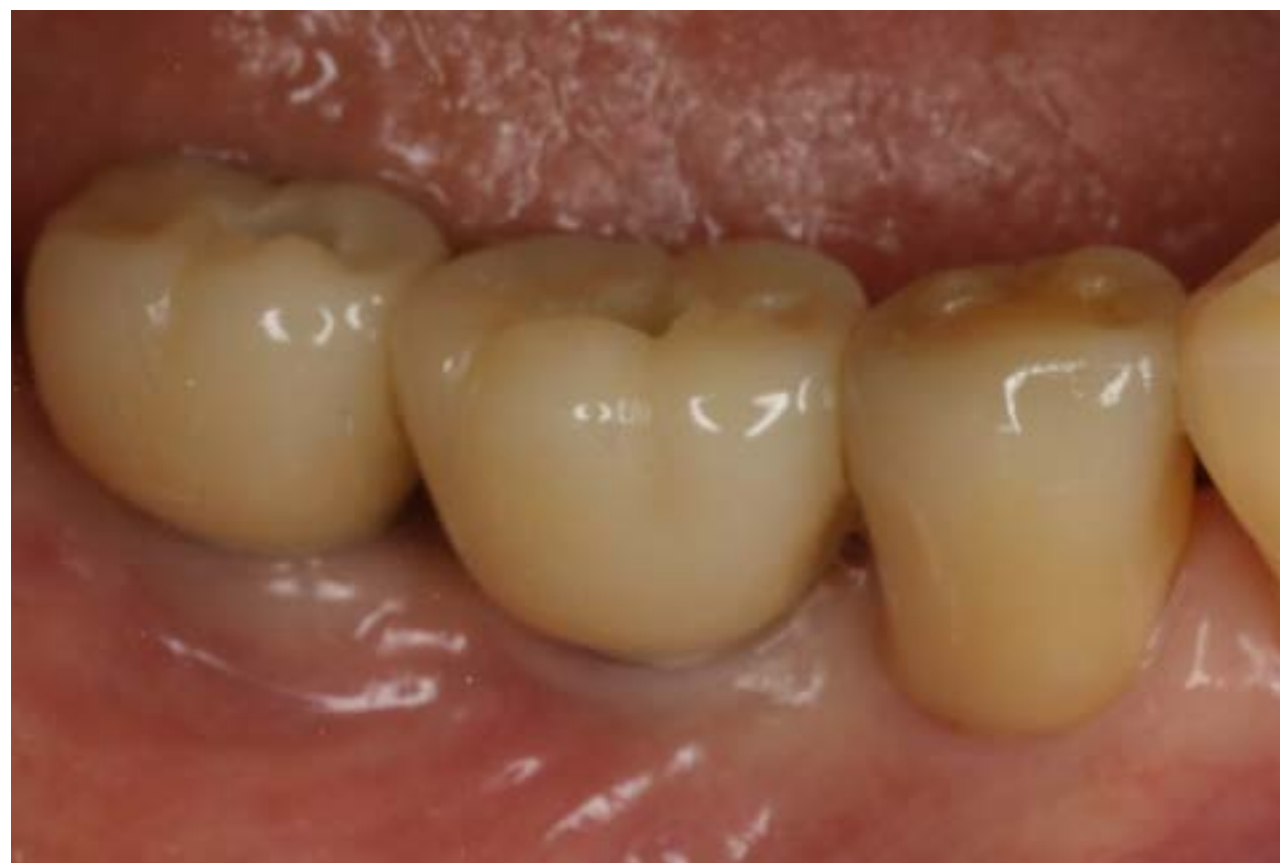
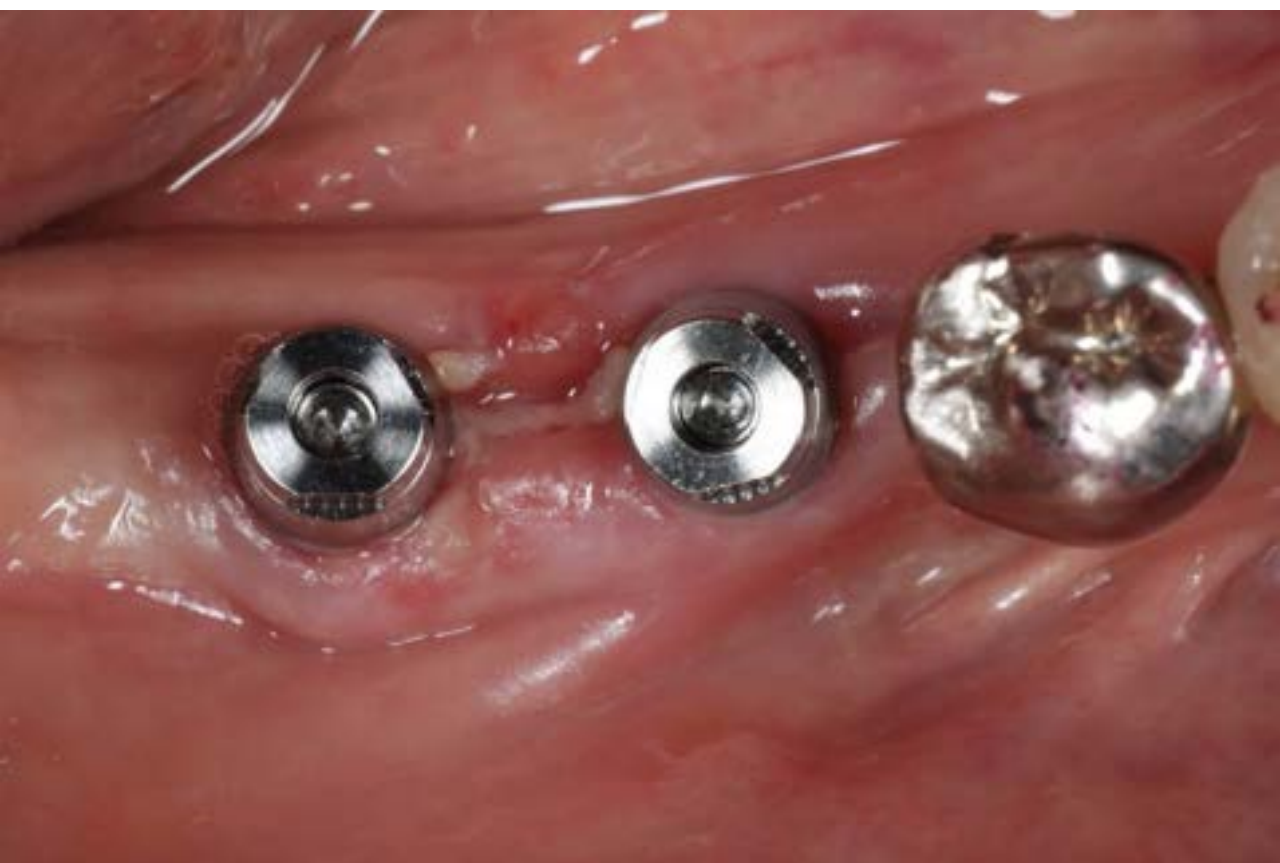


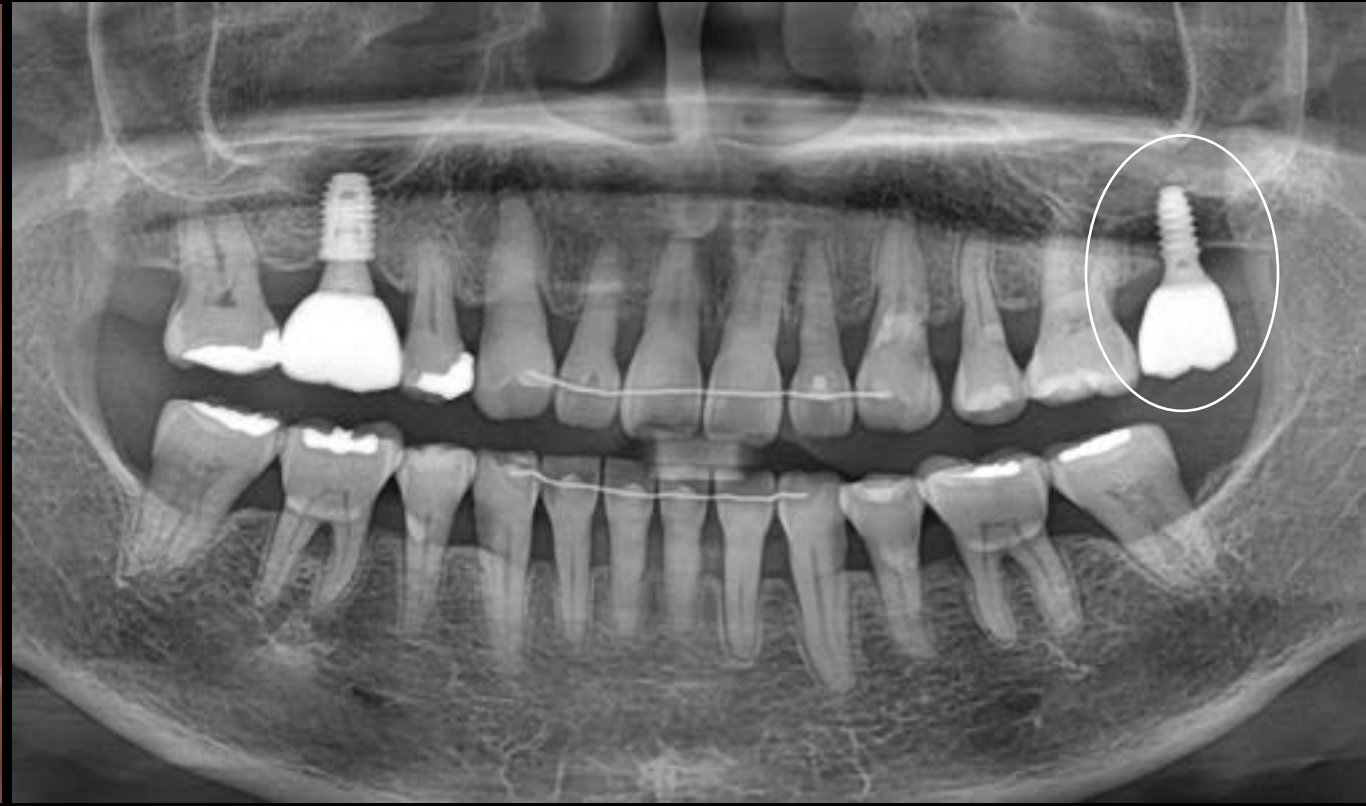
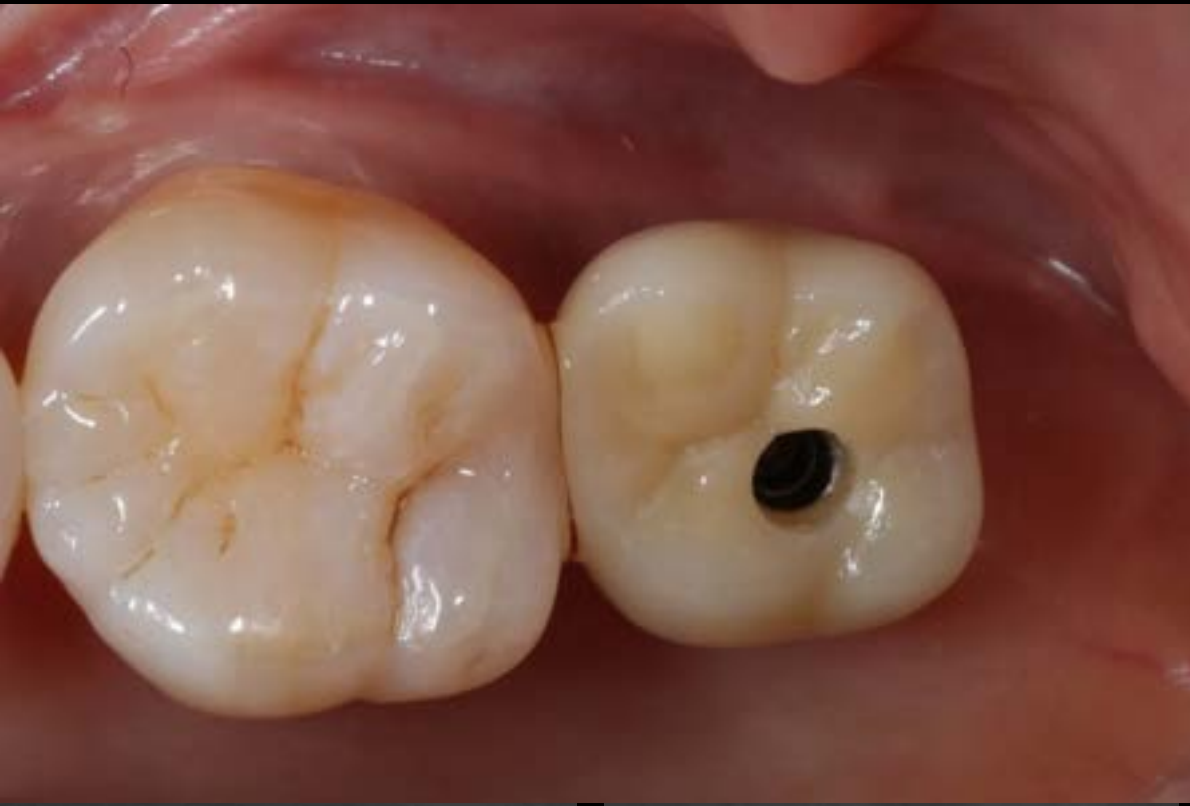#47



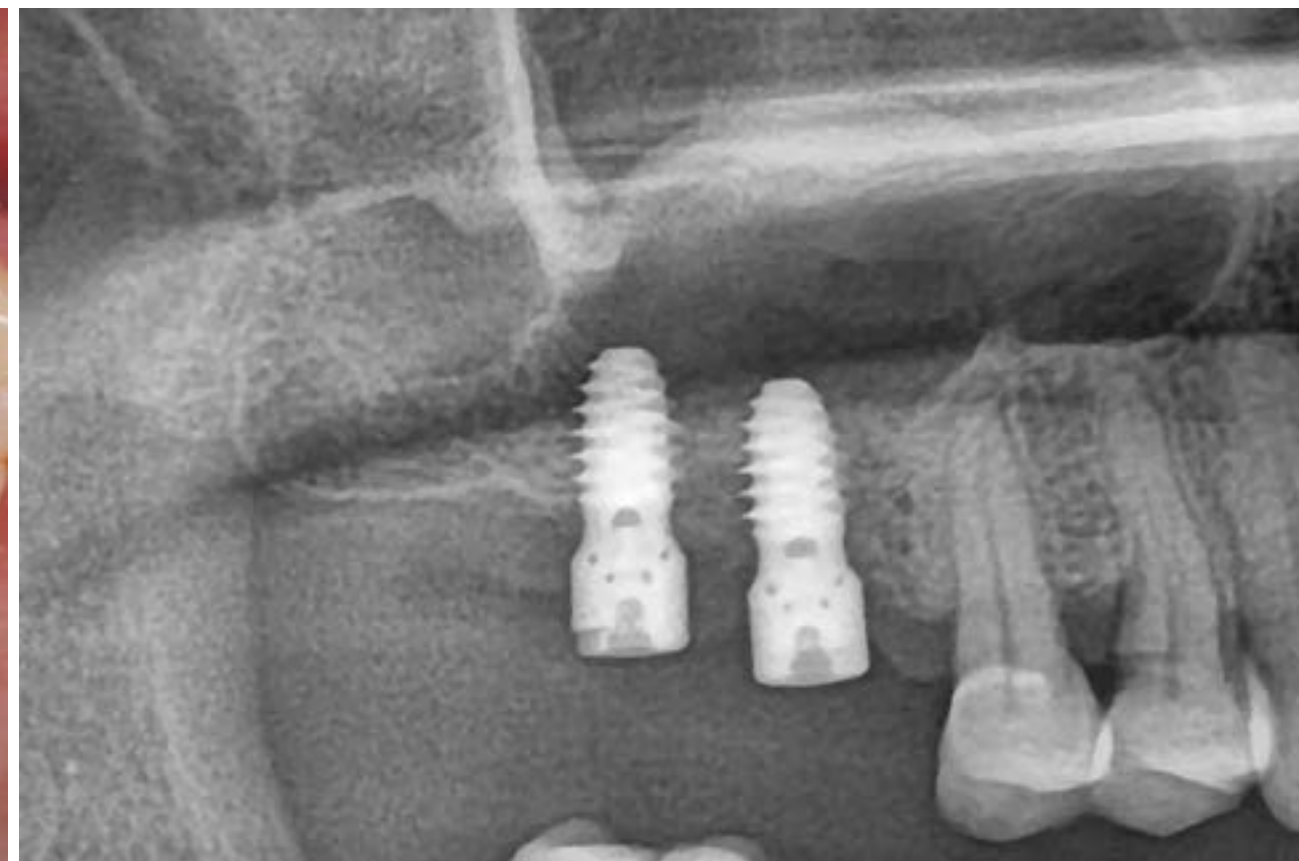
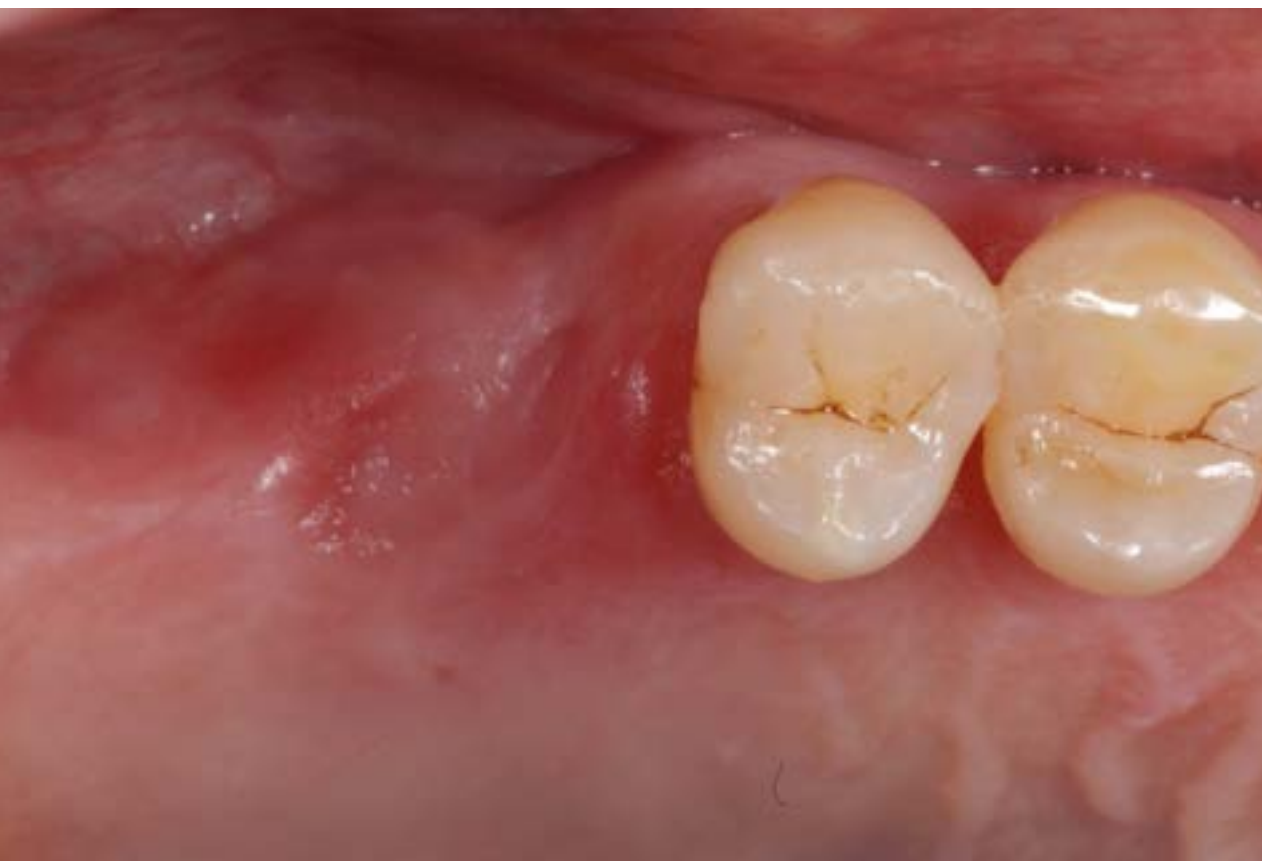#46



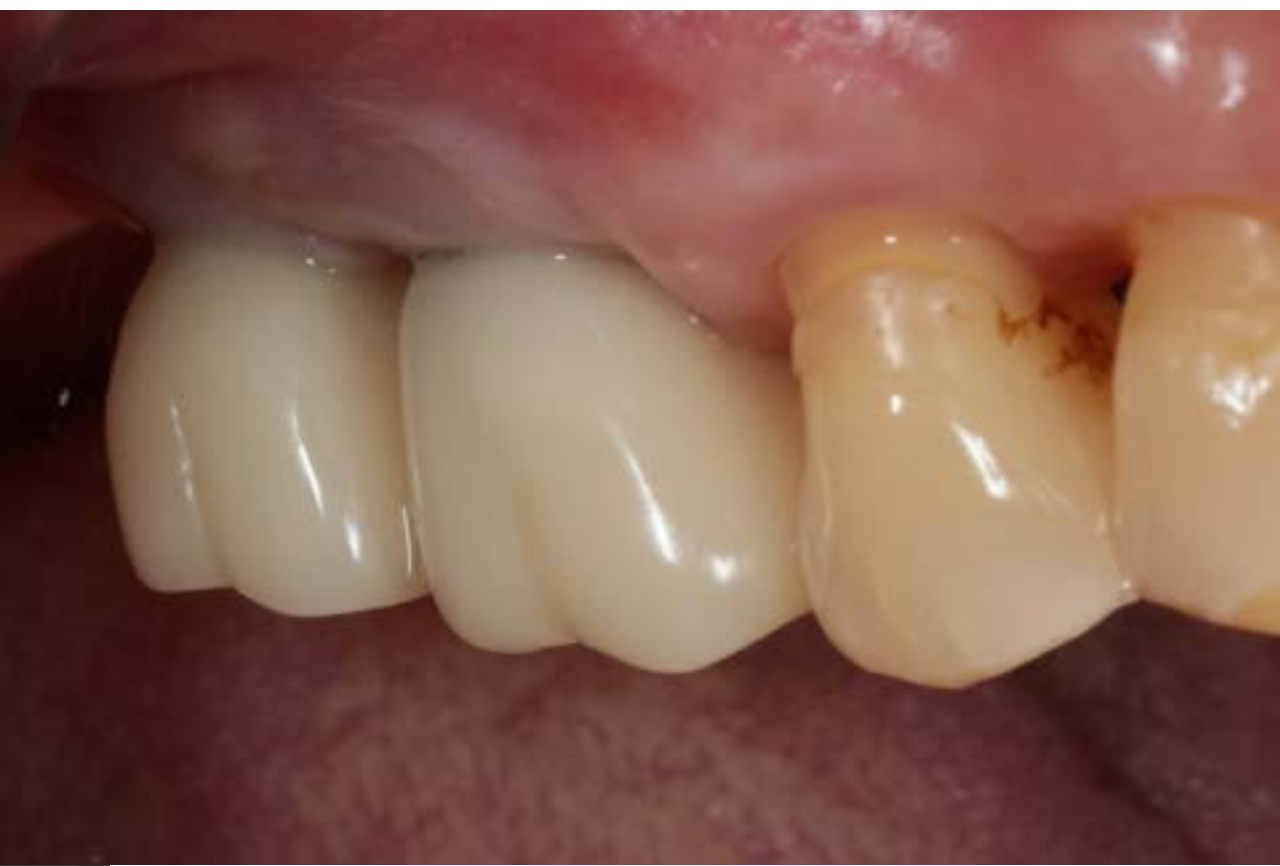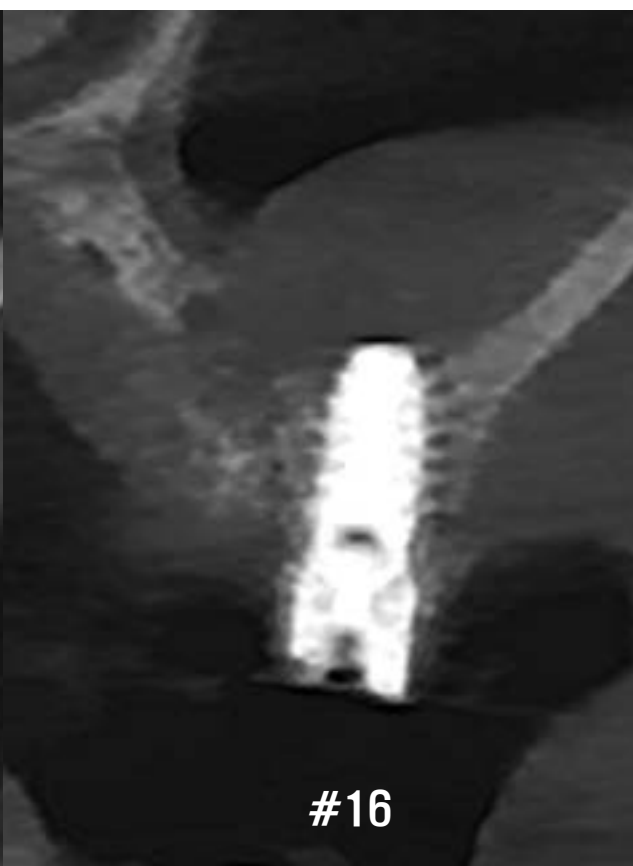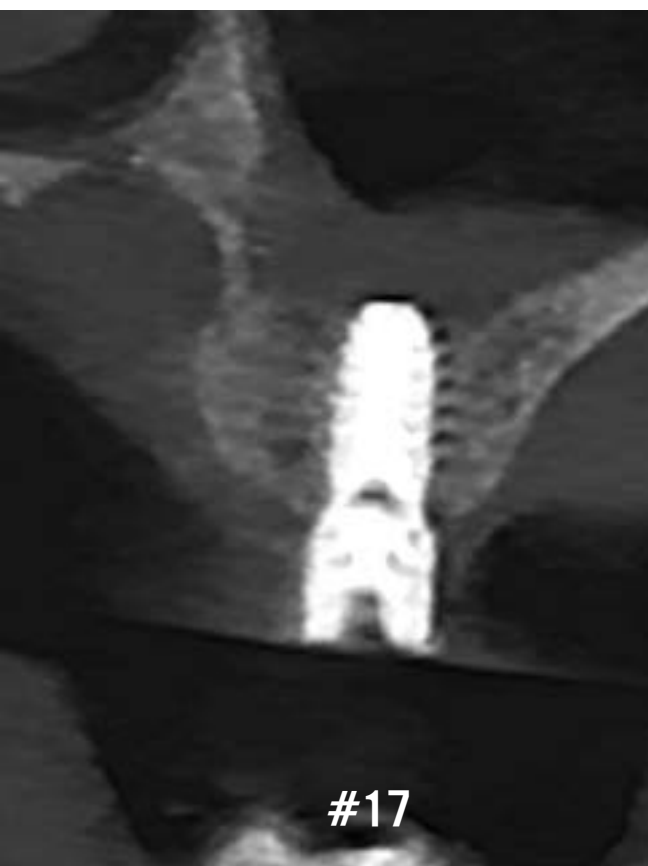bright TL 7mm : bicortical fixation



bright TL (Ø4.0 X 7.0)

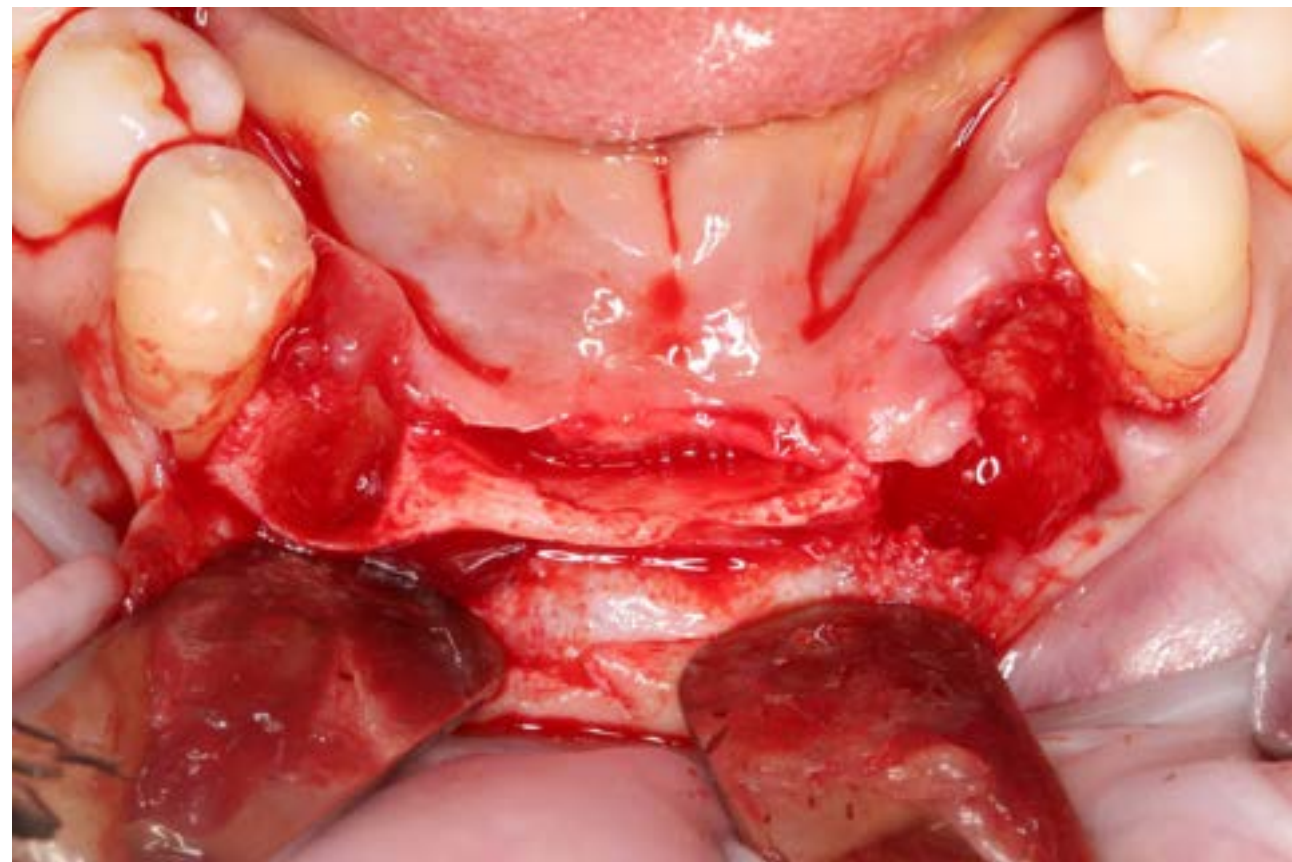
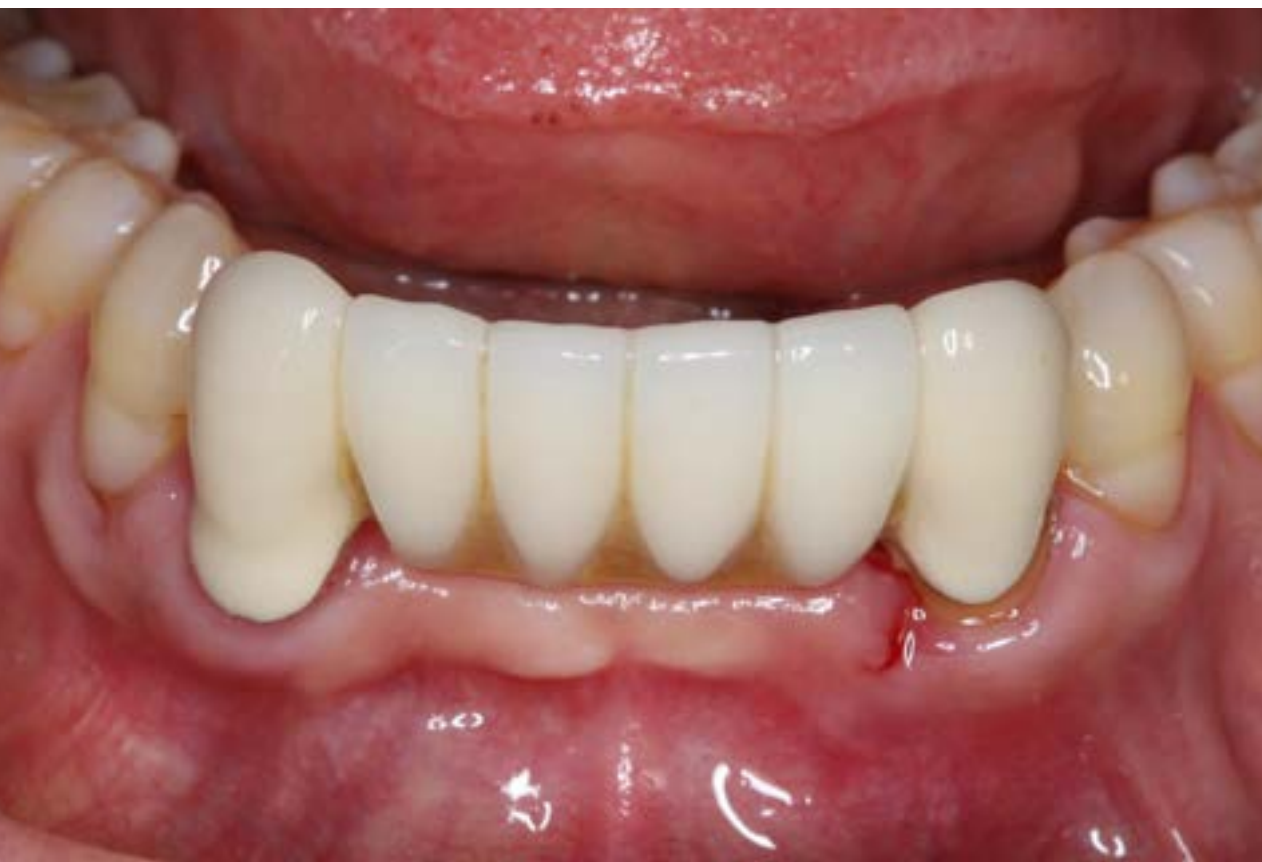

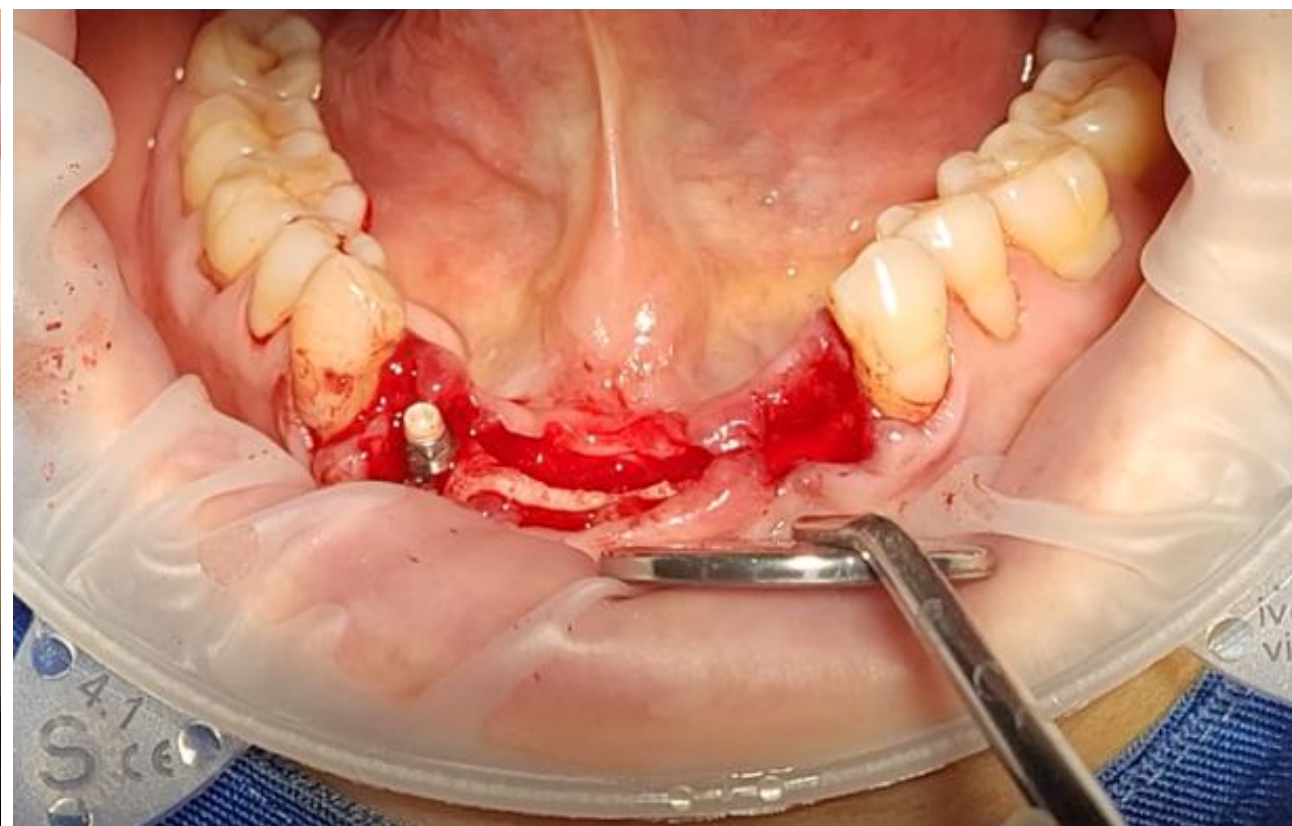
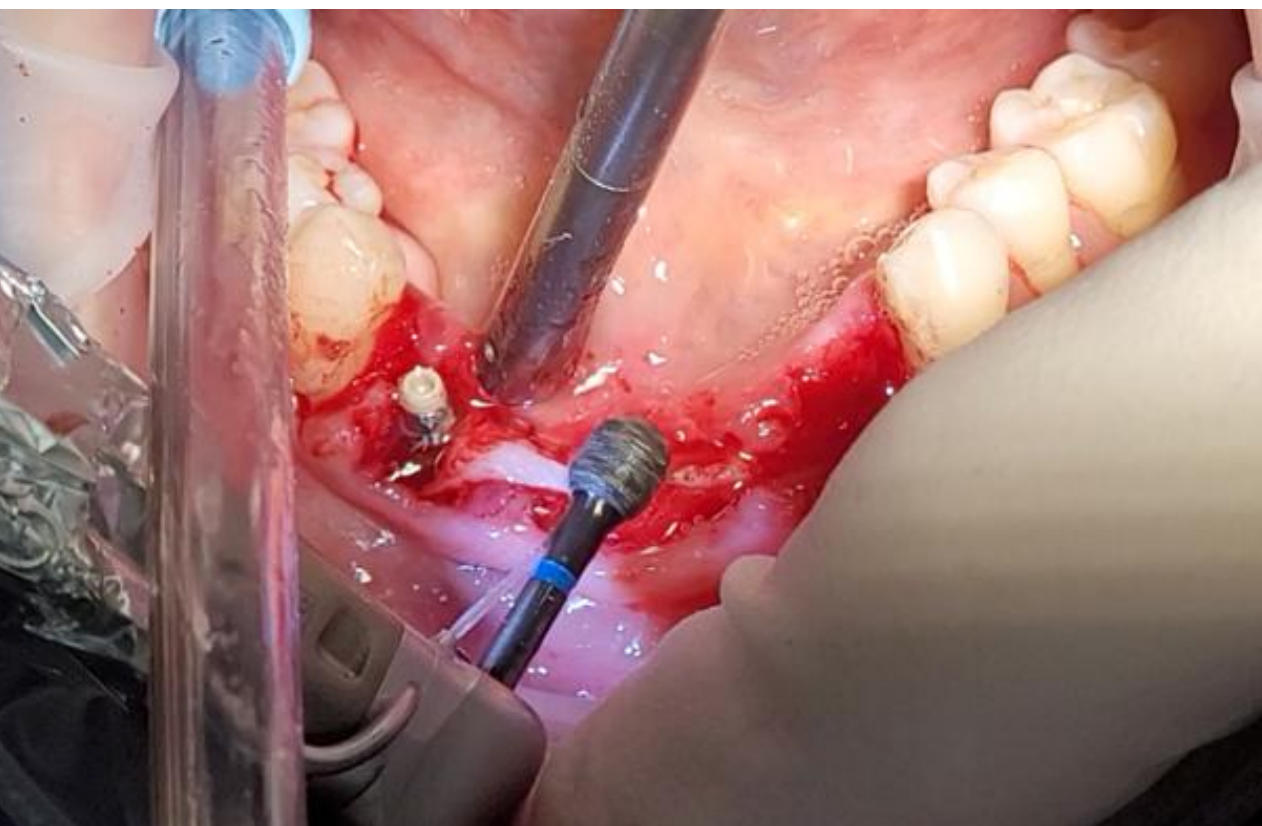
bright TL (Ø4.5 X 7.0)



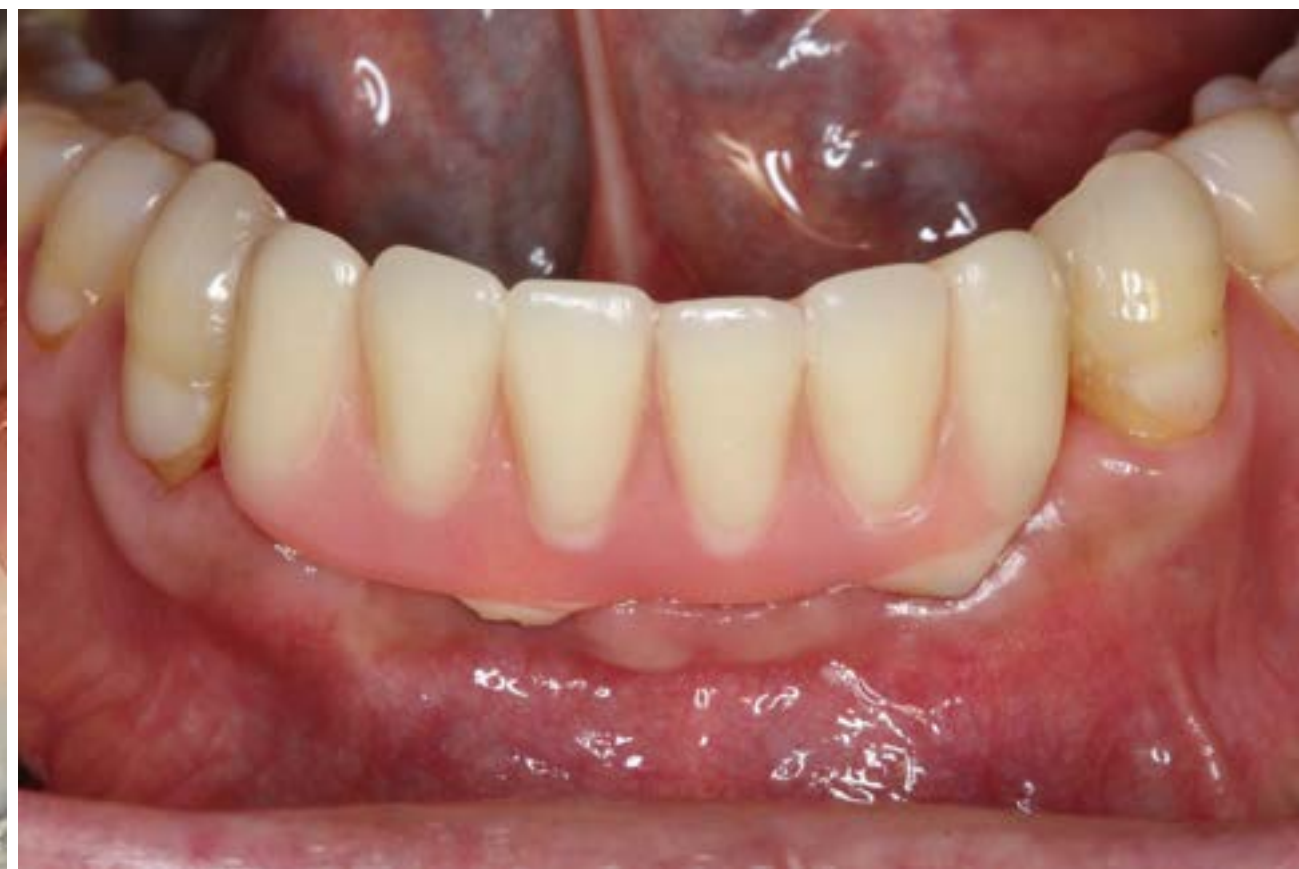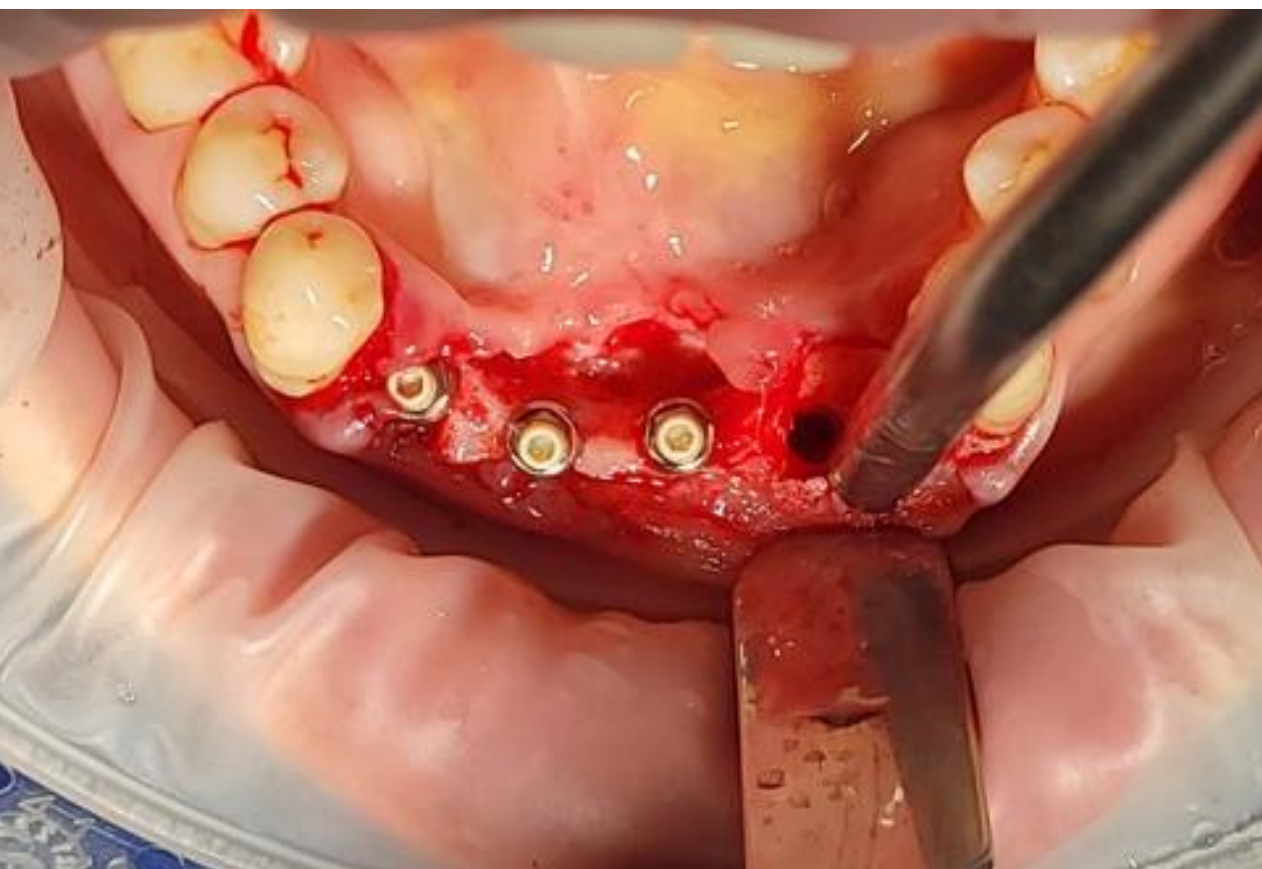
**bright TL is the optimized system
for the elder patients**

narrow ridge implantation



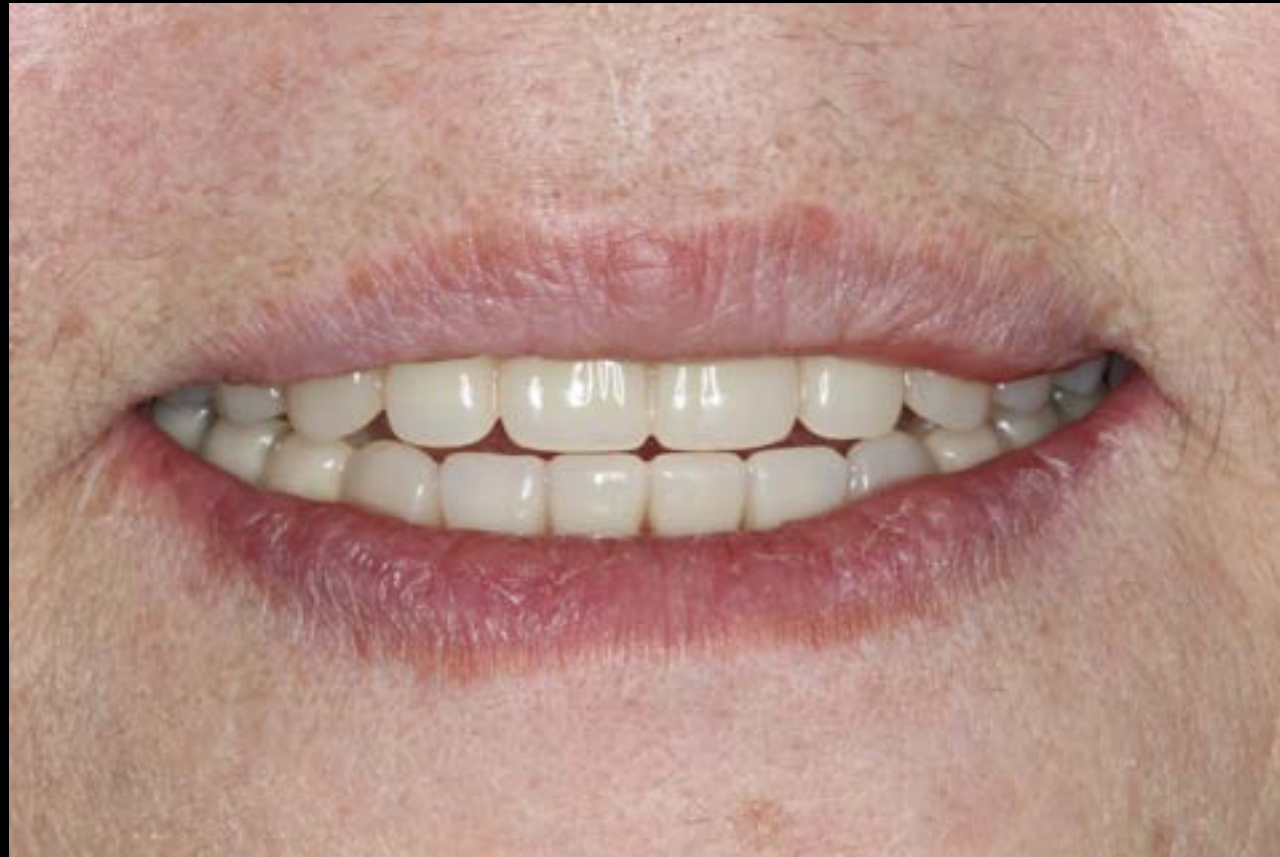
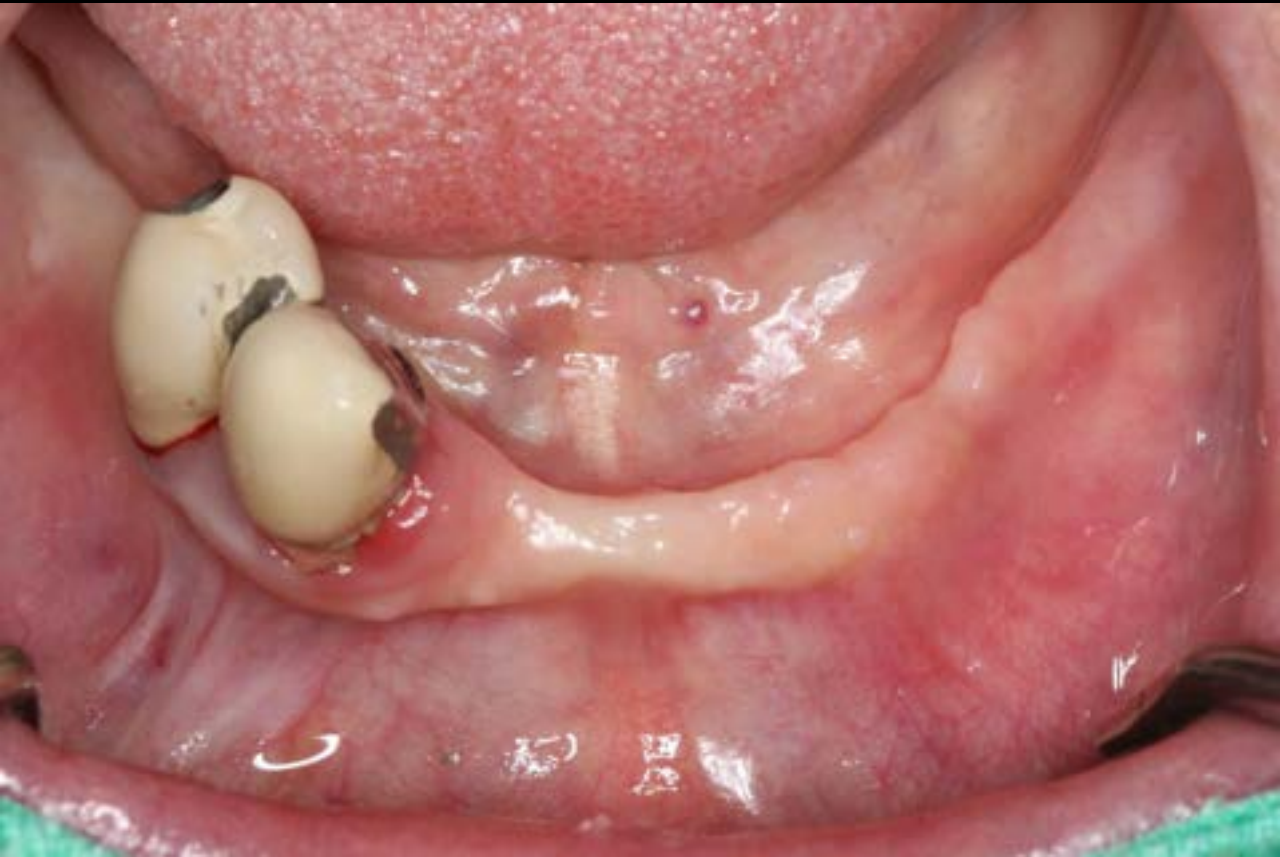
sharp narrow ridge : trimming with DASK bur

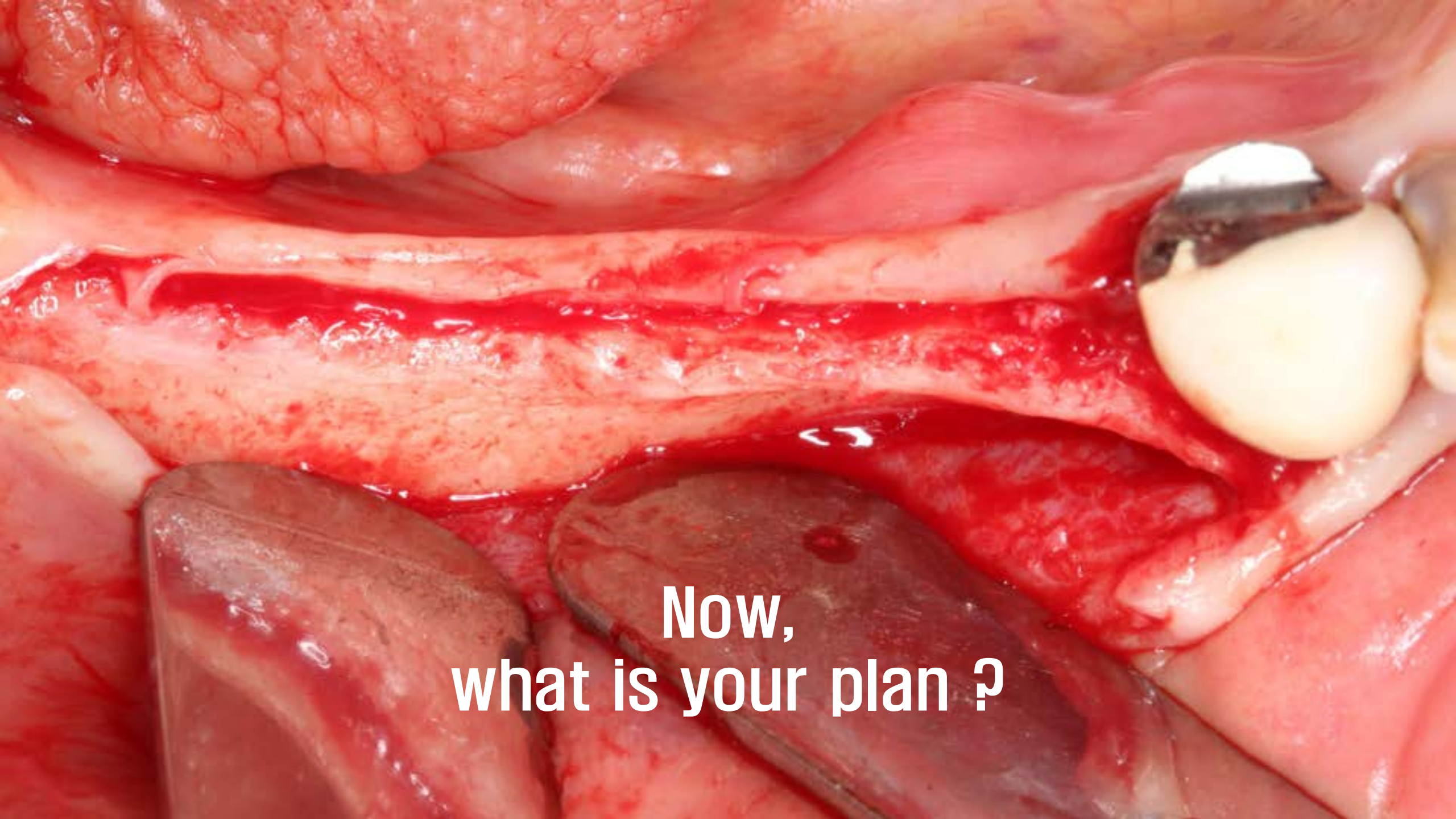


Temporary prosthesis

implant supported over denture



bright TL : it is my secret weapon for elder patients



**Now,
what is your plan ?**

bright TL is a smart answer !



Thank you for your kind attention !

