

A collection of dental-related items including a white spray bottle, a toothbrush, a dental mirror, a pair of dental pliers, a white tooth model, and a dental X-ray, all set against a teal background.

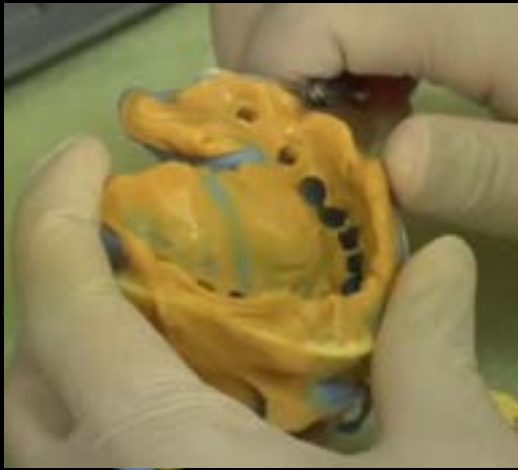# The First Step into Digital Dentistry A Guide to Intra Oral Scanning

# Contents


1. Intra Oral Scanner (BTS / IOS / BOS)
2. Dentium Dental Clinic Process and Clinical Case

# BTS

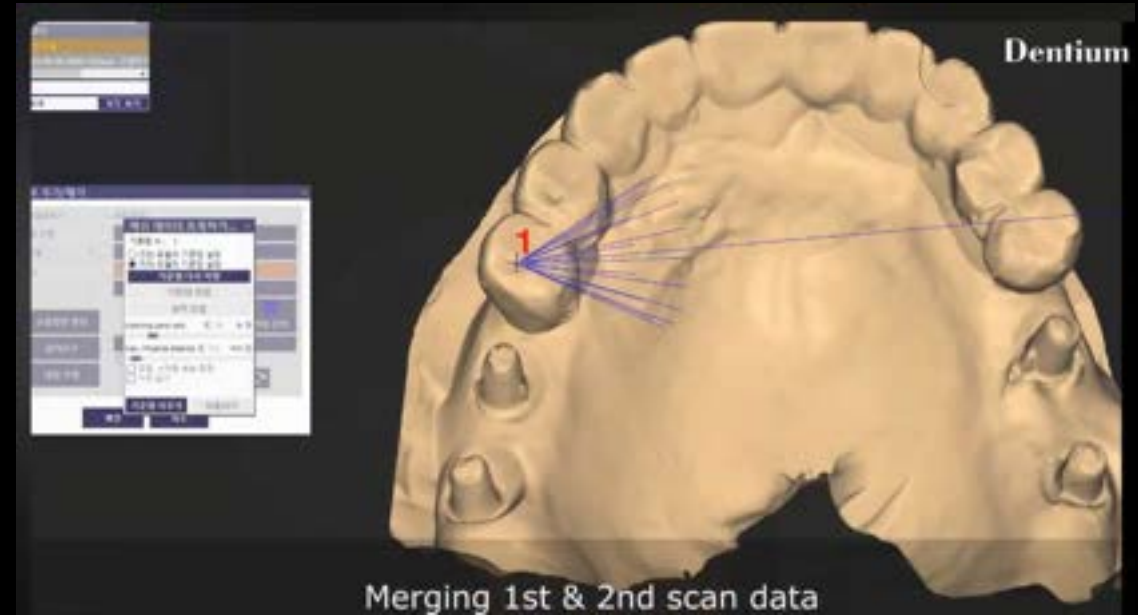

## BiteTray Impression Scanning



Impression Taking  
&  
Rubber Trimming



IMP SCAN

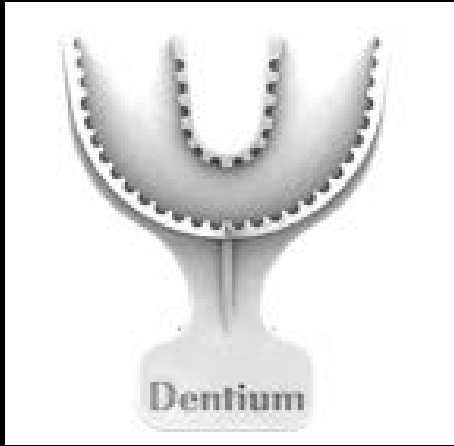

# Dentium Dental Clinic **BTS** Process

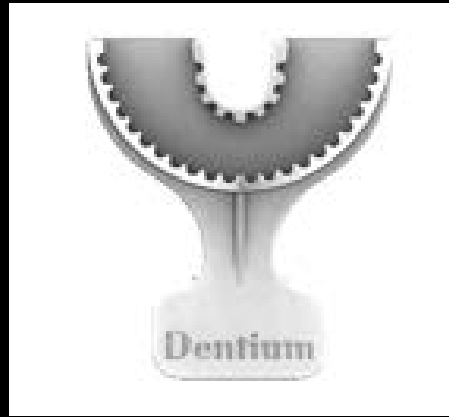## 1. Bite Tray Selection & Simulation



Full - Arch



Anterior - Exd



Anterior



Posterior – Metal



Posterior - Original

# Dentium Dental Clinic **BTS** Process

## 1. Bite Tray Selection & Simulation



Metal frame

- Enhanced Stability↑
- Minimal Distortion

Posterior – **Metal**

# Dentium Dental Clinic **BTS** Process

## 1. Bite Tray Selection & Simulation



Posterior – **Metal**

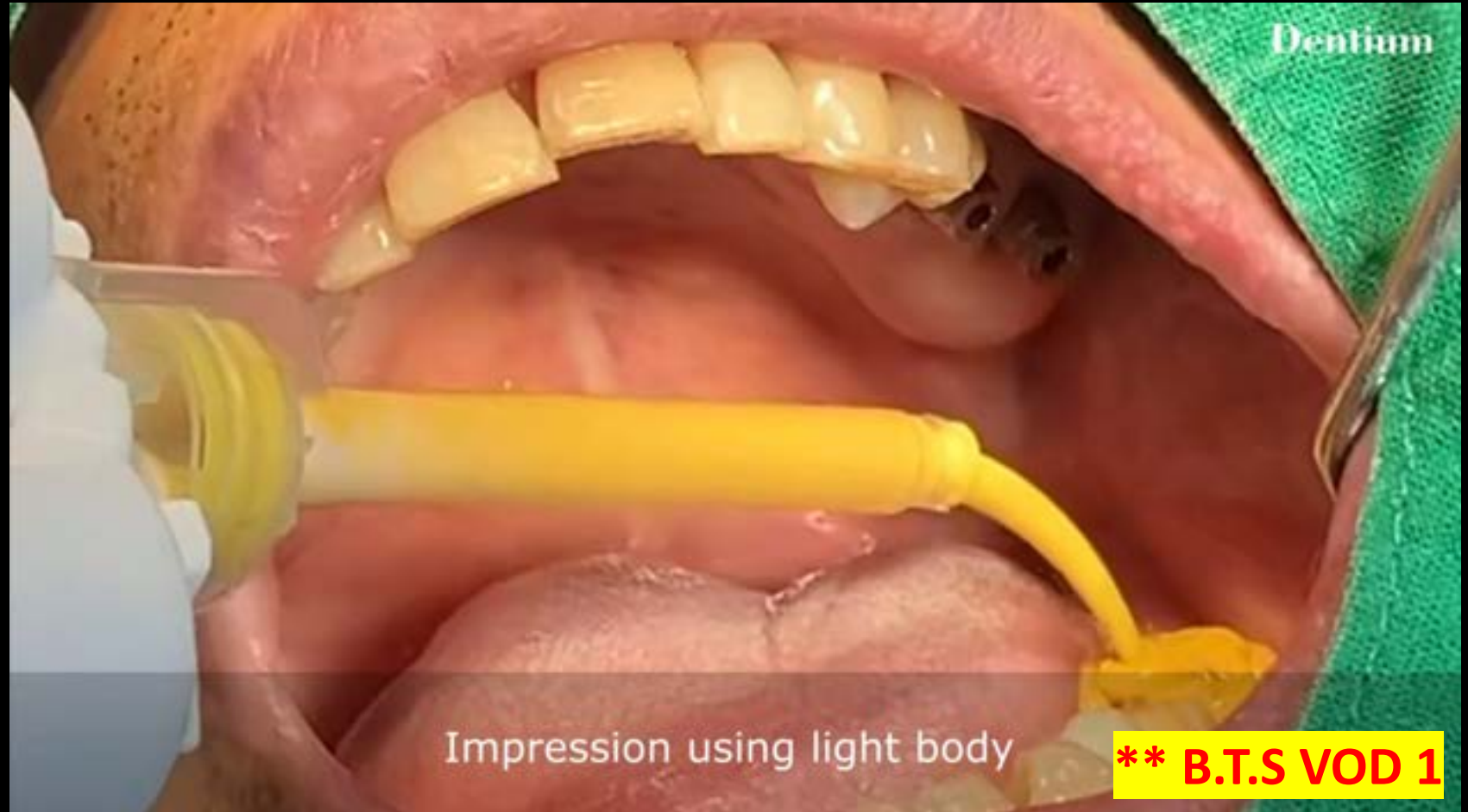

← Name Tag 👍

# Dentium Dental Clinic **BTS** Process

## Full VOD

1. Bite Tray Selection & Simulation
2. Light body & Putty IMP
3. Buccal & Lingual Molding
4. Jaw Fixation



# Dentium Dental Clinic **BTS** Process

## **\*\*Consistency of Rubber Impression Material\*\***

Class I (Putty): A dough-type material with minimal flow

Class II (Heavy Body): High-viscosity material with limited flow

Class III (Medium Body = Regular Body): Standard flow material

Class IV (Light Body): Very low-viscosity material for detailed impressions

Light body > medium body (= Regular) > Heavy body > Putty



# Dentium Dental Clinic **BTS** Process

**\*\*Consistency of Rubber Impression Material\*\***

**Class I (Putty): A dough-type material with minimal flow**

Class II (Heavy Body): High-viscosity material with limited flow

Class III (Medium Body = Regular Body): Standard flow material

Class IV (Light Body): Very low-viscosity material for detailed impressions

Light body > medium body (= Regular) > Heavy body >

**Putty**

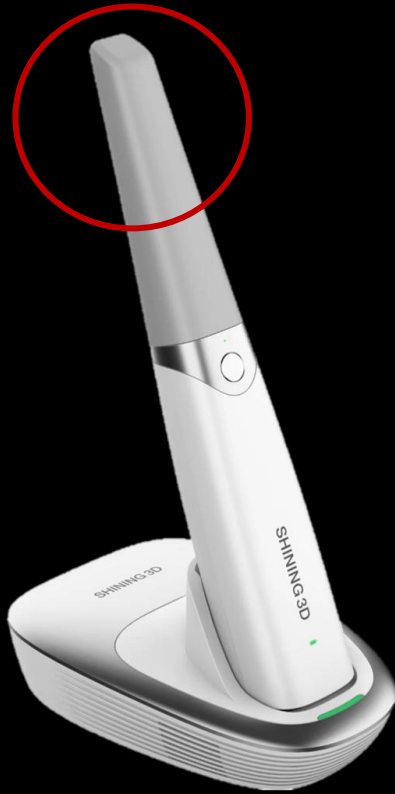

# Dentium Dental Clinic IOS Process

## Shining 3D Aoralscanner

1 Wireless & Lightweight

2 **Multiple tip options**



Aoralscan3 Wireless



Standard  
→ Main Tip



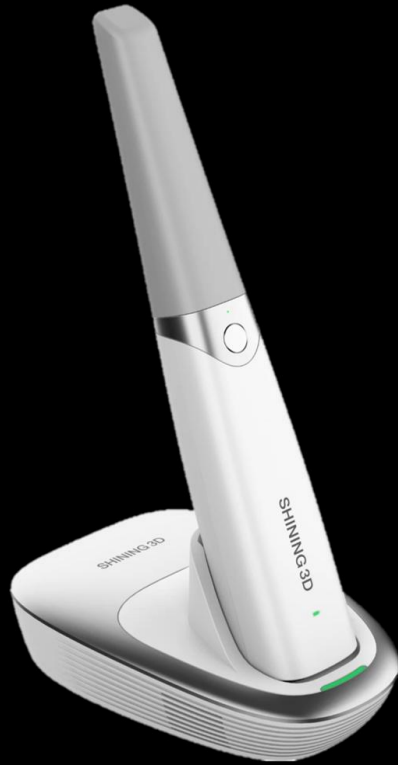Mini  
→ Posterior teeth  
or  
Patients with a small oral cavity

# Dentium Dental Clinic IOS Process

## Shining 3D Aoralscanner

1 Wireless & Lightweight

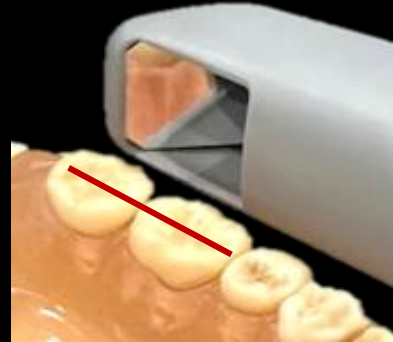
2 **Multiple tip options**



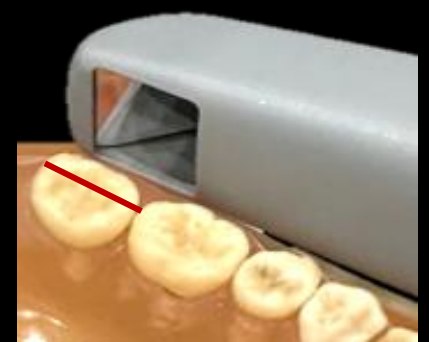
Aoralscan3 Wireless



Standard



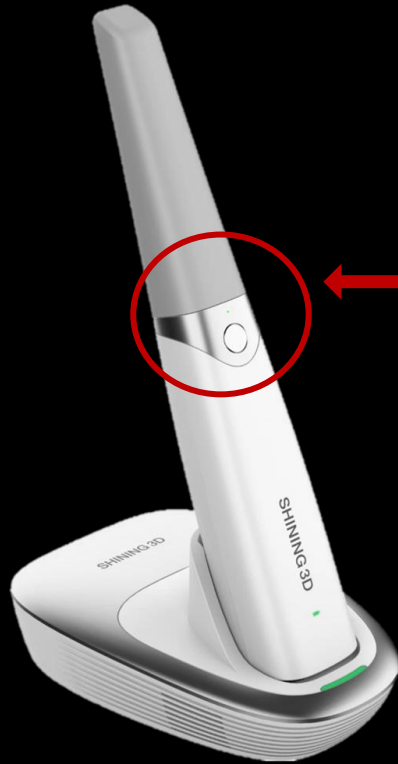Mini



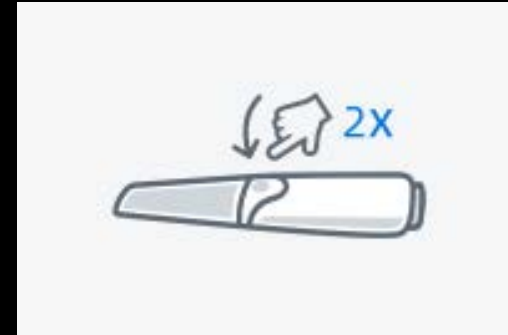# Dentium Dental Clinic IOS Process

## Shining 3D Aoralscanner

- 1 Wireless & Lightweight
- 2 Multiple tip options
- 3 **Motion**



ON/OFF Button  
&  
Motion Button

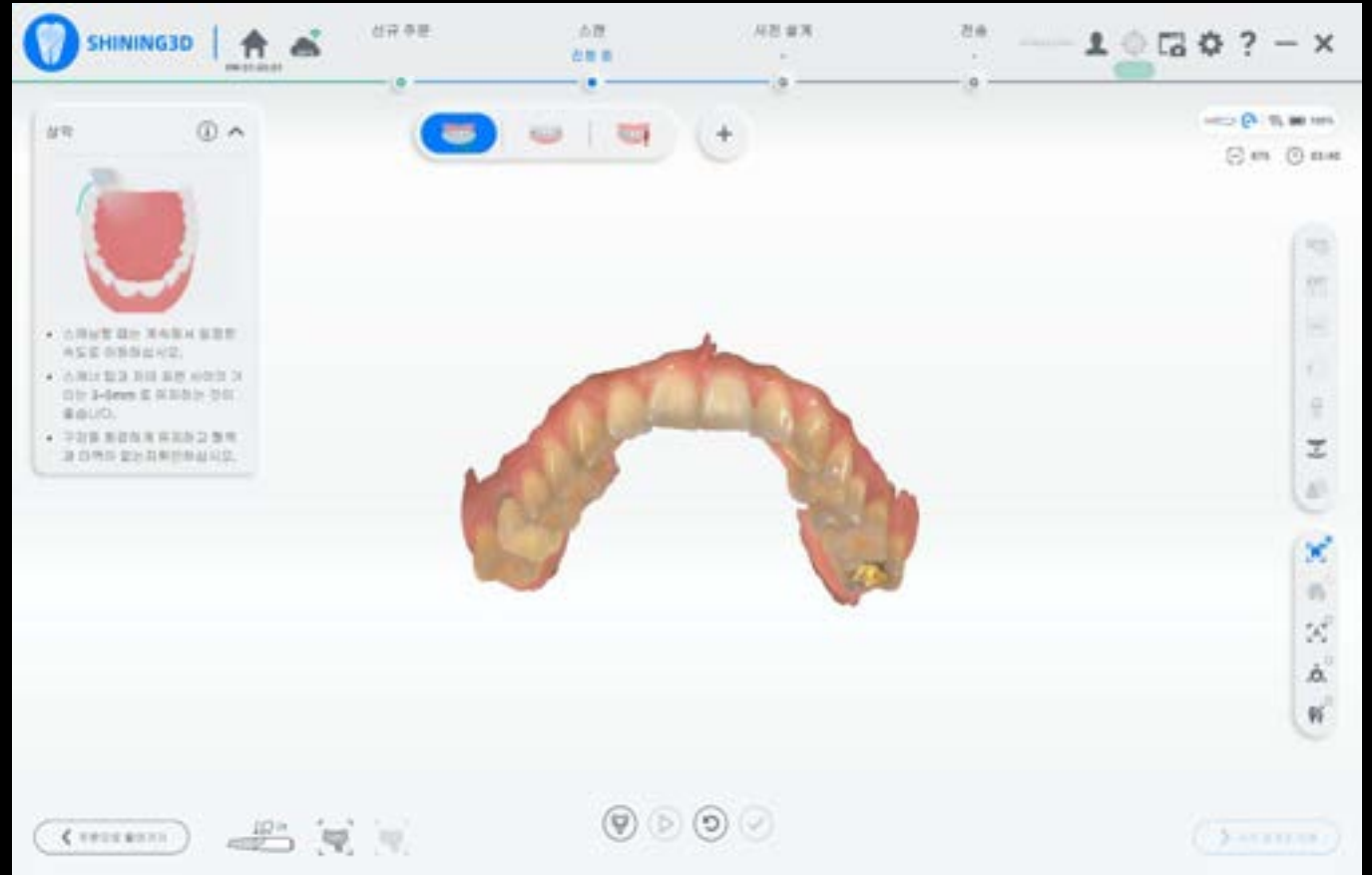
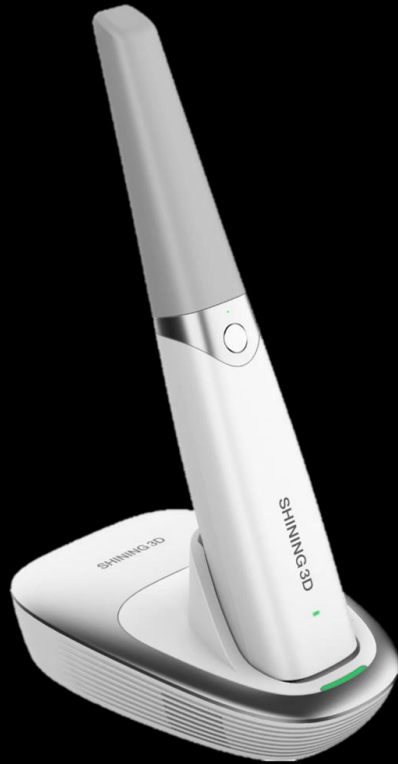

Aoralscan3 Wireless

# Dentium Dental Clinic IOS Process

## Shining 3D Aoralscanner

- 1 Wireless & Lightweight
- 2 Multiple tip options
- 3 **Motion**



Aoralscan3 Wireless

# Dentium Dental Clinic IOS Process

## Shining 3D Aoralscanner

- 1 Wireless & Lightweight
- 2 Multiple tip options
- 3 **Motion**



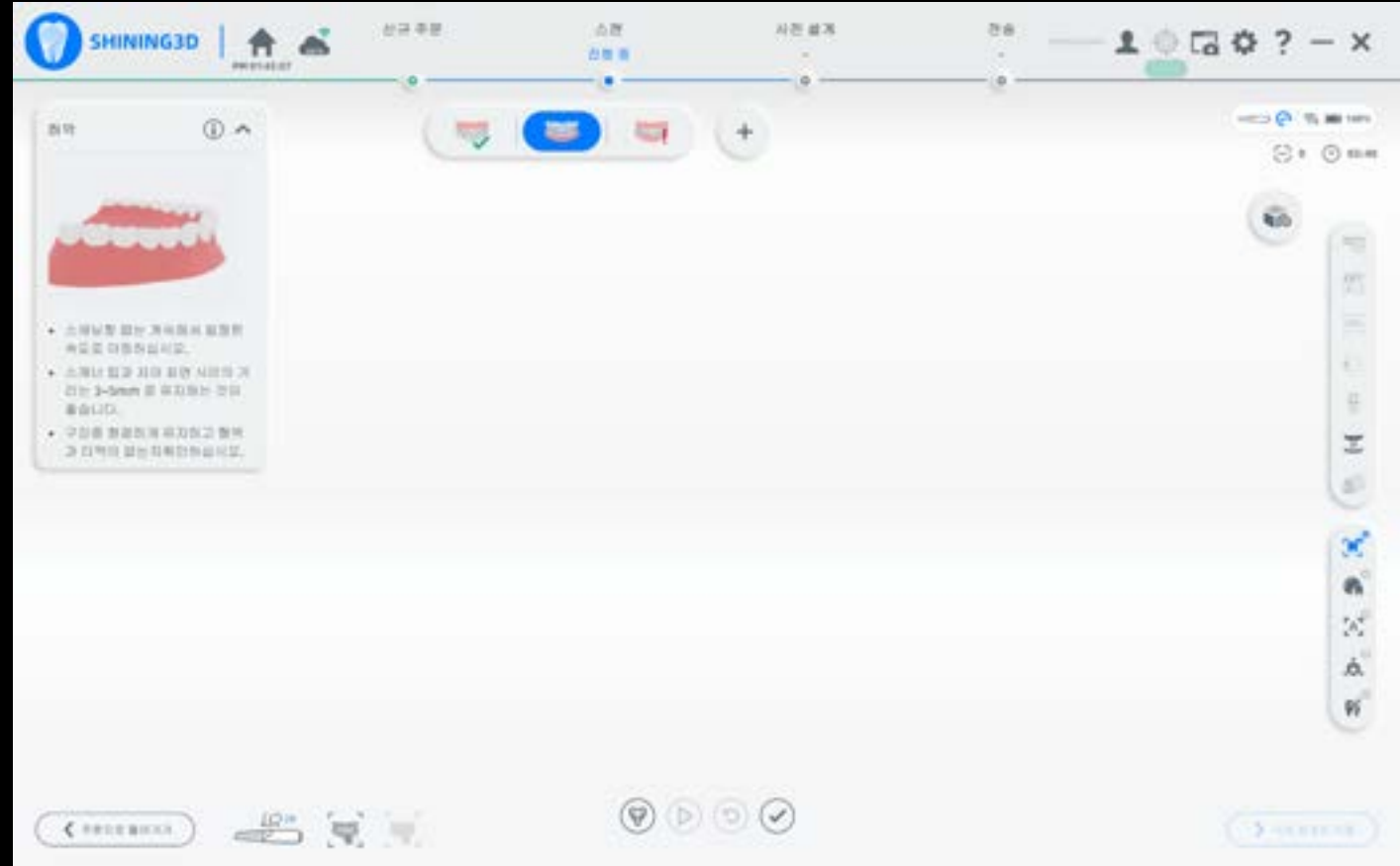
“Hold~”

Aoralscan3 Wireless

# Dentium Dental Clinic IOS Process

## Shining 3D Aoralscanner

- 1 Wireless & Lightweight
- 2 Multiple tip options
- 3 **Motion**



Aoralscan3 Wireless

# Dentium Dental Clinic IOS Process

## Shining 3D Aoralscanner

- 1 Wireless & Lightweight
- 2 Multiple tip options
- 3 **Motion**



**“Twice!!”**

Aoralscan3 Wireless



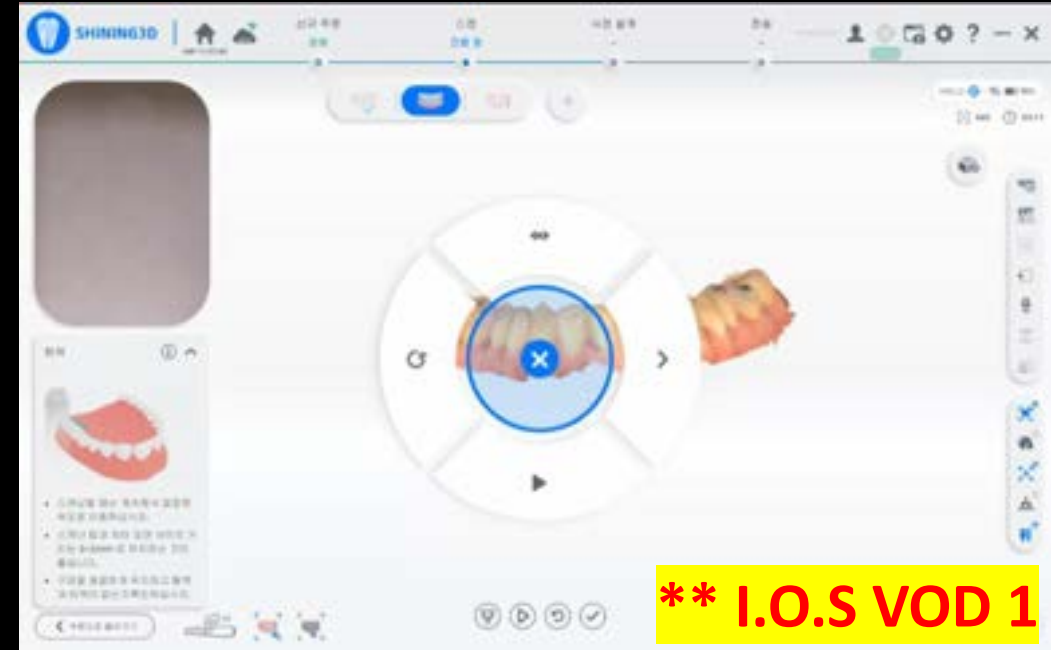# Dentium Dental Clinic IOS Process

## Shining 3D Aoralscanner

- 1 Wireless & Lightweight
- 2 Multiple tip options
- 3 **Motion**



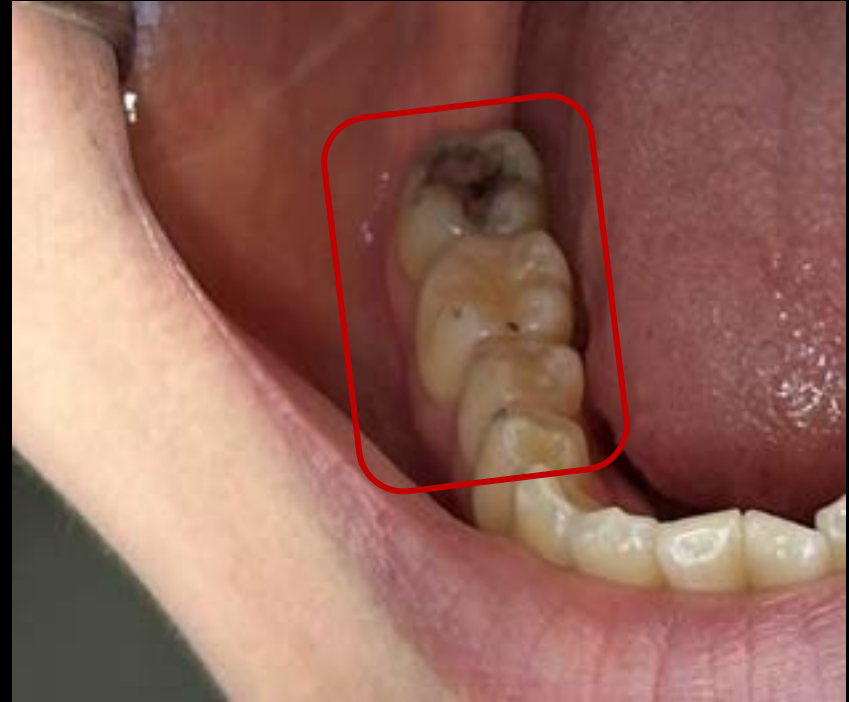
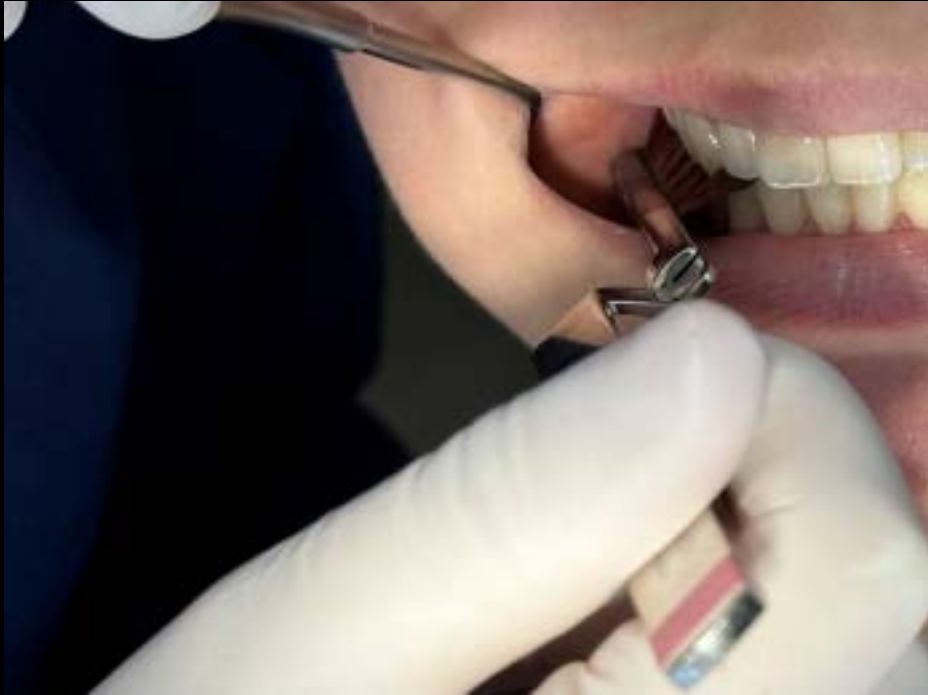Aoralscan3 Wireless



# Dentium Dental Clinic **IOS** Process

IOS Workflow (w. Shining 3D Aoralscan)

## **1. Bite Marking** with Articulating Paper



# Dentium Dental Clinic IOS Process

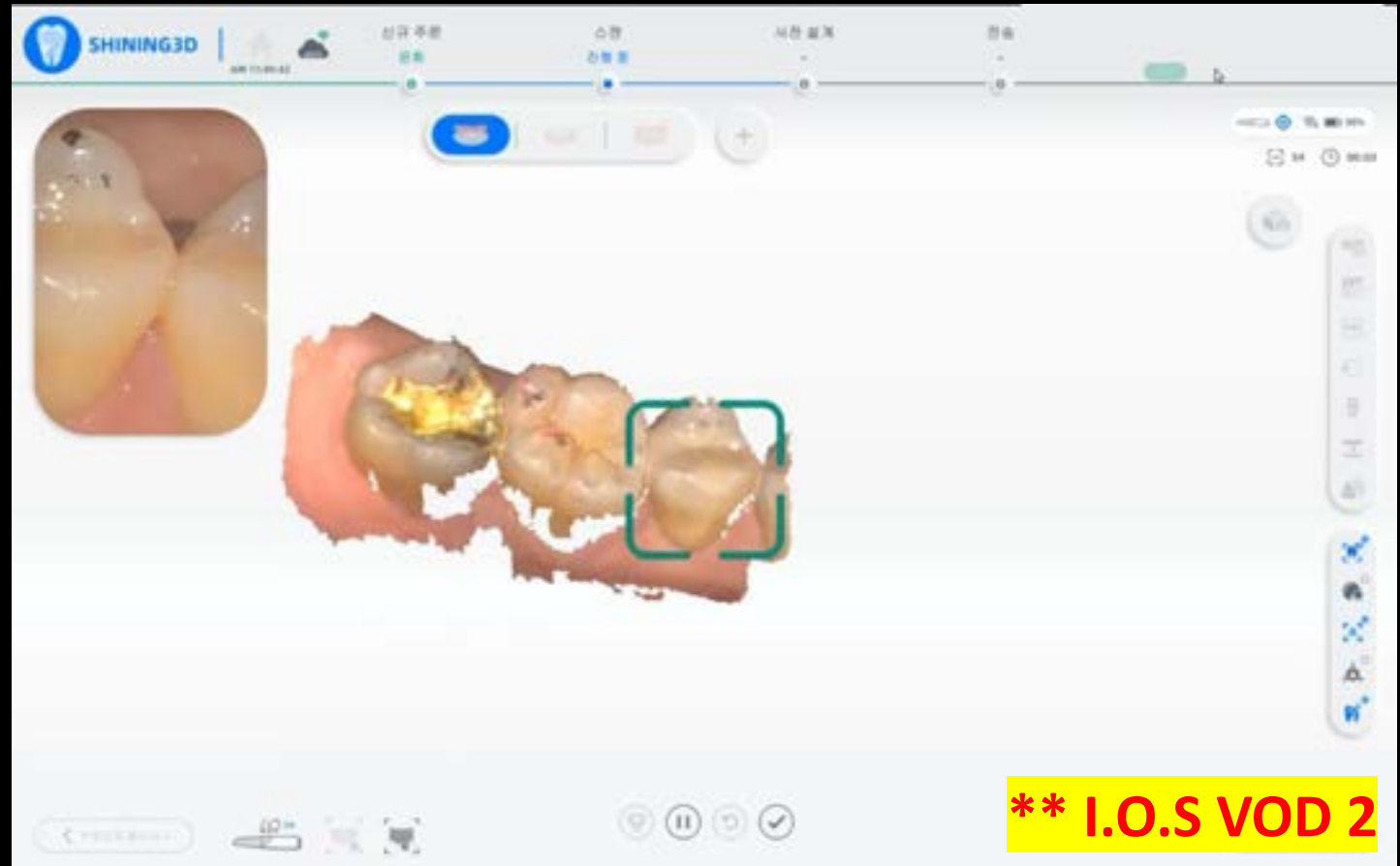IOS Workflow (w. Shining 3D Aoralscan)

1. Bite Marking with Articulating Paper

2. **Upper** SCAN



Standard



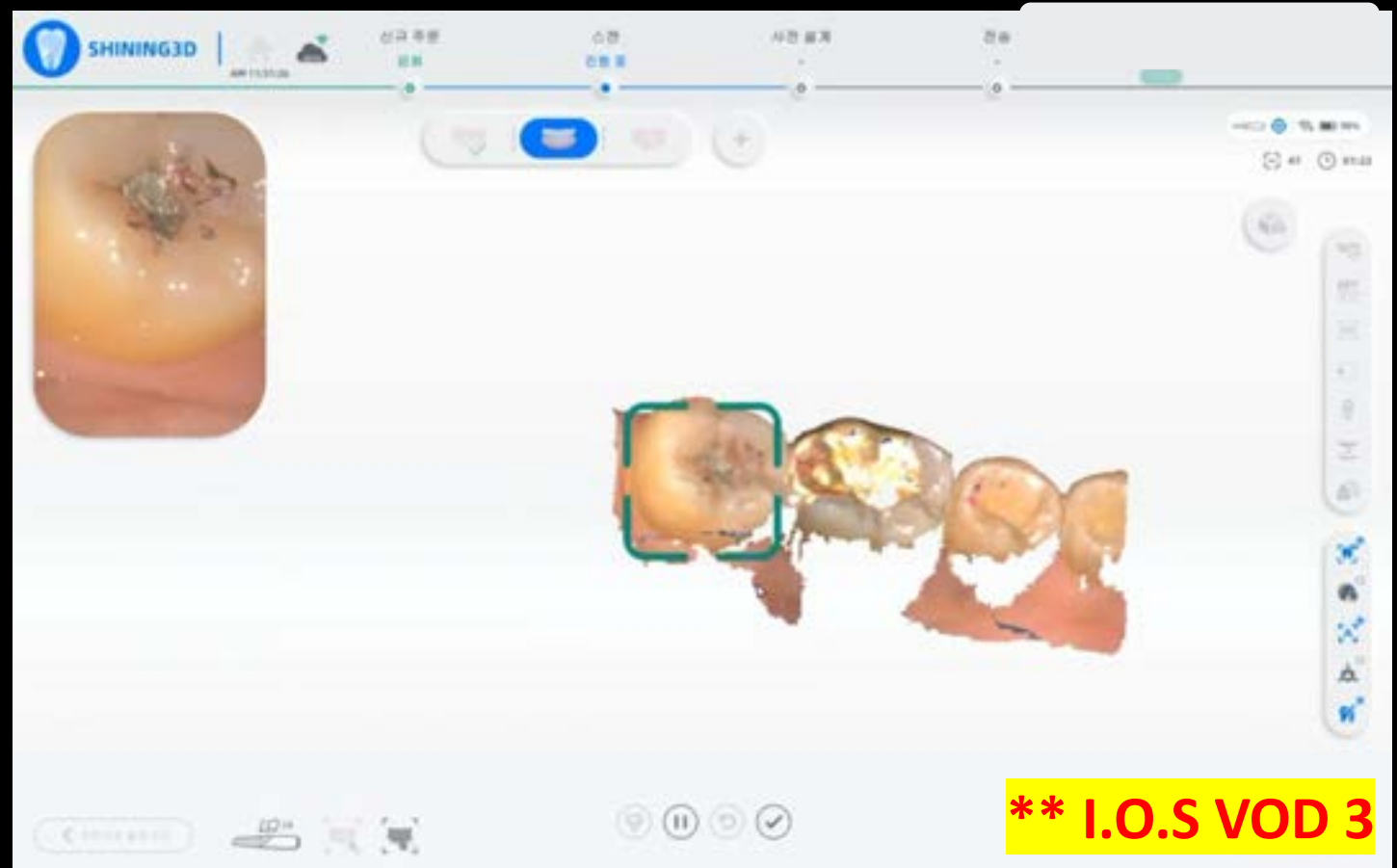
# Dentium Dental Clinic IOS Process

IOS Workflow (w. Shining 3D Aoralscan)

1. Bite Marking with Articulating Paper
2. Upper SCAN
3. **Lower** SCAN



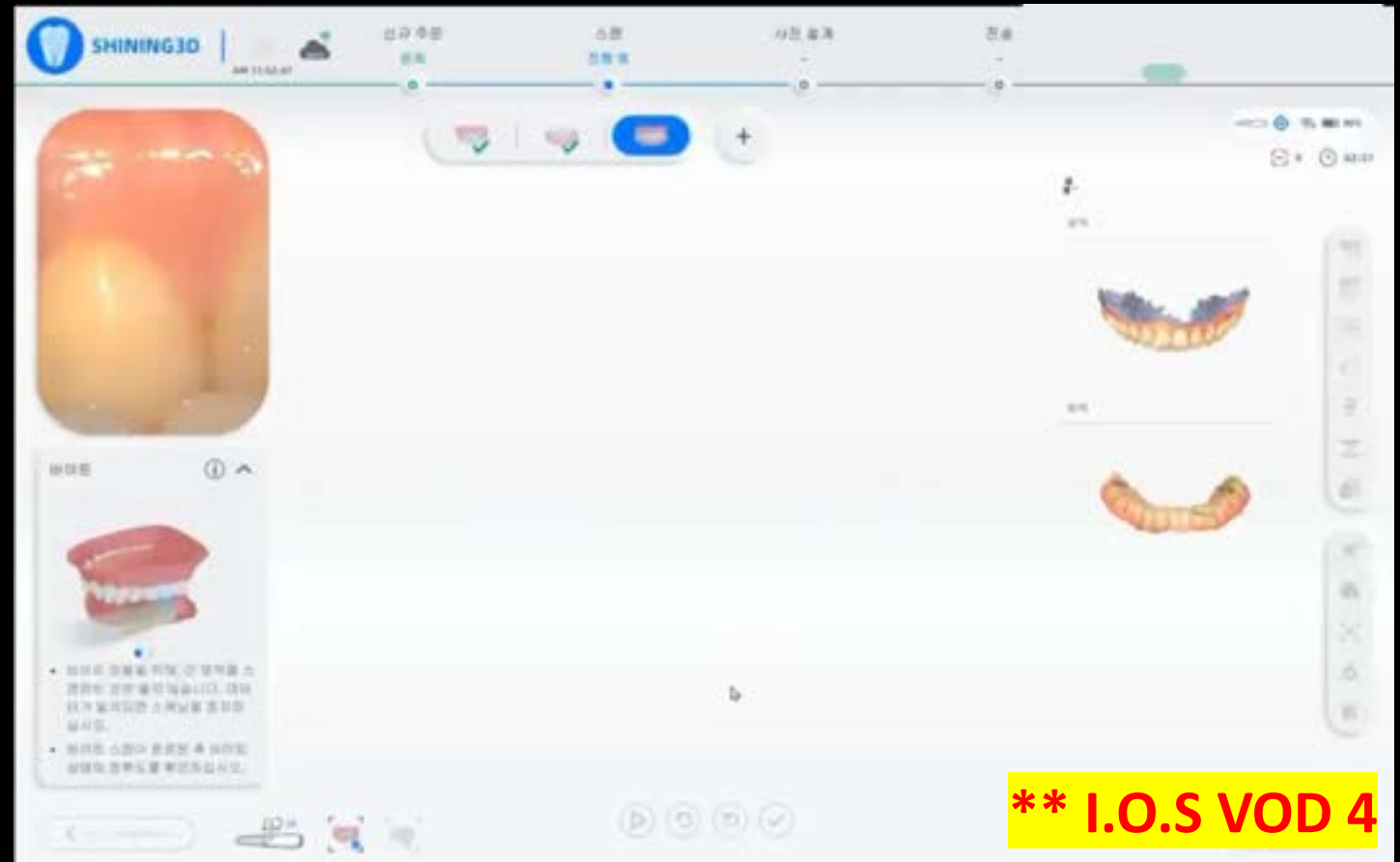
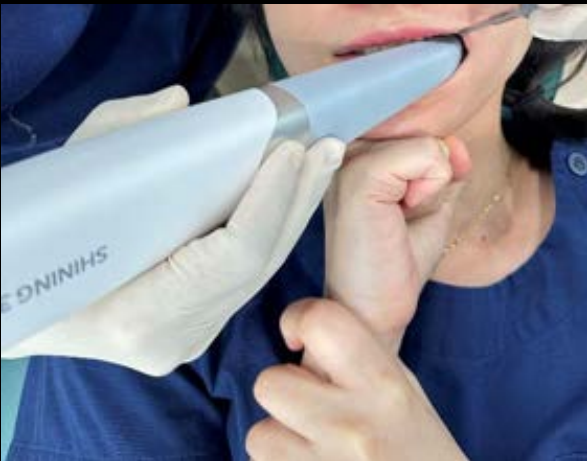Mini



# Dentium Dental Clinic IOS Process

## IOS Workflow (w. Shining 3D Aoralscan)

1. Bite Marking with Articulating Paper
2. Upper SCAN
3. Lower SCAN
4. **Bite SCAN** (w. Jaw Fixation)

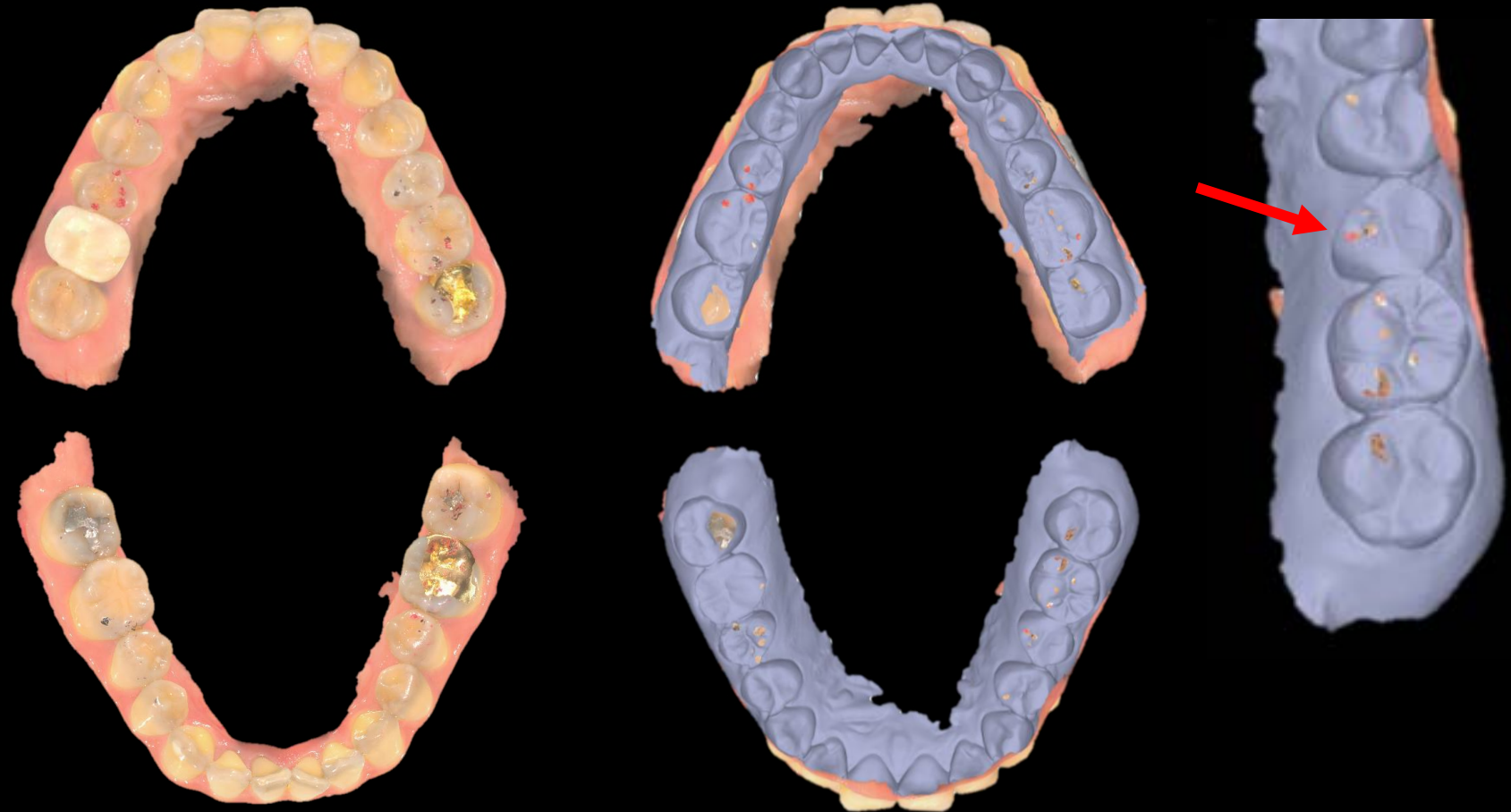


**\*\* I.O.S VOD 4**

# Dentium Dental Clinic **IOS** Process

## IOS Workflow (w. Shining 3D Aoralscan)

1. Bite Marking with Articulating Paper
2. Upper SCAN
3. Lower SCAN
4. Bite SCAN



# BOS

Bite tray impression scanning **With IOS**

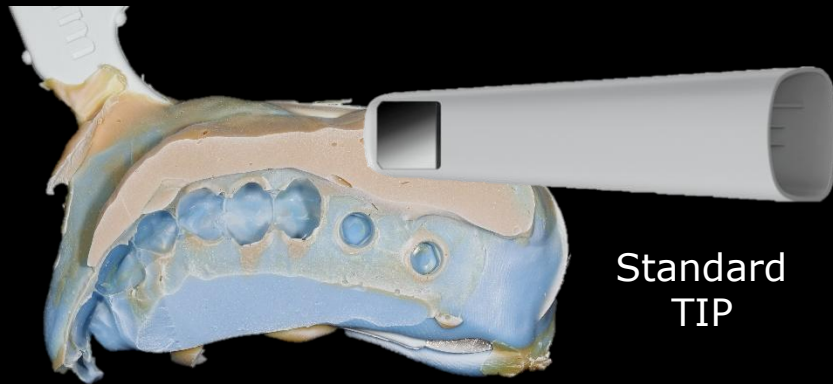
BTS – bite tray impression and impression scanning  
With Model Scanner

BOS – bite tray impression scanning  
With IOS



# Dentium Dental Clinic **BOS** Process

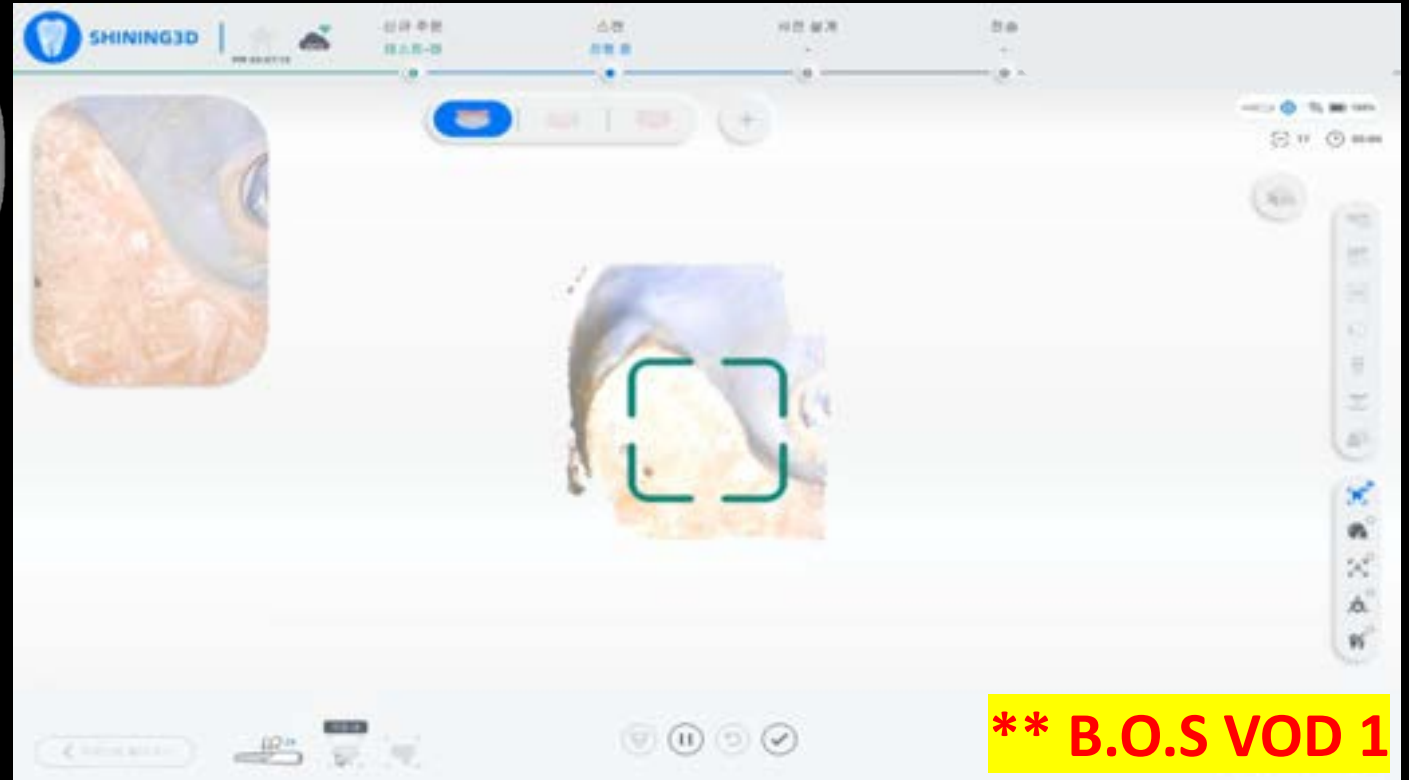
**BOS** (Bite Tray impression scanning With IOS) steps



Bite Impression

→ Scan Spray coating

→ IOS (w. Aoralscan3 Wireless)

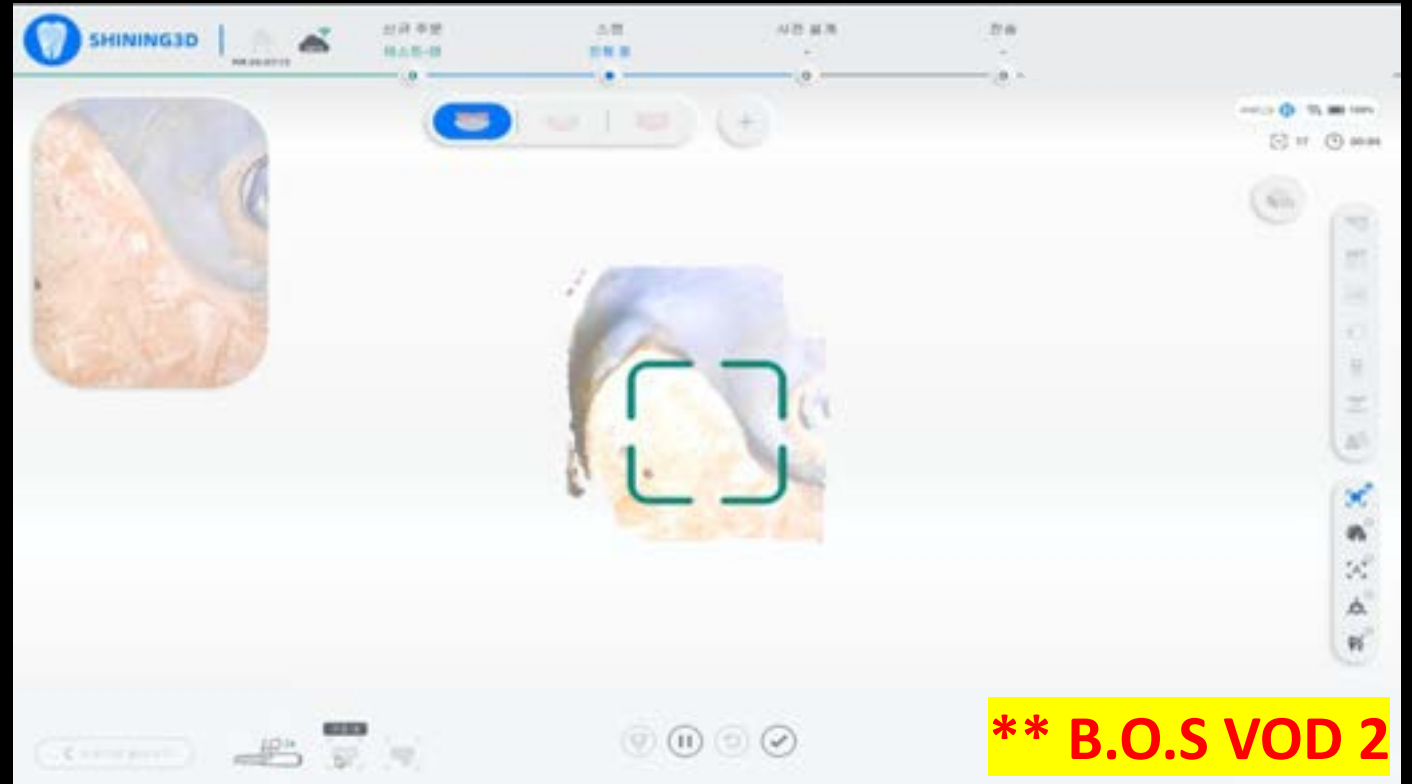
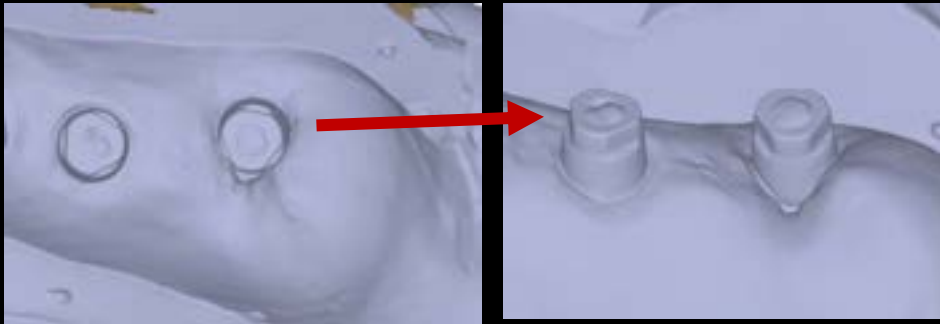
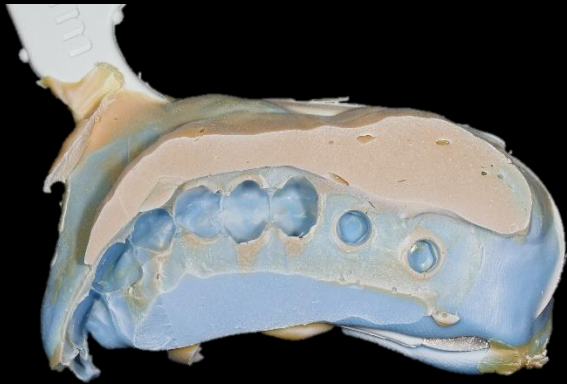


Maxilla Impression SACN



# Dentium Dental Clinic **BOS** Process

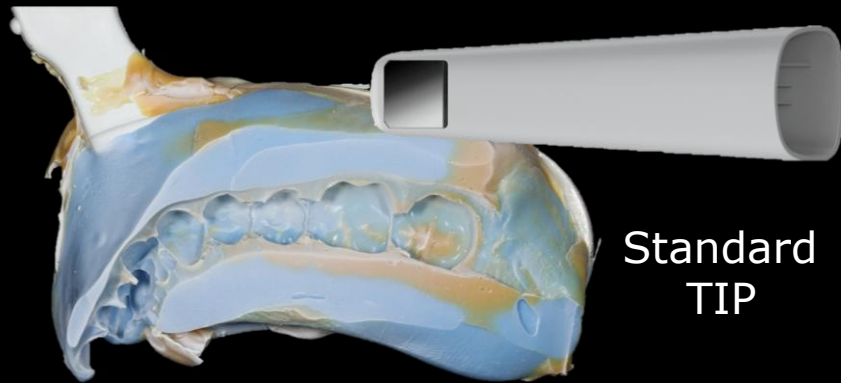
**BOS** (Bite Tray impression scanning With IOS) steps



Maxilla Impression SACN

# Dentium Dental Clinic **BOS** Process

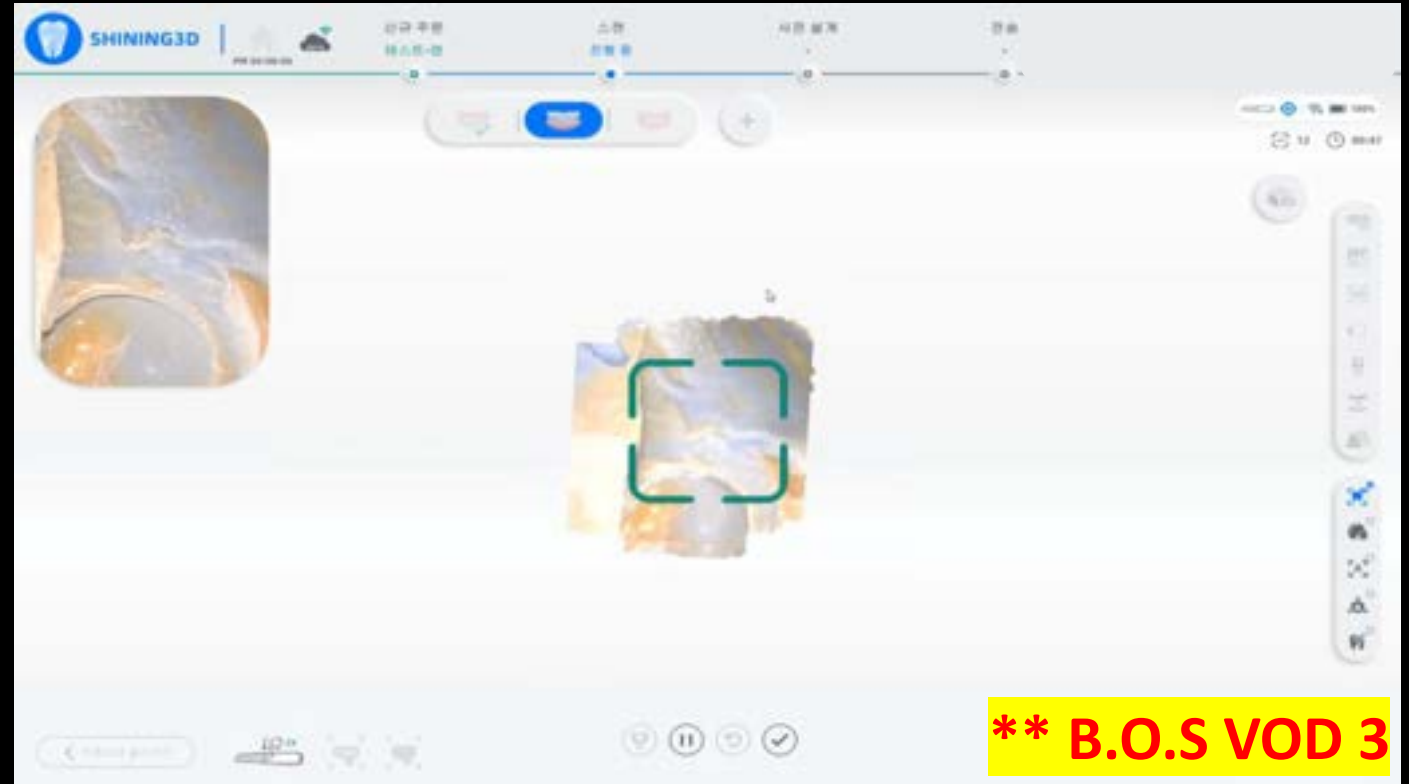**BOS** (Bite Tray impression scanning With IOS) steps



Bite Impression

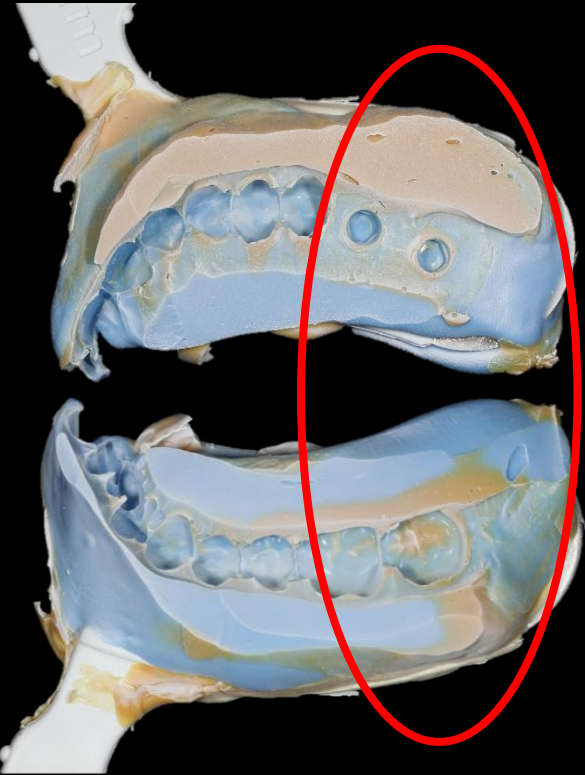→ Scan Spray coating

→ IOS (w. Aoralscan3 Wireless)

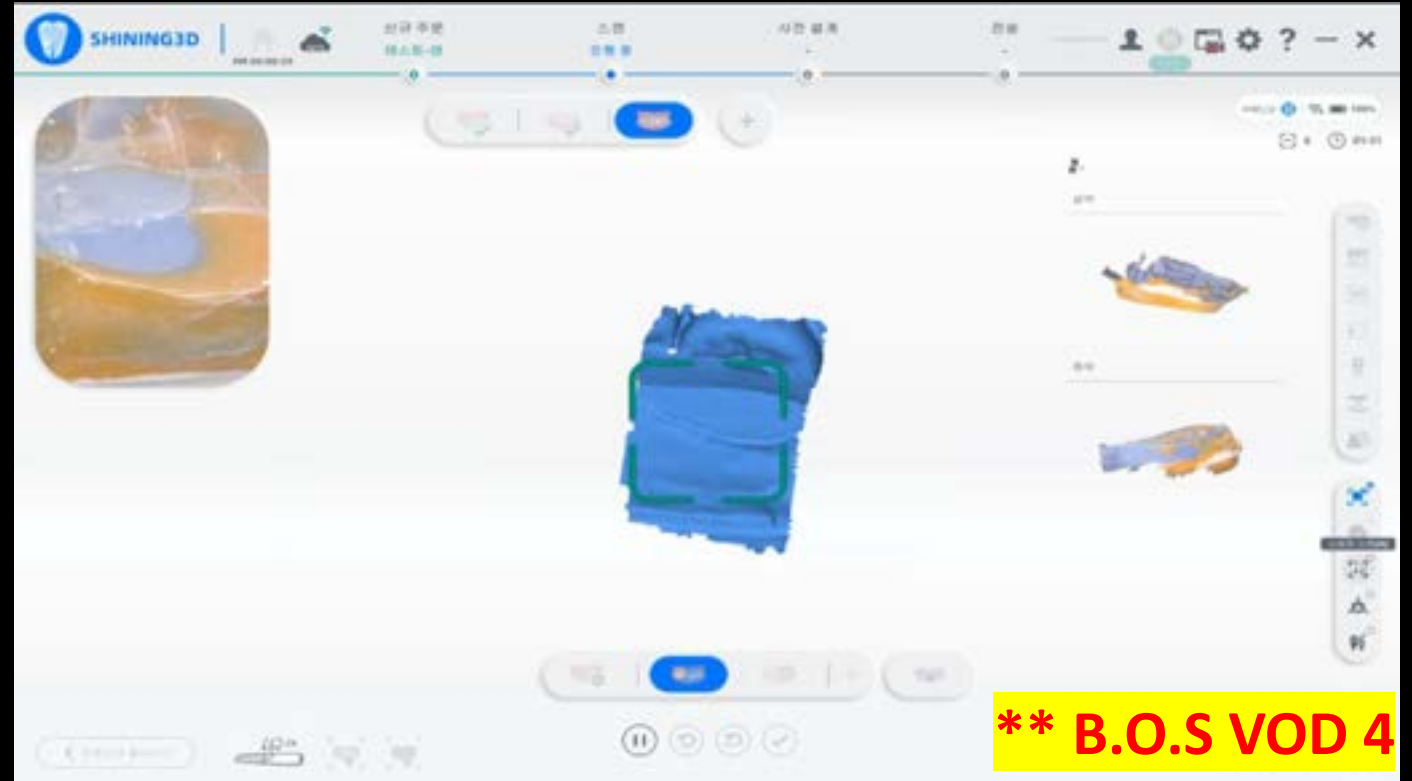


# Dentium Dental Clinic **BOS** Process

**BOS** (Bite Tray impression scanning With IOS) steps



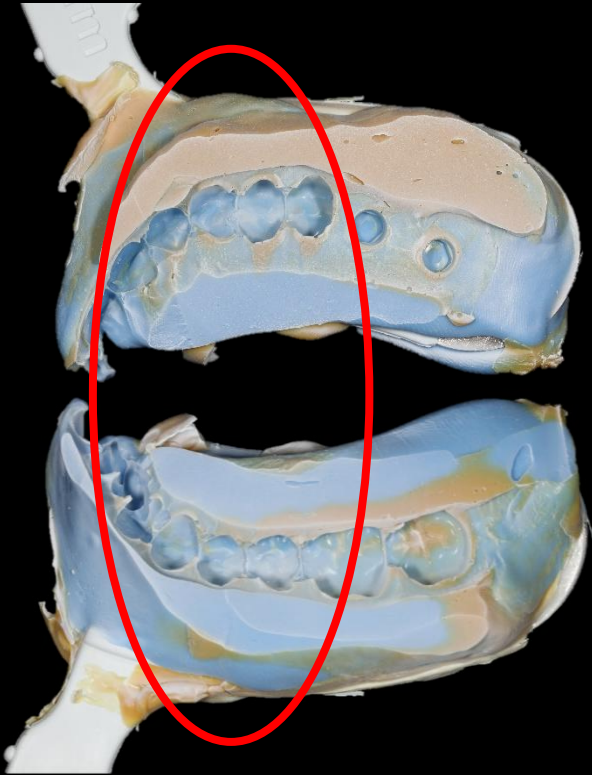
Bite Acquisition



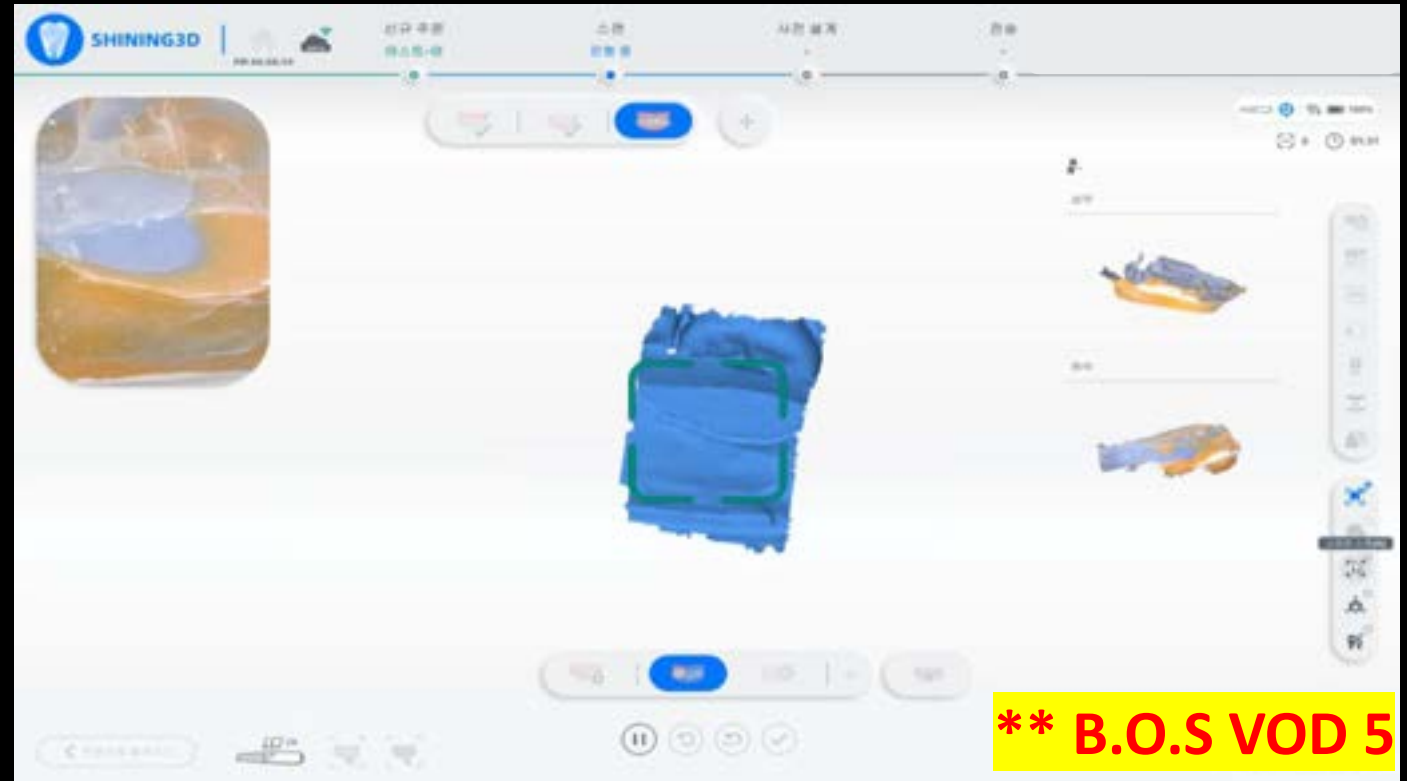**\*\* B.O.S VOD 4**

# Dentium Dental Clinic **BOS** Process

**BOS** (Bite Tray impression scanning With IOS) steps



Bite Acquisition



**\*\* B.O.S VOD 5**

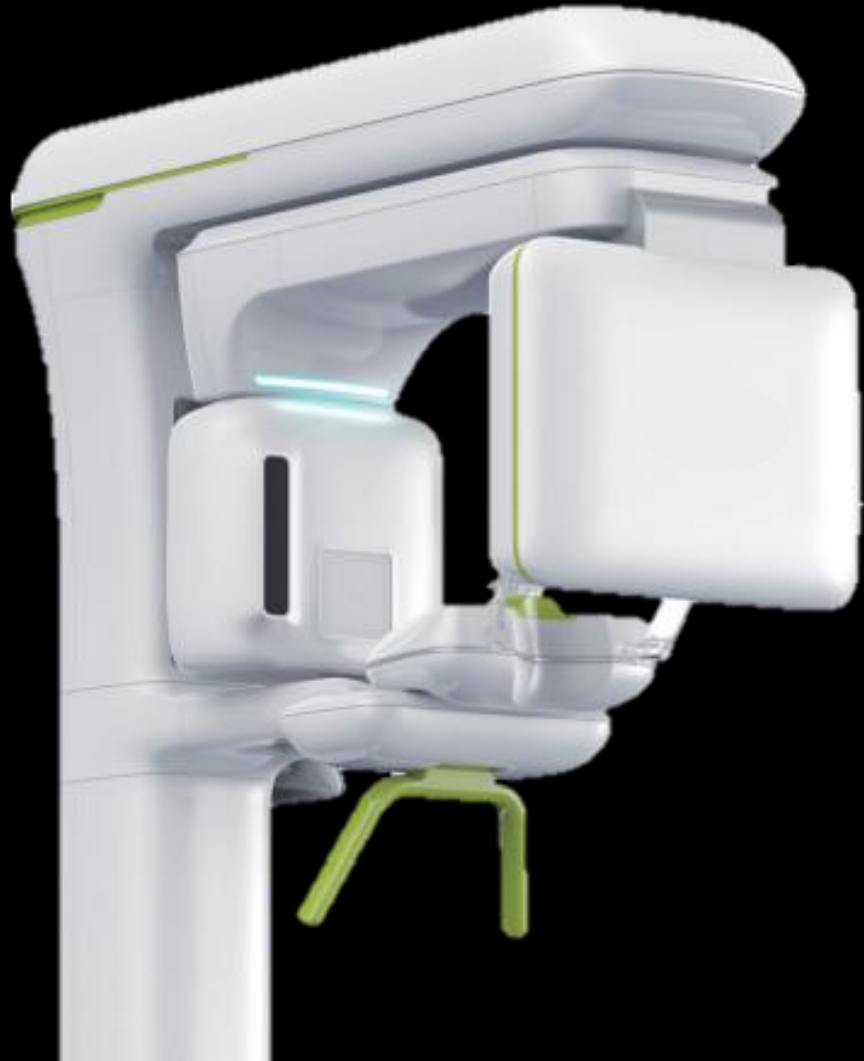

# Dentium Dental Clinic Process

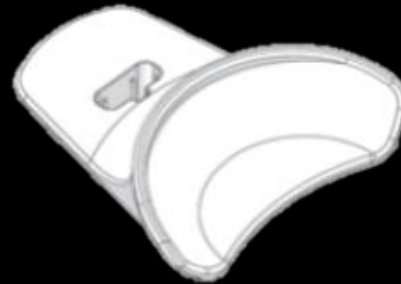(w. Prosthesis Preparation Process and **TIP**)



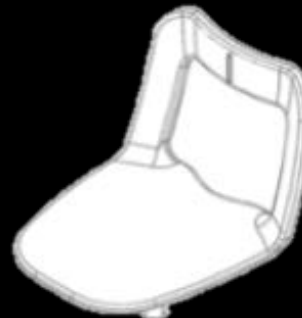# bright CT - Accessory



Standard



Edentulous jaw



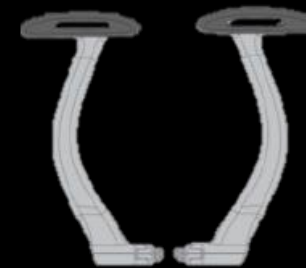TMJ



3 kinds of  
Standard tooth Bite

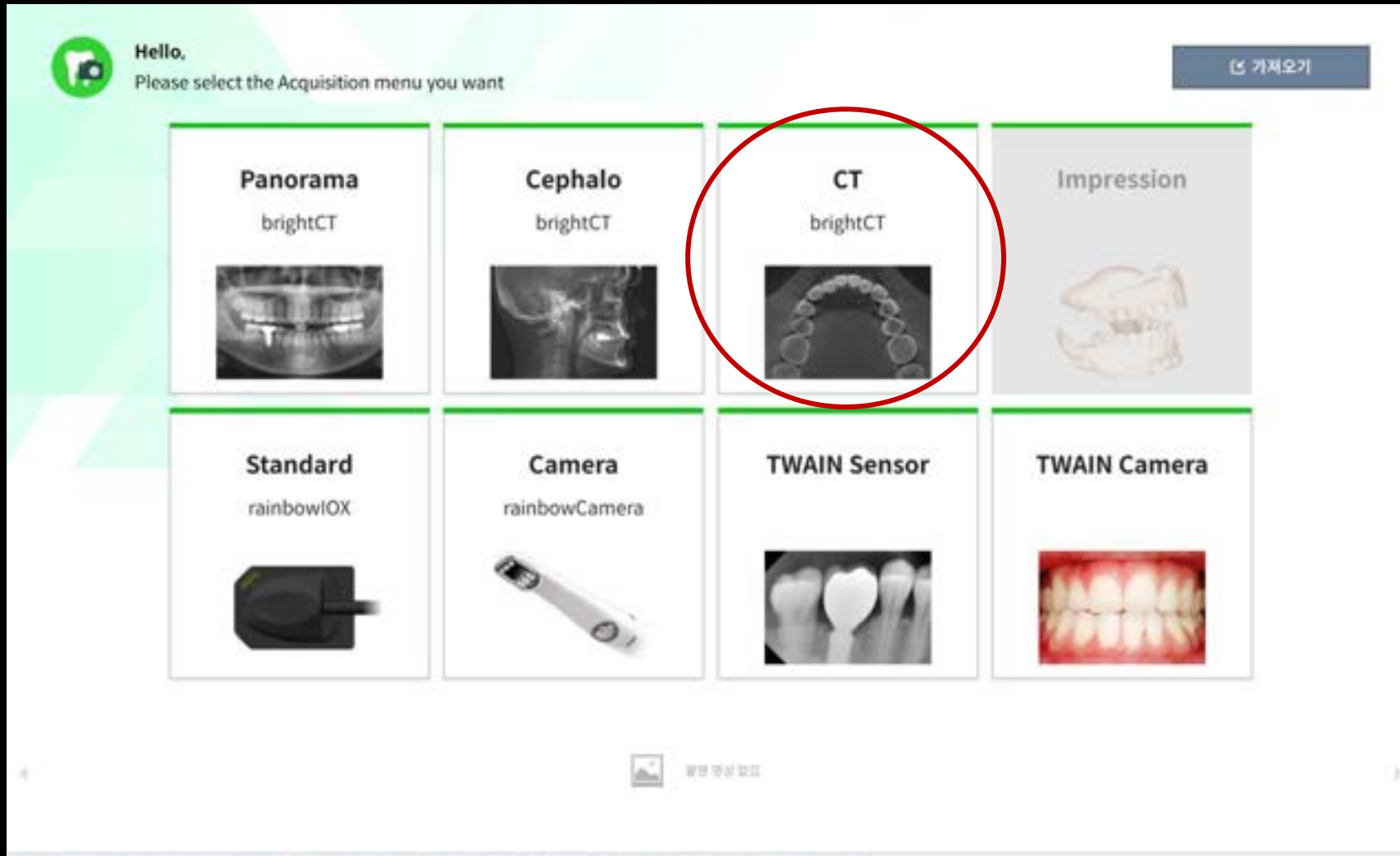


Edentulous  
jaw tooth Bite



Temple Support  
L/R

# bright CT Scan



# bright CT Scan

PANORAMIC CT MODEL

CT Indication

Male Normal 95kVp 11mA ScanTime : 20.0s DAP : 2900.74mGy\*cm²

Patient Type: Male Female Child Somato Type: Thin Normal Fat Scan Condition: 95kVp 11mA Scan Mode: Local Standard Wide Sinus TMJ Left TMJ Right Stitching Resolution: Fast Normal High Res MAR: On Off PatientID : 11569 Name : Gender/ Age : M / 49 Last Shooting Date : 2024/03/19

촬영 모드를 선택하신 후 Confirm 버튼을 클릭해 주세요.

Confirm



# bright CT Scan

PANORAMIC CT MODEL

CT Indication

Male Normal

95kVp 11mA  
ScanTime : 20.0s  
DAP : 2900.74mGy\*cm<sup>2</sup>

Standard

High Res

MAR On

PatientID : 11509  
Name :  
Gender/ Age : M / 49  
Last Shooting Date : 2024/03/19

Patient Type Somato Type Scan Condition Scan Mode Resolution MAR

Male Thin - 95kVp +  
Female Normal - 11mA +  
Child Fat

Local  
Standard  
Wide  
Sinus  
TMJ Left  
TMJ Right  
Stitching

Fast  
Normal  
High Res  
Endo

On  
Off

촬영 모드를 선택하신 후 Confirm 버튼을 클릭해 주세요.

Confirm

Standard

Scan Mode

Local

Standard

Wide

Sinus

TMJ Left

TMJ Right

Stitching

# bright CT Scan

PANORAMIC CT MODEL

CT Indication

Male Normal 95kVp 11mA ScanTime : 20.0s DAP : 2900.74mGy\*cm<sup>2</sup>

Patient Type: Male Female Child

Somato Type: Thin Normal Fat

Scan Condition: 95kVp 11mA

Scan Mode: Local Standard Wide Sinus TMJ Left TMJ Right Stitching

Resolution: Fast Normal High Res

MAR: On Off

PatientID : 11509 Name : Gender/ Age : M / 49 Last Shooting Date : 2024/03/19

촬영 모드를 선택하신 후 Confirm 버튼을 클릭해 주세요.

Confirm

Scan Mode

Local

Standard

Wide

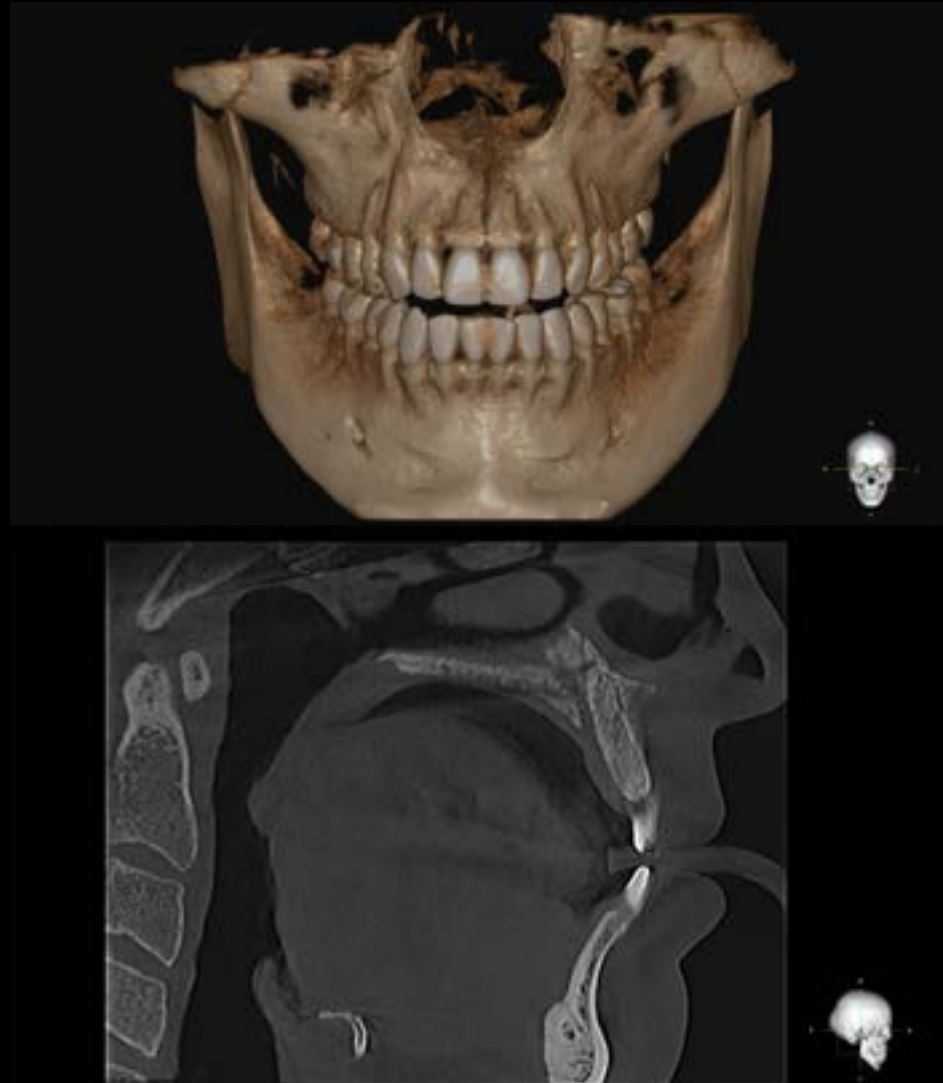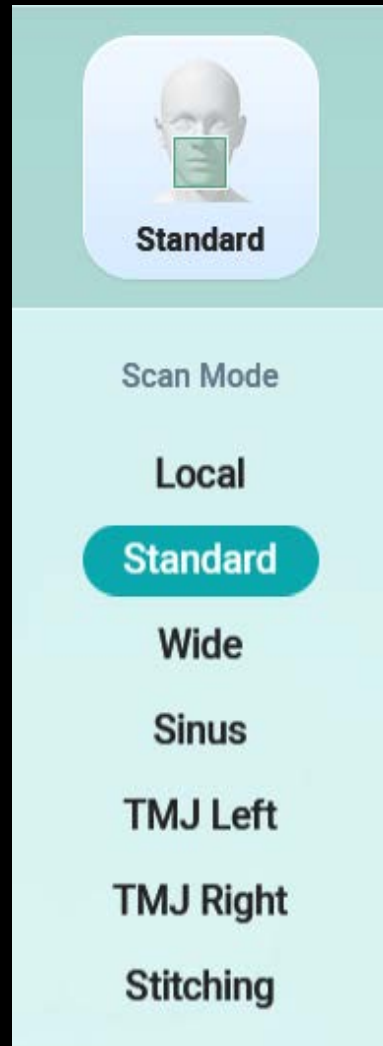
Sinus

TMJ Left

TMJ Right

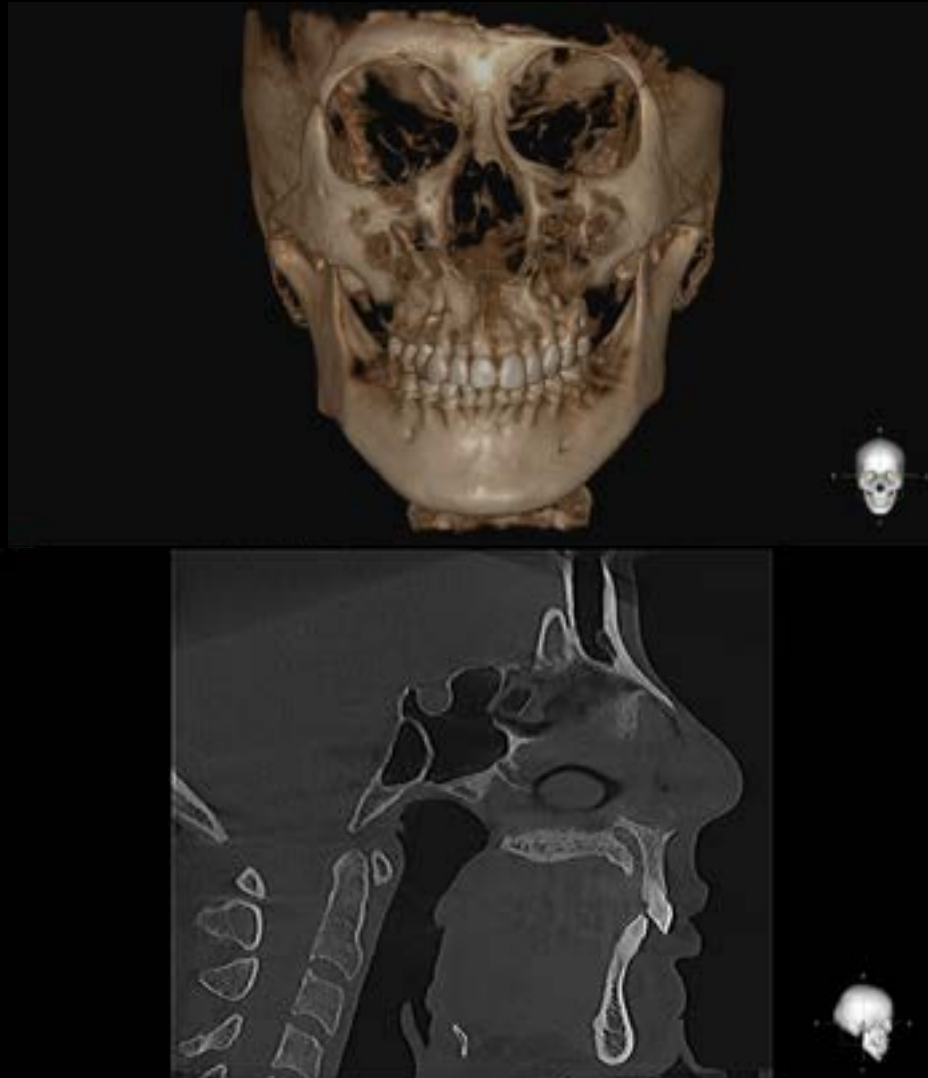
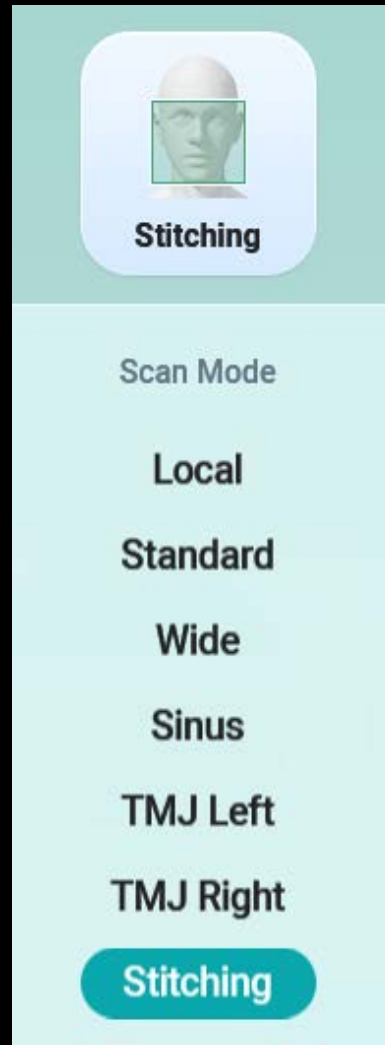
Stitching

# bright CT - Standard Mode View



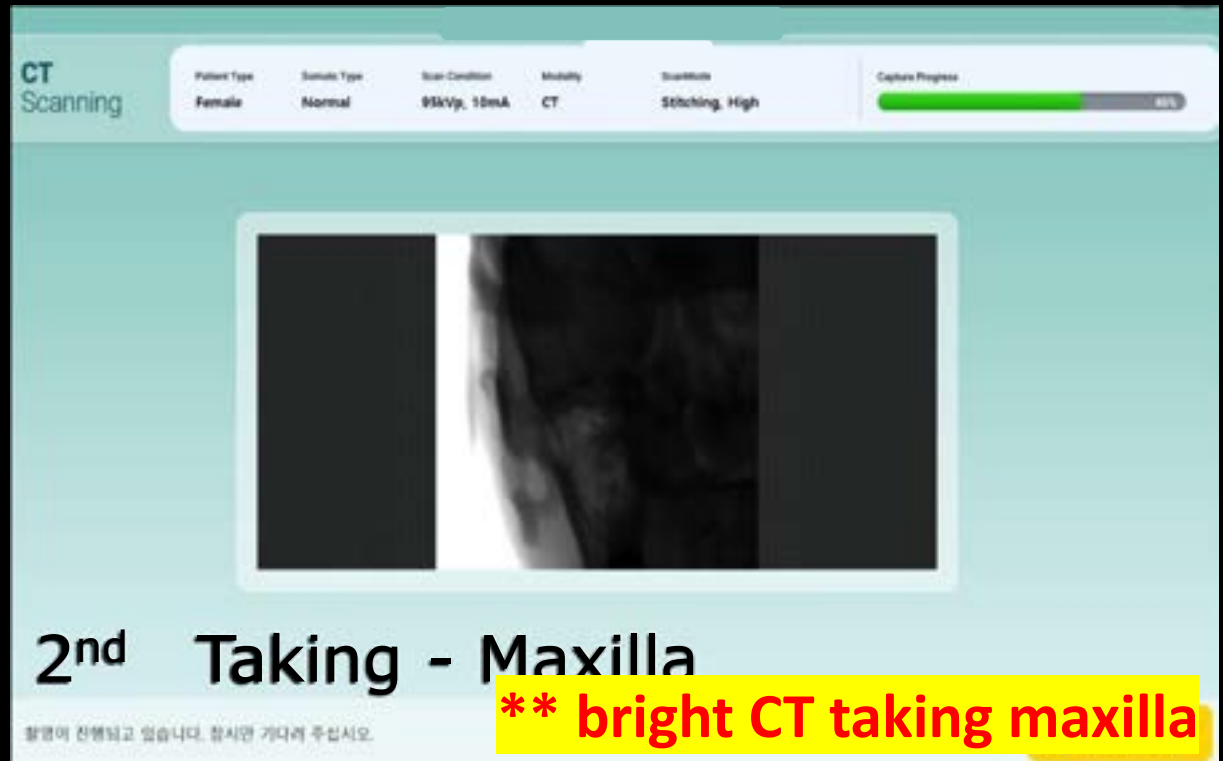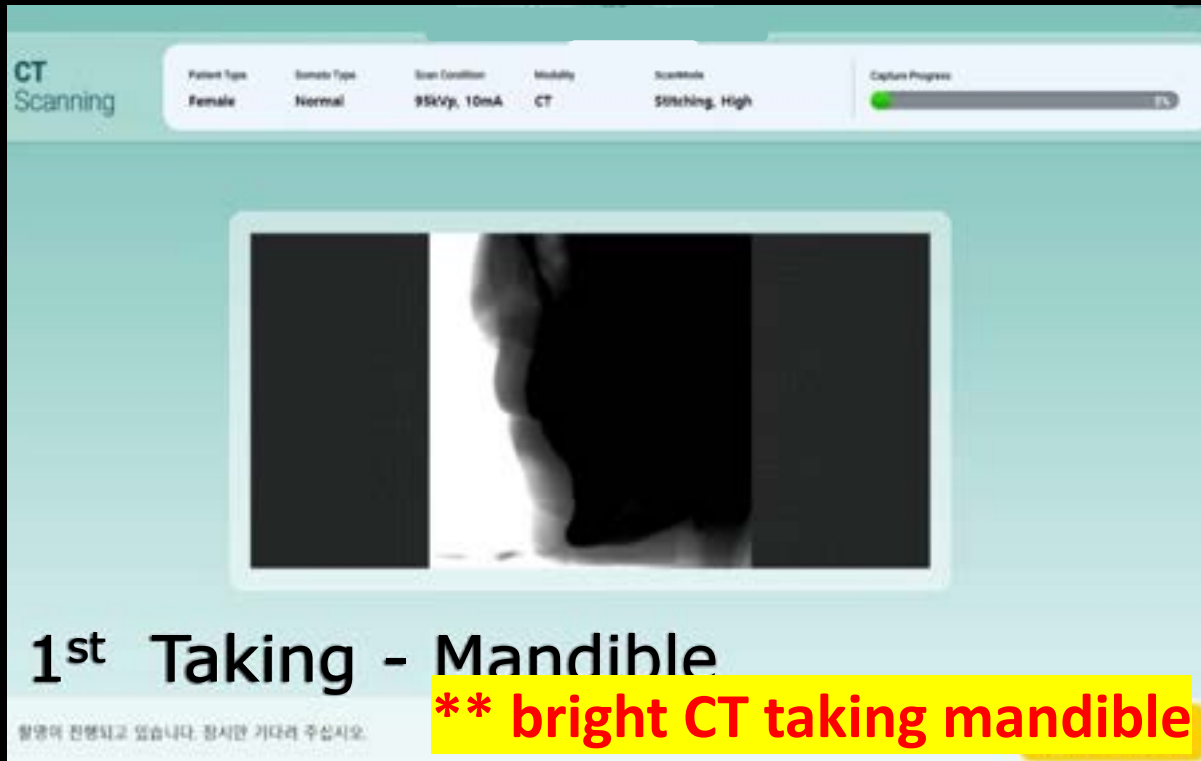Standard rest  
& tooth Bite

# bright CT - Stitching Mode View



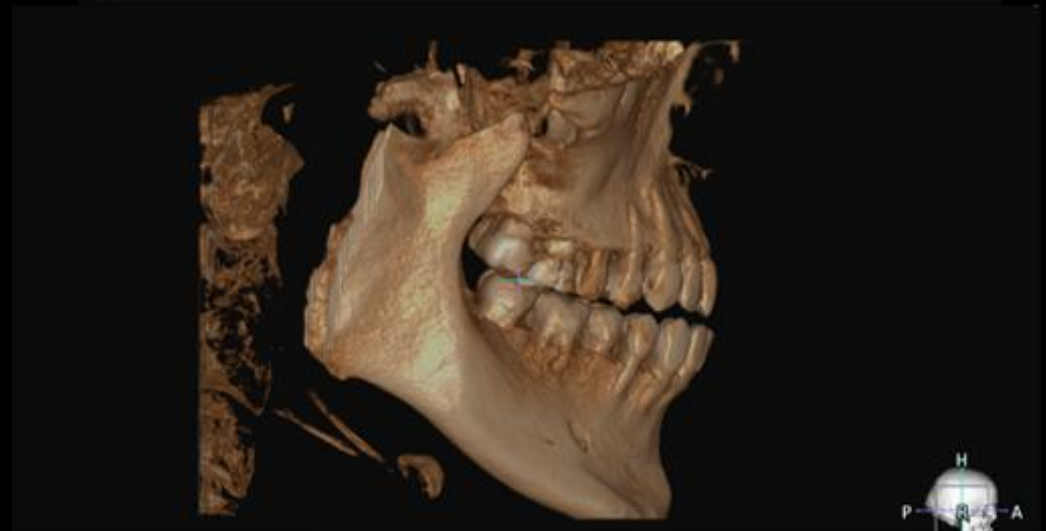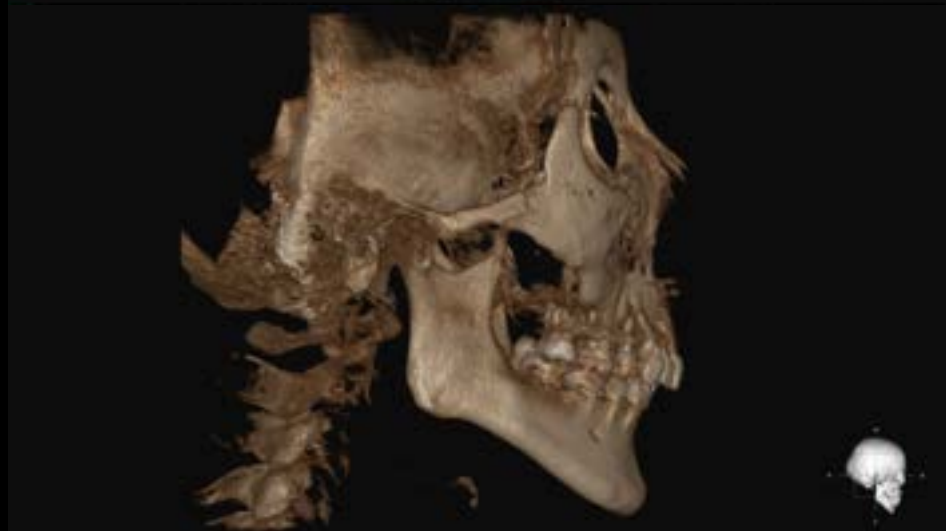
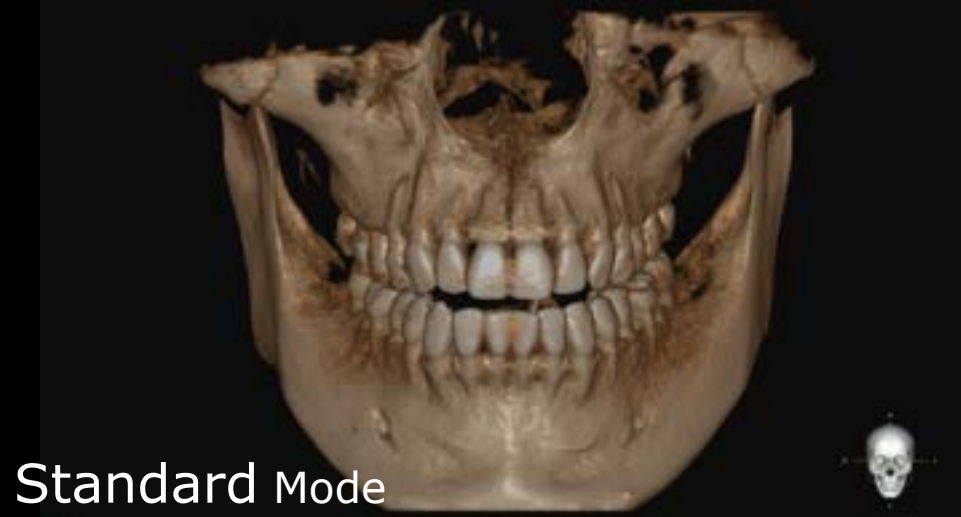# bright CT - Stitching Mode Taking

## Stitching Mode Cautions!



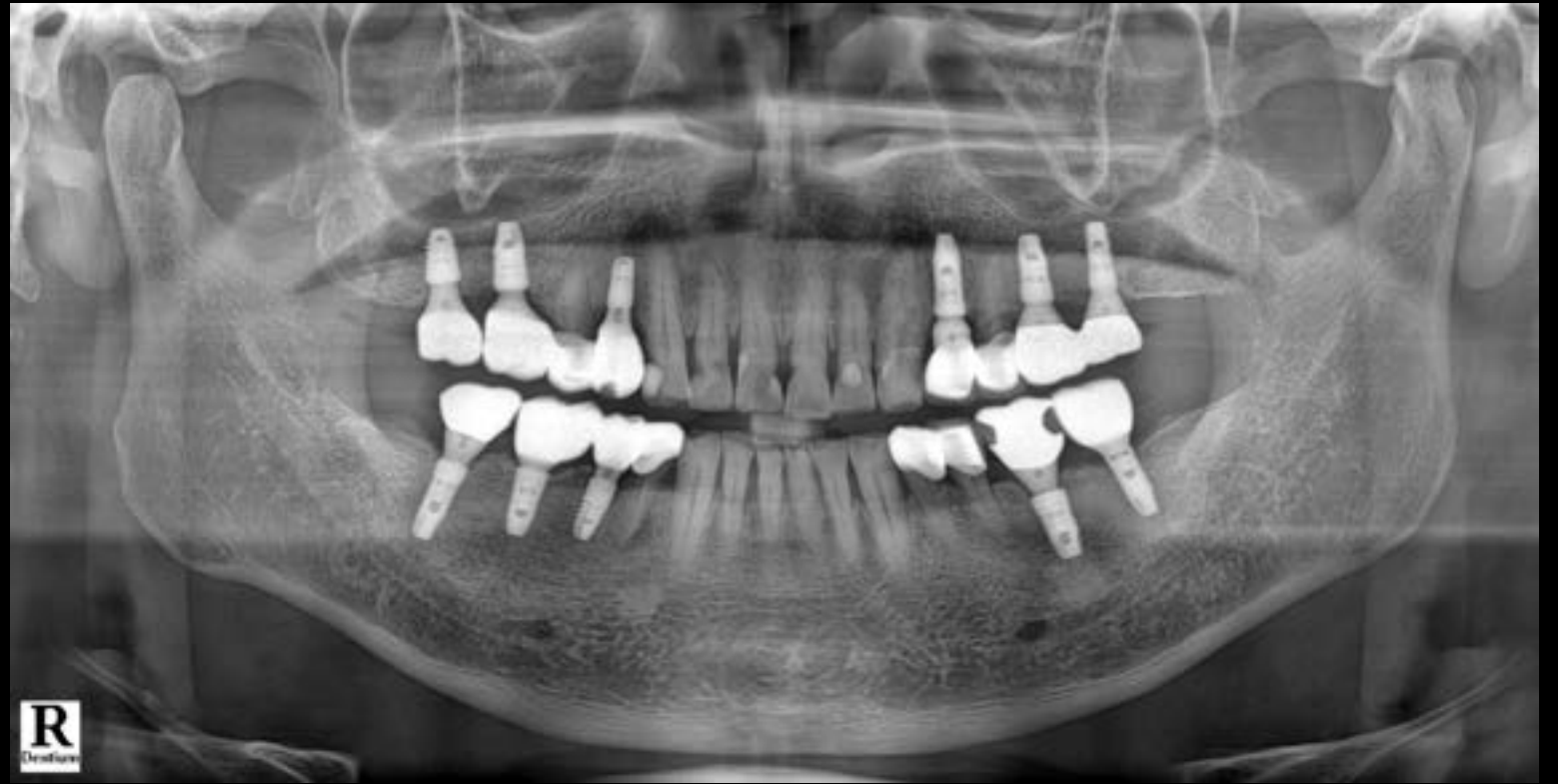

# bright CT - Stitching & Standard View 비교




# Dentium Dental Clinic Process

## PANORAMA Taking

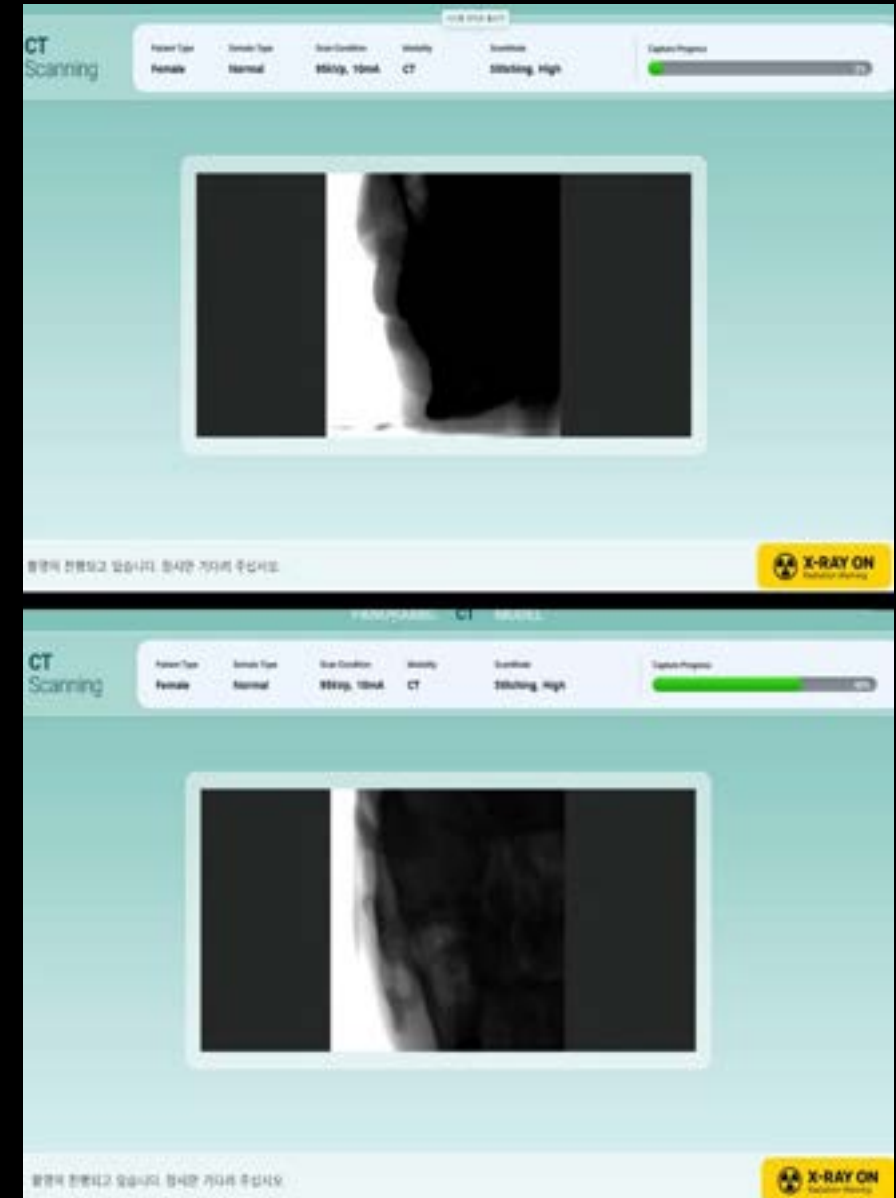
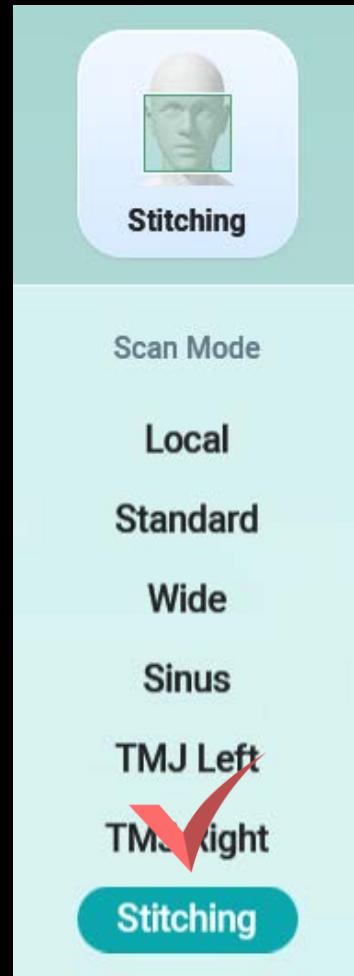


# Dentium Dental Clinic Process

PANORAMA Taking



CT Taking  
(Stitching Mode)



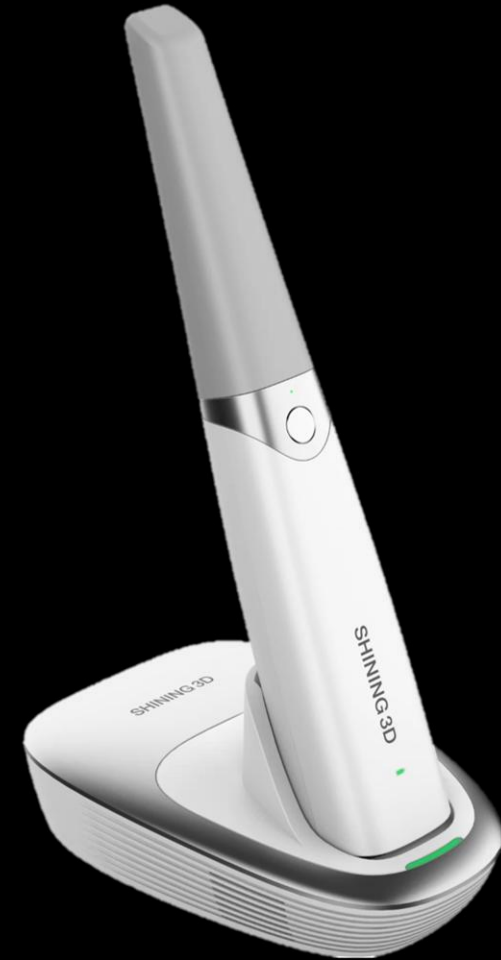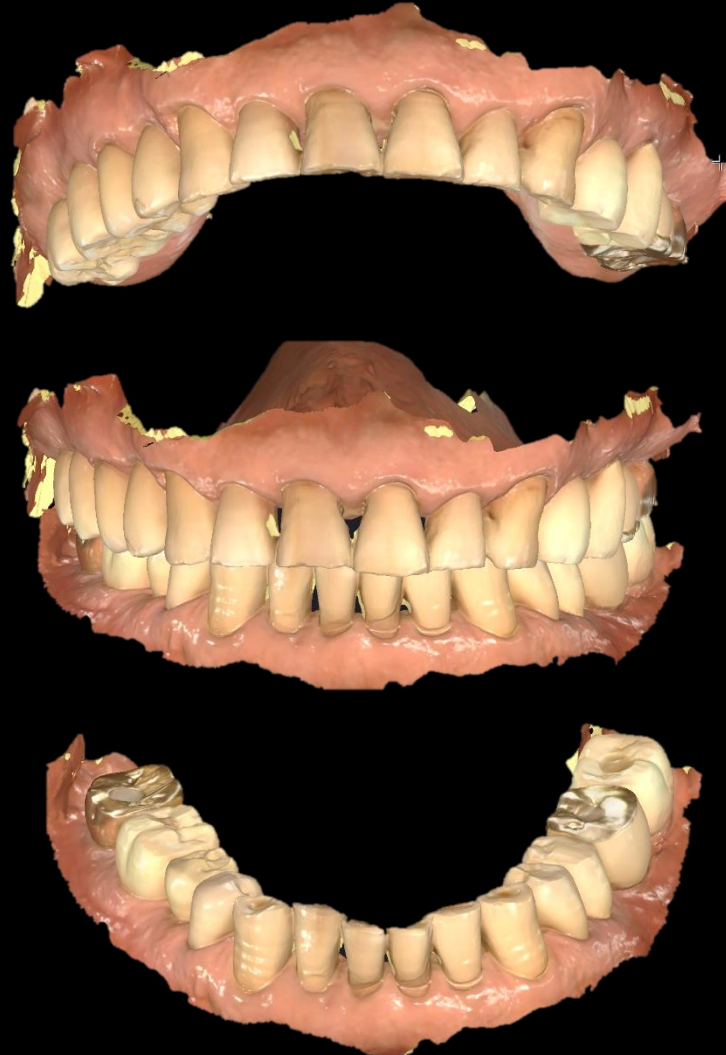


# Dentium Dental Clinic Process

PANORAMA Taking



CT Taking  
(Stitching Mode)  
&  
IOS



Aoralscan3 Wireless

# Dentium Dental Clinic Process

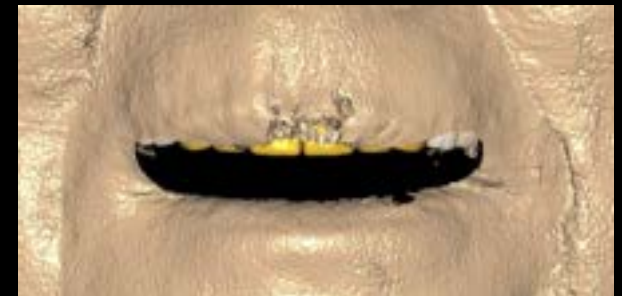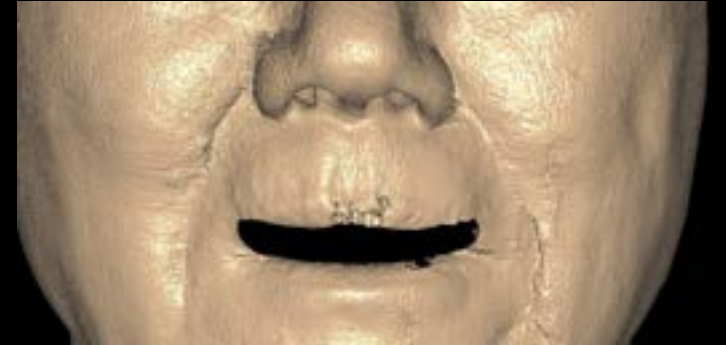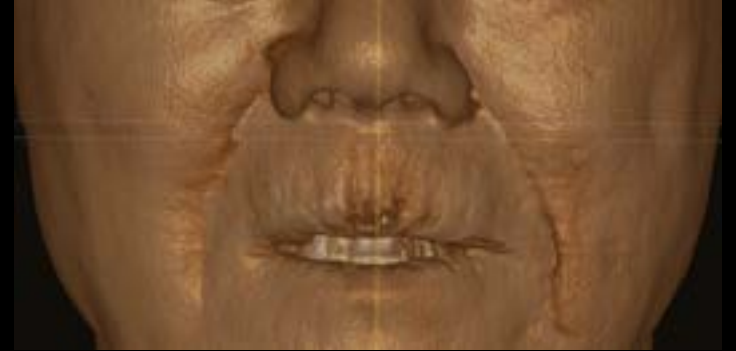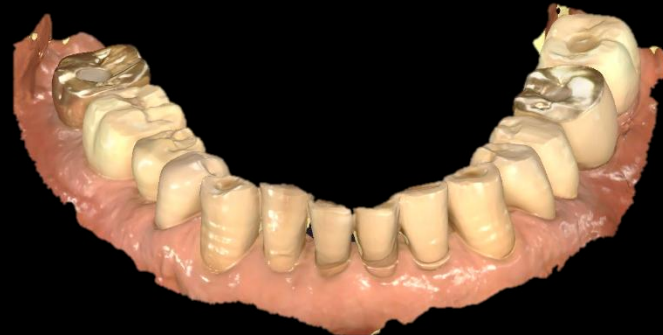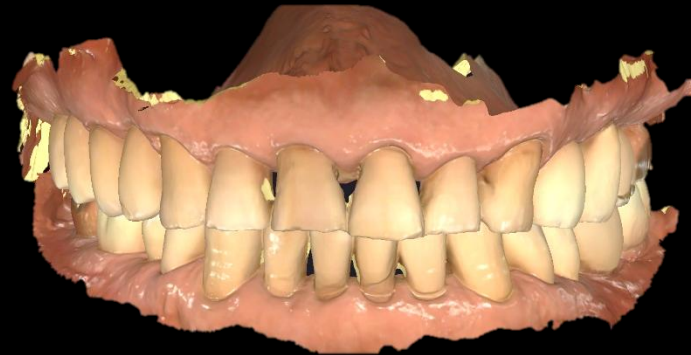
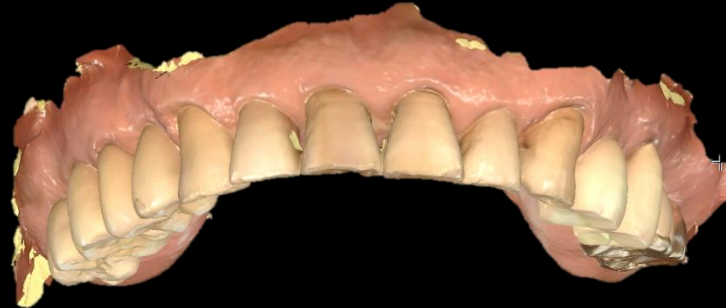PANORAMA Taking



CT Taking  
(Stitching Mode)  
&  
IOS



Virtual Set-up  
&  
Consultation



# Dentium Dental Clinic Process

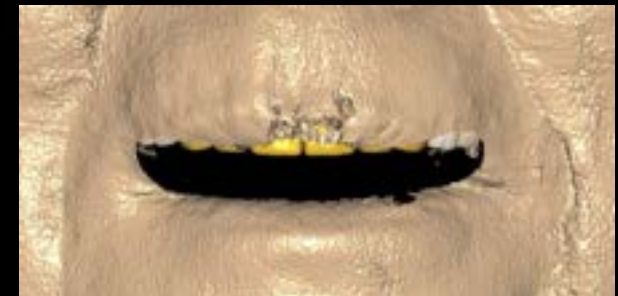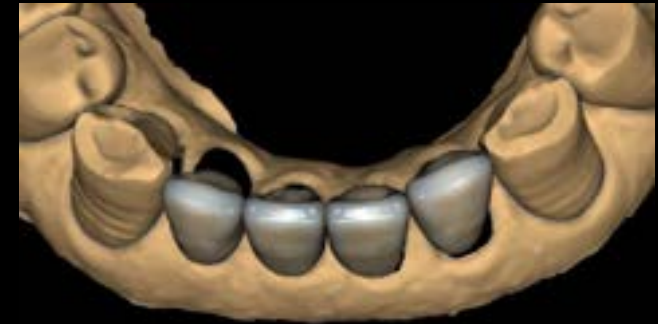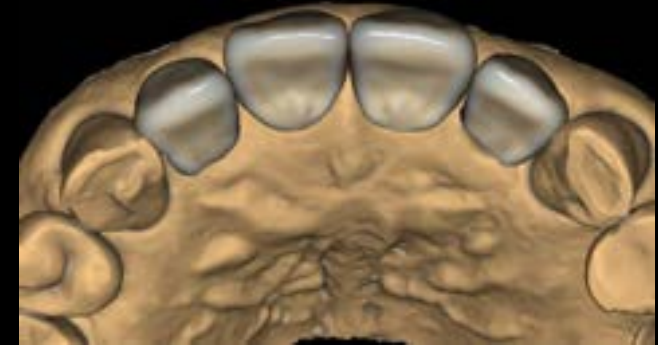
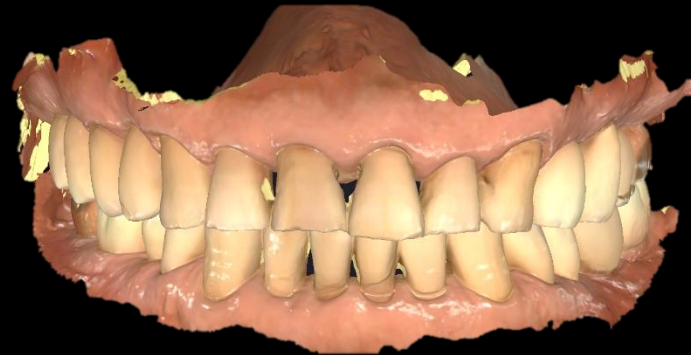
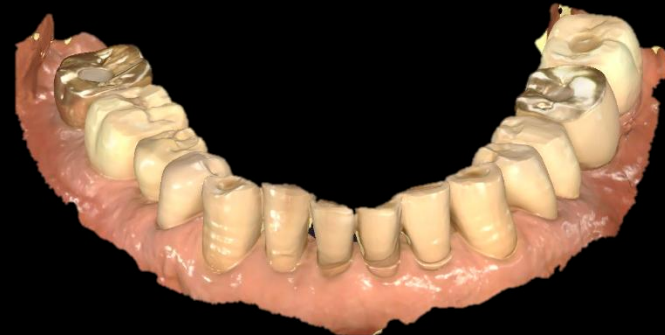PANORAMA Taking



CT Taking  
(Stitching Mode)  
&  
IOS




Virtual Set-up  
&  
Consultation






# Dentium Dental Clinic Process

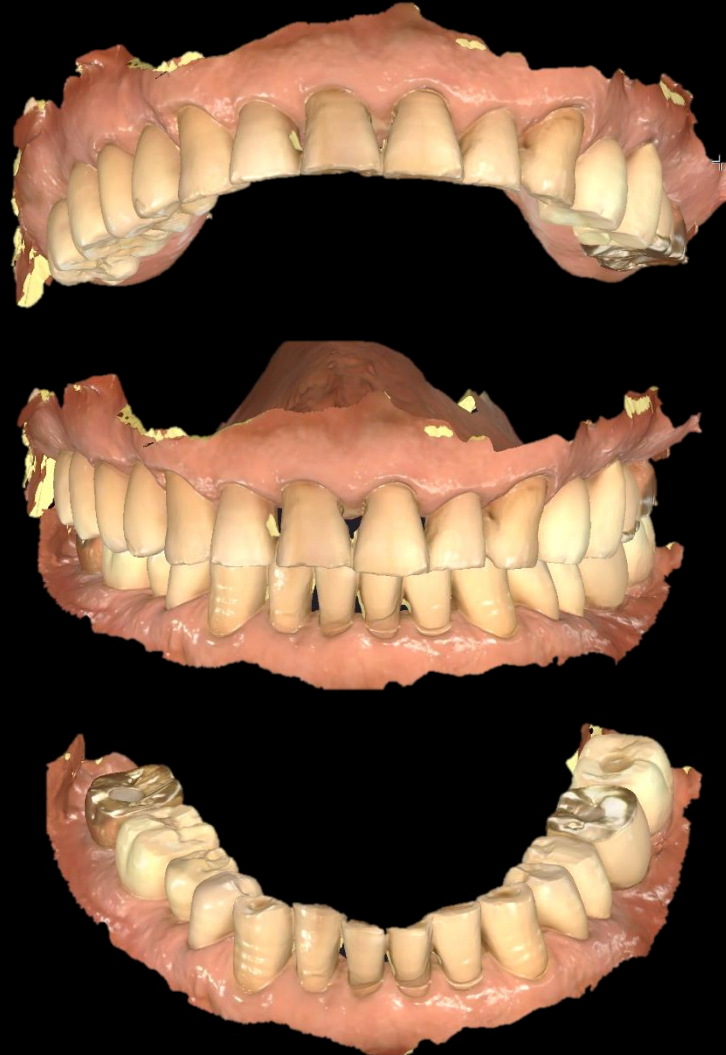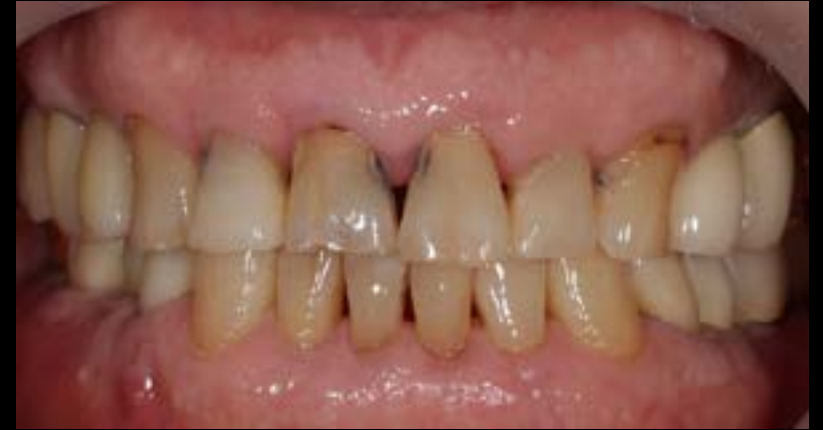
PANORAMA Taking



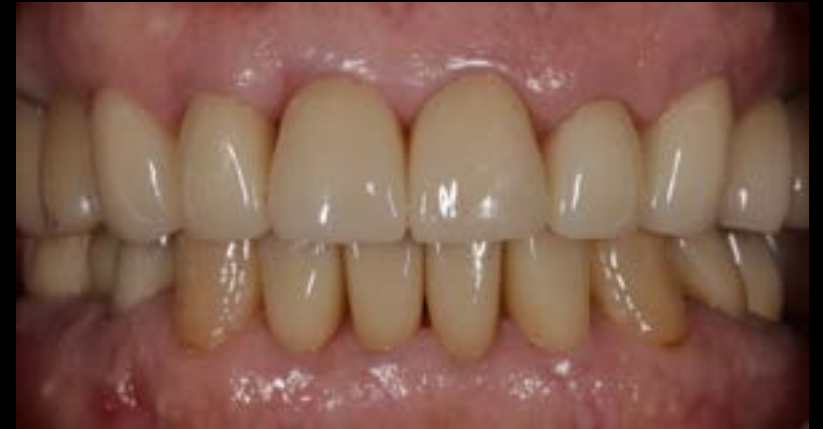CT Taking  
(Stitching Mode)  
&  
IOS



Esthetic Prosthesis  
Treatment



Pre - OP



Permanent Crown

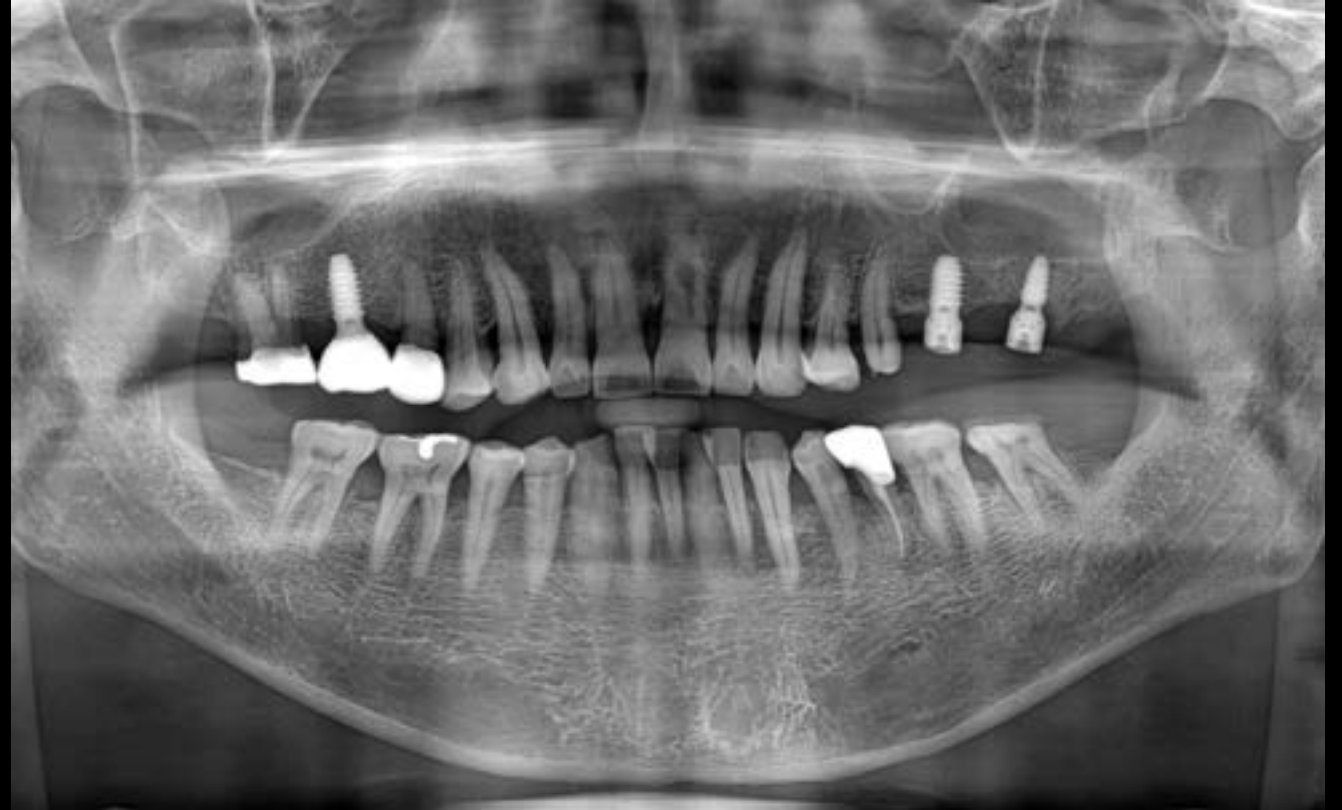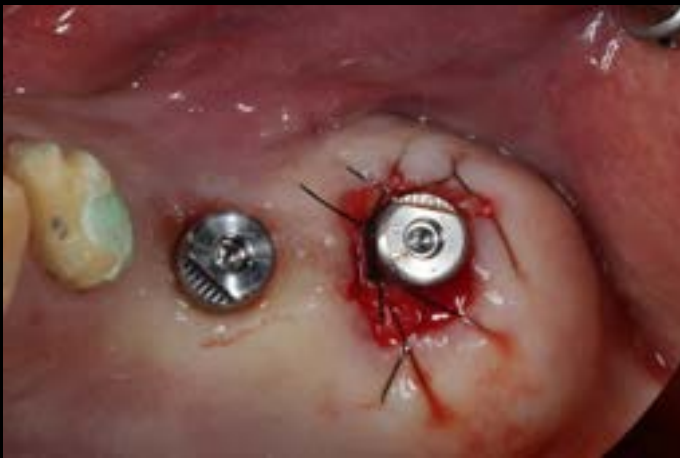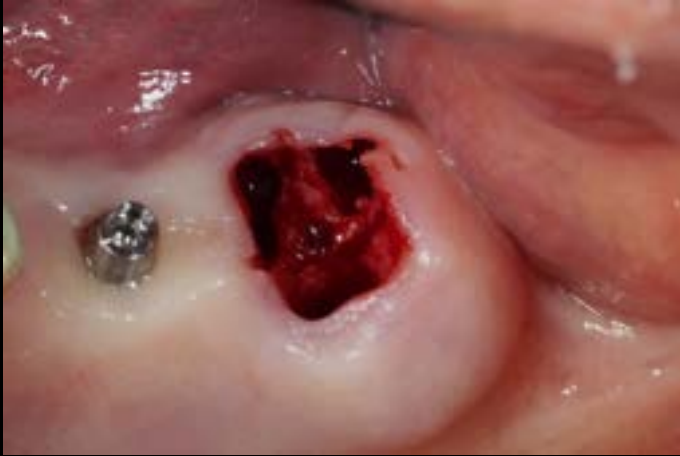# Dentium Dental Clinic

## Clinical Case & CT Applications Guide



# IOS Clinical Case

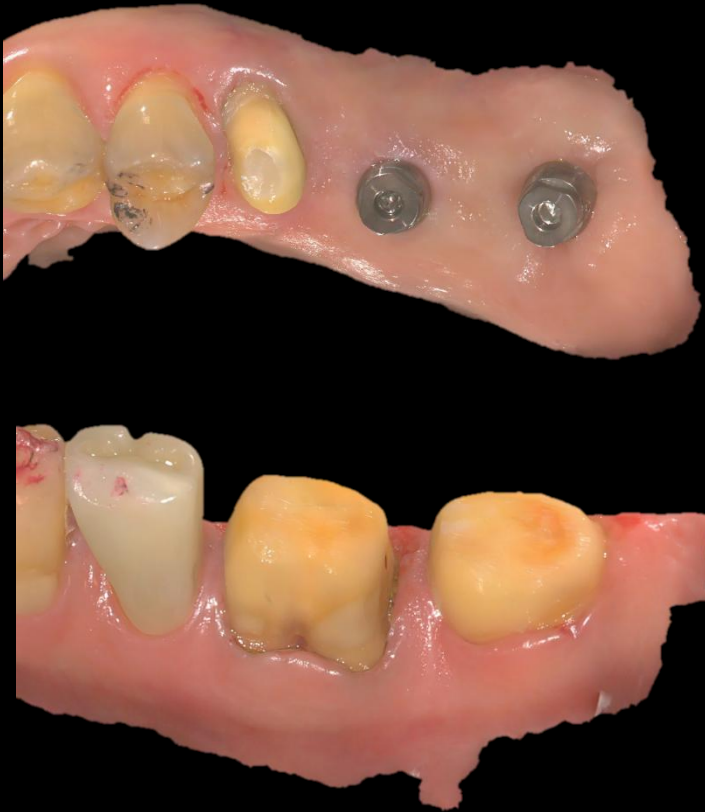## Implant Surgery



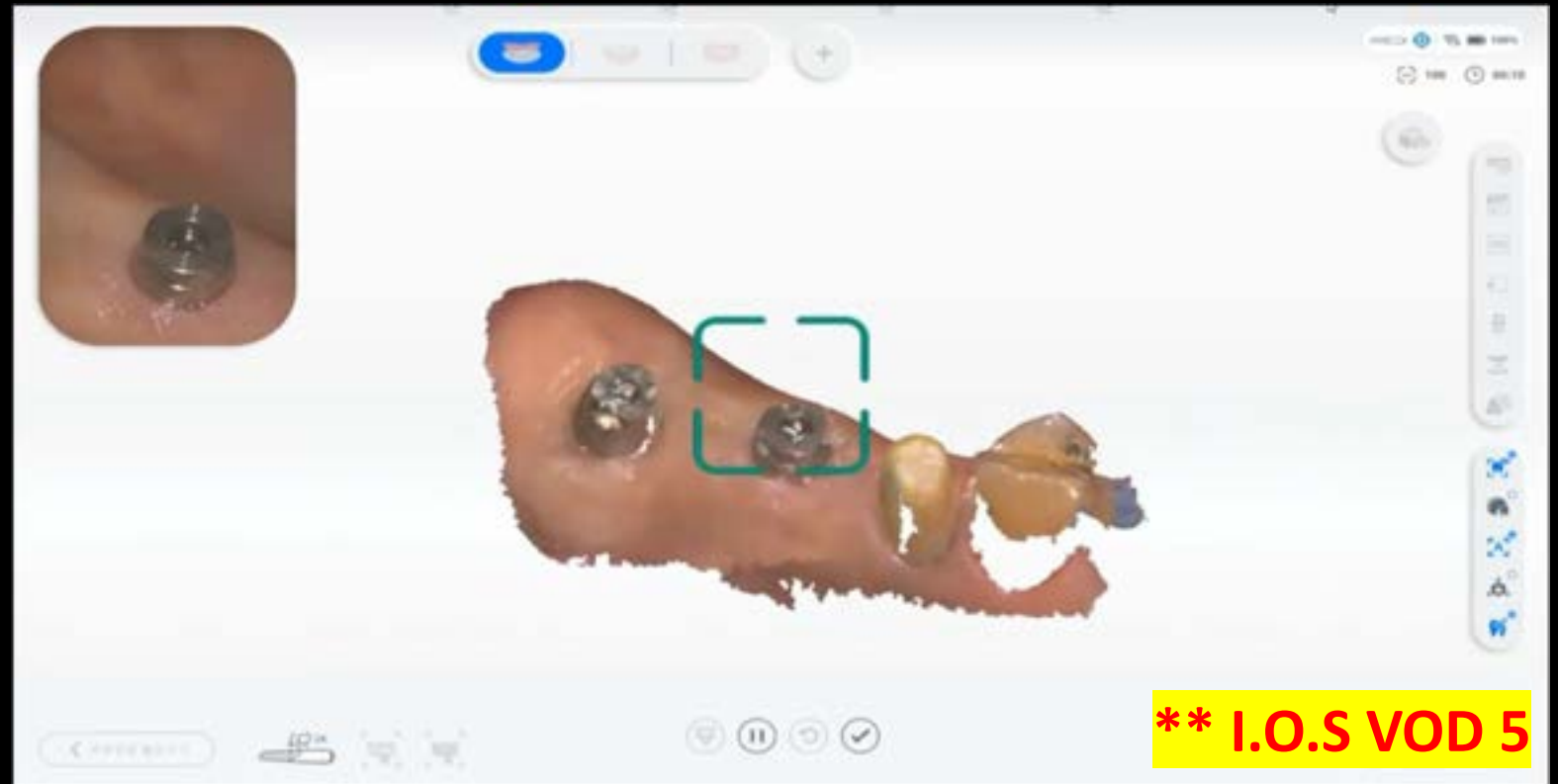
#26 bright Tissue Level (Ø4.5 X 7.0)  
#27 bright Tissue Level (Ø3.5 X 7.0)

# IOS Clinical Case

## Preparation & IOS



Preparation



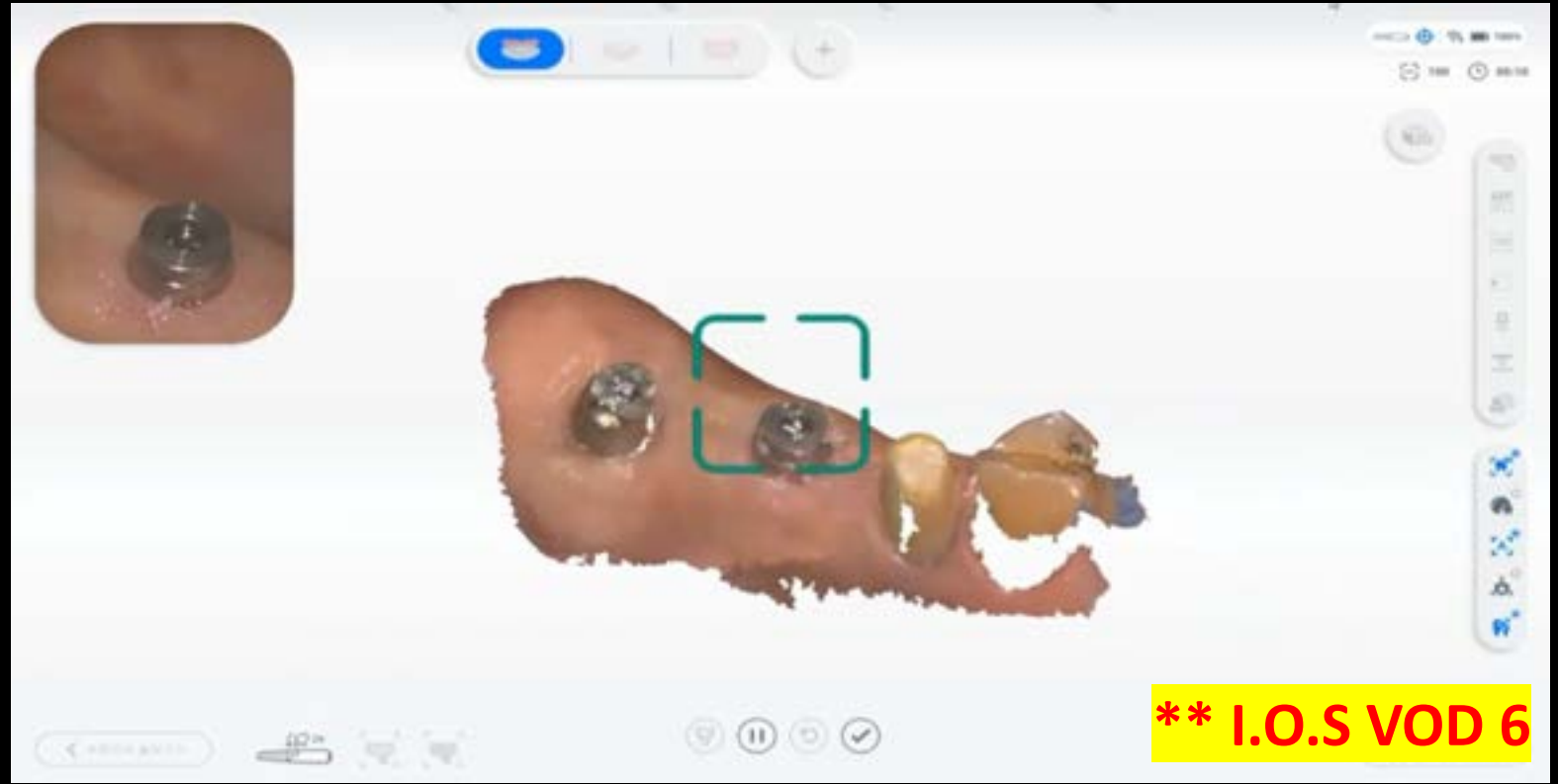
**SCAN** (w. Aoralscan3 Wireless)

# IOS Clinical Case

## Preparation & IOS



Preparation

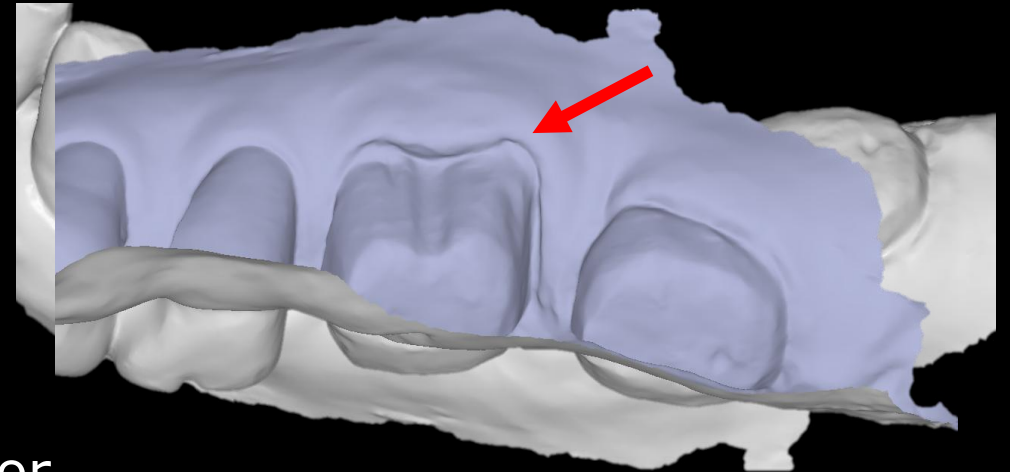
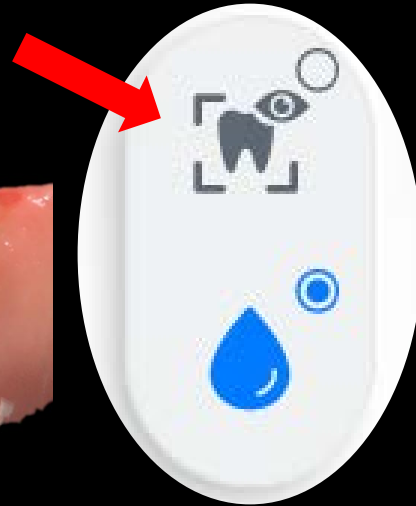
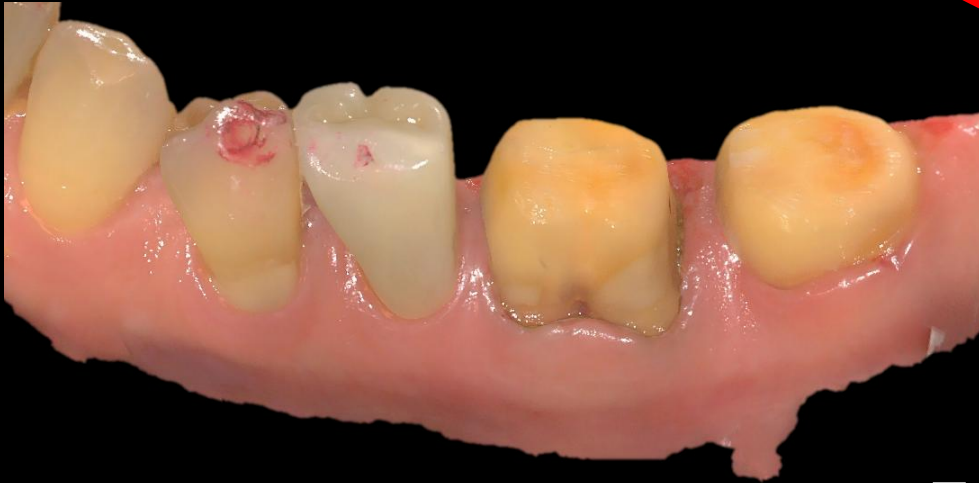
**SCAN** (w. Aoralscan3 Wireless)



# IOS Clinical Case

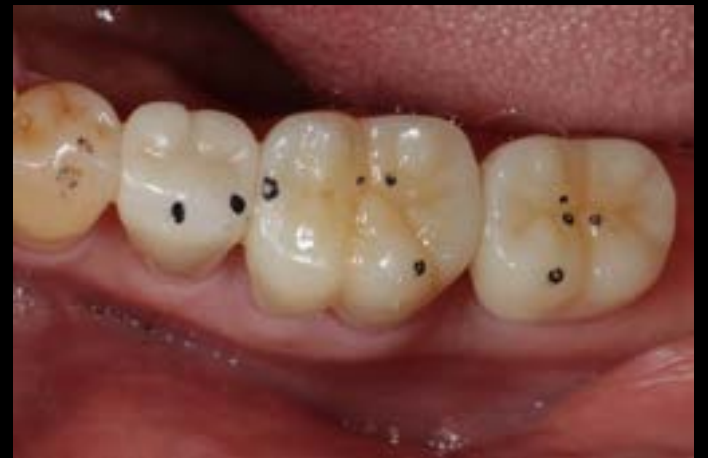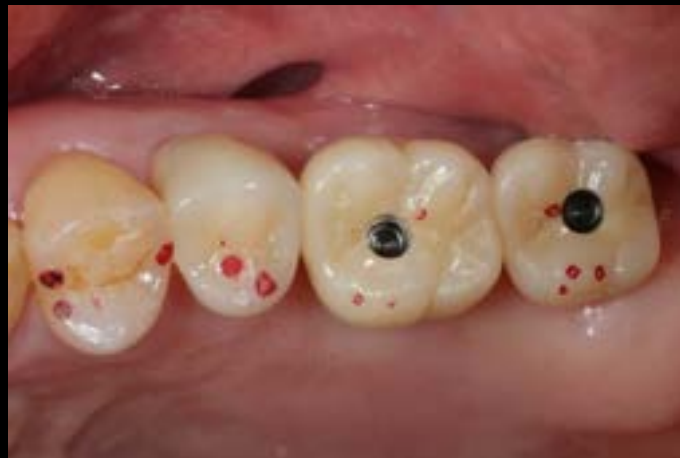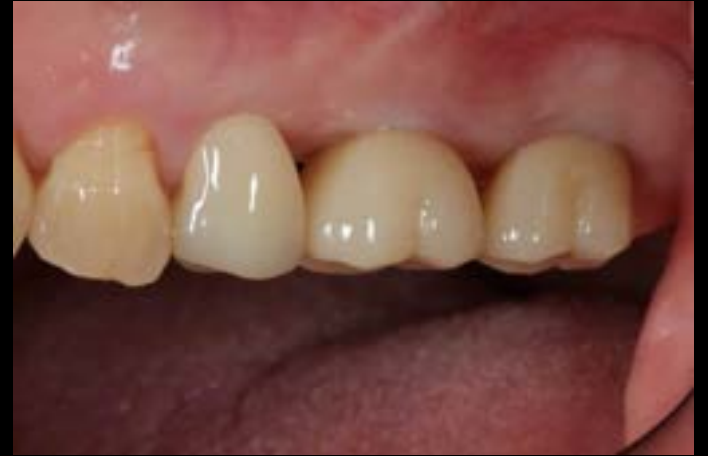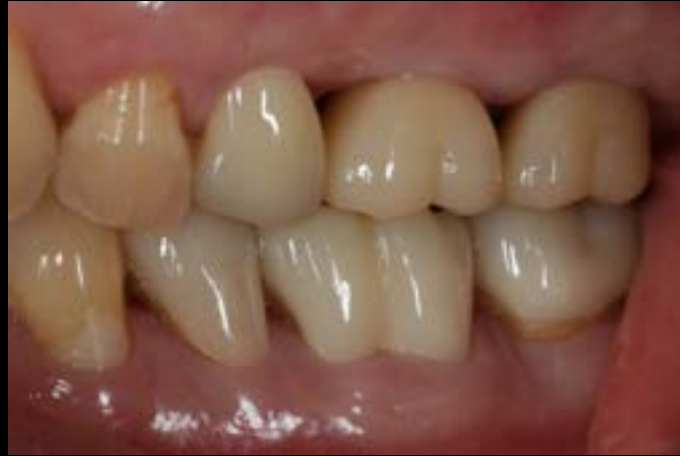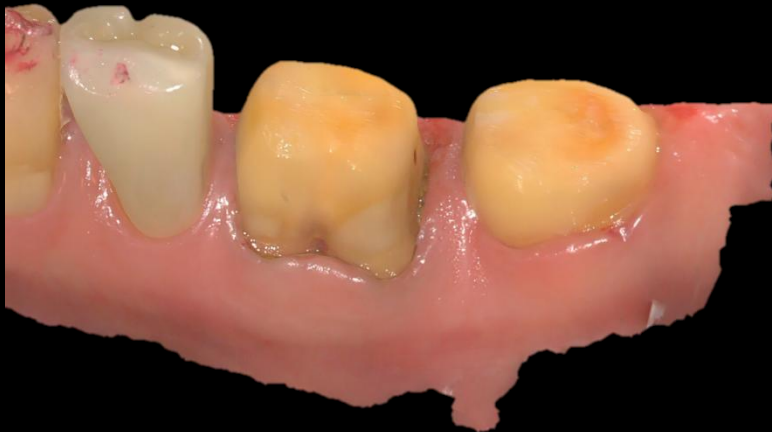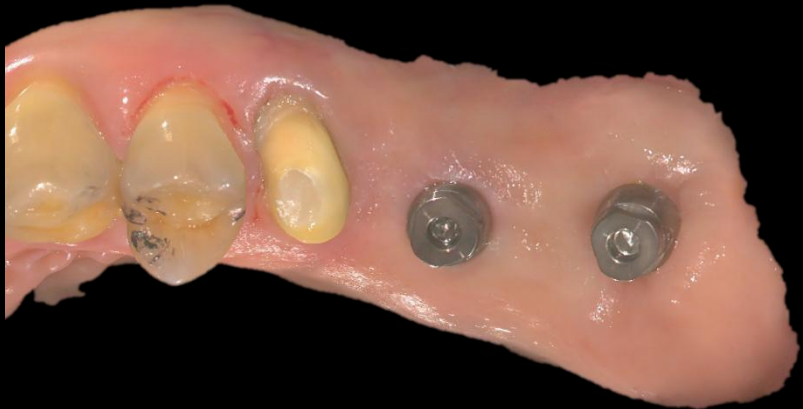
## Preparation & IOS



Turn off data color

# IOS Clinical Case

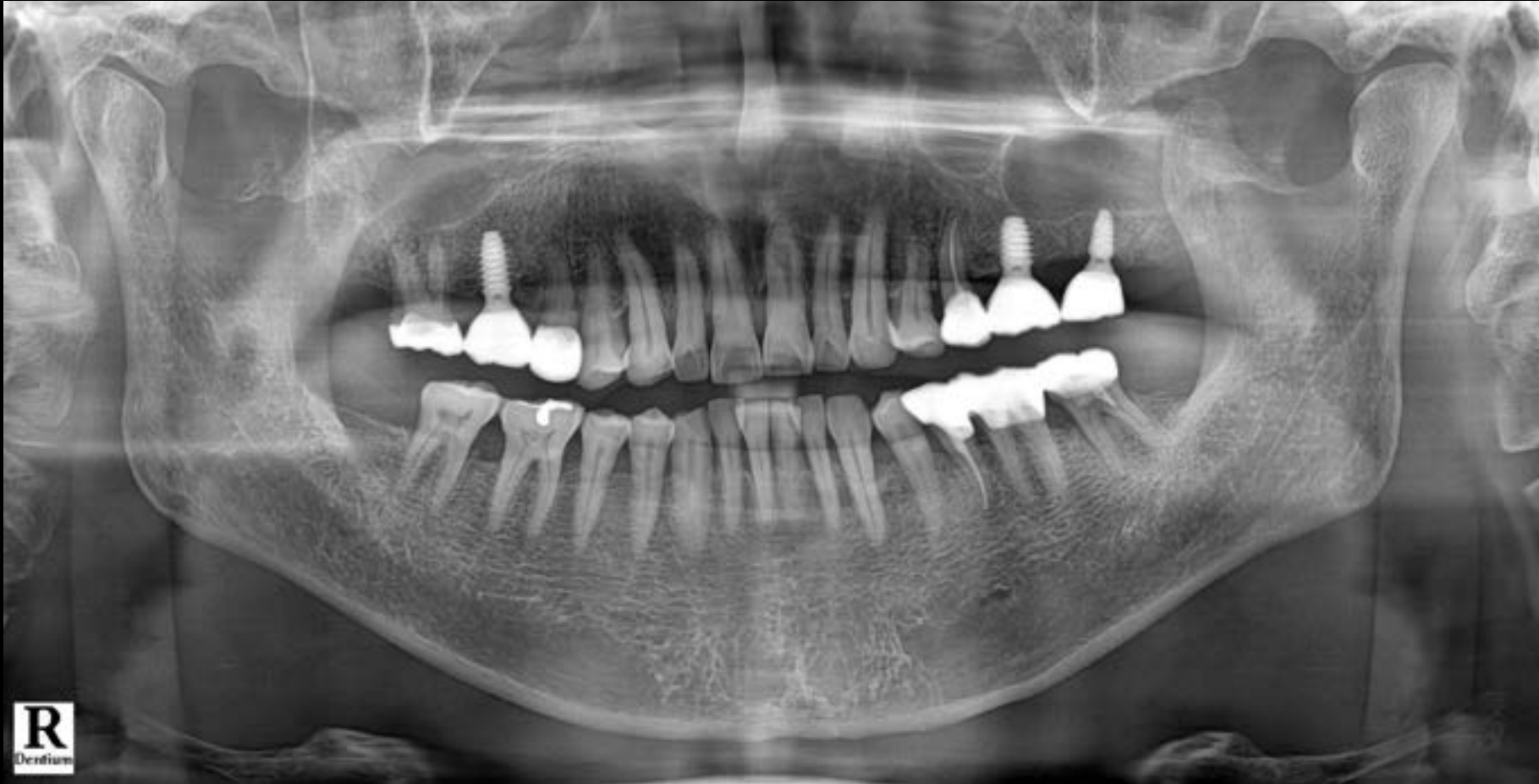## IOS for Abutment & Zirconia



Zirconia DEL

# IOS Clinical Case

## Panorama



# BOS Clinical Case w.BTS

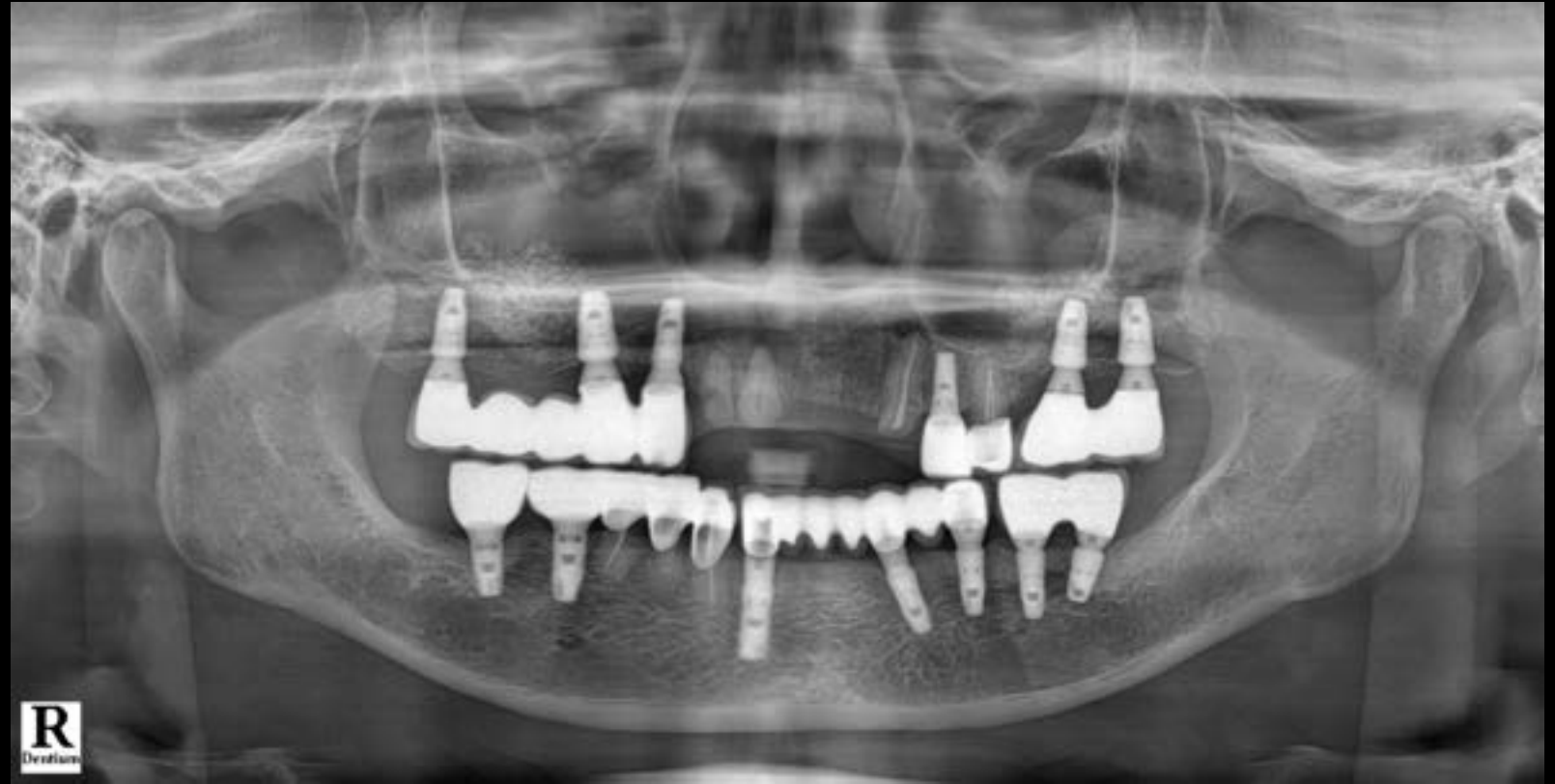Age: 70s / F

CC : Maxillary Anterior Area

Implant Consultation and  
Treatment Planning

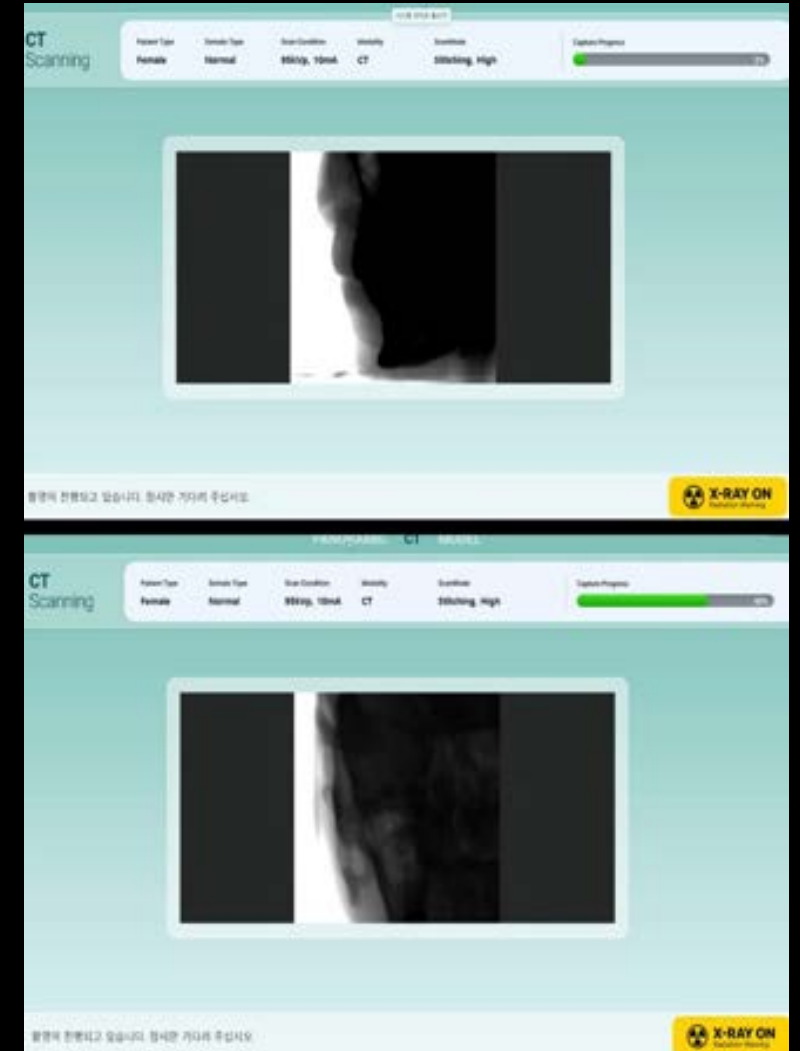
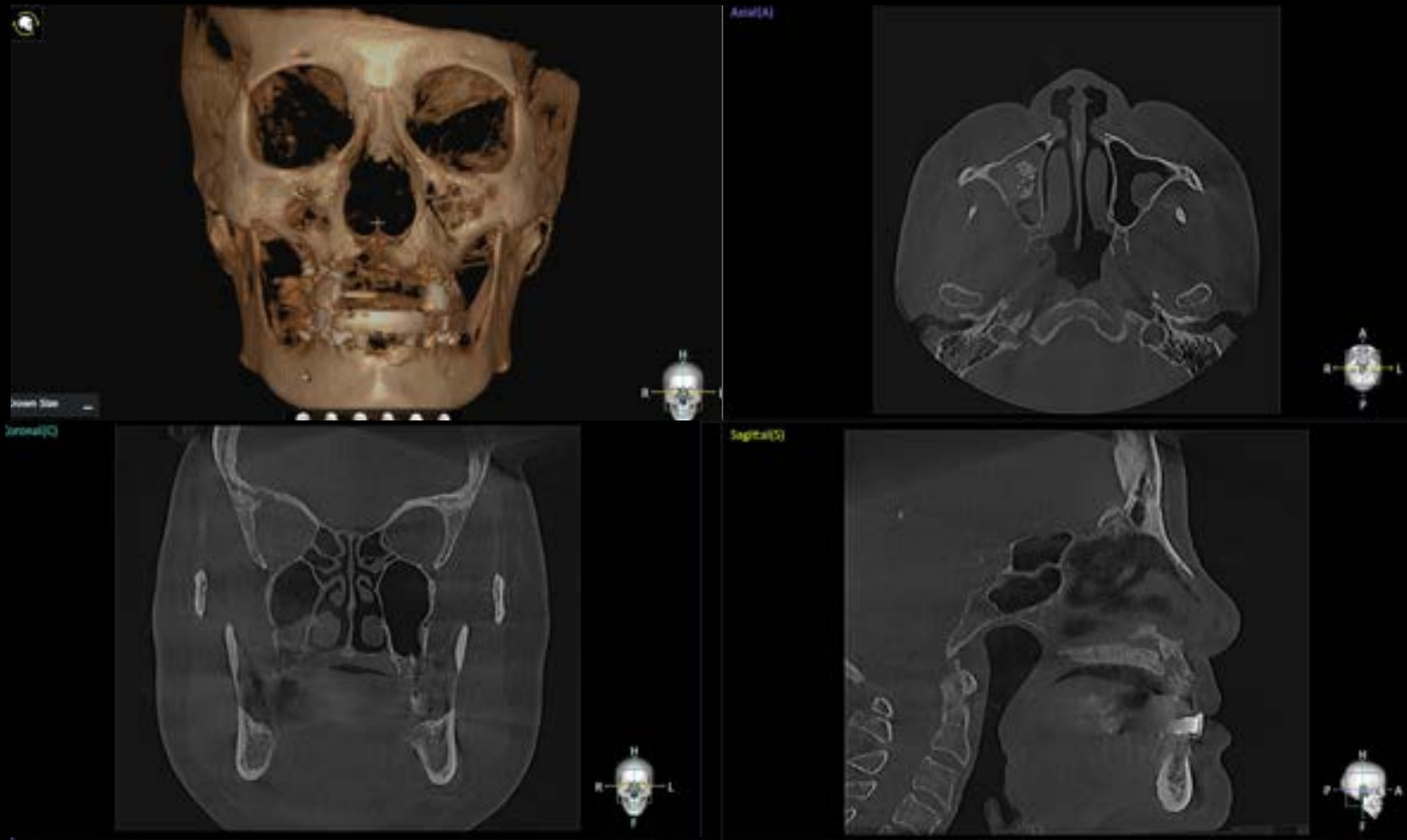
Plan) 2 1 | 3

Root Rest EXT & Implant Surgery



# BOS Clinical Case w.BTS

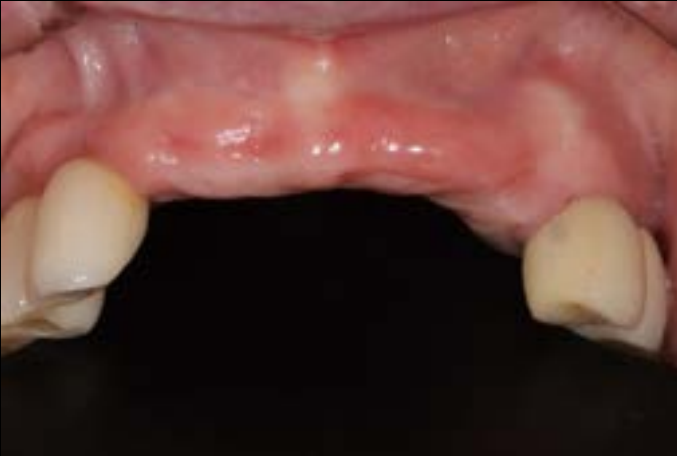## CT Scan (Stitching Mode)



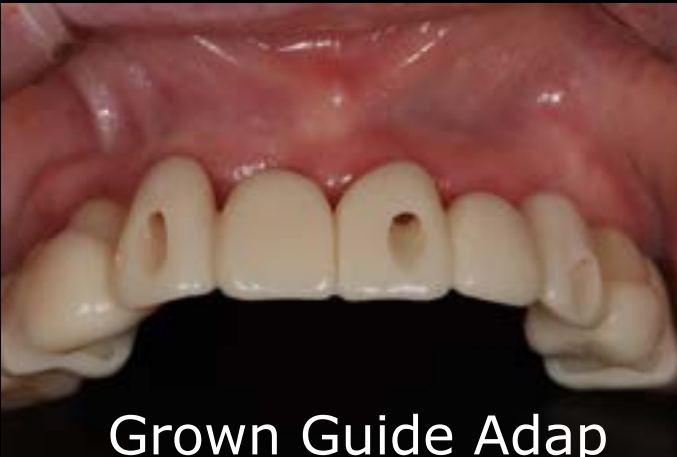

# BOS Clinical Case w.BTS

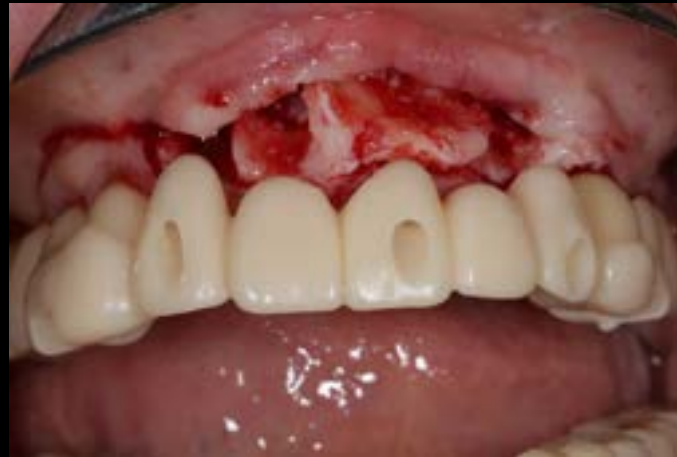## Implant Surgery



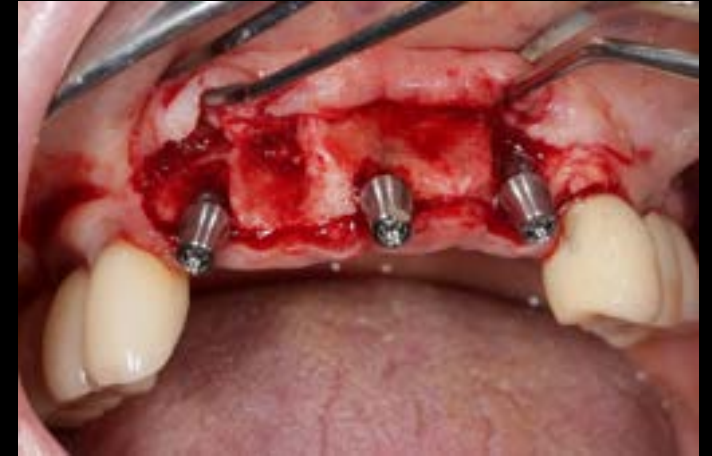Pre - OP



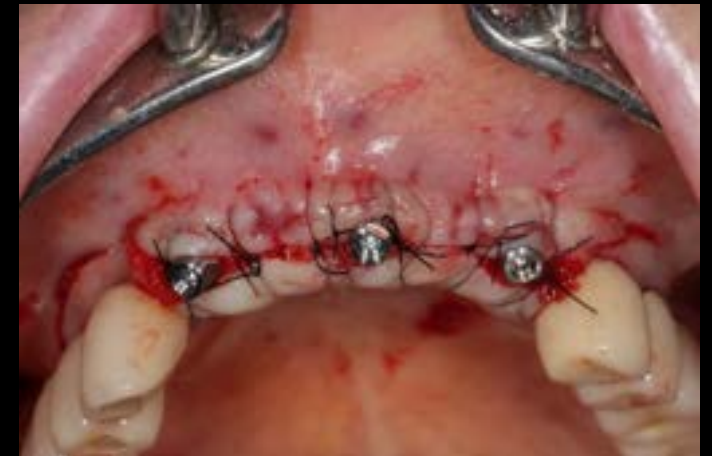Grown Guide Adap



bright TL (Ø2.5 X 11.0)

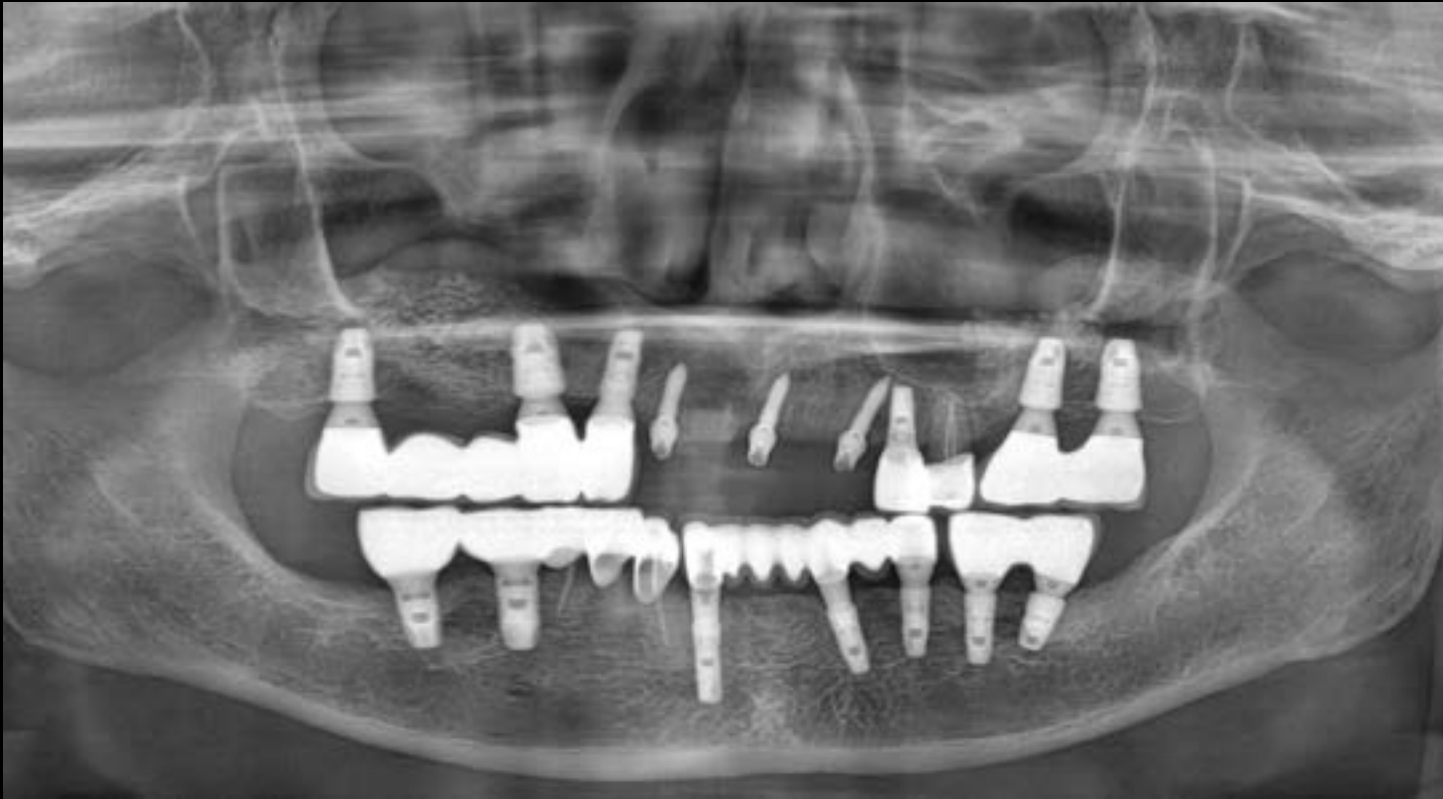

**T**issue Level



# BOS Clinical Case w.BTS

## Implant Surgery



bright TL (Ø2.5 X 11.0)



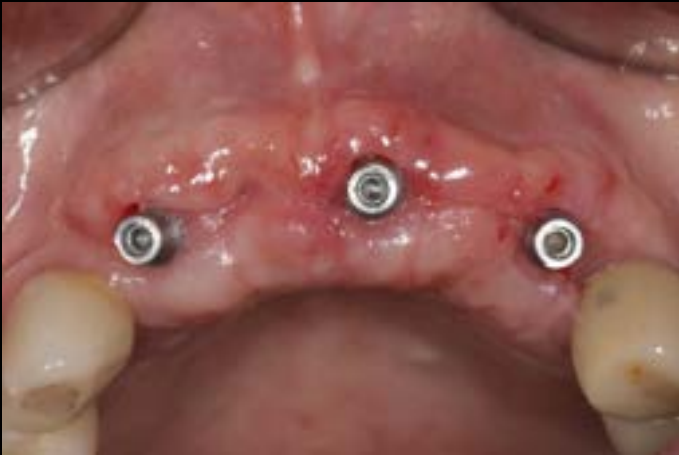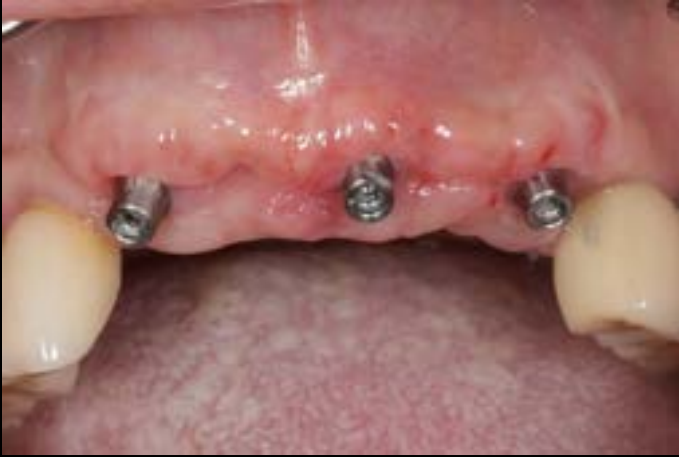**T**issue Level



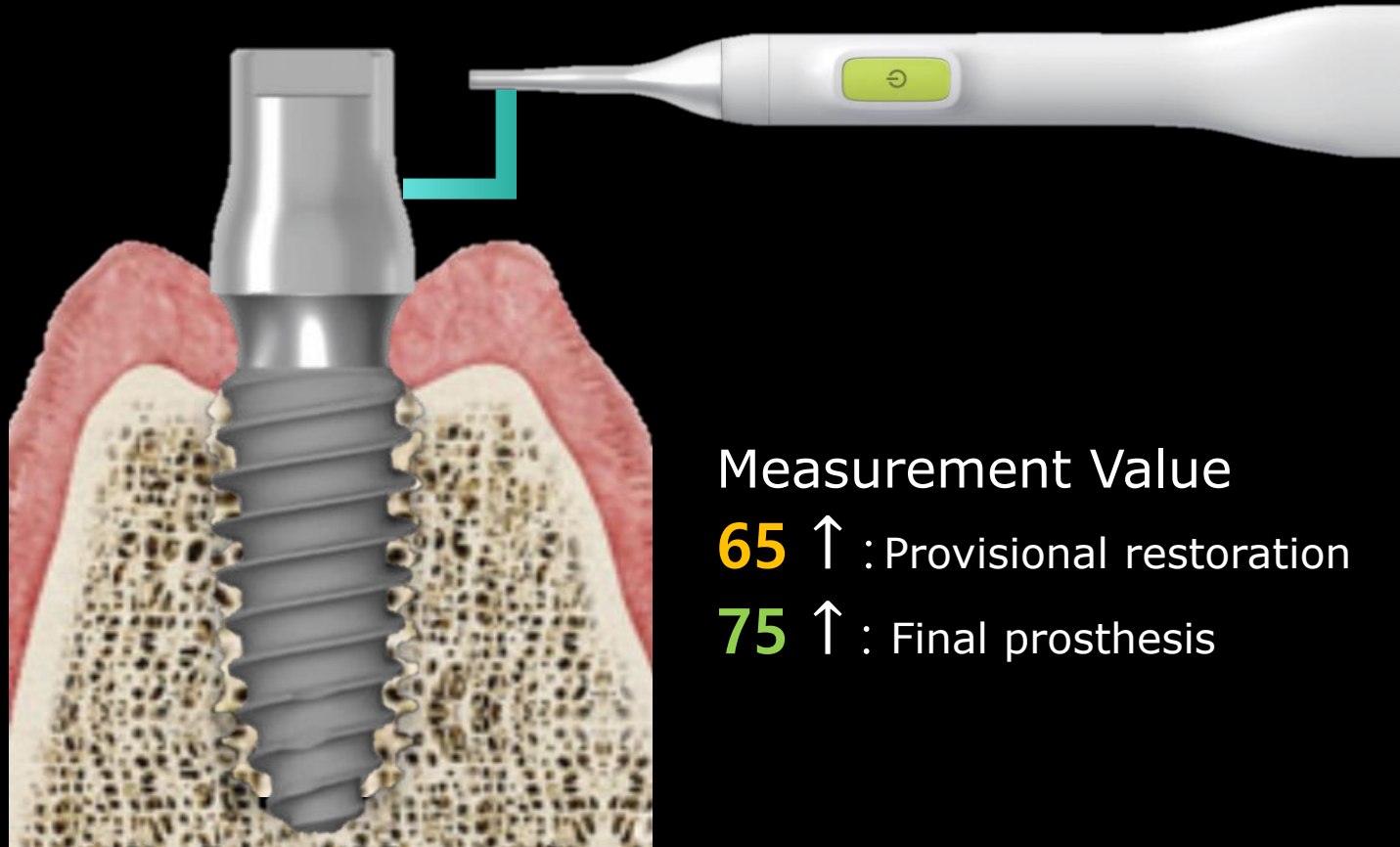


# BOS Clinical Case w.BTS

## The Trust (ISV) Measurement



Healing Photo after 20 days



Measurement Value

**65** ↑ : Provisional restoration

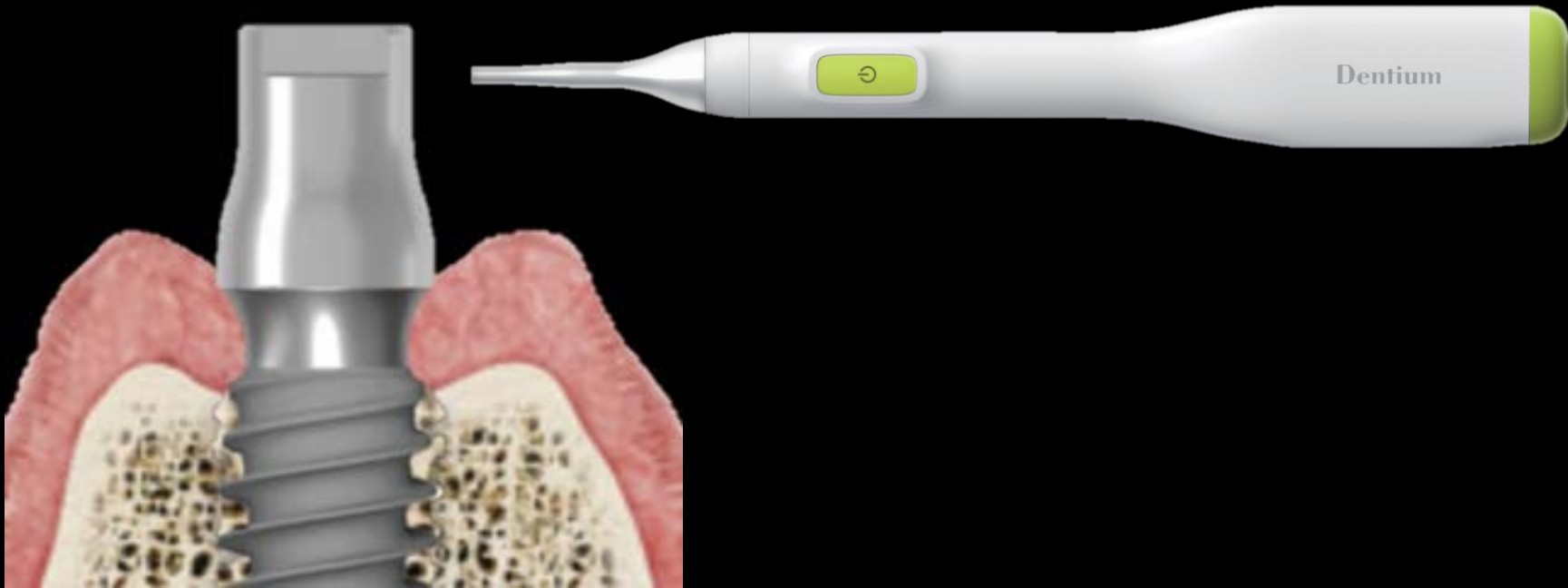**75** ↑ : Final prosthesis

# ISV (Implant Stability Value)?

Instrument for assessing implant stability and osseointegration

## the Trust

A method of measuring ISV (Implant Stability Value) by directly tapping the healing abutment without any additional attachments.

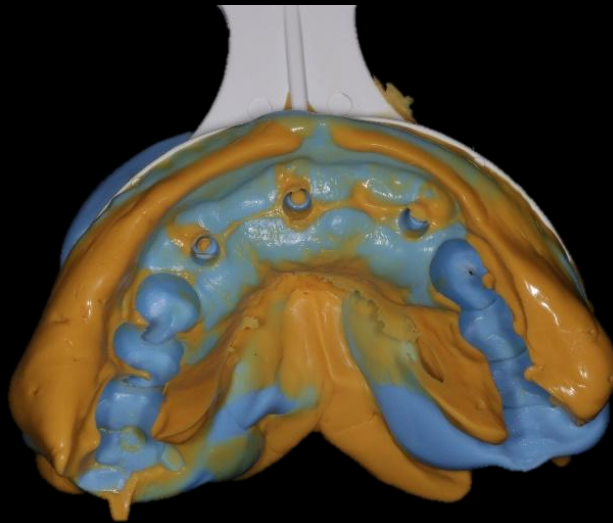


# BOS Clinical Case w.BTS

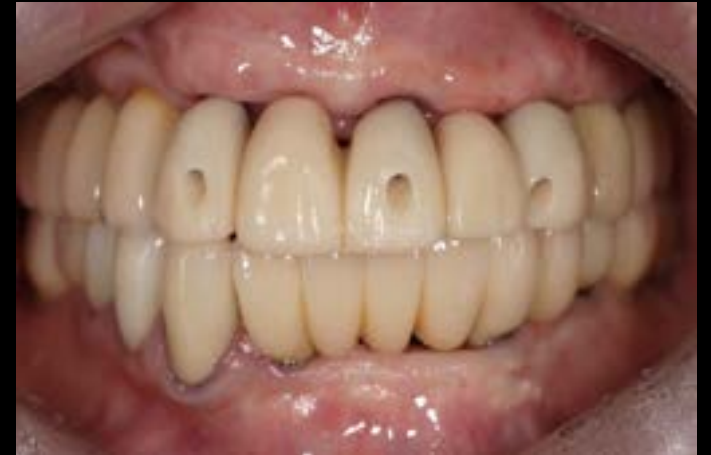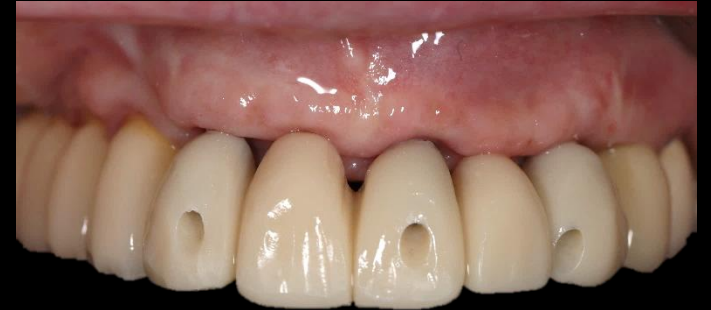**BTS** for Abutment + Temporary



Healing Photo after 20 days



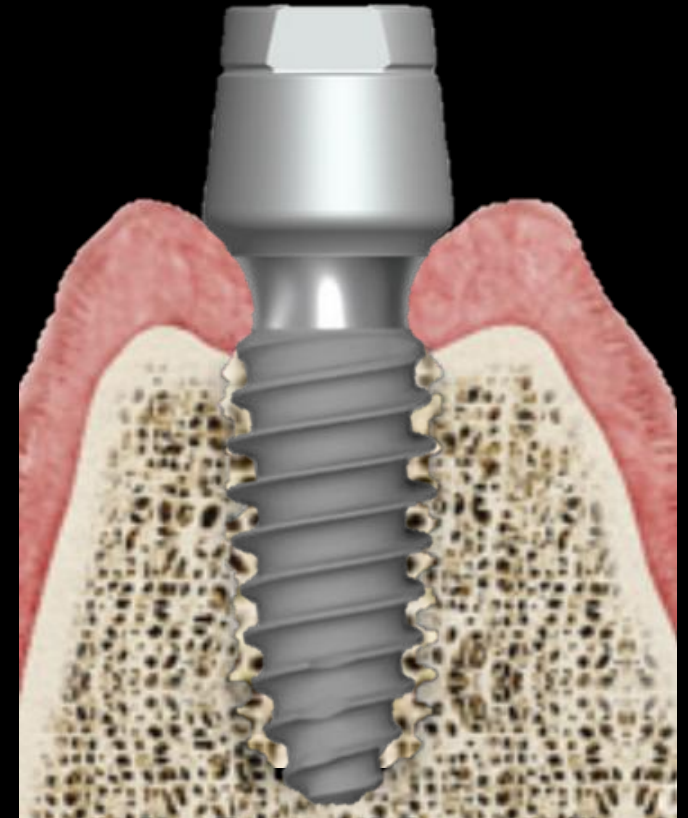
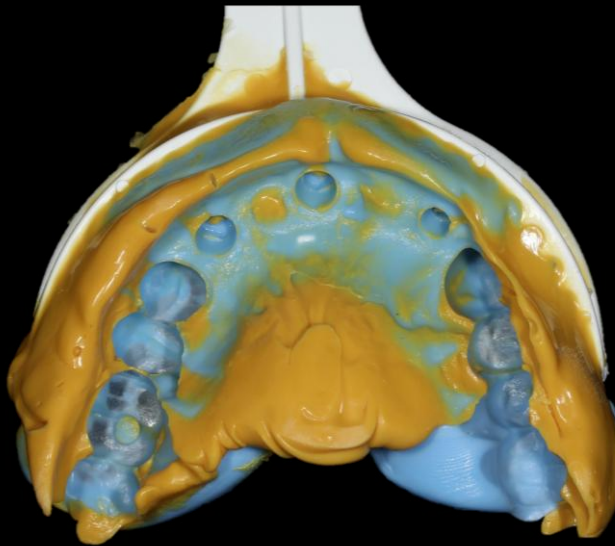
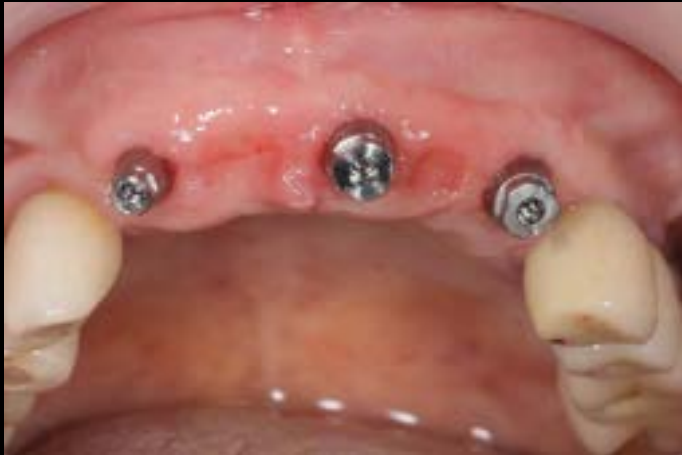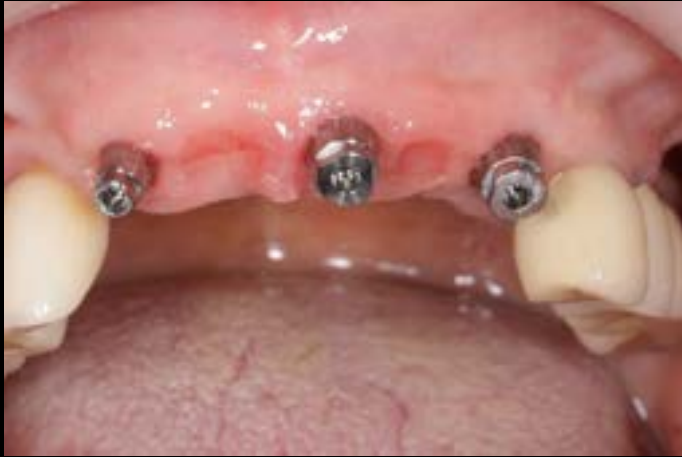Bite Tray Impression





# BOS Clinical Case w.BTS

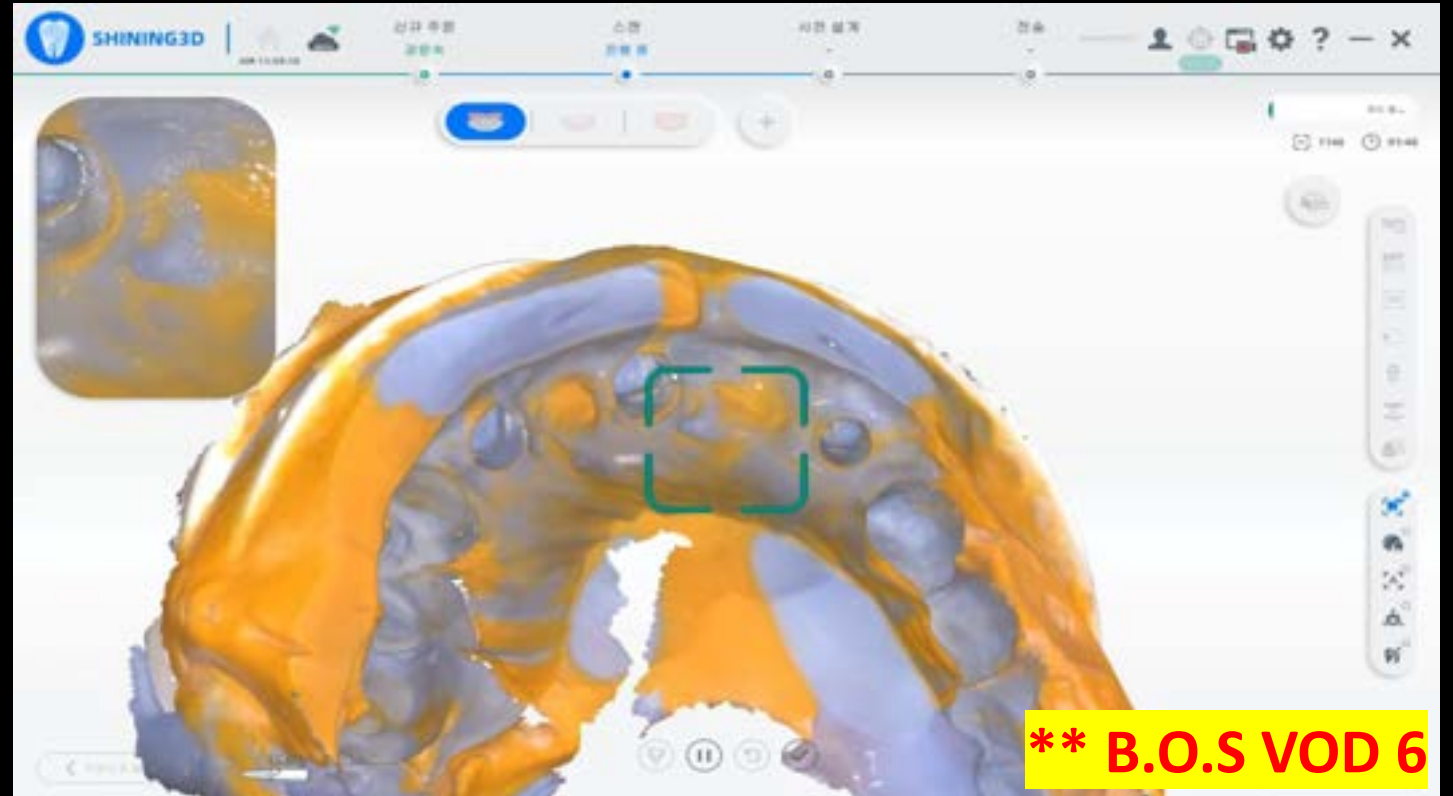
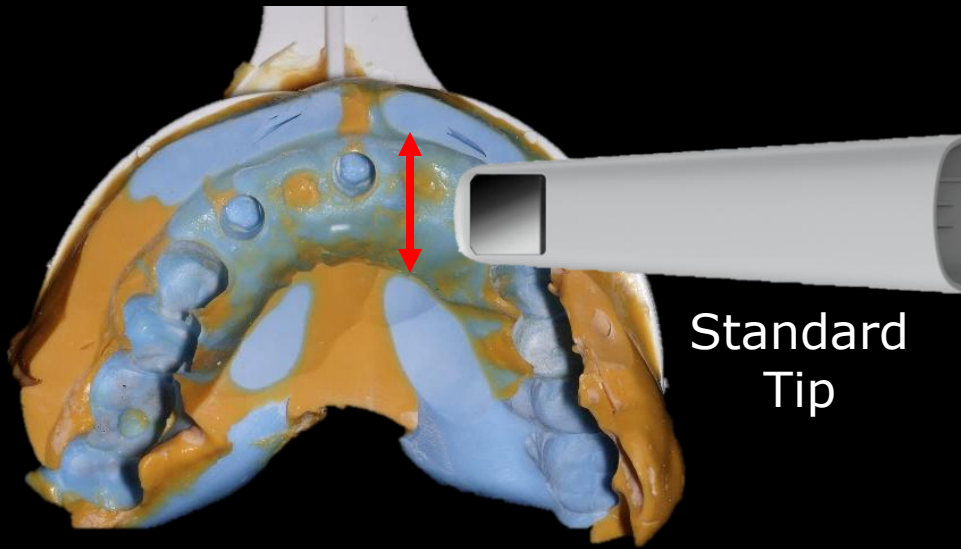
**BTS** for Digital Abutment +Zirconia DEL



Digital Abutment & Final Impression

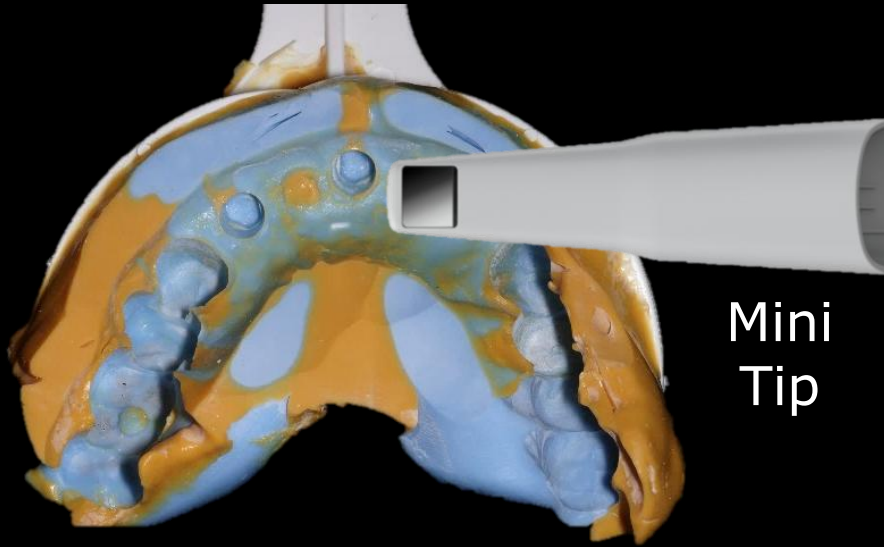
# BOS Clinical Case w.BTS

BOS (Bite Tray impression scanning With IOS)

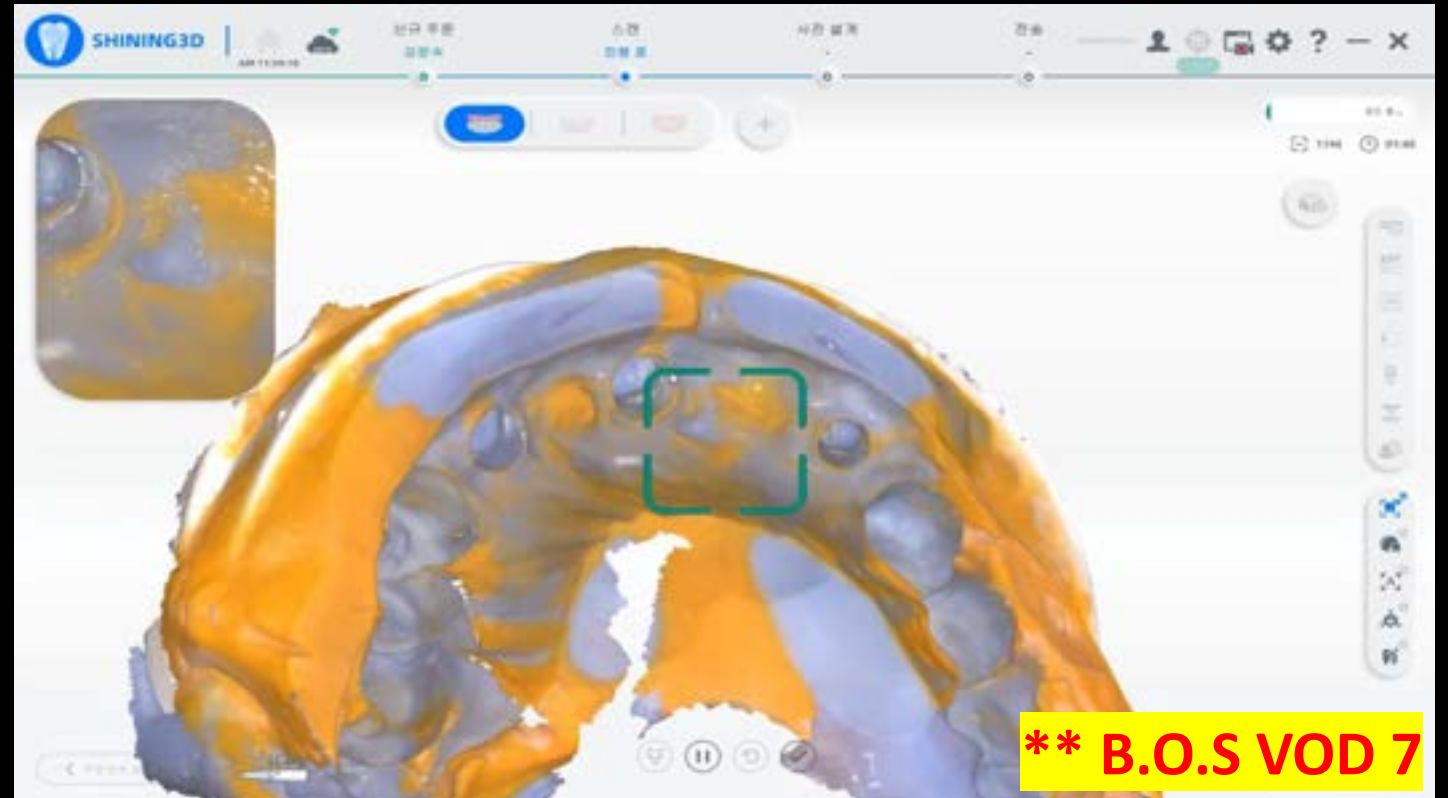


# BOS Clinical Case w.BTS

BOS (Bite Tray impression scanning With IOS)



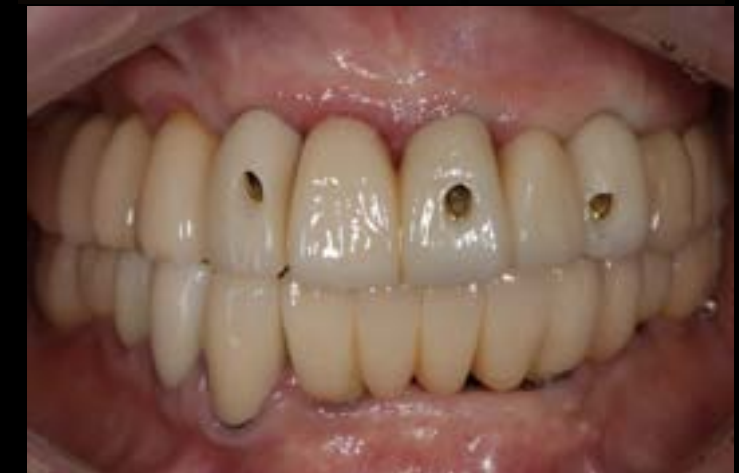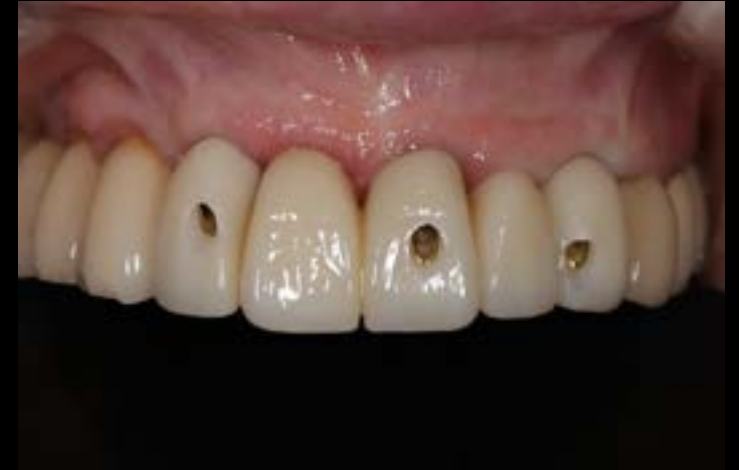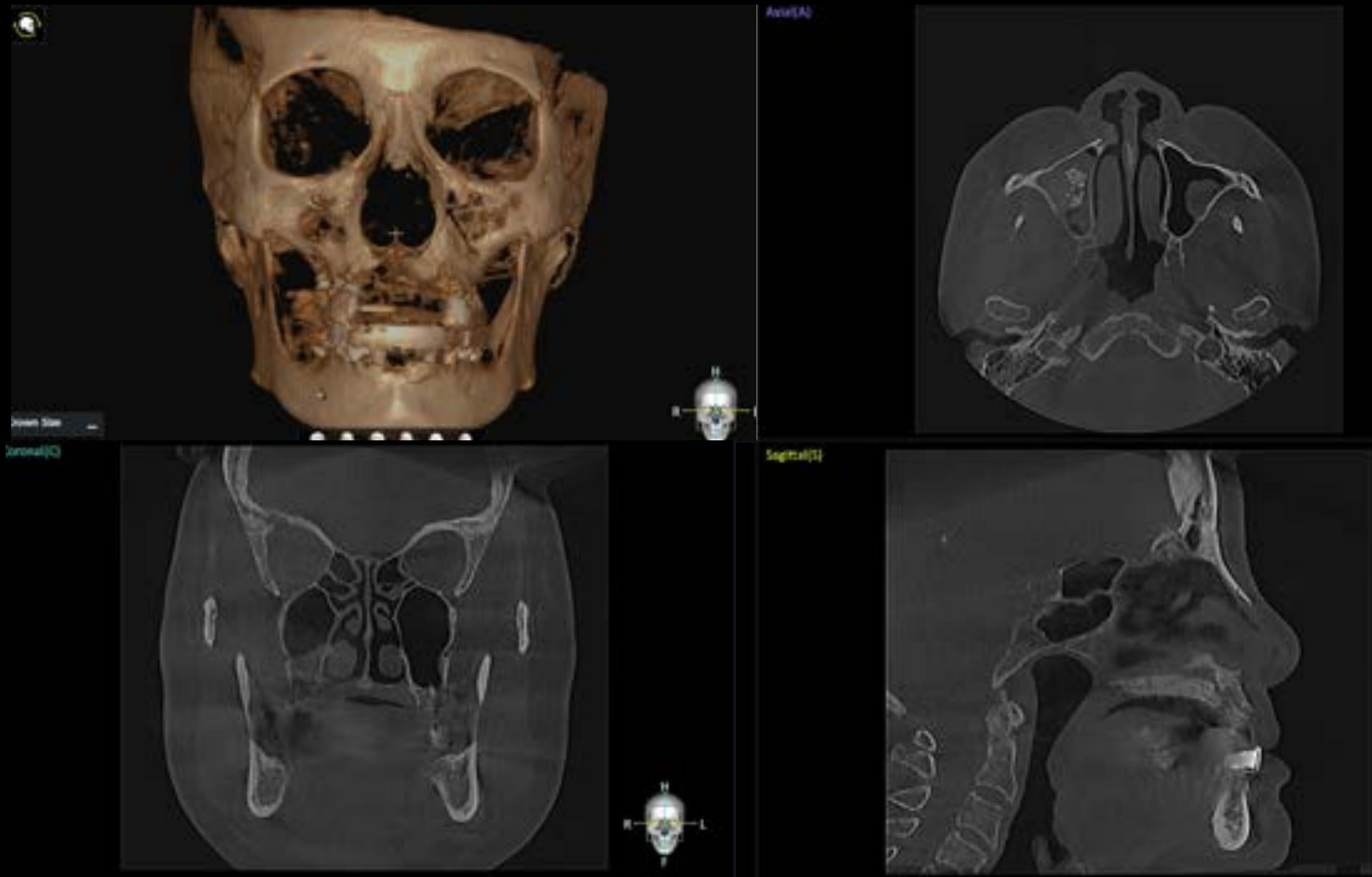
Mini  
Tip





# BOS Clinical Case w.BTS

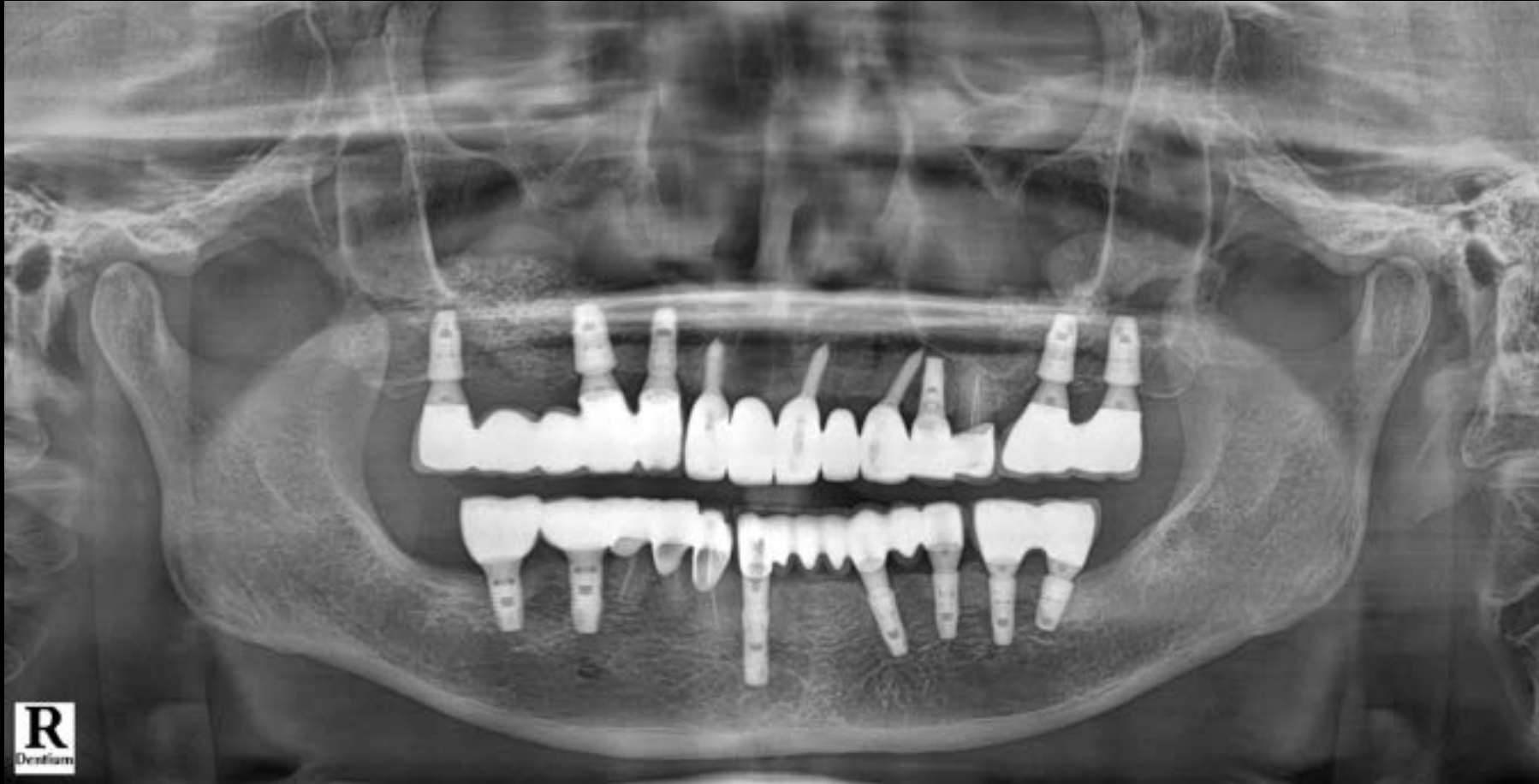## CT Data





# BOS Clinical Case w.BTS

## Panorama



# Full Mouth Clinical Case

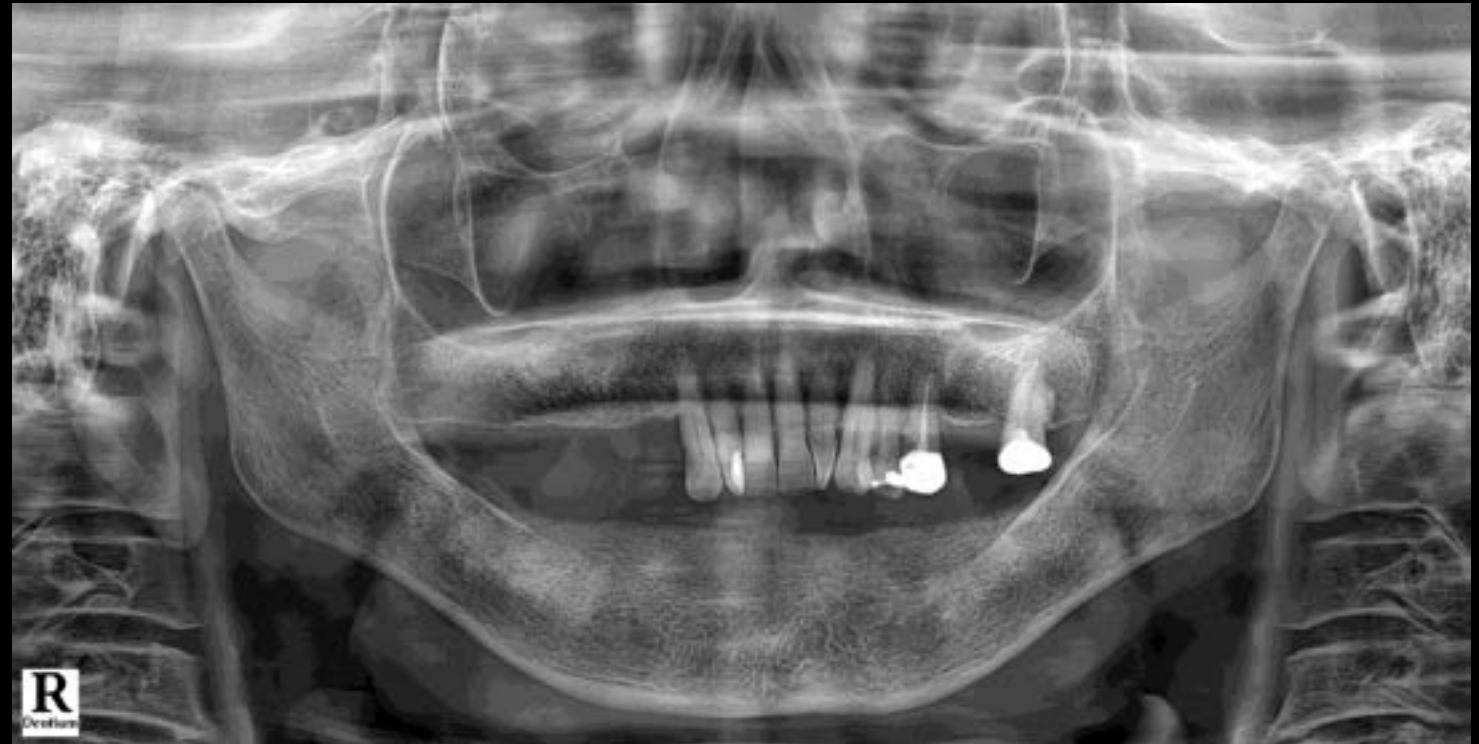Age: 70s / F

CC : Implant Consultation Requested

Plan)

7	5	4		6	Implant Surgery		
7	5	4	3	3	4	5	7

Natural teeth & ALL Crown (VD Up)

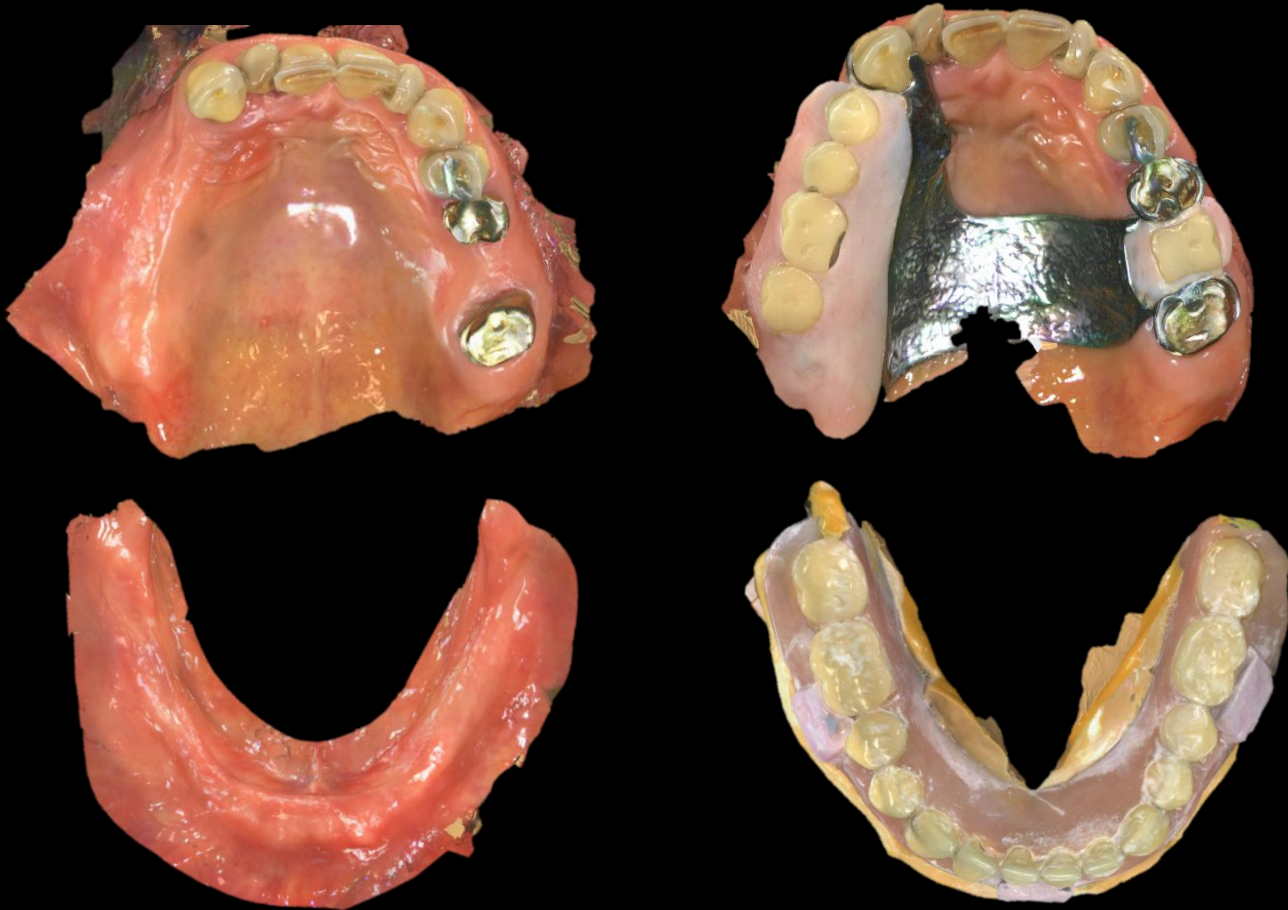


PANORAMA

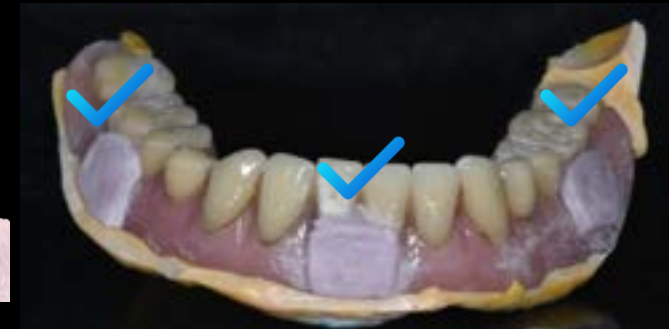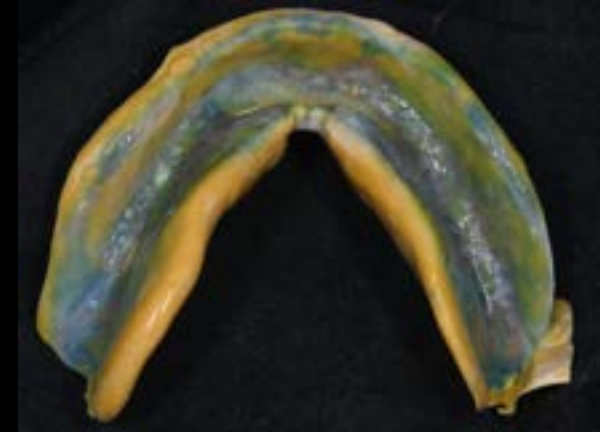# Full Mouth Clinical Case

## 1 Preparation before Surgery

- Stent Fabrication using Existing Denture (w. Intra Oral Scan and CT Scan)



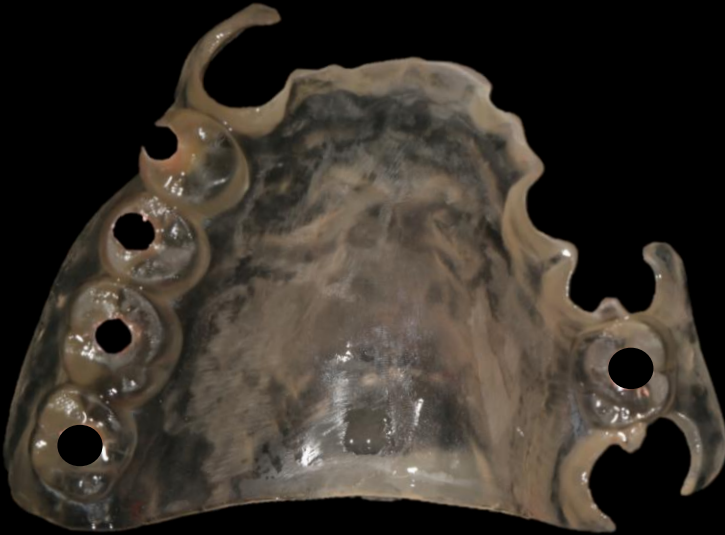SCAN (PrimeScan)



- Using Mandibular Denture for **IMP**
- Ensure Retention of FULL Mandibular Denture
- Marking for CT Scan

# Full Mouth Clinical Case

- 1 Preparation before Surgery
  - CT Taking with Marked Denture



Existing Maxillary RPD  
Replication & Hole Formation  
→ Position CK using Stopper



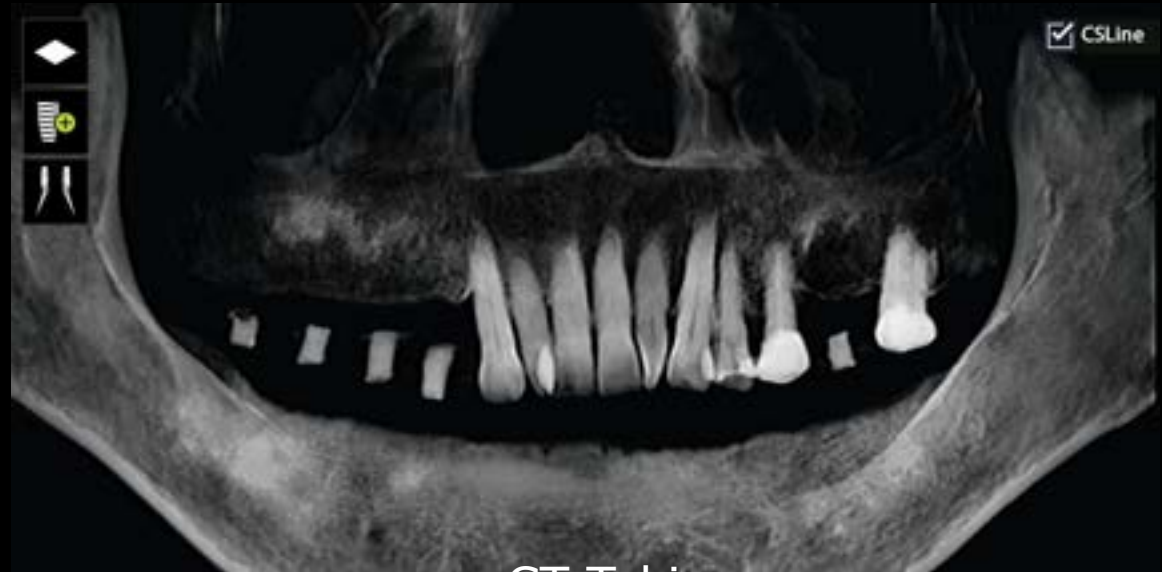Mandibular Surgical Stent  
#43 #33

# Full Mouth Clinical Case

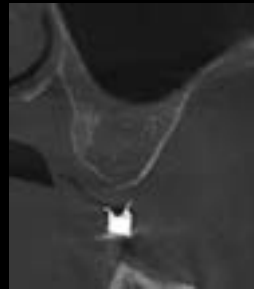- 1 Preparation before Surgery
  - CT Taking with Marked Denture



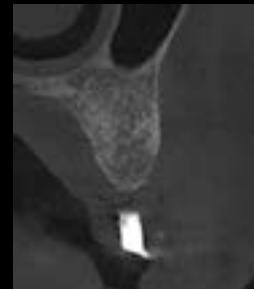Existing Maxillary RPD  
Replication & Hole Formation  
→ Position CK using Stopper



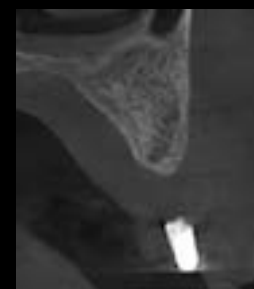CT Taking



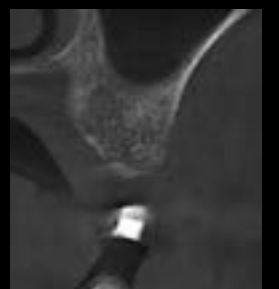# 17



# 15



# 14

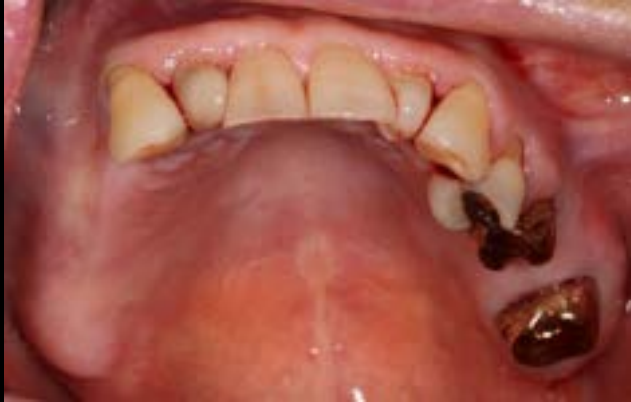

# 26

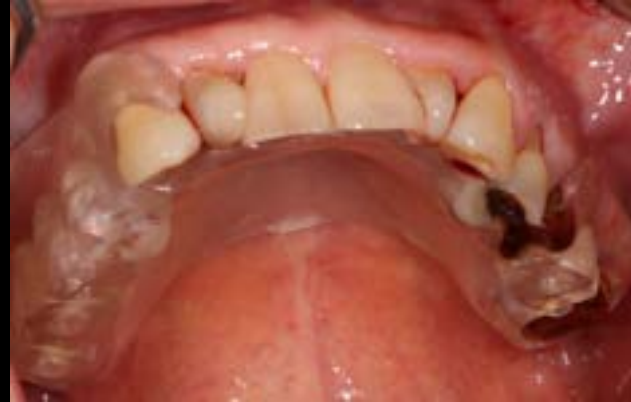

# Full Mouth Clinical Case

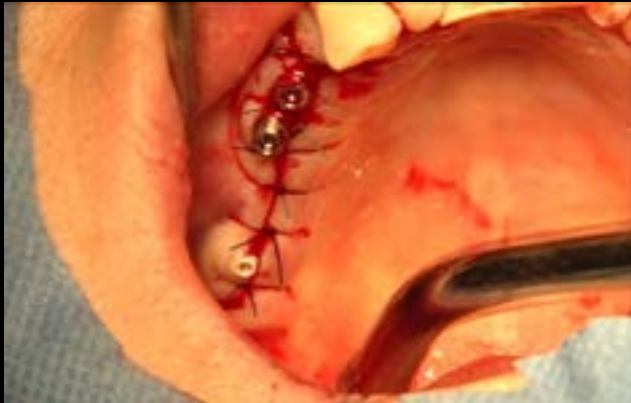## 2 Maxillary Implant Surgery



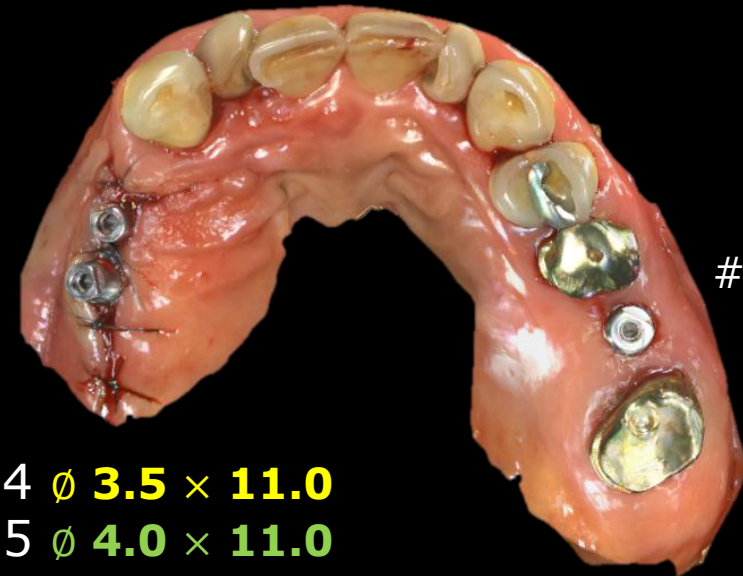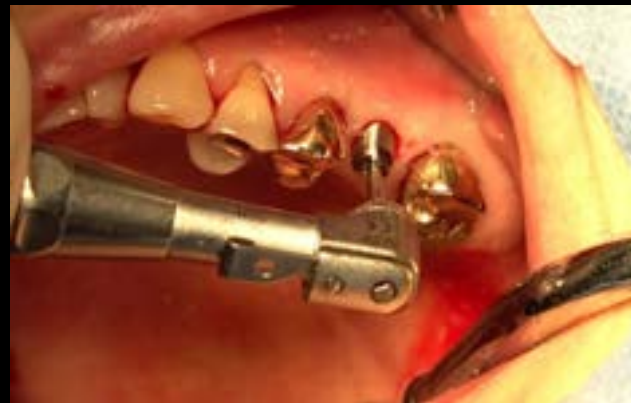Pre -OP



Adaptation of Replicated Denture



bright Tissue Level



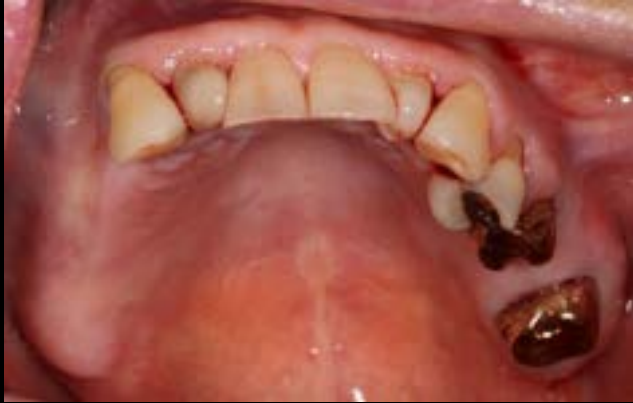#14  $\emptyset$  3.5 × 11.0  
#15  $\emptyset$  4.0 × 11.0  
#17  $\emptyset$  5.0 × 11.0

#26  $\emptyset$  4.5 × 9.0

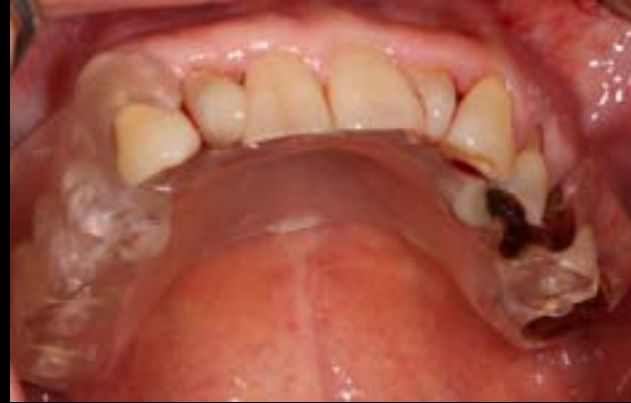Post – OP

# Full Mouth Clinical Case

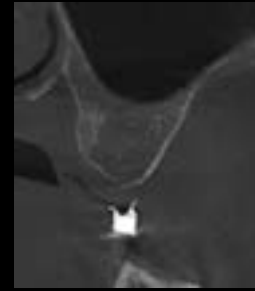## 2 Maxillary Implant Surgery



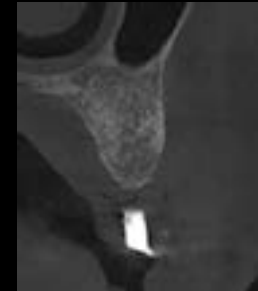
Pre -OP



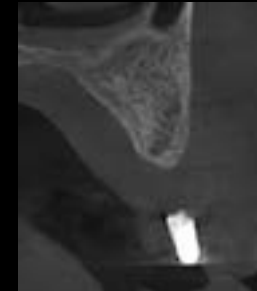Adaptation of Replicated Denture



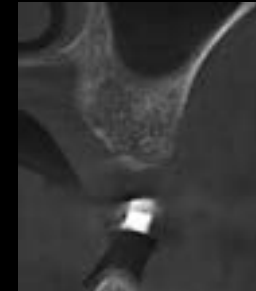# 17



# 15

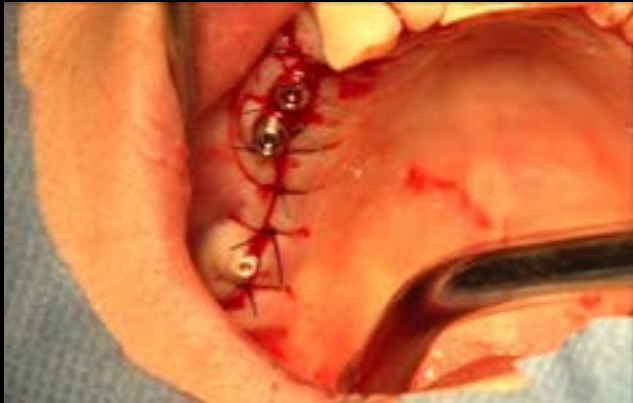

# 14

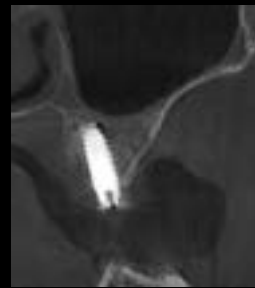

# 26

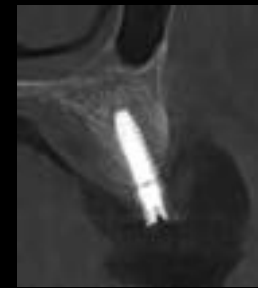
Pre -OP



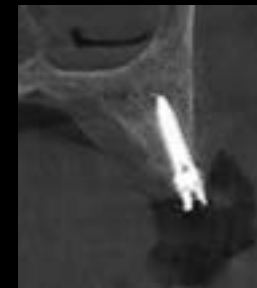bright Tissue Level



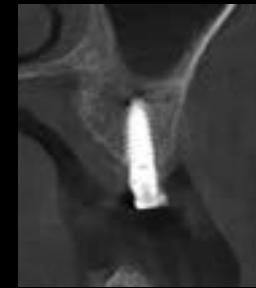# 17



# 15



# 14



# 26

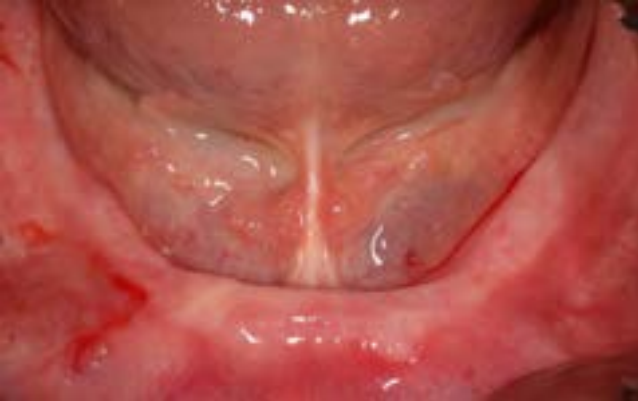Post - OP



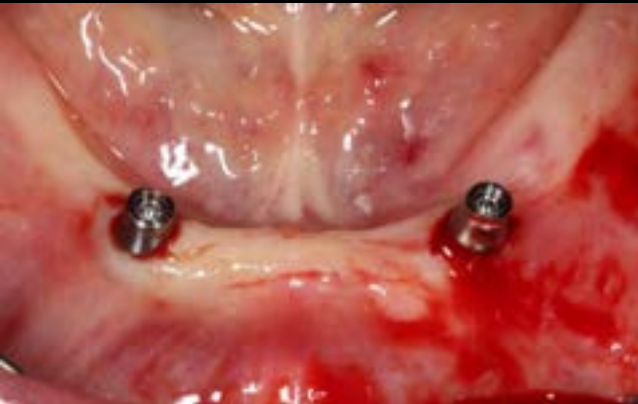# Full Mouth Clinical Case

## 3 1<sup>st</sup> Maxillary Implant Surgery

- Implant Placement at #43 #33, with Existing FD Ball Abutment

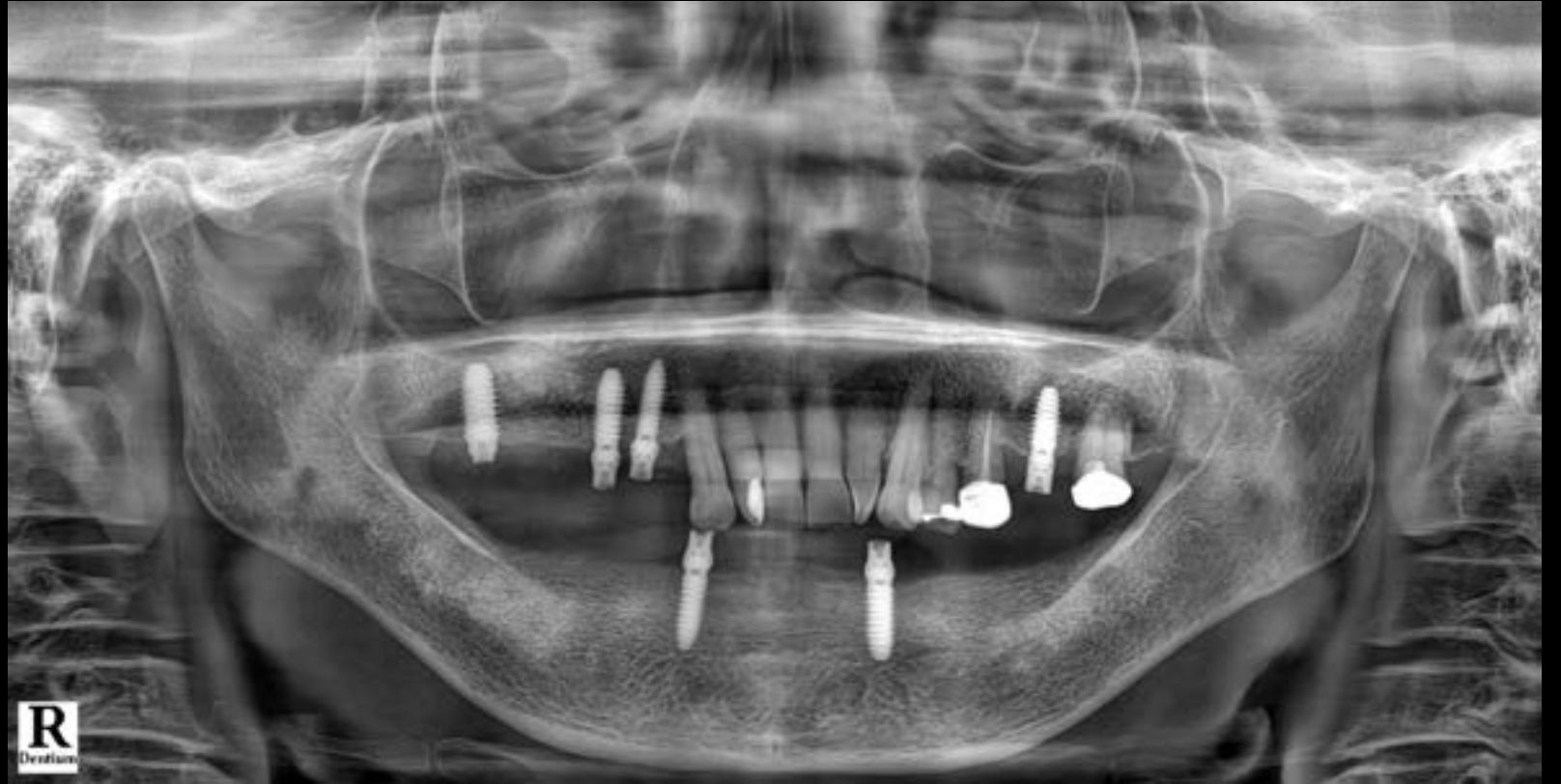

Pre -OP



bright Tissue Level

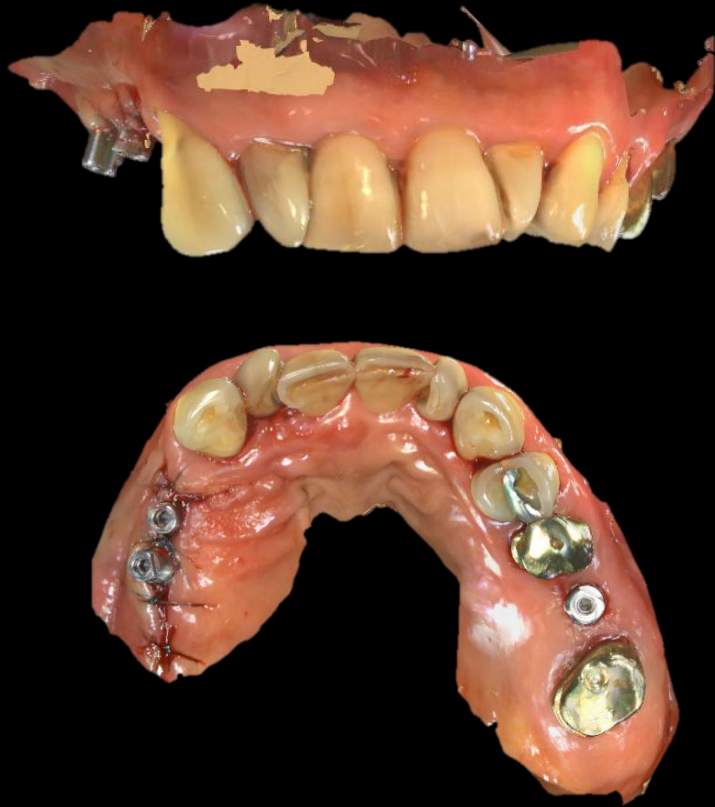#43 Ø 3.5 × 11.0 #33 Ø 4.0 × 11.0



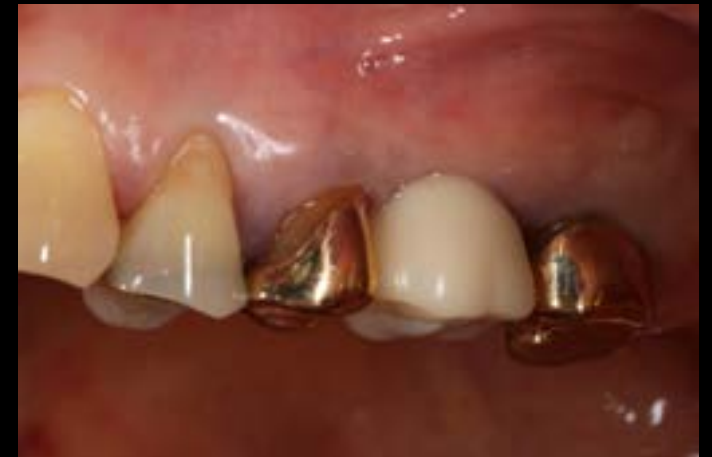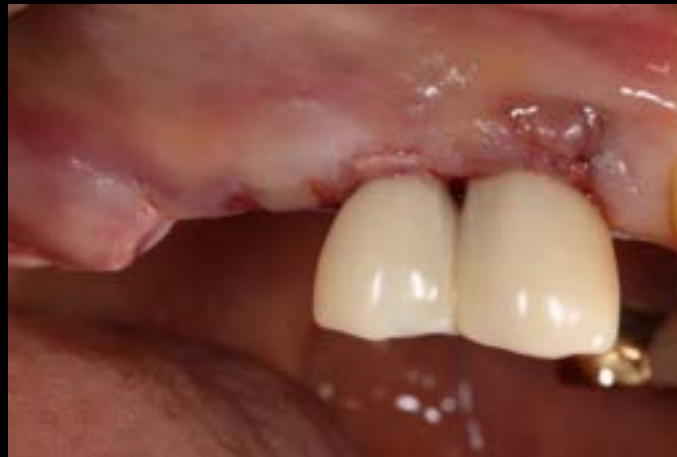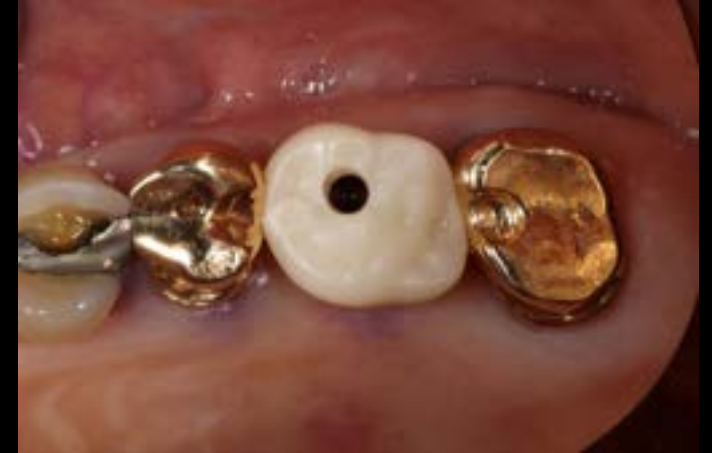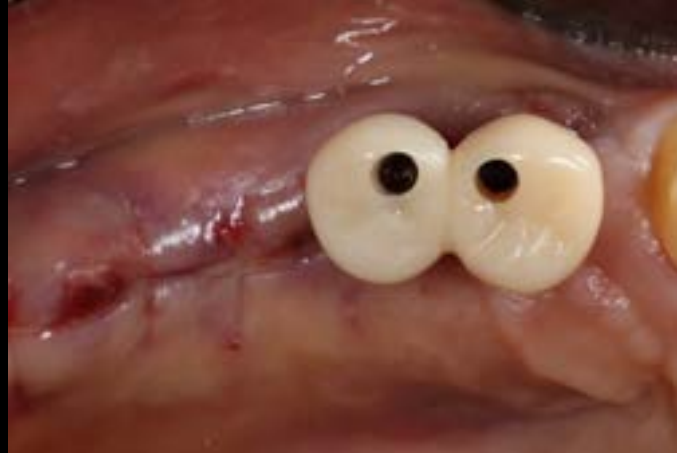PANORAMA

# Full Mouth Clinical Case

4 Intra Oral Scan & Provisional Restoration



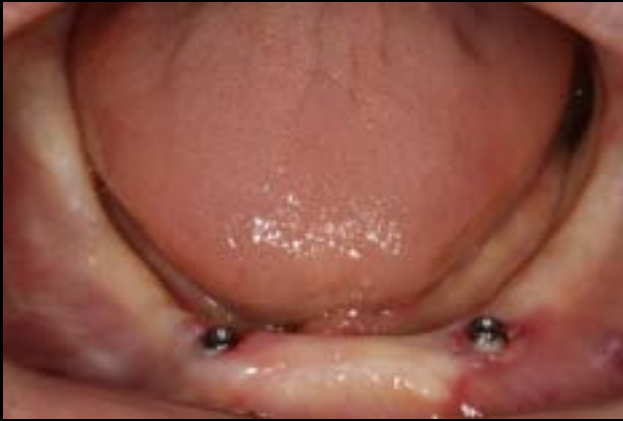SCAN (w. Prime Scan)



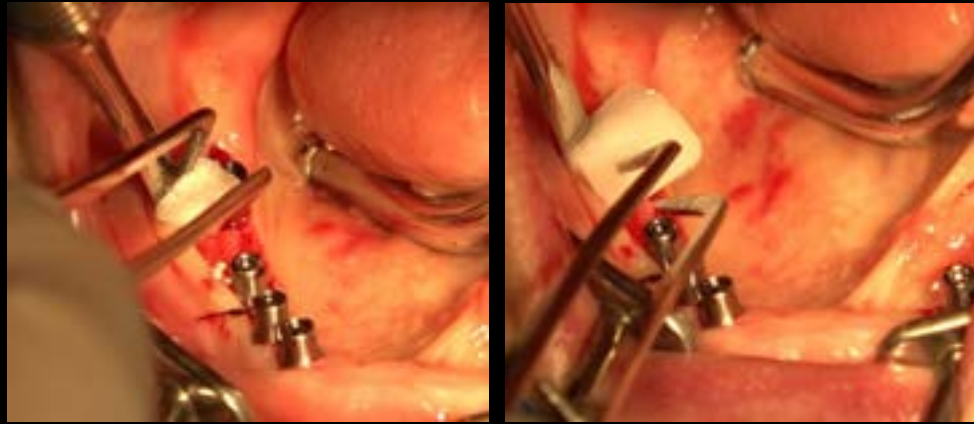
Abutment + Temporary DEL

# Full Mouth Clinical Case

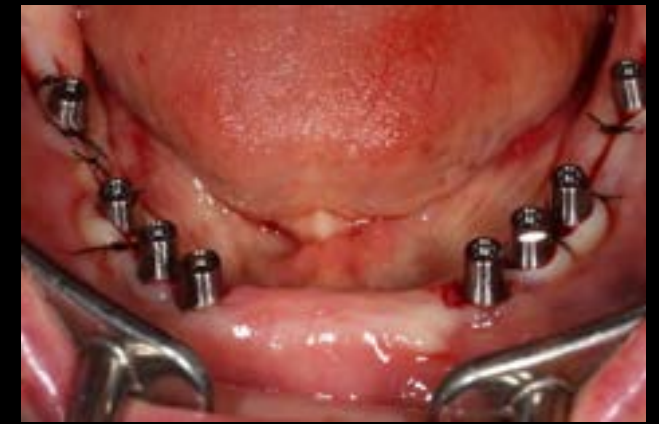## 5 2<sup>nd</sup> Mandibular Implant Surgery



Pre – OP



bright Tissue Level  
#40s Bone Graft  
+Osteon 3 Collagen  
+Collagen Graft x1D  
+PDRN

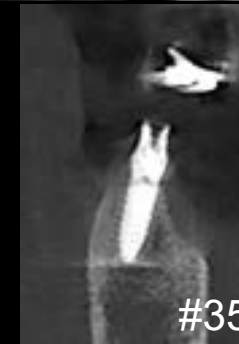
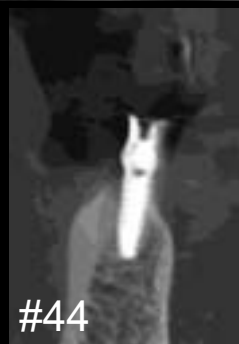
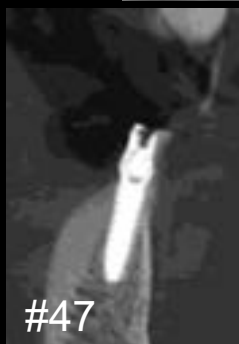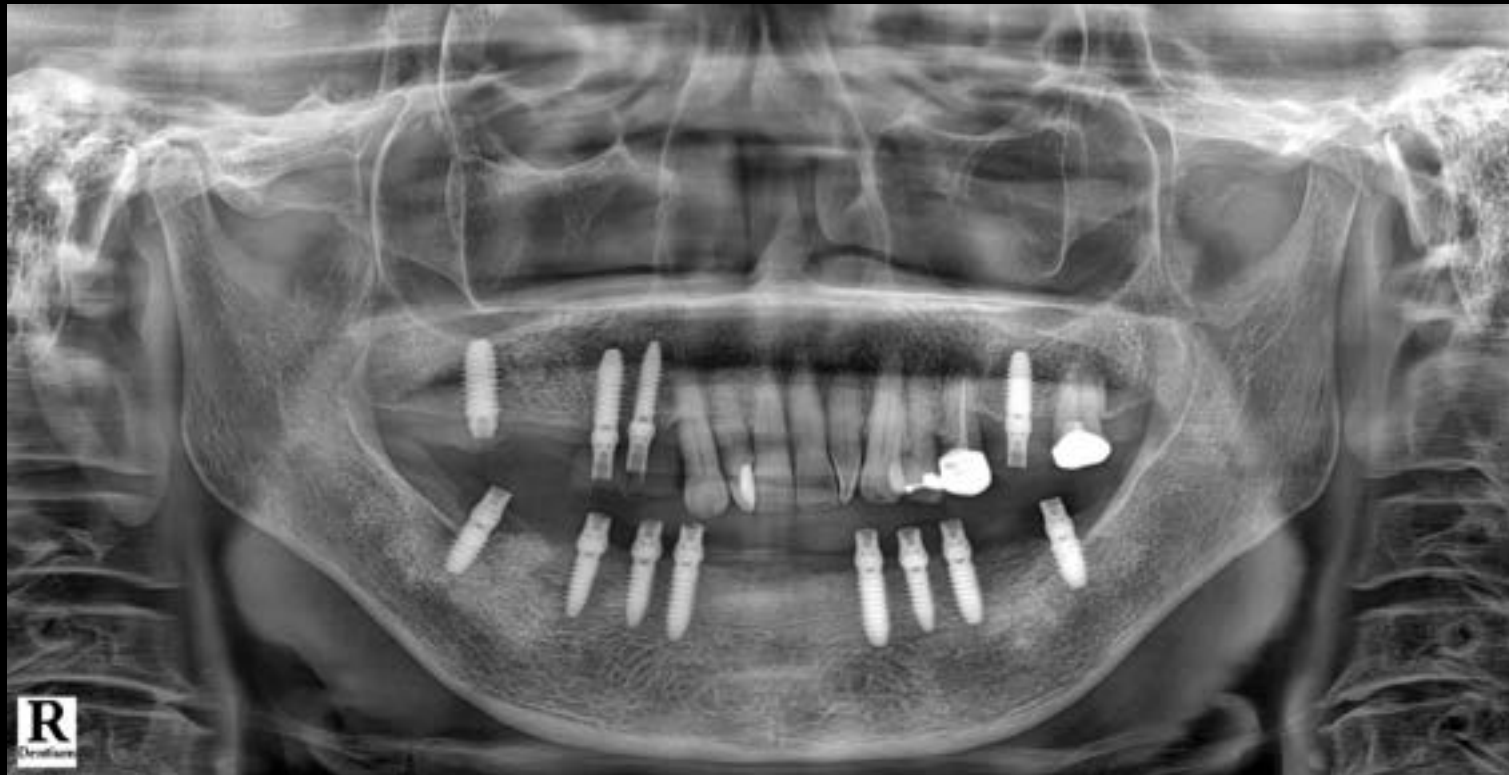Post - OP

#44 Ø 3.5 × 9.0	#34 Ø 3.5 × 9.0
#45 Ø 3.5 × 9.0	#35 Ø 4.0 × 9.0
#47 Ø 4.5 × 7.0	#37 Ø 4.5 × 7.0

# Full Mouth Clinical Case

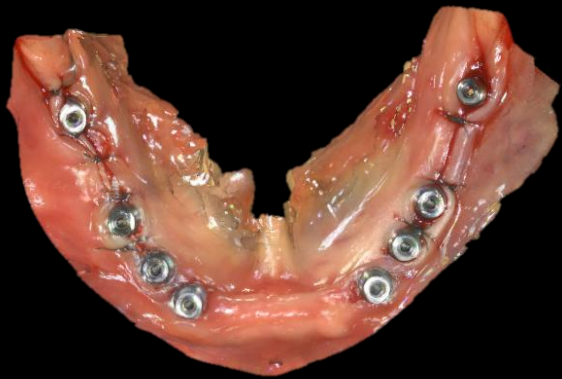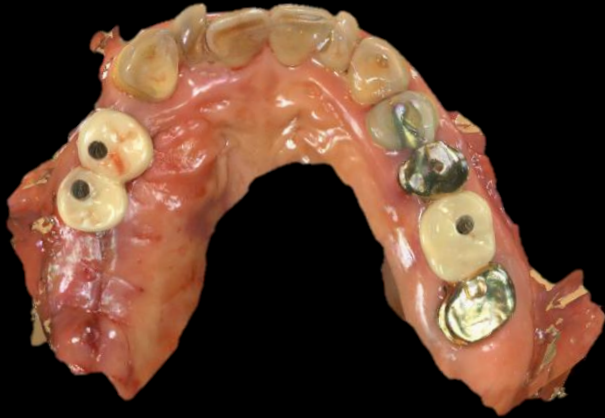CT & PANORAMA



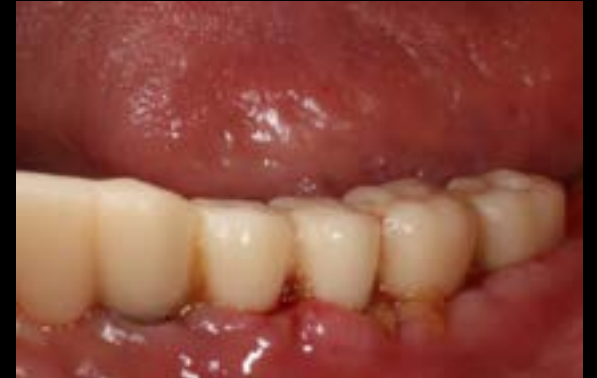
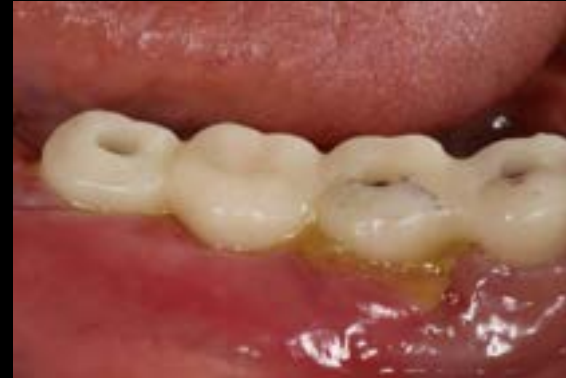
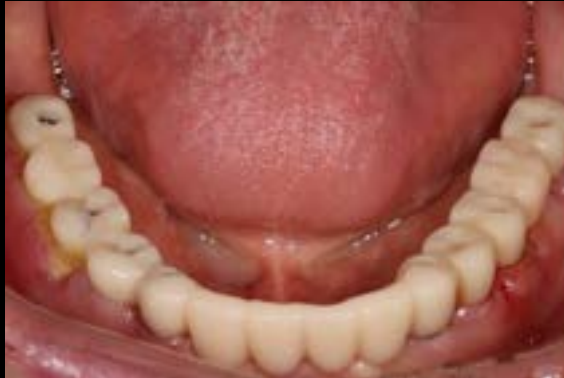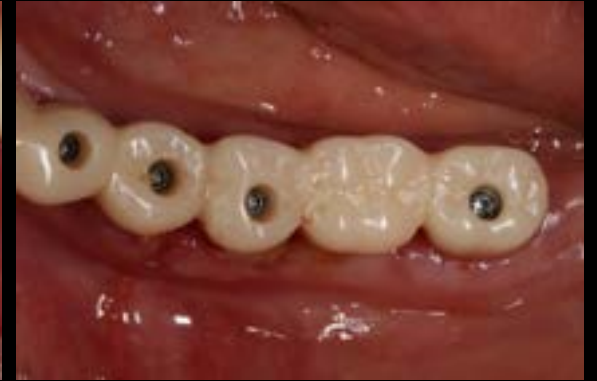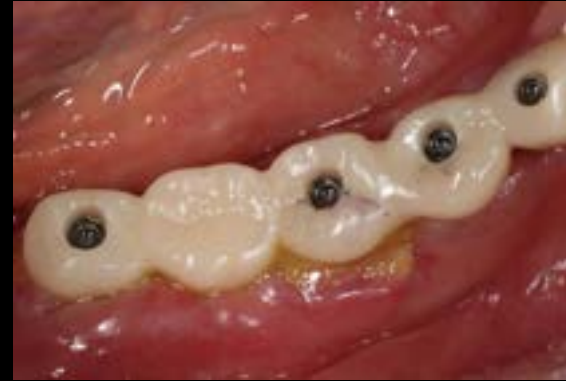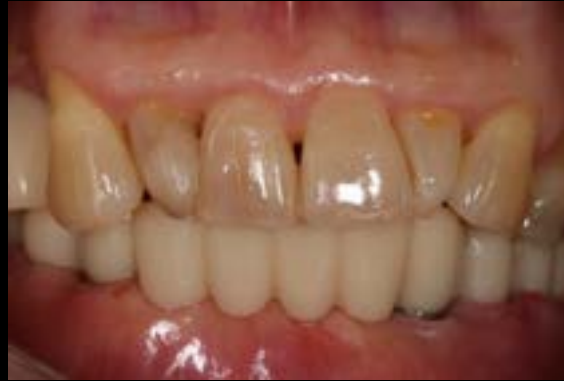# Full Mouth Clinical Case

6 Intra Oral Scan & Provisional Restoration



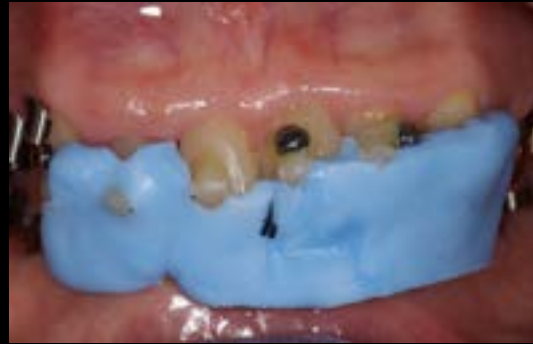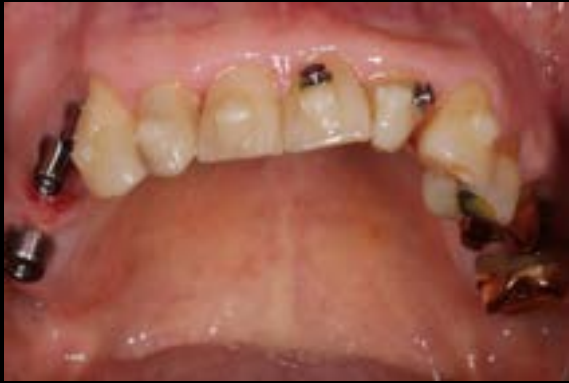SCAN



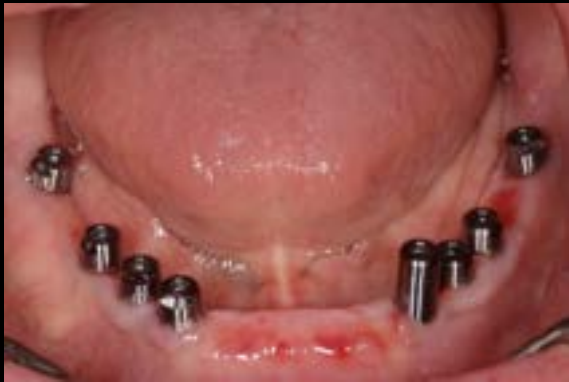After 1 week : Abutment + Provisional Crown DEL  
(Temporary Crown Fabrication with Existing Denture Bite)

# Full Mouth Clinical Case

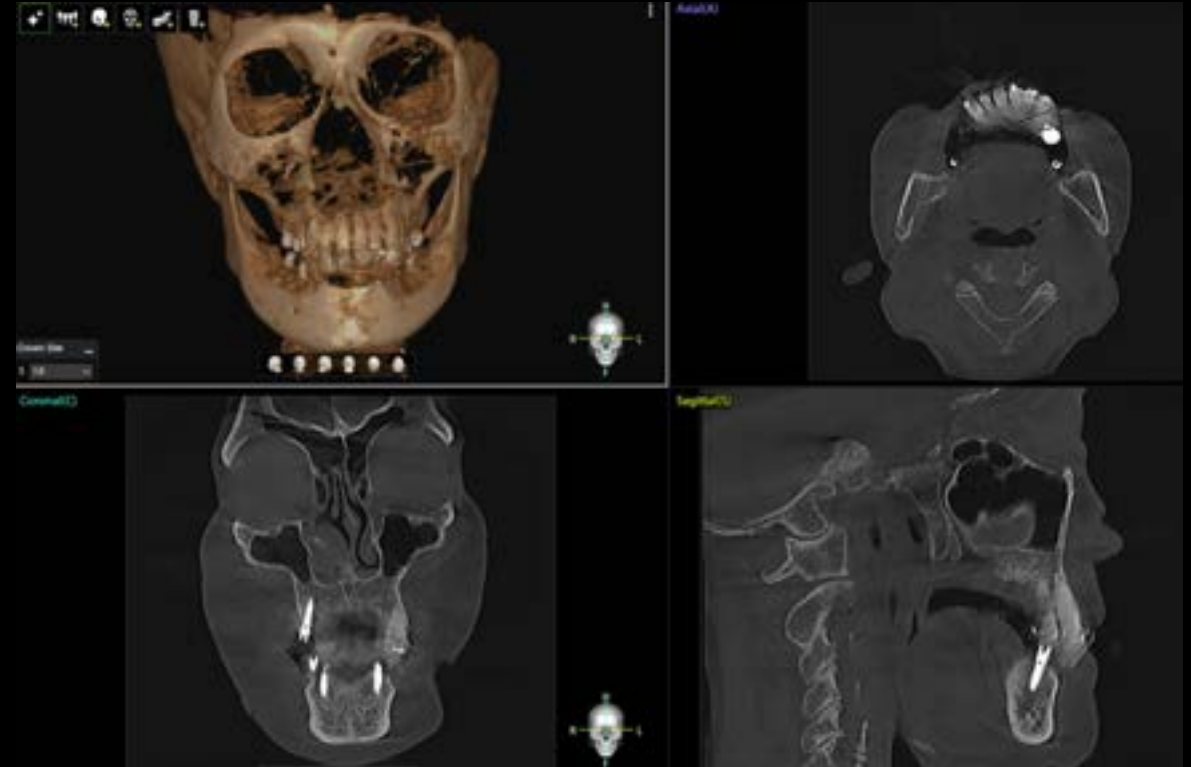
7 VD UP Temporary Crown Preparation (w. Putty Index)



Putty Index



All Scan Comfort CAP


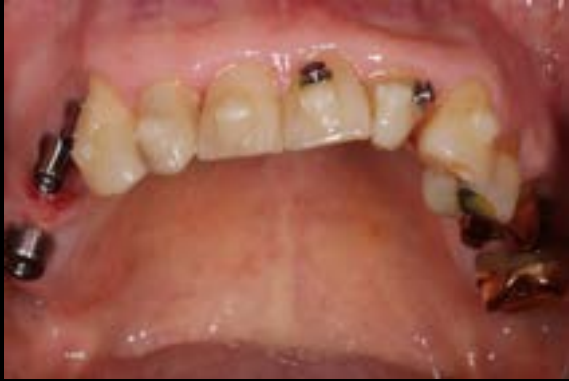
CT Taking (Stitching Mode)  
\*\*CT Scan without Bite Stick\*\*

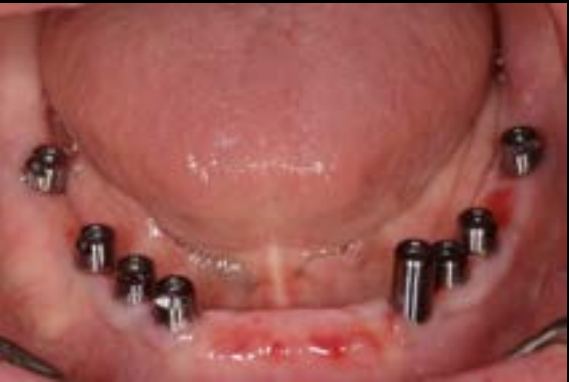

# Full Mouth Clinical Case

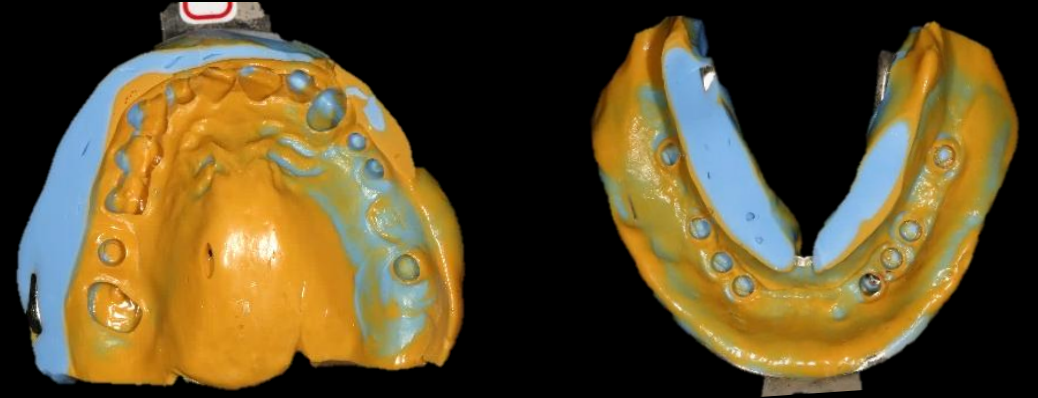
7 VD UP Temporary Crown Preparation (w. Putty Index)



Putty Index



All Scan Comfort CAP


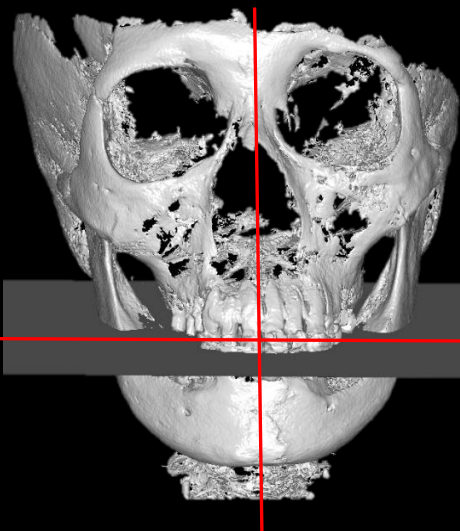


**Partial Impression**

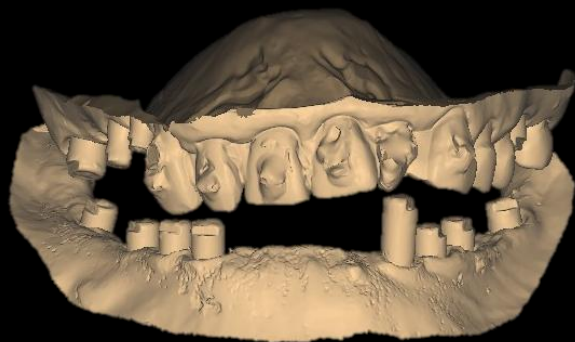
→ Sent to the Lab Without a Separate Bite Registration

# Full Mouth Clinical Case

CT STL export

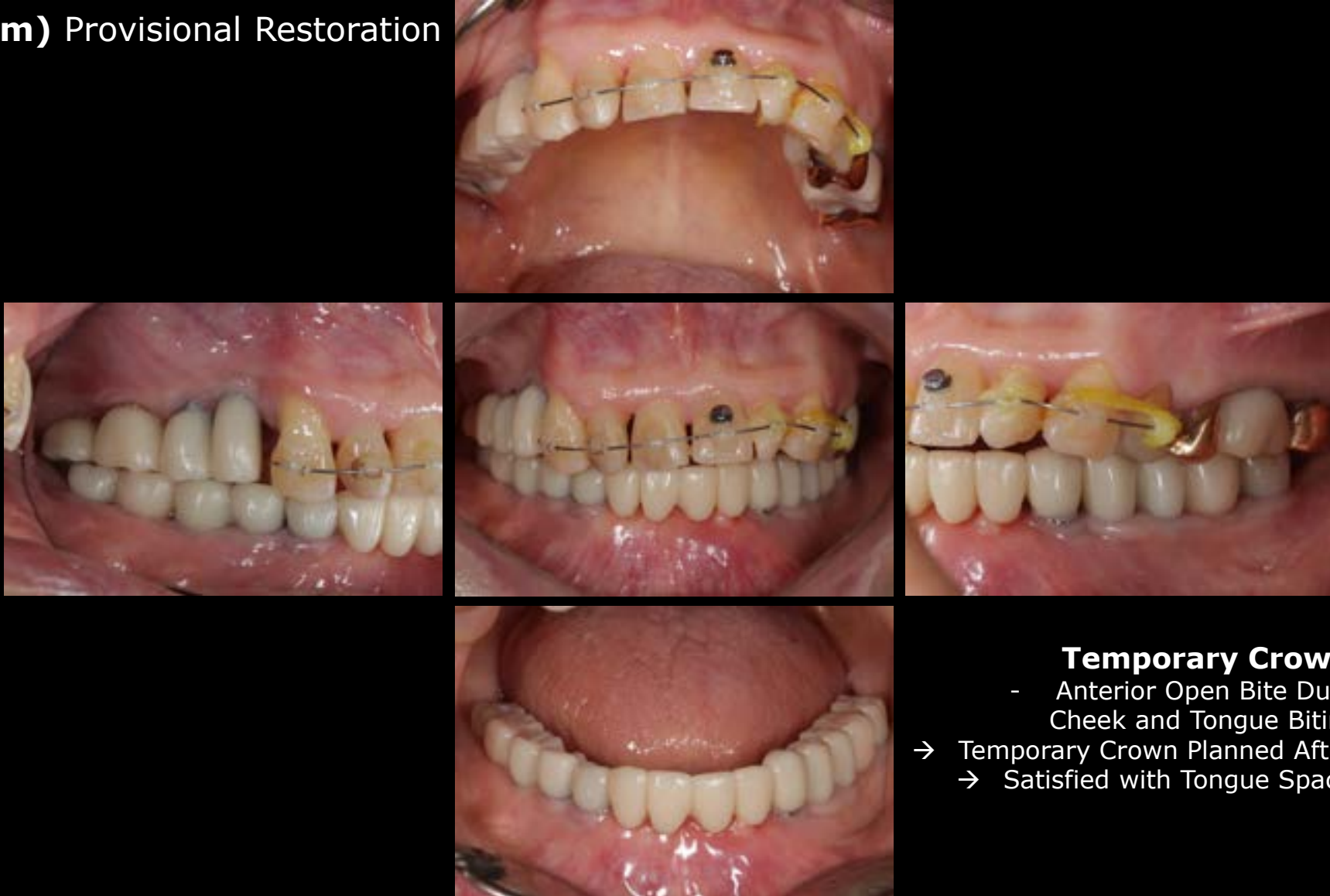

All data Stitching



# Full Mouth Clinical Case

8 VD UP(1.5mm) Provisional Restoration



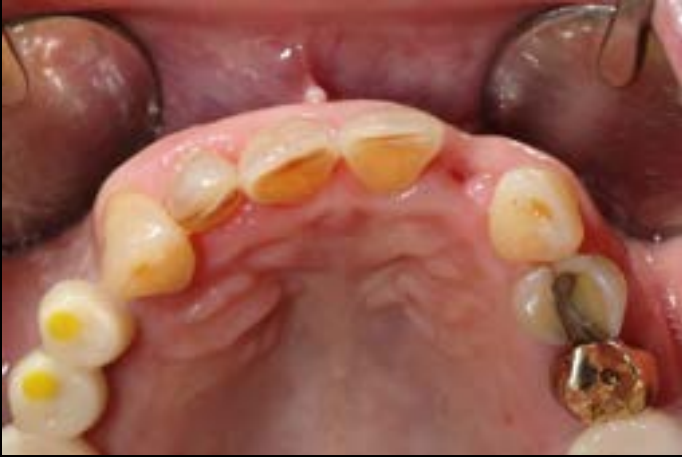## Temporary Crown Delivery

- Anterior Open Bite Due to VD Increase, Cheek and Tongue Biting Symptoms
- Temporary Crown Planned After Orthodontic Finishing,  
→ Satisfied with Tongue Space and Facial Changes

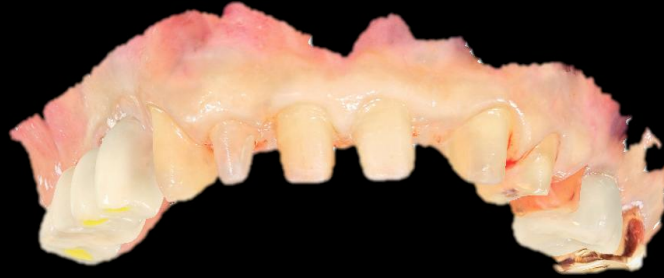

# Full Mouth Clinical Case

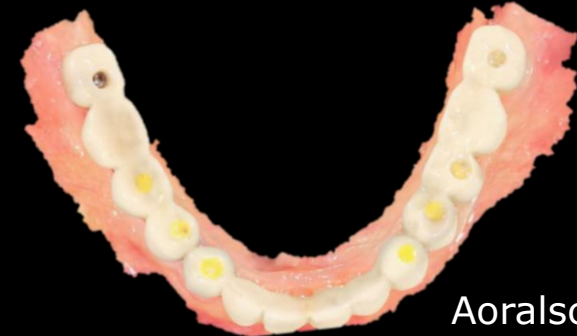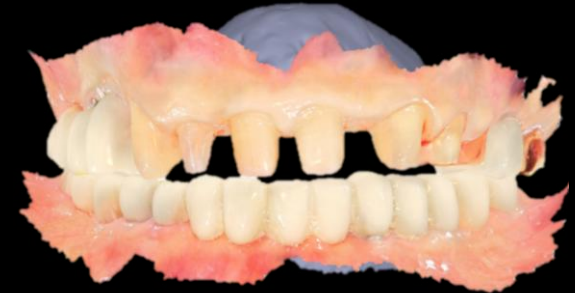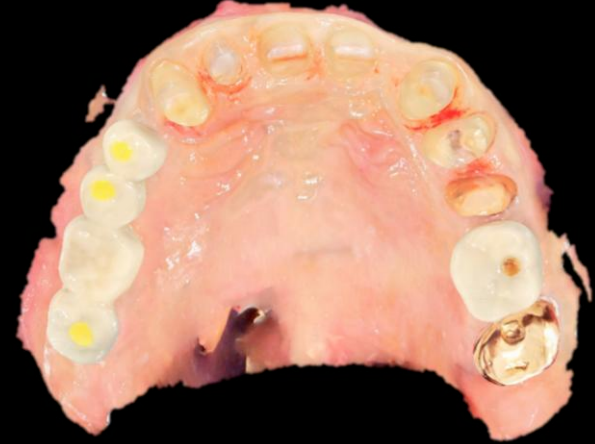
## 9 Natural Tooth Preparation



Pre - op



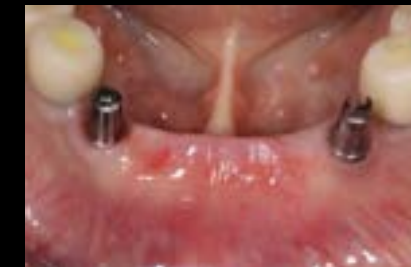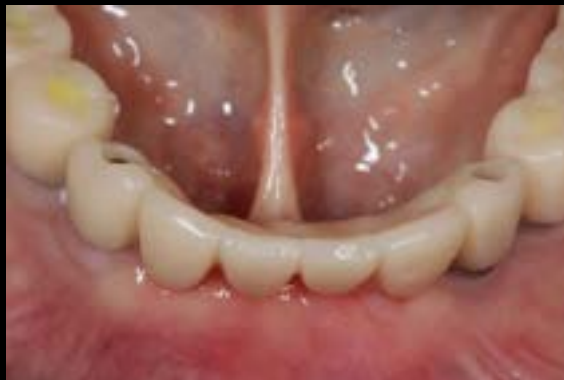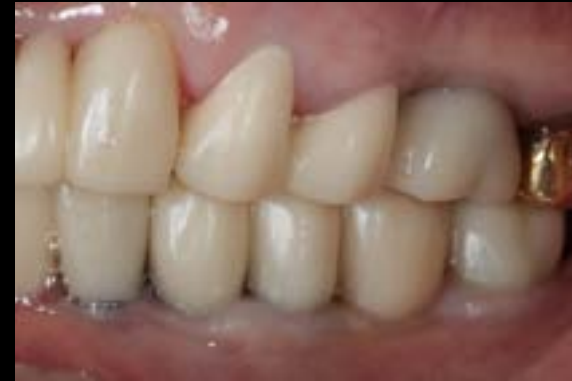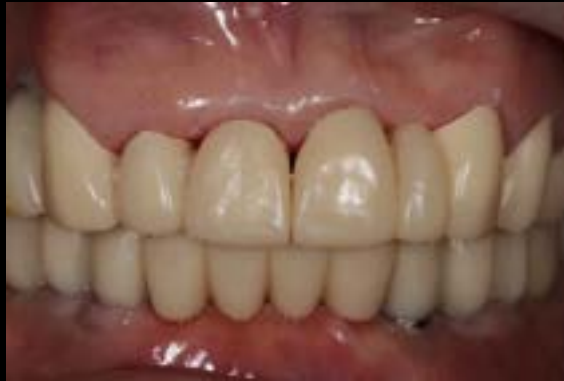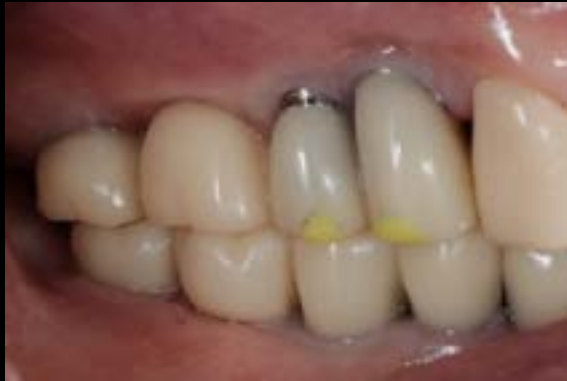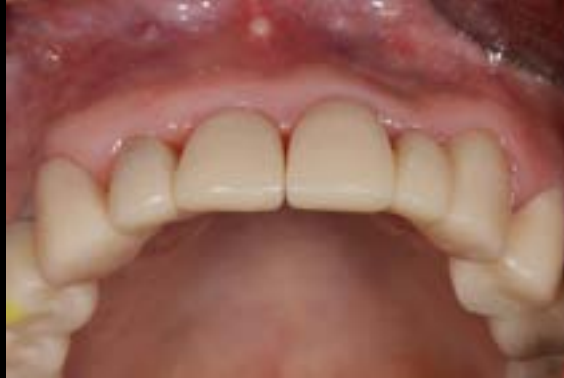Tooth Preparation



Aoralscan3 Wireless

# Full Mouth Clinical Case

9 Temporary Crown DEL on Natural Teeth  
→ VD Increased by 1.5mm

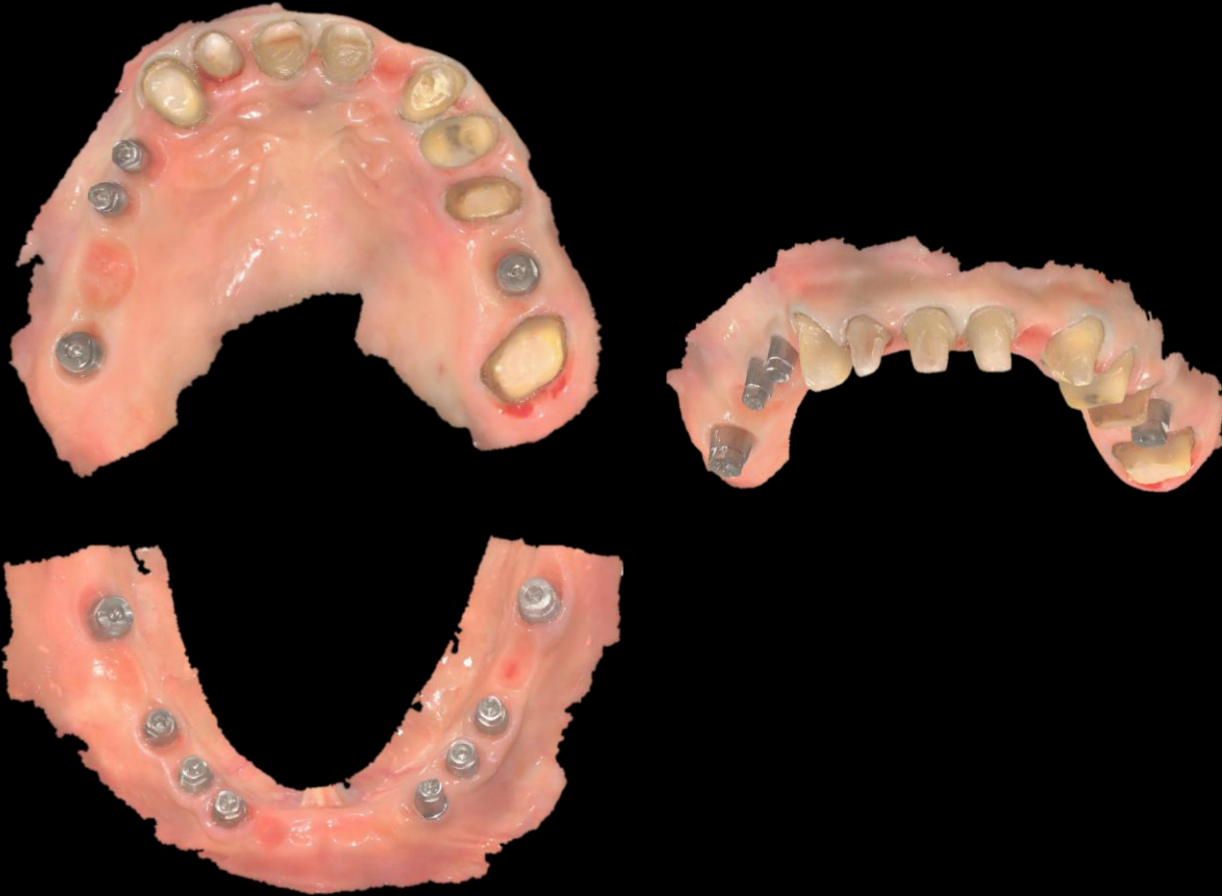

#43 #33  
Ti-base  
Hole Directed Lingually

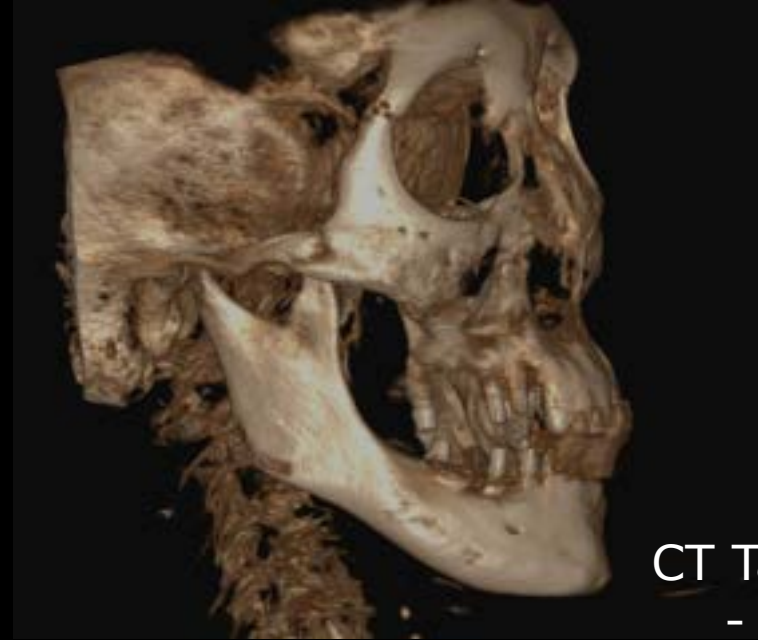

# Full Mouth Clinical Case

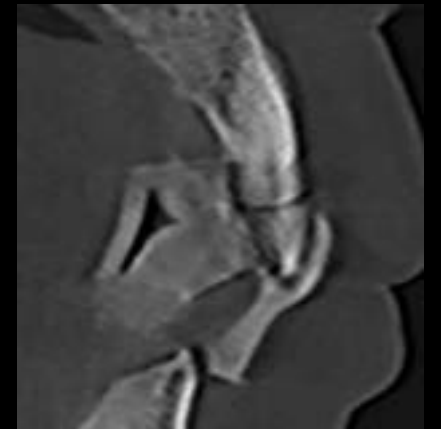
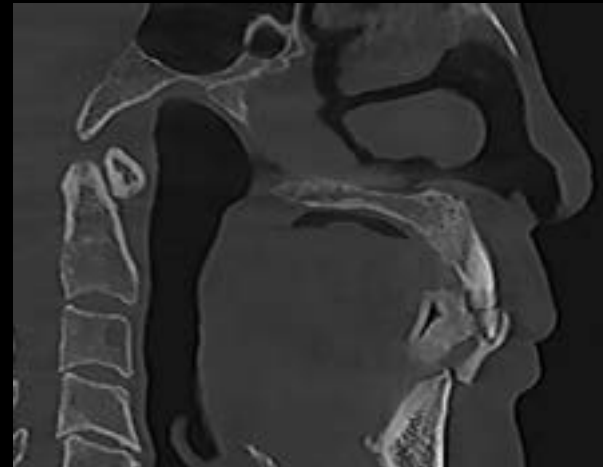
10 Final Impression & Delivery after 6 months



Shining 3D AoralScan3 Wireless

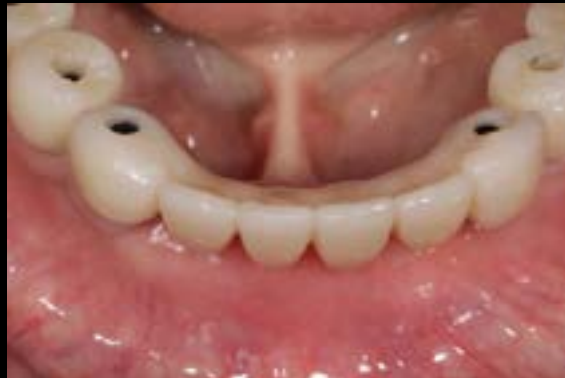
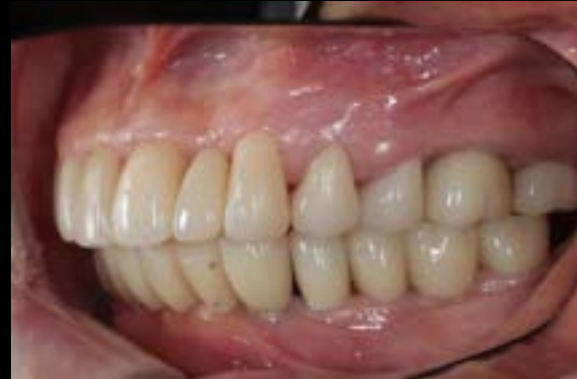
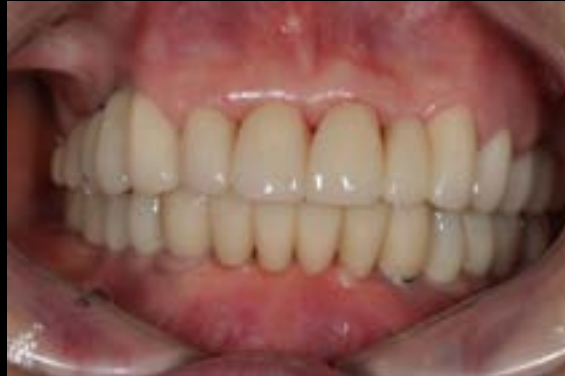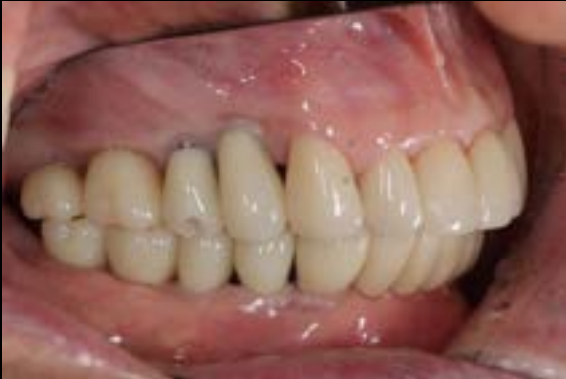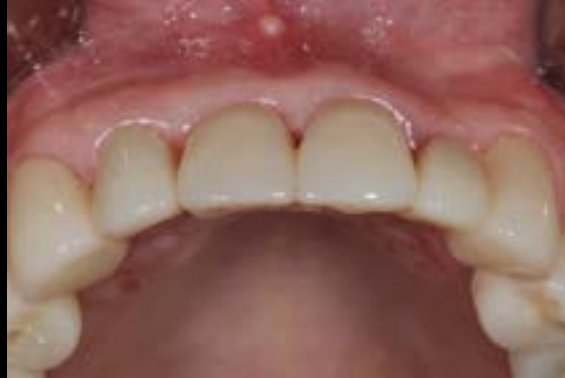CT Taking(Stitching Mode)  
- Putty Index CK



# Full Mouth Clinical Case

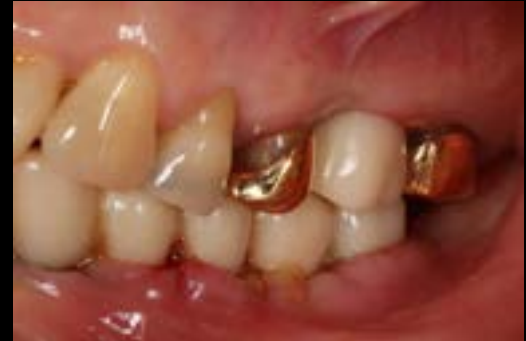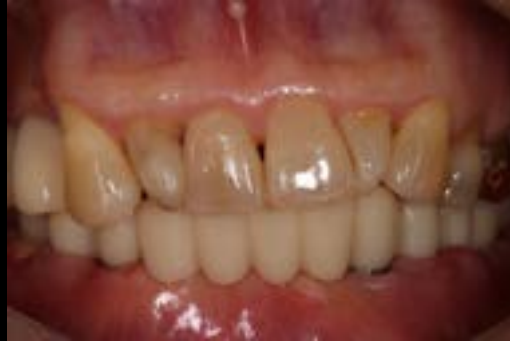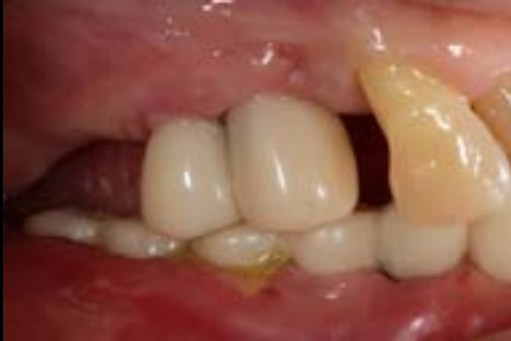10 Final Impression & Delivery  
after 6 months  
→ VD Increased by 1.5mm



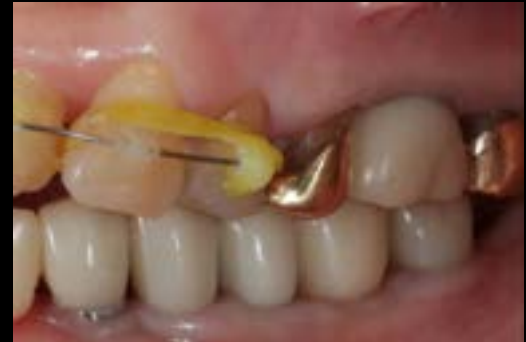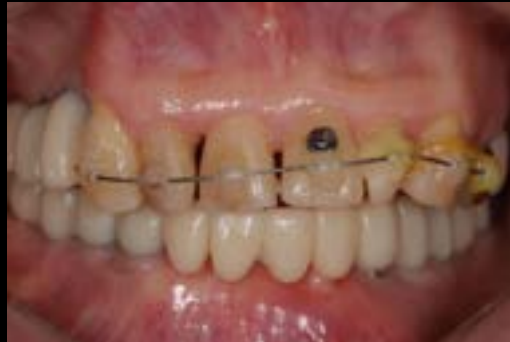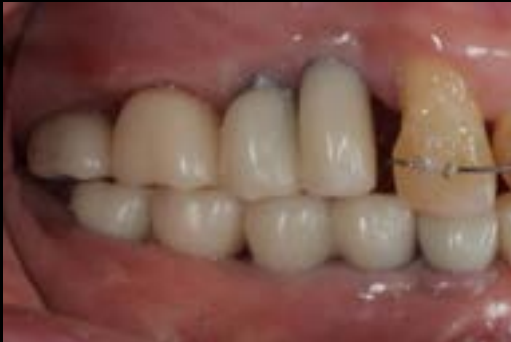# Full Mouth Clinical Case

\* VD Changes \*

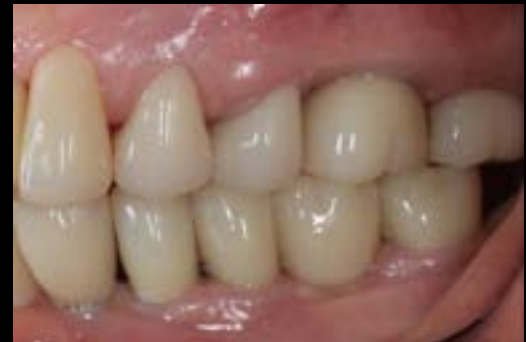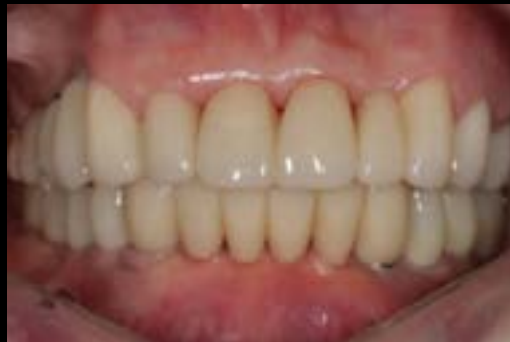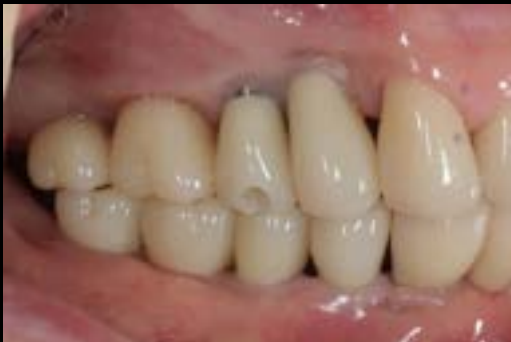Existing Denture Bite



1<sup>st</sup> VD UP (1.5mm)  
Provisional Crown

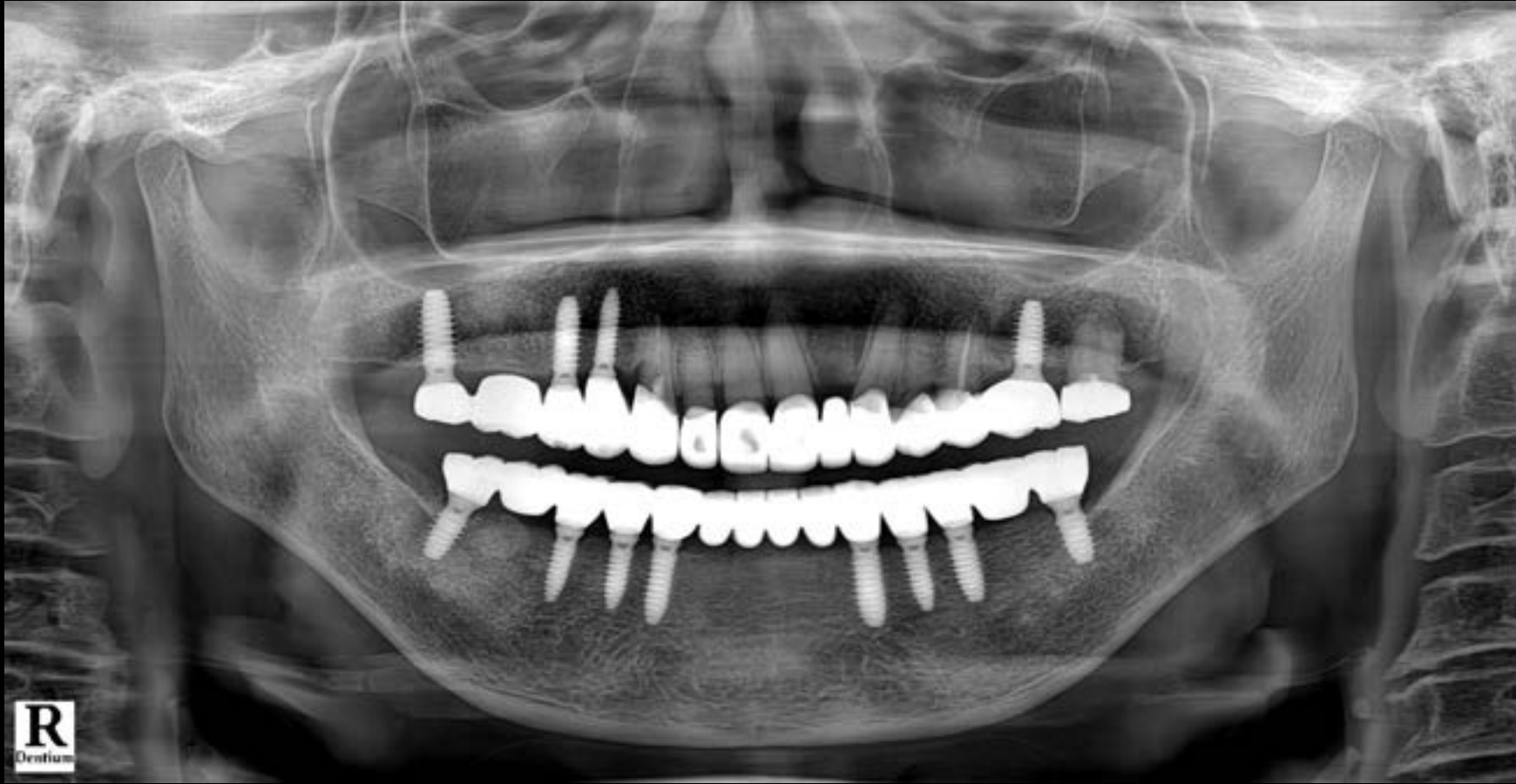

3<sup>rd</sup> VD UP (1.5mm)  
Permanent Crown



\* Total 4.5mm VD UP!! \*

# Full Mouth Clinical Case



PANORAMA

Thank you.

